SURGERY

A Monthly Journal Devoted to the Art and Science of Surgery

Editors

ALTON OCHSNER
New Orleans

OWEN H. WANGENSTEEN
Minneapolis

Associate Editor

ALFRED BLALOCK
Baltimore

Advisory Council

DONALD C. BALFOUR, Rochester, Minn.
VILRAY P. BLAIR, St. Louis
BARNEY BROOKS, Nashville
ELLIOTT C. CUTLER, Boston
WILLIAM E. GALLIE, Toronto
EVARTS A. GRAHAM, St. Louis
HOWARD C. NAFFZIGER, San Francisco
HARVEY B. STONE, Baltimore
ALLEN O. WHIPPLE, New York City

Editorial Board

FREDERICK A. COLLER, Ann Arbor
EDWARD D. CHURCHILL, Boston
VERNON C. DAVID, Chicago
LESTER R. DRAGSTEDT, Chicago
RALPH K. GHORMLEY, Rochester, Minn.
ROSCOE R. GRAHAM, Toronto
SAMUEL C. HARVEY, New Haven
FRANK HINMAN, San Francisco
EMILE F. HOLMAN, San Francisco
EDWIN P. LEHMAN, University, Va.
FRANK L. MELENEY, New York City
JOHN J. MORTON, Rochester, N. Y.
THOMAS G. ORR, Kansas City, Kan.
GEORGE T. PACK, New York City
WILDER G. PENFIELD, Montreal
ISIDOR S. RAVDIN, Philadelphia
WILLIAM F. RIENHOFF, JR., Baltimore

VOLUME 14

JULY—DECEMBER, 1943

ST. LOUIS
THE C. V. MOSBY COMPANY

COPYRIGHT, 1943, BY THE C. V. MOSBY COMPANY

(All rights reserved)

Printed in the
United States of America

Press of
The C. V. Mosby Company
St. Louis

SURGERY

Vol. 14 July, 1943 No. 1

Original Communications

CRILE, KELLY, LANE

Rudolph Matas, New Orleans, La.

THE birth of the year, 1943, was signalized by the disappearance in quick succession of three stars of the first magnitude from the firmament of surgery,—Crile, Kelly, Lane.

GEORGE WASHINGTON CRILE

World renowned surgeon—scientist, investigator, inventor, author, and leader. Born in Chili, Ohio, Nov. 11, 1864, and died at his own Cleveland Clinic, Cleveland, Ohio, at the age of 78 years, on Jan. 7, 1943, of subacute bacterial endocarditis.

HOWARD ATWOOD KELLY

World famed gynecologist—the last of the four great masters, Welch, Osler, Halsted, who headed the Johns Hopkins faculty in 1889. Inventor, author, naturalist, unrivaled artist in the surgery of women. Born in Camden, New Jersey, Feb. 20, 1858. Died at the Union Memorial Hospital, Baltimore, Jan. 12, aged 84 years, of arteriosclerosis, especially involving the coronaries and the renals (uremia). His death preceded by two hours that of his wife (Mrs. Letitia Bredow Kelly, whom he had married at Danzig in 1889), who lay in an adjoining room, in coma from seemingly the same cause.

SIR WILLIAM ARBUTHNOT LANE

Famous surgeon of Guy's Hospital, London—and leader in hygienic and dietetic reforms, advocate of open reduction of fractures and fixation with metallic bone plates (Lane's plates); first to direct attention to chronic intestinal stasis and Lane's kink as a predisposing cause, advocating total colectomy and ileosigmoidostomy for the cure of this condition with extraordinary surgical success; also devised Lane's operation for cleft palate; and author of important technical innova-

Received for publication, Feb. 17, 1943.

tions in various departments of surgery. Born at Fort George, Inverness, Scotland, July 4, 1856. Died in London, Jan. 16, 1943, aged 86 years.

All three have left the imprint of their names in indelible characters on the pages of history and have a right to permanent seats in the medical hall of fame.

All three were explorers and pathfinders who expanded the domain of surgery and cultivated new fields which are now yielding rich harvests for the benefit of humanity. All three were men of extraordinary energy, great originality, and initiative, with inborn qualities for leadership and capacity for inaugurating and directing great enterprises.

All three attained advanced maturity, despite the most strenuous lives of untiring labor, the friction of controversy, and the burden of great responsibilities.

Besides these common characteristics, all three were masters of the technique in their respective fields, real virtuosos in their chosen specialties. Although given practically the same opportunities for a scientific premedical education, and all three had the same joy in handicraft, they differed greatly in their tastes, inclinations, and beliefs. Crile displayed his native and early leaning toward the biologic, physical, and exact sciences. Kelly, while thoroughly precise, methodical, exact, and well disciplined, displayed great aptitude for the natural sciences, with inventiveness in his special department, besides a penchant for history and medical illustrations, of which he was no doubt the greatest promoter and patron in the United States. Lane, although decidedly mechanistic in his tastes as in his work, possessed surgical superiority which rested on a solid and all-absorbing base of human and comparative anatomy, which carried him through to a successful termination of some of the boldest operations in surgery.

In their answers to ultimate questions of creed and belief these men differed. Crile, an out-and-out materialist, was a physiochemic and mechanistic interpreter of the phenomena of life in their application to human and animal behavior. His views were shared by Lane, but not expressed in the same terms or from the same viewpoint—while both were completely opposed by the strictly fundamental evangelistic fervor and ultra episcopalian orthodoxy of Kelly.

Although it is entirely too early to attempt any comprehensive summary of the activities of these remarkable men, much less to attempt any estimate of the ultimate residue that posterity may extract out of their life labors as definite contributions to science, we do know that they will always remain in history as powerful spurs to urge the onward march of surgery in the twentieth century.

Without attempting even a bare outline of their careers, there are some salient points in the history of each of these great leaders that compel attention.

Crile

It has been very truthfully said that Crile did not waste one day in the 78 years of his life. He worked hard even at play until his heart failed, exhausted under the strain of a protracted endocardial infection. Not even when he became virtually blind, nearly two years before the end, did his busy brain cease to evolve and project his very original and bold conceptions.

Crile's scientific bent was demonstrated early in his career: B.S., Ohio Northern University, at 21 years of age; M.D., Western Reserve (1887); postgraduate science courses in London with Victor Horsley, neurosurgery, neuro-anatomy (1895); and other scientific trips to Vienna (in 1893); and Paris (1897); lecturer and demonstrator of histology at Wooster Medical School, Cleveland (1889-90); professor of physiology (1890-1893); professor of surgery at Wooster and later Western Reserve (1893-1924); and director of scientific research, Cleveland Clinic (1924-1943). In all of these his passion for experimentation and insatiable curiosity to peer beyond the mere problems of the operating table led him to the authorship of a series of original monographs which dealt with the basic problems of respiration (1899), circulation and studies on surgical shock (1899), blood pressure (1903), hemorrhage and transfusion (1907). This last, a revolutionary document, was signalized, in 1905, by the first direct transfusion from man to man by suturing the radial artery of the donor to a forearm vein in the recipient, all of which was made much simpler later, with the aid of connecting or anastomotic rings that he devised. His work on transfusion gave the first impulse to the clinical use of this method of revival in hemorrhage, anemia, and shock, which has become so universal in its modified forms.

Then followed his shockless method of operating, which he named "anoci-association" (*a* [negative] plus *nocere* [noxious, harmful] = anoxious association) in accord with his theory of surgical shock, which excluded all pain and sensory impulses from the field of the operation by blocking the nerves of the region with novocain injections, and coincidently excluding psychic shock by a preliminary hypodermic of morphine and scopolamine, which made the patient calm and indifferent, and prepared for general anesthesia with nitrous oxide gas and oxygen. Underlying all this was the principle of gentleness and delicate handling in the dissection of the tissues. The old dictum, *suaviter in modo, fortiter in re*, had been preached long before him but not understood as by him, namely: that shock was caused by exhaustion of the sensorium in the brain and vasomotor centers by the silent but constant clamor of the injured tissues in the field of the operation even after all pain had been suppressed by a general anesthetic.

The removal of the thyroid for goiter was one of the operations most frequently performed in his clinic, and this was done so deftly and silently that watching Crile "steal a thyroid" became a decided inducement to visit his clinic and to see him perform the operation.

Besides these notable mileposts in the march of progress, he devised a number of other original procedures of technical interest, such as special techniques for the extirpation of cancer of the lip and face, uterine suspension for prolapse, his inflatable rubber suit to prevent falling blood pressure in shock; the importance of adrenalin for the restoration of patients in shock and cardiocirculatory failure from any cause which were undoubtedly helpful contributions, as numerous other devices which constantly attracted students and visitors to his clinics.

Fig. 1—Dr. George Washington Crile.

The great war came to interrupt his work in the operating room at Cleveland, but served to rouse further his undying interest in the deeper problems of life and death in their biologic interpretation as these were so strikingly forced upon his attention by his military experience.

His scientific interests never lagged as he directed until the last the disposal and care of the magnificent collection of dissections of the energy-controlling organs of 3,734 animals collected from almost every quarter of the globe, for a systematic and comparative anatomic and physiologic study of the organs of "Crile's kinetic system," namely, the brain, the heart and blood vessels, the liver, the thyroid, and the adreno-

sympathetic and celiac ganglia in the wild and domesticated animals. From the wild life of the jungle in Tanganyika, Southeast Africa, from the frozen shores of the Arctic in Hudson's Bay, in quest of whales, walrus, and the great sea mammals, from the monkey-crowded forests of Panama and South America, from the coast of Georgia and Florida and many other sources, he assembled and allocated this magnificent and unique collection of the land and marine fauna of the world for permanent preservation in the museums of the American College of Surgeons, the Rosenwald Museum in Chicago, and the Clinic Museum at Cleveland, where they constitute the greatest visible monument to his marvelous initiative, tireless industry, farseeing and penetrating vision. A complete catalogue with weight and size of each individual organ and data pertinent to the animal and purpose of the exhibit will be found as a supplement to Crile's last work on *Intelligence, Power and Personality.**

The conclusions drawn from this vast and far-flung research are summed in a decalogue of biologic principles which are further compressed in the postulate that "Intelligence, power and personality are dependent on the absolute and relative size of the brain, the thyroid, the heart and blood volume, the celiac ganglia and plexuses, and the adrenosympathetic system."

The size and weight of the energy-generating and controlling organs that constitute Crile's kinetic series vary individually with the functional demands made upon them by the animal's life habits.

The thyroid gland and the brain exhibit the peak of their dominance in civilized man. The brain and thyroid rise together: the brain as the universal executive, the thyroid as the universal controller and regulator of a constant adaptive oxidation (metabolism). The thyroid gland is relatively larger in man than in any other land animal. The thyroid is smaller and the suprarenals and celiac ganglia larger in all predatory animals, the carnivorous beasts of prey (lions, tigers, leopards, cats, and birds of prey) in which great but intermittent outbursts of energy are required in the pursuit and kill of their quarry, and in the pursued which depend upon speed and endurance for their escape (zebra, horse, gazelle, wild deer, etc.). More thyroid and smaller suprarenals are found in man and animals in which the demands on the energy-producing and controlling organs are continuous and not subject to violent, kinetic flashes (e.g., the herbivora, elephant, hippopotamus, giraffe), and still less in the cold blooded animals (alligator, snakes, and other reptiles, etc.).

To his labors in the experimental laboratory were added those of the clinic as an operating surgeon in great demand, with a clientele drawn from all over the country (he is credited with the personal performance of 25,000 thyroidectomies); in the library as an extraordinarily prolific

*New York, 1941, McGraw-Hill Book Company, Inc.

Besides these notable mileposts in the march of progress, he devised a number of other original proeedures of technieal interest, sueh as speeial teehniques for the extirpation of caneer of the lip and face, uterine suspension for prolapse, his inflatable rubber suit to prevent falling blood pressure in shoek; the importanee of adrenalin for the restoration of patients in shock and eardiocireulatory failure from any eause which were undoubtedly helpful eontributions, as numerous other devices whieh eonstantly attraeted students and visitors to his elinics.

Fig. 1.—Dr. George Washington Crile.

The great war came to interrupt his work in the operating room at Cleveland, but served to rouse further his undying interest in the deeper problems of life and death in their biologic interpretation as these were so strikingly forced upon his attention by his military experience.

His scientific interests never lagged as he directed until the last the disposal and care of the magnificent collection of dissections of the energy-controlling organs of 3,734 animals collected from almost every quarter of the globe, for a systematic and comparative anatomic and physiologic study of the organs of "Crile's kinetic system," namely, the brain, the heart and blood vessels, the liver, the thyroid, and the adreno-

"Struggle is a biological necessity and even war is preferable to pusillanimous peace." (*Mechanistic View of War and Peace,* 1915.) He never let up in the face of criticism and downpour of opposition but continued to present his papers before the best scientific societies (e.g., Philadelphia Philosophical Society) and continued to receive scores of medals and honorary degrees. "He was not even halted in 1920, when the Cleveland Clinic was gutted by fire which cost 125 lives—patients, doctors, nurses—many of Dr. Crile's best friends among them—when, about the same time, he lost in real estate most of the $2,000,000 fortune his surgery had built." (*Time,* Jan. 18, 1943.)

Crile's prodigious capacity for gathering facts and experiences from every department of knowledge in support of his ingenious, bold, and always novel biophysical and heterodox but impressive views and interpretations of the phenomena of life can be accounted for only by his inexhaustible energy in the pursuit of his objectives, his genius for generalization, and the assimilation, organization, and utilization of every available observation or discovery that could contribute to the rapid and successful accomplishment of his task. Besides, and no less important, was his great ability to utilize the resources provided by the many accomplished and brilliant collaborators in the physical, mathematical, and biochemical sciences—men and women, including his accomplished wife, whom he associated in his work—that can account for the enormous scientific, biologic and literary output that he piled up as a superstructure on top of a 24-hour day schedule of the most exacting and continuous professional, educational, and executive functions.

In a recent commentary by a friendly critic, it is said that "there was something about Crile that recalls the scientific romanticism of the Renaissance, and it is as a great romanticist that he will go down in medical and surgical history." It is evident, however, that the writer of this statement has not familiarized himself with Crile's works, and particularly with his last book on *Intelligence, Power and Personality* (1941), which is virtually an epilogue and synopsis of the half century of deep thinking and world gathering of fact that he devoted to arming the citadel in which his embattled scientific creed was entrenched; indeed, this extraordinary book may be regarded as his last scientific testament.

No unprejudiced reader who has even an elementary acquaintance with the language of science can fail to admire the logic, coherence, and lucidity with which he marshalls out his army of facts in support of the ten biologic principles upon which his concept of the physical basis of life is based.

The romanticist is he who builds on the mere creations of his fancy and the figments of his imagination. He is not a romanticist who makes his romance in broad daylight—not in dreams, but upon visible, palpable realities—not in clouds, but on mountains of granite.

author (24 books, with over 400 journal articles); as a traveling lecturer, invited speaker in the countless medical societies that called for him all over the country, in response to the general urge to hear his always interesting, novel, and ingenious scientific theories, as well as for the practical value of his original surgical accomplishments. Moreover, he possessed the rare qualities of a successful organizer, director, and executive in enterprises involving large financial, professional, and social responsibilities: The Cleveland Clinic (1924-1943); president of the American College of Surgeons (1916), member of the Board of Regents (1913-1943), chairman of the Board (1917-1939), in all, 30 years' service as Regent of the A. C. S.; and other innumerable functions and public duties that are incompatible for the great majority of men submerged in laboratories and thought-consuming experimental researches. But still further and besides all this, there is the time and thought that he gave so prodigally to the discussion of transcendental questions, especially on controversial and debatable subjects which challenged established scientific and religious orthodoxies and beliefs, examples of which are his books which followed in a steady stream after World War I, on *The Origin and Nature of the Emotions* (1915), *A Mechanistic View of War and Peace* (1915), *Man an Adaptive Mechanism* (1916), *The Kinetic Drive* (1916), *A Bipolar Theory of Living Processes* (1926), *The Phenomena of Life* (1936), *Intelligence, Power and Personality* (1941), etc. In all these he held and stood forcefully to the contention that everything in the phenomena of life can be identified in terms of physics. Crile propounded his radioelectric theory and maintained that living organisms are bipolar mechanisms, constructed and energized by radiant and electric energy: "Mind is the product of electricity, generated by matter," Crile declared (and in this he anticipated the discovery of modern electro-encephalography), contending that he had established direct experimental proof in his laboratory that "the brain of man and of animals emits short waves and infrared radiations."

"The human body is a vast electric powerhouse, each cell having a complete solar system and complete life," he said; "the brain alone consists of over four quadrillions of individual dynamos, and a distribution system vastly greater in its complexity than all the lines of communication now in existence on the earth's surface." "Plants," he believed, "are generated by radiant and electric energy from the sun; animals get their radiance and electric energy from plants; in a living cell the acid nucleus is positively charged, the surrounding cytoplasm (cell substance) is negative, and the cell membrane is a condenser. In the body as a whole, the brain is a positive pole, the red blood cells negative."

Many of his opponents "were downright irritated" in 1930, when he said that he had produced "something approximating life" from chemicals in a test tube, although he was careful to say it was not life. Crile, however, did not yield to criticism, for in keeping with his belief,

gynecology that it was no longer recognizable as the same specialty he had taught at the beginning of his career. As a pioneer in devising new operations, new instruments, and new textbooks for the study and advancement of the diseases of women, his reputation spread from his clinic at Baltimore throughout the world as one of the greatest of abdominal surgeons, and his clinics were always crowded with visiting colleagues from America and abroad, who came to admire the perfection of his technique and recognized him as *facile princeps* among his colleagues. To see him do an abdominal subtotal hysterectomy for fibroids, a not infrequent operation in his clinic, by his own method of "side-to-side" or "left-to-right" removal of the uterus and adnexa, was a sight that made every surgeon proud of the perfection of his art. Method, system, dexterity, combined to give speed with security, without sacrifice of detail, impressed the observer as a disciplined act akin to a military drill, which painlessly, bloodlessly, and silently accomplished its purpose dramatically and yet with a simplicity that was most becoming in an artist so accomplished and secure in the knowledge of his art as Kelly. "*Tuto, cito et jucunde*—complete, quick and safe," is an ancient motto which Kelly in a modernized sense could have made most fitting as an inscription on the walls of his operating theater.

There are at least six distinctive features of Kelly's professional career that alone suffice to give him a conspicuous place in the gynecologists' hall of fame: (1) He, himself, by his virtuosity and perfection as a gynecologic surgeon set an example of competence and technical achievement that gave prestige and renown to American surgery and to gynecology as a whole, over the world. (2) He was the founder of a school of gynecology that lifted the specialty from a secondary pelvic plane to a high subdiaphragmatic abdominal level. (3) He was the academic or professional father of a group of eminent men who have contributed vastly to the progress of gynecology by perpetuating his example and traditions. Robb, Russell, Clark, Cullen, Hunner, Sampson, Burnham, Elizabeth Hurdon, and J. Withridge Williams are merely a few names suggestive of the great galaxy that Kelly taught and inspired. (4) He revolutionized the art of medical illustration by transplanting Max Broedel, the great medical artist, from Europe to America, and thereby establishing a school of medical art under his direction that remains unrivaled in the world through the sheer force of its artistic superiority. Though Broedel has passed away, the spirit of the great master continues to live through the example of his numerous pupils. It was through the magnificent illustrations to Kelly's great monographs on the surgery of the appendix, uterus, kidneys, etc., which he published with the assistance of his pupils Cullen, Burnham, and others, that the Broedel School of Medical Art asserted itself with its artistic quality to improve the esthetic sense of medical publishers as well as authors, with great profit to the prestige and value of American medical publications.

Regardless of what the reader may think of Crile's theories and interpretations, he must bow in respect and admiration for a genius capable of fortifying his beliefs with such an arsenal of indestructible facts.

Awards, titles, decorations, honorary degrees and fellowships in distinguished American and foreign institutions and societies came to him in profusion, as a glance at his biographic sketch in *Who's Who in America* shows, attesting to the conspicuous recognition that the world of medicine and science gave to his eminence in both.

Crile was elected a fellow of the International Society of Surgery in 1905, during the presidency of Professor W. W. Keen, the first American president of the society, at the International Congress held in Brussels that year. Crile regarded the International Society as the first and most representative international organization of surgeons in the world, and was one of the ablest contributors to its transactions. He often expressed his deep regret that the Nazi occupation of Belgium and World War II had interrupted the society's activities, but rejoiced when he learned of the very promising efforts (which have since been realized) to transfer the official bureau from Brussels to New York for the duration of the war, with every prospect of a complete rehabilitation of the organization in the Western Hemisphere.

Kelly

Educated in Philadelphia, Kelly received his A.B. degree at the University of Pennsylvania, 1877, and M.D. at the same institution, 1882. While a resident physician at the Episcopal Hospital at Philadelphia, he developed a gynecologic dispensary clinic. On completing his internship, he established, in the mill section of the city, a small two-ward hospital which later became the Kensington Hospital, supported by voluntary contributions. There he found his vocation as a gynecologist who had learned to trespass the boundaries of the pelvis with impunity, to find himself at home in the cavity of the abdomen (quite a bit of audacity at that time). In the meantime, he was made associate professor of obstetrics (1888-1889) at his alma mater, under his chief, Professor Goodell. There, at Kensington, he performed abdominal operations so skillfully and successfully that other surgeons came from far away to watch him. After a year in Europe in 1886, he was appointed chief of the department of gynecology and obstetrics at Johns Hopkins Hospital. With the opening of the Medical School in 1893, obstetrics and gynecology were separated, and Kelly retained the professorship of gynecology, to the success of which he concentrated all his efforts. He continued in the chair until 1919, when he resigned and became emeritus professor and chief consulting surgeon in gynecology to the end. In 1892, he established a private sanatorium next to his home in Baltimore, which became the Howard A. Kelly Hospital in 1913.

During the half century that Kelly helped to shape the destinies of his specialty in America, he so enlarged and transformed the field of

Among his numerous contributions to the practice of gynecology, none are more important than his discovery of direct cystoscopy for the complete inspection and treatment of bladder pathology, besides the catheterization of the ureters, which it greatly simplified by using one of his graded illuminating urethral specula with the patient in the knee-chest (Sims) position. The same principle of direct illumination and air distention by gravity was applied to proctoscopy and sigmoidoscopy, which is so indispensable in rectal practice. The Kelly rubber pad was also one of the many devices he invented for use at the bedside and in the operating room for the benefit of the patient, the doctor, and the nurse.

A prolific writer, lecturer, speaker, and lay preacher, he wrote over a score of books, including their several editions, besides over 600 articles on a great variety of subjects, which not only enriched the literature of the profession, but ornamented it by the unique and incomparable beauty of the illustrations that Broedel added to them under Kelly's direction.

Another great undertaking was his stereoclinic, which appeared in 1908 in over 84 sections. The stereoscope, intended to facilitate the understanding of surgical operations and technical procedures as they were reproduced photographically, gave a greater reality by the more solid projection of the image. It was a valuable but costly enterprise which for the time served a very good educational purpose for individual study, before the moving picture and lantern slides had come into general use.

With a polyvalent mind and a master key to all the modern languages, Kelly was a man of broad interests and multiple affinities, which he displayed to great advantage in his knowledge of medical history (American Medical Biographies, two volumes, 1912; *Dictionary of American Medical Biographies* with Burrage, 1920, and again in 1928—books that have become indispensable for reference in every library).

A naturalist by hereditary tastes, he was a botanist and a zoologist with special knowledge and authority on the venomous snakes, which he was able to handle with extraordinary familiarity and seeming safety; besides this he was an anthropologist, as his large and varied bibliography on these subjects attests.

His intellectual curiosity in many fields apart from his profession kept him in the forefront of public interest. His religious convictions have been referred to, and are fully expressed in his book, *A Scientific Man and the Bible* (1925). They were proclaimed and made effective in prayer meetings and in his preaching and lay sermons on morals and social evils. He was also an ardent prohibitionist and a strict sabbatarian. In behalf of these interests he spoke and wrote frequently and forcefully.

The esteem and admiration in which he was held by the profession and the scientific world are told by the long list of honors, titles, decorations, and honorary fellowships that accumulated like an endless catalogue in

(5) Kelly was one of the earliest pioneers in the use of radium for the cure of cancer and other neoplastic lesions in which Curie therapy is indicated. In April, 1913, he presented his first paper on the clinical use of radium, and created a radium school for the teaching of its scientific applications in association with Burnham, one of his former assistants, as its chief executive. He and James Douglas, of New York, were instrumental in securing a large supply of the element from Colorado, which they divided between the General Memorial Hospital in New York and his hospital in Baltimore. He proved his faith in the curative value of radium by investing a large fortune in it, reported to

Fig. 2.—Dr. Howard Atwood Kelly.

be over a million dollars. (6) Electrosurgery: Lying between radium and surgery is the radio knife, with its desiccating, fulgurating, and cutting features and appliances. In his earlier applications of the radio-electric knife for the hemostatic and thorough extirpation of malignant growths, he was so convinced of its superiority over the cold knife that he gave it all the benefit of his support and experience, as is well shown in his treatise on electrosurgery, published in 1932, in association with Grant E. White.

forearm for fracture, and a total colectomy from cecum to sigmoid with a terminal ileosigmoidostomy, by his method of anastomosis—for the relief of what is still known as "Lane's disease." Upon all these operations he stamped the seal of his personality by the originality of his procedures and the smoothness, ease, and perfection of technique that proclaimed a real master, a master who dared where others quailed and who succeeded where others would have failed without his skill, his precision, and the confidence with which he planned and executed his operations.

There is much resemblance between Murphy and Lane in their mechanical inventiveness (the Murphy button and Lane plate) and in their common ambitions to open new and untrodden paths, but, apart from these common traits, these two remarkable men were, in almost every other respect, very different personalities. Lane's recent death recalls the great achievements which so justly entitle him to fame.

Lane's early contention and insistence that the surgeon should do as neat a job in repairing broken bones as the cabinetmaker in mending broken canes, was the starting point of his early pleading (Lancet, London, May 26, 1901) for more thorough and perfect adjustment of broken bones. With the dawn of asepsis and the advent of the x-rays, the open treatment of fractures became a possibility, which Lane soon converted into a reality—and even into an obligate routine—whenever the classic methods of closed reduction failed to bring the broken bones into perfect apposition. To accomplish this purpose, Lane invented the perforated steel plates which were screwed to the bones and allowed to remain permanently imbedded. The simplicity of this procedure and the ease with which it generally accomplished its purpose, immediately gave Lane's plates a warm reception all over the world. Unfortunately, the operation was attempted by too many who were incompetent or careless in their appreciation of Lane's meticulous aseptic technique. Besides, the metal used in the manufacture of the screws and plates started an electrolytic disintegration of the bones in which they were imbedded, causing them to loosen and mobilize the plates, compelling their ultimate removal as foreign bodies.

The story of Lane's plates and their vicissitudes is too well known to justify rehearsal here, suffice it to say that, though it appeared for a while that Lane's plates were destined to the same oblivion that ended the glory of the Murphy button, they have survived despite all the criticisms to which they have been subjected and are now serving their purpose in many modified forms and ways, far beyond Lane's most sanguine expectations. A better knowledge of their indications, and especially the introduction of the neutral metal vitallium* by Venables, of San Antonio, Texas, as an alloy which is practically inert in the tissues, now used as a substitute for Lane's earlier steel plates, has not only rehabili-

*A nonferrous alloy composed of cobalt, chromium, and molybdenum. Its physical and chemical properties and its reactions when placed in living tissues indicate that vitallium is the most silent of all metals or alloys employed for internal fixation in fractures.

various biographic publications and in the appreciations of his pupils and assistants, but never more warmly and eloquently expressed than at the testimonial dinner given in Baltimore on Feb. 20, 1933, in celebration of his seventy-fifth birthday, for even those whom he had debated fiercely and at length came to honor him for his fairness and intellectual integrity.

It can be truly said of him that head, heart, and hand always worked in unison for noble purposes throughout his long and useful life.

Lane

As previously stated, Sir William Arbuthnot Lane was born at Fort George, Inverness, Scotland, in 1856. He received his premedical education in English private schools; his Bachelor of Medicine (M.B.) and Master of Surgery (M.S.), London University, and the usual F.R.C.S.E.; created baronet, 1913; Comp. Bath, 1918; A.C.S. (Hon.), in 1925, and Chevalier of the Legion of Honor, etc.

He had visited the United States frequently, and in October, 1925, came especially to deliver the annual Murphy Oration at the Clinical Congress of Surgeons held in Chicago that year. He was at that time close to his seventieth birthday and about to retire from active service at Guy's Hospital, and at the great Ormond Street Hospital for Children, where he had been the center of attraction for over three decades, especially to American medical tourists, who flocked to his clinic and regarded no visit to London complete without paying him a call and seeing him operate. These friendly relations made him sure of a cordial reception whenever he came to the United States, especially on this mission to Chicago, where he was to reap the laurels of an international friendship which had been planted and cultivated for over three decades.

An anatomist and surgeon by inclination and long culture, his authority had been recognized since early years, when he published an excellent anatomical guide made particularly valuable because of its practical surgical viewpoint. These qualifications soon led to his appointment as chief surgeon at Guy's and at the great Ormond Street Hospital for Children, where he held sway as chief until the date of his retirement. His thorough anatomical and physiological foundation made him a bold yet safe operator, original and resourceful, and always imperturbable in his calm, British self-possession. He seemed to know no limit to the anatomic regions over which he practiced his art. He was as much at home in dealing with the extremities as in the head, neck, and trunk; in the joints and bones; in extirpating the colon, or doing a cleft palate; in ligating and excising the internal jugular vein to check an acute otitic infection on its fatal way to the lungs.

In one morning at Guy's, I saw him do an unusually difficult palatoplasty for cleft palate in a small child, a resection of the lower jaw for malignant disease, an open reduction and plating of both bones of the

pled men and women all over the world, now happily restored to independence and to usefulness by the skillful application of Lane's principles as applied and interpreted with great originality and ingenuity in America, by surgeons such as Smith Peterson, the pioneer, and his host of followers in the orthopedic and surgical ranks. They have devised an effective method of *visible* alignment of the break (open section or x-ray) and a permanent fixation of the fragments by pins or screws which remain indefinitely buried in the welded bones.

Lane not only gave a new outlook to the treatment of fractures, but he created a veritable renaissance in the mechanical therapy of skeletal traumatisms by the impulse that his bold advocacy of open reduction and metallic fixation of fractures gave to the invention of innumerable appliances for the open reduction of fractures that now fill the catalogues of the manufacturers of surgical instruments (Steinman pins, Kirschner's tongs and wire tractors, etc.) including the lastest type of bone coupling fixation by bone penetrating, external and internal clamps, recently described by Stadter.

One of the striking features of Lane's bone instruments was the great length of their handles, which permitted all the work of reduction and bone plating to be done without manipulation in the wound itself. This practice, which he described as the "no-touch" technique, aimed at the avoidance of infections from leaks in punctured gloves or other sources. He had acquired great dexterity in working outside of wounds by constant performance with these tools, a dexterity which he also required of his assistants. He was satisfied that this technique, which gave a special cast to his armamentarium, contributed no little to the aseptic results of his bone surgery.

Lane is to be credited with the first publication, in 1889, of cases of septic lateral thrombosis following middle ear and mastoid infection, successfully treated by the ligation of the internal jugular vein to prevent metastatic infection of the lung. Previously, this procedure had been suggested and actually carried out in one instance by Victor Horsley, who performed the first jugular ligation for this cause in 1888, Lane following immediately, in 1889.

Colectomy.—To those who, like the writer, have had the privilege of watching Lane do a total extirpation of the colon, his very small operative mortality was not at all surprising. One could not see Lane perform this exacting and technique-testing operation without feeling that he had seen something done as well as it could possibly be done. Lane's perfection as an abdominal technician in this special field was based largely on the following distinct features: (1) Free incision, permitting adequate exposure of the abdominal contents, their inspection and palpation. (2) Speed without haste. Lane did not strike a casual observer as a rapid operator, yet the colon was removed in this instance, the terminal ileocolostomy performed, and the peritoneum closed well within an hour;

tated the Lane plates, but has become one of the outstanding contributions to the advance in bone surgery. The most serious objection to the steel first utilized by Lane for this purpose was its electrolytic action upon the host tissues, as manifested by local areas of tissue necrosis with absorption of the bone about the screws and plates. The consequent loosening of the screws impaired the stability of the internal fixation and the devitalized tissues favored bacterial infection.

Fig. 3.—Sir William Arbuthnot Lane.

These are the factors that have contributed most effectively to rehabilitate the Lane plates and have given them a wider and growing field of application. Perhaps no more striking illustration of the diversified effects of Lane's principles in the development of bone surgery could be quoted than the magnificent triumph achieved by surgery in solving the problem of the "broken hip" (fractured neck of the femur) which for centuries had challenged the best of surgery to make this rebellious fracture amenable to its curative laws. Here we see contemporary surgery's most brilliant accomplishment in redeeming thousands of helpless crip-

The kink and stasis predisposed to the elongation and prolapse of the bowel (enteroptosis), to rheumatoid arthritis, to tuberculosis and to arteriosclerosis, to epilepsy, and above all to cancer. The difference between chronic intestinal stasis and plain constipation was that in chronic intestinal stasis the stagnant pool of feces in the colon became definitely infected with pathogenic germs which brewed the toxins that were absorbed and carried everywhere in the organism by the circulation.

"Colectomy," Lane said, "is only called for in the most advanced cases in which the intestinal toxemia has led to cachectic states, or to disabling complications," such as rheumatoid arthritis, tuberculosis, or cancer (epilepsy as claimed by Reed of Cincinnati). "In suitable cases, colectomy affords results which seem to be short of miraculous." In the early cases "the regular evacuation and lubrication of the bowel by the use of liquid paraffin (liquid vaseline and other mineral oils) have done more" he said, "to alleviate suffering and prevent disease than any other known substance." There is no question that it is Lane's great influence that brought the mineral oils into general use for the relief of constipation, which use has become so universal all over the world, just as the practice of drinking acidophilus milk systematically became a habit with thousands of bowel complainers who, accepting Metschnikoff's teachings, drank sour milk acidulated by the acidophilus bacillus, particularly of Bulgarian breed, as an ally in ridding the intestines of the colon bacillus, the breeder of the toxins which gradually brought about arteriosclerosis and premature senility.

Chronic Intestinal Stasis.—It is to the credit of Lane that he gave us a new view of the mechanical cause and effects of chronic intestinal stasis, and that, in doing this, he pointed to hitherto undescribed anatomic anomalies of the peritoneal cover of the bowels which led to a stretching and dragging of the intestinal mass and suspended the viscera, constituting the familiar picture of enteroptosis, visceroptosis and its usual accompaniment, cardiovascular asthenia, etc., which, as a result of his graphic description of the protean picture, was identified as "Lane's disease."

Lane's views on intestinal stasis were merely an offshoot of a very much larger concept of disease brough about by the effects of civilization on the food and nutrition of primitive man. He believed that the gradual change in the dietary of man as he evolved from the primitive state, by the artefacts of civilization, had also effected very radical changes in the functions of the gastrointestinal tract. The wild man in his native state is like the lower animals, free from constipation. His bowels move as often as the fecal residue accumulates and reaches the terminal rectum. The intestinal tract of the civilized man is trained almost after birth to limit evacuations to certain restricted conditions. Civilization also brings about changes in the way of preparing foods, by cooking and otherwise, which deprive it of some of its more vital

but this could not have been possible without making every act purposeful and in uninterrupted continuity, and in entire absence of haste. (3) Lane made a real advance in intestinal surgery when he showed that the small gut could be joined to the large without risk, by an end-to-end anastomosis. He showed that this axial anastomosis possessed no special risks and had every advantage over an end to side ileocolostomy, which had to be abandoned because it failed to obviate the objectionable and dangerous regurgitation of the fecal current into the blind end of the colon, causing its enormous distension and compelling a colostomy for its relief. (4) Another important feature of his technique was the insertion of a rectal tube through the anus to a point in the ileum well above the anastomosis for the purpose of preventing flatulent distention above the line of the ileocolonic joint. Furthermore, he was ahead of most of his British contemporaries in his efforts to prevent post-operative shock and dehydration by preceding the operation and continuing it under the steady flow of a saline solution by hypodermoclysis; a procedure known in his clinic as the "axillary sup," which we carried on in our clinics for the same purpose by the continued intravenous glucose-saline drip.

There can be no question that Lane performed colectomies more frequently, more perfectly, and more successfully than any other surgeon in the world. The great frequency with which he performed this operation was largely accounted for by his profound belief in the dangers of colonic autointoxication from chronic intestinal stasis, sharing in this the well-known views of Metschnikoff, and of Panchet in Paris, the latter perhaps, next to Lane, the most experienced and successful colectomist who, as quoted by Lane, believed that intestinal stasis "was the cause of nearly all the pathology of civilization." Lane himself also said, "it is not an exaggeration to say that we suffer and die through the defects which arise in our sewerage and drainage system." Metschnikoff went much further by attributing senility to chronic intestinal toxemia generated by the colon bacillus, which attacked the arteries, causing arteriosclerosis and premature old age. Lane was absolutely convinced that chronic intestinal stasis was the most predisposing cause of cancer of the colon and even elsewhere, when stasis was aggravated by a mechanical obstacle in the path of the fecal current, such as a kink in the bowel, caused by adherent or acquired peritoneal bands, thereby causing friction and irritation at the point of the obstruction. It was here that the "Lane kink" figured large as a permanent cause of colonic morbidity, and it was the kink in the right colon that Lane so insistently described that kept radiologists busy for many years, demonstrating it to surgeons who were kept still busier for many years performing laparotomies to straighten it out.

their truth, and that even if they have not been confirmed in all his conception of their importance, they have left a residue of value to the future, as the result of their discussion and controversial agitation. With us, as surgeons, his memory will remain most conspicuous as that of a great practitioner of our art, a magnificent technician, and a pathfinder whose name will remain honored as that of a man who made surgery better by his presence and his deeds.

EPILOGUE

In closing this brief sketch of the three great surgeons who have just disappeared from the sphere of their worldly, activities, we are impressed by the fact that all three were exemplars of great minds of unusual grasp and understanding, but who, before the close of their careers gave evidence of extreme views in matters of personal belief that stood in sculptured contrast between them: Crile, a great surgeon-scientist, a free thinker, clear minded in his materialistic philosophy and physical interpretation of the phenomena of mind. Kelly, the great surgeon-artist, a naturalist, a fundamentalist, uncompromising in his evangelistic orthodoxy. Lane, a master surgeon, also a virtuoso in his art, of doubtful religious creed, but, strange to say, ready to exchange all his great surgical accomplishments for leadership in a health crusade designed and organized for the prevention of the diseases (cancer, tuberculosis, syphilis, and the great bacterial infections) which, if eliminated from the great catalogue of human afflictions, would leave surgery bereft of her greatest achievements, but grander and more glorious in the bloodless, scarless, and altruistic accomplishment of her humanitarian mission.

elements, the vitamins, for instance, the importance of which we are only now beginning to understand, and which we are trying to utilize as correctives of our defective foods. Lane was so impressed with the view that cancer and the great bulk of diseases in civilization were due to errors in diet and improper feeding that he founded A New Health Society which was organized essentially as a crusade for the prevention of cancer, a prophylactic aim which could only be made effective by complete revolution in the food and dietetic habits of the people. "We must eat such food as will obtain for us the same results that existed in primitive man; and we must discard such diet as is deprived of the important components of the natural foods. The public must be educated in the knowledge of food values and must be impressed by its extreme importance to health."*

In harmony with these views we see the famous discussion which agitated the medical and lay world in England and America in the controversy between the partisans of whole wheat flour as against the white flour in the making of bread, and the appeals that were made even to legislatures for the complete substitution of the whole wheat bread for the usual white bread which had been deprived of its most active nutritional elements, will be remembered as one of the greatest activities of this New Health Society. The advocacy of foods in the raw state, such as vegetables, fruits and cereals, in order to preserve their vitamins, and diminution in meats of all kinds, as favoring toxic putrefactive products, is also one of the striking features of the New Health campaign. Discussions still linger as distant echoes, but have long ceased to create any acrimonious discussions or radical changes in the national dietetic habits of the people in Britain or elsewhere.

Lane was so enthusiastic in his concept of the dietetic origin of disease and especially of cancer† that he retired from his surgical practice in which he had attained great eminence, seemingly without regret, to assume the direction of the New Health crusade that he had founded and organized, and which, if it had ultimately succeeded in its purpose, would have deprived surgery of some of its most heroic chapters, including some of Lane's greatest triumphs.

In Conclusion.—I may say that Lane expanded the surgical horizon by directing the profession to new surgical possessions and achievements (Lane plates, improved colectomy technique, intestinal stasis and Lane's kink, Lane's operation for cleft palate, and pioneering in jugular ligations to prevent pulmonary metastases from ear infections) many of which we are cultivating with profit and the promise of still greater benefits. Whatever may be the ultimate destiny of Lane's later concepts and theories regarding dietetic errors in predisposing to intestinal stasis, cancer, and other disorders that afflict civilized man, we know that these theories were conceived in good faith and with profound conviction of

*Murphy oration, Surg., Gynec. & Obst. 40: 206, 1925.
†Hoffman, F.: Cancer and Diet, Baltimore, 1927, Williams & Wilkins Company.

The orthodox orthopedic treatment of poliomyelitis is briefly as follows:

1. *The Acute Febrile Stage.*—During the first period the treatment is medical and no orthopedic measures, other than postural, are recommended. This stage lasts about one week and the meningeal symptoms with rigidity of the neck and back are followed by the appearance of the paralysis. It is during this period that the damage to the central nervous system occurs and, in addition to the usual measures used in the treatment of an acute infectious disease, absolute bed rest is insisted upon and the patient is disturbed as little as possible.

2. *The Stage of Tenderness and Early Contractures.*—The second stage begins when the temperature drops to normal (usually within two or three days after the appearance of the paralysis). There is now very little danger of further damage to the central nervous system, but pain, hyperesthesia, muscle tenderness, and paralysis are present to a variable degree. The pain, tenderness, and hyperesthesia cause contractures of the nonparalyzed muscles and this results in stretching of the paralyzed muscles and the development of deformities. Lovett,[2] Legg,[3] and many others have emphasized the fact that these deformities may develop very early in the disease.

This stage lasts from two weeks to three months or more and the degree and extent of the pain, tenderness, and hyperesthesia vary in different cases. The same is true of the paralysis and contractures. The treatment is symptomatic and its intensity varies directly with the severity of the symptoms. Rest in bed is continued until the pain and tenderness subside and the patient is disturbed as little as possible, except for nursing care. A firm flat bed with a board at the foot or a cradle to support the bedclothes is recommended. If the patient is not paralyzed by the disease and has no pain or tenderness, no special treatment is necessary and he is permitted to be up and about as soon as he has recovered from the acute illness. It is to be noted that many nonparalytic cases occur during an epidemic.

Well-padded and fitted plaster molds or padded metal splints are used to immobilize the affected extremities. It is to be noted that proper immobilization of an extremity not only prevents deformity and protects the paralyzed muscles from stretching, but it relieves pain and hastens the disappearance of hyperesthesia, muscle tenderness, and contractures. Peabody, Draper, and Dochez[4] cite an instance of a child who cried to have her splints replaced because they relieved her pain.

When possible, the splints or casts are applied in the physiologic position—that is, with the hips and knees almost straight and the feet dorsiflexed to a right angle. The arms are moderately abducted, the elbows are moderately flexed, and the forearms are supinated. Plantar flexion of the feet, flexion of the hips and knees, scoliosis, and adduction of the arms are the deformities which are especially to be avoided.

THE KENNY VERSUS THE ORTHODOX TREATMENT OF ANTERIOR POLIOMYELITIS

J. ALBERT KEY, M.D., ST. LOUIS, MO.

(From the Department of Surgery of the Washington University School of Medicine, St. Louis)

DURING the past two years the American lay press and radio have widely publicized the Kenny method for the treatment of infantile paralysis and in the *Journal of the American Medical Association* it was stated that "Miss Kenny has presented to the American medical profession her unique and original method of treating the disease infantile paralysis." It is further stated that Miss Kenny's method is based on previously unrecognized symptoms of the disease, namely, muscle spasm, mental alienation, and incoordination. The spasm is said to be due to an inflammatory process within the muscle and with muscle incoordination is the principal cause of disability, because paralysis, while unfortunately a feature of the disease, is, after all, a minor consideration in most cases of infantile paralysis. It is further stated that the Kenny method should be adopted and be made generally known to the physicians of America as quickly as possible (Pohl).[1]

In view of the above statements it seems advisable that a comparison be made between the Kenny and the orthodox treatment of infantile paralysis in order that we may have a clear understanding of the differences between the two methods and determine which is the better.

The orthodox treatment of infantile paralysis is the result of the accumulated experience of many physicians who have studied the disease and have noted carefully its clinical manifestations and sequelae. While differing in minor details in different clinics, the treatment is fairly well standardized throughout the civilized world and it is not necessary for a victim of the disease to travel a long distance in order that he may receive adequate treatment. It is based on the knowledge that infantile paralysis is an acute infectious disease which invades the central nervous system and is especially prone to damage or destroy the anterior horn cells of the spinal cord and to cause temporary or permanent paralysis of the muscles supplied by these cells. It is recognized that the disease is self-limited. The treatment has for its objects: the saving of life; the maintenance of a satisfactory state of general nutrition and comfort in the patient; the protection of paralyzed muscles from stretching and fatigue; the prevention of deformities; the maintenance of circulation in the paralyzed limbs; the training of partially paralyzed muscles; the restoration of function to the paralyzed parts; and the rehabilitation of the patient.

Received for publication, Feb. 18, 1943.

The orthodox orthopedic treatment of poliomyelitis is briefly as follows:

1. *The Acute Febrile Stage.*—During the first period the treatment is medical and no orthopedic measures, other than postural, are recommended. This stage lasts about one week and the meningeal symptoms with rigidity of the neck and back are followed by the appearance of the paralysis. It is during this period that the damage to the central nervous system occurs and, in addition to the usual measures used in the treatment of an acute infectious disease, absolute bed rest is insisted upon and the patient is disturbed as little as possible.

2. *The Stage of Tenderness and Early Contractures.*—The second stage begins when the temperature drops to normal (usually within two or three days after the appearance of the paralysis). There is now very little danger of further damage to the central nervous system, but pain, hyperesthesia, muscle tenderness, and paralysis are present to a variable degree. The pain, tenderness, and hyperesthesia cause contractures of the nonparalyzed muscles and this results in stretching of the paralyzed muscles and the development of deformities. Lovett,[2] Legg,[3] and many others have emphasized the fact that these deformities may develop very early in the disease.

This stage lasts from two weeks to three months or more and the degree and extent of the pain, tenderness, and hyperesthesia vary in different cases. The same is true of the paralysis and contractures. The treatment is symptomatic and its intensity varies directly with the severity of the symptoms. Rest in bed is continued until the pain and tenderness subside and the patient is disturbed as little as possible, except for nursing care. A firm flat bed with a board at the foot or a cradle to support the bedclothes is recommended. If the patient is not paralyzed by the disease and has no pain or tenderness, no special treatment is necessary and he is permitted to be up and about as soon as he has recovered from the acute illness. It is to be noted that many nonparalytic cases occur during an epidemic.

Well-padded and fitted plaster molds or padded metal splints are used to immobilize the affected extremities. It is to be noted that proper immobilization of an extremity not only prevents deformity and protects the paralyzed muscles from stretching, but it relieves pain and hastens the disappearance of hyperesthesia, muscle tenderness, and contractures. Peabody, Draper, and Dochez[4] cite an instance of a child who cried to have her splints replaced because they relieved her pain.

When possible, the splints or casts are applied in the physiologic position—that is, with the hips and knees almost straight and the feet dorsiflexed to a right angle. The arms are moderately abducted, the elbows are moderately flexed, and the forearms are supinated. Plantar flexion of the feet, flexion of the hips and knees, scoliosis, and adduction of the arms are the deformities which are especially to be avoided.

If the deformities are present when the child is first seen it may be necessary to immobilize the limb in a position of deformity and it can be straightened gradually or, in rare instances, the limb can be straightened under general anesthesia and immobilized in splints or casts in a satisfactory position.

It is to be noted that the casts or splints do not interfere with the circulation in the paralyzed limb, nor are they left in place constantly. In order to avoid shortening of muscles and stiffness of the joints the splints or casts are removed twice during the day and the major joints of the extremity are moved passively, not actively, through as great an arc as is tolerated by the patient. Each joint is moved once or twice and the movement is stopped at the point of pain.

The casts or splints are not used on all extremities or on all cases. They are applied only when needed for comfort and to prevent contractures and protect paralyzed muscles. Many cases need no immobilization and in others immobilization can be accomplished sufficiently with sandbags, pillows, or a board or box at the foot of the bed.

As additional measures for the relief of pain and tenderness, Lovett[2] advises warm salt baths and Legg[3] and Peabody, Draper, and Dochez[4] recommend hot packs or dry heat.

Massage and muscle training are not permitted until the tenderness and pain have disappeared, because it has been found that these measures tend to aggravate and prolong the pain and tenderness.

3. *The Convalescent Stage.*—When the pain and tenderness have subsided it is time to take stock of the patient's musculature and determine what damage has occurred. Consequently, a muscle examination is performed and not only the ability to contract, but also the relative strength of the various muscles or groups of muscles is noted and recorded.

At this stage we have a patient with no deformities, but with a variable amount of stiffness and paralysis. If all of the cases which occur during an epidemic are included in a series it will be found that the majority of them have no residual paralysis or stiffness after the pain and tenderness have disappeared. These patients need no special treatment, but they may be permitted gradually to resume their normal activities. They should be examined at monthly intervals for the next six months, because occasionally weakness or partial paralysis of certain muscles may have been missed at the first examination and this may be evident later when the patient has spontaneously recovered the use and power of his normal muscles. I have seen no evidence that such patients ever fail to regain the use of muscles which have a normal nerve supply. And they do this without any special training or muscle re-education, just as infants learn to walk and young birds learn to fly when they are able to do so.

In the minority of these patients there is a variable amount of flaccid paralysis of the voluntary muscles. In some muscles the paralysis is

complete and permanent because all of the motor nerve cells which supply the muscles have been killed and such cells do not regenerate, nor is there any evidence that new neuronal connections are formed. In other muscles the paralysis is temporary because not enough of their motor cells have been killed to interfere seriously with the nerve supply of the muscles. They were damaged by the disease and have ceased to function, but the cells will recover and again transmit motor impulses to the muscles. When this occurs the muscles will resume their function and return to a normal condition and no special treatment is necessary to bring this about.

There is a third group of muscles which are paralyzed; part of the motor cells to these muscles are killed and part of them are damaged and thrown out of function by the disease, but they will recover and again send motor impulses to the muscles. However, since some of the motor cells are killed the muscle will not receive the normal number of motor impulses and will not regain its normal power. Some of these muscles will return almost to normal and others will never regain sufficient power to perform any useful function. It is this third group of paralyzed muscles which we believe can be helped by physical therapy. The first group is beyond help and the second group needs no help. The third group needs protection from stretching and fatigue and graded exercises to develop the maximum power in the fibers which are still supplied with motor impulses.

In addition to the flaccid paralysis of the affected muscles there is a variable amount of contracture of the normal muscles. This contracture is the result of the pain and tenderness and is similar to the contractures which occur in many conditions of the extremities where movement is accompanied by pain. These contractures may occur very early in poliomyelitis. They are minimized by proper splinting of the limbs and by the daily movement of the limbs when the splints are removed for this purpose. The contractures are corrected by gradual stretching and when they have been corrected they do not tend to recur, unless muscle imbalance is present. In this respect the contracted muscles differ from spastic muscles.

In the beginning of the convalescent stage it is not possible to determine which of the paralyzed muscles will fall into each of the three groups mentioned above; consequently, all of the paralyzed muscles are treated by physical therapy. The extremity is first warmed and massaged gently and the shortened muscles are stretched. Then the physical therapist demonstrates the movement by passively moving the limb through the desired range and has the patient by concentration endeavor to carry out the movement by active contraction of the weakened muscles. Depending upon the power present in the involved muscles, the movement is carried out with assistance, with gravity eliminated, against gravity, and against resistance. As a rule, no effort is made to teach the pa-

tient the names and the origin and insertion of the involved muscles, but he is taught to perform definite movements. This is because the pattern in the brain is believed to be one of movement rather than an awareness of the muscles which perform this movement.

In the beginning the patient may have some difficulty in carrying out specific movements, even when sufficient muscle power is present. This is not an incoordination, but is the natural result of the prolonged lack of use during the stage of tenderness and contracture. If the nerve supply to the muscles is intact the patient soon learns to use them normally, just as a patient soon learns to walk after a prolonged illness. If the muscle is weakened by the loss of part of its nerve supply the problem is more difficult and it may require considerable time and patience on the part of the therapist before the patient learns to use the weakened muscles effectively. In such instances the patient may contract all of the muscles in the extremity in an effort to perform a given movement and the extremity is moved in the direction opposite to that desired because the strong muscles overcome the weak ones. The therapist overcomes this tendency by passive movement, assisted movement, and by having the patient perform the exercise with the opposite extremity at the same time. He thus learns to relax the opposing strong muscles while contracting the weak ones. Patients are also taught to set the given muscles; that is, to contract them without moving the extremity.

Muscle examinaions are performed at intervals in order to note and record the improvement in the paralyzed muscles. The power of the muscles is graded and when any group approaches normal its treatment is discontinued, and emphasis is placed on developing power in the muscles which are partially or completely paralyzed. Detailed directions for muscle training are given in many textbooks.

The period of convalescence lasts from a few months to two years, or even longer. It is ended when the paralyzed muscles have returned to a normal condition or when repeated muscle examination fails to reveal improvement in muscles which have been protected from fatigue and stretching and have been adequately trained. The greatest improvement occurs during the first six months and much of this improvement is spontaneous and is not due to the treatment. During this period contractures which may have been present have been corrected by gradual stretching and the patient has been kept in bed until the physician in charge has decided that walking or sitting will not injure the weakened muscles—usually about six months for a patient with considerable involvement in the lower extremities.

Splints are used in the convalescent period only when they are needed to protect the paralyzed muscles from stretching and to prevent the development of contractures and deformities and to enable the patient to use his limbs more efficiently.

The Chronic Stage.—This begins when improvement in the paralyzed muscles ceases and lasts for the rest of the patient's life. The patient

may now be normal or he may be paralyzed to a variable degree. If the orthodox treatment has been properly carried out most deformities will have been prevented and contractures and stiffness will not be present. In my experience splinting and posture have failed to prevent the development of shortening, scoliosis, calcaneus and hip flexion with lordosis where there is marked muscle imbalance. Likewise, in a very rare case muscle contractures and stiffness may persist for a long time in spite of treatment.

In the chronic stage braces are used to enable partially paralyzed limbs to function more efficiently and to prevent the progressive development of deformities where marked muscle imbalance is present. Also, by surgery we are able to correct many deformities which have developed in spite of treatment or because of lack of treatment and have resisted nonoperative attempts at correction. Likewise, by surgery we are able to improve the function by transplantation of muscles and by stabilization of joints and equalization of length in legs.

There are three important variations from the standard orthodox treatment. The first makes extensive use of exercises under water. This method eliminates the effect of gravity and promotes the exercise of very weak muscles. It is best exemplified by the underwater gymnasium of Lowman and the work at Warm Springs, Ga.

The second variation emphasizes prolonged splinting and protection of the paralyzed muscles from stretching, and careful muscle training. It is best exemplified by the work of the Kendalls in Baltimore.

The third is an economical method and recognizes the fact that muscles will not become hopelessly atrophied or contracted, nor will joints become permanently stiffened by constant immobilization in a plaster cast over a period of a few weeks. The affected limbs are immobilized in a neutral or physiologic position until the pain and tenderness have disappeared. Then all splinting is removed and the child is permitted to use his muscles freely in bed and is put in a tub of warm water once or twice a day and encouraged to exercise his limbs in the water. At the end of a few weeks a muscle examination is done and stock is taken of the case and the indicated physical therapy is prescribed. This is best carried out by a trained physical therapist, but if this is not possible the parents are instructed how to exercise the weak muscles. Splints or braces are fitted if they are needed to protect paralyzed muscles and to prevent deformities. The patient is then encouraged to resume his normal existence. Surgery is used when indicated in the chronic stage.

The Kenny Method.—This method is the one being promoted by Miss Elizabeth Kenny, an Australian nurse who came to this country in 1940 for the express purpose of teaching the method to American physicians and physical therapists. Apparently she became interested in the disease about twenty years ago, because it is stated that in 1933 she claimed that she had been treating paralyzed patients for ten years and had

treated thirty patients, curing all of them. At that time the treatment was quite unorthodox and is said to have consisted of violent movements. Facilities for a trial of the method were provided for the treatment of patients suffering from poliomyelitis and spastic paralysis. Forty-seven patients were treated over a period of two years and these cases were reviewed by a commission appointed for the purpose. This report stated that "Originally the Kenny method showed radical departure from orthodox treatment, but in the course of time the former has gradually been brought into conformity with the usual medical practice." The important difference is that in the Kenny method all splinting is abandoned. This commission did not recommend the Kenny method.[5]

However, Miss Kenny has convinced other Australian physicians and laymen of the value of her method and her book illustrates hospitals and clinics in Australia where the Kenny method is practiced (Kenny[6]). My knowledge of the Kenny method is based upon study of her work, of articles (Pohl,[1] Daly and co-workers,[7] Cole and Knapp[8]), and of the booklet by Cole, Pohl and Knapp,[9] as well as upon a two-day demonstration by Miss Kenny in Minneapolis, and visits to Little Rock and Chicago where it was possible to examine many patients of the 1942 epidemics in Arkansas and Illinois who had been treated by the Kenny method.

The method is as follows: Treatment is started as soon as the diagnosis of infantile paralysis is made. The patient is put to bed on a flat mattress in as nearly the normal standing position as possible. A board is placed at the foot of the bed to support the bed clothes and to maintain the normal standing reflexes. It may be necessary to modify the position in order to relax spastic muscles.

As soon as spasm is diagnosed hot fomentations, prepared by removing woolen cloths from boiling water and passing them twice through a wringer, are applied to the spastic muscles. The packs are usually applied every two hours, but may be applied as often as every fifteen minutes and they are continued for twelve hours of each day. The alternate heating and cooling tends to overcome the spasm.

Passive motion through the range that can be obtained without pain is carried out at least once a day, but care is taken not to aggravate spasm by too frequent examination, and muscle testing is not permitted.

Muscle re-education is started as soon as joints can be moved passively through a small range without pain or incoordination. At first this consists largely of maintaining or developing a "mental awareness" of the muscles and their insertions. The technician instructs the patient concerning the part to be moved by stroking the skin over the insertion of the muscle group to be trained. With the patient concentrating on this point of insertion the motion is carried out twice passively and then the patient is instructed to perform that motion actively. Later active motions are instituted under the control and guidance of the technician.

Care is taken that only the muscle which is being trained contracts and if any other muscles come into play the movement is stopped because this contraction of other muscles is considered incoordination. The number and range of movements are increased gradually, but care is taken not to tire the muscle. If there is no trace of motion in spite of absence of spasm, the proprioceptive reflexes are stimulated by placing the muscle slightly on the stretch and then stimulating the muscle through the tendon by moving the joint backward and forward.

The above is condensed from the booklet.[9] The description is brief, but I believe that it includes all that need be said about the Kenny method. Neither in the booklet[9] nor in Miss Kenny's book[6] is any statement made as to how long the hot fomentations are to be continued, nor are any rules laid down as to when muscle re-education is to be stopped. Apparently, hot fomentations are continued until all muscle spasm is abolished (at least six months in some patients) and the muscle re-education is continued indefinitely in the case of alienated or paralyzed muscles and for a considerable period after the patients have returned to normal in the nonparalytic cases. So much of Miss Kenny's book is occupied in disparagement of the orthodox treatment and the citing of unusual, neglected, or improperly treated cases to prove that "orthodox practices are wrong from foundation to finish, both in theory and practice" (Kenny[6], p. 243) and in reiterating that the Kenny method is right, that there is little room for a detailed description of the Kenny method.

It is now in order to consider Miss Kenny's contribution to the symptomatology of the acute stage of the disease. It is claimed that she had discovered the three cardinal symptoms which have never been recognized before and consequently have not been treated by orthodox physicians. These are spasm, incoordination, and mental alienation.

Muscle spasm is the condition which we call rigidity and muscle contracture. I prefer the continuation of the terms rigidity and contractures, because in describing paralysis we reserve the word spastic for upper motor neurone lesions. In this sense spasm does not occur in poliomyelitis, except in very rare instances where the disease damages the upper motor neurones.

Incoordination includes the conditions which we describe as muscle substitution and mass movements. In medical literature incoordination is a condition in which the patient is unable to *synchronize and co-ordinate* his normal muscles to perform complicated movements. This condition is not present in poliomyelitis.

Mental alienation includes temporary paralysis from disuse, temporary paralysis from injury to, but not death of, motor nerve cells, and partial paralysis. In medical literature alienation means insanity or mental derangement.

The terms spasm, incoordination, and mental alienation are not used by us in referring to symptoms present in poliomyelitis, but the conditions to which they refer have been recognized and treated by physicians and physical therapists for many years. It is thus evident that Miss Kenny has not discovered three new cardinal symptoms of the disease, but she has merely used new terms to describe well-known conditions.

The Kenny treatment differs from the orthodox treatment as follows:

In Theory.—The Kenny treatment is based on the belief that the principal lesion of the disease is muscle spasm caused by an acute inflammation in the muscles. There is no evidence that the virus attacks the muscles or that they are inflamed. We believe that the early contractures are caused by pain, tenderness, and hyperesthesia and that these symptoms are due to lesions affecting the sensory nerve cells and fibers. Lesions in the spinal ganglia and inflammation in the meninges have been demonstrated. We recognize the lesions in the anterior horn cells as the chief cause of temporary and permanent flaccid paralysis and consider this the important feature of the disease and not a minor consideration.

In Practice.—

1. The Kenny method begins treatment with hot packs as soon as the diagnosis is made. We believe that these patients need absolute rest and quiet during the febrile stage and that meddlesome therapeutics may be harmful. This stage lasts only a few days.

2. The Kenny method precludes the use of a respirator. We believe that it has saved lives.

3. In the Kenny method spasm is treated by very hot packs applied continuously for twelve hours a day and by daily passive movements. We treat contractures, pain, and tenderness by immobilization in casts or splints and use wet or dry heat when indicated. Daily passive movements relieve stiffness and the splints prevent most contractures. The very hot packs may cause furuncles and burns.

4. The Kenny method begins active muscle re-education before the pain and tenderness have subsided. We wait until this stage is over. Over twenty years ago I was in Boston when Feiss[10] attempted to demonstrate the value of early active movement in poliomyelitis. It was the opinion of Lovett and of others who examined these patients at the Children's Hospital that this treatment had aggravated and prolonged the pain and tenderness.

5. In the Kenny method of muscle re-education, awareness of the muscle to be exercised is imparted to the patient. In the orthodox method the part is first warmed and the patient is then shown the exercise and instructed to perform the desired movements. In other respects the muscle training routines are similar, and this includes the avoidance of mass movements and muscle substitution (incoordination)

and the treatment of temporary and partial paralysis (mental alienation). Our method is simpler and more practical, especially in the treatment of young children. I believe that our trained physical therapists have little to learn from Miss Kenny about muscle training.

6. The Kenny method considers all muscles normal or alienated which are not permanently paralyzed. We recognize temporary and partial paralysis.

7. The Kenny method ignores the power present in a muscle and forbids muscle examinations. Consequently, records of the previous condition of the patients are not available and it is not possible to verify the exhorbitant claims of cures. We examine and grade the muscles at intervals and their condition is recorded.

8. The Kenny method does not use braces or splints and it is said that they interfere seriously with the circulation and cause hopeless muscle atrophy and stiffness. This is not true if they are properly applied. There is not sufficient interference with the circulation to cause harm; the atrophy and stiffness are temporary and from my observations are less extensive than occurs under the Kenny treatment. This is because paralyzed patients treated by the Kenny method are kept flat on the back in the "correct standing position" for six months or longer and are only moved for treatment or turned on the face for one hour a day. Of course their backs, hips, and knees remain stiff even when subjected to continuous hot fomentations. Such patients are immobilized more completely and for a longer period than they would be if they were treated by orthodox methods. Our patients are encouraged to move about during the convalescent stage.

9. The Kenny treatment relieves contractures and prevents deformities by continuous hot packs, frequent manipulation, and practical immobilization of the entire body in bed. We do this more economically and effectively by immobilization of the paralyzed limbs in casts or splints and daily passive movement.

10. The Kenny method does not protect paralyzed muscles from stretching. We do.

11. It is claimed that the Kenny treatment will prevent or lessen paralysis. There is no proof that this is true.

12. In the lay press the Kenny method is credited with remarkable cures and there are extravagant promises of cures. We avoid publicity and are more guarded in our prognoses.

13. It is stated that deformities do not occur in patients treated by the Kenny method. This is not true. I have seen them.

14. Many patients treated by the Kenny method will be handicapped because they will lack splints which would enable them to use their paralyzed limbs more efficiently.

15. The Kenny treatment is laborious and messy, and demands a relatively large number of specially trained technicians for a given number of patients.

16. It is also expensive, because, in addition to the large amounts of boiling water used, the woolen blankets for hot fomentations must be renewed about once a week. And we are at war.

17. The Kenny method is rigid and cannot be used effectively in an epidemic of any magnitude. The orthodox treatment is elastic and has weathered many epidemics. Poliomyelitis is an epidemic disease.

18. All of the improvement which occurs in a patient who is being treated by the Kenny method is attributed directly to the treatment. We recognize the fact that improvement is the rule in most cases and that much of this is spontaneous. It occurs regardless of the treatment. This is true of all of the symptoms of the disease, including contracture and paralysis of muscles.

19. It is stated in the lay press that the Kenny treatment cures 80 per cent of the patients and the orthodox treatment cures only 17 per cent. The series are not comparable. The Kenny series included all cases diagnosed as poliomyelitis and McCarroll's[11] cases included only those with sufficient residual paralysis to cause them to enter the hospital in the convalescent or chronic stage of the disease. In an epidemic of 167 cases in Canada, in 1914, all received orthodox treatment and 137 (or 82.2 per cent) recovered to a point where they were normal or practically normal (Huckell[12]). In the 1941 epidemic in Alabama there were over 800 cases. H. E. Conwell reviewed 120 of these who were treated by the orthodox method[13] and states that over 80 per cent are normal or practically normal. Lenhard[14] reports that of 296 cases in the 1941 epidemic of poliomyelitis in Maryland that received orthodox treatment, 68 per cent recovered completely, 14 per cent had only slight residual paralysis, 11 per cent had moderate residual paralysis, 5 per cent had marked residual paralysis, and only 2 per cent are wheel chair patients. Thus, 82 per cent of these are normal or practically normal. It is, then, evident that the orthodox method can be demonstrated to cure as high a percentage of patients as the Kenny method is claimed to cure and does this with less risk, less cost, in less time, with less labor, and with much less fuss.

COMMENT

The most important difference between the Kenny and the orthodox methods of treating poliomyelitis is that in the Kenny method emphasis is placed upon muscle spasm as the most important feature of the disease and efforts are made to relieve this spasm by hot fomentations, while in the orthodox method flaccid paralysis of muscles is considered the most important feature of the disease and efforts are made to protect and restore function to the paralyzed muscles. The other two symptoms which are stressed by Miss Kenny (incoordination and mental alienation) are recognized under different names, but are treated in much the same manner under each method. However, we believe that early active exercise of muscles is harmful and tends to prolong the

stage of tenderness and contracture and we do not begin our muscle training until these symptoms have subsided, while Miss Kenny begins her muscle training as soon as possible after the diagnosis of poliomyelitis is made. We also consider splints a useful adjunct to our treatment where they are indicated.

The symptoms which Miss Kenny calls muscle spasm are recognized and treated in the orthodox method, but they are called rigidity and muscle contracture and are treated by immobilization in splints or casts to relieve the pain and prevent contractures and the development of deformities. In anticipation of the criticism that even though orthodox treatment has recognized the so-called muscle spasm it has failed to emphasize and treat this symptom, I wish to state that rest is probably the most important therapeutic measure in our armamentarium and that in order to put a muscle at rest we immobilize the part. Consequently, we treat the tender, painful contracting muscles by rest. This is obtained by our splints or casts. The reason we have not emphasized these symptoms is that they tend to subside when the limb is put at rest. The tendency of the muscles to contract (so-called muscle spasm) subsides when the pain and tenderness disappear and if deformities are prevented this symptom is rarely an important problem under orthodox treatment. It has not been emphasized because it subsides spontaneously.

REFERENCES

1. Pohl, J. F.: The Kenny Treatment of Anterior Poliomyelitis, J. A. M. A. 118: 1428, 1942.
2. Lovett, R. W.: The Treatment of Infantile Paralysis, Ed. 2, Philadelphia, 1917, P. Blakiston's Son & Co.
3. Legg, A. T.: Physical Therapy in Infantile Paralysis. Chap. VIII, Vol. II, Principles and Practice of Physical Therapy. Hagerstown, Md., 1932, W. F. Prior Company, Inc.
4. Peabody, F. W., Draper, G., and Dochez, A. R.: A Clinical Study of Acute Poliomyelitis, New York, 1912, Monograph No. 4 of Rockefeller Institute for Medical Research.
5. Report of the Queensland Royal Commission on Modern Methods for the Treatment of Infantile Paralysis, M. J. Australia 1: 187, 1938.
6. Kenny, E.: The Treatment of Infantile Paralysis in the Acute Stage, Minneapolis, 1941, The Bruce Publishing Company.
7. Daly, M. M. I., Greenbaum, J., Reilly, E. T., Weiss, A. M., and Stimson, P. M.: The Early Treatment of Poliomyelitis, J. A. M. A. 118: 1433, 1942.
8. Cole, W. H., and Knapp, M. E.: The Kenny Treatment of Infantile Paralysis, J. A. M. A. 116: 2577, 1941.
9. Cole, W. H., Pohl, J. F., and Knapp, M. E.: The Kenny Method of Treatment for Infantile Paralysis, New York, 1942, Publication No. 40 of the National Foundation for Infantile Paralysis, Inc.
10. Feiss, H. O.: The Treatment of Early Infantile Paralysis as Based on the Physiologic Indications, J. A. M. A. 78: 85, 1922.
11. McCarroll, H. R.: The Role of Physical Therapy in the Early Treatment of Poliomyelitis, J. A. M. A. 120: 517, 1942.
12. Huckell, R. G.: Annual Report of the Department of Health of the Province of Alberta. (In Press.)
13. Conwell, H. E.: Personal communication.
14. Lenhard, R. E.: The Results of Poliomyelitis in Baltimore, J. Bone & Joint Surg. 25: 133, 1943.

ACUTE PERFORATED GASTRIC AND DUODENAL ULCERS

FRANCIS X. PALETTA, M.D., UNIVERSITY, VA., AND WILLIAM R. HILL, M.D.
RICHMOND, VA.

(From the Department of Surgery and Gynecology, University of Virginia School of Medicine)

THE analysis of a series of acute perforations of the stomach and duodenum treated by operation during a period of seventeen years (1925-1942), at the University of Virginia Hospital, has yielded interesting data on certain aspects of this disease.

MATERIAL

The material consists of 83 cases. Thirty of the patients had perforated gastric ulcers and 53, perforated duodenal ulcers. The types of operative procedure performed in these cases are tabulated in Table I. Most of the perforated gastric ulcers were treated by simple closure. Thirty-one of the patients with perforated duodenal ulcers were treated by simple closure, 17 had excision and pyloroplasty, and 5 had closure of perforation with gastroenterostomy. In each case closure was without drainage. More than one-half of the operations were performed by the resident surgeons. No data are presented either for subacute perforations of benign ulcers treated originally by conservative measures, for perforations of malignant ulcers, or for chronic perforations.

RESULTS

The mortality figures are presented in Table I. There were 14 deaths in a total of 83 operative cases, a mortality of 16.9 per cent. The mortality percentage was higher in the 30 gastric cases (26.6 per cent) than in the 53 duodenal cases (11.3 per cent).

The most striking factor observed to modify the mortality rate is age. The mortality for 24 patients above 50 years of age was 41.6 per cent, while in 59 patients below 50 years of age, the mortality was 6.78 per cent (Table III).

The well-recognized factor of the time elapsed between perforation and operation is indicated in Fig. 1. Fifty-nine patients operated upon twelve hours or sooner following perforation of ulcer showed a mortality rate of 13.6 per cent as compared to 25.0 per cent in 24 patients operated upon after twelve hours following perforation.

Twenty of the patients were treated with sulfanilamide applied locally at the site of perforation, including 9 supplemented by parenteral administration. Four others received chemotherapy by the parenteral

Received for publication, March 15, 1943.

route alone. Of the 24 patients treated with sulfanilamide, there were 4 deaths, a mortality of 16.6 per cent as compared to the gross mortality of 16.9 per cent. Two of the deaths occurred in patients over 50 years of age, and 2 in those below 50 years of age.

Causes of Death.—There was a total of 14 deaths, 10 in patients over 50 years of age and 4 in those under 50 years of age. The causes of death for the patients over 50 years of age were as follows: peritonitis 5, pneumonia 4, and peritonitis with subphrenic abscess 1; and for the patients under 50 years of age: pneumonia 2, atelectasis with pneumonia 1, and peritonitis with bleeding gastric ulcer 1.

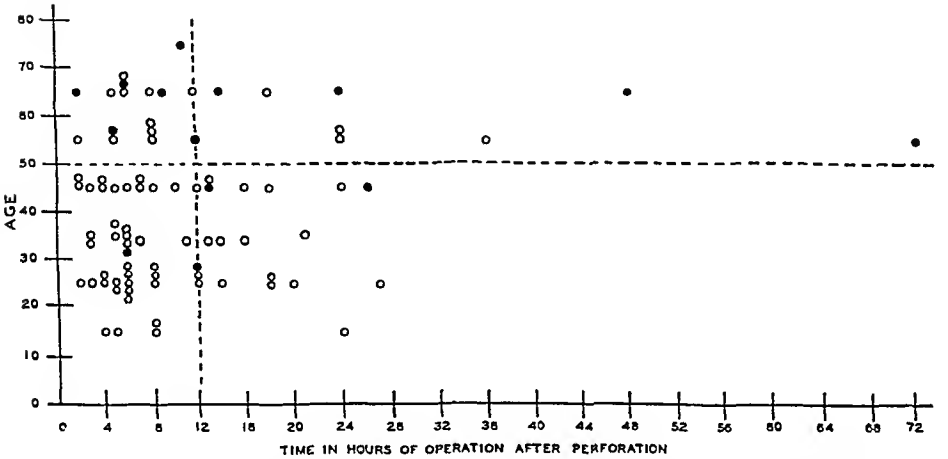

Fig 1.—Scattergram showing results from operation on acute perforated gastric and duodenal ulcers showing mortality in relation to age and to the elapsed time between perforation and operation. Circles indicate survival and dots indicate death.

DISCUSSION

The results of this study need little comment. The average mortality in the present series (16.9 per cent) of 83 cases is well below the average mortality in a collected series (Table II) of more than 7500 cases (26.8 per cent). No attempt can be made to ascribe this difference to any factor or combination of factors. It is unlikely that the material is any more favorable than a cross section of the material in the collected reports would represent. One-third of the patients were operated upon 12 hours or more after perforation and in this third there occurred 57 per cent of the deaths.

The effect of the age of the patient on mortality has probably not received in the literature the attention it seems to deserve on the basis of the present figures. Nearly one-third of this series of acute perforations occurred in patients over 50 years of age; and in that group the mortality was more than six times the mortality in younger individuals. In addition to offering valuable prognostic indications, these data suggest that no series of results in acute perforated ulcers is significant

TABLE I

UNIVERSITY OF VIRGINIA HOSPITAL SERIES

TYPE OF OPERATION	RECOVERED	DIED
Acute Perforated Gastric Ulcers		
1. Closure perforation	17	6
2. Closure perforation, posterior gastroenterostomy	1	1
3. Pyloroplasty, posterior gastroenterostomy	1	0
4. Excision and closure of perforation	1	1
5. Excision and gastroenterostomy	1	0
6. Gastric resection and gastrojejunostomy	1	0
Total, 30 cases Deaths, 8 Mortality, 26.6%		
Acute Perforated Duodenal Ulcers		
1. Closure perforation	27	4
2. Excision and pyloroplasty	17	0
3. Closure perforation, gastroenterostomy	3	2
Total, 53 cases Deaths, 6 Mortality, 11.3%		
Acute Perforated Gastric and Duodenal Ulcers		
Total, 83 cases Deaths, 14 Mortality, 16.9%		

TABLE II

COLLECTED SERIES

AUTHOR	HOSPITAL	NUMBER OF CASES	MORTALITY (%)	YEAR
Corff	Temple University	63	25.8	1936
Davidson and Rudder	Emory University	152	28.0	1940
Debakey	Charity	209	18.2	1940
Donoghue and Jacobs	Cook County	200	24.5	1942
Eliason and Ebeling	University of Pennsylvania	72	47.2	1934
Evans	Liverpool	67	22.0	1926
Fallis	Henry Ford	100	20.0	1938
Graham	Toronto General	51	2.0	1937
Graves	Report from German and	1345	50.9	1907-1908
	Central Europe	1394	20.0	1918-1926
		918	16.6	1926-1931
Griswold and Antoncic	Louisville City	102	19.6	1941
Judin	Moscow	418	12.8	1937
Kelly	St. Louis City	140	27.8	1939
McCreery	Bellevue	170	20.5	1938
Morrison	Boston City	200	21.0	1935
Parker	Roper	52	52.0	1941
Read	Grady	100	30.0	1938
Ross and Letourneau	Montreal General	228	20.6	1939
Sallick	Beekman St., N. Y.	74	10.8	1936
Sangster	St. James, Loudon	100	23.0	1937
Shawan	Detroit Receiving	389	25.4	1938
Southam	Manchester Royal Infirmary	46	9.0	1922
Stenbuck	Mt. Sinai	88	31.0	1927
Thompson.	Los Angeles	500	28.7	1939
Tilton	Broad Street, N. Y.	52	2.0	1936
Ulfelder and Allen	Massachusetts General	334	26.9	1942
White and Patterson	Roosevelt.	79	21.5	1931
Total		7564	Ave. 26.8	
Paletta and Hill	University of Virginia	83	16.9	

without reference to age. Although the difference recorded here is greater than that shown in any other series, those other authors[4, 6, 7, 16, 25] who have calculated the mortality by age (Table III) report an average mortality (45.9 per cent) in the older group more than twice that in the younger group (19.3).

TABLE III

INFLUENCE OF AGE ON MORTALITY

AUTHOR	MORTALITY PERCENTAGE	
	UNDER 50 YEARS (%)	OVER 50 YEARS (%)
Davidson and Rudder	26.6	43.7
Debakey	19.0	45.5
Donoghue and Jacobs	21.25	37.5
Graves	20.5	50.0
Richardson	16.6	75.0
Average	19.3	45.9
Paletta and Hill	6.78	41.6

Perforation of a gastric ulcer seems to be more dangerous than that of a duodenal ulcer, as demonstrated by collected figures (Table IV) from authors reporting the site.[1, 4, 6, 7, 8, 24, 25, 28, 30] The average mortality in the former group is 33.2 per cent and in the latter 21.6 per cent.

The place of drainage of the peritoneum in the treatment of acute perforated peptic ulcers is still debated in the literature. A large number of authors[1, 2, 8, 9, 14, 15, 20, 29, 30] have written on this problem, including Guthrie[18] (1923) and Trout[34] (1935), who sent questionnaires to leading surgeons inquiring whether they employed drainage in the management of their cases. A review of these papers reveals no unanimity

TABLE IV

INFLUENCE OF SITE ON MORTALITY

AUTHOR	MORTALITY PERCENTAGE	
	GASTRIC (%)	DUODENAL (%)
Collinson	53.8	30.8
Davidson and Rudder	27.0	24.0
Debakey	33.3	21.1
Donoghue and Jacobs	24.2	23.4
Eliason and Ebeling	42.8	48.2
Read	34.7	26.0
Richardson	50.0	31.2
Sangster	29.2	16.0
Southam	9.0	5.0
Average	33.2	21.6
Paletta and Hill	26.6	11.3

of opinion, although there is a tendency away from the use of drainage. It is possible that the absence of drainage in this series may be a factor. Certainly the results shown would not suggest the wisdom of any change in the present policy. Drainage of the peritoneum, except in the pres-

ence of granulation tissue, has been taught in this clinic for many years as an anachronism going back to the earliest days of surgical peritoneal invasion and even to the pre-Listerian treatment of wounds. The work of Yates,[38] nearly forty years ago, demonstrates the futility of peritoneal drainage. Without assuming that the present figures prove the lack of value in drainage, it may be said fairly that they present no argument in its favor.

Favorable reports have appeared on the use of sulfanilamide. Griswold and Antoncic[17] (1941) reported one death in 12 operative cases of perforated ulcer in which sulfanilamide was used locally. Ulfelder and Allen[35] (1942) attribute the sharp drop in their mortality rate in 1940 to the use of sulfanilamide. The apparent influence of sulfanilamide in the mortality of this group of cases is insignificant. This may be due to the small series of cases treated by chemotherapy.

SUMMARY

Eighty-three patients with acute perforation of gastric and duodenal ulcer were operated on at the University of Virginia Hospital in the years 1925 to 1942. There were 14 deaths, a mortality of 16.9 per cent. In the gastric group of cases, the mortality was more than twice that in the duodenal group. Patients over 50 years of age showed a mortality six times that seen in patients under 50 years of age. There was a mortality of 25 per cent for the patients operated upon after 12 hours following the perforation as compared to a mortality of 13.6 per cent for the group operated upon 12 hours or sooner following perforation. The influence of sulfanilamide on the mortality in this group of cases is not perceptible.

We are indebted to Dr. E. P. Lehman for his helpful suggestions during this study.

REFERENCES

1. Collinson, H.: J. A. M. A. 63: 1184, 1914.
2. Colp, R.: New York State J. Med. 29: 13, 1929.
3. Corff, M.: Am. J. Surg. 31: 77, 1936.
4. Davidson, T. C., and Rudder, F. F.: South. Surgeon 9: 75, 1940.
5. Deaver, J. B., and Pfeiffer, D. B.: Ann. Surg. 73: 441, 1921.
6. Debakey, M.: SURGERY 8: 852, 1940; 6: 1028, 1940.
7. Donoghue, J. B., and Jacobs, M. B.: Illinois M. J. 81: 62, 1942.
8. Eliason, E. L., and Ebeling, W. W.: Am. J. Surg. 24: 63, 1934.
9. Eliason, E. L., and North, J. P.: Ann. Surg. 105: 507, 1937.
10. Evans, A. J.: Brit. M. J. 1: 184, 1926.
11. Fallis, L. S.: Am. J. Surg. 41: 427, 1938.
12. Finney, J. T.: Am. J. Surg. 1: 323, 1926.
13. Fleming, B. L.: J. A. M. A. 97: 6, 1931.
14. Gilmour, J.: Brit. J. Surg. 20: 78, 1932-33.
15. Graham, R. R.: Surg., Gynec. & Obst. 64: 235, 1937.
16. Graves, A.: Ann. Surg. 98: 197, 1933; Internat. S. Digest 16: 259, 1933.
17. Griswold, R. A., and Antoncic, R. F.: Ann. Surg. 113: 791, 1941.
18. Guthrie, D.: New York State J. Med. 23: 66, 1923.
19. Judin, S. S.: Surg., Gynec. & Obst. 64: 63, 1937.
20. Kelly, M.: SURGERY 6: 524, 1939.
21. McCreery, J. A.: Ann. Surg. 107: 350, 1938.

22. Morrison, W. R.: New England J. Med. 213: 447, 1935.
23. Parker, E. F.: SURGERY 10: 49, 1941.
24. Read, J. C.: South. Surgeon 7: 436, 1938.
25. Richardson, E. P.: Boston, M. & S. J. 176: 158, 1917.
26. Ross, A., and Letourneau, C.: Canad. M. A. J. 41: 473, 1939.
27. Sallick, M. A.: Ann. Surg. 104: 853, 1936.
28. Sangster, A. H.: Lancet 2: 1311, 1939.
29. Shawan, H. K.: Am. J. Surg. 40: 70, 1938.
30. Southam, A. H.: Brit. M. J. 1: 556, 1922.
31. Stenbuck, J. B.: Ann. Surg. 85: 713, 1927.
32. Thompson, H. L.: J. A. M. A. 113: 2015, 1939.
33. Tilton, B. T.: Am. J. Surg. 32: 238, 1936.
34. Trout, H.: Am. J. Surg. 46: 621, 1939; J. A. M. A. 104: 6, 1935.
35. Ulfelder, H., and Allen, A. W.: New England J. Med. 227: 780, 1942.
36. White, W. C., and Patterson, H. A.: Ann. Surg. 94: 212, 1931.
37. Williams, H., and Walsh, C. H.: Lancet 218: 9, 1930.
38. Yates, J. L.: Am. J. Surg. 1: 473, 1905.

ence of granulation tissue, has been taught in this clinic for many years as an anachronism going back to the earliest days of surgical peritoneal invasion and even to the pre-Listerian treatment of wounds. The work of Yates,[38] nearly forty years ago, demonstrates the futility of peritoneal drainage. Without assuming that the present figures prove the lack of value in drainage, it may be said fairly that they present no argument in its favor.

Favorable reports have appeared on the use of sulfanilamide. Griswold and Antoncic[17] (1941) reported one death in 12 operative cases of perforated ulcer in which sulfanilamide was used locally. Ulfelder and Allen[35] (1942) attribute the sharp drop in their mortality rate in 1940 to the use of sulfanilamide. The apparent influence of sulfanilamide in the mortality of this group of cases is insignificant. This may be due to the small series of cases treated by chemotherapy.

SUMMARY

Eighty-three patients with acute perforation of gastric and duodenal ulcer were operated on at the University of Virginia Hospital in the years 1925 to 1942. There were 14 deaths, a mortality of 16.9 per cent. In the gastric group of cases, the mortality was more than twice that in the duodenal group. Patients over 50 years of age showed a mortality six times that seen in patients under 50 years of age. There was a mortality of 25 per cent for the patients operated upon after 12 hours following the perforation as compared to a mortality of 13.6 per cent for the group operated upon 12 hours or sooner following perforation. The influence of sulfanilamide on the mortality in this group of cases is not perceptible.

We are indebted to Dr. E. P. Lehman for his helpful suggestions during this study.

REFERENCES

1. Collinson, H.: J. A. M. A. 63: 1184, 1914.
2. Colp, R.: New York State J. Med. 29: 13, 1929.
3. Corff, M.: Am. J. Surg. 31: 77, 1936.
4. Davidson, T. C., and Rudder, F. F.: South. Surgeon 9: 75, 1940.
5. Deaver, J. B., and Pfeiffer, D. B.: Ann. Surg. 73: 441, 1921.
6. Debakey, M.: SURGERY 8: 852, 1940; 6: 1028, 1940.
7. Donoghue, J. B., and Jacobs, M. B.: Illinois M. J. 81: 62, 1942.
8. Eliason, E. L., and Ebeling, W. W.: Am. J. Surg. 24: 63, 1934.
9. Eliason, E. L., and North, J. P.: Ann. Surg. 105: 507, 1937.
10. Evans, A. J.: Brit. M. J. 1: 184, 1926.
11. Fallis, L. S.: Am. J. Surg. 41: 427, 1938.
12. Finney, J. T.: Am. J. Surg. 1: 323, 1926.
13. Fleming, B. L.: J. A. M. A. 97: 6, 1931.
14. Gilmour, J.: Brit. J. Surg. 20: 78, 1932-33.
15. Graham, R. R.: Surg., Gynec. & Obst. 64: 235, 1937.
16. Graves, A.: Ann. Surg. 98: 197, 1933; Internat. S. Digest 16: 259, 1933.
17. Griswold, R. A., and Antoncic, R. F.: Ann. Surg. 113: 791, 1941.
18. Guthrie, D.: New York State J. Med. 23: 66, 1923.
19. Judin, S. S.: Surg., Gynec. & Obst. 64: 63, 1937.
20. Kelly, M.: SURGERY 6: 524, 1939.
21. McCreery, J. A.: Ann. Surg. 107: 350, 1938.

tion were negative. Gastric analysis showed 58° free hydrochloric acid and 73° total acid. Microscopic examination of the fasting stomach contents showed 1 to 2 white blood cells, an occasional erythrocyte, yeast 2 plus, and starch 4 plus. The serum proteins, plasma chlorides, and clotting, bleeding, and prothrombin times were normal.

The patient was prepared for operation with daily gastric lavage, adequate fluid intake intravenously, and vitamins parenterally including vitamin K.

At operation, Nov. 11, 1940, under spinal anesthesia, there were found distributed over the distal third of the anterior wall of the stomach many small subserosal yellowish-gray nodules 1 to 2 mm. in diameter. There was no free fluid present. Exploration revealed a firm indurated lesion approximately 5 to 7 cm. in diameter on the posterior wall of the first portion of the duodenum. The mass was adherent to and apparently involved the head of the pancreas and obstructed the pylorus. A definite ulcer crater was palpable. There were numerous large, soft lymph nodes along both the lesser and greater curvatures. Biopsies were taken from the wall of the stomach and duodenum and three lymph nodes were excised. Frozen sections of these tissues were tentatively reported as indicating lymphosarcoma but before the abdomen was closed the report was changed to inflammatory tissue. Due to the question of lymphosarcoma and since removal of the lesion would have been a long and difficult procedure, it was decided to establish a posterior isoperistaltic gastrojejunostomy.

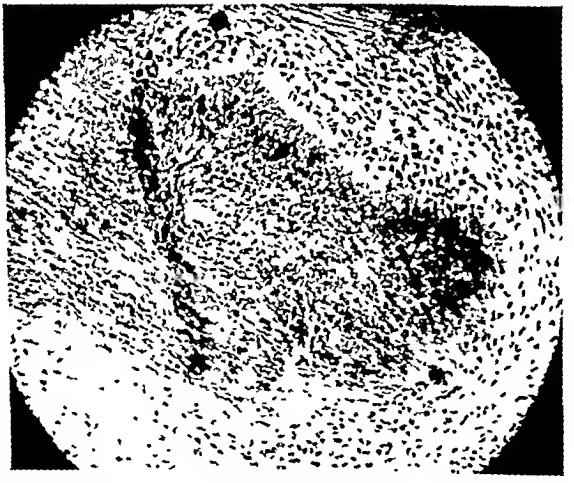

Fig 1 (Case 1).—Section from serosa of stomach showing the actinomyces (×220).

The postoperative course was essentially uncomplicated, the highest temperature being recorded at 100° F. (rectal) with a highest pulse rate of 100. She was discharged the sixteenth postoperative day on a five meal gastric diet. An examination of the gastric contents removed through the suction tube after operation failed to reveal fungi.

Pathologic Report.—The specimen consisted of two small pieces of tissue from the stomach wall and seven small pieces of lymph nodes. Microscopic examination of the biopsies from the stomach wall showed bundles of smooth muscle containing irregular clumps of pink staining amorphous material. Scattered throughout were bluish areas, around the periphery of which were many giant cells and a few polymorphonuclear cells, plasma cells, lymphocytes, and eosinophiles (Fig. 1). The blue-staining material presented radially arranged structures having the appearance of clubbed mycelia. A bacterial stain revealed small filaments but no other organisms.

ACTINOMYCOSIS OF STOMACH AND DUODENUM

Report of Two Cases

Edwin W. Shearburn,* M.D., Charlottesville, Va.

(From the Department of Surgery and Gynecology, University of Virginia School of Medicine)

ALTHOUGH innumerable cases of mycotic infections arising from the alimentary canal in the ileocecal region have been reported, actinomycosis of the stomach and duodenum is a rare disease. Sanford and Voelker,[22] in reviewing actinomycosis in the United States up to 1925, did not list any cases of infection of the stomach or duodenum. Reports in the English and American literature have been infrequent. Blain,[5] in 1933, reported the first case of primary actinomycosis of the stomach in the American literature and stated that there was only one other thoroughly authenticated case in the foreign literature (Nathan's case[19]). More recently (1939) Cogniaux[8] reported a case of primary actinomycosis of the stomach. Two reports of actinomycotic infections primary in the duodenum have been found in the English and American literature.[21, 26] Numerous articles dealing with other mycotic infections of stomach and duodenum have been reported in the German literature and a few in the American literature.

Graves and Ochsner[11] reported two cases of subphrenic actinomycosis treated by the posterior extraserous approach; the patients in both of these cases died of widespread infection. The authors stated that only eight cases of actinomycosis of the subphrenic space had been previously reported and none have been reported since that time.

CASE REPORTS

Case 1.—A white woman, aged 24 years, entered the University of Virginia Hospital Nov. 6, 1940, with a history of recurrent attacks of right upper quadrant and epigastric pain for six or seven years. For the previous eight months the attacks had been more severe and there had been associated nausea and vomiting. There had been some relief with soda but no food relief. She had vomited bright red blood on one occasion but there was no history of tarry stools. Gastrointestinal x-ray series in the outpatient department showed a complete pyloric obstruction and she was admitted to the hospital for study.

General physical examination in the hospital revealed no significant findings other than pyorrhea alveolaris.

Laboratory findings revealed: erythrocyte count, 4.47 million; hemoglobin, 11 Gm. per 100 c.c. (71 per cent, Dare method); leucocyte count, 9,000. The Schilling differential count revealed a slight shift to the left. Urinalysis and stool examina-

*Captain, Medical Corps, U. S. Army.

Received for publication, Nov. 30, 1942.

induration were noted in the region of the old right rectus scar and on July 29, 1941, incision and drainage were carried out, opening into a subcutaneous abscess in the region of the previous operative scar. Following the last operative procedure, the patient's temperature became essentially normal for the remainder of his hospital stay. Both the anterior and posterior wounds closed fairly rapidly until only small draining sinuses were present. Attempts at demonstrating radiographically a communication between the anterior and posterior wounds by the injection of lipiodol into the sinuses were unsuccessful. Routine cultures of the wound recovered no organisms from the subphrenic abscess and *Bacillus coli* from the anterior abscess. The patient was discharged forty-one days after admission and was followed through the outpatient department for dressings thereafter.

Drainage persisted from both the anterior and posterior wounds and the patient was readmitted to the hospital on Oct. 21, 1941. Since leaving the hospital he had had drained by his local physician a small subcutaneous abscess on the lateral chest wall approximately midway between the anterior and posterior wounds.

Examination at the time of admission on this occasion was essentially negative except for draining sinuses in the region of the subphrenic wound and a small sinus opening in the right upper rectus scar. The temperature was normal, the erythrocyte count was 3.5 million with 58.4 per cent hemoglobin (9 gm.) and 30,200 leucocyte count. There was a moderate shift to the left by the Schilling differential. Urinalysis was normal.

On Oct. 24, 1941, lipiodol was injected into the posterior sinus and an extensive system of communicating sinuses in the posterior abdominal wall and abdomen was demonstrated by x-ray but no connection between the anterior and posterior sinuses could bo demonstrated. Routine cultures and cultures for actinomycosis were carried out on numerous occasions but no definite actinomycosis was demonstrable. *Staphylococcus aureus* nonhemolyticus and diphtheroids were the only bacteria reported.

It was felt that the draining tracts should be opened and better drainage provided. Therefore, on October 27, under general anesthesia, all the sinus tracts were laid open throughout their extent and granulation tissue removed for biopsy and cultures. The wound bled considerably and it was necessary to pack to prevent serious hemorrhage.

Pathologic Report.—The specimen consisted of a number of fragments of granulation tissue in which there was a marked inflammatory reaction. In one segment of this granulation tissue a mass of radially growing mycelial filaments which had the typical clubbed-shaped bodies on their ends were found. Diagnosis: Actinomycosis (Fig. 2).

The patient's postoperative course was fairly satisfactory. He was treated with thymol by mouth and thymol in oil in the dressings. He was also given a course of sulfadiazine without appreciable improvement. He was discharged on the twenty-sixth postoperative day. At the time of his discharge a small persistent sinus was present posteriorly but drainage was minimal. After the second discharge from the hospital he was almost asymptomatic at home but when he returned to the outpatient department on Dec. 13, 1941, for a routine checkup, he was found to have a large nontender mass in the right upper quadrant which extended down to the iliac crest. In addition, a small fluctuant abscess was found along the right lower costal margin and a small draining sinus persisted at the lower end of the right rectus scar. There was also evidence of fluid in the peritoneal cavity.

He was again admitted on Dec. 15, 1941, for further treatment. Bacteriologic studies of the purulent material aspirated in the outpatient department were suggestive of actinomycosis. Examination at the time of the last admission revealed dullness in the chest with suppression of breath sounds by auscultation in the right posterior base. The abdomen was distended, tympanitic, and free fluid was thought

Acid-fast stains were negative. The general architecture of the lymph nodes was preserved but there was a marked reticulo-endothelial hyperplasia. There were a few scattered mixed inflammatory cells. Diagnosis: Mycotic infection of the stomach wall, probably by one of the actinomyces. Chronic lymphadenitis.

The patient returned on Dec. 12, 1940, asymptomatic and in excellent general condition. Gastrointestinal x-ray examination showed a satisfactorily functioning gastroenterostomy and a marked distortion of the duodenal bulb.

She was again seen in March, 1941, had gained twenty-eight pounds in weight and was still asymptomatic.

A recent report from the patient stated that she has no symptoms and is feeling well. There has been no gastrointestinal complaint.

Summary.—A case of gastric and duodenal actinomycosis with associated pyloric obstruction and duodenal ulcer is reported, apparently asymptomatic eighteen months after operation. The presence of actinomyces in the wall of the stomach suggests a similar infection of the duodenal ulcer.

CASE 2.—A white man, aged 41 years, was admitted to the University Hospital on July 1, 1941, complaining of dull pain in the right upper quadrant of two months' duration. There had been no history of nausea and vomiting, no cough, no hemoptysis nor hematemesis. There had been a moderate diarrhea due to medication by the local physician. There had been a loss of weight of approximately twenty-five pounds during the previous two months. Ten months prior to admission the patient had been operated on elsewhere for a perforated "peptic" ulcer which had been closed. The postoperative course was apparently uneventful. The subsequent course had been essentially normal until the onset of the present illness.

On admission the temperature was 99.8° F., the pulse was 80, and the respirations were 16. Physical examination revealed a pale malnourished individual. The teeth showed marked pyorrhea alveolaris. There was moderate generalized lymphadenopathy, discrete and nontender. Examination of the chest revealed dullness on the right from the eighth dorsal vertebra downward, with decrease in the breath sounds and whispered voice. The diaphragm apparently moved on respiration but was high on the right. A few moist râles were heard in the base of the right lung posteriorly. There was a soft systolic murmur at the apex of the heart and over the precordium. Abdominal examination revealed voluntary muscle spasm in the right upper quadrant with some tenderness on deep palpation. There was a long right rectus scar. The liver edge was thought to be palpable one fingerbreadth below the costal margin.

Laboratory studies at the time of admission revealed an erythrocyte count of 2.9 million with 61.6 per cent hemoglobin (9.5 Gm.). The leucocyte count was 19,200 with a moderate shift to the left by the Schilling differential. Urinalysis was essentially normal.

X-ray examination of the chest, on July 2, showed an immobile diaphragm on the right. The lung fields were essentially negative. Impression of the radiologist was infection beneath the diaphragm, liver abscess or perinephric abscess being the most likely. The clinical impression, however, was subphrenic abscess.

Exploration of the right subphrenic space posteriorly was carried out on July 7, 1941, by the extraserous approach, removing the twelfth rib on the right. A large abscess cavity was entered and approximately 200 c.c. of purulent material were released.

The patient's postoperative course was entirely satisfactory except that the fever which was as high as 102° F. preoperatively persisted up to 101° F. daily. The anemia was corrected by several blood transfusions. On July 27, tenderness and

induration were noted in the region of the old right rectus scar and on July 29, 1941, incision and drainage were carried out, opening into a subcutaneous abscess in the region of the previous operative scar. Following the last operative procedure, the patient's temperature became essentially normal for the remainder of his hospital stay. Both the anterior and posterior wounds closed fairly rapidly until only small draining sinuses were present. Attempts at demonstrating radiographically a communication between the anterior and posterior wounds by the injection of lipiodol into the sinuses were unsuccessful. Routine cultures of the wound recovered no organisms from the subphrenic abscess and *Bacillus coli* from the anterior abscess. The patient was discharged forty one days after admission and was followed through the outpatient department for dressings thereafter.

Drainage persisted from both the anterior and posterior wounds and the patient was readmitted to the hospital on Oct. 21, 1941. Since leaving the hospital he had had drained by his local physician a small subcutaneous abscess on the lateral chest wall approximately midway between the anterior and posterior wounds.

Examination at the time of admission on this occasion was essentially negative except for draining sinuses in the region of the subphrenic wound and a small sinus opening in the right upper rectus scar. The temperature was normal, the erythrocyte count was 3 5 million with 58 4 per cent hemoglobin (9 gm.) and 30,200 leucocyte count. There was a moderate shift to the left by the Schilling differential. Urinalysis was normal.

On Oct 24, 1941, lipiodol was injected into the posterior sinus and an extensive system of communicating sinuses in the posterior abdominal wall and abdomen was demonstrated by x ray but no connection between the anterior and posterior sinuses could be demonstrated. Routine cultures and cultures for actinomycosis were carried out on numerous occasions but no definite actinomycosis was demonstrable. *Staphylococcus aureus* nonhemolyticus and diphtheroids were the only bacteria reported.

It was felt that the draining tracts should be opened and better drainage provided Therefore, on October 27, under general anesthesia, all the sinus tracts were laid open throughout their extent and granulation tissue removed for biopsy and cultures The wound bled considerably and it was necessary to pack to prevent serious hemorrhage.

Pathologic Report—The specimen consisted of a number of fragments of granulation tissue in which there was a marked inflammatory reaction. In one segment of this granulation tissue a mass of radially growing mycelial filaments which had the typical clubbed shaped bodies on their ends were found Diagnosis: Actinomycosis (Fig. 2)

The patient's postoperative course was fairly satisfactory. He was treated with thymol by mouth and thymol in oil in the dressings He was also given a course of sulfadiazine without appreciable improvement. He was discharged on the twenty sixth postoperative day At the time of his discharge a small persistent sinus was present posteriorly but drainage was minimal. After the second discharge from the hospital he was almost asymptomatic at home but when he returned to the outpatient department on Dec 13, 1941, for a routine checkup, he was found to have a large nontender mass in the right upper quadrant which extended down to the iliac crest In addition, a small fluctuant abscess was found along the right lower costal margin and a small draining sinus persisted at the lower end of the right rectus scar There was also evidence of fluid in the peritoneal cavity.

He was again admitted on Dec 15, 1941, for further treatment. Bacteriologic studies of the purulent material aspirated in the outpatient department were suggestive of actinomycosis Examination at the time of the last admission revealed dullness in the chest with suppression of breath sounds by auscultation in the right posterior base The abdomen was distended, tympanitic, and free fluid was thought

to be present. There was a large mass in the right upper quadrant apparently attached to the liver and extending from the costal margin to the level of the iliac crest on the right and nearly to the midline on the left. There was a large draining sinus in the right flank, a smaller one at the level of the umbilicus, and one in the previous right rectus incision scar. Fluoroscopy and x-ray on the day of admission showed the right diaphragm to be elevated to the level of the anterior end of the fourth rib and to be almost completely fixed. The lung fields were clear. A moderate anemia was again present and urinalysis was normal. The patient was afebrile.

On Dec. 16, 1941, under general anesthesia an incision was made into the sinus tract in the right upper quadrant and a large abscess was opened into just beneath the right rectus muscle which extended from the midline across to the right flank. The entire abscess cavity was laid open by a wide incision and the wound packed open. A small draining tract superficially in the right flank was also incised and packed open.

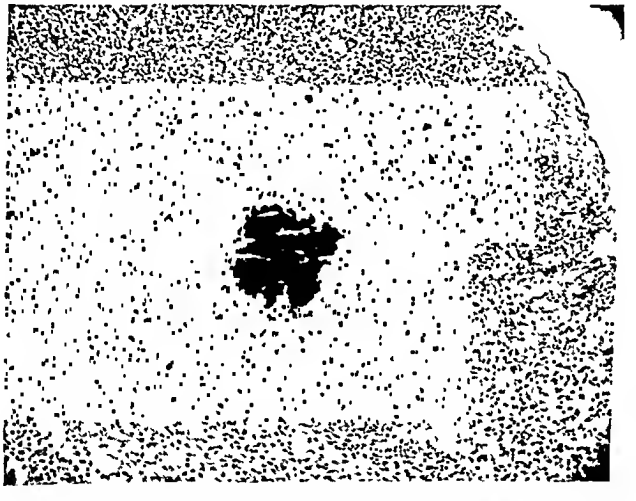

Fig. 2 (Case 2).—Section of granulation tissue showing actinomyces (×240).

Cultures and tissue for biopsy were taken from the wound at operation. Cultures failed to reveal actinomycosis and pathologic study revealed granulation tissue. He was again treated with thymol by mouth and thymol packs in the wound. A course of sulfadiazine was also given but this was not tolerated well and an insufficient amount to obtain an adequate blood concentration was given. Several transfusions were given to correct the anemia. The patient's postoperative course was relatively smooth. The wounds filled in by granulation tissue. He remained afebrile and there was little drainage. On the thirty-fifth postoperative day he was again discharged from the hospital with a small draining sinus in the right upper quadrant and one in the posterior subphrenic region.

The patient was examined on April 24, 1942. His general condition was improved. His appetite was good and there had been a gain in weight. The anterior abdominal wall was entirely healed and no intra-abdominal masses were palpable. However, two small superficial sinus tracts remained in the scar of the previous subphrenic drainage and biopsies of the granulations lining the tracts revealed actinomyces in the tissue. Cultures taken at the same time were overgrown by staphylococci but a direct smear revealed the presence of actinomyces. An x-ray of the chest showed the lung fields to be clear and the right diaphragm was lower than at a previous examination.

Because mycotic infection still persisted the patient was again admitted to the hospital on May 6, 1942, and exploration under general anesthesia revealed a small sinus tract extending from the posterior sinus opening down to the right superoanterior iliac spine and terminating in a small collection of granulation tissue. The bone was slightly rough. The tract was excised and packed open. Sulfadiazine by mouth was given in doses sufficient to maintain a blood level above 10 mg. per cent. Thymol was used in the packs which were changed daily. The wound was healing by granulation when the patient was discharged May 24, 1942. Biopsies, smear, and culture were all positive for actinomycosis.

The patient returned for examination on June 29, 1942. He had gained eight pounds in weight and had no complaints. There was a small amount of drainage from the center of the most recent incision and the wound was granulating over an area 8 by 1 cm. Otherwise examination was negative.*

Summary.—A case of actinomycotic infection of the subphrenic space, presumably arising from a perforated duodenal ulcer, is reported.

DISCUSSION

Etiology.—The role of fungi in inflammatory lesions of the stomach and duodenum is not clear. There is a general agreement among the many writers on this subject that fungi in the stomach and duodenum are not the primary cause of ulceration. The pathogenicity of fungi in already established ulcers seems to be the point of controversy. Askanazy[2] presented experimental evidence to show that fungi present in gastroduodenal ulcerations influenced the growth and promoted chronicity in the lesion. Several authors[6, 12, 16, 25] supported this opinion. Others[1, 10, 15, 20, 24] attached little significance to the presence of fungi in the exudate at the base and in the margins of such ulcers. Hauser[13] reviewed the situation and concluded that fungi might inhibit healing to some degree but that the inhibitory effect was of minor importance compared to the influence of other factors. Singer[23] thought fungi were of little clinical importance in gastric ulcerations but that there were insufficient clinical data available up to that time upon which to base final conclusions.

Meyer[17] stated that various bizarre organisms reported by different authors probably represented the same organism altered by the type of media used, especially in regard to the hydrogen-ion concentration.

On the basis of the two cases presented here and the reports in the literature, no definite opinion as to the pathogenicity of fungi in gastric and duodenal ulceration can be formulated. After perforation occurs through either a gastric or duodenal ulcer in which fungi are present, then the problem becomes one of peritoneal contamination and under

*This patient was again studied on Nov. 10 and 11, 1942 after Dr. Shearburn's departure for active military duty. He w[illegible] the sinuses had almost completely healed, presenting only minute [illegible] were palpable. X-ray examination of the chest showed no abnor[illegible] elevation and immobility of the right diaphragm. Examination after a barium meal revealed deformity of the duodenal bulb without obstruction.

April 19, 1943. A recent report from another hospital stated that the patient had been admitted in bad condition. Except for the presence of anemia, no details were given. It may be assumed that this illness represents recurrence of actinomycosis. (E. P. L.)

these circumstances the presence of fungi may affect the subsequent course of infection.

Clinical Data.—Bearse[3] reviewed the literature, in 1938, and discussed the clinical findings, stressing the absence of any characteristic syndrome warranting a preoperative diagnosis. Singer[23] also pointed out the absence of any typical diagnostic features. To date, a preoperative diagnosis of actinomycosis of the stomach confirmed by operation has not been reported. However, Bearse[3] and Singer[23] state that bloody vomitus such as occurred in Case 1 of this report is an almost constant characteristic of a mycotic lesion of the stomach. Bearse urged the routine preoperative study of gastric washings for the presence of mycelia and suggested the possibility of a presumptive preoperative diagnosis by the demonstration of organisms in the gastric contents together with positive serologic evidence. However, in neither of the two cases reported herein was it possible to demonstrate fungi in the gastric washings.

The clinical features of the first case were essentially those of duodenal ulceration with increasing pyloric obstruction. The episode of hematemesis was not interpreted as being of more than the usual significance. In the second case, there was no history of bloody vomitus, either prior to or following perforation. The patient had had gnawing epigastric pain relieved by food and soda. The subphrenic infection was preceded by fatigue, malaise, anorexia, and vague epigastric and right upper quadrant discomfort. Later, pain became more severe and was aggravated by respiratory movements. There were no associated respiratory symptoms.

Treatment.—The treatment of gastroduodenal ulceration caused by or secondarily invaded by actinomycosis should in theory consist of resection of the involved part if this procedure is possible. However, the case reported by Blain[5] was treated by resection and although the patient survived the operation, death followed in eight months and at autopsy multiple liver abscesses were found from which actinomyces were recovered. DeCourcy-Wheeler[26] resected a portion of jejunum for actinomycotic infection of duodenum and jejunum and the patient died shortly after operation. X-ray therapy, large doses of potassium iodide, or one of the sulfonamides may be indicated when there is generalized abdominal infection. Thymol by mouth and locally has also been used in treating actinomycotic infections elsewhere in the body.[7, 9, 14, 18]

In the first case reported herein gastroenterostomy was performed because of the apparent risk from resection of so extensive a lesion involving the pancreas and also because the diagnosis was uncertain. Certainly the surgical treatment was in no way specific. The fact that the patient remained asymptomatic for a period of eighteen months following operation would seem to indicate that the mycotic infection is probably no longer a source of danger. During the early postoperative phase, thymol therapy was considered. However, her immediate and continued

excellent response to gastroenterostomy soon made it evident that any drug or x-ray therapy was contraindicated.

The second case reported is a proved case of subphrenic actinomycosis presumed to be the result of perforation of a duodenal ulcer harboring actinomyces. The problem at the stage in which the patient was first observed in this clinic was one of diffuse infection throughout the upper abdominal wall and subphrenic space. The response to adequate surgical drainage supplemented by thymol therapy has been good. Any share of thymol in the patient's improvement is, of course, not proved. The sulfonamide therapy did not result in a high enough blood concentration to be effective. It is possible that further therapy will be necessary if a permanent cure is to be hoped for. The course of peritoneal actinomycosis is so deceptive that a future exacerbation of the disease must be expected.*

SUMMARY

1. A case of proved mycosis of the stomach with duodenal ulcer is reported, asymptomatic at eighteen months. It is the only case found in the literature in which the patient lived more than one year after operation.

2. A case of subphrenic actinomycotic abscess with persistent infection is reported, presumed to be the result of actinomycotic infection resulting from perforation of a peptic ulcer.

3. It is impossible to determine whether the proved mycosis in the first case was the primary cause of duodenal ulcer and pyloric stenosis or whether the mycelia were merely secondary invaders. The same uncertainty is present regarding the etiology in the second case.

REFERENCES

1. Aschoff, L.: Aussprache zu Wissen, Verhandl. d. deutsch. path. Gesellsch. 18: 287, 1921. (Cited by Singer.[23])
2. Askanazy, M.: Ueber Bau und Entstehung des chronischen Magengeschwurs sowie Soorpilzbefunde in ihm, Virchows Arch. f. path. Anat. 250: 370-486, 1924.
3. Bearse, C.: Mycotic Infections of the Stomach, Am. J. Digest. Dis. 5: 674-676, 1938.
4. Bearse, C., and Pollock, L. H.: Mycotic Infections of the Stomach, Ann. Surg. 104: 167-174, 1936.
5. Blain, A. W.: Primary Actinomycosis of the Stomach, J. A. M. A. 100: 168-169, 1933.
6. Cafasso, K.: Ueber das Vorkommen des Soorpilzes im Magensafte beim Ulkus und bei anderen Erkrankungen des Magens, Med. Klin. 18: 828, 1922. (Cited by Singer.[23])
7. Clemens, H. H.: Actinomycosis. Report of a Case in a Child With Recovery Following Thymol Therapy, J. Pedint. 16: 487-494, 1940.
8. Cognianux, P.: L'Actinomycose gastrique primitive, J. de chir. et. ann. Soc. belge de chir. 38-36: 146-150, 1939.
9. Etter, L. E., and Schumacher, F. L.: Pulmonary Actinomycosis: Recovery After Thymol Therapy, J. A. M. A. 113: 1023-1024, 1939.
10. Frank, P. S.: Ueber die Beziehungen des Soorpilzes zu dem runden Magengeschwur, Wien. Arch. f. inn. Med. 5: 39-42, 1922. (Cited by Singer.[23])

*See footnote p. 43.

11. Graves, A. M., and Ochsner, A.: *Actinomycosis of the Subphrenic Space*, Am. J. Surg. 23: 54-62, 1934.
12. Hartwich, A.: Ueber das Vorkommen von Soor im chronischen Magengeschwur, in hämorrhagischen Erosionen und Magencarcinomen, Virchows Arch. f. path. Anat. 241: 116-135, 1923. (Cited by Singer.[23])
13. Hauser, G.: Infektiose und infektios-toxische Einflusse Der Soorpilz. Handbuch der speziellen pathologischen Anatomie und Histologie, Henke, F., and Lubarsch, O.: Vol. IV, Berlin, 1926, Julius Springer, pp. 736-741.
14. Joyce, T. M.: Thymol Therapy in Actinomycosis, Ann. Surg. 108: 910-917, 1938.
15. Kirch, E., and Stahnke, E.: Pathologisch-anatomische, klinische und tierexperimentelle Untersuchungen ueber die Bedeutung des Soorpilzes für das chronische [illegible] t. a. d. Grenzgeb. d. Med. u. Chir. 36: 174-200, 1923. [illegible]
16. Merke, F.: [illegible] des Soorpilzes für das chronischen Magengeschwur, Beitr. z. klin. Chir. 130: 549-566, 1924. (Cited by Singer.[23])
17. Meyer, A.: Infektion des Duodenums mit Blastomyceten und Blastomykosen. Ztschr. f. klin. Med. 121: 247-262, 1932. (Cited by Bearse and Pollock.[4])
18. Myers, H. B.: Thymol Therapy in Actinomycosis, J. A. M. A. 108: 1875, 1937.
19. Nathan, H.: Primäre Aktinomykose des Magens, Virchows Arch. f. path. Anat. 273: 480-495, 1929. (Cited by Blain.[5])
20. Nissen: Ueber die Bedeutung des Soorpilzes für das chronischen Magengeschwur, Verhandl. d. deutsch. path. Gesellsch. 18: 283-287, 1921. (Cited by Singer.[23])
21. Rabinowitz, L.: Ulceration of the Duodenum From Actinomycotic Infection, New England J. Med. 209: 236, 1933.
22. Sanford, A. H., and Voelker, M.: Actinomycosis in the United States, Arch. Surg. 11: 809-841, 1925.
23. Singer, H. A.: Mycotic Gastritis, Arch. Int. Med. 40: 873-890, 1927.
24. Sternberg, C.: Aussprache zu Wissen, Verhandl. d. deutsch. path. Gesellsch. 18: 286, 1921. (Cited by Singer.[23])
25. Von Meyenburg, H.: Ueber Schimmelpilzerkrankungen der Magenwand, Frankfurt. Ztschr. f. Path. 23: 86, 1920. (Cited by Singer.[23])
26. DeCourcy-Wheeler, W. I.: A Case of Actinomycotic Ulceration of Duodenum and Jejunum, Brit. J. Surg. 15: 430-437, 1928.

LIPOMAS OF THE GASTROINTESTINAL TRACT

With Special Reference to the Small Intestine Including the Ileum; Review of the Literature and Report of Six Cases

Lewis E. Schottenfeld, M.D., C.M., Brooklyn, N. Y.

(From the Department of Surgery and Pathology of the Jewish Hospital of Brooklyn)

LIPOMAS of the gastrointestinal tract are encountered with relative infrequency. Other benign tumors such as adenoma and myoma are fairly common. My interest in these tumors was aroused by a rare case of multiple lipomas of the ileum which produced an intussusception. A search through the hospital records disclosed five other cases, two surgical and three in which the lipoma was an incidental autopsy finding.

From a review of the literature it may be stated that the autopsy incidence of lipomas is greater than the operative findings, indicating that "silent" lipomas may exist without being recognized. In benign tumors of the gastrointestinal tract, the ileum is the most commonly involved site in the small bowel, and lipoma the second or third most common benign tumor encountered. More than one-half of all lipomas of the gastrointestinal tract are found in the small intestine and almost one-third in the ileum. Over one-third, or 100 cases, of all lipomas result in intussusception. In the small intestine, intussusception is found in 16.0 per cent of all lipomas and 44.0 per cent of all of those which intussuscepted.

The earliest recorded account of intestinal lipomas is that of Bauer in 1757 in his *Epistola de Molis Intestinorum*. Morel (1876[1]) reported a case of lipoma of the ileum which had invaginated and eventually protruded from the anus. Coupland (1879)[2] related a case of intussusception produced by a lipoma of the ileum which had gone unrecognized before the patient, a girl 16 years of age, was operated upon, with death following in thirty-six hours. Re-examination of an old museum specimen by Turner (1884)[3] revealed an intussusception of the small intestine produced by a fatty polypoid tumor. Chandler and Baldauf (1907)[5] reported a case, in an infant, of a subserous lipoma of the sigmoid which had twisted the bowel and caused an intestinal obstruction, with an uneventful recovery following excision of the tumor. Stetten (1909)[7] reported two cases after reviewing the literature which, up to 1909, comprised seventy-seven cases. Francini (1909)[6] described multiple submucous lipomas of the small intestine discovered during

Received for publication, Dec. 9, 1942.

the course of an operation for gastric carcinoma. Other cases of submucous lipomas of the ileum with intussusception have been reported by Harrigan (1916),[9] Bland-Sutton (1920),[10] Swanson (1924),[16] Horsley (1929),[22] McCloskey (1931),[26] Bargen (1932),[31] Knoepp (1935),[35] Rankin and Newell (1933),[34] Poston (1934),[36] Kirshbaum (1935),[40] Wilmoth (1936),[41] and Bonomini (1939).[45] A case of subserous lipoma was cited by Brechat (1920).[11] Two lipomas, one in the submucosa and one in the subserosa, were found in a patient treated by Vaccari (1923).[14] Multiple submucous lipomas were also described by Wiener and Polayes (1938).[42] Comprehensive papers on lipomas of the small intestine are recorded by Stetten (1909),[7] Mirrolli (1929),[21] and Raiford (1932).[29] Accounts of exceptional cases of multiple lipomas with intussusception are less common.

SITE AND INCIDENCE

Several analyses concerning the site and incidence of these tumors are found in the literature. Notably are those by Stetten (1909),[7] Odelberg (1921),[12] Thorek (1923),[15] King (1917), Forni (1930),[23] Wakeley and Paul (1931),[24] and Comfort (1931).[25]

Roan (1932),[28] in a review of 100 authentic cases of benign tumors of the small intestine causing intussusception, found fifty-nine cases in the ileum heading the list, and eleven lipomas the third most frequent benign tumor. Raiford (1932),[29] analyzed 986 cases of tumors of the gastrointestinal tract, of which 210 were benign and 776 malignant. Eighty-eight (8.9 per cent) tumors were in the small intestine, of which fifty (56.8 per cent) were benign; only seven were lipomas and they ranked third in frequency of all benign growths.

Koster (1933)[32] quotes King, who cited only six intestinal lipomas encountered in 44,654 intraperitoneal operations performed at the Mayo Clinic.

The autopsy incidence of intestinal lipomas from the available reports in the literature is tabulated in Table I.

TABLE I

AUTOPSY INCIDENCE OF LIPOMAS OF THE GASTROINTESTINAL TRACT

	NO. OF AUTOPSIES	LIPOMAS	PER CENT	NO. IN SMALL BOWEL
Comfort[25] (Mayo Clinic)	3,924	24	0.60	10 (4 ileum)
Kirshbaum[40]	5,754	9	0.02	6 (3 ileum)
Eliason and Wright (quoted by Comfort)	8,000	1	0.01	
Staemmler (quoted by Kirshbaum)	17,000	9	0.05	
Schottenfeld	4,063	3	0.07	
Total	38,741	46	0.118	16 (7 ileum)

Three of the six cases in my series were incidental findings in routine necropsy examinations. Up to 1934, Poston[36] was able to assemble 242 cases of gastrointestinal lipomas; in 1938, Wiener and Polayes[42] increased these to 259 cases. Since then, the number has risen to ap-

proximately 275 cases. The distribution of these cases computed and estimated up to the present, including those which terminated in intussusception, is tabulated as shown in Table II.

TABLE II

INCIDENCE AND DISTRIBUTION OF LIPOMAS AND INTUSSUSCEPTION

Incidence of lipomas	Total number of lipomas		275
	Total in ileum	About 30.0 per cent of total	82
	Total in small intestine	About 56.0 per cent	154
	Total in ileum	About 52.0 per cent of small bowel	80
	Stomach and colon		Remainder
Incidence of intussusception	Total number of lipomas		275
	Total with intussusception	About 36.3 per cent	100
	Total with intussusception in small bowel	16.0 per cent of all lipomas 44.0 per cent of all with intussusception	44

ETIOLOGY AND PATHOGENESIS

Gastrointestinal lipomas are almost evenly divided between the sexes. The majority occurred between the third and the sixth decade, i.e., about 75 per cent are found during the so-called cancer age.

Knowledge concerning the cause of the growth of these fatty tumors is lacking. Fat cells first appear in the tissues of the fetus about the fourth month. Little evidence exists in textbooks on embryology and histology that fat cells or their mesenchymal prototypes, the lipoblasts and their grouped adipose glands, are normally present in the submucosa or subserosa of the bowel at any time during fetal life. Only by routine macroscopic and microscopic examination of every portion of the gastrointestinal tract might one expect to find discrete collections of fat cells or submucous fatty infiltration.

In *Gray's Anatomy* (Ed. 22), the submucous and subserous layers are also referred to as the areolar layers. Areolar tissue consists of connective tissue cells lying in their intercellular matrix. The connective tissue is derived from the mesenchyma of the mesodermal primitive layer. The mesenchyma is made up of a network of branching stellate cells between which is an intercellular fluid secreted by the cells. This later becomes mucoid and is differentiated into connective tissue fibers. As growth continues, these cells and their intercellular matrix either become condensed or diminish in amount. In this way they differentiate into various forms of organized connective tissue such as tendon, cartilage, and bone. This unformed connective tissue shows a variety of cells, a condition of considerable significance in the regenerative and defensive function of this tissue; it has been shown that certain of these cells, the histiocytes, form the greater number of the large phagocytes or macrophages, which combat microorganisms. In addition to the

histiocytes, there are fibroblasts or fixed connective tissue cells, various kinds of wandering cells, and plasma cells formerly called mast cells. Plasma or mast cells occur in varying numbers in most loose connective tissue, being especially numerous along the course of the blood vessels. They are large round or ovoid cells, with a pale-staining nucleus and coarse cytoplasmic granules which stain deeply with basic dyes. Their origin and function are not clear, though some investigators believe them to be connected with the formation of fat. They may be the anlage of fat cells and lipomas in the submucosa and subserosa.

The appearance of the adult fat cell can best be understood by a reference to its histogenesis. As the original embryonal stellate-form cells enlarge, they lose their stellate appearance, become rich in protoplasm, and have the general configuration of secretory cells (steatoblasts). Fine fat droplets are formed in the cytoplasm, which increase in number and finally coalesce forming larger droplets. In doing so the cell takes on a moruloid or "mulberry" appearance, the nucleus is pushed to one side, and the cytoplasm gradually reduced to the thin membrane of the adult cell. Only with the most extreme deposition of fat do all the droplets fuse into one or a few large fat spaces, and often the nucleus retains its central location and does not take the flattened form at the cell periphery characteristic of the ordinary adipose tissue. The origin of the fat droplets is still obscure, although various theories have been proposed. The blood supply is rich and the adult lobule retains its embryonal vascular relations, the vascular supply of each lobule being complete and independent.

Some consider fat as a special tissue arising from specific secretory cells, steatoblasts, while others think it to be derived from a modified type of fibrillar connective tissue in which the cells have lost their fiber-forming capacity and have assumed the function of fat storage.

Fat cells are found isolated or in groups in all loose connective tissue, and when present in large amounts, they are referred to as adipose tissue. It is conceivable that lipomas spring from steatoblasts, which first appear singly or in aggregates, lie dormant until adult life, and then form fat cells which continue to multiply. These become surrounded by an envelope of fibrous connective tissue which develops into the capsule. Together, they constitute the lipoma. There may be an intermediary stage, the lipoblasts, between the steatoblasts and the fat cells. The entire mechanism is still a moot question.

One of the most illuminating and fascinating concepts concerning fat tissue recently appeared by H. Gideon Wells (1940).[57, 58] He states that adipose tissue is not merely a storehouse. It is also a manufacturing plant in active operation, not only producing some or all of its stored materials but probably conducting other processes not as yet revealed.

There is reason to believe that adipose tissue is a specialized tissue and not merely ordinary connective tissue in which fat is deposited

when in excess. Histologic and embryologic evidence has also been presented in support of this idea, in fact, that it is a definite organ. The existence of such specialized tissue for the deposition of fat is especially well seen in certain organs and in certain species, especially the hibernating animals. Hammer (quoted by Wells, 1895) especially developed this conception of two types of fat tissue coming from the same primitive connective tissue elements. In man, the perirenal fat tissue offers the closest resemblance to primitive fat organs or to the fat glands of hibernating animals. It exhibits some of the characters of glandular adipose tissue, the cells being more or less multilocular when not too well filled with fat, although in well-nourished adults they appear like ordinary fat tissue.

Mallory goes so far as to say that the fat cell is a perfectly definite type of cell formed by differentiation from a mesenchymal cell without any relation to a fibroblast.

In other words, the adipose tissue is to be looked upon as part of the reticulo-endothelial system, a conception which suggests more active function for adipose tissue than has been generally recognized. Wells is prepared to accept the view that even while still distended with fat, the fat cells may be carrying on important functions not as yet disclosed, for the mere presence of a load of fat need not seriously impair other activities. Even extreme fatty degeneration and infiltration of parenchymatous cells are not necessarily associated with marked interference with function.

To regulate the functional activity of the fat organs an abundant nerve supply to both the vessels and the parenchyma is present. Section of the nerve supply modifies the behavior of the fat cells in storing and yielding fat. Beznák and Hasch (quoted by Wells, 1937) have shown that it is the sympathetic fibers that control both deposition and mobilization of fat in adipose tissue, and Boeke (quoted by Wells, 1933) had demonstrated sympathetic nerve fibers running to individual fat cells.

During fat resorption from ordinary white fat tissue the large drops do not simply grow smaller but the fat is taken up by the cell cytoplasm and consumed therein. This process may be analogous to the hyperplasia phase in the hyperplasia-involution process which goes on in the thyroid gland, when the acinar cells draw upon the iodine within the acinus, and gradually diminishes the colloid.

Wassermann found that the thin rim of cytoplasm of the distended fat cell can swell up with fluids and suggests that adipose tissue may play a role in water metabolism. This view is supported by the remarkable and deceiving water losses and retentions observed in defatting treatments of the obese, as emphasized by Newburgh (quoted by Wells, 1931).

Stetten (1909)[7] and Kirshbaum (1935)[10] mention briefly that lipomas spring from the connective tissue of the submucosa as the result of meta-

histiocytes, there are fibroblasts or fixed connective tissue cells, various kinds of wandering cells, and plasma cells formerly called mast cells. Plasma or mast cells occur in varying numbers in most loose connective tissue, being especially numerous along the course of the blood vessels. They are large round or ovoid cells, with a pale-staining nucleus and coarse cytoplasmic granules which stain deeply with basic dyes. Their origin and function are not clear, though some investigators believe them to be connected with the formation of fat. They may be the anlage of fat cells and lipomas in the submucosa and subserosa.

The appearance of the adult fat cell can best be understood by a reference to its histogenesis. As the original embryonal stellate-form cells enlarge, they lose their stellate appearance, become rich in protoplasm, and have the general configuration of secretory cells (steatoblasts). Fine fat droplets are formed in the cytoplasm, which increase in number and finally coalesce forming larger droplets. In doing so the cell takes on a moruloid or "mulberry" appearance, the nucleus is pushed to one side, and the cytoplasm gradually reduced to the thin membrane of the adult cell. Only with the most extreme deposition of fat do all the droplets fuse into one or a few large fat spaces, and often the nucleus retains its central location and does not take the flattened form at the cell periphery characteristic of the ordinary adipose tissue. The origin of the fat droplets is still obscure, although various theories have been proposed. The blood supply is rich and the adult lobule retains its embryonal vascular relations, the vascular supply of each lobule being complete and independent.

Some consider fat as a special tissue arising from specific secretory cells, steatoblasts, while others think it to be derived from a modified type of fibrillar connective tissue in which the cells have lost their fiber-forming capacity and have assumed the function of fat storage.

Fat cells are found isolated or in groups in all loose connective tissue, and when present in large amounts, they are referred to as adipose tissue. It is conceivable that lipomas spring from steatoblasts, which first appear singly or in aggregates, lie dormant until adult life, and then form fat cells which continue to multiply. These become surrounded by an envelope of fibrous connective tissue which develops into the capsule. Together, they constitute the lipoma. There may be an intermediary stage, the lipoblasts, between the steatoblasts and the fat cells. The entire mechanism is still a moot question.

One of the most illuminating and fascinating concepts concerning fat tissue recently appeared by H. Gideon Wells (1940).[57, 58] He states that adipose tissue is not merely a storehouse. It is also a manufacturing plant in active operation, not only producing some or all of its stored materials but probably conducting other processes not as yet revealed.

There is reason to believe that adipose tissue is a *specialized tissue* and not merely ordinary connective tissue in which *fat is deposited*

when in excess. Histologic and embryologic evidence has also been presented in support of this idea, in fact, that it is a definite organ. The existence of such specialized tissue for the deposition of fat is especially well seen in certain organs and in certain species, especially the hibernating animals. Hammer (quoted by Wells, 1895) especially developed this conception of two types of fat tissue coming from the same primitive connective tissue elements. In man, the perirenal fat tissue offers the closest resemblance to primitive fat organs or to the fat glands of hibernating animals. It exhibits some of the characters of glandular adipose tissue, the cells being more or less multilocular when not too well filled with fat, although in well-nourished adults they appear like ordinary fat tissue.

Mallory goes so far as to say that the fat cell is a perfectly definite type of cell formed by differentiation from a mesenchymal cell without any relation to a fibroblast.

In other words, the adipose tissue is to be looked upon as part of the reticulo-endothelial system, a conception which suggests more active function for adipose tissue than has been generally recognized. Wells is prepared to accept the view that even while still distended with fat, the fat cells may be carrying on important functions not as yet disclosed, for the mere presence of a load of fat need not seriously impair other activities. Even extreme fatty degeneration and infiltration of parenchymatous cells are not necessarily associated with marked interference with function.

To regulate the functional activity of the fat organs an abundant nerve supply to both the vessels and the parenchyma is present. Section of the nerve supply modifies the behavior of the fat cells in storing and yielding fat. Beznák and Hasch (quoted by Wells, 1937) have shown that it is the sympathetic fibers that control both deposition and mobilization of fat in adipose tissue, and Boeke (quoted by Wells, 1933) had demonstrated sympathetic nerve fibers running to individual fat cells.

During fat resorption from ordinary white fat tissue the large drops do not simply grow smaller but the fat is taken up by the cell cytoplasm and consumed therein. This process may be analogous to the hyperplasia phase in the hyperplasia-involution process which goes on in the thyroid gland, when the acinar cells draw upon the iodine within the acinus, and gradually diminishes the colloid.

Wassermann found that the thin rim of cytoplasm of the distended fat cell can swell up with fluids and suggests that adipose tissue may play a role in water metabolism. This view is supported by the remarkable and deceiving water losses and retentions observed in defatting treatments of the obese, as emphasized by Newburgh (quoted by Wells, 1931).

Stetten (1909)[7] and Kirshbaum (1935)[40] mention briefly that lipomas spring from the connective tissue of the submucosa as the result of meta-

plasia, or from the fat in the subserosa, but do not trace the pathogenesis any further. Raiford (1932)[29] seeks to explain the predominating occurrence of tumors, including lipomas, in the ileum by the stasis-irritation theory. He points out that the terminal ileum is the only part of the small intestine where the fecal stream slows up and accumulates. In doing so it exercises an irritating influence on the bowel which results in tumor formation. Stasis and irritation are likewise present in the stomach and large intestine where invasion by tumors is well known. This includes lipomas which in the stomach occur mainly in the distal half. If this theory in its application to cancer production is accepted, then it must also hold true as a contributory factor in the formation of other tumors in the small bowel, such as lipomas. But the underlying factor in this theory is unknown.

In the embryonic theory of Cohnheim, which has many supporters, may lie the explanation for some cases. This has as its basis, arrested development and misplaced embryonic tissue. It is questionable whether this could apply to the small intestine, which does not develop until the last four months of fetal life, as compared to the remainder of the gastrointestinal tract which develops earlier.

Staemmler regarded lipomas as arising from heteroplastic fatty tissue. This seems like a convenient term to explain the situation without offering any factual evidence. Erlich, on the other hand, considered the growth as a simple hyperplasia of fat cells but does not account for the origin of the fat cells. Mirrolli (1929)[21] proposes a theory which bears repetition. He feels that, following an inflammatory reaction in the wall of the bowel, an exudate is poured out which is rich in leucocytes and fibroblasts. The leucocytes metaplase into fat cells and the fibroblasts form fibrous connective tissue which surrounds the fat cells and forms a capsule, the whole then constituting the lipoma. He cites cases of fibrolipomas formed in inflamed portions of bowel. There is, however, little or no evidence that a leucocyte at any stage in its evolution from its primordial cell or myeloblast, can metaplase into a fat cell. It also does not explain those lipomas which arise within bowel which does not show evidence of previous inflammation. Metaplasia, as the motivating force in the formation of a lipoma, has yet to be definitely proved.

Specimens exhibiting early stages of lipoma formation have shown that the lipoma arises like normal fatty tissue from a preadipose tissue derived from embryonic mesenchymal tissue. Even benign lipomas may contain immature cells, arousing suspicion of a malignant growth, which is explained by the fact that mature fat cells seem to be unable to proliferate, and growth is accomplished by immature cells. Occasionally lipomas do take on a malignant character and then they demonstrate nicely the embryonic origin of fat in relation to the primitive myxomatous connective tissue of the early fetus. Such tumors may reach great size, especially in the retroperitoneal region.

PATHOLOGY

Gross Appearance (Fig. 1).—Lipomas are completely differentiated benign tumors. In the intestinal tract they grow mostly (about 90 per cent) in the submucosa, and to a lesser extent in the subserosa. They occur most frequently as single tumors, but may be found as multiple growths. Both submucous and subserous types may be present in the same patient. Multiple growths are most commonly submucosal. Reports in the literature include the cases of Huss with twelve submucous lipomas of the ileum, Hahn with four submucous lipomas and one subserous lipoma in the ileum, Odelberg (1920)[12] with one submucous and one subserous lipoma in the ileum, Hellstrom (1906) with

Fig. 1 (Case 1).—Ileum opened showing mucosal lining and both lipomas at either end of resected portion of gut.

multiple submucous and subserous lipomas of the ileum, and Saugalli, Bierring, and Bauer who reported multiple lipomas of the colon. In my case there were two submucous lipomas in the ileum. Deroque and Deroque (1924)[17] in their series of 105 cases included seven cases (6.6 per cent) of multiple lipomas. Comfort's (1931)[25] series includes thirteen cases of multiple lipomas and seven cases of combined submucous and subserous types. A very rare subserous lipoma was found in Brechat's (1920)[21] case, where the tumor in the ileum resulted in a volvulus. The majority of lipomas in the subserous layer are found in the large bowel.

They usually originate from the appendices epiploicae where they grow toward the peritoneal cavity and are more or less pedunculated. They give trouble either by direct compression or by traction on their pedicle, but very rarely produce invagination. Ruben, in 1921, collected only fifteen cases.

Size: Submucous lipomas of the small intestine do not attain the size of those in the large bowel because of the smaller lumen of the small intestine. Giving rise to symptoms much earlier because of this fact, they are recognized and treated sooner. The subserous tumors find less resistance offered to their expansion by the serosa than by the rest of the intestinal wall and therefore grow toward the peritoneal cavity. They may attain the size of a child's head before they are recognized clinically. Both types may be present as microscopic collections of fat cells, diffuse lipomatous infiltration, or a discrete tumor. The latter is the most frequently encountered. The other two forms are rarely seen and may be intermediary stages in the growth of these tumors.

Manner of growth: Lipomas, not unlike other benign small bowel tumors, may be either sessile or polypoid. The former are oval or round and of varying thickness. The submucous growths are covered by the mucosa and occasionally the muscularis mucosa, while the subserous variety lie directly under the peritoneum. In each case the covering constitutes a locus minoris resistentiae, with a more unyielding muscular layer opposite, forcing their growth toward the lumen of the intestine or the general peritoneal cavity.

The polypoid types, in some instances, begin as sessile forms and later develop a pedicle. They may, from their inception, grow on a broad base and reach mature size without forming a pedicle. Polypoid tumors comprise a group to which the diagnosis of intestinal polyp is often carelessly given. While benignancy is usually implied, and the majority of such polyps fall into the class of adenomas, almost any histologic type may assume the form of a polyp. One should, therefore, qualify the term polyp by its histologic surname or prefix. They originate as small infoldings of mucosa into which the submucosa, with a cluster of fat cells or a minute lipoma, herniates. Other histologic varieties of polyp follow this manner of development. The passing intestinal contents together with the peristaltic wave exert a constant force, pulling and drawing on the base, until a pedicle is formed. The pedicle may vary in thickness from a tiny thread to a thick cord, and from a short stubby base to many centimeters in length.

Cut Section (Fig. 2).—The substance of the lipoma resembles normal fatty tissue. It is soft and light yellow. It is well circumscribed and frequently covered by a visible fibrous connective tissue capsule from which arise septa of varying thicknesses which divide the tumor into

lobules. Lipomas which contain numerous fibrous connective tissue septa are often termed fibrolipomas. Small blood vessels are seen coursing through them. Damage to these vessels accounts for the bleeding when these tumors cause obstruction. Cystic degeneration, necrosis, ulceration, or sloughing of the lipoma, have been cited.

Microscopic Appearance (Figs. 3 and 4).—Microscopic sections should include the site from which the tumor springs as well as a portion of the intestine on each side. In the submucous variety, it appears at first that the lipoma arises from the mucosa or from the muscular layer. If the mucosa is traced, it will be seen to surround the tumor and that the muscular layer rapidly peters out near the base. The mucosal covering is thin and atrophic and the muscularis mucosa is barely perceptible. The fat cells are divided by fine connective tissue septa into lobules of various sizes and shapes. Where some of the septa join,



Fig. 2 (Case 1).—Same specimen with cut section of lipomas showing smooth glistening yellow-white surface.

small groups of fibroblasts are visible, and in other places round cell infiltration may be present. Fine capillaries and larger vessels are scattered throughout the tumor. The cells are fully developed adult fat cells closely packed together. They have a polyhedral shape because of the pressure of adjacent cells, whereas fat cells which occur singly or in small groups retain their spherical or ovoid form. Only the thin skeleton of the cells is visible. No fat droplets are seen within the cells

because they are dissolved out in the fixing process. Here and there a dark-staining crescentic area is seen at the periphery of a cell. This is the nucleus with a small amount of surrounding cytoplasm which has been pressed against the cell wall by the fat drop within the cell. They are the so-called signet-ring cells. They occur only when the plane of the section passes through the nucleus.

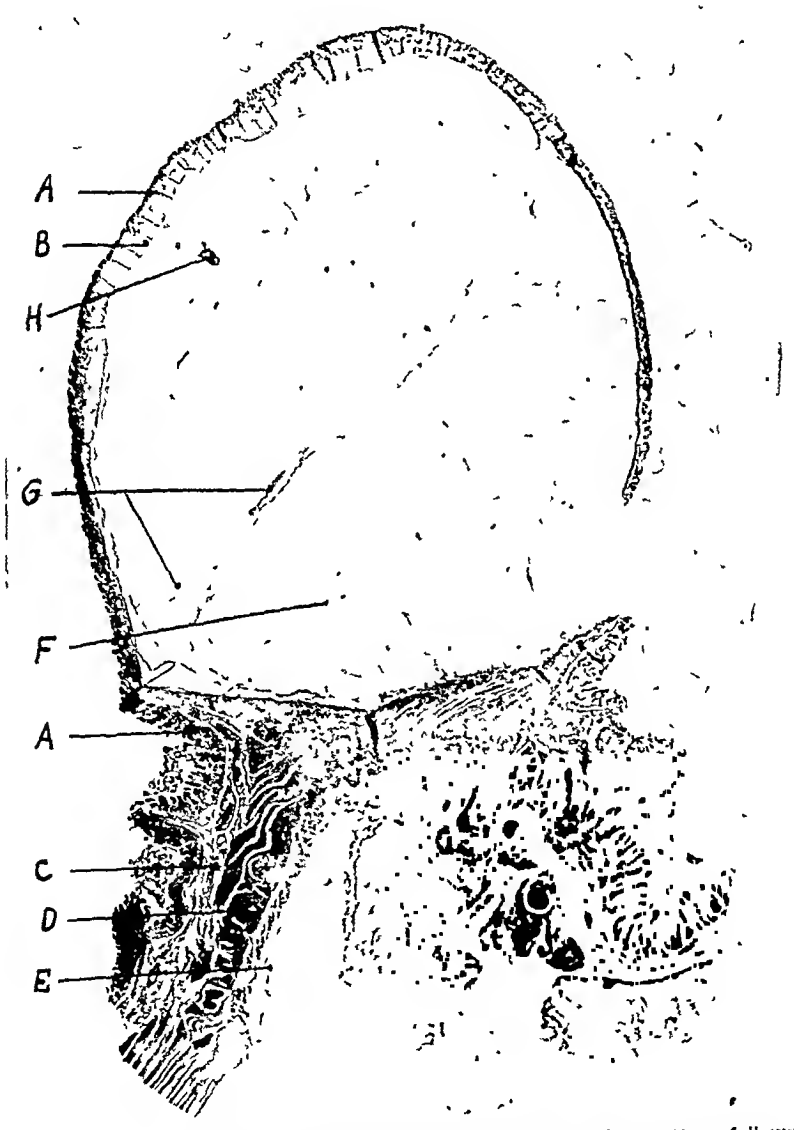

Fig. 3 (Case 1).—Low-power magnification ×[illegible]. Section includes portion of ileum on each side of one lipoma. A, Mucosa: that covering lipoma is thinned out and atrophied. B, muscularis mucosæ. C, submucosa, containing vessels and areolar tissue. D, muscular layer of gut. E, adventitia of gut. F, adipose tissue comprising the lipoma. G, fibrous connective tissue trabeculæ. H, blood vessel.

SYMPTOMATOLOGY

There is no syndrome which is peculiar to lipomas. Other benign tumors of the bowel may produce similar symptom complexes. Symptoms are those of intestinal obstruction produced by the tumor itself or by intussusception. All varieties of intestinal obstruction may be met—acute, subacute, chronic, acute exacerbation of a chronic obstruction, partial or complete, intermittent or progressive. The symptoms may be preceded by months or years of abdominal complaints of a vague or mild nature.

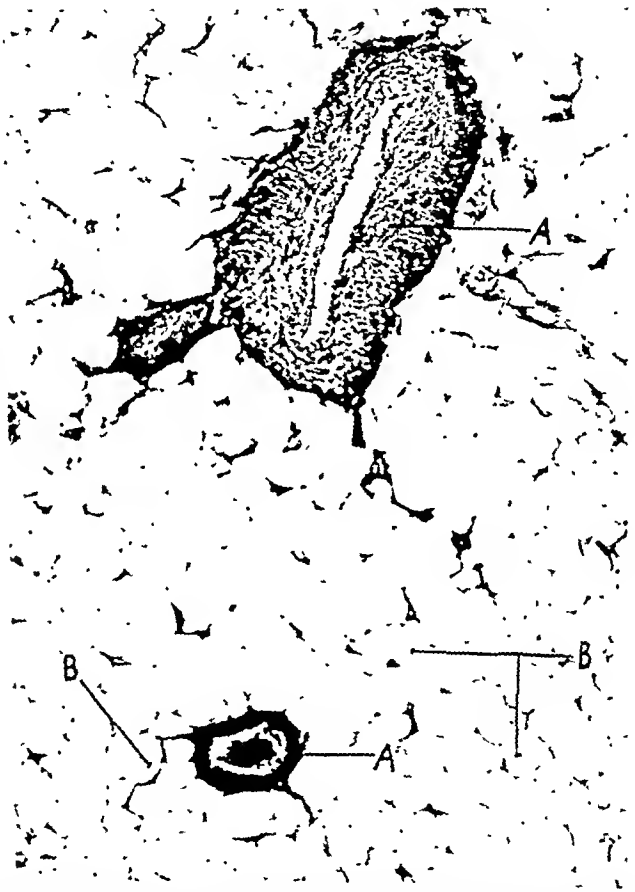

Fig. 4 (Case 1).—High-power magnification. Shows a portion of lipoma. *A*. Blood vessel, the vessel is well developed and shows marked thickening of the intima with the endothelium well preserved. *B*. Fat cells, some of the "signet-ring" type; the fat has been dissolved out in the fixing process leaving only the cell membrane.

The size, location, and behavior of the tumor determine the time of onset of the symptoms. These are probably due to (1) interference with the intrinsic nervous mechanism of the gut wall causing disordered peristaltic activity, (2) obstruction of the lumen, (3) intussusception, (4) ulceration of the lining mucosa or the tumor itself with or without

hemorrhage, and (5) the results of circulatory changes incidental to forceful peristalsis or intussusception, such as edema, congestion, ulceration, hemorrhage into the tumor, necrosis, and gangrene.

The symptomatology may be classified as follows:

1. Latent or silent.
2. Nonobstructive.
   (a) Mild, recurrent.
   (b) Chronic intestinal obstruction. (Chronic intussusception.)
3. Obstructive.
   (a) Gradual enlargement of the lipoma.
   (b) Acute intussusception.

Latent or Silent.—Some lipomas may exist without causing symptoms. They are found incidentally at necropsy or during a laparotomy. They are usually small submucous sessile growths which do not interfere with the passage of the intestinal contents or the normal peristaltic activity of the bowel.

Nonobstructive.—Some lipomas produce symptoms, yet are nonobstructive.

Mild, recurrent: When these tumors grow to the size of a walnut and cause some derangement of bowel action, there is produced a combination of a hindering and an irritating effect on the intestine. This stage may be preceded for months or years by irregular, vague, evanescent complaints of malaise, loss of appetite, and fleeting abdominal pains. These pains may be diffuse, but are frequently localized to the region of the tumor. Tumors located in the terminal ileum or cecum have frequently been diagnosed as appendicitis, whereas duodenal tumors have simulated biliary colic. The pains are probably produced by the tugging of the gut wall by the peristaltic effort to expel the tumor, or by a beginning but unsuccessful invagination. They may cease as suddenly as they began.

Chronic intestinal obstruction: With an increase in the intensity and persistence of the symptoms, a more progressive pathologic state manifests itself. The growths may obstruct either by encroachment on the lumen or by invagination. There may be repeated attacks of intestinal colic, nausea, and frequently vomiting. Constipation, due to the obstruction or to interference with the peristaltic mechanism, may follow and may alternate with periods of diarrhea. Blood, mucus, or pus may be found in the stool as a result of interference with the blood supply of the tumor, pressure, necrosis or ulceration, or trauma of the pedicle by active peristalsis. Chronic or recurrent ileus may become a major factor, producing abdominal distention, considerable discomfort, belching, and hiccups. The case may simulate acute intestinal obstruction and pose a problem for the exercise of surgical judgment. But such cases are uncommon and usually respond to palliative therapy. In thin individuals the tumor may be felt by abdominal palpation.

Attempts at invagination may lead to chronic intussusception which continues for months, with resultant acute obstruction. Morel (1876)[1] reported a case that had been observed for three years with numerous attacks of intestinal colic, until a large lipoma of the small bowel was extruded from the anus. The patient in Goodall's (1912)[8] case had twenty months of repeated colic brought on by chronic invagination of a lipoma of the ileum. Various diagnoses of an organic and functional nature were made before an operation was undertaken; the patient recovered following a resection. In a case of multiple lipomas of the ileum which had caused a long-standing obstruction, Melletti (1933)[33] found a marked dilatation and hypertrophy of the bowel. A similar case had been reported previously by Francini (1909).[6] He explained the absence of intussusception by the fact that the coarctation, resulting from the hypertrophy of a long portion of bowel, prevented invagination from taking place. Such cases of chronic occlusion are more common in the small intestine. That a lipoma of the large bowel may cause chronic obstruction is demonstrated by Mirrolli's (1929)[21] case, in which a submucous lipoma of the descending colon had produced an invagination and finally extruded from the anus.

Cases of spontaneously extruded lipomas are very uncommon. They may originate from either the ileum or colon. Dewis (1906)[59] noted this phenomenon in 20 per cent of his forty-four cases. Mirrolli (1929)[21] lists eleven such cases, of which seven originated from the ileum, including Morel's case, and four from the colon. Comfort (1931)[25] found fourteen cases (7.7 per cent) which were extruded from the anus, most of them having their origin in the colon. In twelve others the lipoma was spontaneously expelled. This is not to be confused with extrusion where the lipoma forming the head of the intussusception appears at the anus, whereas in expulsion the lipoma breaks off, usually from a thin pedicle.

The problem of intestinal occlusion usually plays little part in subserous lipomas. The symptoms which they produce are the result of pressure on contiguous organs. Most abdominal viscera yield readily to pressure around them. This accounts for the large dimensions which a subserous lipoma may attain before it is recognized clinically. When such a tumor abuts against a firm unyielding viscus, for example, the liver, symptoms will occur earlier. Pressure on adjacent loops of bowel may produce partial obstruction.

Obstructive.—Most cases which come under observation fall into this group. The obstruction is of the acute or progressive type and usually requires surgical intervention. Of Stetten's cases, fifty-six (72.7 per cent) were accompanied by symptoms, of which twenty (25.9 per cent) resulted in acute intestinal obstruction. In eighteen (23.2 per cent) of these the obstruction was due to acute intussusception. In Comfort's cases, 114 (62.9 per cent) caused symptoms.

Gradual enlargement: Obstruction will result when the lumen of the bowel is completely encroached upon by the lipoma. This is char-

acteristic of benign tumors and is contrary to the behavior of malignant growths which constrict the bowel. The onset of symptoms is gradual and may be preceded for a long time by indefinite symptoms of "indigestion," malaise, and mild colic. Pain, which is constant, may be diffuse or situated in the lower abdomen. It may be dull, sharp, or cramplike. It usually increases in severity without any remissions. Nausea and vomiting, which appear later, are constant and occur more frequently when the tumor is located higher in the small intestine. Bloating is usually a sign of high intestinal obstruction. Malaise appears very early. Anorexia is soon followed by weight loss. Constipation may be marked and may alternate with diarrhea; obstipation ensues when the obstruction is complete. Cachexia and signs of malnutrition may appear within a few days. Tenderness is most often present over the site of the tumor and is accompanied by spasticity. A large mass or a sense of resistence may be felt if the spasticity is not pronounced and the patient is not obese. The lipomas in twenty-three of Comfort's series were palpable; three of these were in the small intestine. Distention is a late sign. Gross or occult blood may be present in the stool and is usually a sign of ulceration, necrosis of the mucosa overlying the tumor or the tumor itself, or trauma to the pedicle.

Acute intussusception: The term intussusception, meaning "reception within," connotes a deliberate preparation to receive something and is therefore not a true pathogenic description.

The majority of lipomas which cause obstruction terminate in acute intussusception. Reports in the literature overlap and are somewhat confusing. Many reported series of cases are minced and in the earlier literature the data presented are inaccurate. The many incomplete case reports, together with those which never reached the printed archives, render a true account of the incidence of intussusception a difficult task. Raiford's (1932)[29] incidence of intussusception of all tumors situated in the ileum and jejunum was 23 per cent. Staemmler is quoted as stating that 30 per cent had this complication. Some of Stetten's cases were shown by Comfort to be inconclusive and incomplete. Poston (1934)[36] was able to assemble 242 cases of gastrointestinal lipomas reported up to 1934; 80 (33.0 per cent) of these terminated in intussusception, of which 34 were in the small intestine (14.0 per cent of lipomas and 42.5 per cent of those with intussusception). Since then only about 275 gastrointestinal lipomas have been recorded in the literature. Botsford and Newton (1941),[45] accepting Poston's analysis as a basis, add fifteen additional cases of intussusception by gastrointestinal lipomas, collected from the literature since 1934. These, together with the two cases from their clinic and my three cases, would bring the total to about 100 cases with intussusception (Table II). In view of the fact that the incidence in the small intestine is approximately one-half that of the entire gastro-intestinal tract, adding to

Poston's thirty-four cases of intussusception in the small bowel would bring the total to about forty-four cases. In short, of about 275 cases of gastrointestinal lipomas, about 100 (36.3 per cent) terminated in intussusception; 44 were in the small intestine (16.0 per cent of all lipomas and 44.0 per cent of all with intussusception).

Symptoms of Intussusception.—The acute intestinal obstruction which intussusception produces usually requires urgent surgical intervention. The intussusception is progressive and differs from that in children where spontaneous reduction may occur frequently or may be reduced by enemas. Intussusception may be the first indication that a lipoma is present in the intestine. It may be an exacerbation of previous attacks of beginning intussusception or the complete obstructive phase of a chronic intussusception.

Pain, usually the first symptom, is sharp, constant, and severe and may endure for several hours. It is usually defined in the right or left lower quadrant. It is followed shortly by colic as complete obstruction sets in, which increases in severity as the bowel makes frantic efforts to overcome the obstruction. Nausea and vomiting may be early in their appearance or delayed for several hours. With the sudden onset of obstruction, the vomiting is reflex, followed by a free period, only to reappear frequently when obstruction is established. Symptoms of shock are fairly frequent, but occur later as dehydration and hemoconcentration develop. Distention comes on slowly and increases as the obstruction continues. Tenderness is present over the site of the intussusception, usually in both lower quadrants. Rigidity follows if peritonitis develops as the result of vascular obstruction, inflammation of the serosa, or exudation into the peritoneal cavity. A mass or a sense of resistance may be palpated if the abdomen is not too spastic or obese. It is situated near the umbilicus, is round or sausage-shaped and hard in consistency, the hardness increasing during attacks. Tenesmus may follow if the intussusceptum has advanced to the left half of the colon. Blood and mucus will appear in the stool or on the examining finger as a result of the compromise of the circulation and the irritation of the bowel. If the invagination has proceeded to the sigmoid colon or rectum, the intussusceptum may be felt digitally. But in the majority of cases surgery is instituted long before symptoms of peritonitis set in or the head of the intussusception presents itself to the examining finger.

A better grasp of the mechanism of intussusception will be obtained if one understands its pathogenesis based on the physiology and especially the muscular movements of the intestine. These are three in number: peristalsis, which follows the "law of the intestine" formulated by Bayliss and Starling in 1899, segmenting contractions and pendular movements. These in turn are closely related to the neuromuscular mechanism of the intestine with its myenteric plexus of Auerbach and the submucosal plexus of Meissner. These subjects are more

completely described elsewhere.[49, 52] Various explanations have been promulgated to elucidate the phenomenon of intussusception. Best known are those of J. Fraser, Illingworth and Dick, Nothnagel and Morris, and Peyers and Leichtenstern.

DIAGNOSIS

The diagnosis of a lipoma of the intestinal tract is rarely, if ever, made. It can be ascertained only by laparotomy, necropsy, or if the tumor during the stage of intussusception either presents at the anus or is spontaneously expelled. From the symptoms and signs during the nonobstructive stage, without a tumor being felt one may hazard only a guess that partial intestinal obstruction exists. A significant history of intermittent attacks of abdominal pain over a long period of time associated with signs of incomplete intestinal obstruction may arouse suspicion. Even with the onset of acute obstruction one cannot attempt an exact pathologic diagnosis, even if a mass is palpated. In intussusception in adults, too much reliance should not be placed on the finding of blood per rectum because this is found not as frequently as in children. The x-ray following a barium enema has been of some aid in demonstrating the presence of an obstruction, with a cupping defect showing where the intussusceptum projects into the bowel; a diagnosis by this means has been made by Raiford (1932),[29] Knoepp (1935),[35] Bonomini (1939),[45] Good (1941),[46] and Botsford and Newton (1941).[47] The x-ray, of course, is of value in any form of intestinal obstruction, in demonstrating loops of dilated ileum or colon, or a filling defect at the site of the tumor, or the presence of an extrinsic tumor such as a subserous lipoma.

The differential diagnosis at any stage of the symptomatology must always include the "joker" of the abdominal cavity, the appendix (Case 1). When the lipoma is situated in the right colon, it may simulate a renal colic or tumor. When located high in the right upper quadrant either in the colon or small bowel, a peptic ulcer or biliary colic may be the first considered as a likely diagnosis. Other benign or cancerous growths, either of the intestinal tract or in viscera adjacent to the growth, must be thought of. With the onset of obstruction, bowel strangulation, volvulus, or diverticulitis must be ruled out. The latter is known to occur in the cecum, although most often it is found in the left portion of the colon.

PROGNOSIS

The prognosis differs with the type of case. It is good if no obstruction or intussusception has occurred. Both of these conditions greatly increase the mortality rate. The eventual outcome depends on the early diagnosis of a lipoma at any stage of its development and on whether it has gone on to the stage of intussusception. It will also depend upon the institution of early operative intervention, the recognition of multiple tumors, and the type of surgical procedure which is elected.

Percentages for mortality rates vary. In the fifty-six cases of Stetten's series which caused symptoms, he reported 29 per cent deaths. Wiener and Polayes (1938)[42] quoted 40 to 52 per cent mortalities, associating the higher rate with those cases in which the patients were subjected to resection. In Roan's (1932)[28] 100 cases of intussusception which were produced by benign tumors including lipomas, 28 per cent was the average mortality rate. Mirrolli (1929),[21] in his extensive review of cases which had come to resection, mentions 24.4 per cent as the death rate. Of the three patients of my series which presented symptoms, in which resection was done, all recovered.

In general, it may be stated that more deaths will occur in those cases which go on to intussusception, and the longer this complication has existed the higher will be the morbidity and mortality because of the necrosis, gangrene, hemorrhage, and peritonitis which may follow.

TREATMENT

Early surgery will lower considerably the high mortality which exists in this condition. Where a lipoma is known to exist, surgery should be instituted, if possible in the presymptomatic stage. At this time a simple enterotomy with a local excision of the tumor may suffice. One may, however, elect to do a resection. In the absence of an obstructed loop of bowel with its concomitant risks such a procedure can be performed with comparative safety.

In chronic intussusception, an attempt should be made to reduce this first. Failing this, usually because the loops are adherent, a resection of the entire intussuscepted mass should be accomplished, unless the condition of the patient contraindicates such a procedure.

The cases of acute intussusception present the greatest dangers. The results following operation will depend upon the individual case, the surgeon doing the operation, and the type of operation selected. Each case must be individualized as in any other branch of surgery. In patients who can easily withstand a major surgical procedure, one may pursue either of the following courses: (1) A reduction of the intussusception followed by enterotomy and local extirpation of the lipoma, as recommended by Leclerc; (2) a reduction of the intussusception followed by resection of that part of the bowel containing the tumor; (3) where it is impossible to reduce the intussusception it may be found necessary to resect the whole intestine involved in the intussusception with the tumor.

Where a primary resection is done, the type of anastomosis will depend upon the preference of the individual surgeon. Of the three types commonly employed, end-to-end, end-to-side, and side-to-side, I prefer the latter. When in doubt as to the identity of the tumor, benign or malignant, it is usually better to resect.

In any procedure, two points must be kept in mind. First, multiple growths should always be sought for; in the tension of the moment one

may fail to search adjacent as well as distant loops of bowel for additional growths. Second, care should be exercised in suturing intestine that was part of an intussusception because of the edema and inflammation which are present. Injudicious use of suture material may cut through such bowel and result in leakage. If the bowel is too friable a simple exteriorization may be more discretionary and better surgical judgment, to be followed at a later date by a secondary operation.

In bad-risk patients or those too sick to withstand any radical operation, one must resort to less manipulative operations. First, an exteriorization of the entire intussuscepted bowel may be tried, including a generous portion of healthy intestine proximal and distal to the obstruction. Second, a palliative enterostomy should be attempted only as a last resort because of undesirable sequelae such as hypohydration, demineralization, avitaminosis, and skin excoriation, all of which may be difficult to control in spite of the usual measures employed to combat them.

Finally, following the advice of Oughterson and Cheever, whenever any kind of tumor is discovered, no matter how benign its character, especially if it projects into the lumen of the bowel, it should be removed, since it always carries the threat of intussusception.

CASE REPORTS

CASE 1.—*History.*—R. G., a white married female aged 52 years, was admitted to the Jewish Hospital of Brooklyn on July 20, 1939. She complained of abdominal cramps which began five hours prior to her admission. Shortly after the onset the cramps radiated from the region of the umbilicus to the right lower quadrant. Three hypodermic injections of morphine were given during this period without any appreciable relief of the pain. Nausea and vomiting occurred only once at the time of admission. The cramps continued in spite of an enema given when the attack started. The pain and cramps gradually increased in severity up to the moment of operation. There had never been a previous episode of this kind. Her appetite was not at any time affected. Her bowel movements were always regular. She had never noted any blood in her stools nor were they black at any time.

Family History.—Irrelevant.

Past History.—Her menses began at 14 years and recurred regularly every twenty-eight days but were always accompanied by dysmenorrhea. She had had several children who were well. For thirteen years prior to 1934 she suffered from metrorrhagia, a bleeding period occurring every two weeks. In February, 1934, she was admitted to the Memorial Hospital in New York City, where a Hegar colpo perineoplasty, supracervical hysterectomy, bilateral salpingo oophorectomy, and appendectomy were carried out. The diagnosis was myoma uteri and rectocele; this was confirmed by the pathologic examination. Following this operation she underwent an artificial menopause.

Physical Examination.—Examination revealed a moderately obese, middle aged woman, who complained of abdominal pain but did not appear very ill.

Her temperature was 99.8° F.; the pulse was 76 per minute, regular and of good quality. The respirations were 24 per minute, the systolic blood pressure was 170 mm. of mercury, and the diastolic pressure was 100 mm. The pupils were almost pin point from the three injections of morphine but reacted slightly to light. The lungs revealed no pathologic signs. Except for a short systolic blow at the apex, the heart was normal. The abdomen showed a marked adiposity and moved well with the respiratory excursions. There was moderate tenderness in the right lower

quadrant accompanied by spasticity and slight rebound. No masses were palpated. The liver, spleen, and kidneys were not felt. A rectal examination gave no further information.

Urinalysis showed a trace of albumen. The red blood cell count was 5 million and the hemoglobin content 88 per cent (Sahli). The leucocyte count was 11,000 with 74 per cent polymorphonuclear cells (band forms 5 per cent), 18 per cent total lymphocytes, and 8 per cent monocytes.

The diagnosis made by the physician who sent her into the hospital and by the house staff was acute appendicitis. When seen by me, the one fact which seemed impressive was the increasing severity of the cramps in spite of three ¼ gr. doses of morphine. Absolute knowledge that the appendix had been removed at the previous operation was not available at the time. Although the history and the physical examination were very suggestive of an acute appendicitis, a diagnosis of intestinal obstruction of unknown etiology was made.

Operation.—Under N20-02-ether anesthesia the abdomen was entered through a right lower rectus incision. A large elongated mass presented itself. This proved to be an intussusception of the terminal ileum through the ileocecal junction up to the transverse colon. The bowel appeared viable. The intussusception was reduced with some difficulty. The terminal two feet of ileum appeared edematous. No compromise of the circulation was apparent. Two spherical firm tumors about three inches apart were palpated in the ileum about two feet from the ileocecal valve. Both appeared to be about the size of walnuts. The remainder of the abdominal organs showed no gross pathologic changes. A resection of the ileum containing the tumors was done, the ends inverted by a double row of purse-string sutures, the ends further sealed by portions of the mesentery, and a side-to-side anastomosis performed. The abdomen was closed in layers without drainage. The patient withstood the operation well. The skin sutures were removed on the seventh postoperative day and she was dismissed from the hospital on the nineteenth postoperative day. Subsequent follow-up two years later showed her to be in good health and without any complaints.

Pathologic Report (Figs. 1 and 2).—Each tumor was made up of a mixture of fat cells, which comprised the greater part of the tumor, blood vessels, and fibrous connective tissue trabeculae which ramified throughout the tumor dividing it into large and small lobules. The cells for the most part were polygonal in shape, fairly uniform in size, and were represented by clear spaces surrounded by a very thin cobweblike cell membrane. No fat droplets were visible, having been dissolved out in the fixing process. The greater part of the surface of the tumor was covered by a thin layer. For some extent under this mucosal layer there was a portion of the muscularis mucosa. At the base of the tumor the inner round and the outer longitudinal layers of muscle were clearly visible. On either side of the base of the tumor was a portion of normal intestine; the transition between its mucosa and the thinned-out mucosa covering the tumor was very distinct. Under still higher power (Fig. 4) the fat cells and the slight amount of intercellular matrix and some signet-ring cells were clearly discernible. Some blood vessels caught in cross section and on a bias were fairly normal in appearance and well developed. The arteries were thick walled, due chiefly to the thick intima; the endothelial layer was intact.

The diagnosis was multiple submucous lipoma of the ileum.

This case is unique in many respects. It is extremely rare as the reports in the literature show, and it is the only case of its kind in the annals of our own hospital which, in a period of thirty-five years, take in, in round numbers, 250,000 admissions, 150,000 operations, and 4,063 necropsies. As concerns the case itself, there was little toxemia present as a result of the extensive pathology and complete intestinal obstruc-

may fail to search adjacent as well as distant loops of bowel for additional growths. Second, care should be exercised in suturing intestine that was part of an intussusception because of the edema and inflammation which are present. Injudicious use of suture material may cut through such bowel and result in leakage. If the bowel is too friable a simple exteriorization may be more discretionary and better surgical judgment, to be followed at a later date by a secondary operation.

In bad-risk patients or those too sick to withstand any radical operation, one must resort to less manipulative operations. First, an exteriorization of the entire intussuscepted bowel may be tried, including a generous portion of healthy intestine proximal and distal to the obstruction. Second, a palliative enterostomy should be attempted only as a last resort because of undesirable sequelae such as hypohydration, demineralization, avitaminosis, and skin excoriation, all of which may be difficult to control in spite of the usual measures employed to combat them.

Finally, following the advice of Oughterson and Cheever, whenever any kind of tumor is discovered, no matter how benign its character, especially if it projects into the lumen of the bowel, it should be removed, since it always carries the threat of intussusception.

CASE REPORTS

CASE 1.—*History.*—R. G., a white married female aged 52 years, was admitted to the Jewish Hospital of Brooklyn on July 20, 1939. She complained of abdominal cramps which began five hours prior to her admission. Shortly after the onset the cramps radiated from the region of the umbilicus to the right lower quadrant. Three hypodermic injections of morphine were given during this period without any appreciable relief of the pain. Nausea and vomiting occurred only once at the time of admission. The cramps continued in spite of an enema given when the attack started. The pain and cramps gradually increased in severity up to the moment of operation. There had never been a previous episode of this kind. Her appetite was not at any time affected. Her bowel movements were always regular. She had never noted any blood in her stools nor were they black at any time.

Family History.—Irrelevant.

Past History.—Her menses began at 14 years and recurred regularly every twenty eight days but were always accompanied by dysmenorrhea. She had had several children who were well. For thirteen years prior to 1934 she suffered from metrorrhagia, a bleeding period occurring every two weeks. In February, 1934, she was admitted to the Memorial Hospital in New York City, where a Hegar colpo perineoplasty, supracervical hysterectomy, bilateral salpingo oophorectomy, and appendectomy were carried out. The diagnosis was myoma uteri and rectocele; this was confirmed by the pathologic examination. Following this operation she underwent an artificial menopause.

Physical Examination.—Examination revealed a moderately obese, middle aged woman, who complained of abdominal pain but did not appear very ill.

Her temperature was 99.8° F.; the pulse was 76 per minute, regular and of good quality. The respirations were 24 per minute, the systolic blood pressure was 170 mm. of mercury, and the diastolic pressure was 100 mm. The pupils were almost pin point from the three injections of morphine but reacted slightly to light. The lungs revealed no pathologic signs. Except for a short systolic blow at the apex, the heart was normal. The abdomen showed a marked adiposity and moved well with the respiratory excursions. There was moderate tenderness in the right lower

Physical Examination.—Examination revealed a fairly well-developed man who did not appear acutely ill. The temperature, pulse, and respiration were within normal limits. The pupils were equal and reacted to light and accommodation. Examination of the heart and lungs disclosed no pathologic signs. The abdomen was slightly distended but moved with the respiratory excursions. Slight tenderness was present in the right lower quadrant. No masses were palpated and no hernia was present. Operation was decided upon because of the x-ray findings.

Fig. 5 (Case 2).—The sessile character of this lipoma is evident; the transverse mucosal ridges of the mucosa are somewhat smoother in the region of the lipoma. The hemorrhagic necrotic surface of the lipoma is shown.

Operation was performed on July 26, 1938. The abdominal cavity was entered through a right upper rectus incision. There was no fluid in the peritoneal cavity. The liver, gall bladder, stomach, and small intestine appeared normal. An intussusception was present in the transverse colon extending from its mid-portion toward the left for a distance of about seven inches. The intussusception was reduced with little difficulty. An intraluminal mass was found about six inches to the left of the hepatic flexure with a dimpling in the serosa overlying the mass. The mass was felt to be about the size of a plum. The mesentery involved in the intussusception was edematous and the vessels engorged. No glands were felt in the mesocolon. The transverse colon containing the tumor and six inches of bowel on each side was brought up into the wound and a Rankin clamp applied to both limbs, which were then approximated by suturing with black silk. The exteriorized loop was then resected and the wound was closed in layers around the resected loop.

Pathologic Report (Figs. 5 and 6).—The mass in the transverse colon measured 9 by 5 cm. The serosa over it was freely movable. The pedicle of the tumor was 6 cm. long by 5 cm. wide. The surface of the tumor was green and yellow. On cut section the mass appeared to originate from the submucosa; it consisted of

tion. This can be accounted for only by the short time which elapsed between the onset of symptoms and operative intervention. The most interesting feature, which led to a diagnosis of intestinal obstruction rather than acute appendicitis, was the persistence of the cramps in spite of repeated doses of morphine. This bears out the experience of Zierold (1935),[53] Singer (1936),[54] and Eusterman (1938),[55] who for many years have utilized morphine as a diagnostic aid in various acute abdominal conditions. Zierold has presented data purporting to show that generalized spasticity and rigidity is a widespread response to cortical stimulation and takes place when the sensory stimulus from the affected part is excessive and overleaps the bounds of the local spinal reflex which produces localized spasm and which occurs when the stimulus from the affected part is minimal. It is maintained that by administration of morphine in sufficient amount to abolish pain, the extraneous cortical component of the muscular spasm is removed leaving simply that element of rigidity affected solely by the spinal reflex. In this way one can, with a fair degree of accuracy, determine (1) the location of the point of maximum tenderness, (2) the degree of tenderness, (3) the presence or absence of an abdominal mass, and (4) the local reflex spasticity and rigidity produced by the affected organ. The procedure to be employed is to obtain a preliminary history and do a physical examination. These are recorded. Morphine sulfate, gr. ¼, or dilaudid, gr. 1/20, is injected intravenously. Disappearance of pain and relaxation are almost immediate. A more adequate history is now obtained and a more complete and satisfactory physical examination is then done, which the generalized tenderness and rigidity did not permit. Both sets of observations are then correlated.

The administration of morphine to patients with acute abdominal conditions is contrary to the usual teachings on the grounds that it is supposed to "mask" the physical signs. However, these workers, basing their claim on thousands of cases over a period of years, vouch for this procedure. It must always be kept in mind that every case is individual, and that the usual emphasis placed on the history and the clinical picture still holds. In my case the persistence of the cramps was probably due to the increased tone of the intestine with spasm which the morphine produced.

CASE 2.—*History.*—J. A., a white man, aged 48 years, was admitted to the Jewish Hospital of Brooklyn on July 24, 1938. He complained of abdominal pain of three days' duration. For five weeks prior to admission he had complained of recurrent colic. Eight days before admission he was awakened by nausea and vomited several times. He went to the hospital the following day at which time a gastrointestinal x-ray series was taken and a diagnosis of a neoplasm in the transverse colon was made. During this time he was constipated and this alternated with bouts of diarrhea. In the six weeks before he was admitted he had lost about fifteen pounds. For three days the abdominal pains had slowly increased over the right lower and left lower quadrants and were both cramplike and cutting in nature.

The family history and past history were irrelevant.

continued until admission, at which time the vomitus had a fecal odor. There were no bowel movements for five days. During the past year she had noted an increasing moderate constipation and within the past two months had lost twenty pounds although her appetite remained good. There had not been any rectal bleeding, melena, or diarrhea.

On physical examination she appeared acutely and chronically ill and was vomiting. Her heart and lungs showed no pathologic signs. The abdomen was distended and tympanitic. A mass was felt on deep palpation in the right lower quadrant. There was no tenderness or spasm. A diagnosis of intestinal obstruction, due to a neoplasm or intussusception, was made. The patient was given a blood transfusion of 500 c.c. and taken to the operating room.

When operation was performed an intussusception was found, extending from the ileum up to the hepatic flexure of the colon. After the intussusception was reduced a loop of gangrenous ileum 15 cm. in length was found, involving also the mesentery of this portion of the bowel. When, after twenty-five minutes of application of hot packs, the color of the bowel did not return, a resection was done and a side-to side, antiperistaltic, ileotransverse colostomy was done. The abdomen was closed in layers.

The pathologic report showed a gangrene of the ileum with a polypoid tumor about the size of a small plum in the lumen which on microscopic section showed it to be a lipoma with hemorrhagic infarction.

Her postoperative course for the first six days was good, after which she developed a moderate cystopyelitis and slight wound infection. Both of these were treated with sulfathiazole and sulfadiazine and she was discharged from the hospital on her nineteenth postoperative day in good condition but with the wound still somewhat infected.

In the three cases that follow, the lipomas were incidental findings during routine necropsy examinations.

CASE 4.—*History.*—S. F., a 44 year old woman, was admitted to the Jewish Hospital of Brooklyn, on Feb. 26, 1942, because of abdominal cramps. These were first noted about eight months prior to admission, were generalized in character, somewhat more pronounced in the upper abdomen, and associated with occasional bright red blood in the stools. The patient, though constipated, had had bowel movements. After a complete investigation when this illness first started, no organic lesion was found but the abdominal cramps and vomiting persisted and became more marked in the two weeks prior to admission. For the past eight months she had lost about thirty five pounds. The family history and past history were irrelevant. On physical examination the patient's temperature was 100.6° F., her pulse 100 per minute, and respirations 26 per minute. She appeared chronically ill. The extremities were cold; the heart and lungs were negative. The abdomen was slightly distended. A diagnosis was made of chronic intestinal obstruction due to a neoplasm in the hepatic flexure.

Course in the Hospital.—On March 5, 1942, a pinch cecostomy was performed. The cecum and small intestine were distended. On March 12, 1942, her pulse became rapid and feeble and vomiting persisted. The abdomen was soft and distended and there was no abdominal pain. She appeared acutely ill and her lips and nail beds were cyanotic. She expired the following day.

Laboratory Examinations.—On March 4, 1942, her urine showed a trace of albumen and many clumped pus cells. Her hemoglobin was 81 per cent, red blood cell count 4,800,000, leucocyte count 3,900, with 56 per cent polymorphonuclear cells, 36 per cent lymphocytes, and 6 per cent monocytes. Blood chemistry was within normal limits. A barium enema on Feb. 28, 1942, revealed a redundant, slightly dilated sigmoid and transverse colon. An organic obstruction was thought to be

lobules of fatty tissue. Microscopically the section through the pedicle at the base showed a well-preserved mucosa. The lamina propria was infiltrated with small round cells, large mononuclear cells, eosinophiles, and polymorphonuclear cells. In the submucosa and in the connective tissue between the muscle bundles there was infiltration with polymorphonuclear cells, small round cells, and large mononuclear cells. Some of the blood vessels in the serosa appeared engorged. A preparation from the tumor consisted of lobules of adipose tissue covered in places by a network of fibrin in which were enmeshed polymorphonuclear and small round cells. Within the connective tissue septa which formed the lobules and in the walls of the vessels were similar infiltrations of cells.

Fig. 6 (Case 2).—Lipoma of transverse colon. Same as Fig. 5, only lipoma has been cut showing smooth homogenous yellow-white adipose tissue.

The diagnosis was submucous lipoma of the colon with necrosis.

The patient was discharged from the hospital on Aug. 21, 1938, in fairly good condition and with the colostomy functioning. He was instructed to return within two weeks.

He was readmitted to the hospital on Sept. 12, 1938, with the colostomy still functioning. On Sept. 13, 1938, he was again operated upon. The colostomy was closed with a Connell suture. The wound healed by primary union. The patient had normal bowel movements. Upon leaving the hospital an abdominal belt was prescribed. He was discharged on Sept. 23, 1938.

Case 3.—*History.*—G. M., a white woman, aged 57 years, was admitted to the Jewish Hospital of Brooklyn with complaints of abdominal pain and vomiting of five days' duration. Her family history and past history were irrelevant. Five days prior to admission she suddenly developed persistent generalized abdominal cramps of moderate severity. Progressive vomiting set in three days later and

4. An attempt is made to explain the growth of these tumors in the intestinal tract. Various phases of the pathologic picture are described.

5. A working classification is presented of the different clinical manifestations which lipomas of the intestinal tract produce, together with the symptomatology of each type including intussusception.

6. The diagnosis and prognosis of the different aspects of this subject are presented.

7. In the treatment, special consideration has been given to those cases which terminate in intussusception.

I wish to express my gratitude to Dr. Paul W. Aschner, Dr. Louis Berger, and Dr. J. Rabinovitch for permission to use their cases in this review. Appreciation is also extended to Dr. Leo M. Davidoff, Dr. Paul W. Aschner, and Dr. Max Lederer for their helpful suggestions in reviewing this paper.

REFERENCES

1. Morel: Lipoma de l'intestine, Bull. Soc. anat. de Par. 1: 662, 1876.
2. Coupland: A Case of Intussusception of the Ileum Into the Cecum Through the Ileocecal Valve Associated With a Polypoid Tumor, Brit. M. J. 1: 854, 1879.
3. Turner, F. C.: Intussusception of the Small Intestine, Tr. Path. Soc. Lond. 35: 212, 1884.
4. Lewtas, J.: Tumor of the Intestine: Symptoms Simulating Biliary Colic, Brit. M. J. 1: 415, 1888.
5. Chandler, G., and Baldauf, L. K.: Lipoma of the Intestine in a Child 13 Months Old, Causing Symptoms of Intestinal Obstruction, Ann. Surg. 45: 836, 1907.
6. Francini, M.: Lipomi dell 'intestine, Clin. chir. 17: 163, 1909.
7. Stetten, D.: The Submucous Lipoma of the Gastrointestinal Tract, Surg., Gynec. & Obst. 9: 156, 1909.
8. Goodall, H. W.: Chronic Invagination of the Ileum Secondary to Lipoma of the Intestinal Wall, Boston M. & S. J. 167: 548, 1912.
9. Harrigan, A. H.: Submucous Lipoma of the Ileum Causing Ileocolic Intussusception, M. Rec. 89: 1069, 1916.
10. Bland-Sutton, J.: Clinical Lecture on Fibroids, Lipomas, Dermoids, and Polypi of the Stomach and Intestine, Lancet 2: 5, 1920.
11. Brechat, A.: Lipomas of the Intestine, Progrès méd. 35: 539, 1920.
12. Odelberg, A.: Lipomata of the Jejuno-ileum, Acta chir. Scandinav. 53: 154, 1920; abstract: J. A. M. A. 76: 974, 1921.
13. Carlucci, G. A.: Polypoid Lipoma of the Intestinal Tract, Ann. Surg. 74: 230, 1921.
14. Vaccari, C.: Lipoma of the Intestine, Arch. ital. di chir. 6: 589, 1923; abstract: J. A. M. A. 80: 1274, 1923.
15. Thorek, M.: Lipomata of the Jejunum Causing Intussusception, Med. Rev. of Rev. 29: 442, 1923.
16. Swanson, G. C.: Ileocolic Intussusception Due to Fibrolipoma of the Ileum, Glasgow M. J. 102: 326, 1924.
17. Deroque, P., and Deroque, A.: Les Lipomas sous-muqueux de l'intestin., J. de chir. 24: 163, 1924; abstract: J. A. M. A. 83: 1205, 1924.
18. Heinonen, J.: Case of Invagination of the Intestine Induced by a Submucous Lipoma, Finska läk.-sällsk. handl. 68: 23, 1926; abstract: J. A. M. A. 18: 1258, 1926.
19. Polak, E.: Submucous Lipoma, Acta chir. Scandinav. 63: 65, 1928.
20. Morrison, W. A.: Case of Double Intussusception From a Tumor of the Terminal Ileum, S. Clin. North America 8: 1473, 1928.
21. Mirrolli, A.: Contribution to the Study of Submucous and Subserous Lipomata of the Intestine, Arch. ital. di chir. 24: 553, 1929.
22. Horsley, J. S.: Intussusception Due to Intestinal Lipoma in an Adult Followed by Gangrene of the Abdominal Wall, Arch. Surg. 18: 882, 1929.
23. Forni, G.: Chronic Remittent Intussusception of the Jejunum From an Intraparietal Lipoma, Ann. ital. di chir. 9: 556, 1930.
24. Wakeley, P. G., and Paul, M. A.: Tumors of the Small Intestine, Australian & New Zealand J. Surg. 1: 227, 1931.

present near the hepatic flexure. Three negative shadows in the right hypochondrium were suspicious of gall stones.

Autopsy Findings.—There was an adenocarcinoma in the ascending colon with obstruction; ulcers in the ascending colon; a scirrhus carcinoma in the esophagus with metastasis to the regional lymph nodes; and a focal pneumonia. There were polyps in the colon and rectum and a submucous lipoma in the transverse colon.

In this case the lipoma of the transverse colon was, of course, of secondary importance in view of the multiple carcinomas which were present. An interesting feature which might be mentioned is that this patient apparently showed a general tendency towards multiple tumor growths, both benign and malignant.

CASE 5.—*History.*—J. S., a white woman aged 51 years, was admitted to the Jewish Hospital of Brooklyn on Aug. 27, 1935. Eight years previously she had been at Mt. Sinai Hospital in New York where she had a stricture of the rectum and a stenosis of the vagina, both on a syphilitic basis. Her blood Wassermann was 4 plus but the spinal fluid was negative for syphilis. On admission to the Jewish Hospital she complained of rectal discharge for two years accompanied by vomiting. She had the appearance of being ill for a long time. An indefinite mass was felt in the lower part of the abdomen. A sigmoidoscopic examination revealed a rectal stricture and polyposis with possible malignant degeneration. At operation there was found a large ovarian cyst with chronic salpingitis and tubo-ovarian disease all matted together in a large mass and attached to the large bowel. Her condition became rapidly worse and she died two days after the operation. The necropsy disclosed chronic and acute colitis with stricture, diverticulitis with perforation, acute peritonitis, a polyp of the colon, and multiple submucous lipomas of the cecum and ascending colon.

CASE 6.—*History.*—K. C., a white woman aged 55 years, was admitted to the Jewish Hospital of Brooklyn on Nov. 15, 1936. For twenty-five years she had bilateral inguinal hernias. Four hours before admission, following a severe coughing spell, the right hernia protruded, became very painful, and could not be replaced. Her pains and cramps increased and after taking a laxative these symptoms increased. She was brought into the hospital where it was found she had a strangulated hernia. At operation the diagnosis was substantiated and after the release of the hernial ring the bowel appeared to assume its normal color but the appendix which was part of the hernia was markedly congested and was removed. A hernial repair was done. The pathologic report showed an involution of the appendix with hemorrhage and a hernial sac. The patient bled from the rectum on several occasions. She also had repeated asthmatic attacks. She finally developed a thrombophlebitis and died on Nov. 29, 1936, two weeks after the operation. The necropsy disclosed a bilateral focal pneumonia, ulcerative enterocolitis, a passive congestion of the viscera, a polyp of the ascending colon, diverticula of the transverse and descending colon, and a lipoma of the ascending colon.

SUMMARY

1. Six cases of intestinal lipoma are presented, from the records of the Jewish Hospital, three of them surgical, including my own case, and the other three where the lipomas were incidental autopsy findings. The three operative patients recovered without unusual incidence.
2. A brief review of the literature on small intestinal lipomas is given.
3. The incidence of intestinal lipomas is presented with emphasis on the subject of intussusception which they produce.

4. An attempt is made to explain the growth of these tumors in the intestinal tract. Various phases of the pathologic picture are described.

5. A working classification is presented of the different clinical manifestations which lipomas of the intestinal tract produce, together with the symptomatology of each type including intussusception.

6. The diagnosis and prognosis of the different aspects of this subject are presented.

7. In the treatment, special consideration has been given to those cases which terminate in intussusception.

I wish to express my gratitude to Dr. Paul W. Aschner, Dr. Louis Berger, and Dr. J. Rabinovitch for permission to use their cases in this review. Appreciation is also extended to Dr. Leo M. Davidoff, Dr. Paul W. Aschner, and Dr. Max Lederer for their helpful suggestions in reviewing this paper.

REFERENCES

1. Morel: Lipoma de l'intestine, Bull. Soc. anat. de Par. 1: 662, 1876.
2. Coupland: A Case of Intussusception of the Ileum Into the Cecum Through the Ileocecal Valve Associated With a Polypoid Tumor, Brit. M. J. 1: 854, 1879.
3. Turner, F. C.: Intussusception of the Small Intestine, Tr. Path. Soc. Lond. 35: 212, 1884.
4. Lewtas, J.: Tumor of the Intestine: Symptoms Simulating Biliary Colic, Brit. M. J. 1: 415, 1888.
5. Chandler, G., and Baldauf, L. K.: Lipoma of the Intestine in a Child 13 Months Old, Causing Symptoms of Intestinal Obstruction, Ann. Surg. 45: 836, 1907.
6. Francini, M.: Lipomi dell 'intestine, Clin. chir. 17: 163, 1909.
7. Stetten, D.: The Submucous Lipoma of the Gastrointestinal Tract, Surg., Gynec. & Obst. 9: 156, 1909.
8. Goodall, H. W.: Chronic Invagination of the Ileum Secondary to Lipoma of the Intestinal Wall, Boston M. & S. J. 167: 548, 1912.
9. Harrigan, A. H.: Submucous Lipoma of the Ileum Causing Ileocolic Intussusception, M. Rec. 89: 1069, 1916.
10. Bland-Sutton, J.: Clinical Lecture on Fibroids, Lipomas, Dermoids, and Polypi of the Stomach and Intestine, Lancet 2: 5, 1920.
11. Brechat, A.: Lipomas of the Intestine, Progrès méd. 35: 539, 1920.
12. Odelberg, A.: Lipomata of the Jejuno-ileum, Acta chir. Scandinav. 53: 154, 1920; abstract: J. A. M. A. 76: 974, 1921.
13. Carlucci, G. A.: Polypoid Lipoma of the Intestinal Tract, Ann. Surg. 74: 230, 1921.
14. Vaccari, C.: Lipoma of the Intestine, Arch. ital. di chir. 6: 589, 1923; abstract: J. A. M. A. 80: 1274, 1923.
15. Thorek, M.: Lipomata of the Jejunum Causing Intussusception, Med. Rev. of Rev. 29: 442, 1923.
16. Swanson, G. C.: Ileocolic Intussusception Due to Fibrolipoma of the Ileum, Glasgow M. J. 102: 326, 1924.
17. Deroque, P., and Deroque, A.: Les Lipomas sous-muqueux de l'intestin., J. de chir. 24: 163, 1924; abstract: J. A. M. A. 83: 1205, 1924.
18. Heinonen, J.: Case of Invagination of the Intestine Induced by a Submucous Lipoma, Finska läk.-sällsk. handl. 68: 23, 1926; abstract: J. A. M. A. 18: 1258, 1926.
19. Polak, E.: Submucous Lipoma, Acta chir. Scandinav. 63: 65, 1928.
20. Morrison, W. A.: Case of Double Intussusception From a Tumor of the Terminal Ileum, S. Clin. North America 8: 1473, 1928.
21. Mirrolli, A.: Contribution to the Study of Submucous and Subserous Lipomata of the Intestine, Arch. ital. di chir. 24: 553, 1929.
22. Horsley, J. S.: Intussusception Due to Intestinal Lipoma in an Adult Followed by Gangrene of the Abdominal Wall, Arch. Surg. 18: 882, 1929.
23. Forni, G.: Chronic Remittent Intussusception of the Jejunum From an Intraparietal Lipoma, Ann. ital. di chir. 9: 556, 1930.
24. Wakeley, P. G., and Paul, M. A.: Tumors of the Small Intestine, Australian & New Zealand J. Surg. 1: 227, 1931.

25. Comfort, M. W.: Submucous Lipomata of the Gastrointestinal Tract, Surg. Gynec. & Obst. 52: 101, 1931.
26. McCloskey, B. J.: Lipoma of the Small Intestine (Ileum) With Superimposed Ulceration, Pennsylvania M. J. 34: 713, 1931.
27. Esser, A.: Multiple Lipomas of the Small Intestine, Centralbl. f. allg. Path. u. path. Anat. 55: 6, 1932.
28. Roun, O.: Intussusception Due to Benign Tumors of the Small Intestine, Texas State J. Med. 27: 872, 1932.
29. Raiford, T. S.: Tumors of the Small Intestine, Arch. Surg. 25: 321, 1932.
30. Rankin, F., Bargen, J. A., and Buie, L.: The Colon, Rectum, and Anus, Philadelphia, 1932, W. B. Saunders Company, p. 396; quote Dewis, 1906.
31. Bargen, J. A.: Lipoma of the Small Intestine, Proc. Staff Meet., Mayo Clin. 7: 689, 1932.
32. Koster, H.: Intussusception, Am. J. Surg. 22: 465, 1933.
33. Melletti, M.: Lipomatosi con enorme dilatezione et ipertrofia dell'ileo terminale, Policlinico (sez. prat.) 40: 1285, 1933.
34. Rankin, F. W., and Newell, C. E.: Benign Tumors of the Small Intestine, Surg. Gynec. & Obst. 57: 501, 1933.
35. Knoepp, L. F.: Submucous Lipoma of the Ileum With Intussusception, Proc. Staff Meet., Mayo Clin. 8: 765, 1935.
36. Poston, R. I.: Acute Enteric Intussusception in an Adult Caused by a Lipoma, Brit. J. Surg. 22: 108, 1934.
37. Moore, R. M., and Schmeisser, H. C.: Benign Tumors of the Small Intestine, South. M. J. 27: 386, 1934.
38. Joyce, T. M.: Tumors of the Small Intestine, Ann. Surg. 100: 949, 1934.
39. Lytle, C., and Fritz, L. H.: Polyp of the Ileum With a Double Intussusception, J. Iowa M. Soc. 25: 207, 1935.
40. Kirshbaum, J. D.: Submucous Lipomas of the Intestinal Tract as a Cause of Intestinal Obstruction, Ann. Surg. 101: 734, 1935.
41. Wilmoth, C. L.: Intraluminal Lipoma of the Small Intestine Producing Intussusception, Am. J. Surg. 31: 567, 1936.
42. Wiener, M. F., and Polayes, S. H.: Benign Tumors of the Ileocecal Region, Am. J. Surg. 40: 538, 1938.
43. Monfort, J. J.: Intussusception: A Case Report, J. Arkansas M. Soc. 34: 271, 1938.
44. Clagett, O. T.: Lipoma of the Cecum, Proc. Staff Meet., Mayo Clin. 14: 505, 1939.
45. Bonomini, B.: Ileocolic Invagination Due to Submucosal Lipoma of the Ileum, Radiol. med. 26: 1036, 1939.
46. Good, C. A.: Chronic Intussusception of the Small Intestine: Three Cases in Which Diagnosis Was Established by Roentenologic Methods, Proc. Staff Meet., Mayo Clin. 16: 324, 1941.
47. Botsford, T. W., and Newton, F. C.: Intussusception in an Adult Due to Submucous Lipoma of the Ileum, SURGERY 10: 265, 1941.
48. Gray's Anatomy: Ed. 22. London, 1935, Longmans, Green & Co.
49. Callander, C. L.: Surgical Anatomy, Ed. 2, Philadephia, 1939, W. B. Saunders Company.
50. Arey, L. B.: Developmental Anatomy, Ed. 3, Philadelphia, 1935, W. B. Saunders Company.
51. Bailey's Textbook of Histology: Ed. 9, Baltimore, Md., 1939, Williams & Wilkins Company.
52. Best, C. H., and Taylor, N. B.: The Physiological Basis of Medical Practice, Ed. 2, Baltimore, Md., 1939, Williams & Wilkins Company, pp. 804-817.
53. Zierold, A. A.: Morphine as a Diagnostic Agent, Proc. Staff Meet., Mayo Clin. 10: 297, 1935.
54. Singer, H. A.: Morphine as an Aid in Diagnosing Acute Abdominal Affections, Am. J. Surg. 34: 5, 1936.
55. Eusterman, G. B.: Common Gastro-intestinal Emergencies, Ann. Int. Med. 12: 307, 1938.
56. Editorial: Morphine as a Diagnostic Agent, SURGERY 7: 617, 1940.
57. Wells, H. Gideon: Adipose Tissue, a Neglected Subject, J. A. M. A. 114: 2177, 1940.
58. Wells, H. Gideon: Adipose Tissue, a Neglected Subject, J. A. M. A. 114: 2284, 1940.
59. Dewis, J. W.: A Small Fibroma of the Ileum Resulting in Obstructions of the Bowel, With a Consideration of Various Forms of Benign Intestinal Tumors, Boston M. & S. J. 155: 427, 1906.

RECTAL STRICTURE DUE TO LYMPHOGRANULOMA VENEREUM

Treatment With a Sulfonamide and Frei Antigen

Howard Robert Seidenstein, M.A., M.D., New Rochelle, N. Y.
(From the New Rochelle Hospital)

THIS communication deals with patients treated for advance stricture of the rectum due to lymphogranuloma venereum. Because of the small number of cases few hard and fast generalities can be laid down in this work, but many instructive points can be emphasized.

Although a voluminous literature has appeared on lymphogranuloma venereum for over a decade, only recently did Kornblith[1] bring out the fact that about one-third of all cases of the disease heal spontaneously but that no cases of rectal stricture ever heal spontaneously without scar. Lichtenstein[2] also noted this latter point, and it is this fact which adds worth to reports based on five cases.

Recently numerous investigators have reported upon the efficacy of sulfonamides in this disease. Almost all have reported good results but it is significant that no follow-ups have appeared. It is also important to note that improvement has been symtomatic with most strictures reported as remaining. Mentzer and Allen[3] remark that "recurrence of purulent rectal discharge and rectal ulceration usually follows discontinuance of the drug after varying intervals of time." Herb and co-workers[4] have reported most of the cases of complete disappearance of strictures, but from the time of their reports it is obvious that a considerable period for follow-up could not have been allowed. Marino and associates[5] reported that the scar became more elastic, the inflammation disappeared, the raw areas healed, and the general health was better. They also stressed strict hospitalization for the control of treatment. Kennedy and co-workers[6] noted symtomatic benefit but no change in the rectal strictures. Grace,[7] in an excellent paper, showed that prolonged treatment was necessary to effect "cure" in less than 40 per cent of the cases. He concluded that there was no relation between blood concentration and the ultimate therapeutic effect of these drugs and "that the marked beneficial effect . . . . springs from the virostatic effect of these chemicals upon the etiological agent of this disease." Stein[8] reported a reversal of the Frei test with sulfanilamide treatment for buboes due to lymphogranuloma venereum as well as cure of the condition. Carmel,[9] on the other hand, concluded that sulfanilamide was not impressive, but that Frei antigen was of value.

Received for publication, Aug. 17, 1942.

Kornblith[10] has reported good results with Frei antigen alone but now feels[11] that a combination of Frei antigen and sulfonamides offers the best opportunity for cure, a viewpoint shared by Costello and Cohen,[12] whereas Yeomans[13] urges the profession to use sulfonamides as do Palmer and associates.[14] Martz and Foote[15] recently used Frei antigen and diathermy combined with excellent results. It is apparent, therefore, that there is little unanimity of opinion as to the treatment of this disease even at the present time. Few men have combined the best characteristics of those methods reported as giving good results in the past, although Mathewson[16] had reported earlier that the most effective treatment was Frei antigen plus treatment to combat secondary infection.

METHOD

When the first patient of this series was seen, reports of the efficacy of sulfanilamide were beginning to be published by Shropshear.[17] Sulfanilamide was started accordingly but there was a rapid fall in hemoglobin and its use was discontinued. Since neoprontosil* was thought to be "less toxic" to the hemopoietic system, that drug was substituted, and at the patient's demand for local treatment, retention enemas of the drug were substituted for oral administration. It was assumed that in this way a possible local action would be added to the general effect. It might be noted, too, that while instillations through a catheter were ordered by the doctor, the patient improved upon the method by using a 4 ounce rubber-bulb syringe; three 5 gr. tablets in one-half glass of tap water (approximately a 1 per cent solution) were used t.i.d. Later four tablets in 4 ounces of water were administered b.i.d. It was found that this regimen could be continued almost indefinitely in four of the five patients, and that while ferrous sulfate in 1 Gm. doses daily accompanied this medication, there was actually a rise in hemoglobin in spite of long-continued sulfonamide therapy. It should be stressed that the patients were ambulatory, being seen at the office, except when they were hospitalized for study at the start of treatment.

All of these cases occurred in young adult negro women; all five of these cases had advanced strictures confined to the lower 8 cm. of the rectum (stressing again the necessity of routine digital examinations); all five patients complained of "corruption" coming from the rectum (indicating serosanguineous and sanguopurulent discharge); all had some dysfunction of bowel movement ranging from constipation in one, through pencil-like stools, to alternating constipation and diarrhea. *None* of these patients had *complete* obstruction, although in one case the rectal opening was the diameter of the lead in an ordinary pencil and practically all of her fluid stools were passed via a rectovaginal fistula. All of these patients had been advised to have colostomies, and

*A supply courteously furnished by The Winthrop Chemical Co.

a consulting dermatologist predicted the need for colostomy in spite of of all treatment, although it was at his suggestion that intravenous Frei antigen* (mouse-brain type in increasing doses) was begun in the first case. Three of the five had at least one other proved venereal disease, a point also stressed by Kornblith.

In following these cases it was noted that the first had by far the best results and since she was the only patient who had, up to that time, received Frei antigen, it was deemed advisable to give that treatment to the other four. Accordingly, they received eight intravenous injections over a period of four weeks and one of these patients received a second course several months later. In the final evaluation it would seem that about 50 per cent of the improvement can be attributed to this source and about 50 per cent to the sulfonamide. Incidentally, Costello and Cohen[12] have suggested that the rise of temperature following the administration of Frei antigen intravenously might be used as a confirmatory test for this disease. Kornblith[1] had previously shown several types of temperature reactions, and in this series these aberations and absences of the expected reaction were also present, thus making it, in my opinion, an extremely poor test of the presence of lymphogranuloma venereum. It might be noted in passing that the newer sulfonamides were not used in the latter cases because it was deemed advisable to see just how a single member of the group worked in several comparable cases especially in view of the more than satisfactory result in the first case.

RESULTS

The results of treatment in five similarly treated cases in this series range from good to poor, although every patient improved to some degree. One patient had a complete cure subjectively and objectively for twenty-one months, and then suffered a recurrence of proctitis in a former area of inflammation although the "cured" stricture previously present in another area did not return; a second was symptomatically cured with objective improvement so marked that an excellent surgeon has undertaken to attempt surgical cure of her recto-vaginal fistula; and the three others at least have had no progression of their disease for over a year, are symtomatically cured, and objectively somewhat improved. Because of the recurrence in the case with the best results, no claim for even permanent arrest is tenable. All of these patients, in spite of persistent treatment, retain their positive Frei test, as reported by Kornblith,[18] and at least two of the three tested retain high blood globulin values.

DISCUSSION

I am unable to explain how a fibrous stricture, present for a long period of time, "melted" and finally disappeared under this form of

*Kindly supplied by Lederle Laboratories, Inc.

combined therapy. From a pathologic viewpoint it would appear that the scar would remain even if extermination of the virus could be accomplished. In this case complete extermination of the virus was not possible but the scarring disappeared. In a much less chronic case involving the pharynx, Myerson[19] was able to report complete healing of the mucosa by the use of Frei antigen alone, and sporadically others have reported "cures" which evidently are meant to represent complete cures without resultant scars.

When a case of rectal stricture due to lymphogranuloma venereum has been cured for twenty-one months and then recurrence of a proctitis occurs in an area previously showing only a transient inflammation, it is well to beware of optimistic prognosis. Although one of these patients had developed an almost complete stricture in fourteen months, and Grace[7] reported slight narrowing of the rectum in less than three months, it is well to remember that Lazzari[20] and Vandermeer and co-workers[21] showed that it took many years for the formation of strictures, and it may be that long-time follow-up of some of the reported cases will show recurrence of proctitis, followed by new stricture formation. Palmer and associates[14] have shown the presence of the virus after prolonged periods, blasting Vandermeer's[21] premise that it is doubtful whether the virus is active in the old strictures. Kornblith,[11] too, found an abdominal gland showing evidence of the active disease, thirteen years after the formation of a fibrous stricture. It is probable that the virus remains present and active in the lymphatics and that its spread is via this channel. In the first case reported here, the recurrence was at a level where the middle group of lymphatics gathers along the rectum. If, as seems probable, the virus can reinfect a previously "cured" patient, it seems that the lasting immunity mentioned by Prehn[22] is a myth. There is also a problem which arises from the public health aspect, since it appears that the discharges from these people are potentially infective over long periods of time.

D'Aunoy and von Hamm,[23] in their excellent review, stated that "pyogens invading such ulcerated areas play havoc in the altered tissue strictures and establish foci of infection ultimately responsible for the fast downhill course of the patients affected with these lesions." From my small series I am inclined to agree with them and I feel certain that the sulfonamide used here exerted its main influence upon the secondary invaders, leaving the body defenses better fitted for the task of combating the primary infection due to the virus. In this connection it must be emphasized again that Kornblith[1] found that in approximately one-third of the cases of lymphogranuloma venereum exclusive of rectal strictures, the body can do an adequate job without the aid of the physician. Whatever the explanation, I agree with Palmer and associates:[14] "regardless of the mechanism of action, however, the therapeutic value of *sulfanilamide* and its derivatives seems definitely established." I suggest that perhaps better results might be brought

about through its combination with Frei antigen treatment, since even the two combined, while infinitely better than any previous treatment, leave much to be desired When compared to the alternative, a permanent colostomy, I feel that the treatment outlined here is infinitely more desirable.

CONCLUSIONS

1. The anorectal manifestations of lymphogranuloma venereum seem to be best treated by prolonged local and general sulfonamide therapy combined with at least one course of Frei antigen intravenously. The first half can be accomplished by retention enemas of azosulfanilamide.

2 A rise in temperature following the injection of mouse-brain Frei antigen intravenously is not a reliable test of the presence of lymphogranuloma venereum.

3 The Frei test does not seem to be reversed after this treatment, in spite of clinical improvement and arrest of the pathologic process.

4 Serum globulins appear to be increased in this disease

5 No explanation is offered for the complete disappearance of a stricture under the regimen described here.

6 In spite of complete local arrest there is evidence of continued action of the virus This conclusion may be of interest from a public health standpoint.

CASE 1.—B M, a light Negro woman, aged 24 years, was seen in the out patient department on Oct. 5, 1939, complaining of constipation. Digital examination showed an almost complete obstruction of the rectum and proctoscopic examination showed the presence of a stricture and "catarrhal proctitis." Frei test was "weakly" positive (four times the control, however, and lasted for many weeks) It was repeated with the same result. She was admitted to the hospital on Nov 1, 1939, with the following history. For eight to nine months she had had increasing difficulty in the passage of stools These had been ribbon like and were passed only with considerable strain. After a cathartic she easily passed liquid stools For some months previously she had had bleeding and discharge ("corruption") from the rectum, at times without relation to bowel movements She had no tenesmus and little pain Four years previously she had had bilateral swelling of the inguinal glands but these had regressed without treatment Two years previously an M D had told her that both ovaries were infected when she had had a vaginal discharge She had never had any lesions about the vulva or rectum and denied any perverted sex practices

Physical examination revealed an undernourished, chronically ill woman, 5 feet four inches tall, weighing 100 pounds Rectal examination revealed a completely annular stricture 4 cm above the anus, about one half inch long, scarcely admitting the tip of the forefinger (about 1 cm in diameter). Anoscopic examination, on Nov 6, 1939, showed this to be whitish in color, fibrous at its base, and granulomatous toward the lumen There were some granulations down to the anus and a few skin tags On Nov 7, 1939, sulfanilamide, 15 gr daily, was started but was stopped three days later because of a drop of 1,000 000 in the R B C

On Nov 17, 1939, under gas oxygen anesthesia the stricture was dilated with graduated metal dilators and a mechanical hand dilator, the stricture was broken up completely and a rectal tube was inserted At this time a biopsy was taken which was reported as chronic inflammatory tissue suggestive of lymphogranuloma

venereum. On Nov. 19, 1939, the rectal tube was removed and a note stated that the site was satisfactory. On Nov. 20, 1939, five units* of Frei antigen were given intravenously and the patient experienced headache and fever. On Nov. 22, 1939, another injection of ten units, and on Nov. 26, still another of twenty units was given. After this injection the fever reached 104° F. in a few hours By Nov. 29, 1939, the stricture was returning but the tissue was a little more elastic. A final note on the chart was that the stricture had returned rapidly in spite of treatment. Laboratory data while in the hospital showed a definitely positive Frei test, negative Wassermann, and a total protein of 8 4 with albumin 5.3, and globulin 3.1 per cent. The rest of the data was not significant, except for a hemoglobin of 70 per cent on discharge. Her weight was 98 pounds. On Nov. 30, she was started on sulfanilamide again, 90 gr. daily, and she had thirty units of Frei antigen intravenously. On Dec. 5, 1939, she had forty units, on Dec. 9, fifty units, and on Dec. 12, sixty units. By Dec. 9, hemoglobin was 49 per cent and the sulfanilamide was discontinued. On Dec. 5, there was a stricture band on the left but the lumen of the rectum was wide. On Dec. 12, there was still some discharge and the stricture had reformed except for one small area. Under vigorous rectal massage the recurring stricture was broken up. Ferrous sulfate was then started in 25 gr. dosage daily. By Dec. 30, the patient weighed 105 pounds, the hemoglobin was 78 per cent, and through repeated normal dilatations, although there was some narrowing of the rectum, there was not a complete stricture but merely many tags of fibrous tissue. On Jan 17, 1940, by which time there was again a renewal of the stricture, neoprontosil, 45 gr. daily, by means of three retention enemas, was started. On Jan. 28, 1940, the weight was 111½ pounds and on Jan 31, 1940, the rectum seemed distinctly better than when not dilated for twelve days at any previous time. On Feb. 9, 1940, she passed some bloody mucus for the last time. By Feb 24, her hemoglobin was 85 per cent and she stated that she felt better than she had for a year. Her bowels were normal, her appetite was good, and she weighed 114 pounds. At this time proctoscopy revealed an area of proctitis about 10 cm above the anus which had not been present twenty days previously. On March 20, she weighed 116 pounds and was completely well except for some clear mucus at stool. By this time she had had about 162 Gm. of neoprontosil and the drug was stopped since the rectum appeared to be almost completely healed. On April 6, 1940, the neoprontosil was again resumed because it appeared that there was some slight narrowing of the lumen although no proctitis could be observed By May 4, 1940, she had had 84 Gm. additional of the drug and it was discontinued On July 20, 1940, she weighed 120 pounds and the rectum felt as it had on previous examination Proctoscopically the mucosa was completely healed, was not contracted, was soft, and a tiny ridge, which had been felt with the finger, was unable to be seen. On Sept 7, 1940, she had a normal rectum except for a "sentinel pile." On Nov. 11, 1940, and on Jan 14, 1941, the rectum appeared normal upon examination and her weight was 125 pounds Her Frei test was still positive in Nov. 1941, and at this time total proteins were 8 5 per cent with a globulin 4 5 and albumin 4 0

On Jan. 25, 1942, the patient stated that she had passed a drop of red blood with her bowel movement although she had not been constipated. This was twenty one months after any previous evidence of activity in a case which was about to be reported as a complete cure At proctoscopy on Jan 29, 1942, there was a hyperplastic cobblestone like area 10 cm. from the anus at the site of a previously mentioned proctitis. This area was about 4 by 2 cm. and was on the right antero lateral wall. The site of the previous stricture was still normal and a consulting proctologist not familiar with the history of previous pathology saw nothing resembling a stricture in that area even after it had been called to his attention.

*The therapeutic unit of Frei antigen (Lederle Laboratories, Inc), mouse-brain suspension has been laid down as 1/10 of the skin-test dose of that material as determined for each lot in lymphogranulomatous subjects

Neoprontosil was again started as formerly and a biopsy was taken. Pathologically this showed signs of chronic inflammation. August, 1942, this area was completely healed but neoprontosil was to be given prophylactically for two weeks every six months

This case illustrates that permanent cure was not brought about in spite of a result equal to any recorded in the literature and emphasizes the need for follow-up care.

CASE 2.—Z. W., a Negress, aged 31 years, was seen at the office on Dec 5, 1940, complaining of inability to move her bowels After an enema she got a result only if the tip was left in place and the flow was through it. She stated she had had two years of trouble dating back to August, 1939, at which time she noted rectal "bleeding" and ribbonlike stools In 1940, she had an operation (biopsy) following which she had "no control" over a flatus or liquid stools She stated that she had had glands in the groin lanced in 1932, with drainage of pus there after She had had gonorrhea treated with sulfanilamide and a 4 plus Wassermann treated for over a year, this was still being treated When the past history was investigated it was found that at the birth of a child in 1928 she had had swollen glands in the groin but these subsided gradually. On Aug 24, 1939, she had been seen in the hospital clinic because of prolonged pain in the rectum, constipation, and pus discharging in the anal region A fistula was found at that time extending from the rectum through the ischiorectal fossa and onto the right buttock lateral to the vulva On Aug 28, 1939, she was admitted to the hospital with a history of progressive constipation of one year's duration, with no discharge except from the fistula and relief of constipation only through enemas Rectal examination at that time revealed a rough, irregular feeling in the region of the sphincter and about 3 cm above the anus a smooth circular stricture barely admitting the tip of the index finger The Frei test was positive as was the Wassermann It is interesting to note that although the temperature was normal throughout, it rose to 103° F and she had a three quarter hour chill after the Frei antigen was injected intracutaneously for testing. On June 28, 1940, biopsy from the stricture showed a nonspecific chronic inflammatory process. Following this admission she developed inability to control flatus and liquid feces It was later found that these escaped from the vaginal orifice via a rectovaginal fistula.

When seen on Dec 5, 1940, she was chronically ill She weighed 128 pounds and was 5 feet four and one half inches tall Significant findings included early mitral insufficiency, rectovaginal fistula, old healed fistula, a small walnut sized mass to the left and below the urethra diagnosed as inflammation of the periurethral glands and ducts, and she had moderate elephantiasis of the vulva. Although her hemoglobin had been 78 per cent the year previously when in the hospital, it was now 56 per cent, the stricture which had been approximately 1 cm in diameter was now 0 3 to 0 5 cm and she had a chronic proctitis below it with many granulations and two skin tags Her rectum and anal region were exquisitely tender on digital examination The rectum was dilated gradually with the tip of the little finger every other day, over a four week period, and neoprontosil was given in 15 gr. retention enemas tid At first most of it escaped through the fistula but after a short time most was retained by the practice of lying with the head low and the thighs together from one half to one hour after each enema She had ninety eight days' treatment with several short periods of rest (three to seven days) because of dizziness and small drops in the hemoglobin Throughout this time she was taking 15 to 25 gr. of ferrous sulfate daily and hemoglobin was constantly below 65 per cent By Jan 7, 1941, the rectal mucosa was much smoother, lumen was about 1 cm in diameter, and the bowels were almost normal as far as she was concerned By March 15, 1941, the rectum was about 2 cm in diameter, and

smooth; she had no difficulty. When examined two weeks later it seemed that the stricture was contracting though there was no new pathology. At this time she was given Frei antigen intravenously in 1, 5, 10, 20, 30, 40, 50, and 60 unit doses from April 1 to 28. On July 16, 1941, there was no further progression of the stricture and its diameter was 2.3 cm. During the previous period she had resumed neoprontosil retention enemas, 40 gr. daily. She stated that her bowels were perfectly normal even without lubrication of mineral oil, she had had no bleeding or discharge, and she stated that she felt better than in many years. Her hemoglobin was now 75 per cent and her weight 137 pounds. On Oct. 2, 1941, she stated that she was normal but no examination was made since I did not want to exert even digital pressure on the remaining stricture for some time, feeling that it could not contract adequately if it were going to do so. A few days later, while on a visit to New York City, she was operated upon for a ruptured ectopic pregnancy at the Harlem Hospital. She had an uneventful course. In December, 1941, the Frei test was still positive, total proteins were 7.6 per cent, globulin 3.9 per cent, and albumin 3.7 per cent. When seen in March, 1942, her rectum was as it had been in September, 1941, at the last examination, in spite of no manipulation of any kind. At present there is still a completely circular fibrous band present but this is more distensible than at any previous time and the normal lumen is 2.3 cm., which is four to eight times larger than at the beginning of treatment. The wall is smooth and it is now proposed that the patient be operated upon for repair of her tiny rectovaginal fistula. The vulva is of normal size and the periurethral mass is now only about 1 cm. in diameter. Wassermann, too, is negative.

CASE 3.—H. S., a Negress, aged 30 years, was first seen in the office on Sept. 19, 1940, complaining of "corruption" from the rectum, pain, marked constipation, and intermittent diarrhea. She had been seen in the clinic on June 15, 1939, when she complained of bleeding from the rectum, present for some time. Examination at that time had revealed a small ulcer at the posterior commissure of the rectum about 3 cm. above the anus, many small bleeding internal hemorrhoids (?), and a small external hemorrhoid. There was no constriction of the lumen but she was advised to return for a Frei test. She was not seen again until Aug. 29, 1940 (fourteen and one-half months later), at which time she complained of pain and bleeding on defecation. She stated that she had no normal movements and always required a cathartic. Digital examination at that time revealed an almost complete stricture of the rectum 2 cm. above the anus, the lumen being less than 1 cm. in diameter. There was exquisite tenderness and some bleeding on digital examination.

From previous hospital admissions it was learned that in 1930, at the time of a delivery, she had a normal anus and rectum. Subsequently, she had an early miscarriage. In November, 1934, she had some swelling in the inguinal region. At this time, too, she had sharp vaginal pain and discharge and on Dec. 9, 1934, because of a small, walnut-sized mass felt in the cul-de-sac just to the left of the uterus and projecting against the rectal wall, she was operated upon for chronic bilateral salpingo-oophoritis. The specimen was reported as corresponding to the preoperative diagnosis and review at the present time confirms that opinion. She had been admitted to the hospital on Sept. 4, 1940, for diagnosis. Biopsy showed granulomatous tissue probably due to lymphogranulomatous venereum. The Frei test was positive; Wassermann was negative as it had been on previous admissions; and culture from the rectum showed *Bacillus coli* and nonhemolytic streptococci. The rest of the examination was essentially normal except for a hemoglobin of 58 per cent and weight of 98 pounds.

Examination Sept. 19, 1940, revealed the picture described above. The patient was given neoprontosil, 60 gr. daily, by retention enema and a few days later improvement in the discharge was reported. The dosage was reduced to 40 gr. daily

and after one month's treatment the stricture was softer and would admit the largest finger with some effort but no pain. By Oct. 28, 1940, the hemoglobin was 70 per cent. Two weeks later, because of diarrhea, medication was suspended for one week. Her weight was down to 93 pounds. On Dec. 3, 1940, the largest finger could be inserted without difficulty and a month later she stated that her bowels were normal. At this time she took 30 gr. of neoprontosil by enemas daily. Weight was 98 pounds and she had a small amount of clear, mucous discharge. Her condition remained the same until March 24, 1941, at which time it was felt that Frei antigen intravenously could be started with great profit. Following these injections, although there were no symptoms, it did seem that the fibrous tissue was contracting once more, though the lumen of the rectum was 2.3 cm. in diameter. Accordingly, in June, a second course of Frei antigen was given along with resumption of neoprontosil. When last seen on Oct. 30, 1941, her weight was 110 pounds, there was no discharge, the bowels were normal, and she felt too well to return for further checkup. At this time the stricture composed of old scar tissue completely covered by normal mucosa still is responsible for a narrowing of the rectal lumen to a diameter of 2.3 cm., the size of the examining finger.

Early in the course of her treatment, this patient remarked that a severe arthritis, which had limited motion in the right wrist, and had also involved the left elbow, had disappeared. She had suffered this difficulty intermittently for several years but it has not recurred since the latter part of October, 1940.

CASE 4.—E. D., a Negress, aged 26 years, was first seen in the outpatient department on Oct. 10, 1940, complaining of constipation and rectal bleeding of five years' duration. External inspection was negative. Digital examination revealed a rectal stricture 8 to 9 cm. above the anus, too contracted to admit the tip of the middle finger. There was some sanguino-purulent discharge at this time. Six years previously she had had an operation (appendectomy?) in the South and at that time had been told that she had some rectal pathology. Inquiries directed to that institution have not been answered. She was admitted to the hospital on Oct. 10, 1940, and discharged on Oct. 17. In spite of a familial history of tuberculosis, the Mantoux test was repeatedly negative as was the Wassermann. The Frei test was read as negative by the intern but was positive when seen one month later. When this test was repeated it was positive. At the time of admission she stated that she had had pencillike stools for eighteen months. Biopsy was not done but clinically the stricture was typical of lymphogranuloma venereum and the Frei test seemed amply confirmatory. She was given the neoprontosil retention enemas treatment which was continued from Nov. 21, 1940, to April 3, 1941. At the end of that period she was symptom-free but still had the stricture, although the lumen was now about 2 cm. in diameter. She was not seen again until Sept. 11, 1941, at which time she had no constipation or pain but did have some serous discharge. Neoprontosil was resumed and she was given a course of Frei antigen intravenously. She has been completely symptom-free since that time and her stricture is now a fibrous band of which the lumen is still 2 cm. in diameter and is completely covered by mucosa. It may be noted that her Frei test was still positive and the albumin-globulin ratio, fourteen months after the start of treatment, was 3.8 to 3.3. It is intended that she continue treatment by taking a two-week course of neoprontosil every six months.

CASE 5.—J. G., a Negress, aged 24 years, was seen on Nov. 22, 1940, in the ward, where she was suffering from bilateral salpingitis. At the time of admission she had received several months of antisyphilitic therapy. Routine examination disclosed a marked rectal stricture with a lumen of about 1 cm. diameter, 5 cm. from the external sphincter. A Frei test, performed on Dec. 8, 1940, was positive. Conservative supportive therapy resulted in the subsidence of the salpingitis and on Dec. 11, 1940, the rectum was dilated under pentothal sodium. At this time it was

smooth; she had no difficulty. When examined two weeks later it seemed that the stricture was contracting though there was no new pathology. At this time she was given Frei antigen intravenously in 1, 5, 10, 20, 30, 40, 50, and 60 unit doses from April 1 to 28. On July 16, 1941, there was no further progression of the stricture and its diameter was 2.3 cm. During the previous period she had resumed neoprontosil retention enemas, 40 gr. daily. She stated that her bowels were perfectly normal even without lubrication of mineral oil, she had had no bleeding or discharge, and she stated that she felt better than in many years. Her hemoglobin was now 75 per cent and her weight 137 pounds. On Oct. 2, 1941, she stated that she was normal but no examination was made since I did not want to exert even digital pressure on the remaining stricture for some time, feeling that it could not contract adequately if it were going to do so. A few days later, while on a visit to New York City, she was operated upon for a ruptured ectopic pregnancy at the Harlem Hospital. She had an uneventful course. In December, 1941, the Frei test was still positive, total proteins were 7.6 per cent, globulin 3.9 per cent, and albumin 3.7 per cent. When seen in March, 1942, her rectum was as it had been in September, 1941, at the last examination, in spite of no manipulation of any kind. At present there is still a completely circular fibrous band present but this is more distensible than at any previous time and the normal lumen is 2.3 cm., which is four to eight times larger than at the beginning of treatment. The wall is smooth and it is now proposed that the patient be operated upon for repair of her tiny rectovaginal fistula. The vulva is of normal size and the periurethral mass is now only about 1 cm. in diameter. Wassermann, too, is negative.

CASE 3.—H. S., a Negress, aged 30 years, was first seen in the office on Sept. 19, 1940, complaining of "corruption" from the rectum, pain, marked constipation, and intermittent diarrhea. She had been seen in the clinic on June 15, 1939, when she complained of bleeding from the rectum, present for some time. Examination at that time had revealed a small ulcer at the posterior commissure of the rectum about 3 cm. above the anus, many small bleeding internal hemorrhoids (?), and a small external hemorrhoid. There was no constriction of the lumen but she was advised to return for a Frei test. She was not seen again until Aug. 29, 1940 (fourteen and one-half months later), at which time she complained of pain and bleeding on defecation. She stated that she had no normal movements and always required a cathartic. Digital examination at that time revealed an almost complete stricture of the rectum 2 cm. above the anus, the lumen being less than 1 cm. in diameter. There was exquisite tenderness and some bleeding on digital examination.

From previous hospital admissions it was learned that in 1930, at the time of a delivery, she had a normal anus and rectum. Subsequently, she had an early miscarriage. In November, 1934, she had some swelling in the inguinal region. At this time, too, she had sharp vaginal pain and discharge and on Dec. 9, 1934, because of a small, walnut-sized mass felt in the cul-de-sac just to the left of the uterus and projecting against the rectal wall, she was operated upon for chronic bilateral salpingo-oophoritis. The specimen was reported as corresponding to the preoperative diagnosis and review at the present time confirms that opinion. She had been admitted to the hospital on Sept. 4, 1940, for diagnosis. Biopsy showed granulomatous tissue probably due to lymphogranulomatous venereum. The Frei test was positive; Wassermann was negative as it had been on previous admissions; and culture from the rectum showed *Bacillus coli* and nonhemolytic streptococci. The rest of the examination was essentially normal except for a hemoglobin of 58 per cent and weight of 98 pounds.

Examination Sept. 19, 1940, revealed the picture described above. The patient was given neoprontosil, 60 gr. daily, by retention enema and a few days later improvement in the discharge was reported. The dosage was reduced to 40 gr. daily

THE MURPHY BUTTON IN ESOPHAGOGASTROSTOMY

LAURENCE MISCALL, M.D., AND BLISS B. CLARK, M.D.
NEW YORK, N. Y.
(From the Second [Cornell] Surgical Division of Bellevue Hospital)

THIS report details the use of the Murphy button in two patients with carcinoma of the lower third of the esophagus subjected to resection and primary esophagogastrostomy. The satisfactory results from extensive use of the button in intestinal resection on this division of Bellevue Hospital have been attributed to the belief that it prevents leakage at the site of anastomosis by insuring a tight but patent anastomosis until adequate adhesions form. In these two cases the button not only accomplished these important prerequisites but also facilitated operative anastomosis. The unfortunate death of one patient (H. C., Case 1) should not be attributed to failure of the button but rather to an error in the technique of the operator. Since this essentially simple method may have definite advantages in esophagogastrostomy, a review of the important points may be of value.

Through a left transthoracic intercostal approach the esophagus was mobilized upward from the hiatus to just below the arch of the aorta. Through it the gastrocolic and gastrohepatic omentum and vessels on both curvatures were divided sufficiently to allow delivery, without tension, of the fundus to the arch of the aorta. The esophagus was then divided from the stomach between clamps and the latter closed with interrupted sutures. With the esophagus retracted over the arch, the fundus was sutured to the thoracic wall and pleura at this level (Fig. 1). These sutures were placed in the posterior gastric wall to allow later folding of the anterior wall around the anastomosis. About two and one-half inches above the tumor the posterior esophageal wall was approximated to the anterior gastric wall by three interrupted silk sutures which were not tied at this time. A small intestinal clamp was then placed above these across the esophagus, which was then divided between clamps just above the tumor. Roughly one inch of mobile esophagus below the above untied silk sutures is needed for easy insertion of the button. A purse string in the anterior gastric wall, at the point to which the esophagus easily reached, was tied snugly around the neck of the inserted button which is retained in place by a hemostat (Fig. 2). An over-and-over running suture in the edge of the open esophagus was reinforced by a ligature to retain the button (Fig. 3). The first silk sutures were now tied and the button closed. The anterior gastric wall was then sutured around the anastomosis by approximating line *C-C'* and *D-D'*. The closure was completed by interrupted sutures circumferentially approximating the esophagus to the upper border of gastric serosa (Fig. 4).

Received for publication, Oct. 13, 1942.

found that there were many areas of proctitis and granulation from 2 to 3 cm. above the stricture down to the anus. That evening her temperature rose to 104.4° F. and thereafter, for ten days, there was considerable spiking each day. At the end of this period she permitted the beginning of treatment by neoprontosil retention enemas. She returned to the office after almost a month's lapse and after only one week's treatment. When seen on Jan. 30, 1941, the rectal mucosa was much smoother, the proctitis markedly better, and she did not want further treatment, although she was prevailed upon to treat herself for ten days. In six weeks she returned for eight intravenous injections of Frei antigen, 1 to 60 units. When seen on July 15, 1941, the lumen of the rectum was still as wide as normal but there were many granulations and a moderate amount of purulent discharge, a condition still present on Sept. 15, 1941. In view of previous experiences I feel that the failure of this stricture to re-form promptly after dilatation was due to the treatment instituted. I feel, however, that treatment has been inadequate and that ultimately the stricture will recur.

REFERENCES

1. Kornblith, B. A.: Lymphogranuloma Venereum Treatment of Three Hundred Cases, Am. J. M. Sc. 198: 231, 1939.
2. Lichtenstein, L.: Rectal Stricture, Am. J. Surg. 31: 111, 1936.
3. Mentzer, C. G., and Allen, R. F.: Treatment of Rectal Manifestations of Lymphogranuloma Venereum, Bull. Jackson Mem. Hosp. 4: 30, 1942.
4. Herb, A., Sullivan, S. G., and Felton, L. D.: Treatment of Lymphogranuloma Venereum With Sodium Sulfanilyl Sulfanilate and Sodium Sulfanilate, Pub. Health Rep. (No. 2101) 54: 1750, 1939.
5. Marino, A. W., Buda A. M., Turell, R., and Nerb, L.: The Treatment of Venereal Lymphogranuloma With Sulfanilamide, Am. J. Surg. 46: 343, 1939.
6. Kennedy, C. B., Howles, J. K., Smallen, G., and Kapfler, M. E.: Treatment of Lymphogranuloma Inguinale With Neoprontosil, New Orleans M. & S. J. 93: 460, 1941.
7. Grace, A. W.: Lymphogranuloma Venereum, Bull. New York Acad. Med. 17: 627, 1941.
8. Stein, R. O.: Observations on Thirty-Five Cases of Venereal Lymphogranuloma Treated With Sulfanilamide, Am. J. Syph., Gonor. & Ven. Dis. 24: 454, 1940.
9. Carmel, A. G.: Stricture of the Rectum, Ohio State M. J. 36: 262, 1940.
10. Kornblith, B. A.: Observations on Lymphogranuloma Venereum, Surg., Gynec. & Obst. 63: 99, 1936.
11. Kornblith, B. A.: Personal Communication.
12. Costello, M. J., and Cohen, J. A.: Lymphogranuloma Venereum, Arch. Dermat. & Syph. 44: 391, 1941.
13. Yoemans, F. C.: Proctology, J. A. M. A. 117: 2054, 1941.
14. Palmer, W. L., Kirsner, J. B., and Rodaniche, E. C.: Lymphogranuloma Venereum Infection of the Rectum, J. A. M. A. 118: 517, 1942.
15. Martz, H., and Foote, M. N.: Stricture of Rectum Secondary to Lymphogranuloma Venereum Treatment With Diathermy, J. A. M. A. 114: 1041, 1940.
16. Mathewson, C., Jr.: Inflammatory Strictures of the Rectum Associated With Venereal Lymphogranuloma, J. A. M. A. 110: 709, 1938.
17. Shropshear, G.: Sulfanilamide in the Treatment of Strictures of the Rectum Caused by Lymphogranuloma Venereum, Illinois M. J. 74: 153, 1938.
18. Kornblith, B. A.: Chancroid: Lymphogranuloma Venereum (Healed): Syphilis, Arch. Dermat. & Syph., Soc. Trans. 44: 727, 1941.
19. Myerson, M. C.: Lymphogranuloma Venereum of the Hypopharynx and Larynx, J. A. M. A. 117: 1877, 1941.
20. Lazzari, J. H.: Anorectal Syndrome of Lymphogranuloma, Am. J. Surg. 34: 316, 1936.
21. Vandermeer, J. B., Cornia, F. E., and Ullery, J. C.: Lymphopathia Venereum and Its Relation to Rectal Stricture, Am. J. M. Sc. 190: 178, 1935.
22. Prehn, D. T.: Lymphogranuloma Venereum and Associated Diseases, Arch. Dermat. & Syph. 35: 237, 1937.
23. D'Aunoy, R., and von Hamm, E.: Venereal Lymphogranuloma, Arch. Path. 27: 1032, 1939.

CASE 1.—H. C. (No. 69930) was admitted to Bellevue Hospital Dec. 28, 1941, with a chief complaint of progressive dysphagia for six weeks. This was associated with constant substernal, nonpainful discomfort described as a tightness. He had lost thirty-five pounds in weight.

Physical examination showed a chronically ill, emaciated white man about 70 years of age. He was dehydrated and obviously weak. He could swallow fluids but not solid food.

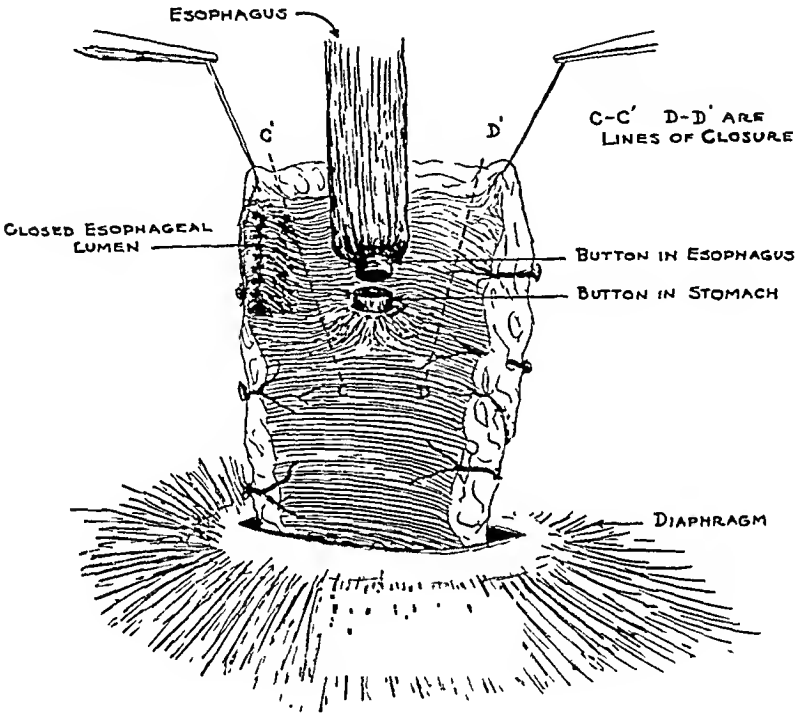

Fig. 3.

Laboratory.—W. B. C., 6,000; R. B. C., 4,000,000; Hb., 60 per cent; normal differential; Wassermann, negative; N.P.N., 34; blood sugar, 81; urine repeatedly negative. Stool had been negative for blood on many occasions. Esophagogram showed a persistent filling defect of the lower third of the esophagus reported as a probable carcinoma. Biopsy showed transitional cell epithelioma.

Operation was done Jan. 20, 1942.

Pathology.—The lower third of the esophagus contained an annular hard mass (6 by 4 cm.) with a few obvious metastases in the nodes along the aorta and in the gastrohepatic omentum.

Procedure.—Under cyclopropane anesthesia the skin was suitably prepared and an intercostal incision between the seventh and eighth ribs was made from the costal margin to the spine. The esophagus was mobilized upwards from the hiatus after careful ligation of its vessels. This was continued to just below the arch of the aorta. The diaphragm was incised radially from the hiatus. The stomach was mobilized by division and ligation of the omentum and vessels including the left gastric artery. A splenectomy was necessary because of adhesions to allow delivery, without tension, of the fundus to the arch of the aorta. The esophagus and stomach

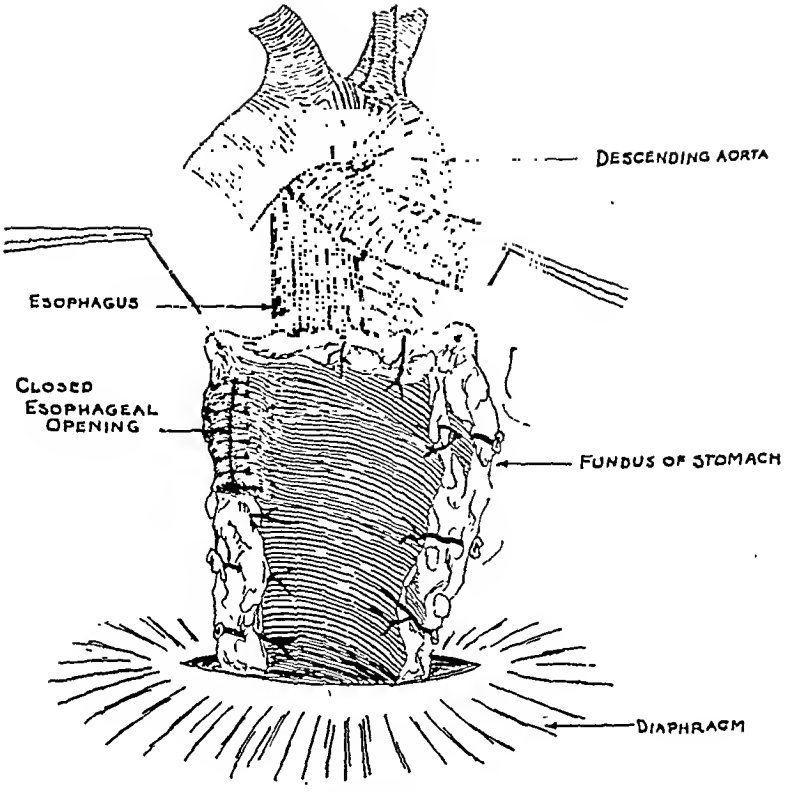
DESCENDING AORTA
ESOPHAGUS
CLOSED
ESOPHAGEAL
OPENING
FUNDUS OF STOMACH
DIAPHRAGM

Fig. 1.

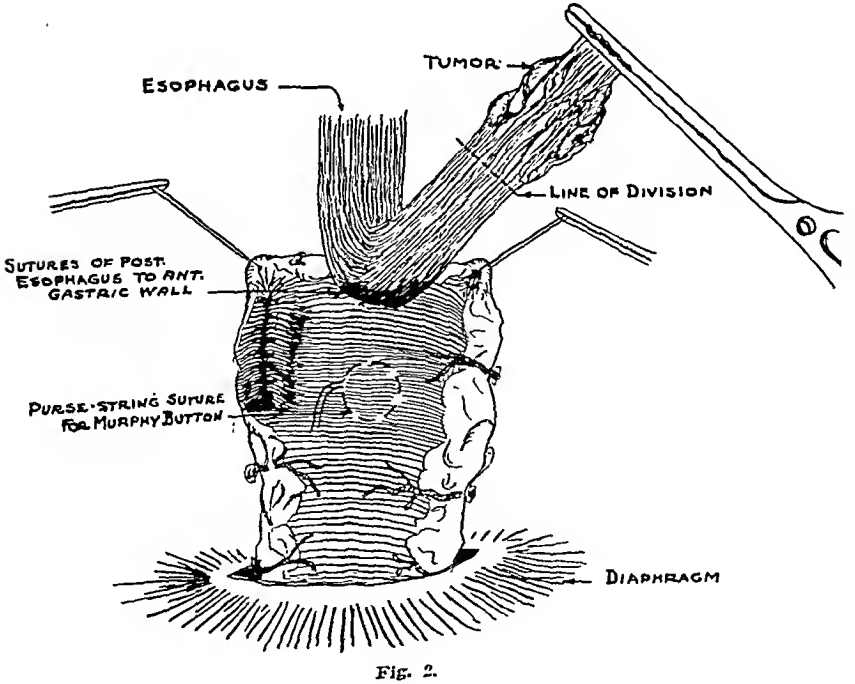
TUMOR
ESOPHAGUS
LINE OF DIVISION
SUTURES OF POST.
ESOPHAGUS TO ANT.
GASTRIC WALL
PURSE-STRING SUTURE
FOR MURPHY BUTTON
DIAPHRAGM

Fig. 2.

wound cleared up well, temperature receded, and the patient was able to take fluids without pleural leakage. In five days he took a soft diet. On his thirtieth postoperative day, an infection of a decubitus ulcer spread rapidly and he died on his thirty-sixth postoperative day. Until shortly before his death he was able to take fluids and semisolids without any evidence of pleurogastric fistula.

CASE 2.—B. A. (No. 31705) was admitted to Bellevue on June 9, 1942, with a chief complaint of inability to swallow. Ten years before he was treated with digitalis for two months for a nervous heart. Since then he has never had any symptoms until dysphagia began three months before admission. This gradually increased until he was admitted unable to take even liquids.

Physical examination showed a chronically ill, emaciated white man, about 55 years of age, with a weight loss of thirty pounds. Through a Levin tube the patient was receiving liquids. The heart was slightly enlarged to the left with an apical systolic murmur and irregular rhythm and blood pressure of 130/70.

Laboratory.—Temperature and respiration normal; pulse, somewhat irregular; R. B. C., 5,000,000; Hb., 90 per cent; W. B. C., 8,000; normal differential; Wassermann, negative; urine, negative; N.P.N., 26. X-ray study of the esophagus with barium showed an obstructing lesion of the lower third of the esophagus.

Operation was performed June 12, 1942.

Pathology.—A stony hard lesion approximately the size of a walnut was present in the lower third of the esophagus about one inch above the hiatus. There were several discrete stony hard nodes below the diaphragm but the liver was free of metastases.

Procedure.—Silk was used exclusively in doing the same procedure as in Case 1.

Postoperative Follow-up.—The patient had a very satisfactory postoperative course. His temperature rose to approximately 101° F. for seven days, then subsided to normal by the thirteenth postoperative day. The white count rose to 13,000 but also returned to normal. Serosanguineous drainage from the chest rapidly decreased and the tube was removed on the sixth postoperative day. The sutures were removed on the seventh and ninth postoperative days with primary union. The patient took sips of water on the second postoperative day. The fluid intake was gradually increased and by the seventh postoperative day he was taking the routine semifluid diet given during gastric resections. The Murphy button remained fixed in the esophagus until the sixteenth postoperative day when it passed into the stomach. On the twenty-first postoperative day the patient was taking a soft diet with no difficulty in swallowing. He was allowed out of bed at this time. The Murphy button was still at the antrum at discharge on his thirty-second postoperative day.

SUMMARY

In these two cases a satisfactory esophagogastric anastomosis was obtained using the Murphy button. One death occurred from extrapleural infection.

If the button is used, its line of anastomosis should be reinforced by adequate serosal covering which is easily done by the described method without tension at the site of suture. Silk sutures throughout are probably necessary. The button not only provides a tight, nonleaking anastomosis while adequate adhesions form but also insures a patent lumen which allows early oral administration of fluids. The spontaneous opening of the stomach which had been closed with catgut (Case 1) emphasizes the importance of adequate closure, which can probably best be accomplished with the exclusive use of silk sutures.

were divided between clamps and the gastric opening closed with two layers of catgut. Three silk sutures were placed but untied to approximate the posterior esophageal wall to the anterior wall of the stomach at its highest point. An intestinal clamp was placed above the level of these sutures and the tumor excised between two other clamps. A purse-string suture of medium silk was placed in the anterior gastric wall at the point to which the lower end of the esophagus reached easily. This was tied snugly around the neck of the button which had been inserted into the stomach, and retained in place by a hemostat. An over-and-over running suture in the edge of the open esophagus and a second ligature were tied snugly around the other half of the button. The three silk sutures were then tied and the button closed

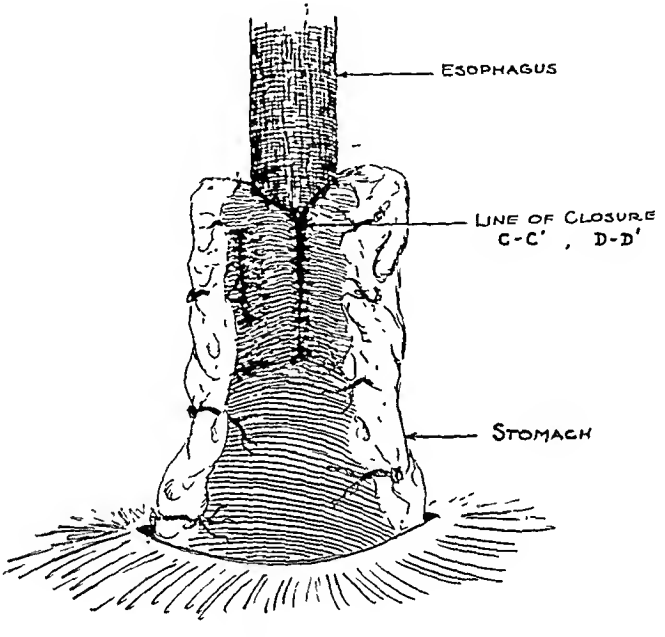

Fig. 4.

tightly. The anterior gastric wall was then sutured over the site of anastomosis in a V-shaped manner and to the esophagus with interrupted silk. Sulfanilamide powder, 5 Gm., was sprinkled in the chest which was drained through a small stab wound. Two silver wires approximated the ribs and the wound was closed with interrupted silk. The left lung was expanded and an infusion of 1,000 c.c. of 5 per cent glucose-saline was given on the table. He was returned to the ward in good condition, placed in an oxygen tent, and the tube connected for closed drainage.

Follow-up.—The patient's immediate postoperative course was satisfactory, oral fluids being started on the second postoperative day. On the first postoperative day, 430 c.c. of fluid and 15 c.c. on the second postoperative day were removed from the left chest. Culture of this showed no growth. On the sixth postoperative day when the temperature rose to 104° F., an x-ray showed a hydropneumothorax and 500 c.c. of foul smelling purulent fluid were aspirated. Closed drainage was instituted and followed by open drainage on the eleventh postoperative day, when, with methylene blue, a pleural gastric fistula was demonstrated. On the thirteenth postoperative day the chest was reopened and it was found that the closure of the esophageal opening in the stomach had blown out. This had been repaired with catgut. It was reclosed with three layers of interrupted silk sutures and a transfusion of 500 c.c. of whole blood was given. The site of anastomosis was tight and patent. The chest

facts have shaken profoundly our belief in the role played by the diminution of renal blood flow in the intrinsic mechanism of arterial hypertension.

The purpose of this study was, therefore, to check whether and to what degree the ischemia of renal tissue shares in the production of hypertension and, if not, which other factor can be made responsible for the appearance of high blood pressure. This study was carried out in the Institute of Experimental Surgery of Caracas, a legacy of a distinguished Spanish colleague, the late Manuel Corachan of Barcelona, who with the aid of its present director, Herman de Las Casas, founded this Institute and to whose courtesy we are indebted for the privilege of utilizing its facilities.

Method.—In order to establish which part the renal ischemia plays in creating arterial hypertension, we considered the effect of venous congestion from the point of view of the blood pressure in experimental animals. As is well known from numerous clinical and experimental studies, as well as from the paper recently published by Linton and his associates,[7] venous congestion increases considerably arterial flow to the ischemic as well as to the normal tissue. In view of this fact, and the widely accepted theory that the renal ischemia is responsible for hypertension, it could be a priori taken for granted that passive congestion following venous obstruction should eliminate renal ischemia resulting from constriction of the renal artery and in this way have a beneficial effect upon essential hypertension. This is not the case, as can be seen from our graph based on the experiment with Dog No. 69, which only confirms the results already obtained by other authors. Thus, it is well known that partial venous obstruction not only does not influence arterial hypertension in a favorable direction but, on the contrary, can be considered as one of the most reliable means of creating experimental hypertension and in this respect can be put nearly on the same level with constriction of the renal arteries (Weiss[8]). The next step was to find out what factor is common to two quite opposite procedures from the point of view of arterial inflow like arterial or venous constriction. This denominator common to two so widely different procedures was, as found by us, only an increase of the venous pressure in relation to the pressure on the arterial side of the kidney. Such a relative and absolute increase of venous pressure is quite obvious in case of constriction of the renal vein. But if the pressure on the arterial side of the kidney becomes diminished through clamping of the renal artery, it is also clear that the venous runoff is diminished and venous pressure increased in relation to the arterial pressure, or vis a tergo, among other things, also because the arterial pulsation assists the movement of blood in certain veins, as shown by Schade and Wohlleben.[9] In both cases, therefore, i.e., after arterial or venous constriction has been produced, the pressure difference on the trajectory arterioles, capillaries, and venules

RENAL CIRCULATION AFTER THE COMPRESSION OF RENAL ARTERY ACCORDING TO THE METHOD OF GOLDBLATT

Study of the Influence of the Renal Venous Runoff Upon the Experimental Hypertension

Frank P. Corrigan, M.D., Cleveland, Ohio,* and
Ignacy Pines, M.D., Warsaw, Poland*

THE present period in the study of essential hypertension was opened by famous experiments of Goldblatt, Lynch, Hanzal, and Summerville,[1] who once again brought to the fore the so-called renal theory of hypertensive disease. These observers proved definitely that the moderate compression of one renal artery of a dog leads to temporary hypertension, whereas the compression of both renal arteries is accompanied, as a rule, by an immediate rise of blood pressure persisting, for practical purposes, indefinitely. Simultaneously, or a little later, other authors have stressed the value of these experiments by showing that in human cases of arterial hypertension the same constriction of renal vessels can be demonstrated in the majority of cases.

However, in spite of this considerable progress made in the study of experimental and clinical hypertension, many parts of the mechanism of appearance of this syndrome are still in doubt. To begin with, even the simple fact of renal ischemia, depending upon the constriction of the main renal artery by the maneuver of Goldblatt[1] or because of the atherosclerotic alterations of the renal arteries in man, is questioned from many sides. Some, like Steiner, Weeks, and Barach,[2] have shown on experimental animals as well as on human beings with arterial hypertension that the degree of the saturation of blood by oxygen has no influence upon the elevated level of blood pressure. Others, like Corcoran and Page,[3] have established that the persistent hypertension depending upon renal arterial compression or compression of the renal parenchyma, as in perinephritis, may occur without changes in the renal clearances of diodrast, phenol red, inulin, or urea and without alterations of tubular, excretory, and reabsorptive capacity and, therefore, probably in the absence of ischemia of excretory renal tissue. Finally, still others have brought indirect proofs that arterial hypertension does not depend upon the renal ischemia, by demonstrating that repeated attempts to treat experimental or human hypertension by creating an efficient collateral circulation are nearly always unsuccessful (Mansfield and associates,[4] Bruger and Carter,[5] and De Takáts and Scupham[6]). These

*Now in Caracas, Venezuela.

Received for publication, Dec. 5, 1942.

facts have shaken profoundly our belief in the role played by the diminution of renal blood flow in the intrinsic mechanism of arterial hypertension.

The purpose of this study was, therefore, to check whether and to what degree the ischemia of renal tissue shares in the production of hypertension and, if not, which other factor can be made responsible for the appearance of high blood pressure. This study was carried out in the Institute of Experimental Surgery of Caracas, a legacy of a distinguished Spanish colleague, the late Manuel Corachan of Barcelona, who with the aid of its present director, Herman de Las Casas, founded this Institute and to whose courtesy we are indebted for the privilege of utilizing its facilities.

Method.—In order to establish which part the renal ischemia plays in creating arterial hypertension, we considered the effect of venous congestion from the point of view of the blood pressure in experimental animals. As is well known from numerous clinical and experimental studies, as well as from the paper recently published by Linton and his associates,[7] venous congestion increases considerably arterial flow to the ischemic as well as to the normal tissue. In view of this fact, and the widely accepted theory that the renal ischemia is responsible for hypertension, it could be a priori taken for granted that passive congestion following venous obstruction should eliminate renal ischemia resulting from constriction of the renal artery and in this way have a beneficial effect upon essential hypertension. This is not the case, as can be seen from our graph based on the experiment with Dog No. 69, which only confirms the results already obtained by other authors. Thus, it is well known that partial venous obstruction not only does not influence arterial hypertension in a favorable direction but, on the contrary, can be considered as one of the most reliable means of creating experimental hypertension and in this respect can be put nearly on the same level with constriction of the renal arteries (Weiss[8]). The next step was to find out what factor is common to two quite opposite procedures from the point of view of arterial inflow like arterial or venous constriction. This denominator common to two so widely different procedures was, as found by us, only an increase of the venous pressure in relation to the pressure on the arterial side of the kidney. Such a relative and absolute increase of venous pressure is quite obvious in case of constriction of the renal vein. But if the pressure on the arterial side of the kidney becomes diminished through clamping of the renal artery, it is also clear that the venous runoff is diminished and venous pressure increased in relation to the arterial pressure, or vis a tergo, among other things, also because the arterial pulsation assists the movement of blood in certain veins, as shown by Schade and Wohlleben.[9] In both cases, therefore, i.e., after arterial or venous constriction has been produced, the pressure difference on the trajectory arterioles, capillaries, and venules

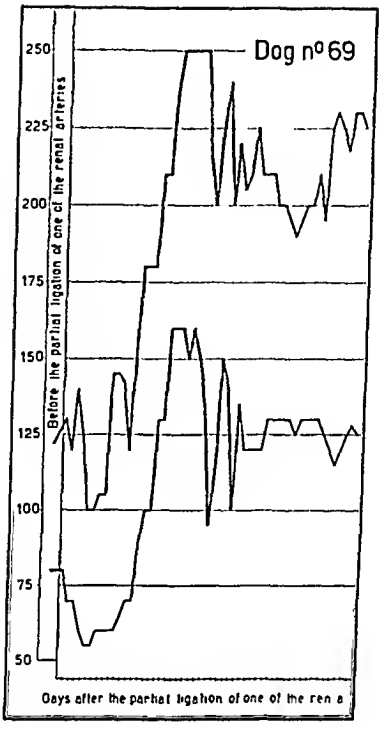
Dog nº 69
250
225
200
175
150
125
100
75
50
Before the partial ligation of one of the renal arteries
Days after the partial ligation of one of the ren a

Fig 1

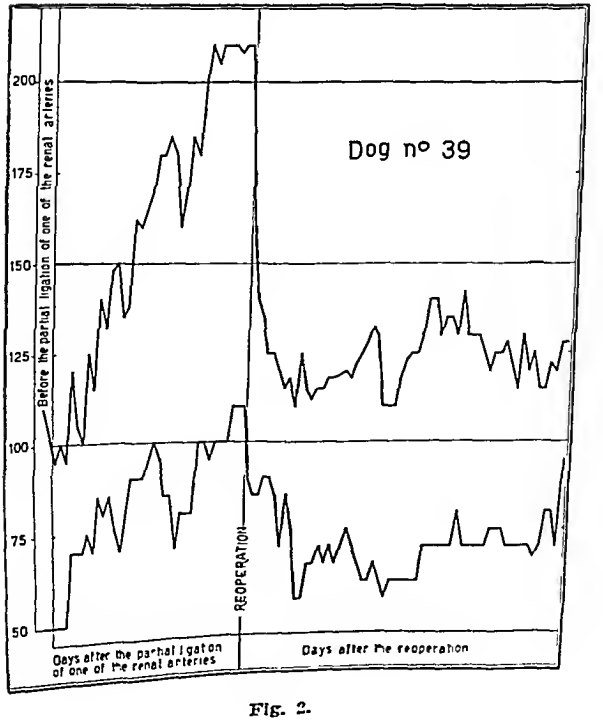
Dog nº 39
200
175
150
125
100
75
50
Before the partial ligation of one of the renal arteries
REOPERATION
Days after the partial ligaton of one of the renal arteries
Days after the reoperation

Fig. 2.

would diminish and probably bring with itself a concomitant stasis in the renal capillaries.

Taking all of these factors into consideration, we desired to examine the possibility of arterial hypertension being dependent upon the relative increase of local venous pressure as compared to the pressure on the arterial side of the kidney. We sought then to increase the venous runoff and to diminish the venous pressure after the Goldblatt[1] maneuver had been performed. In order to accomplish this purpose, we elevated the kidneys sufficiently to straighten the course of the renal veins. This added the force of gravity to the vis a tergo in certain positions of the animal, prevented the collapse of venous walls, and also, by establishing a closer contact between the renal vein and artery, increased the effect of arterial pulsation upon the movement of blood in the renal vein. This procedure was applied only to animals that had developed hyper-

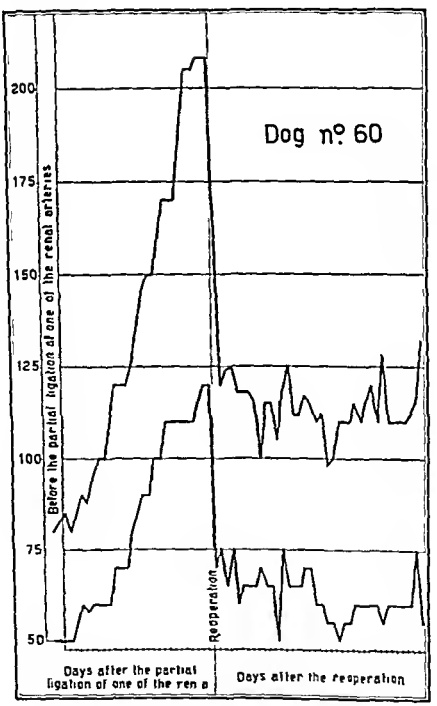

Fig. 3.

tension and in the following ways: (a) In the first group (Dogs 39, 54, 60, and 68) to the kidneys whose renal arteries were previously constricted; (b) in the second group (Dogs 32, 44, 48, 70, 72, and 73) to the intact opposite kidney with simultaneous ligation of the renal artery so that both renal arteries were ligated and only one kidney was elevated; and (c) in the third group (Dog 14) to the intact opposite kidney without ligating the ipsilateral artery so that one renal artery was ligated

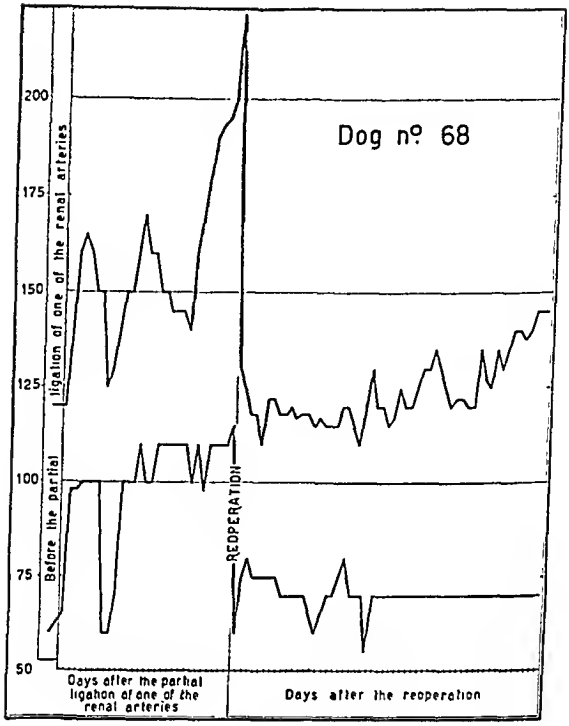
Dog nº 68
200
175
150
125
100
75
50
Before the partial ligation of one of the renal arteries
REOPERATION
Days after the partial ligation of one of the renal arteries
Days after the reoperation

Fig. 4.

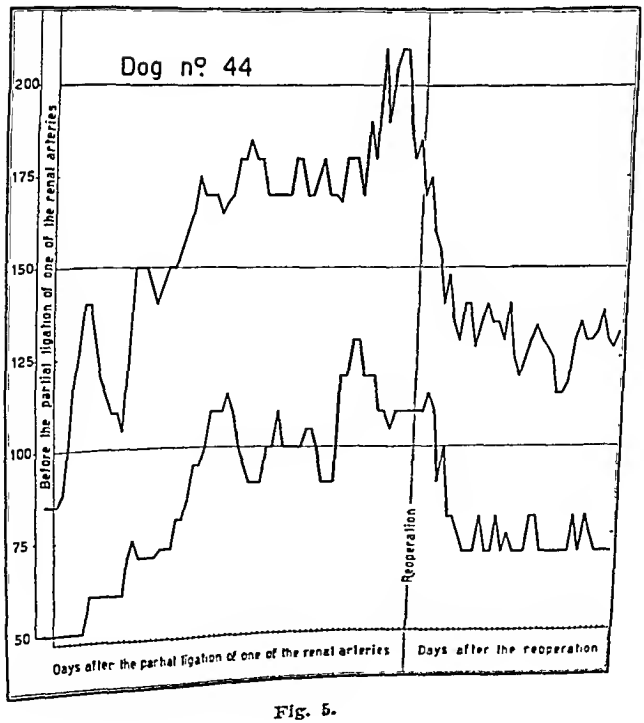
Dog nº 44
200
175
150
125
100
75
50
Before the partial ligation of one of the renal arteries
Reoperation
Days after the partial ligation of one of the renal arteries
Days after the reoperation

Fig. 5.

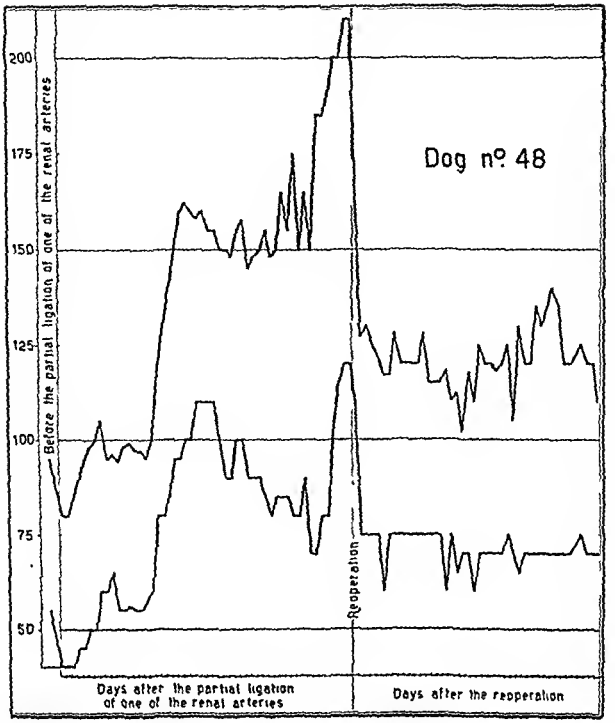

Fig. 6.

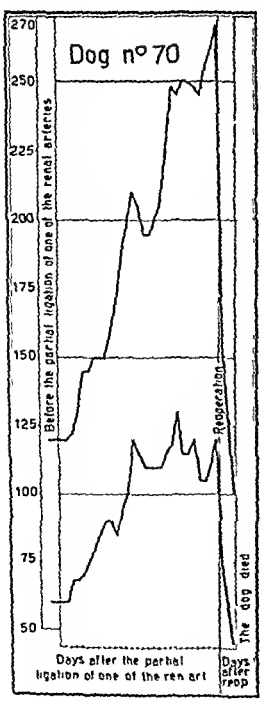

Fig. 7.

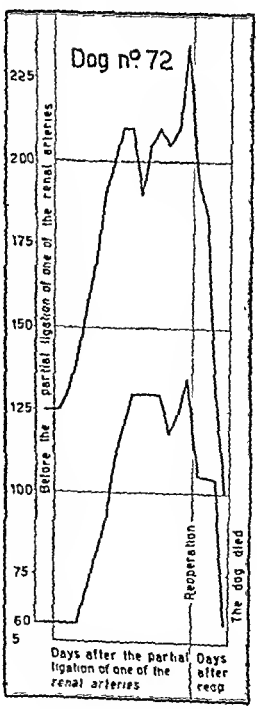

Fig. 8.

and the opposite kidney elevated in the manner already described. In all cases, as can be seen from the graphs, there was a marked fall of blood pressure. These results were particularly striking in the second group (b) in which, following constriction of both arteries, a further increase of blood pressure could be expected.

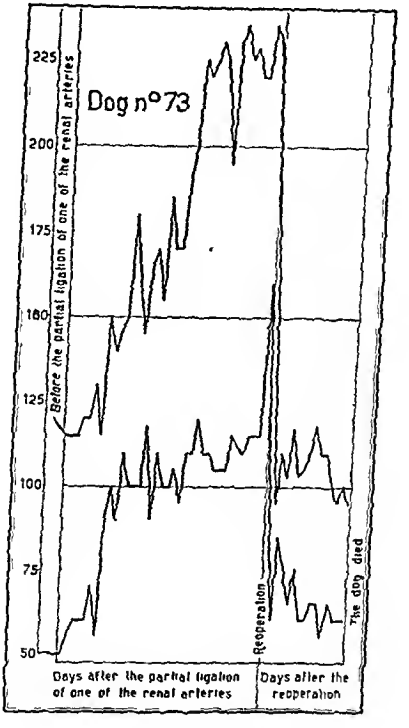

Fig. 9.

Surgical Procedure.—The first step of the operation was relatively simple, consisting of a diagonal incision about 8 cm. long beginning at a point at the juncture of posterior and middle thirds of the last rib and extending downwards and inwards at an angle of about 45 degrees roughly parallel to the fibers of the external oblique muscle. The transverse cutting of muscles was not always avoidable but was minimized as far as possible by using a muscle-splitting technique and dry dissection. The peritoneum in the dog should be handled carefully in order not to open it and thus make more difficult the retroperitoneal approach to the kidney. The kidney, exposed by separating the peritoneum from the postparietal wall and overlying structures, was brought into view and lifted from its bed, and in the first instance the renal artery was tied off in such a way as to reduce its caliber to about 60 per cent of normal capacity. In most instances it was not necessary to deliver the kidney, and primary ligation with a linen ligature was made in situ, with little disturbance of the organ from its normal position. The

closure was made in the usual orthodox fashion by layers. The mortality and morbidity were relatively low, being markedly higher in the reoperation of animals that had developed blood pressure of over 200 mm. of mercury. The results of the primary ligations were quite uniform and in line with previous experimental and clinical evidence. Elevations in blood pressure of 100 mm. or more were secured in each case of successful partial occlusion of the artery. The whole appearance of the animal changed; the nervous system became more excitable and it was manifestly more animated than before.

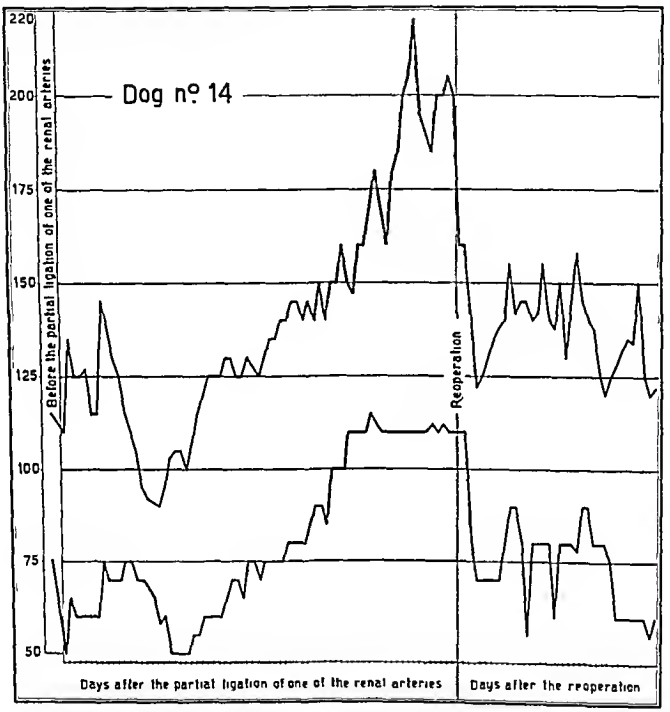

Fig. 10.

This observation of the well-known fact of the elevations of blood pressure by ischemia of the kidney was demonstrated as a preliminary step only. The next step in the experiment was one in which we were treading on new ground and for which a technique had to be devised. The desideratum was an increased runoff. There were also two steps in this stage of the investigations. In the first series, the animals whose renal arteries had already been subjected to partial occlusion were freshly exposed on the same side. The kidney was dislocated and fixed to the parietal wall with the lower part of the kidney about on a level with the lower edge of the last rib and with an average distance of removal of at least 5 cm. from its previous position. Nothing was done to the ligated artery except to establish the fact that it was function-

and the opposite kidney elevated in the manner already described. In all cases, as can be seen from the graphs, there was a marked fall of blood pressure. These results were particularly striking in the second group (b) in which, following constriction of both arteries, a further increase of blood pressure could be expected.

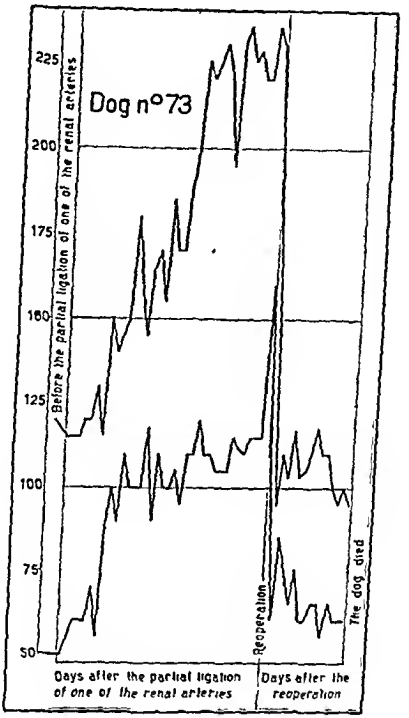

Fig. 9.

Surgical Procedure.—The first step of the operation was relatively simple, consisting of a diagonal incision about 8 cm. long beginning at a point at the juncture of posterior and middle thirds of the last rib and extending downwards and inwards at an angle of about 45 degrees roughly parallel to the fibers of the external oblique muscle. The transverse cutting of muscles was not always avoidable but was minimized as far as possible by using a muscle-splitting technique and dry dissection. The peritoneum in the dog should be handled carefully in order not to open it and thus make more difficult the retroperitoneal approach to the kidney. The kidney, exposed by separating the peritoneum from the postparietal wall and overlying structures, was brought into view and lifted from its bed, and in the first instance the renal artery was tied off in such a way as to reduce its caliber to about 60 per cent of normal capacity. In most instances it was not necessary to deliver the kidney, and primary ligation with a linen-ligature was made in situ, with little disturbance of the organ from its normal position. The

cases of congestion do we find elevated arterial blood pressure, but this is doubtless due to the fact that adequate heart action cannot be maintained or that the great rise of venous pressure takes place more particularly in the system of vena portae, thus having no influence upon the renal venous runoff.

But all of this leaves a question still open as to what is happening to the excess blood if the blood flow through the kidney is not diminished during arterial hypertension and there is present a greater or smaller degree of stasis in the capillaries. This problem, it seems, can be solved only when we admit that in the arterial hypertension blood passes through the renal arteriovenous shunts opened by the increased venous pressure. The presence of the arteriovenous connections, although suspected since 1707, has been finally established definitely in man and in other mammals by Sucquet[14] in 1862, and by Hoyer[15] in 1877. The recognition of importance of the arteriovenous connections in physiologic and pathologic conditions is growing rapidly due to the studies of Masson and Popoff,[16] and of Lewis.[17] Recently Spanner[18] has found them in a relatively considerable quantity in renal tissue. Wright and Duryee[19] have shown that although there is some interchange of the matters through the walls of the arteriovenous anastomoses, the tissue metabolism depends on the circulation of the blood in the capillaries. It is not surprising, therefore, that when the capillary stasis develops as the result of the constriction of the renal artery or vein, the blood passes directly through the arteriovenous shunts, thus leading to the ischemia of the tissue responsible for the production of the hypertensive factor or to deficient oxidation of some very important products of tissue metabolism.

To conclude, we are inclined to believe, on the basis of our experiments, reasonings, and clinical experience, that hypertension depends upon the disturbance of the balance between the pressure on the arterial and on the venous side of the kidney. When this balance is disturbed in favor of the venous pressure, stasis probably takes place in the renal capillaries and primary renal circulation is short-circuited through arteriovenous shunts. Consequently, the tissue responsible for hypertension begins to suffer from inadequate supply of blood and production of a hypertensive substance is begun. On the other hand, we believe that when the balance between the pressure in the arterial and venous sides of the kidney is restored, the production of hypertensive substance will cease, perhaps through re-establishment of an efficient oxygenation.

REFERENCES

1. Goldblatt, H., Lynch, J., Hanzal, R. F., and Summerville, W. W.: J. Exper. Med. 59: 347, 1934.
2. Steiner, A., Weeks, D. M., and Barach, A. L.: Am. Heart J. 19: 708, 1940; according to Review of Literature, Rev. argent. de cardiol. 7: 193, 1940.
3. Corcoran, A. C., and Page, I. H.: Am. J. Physiol. 135: 361, 1941-42.
4. Mansfield, J. S., Weeks, D. M., Steiner, A., and Victor, J.: quoted by A. Blalock in "Experimental Hypertension," Physiol. Rev. 20: 159, 1940.

ing normally although with marked reduction of blood volume. In all of these cases there was rapid restoration of the blood pressure to a much lower level, a result which we attributed to the increased run-off, due to purely physical factors and increasing the massage effect of the adjacent artery and to putting the renal vein on a stretch. The soundness of this position was by no means certain, but in the later series when we operated the animals on the sound side (groups second and third) using the same technique of dislocation of the kidney in such a way as to straighten out the renal vein, it seemed more and more evident that these factors had definitely improved the runoff of the kidney. Eliminating the normal tortuosities of the renal vein and putting it somewhat on a stretch so that the rate of flow of blood in the stretched-out artery was unimpeded could be compared to the rate of flow in a river meandering through a flat plain with many curves and much friction, and a river coursing through a narrow canyon.

Opportunity was afforded to re-examine the displaced kidney and it was found that the technique used resulted in a very firm attachment. A considerable collateral circulation was established but not sufficient, in our opinion, to explain the sustained fall in blood pressure. Also, the effect was produced by displacing the opposite kidney, not the one responsible primarily for hypertension.

Discussion.—In our opinion the results of our experiments are confirmed by the clinical experience of McCann and Romansky[10] and of Riskind and Greene[11] who have established that the hypertension which accompanies the renal ptosis or renal torsion can be actively eliminated as soon as the incorrect position of the kidney is improved by a surgical operation or by an abdominal belt. The first two mentioned authors even introduce the term of the orthostatic hypertension to designate that in these cases posture has a great influence upon the high level of arterial pressure. The decisive factor, however, in our opinion, consists not in the reduction of the lumen of the renal artery because of the renal ptosis, but in the impeding of the venous outflow in these conditions and in the fact that the restoration of the kidneys to their right place has had its effect upon arterial blood pressure through improvement of the venous return.

Further, it may well be noted that many physicians have known for a long time of the influence exercised by venous pressure upon the level of the arterial blood pressure. There are numerous observations according to which a sudden bout of circulatory decompensation brings with itself a marked rise of arterial blood pressure which falls again as soon as the circulatory balance is re-established by digitalis and other means. Sahli[12] introduced the term of "Hochdruckstauung," i.e., high blood pressure depending upon stasis in the venous part of circulation, and Gallavardin[13] speaks of the "hypertension asystolique" or high blood pressure accompanying heart insufficiency. Of course, not in all

SULFONAMIDE THERAPY IN ACTINOMYCOTIC INFECTIONS

CHAMP LYONS, M.D., CORA R. OWEN, PH.D., AND
WILLIAM B. AYERS, M.D., BOSTON, MASS.
(From the Massachusetts General Hospital, Boston)

RATHER recently, sufficient success has attended our efforts in the management of actinomycotic infections to warrant a report of our limited experience. The program of treatment combines drainage of pus, excision of infected tissue, and long-continued sulfonamide therapy.

In all cases of infection with chronic suppuration and tissue deformity a search has been made for "sulfur granules." These granules vary in size and color, the smaller ones being translucent and the larger ones yellow or even brown. Such granules occur fairly frequently in pus and too much emphasis cannot be given to Henrici's[1] statement "that the mere finding of radiating lobulated granules in pus is not sufficient evidence to establish a diagnosis of actinomycosis." It must be proved that the "granules are composed of finely branched filaments characteristic of the mycelium of the actinomyces." Confirmation of the diagnosis is frequently obtained by histologic examination of biopsy material from the abscess cavity. It is recommended that direct examination of the pus and tissue biopsy be performed in any suspected case.

Topley and Wilson[2] have proposed a classification of the actinomycetes which has facilitated accurate reporting of the infections. The true ray fungus of Wolff-Israel is a preferential anaerobe or microaerophile, now known as *Actinomyces boris.* This organism is regarded as the etiologic agent of the cervicofacial, pulmonary, and abdominal infections producing sulfur granules and classified as actinomycosis. According to Gammel,[3] the actinomycotic species isolated from Madura foot produce sulfur granules and are aerobic.

A considerable number of infections without sulfur granules or characteristic tissue deformity show mycelia without club forms in the pus and a characteristic actinomyces growth on aerobic culture. These infections are occasionally reported as streptotrichosis. Topley and Wilson[2] classify such organisms as actinomycetes and divide them into two groups: acid-fast and nonacid-fast. The acid-fast group are rarely encountered in infections of man but are characterized by their high and constant virulence for laboratory animals. They occasionally confuse the diagnosis of tuberculosis because of the marked similarity of the clinical disease and the difficulty in distinguishing the acid-fast mycelial fragments from tubercle bacilli. The nonacid-fast group is more com-

Received for publication, April 5, 1943.

5. Bruger, M., and Carter, R. F.: Am. J. M. Sc. 197: 832, 1939.
6. De Takáts, G., and Scupham, G. W.: Arch. Surg. 41: 1394, 1940; according to Selected Abstracts, Am. Heart J. 21: 536, 1941.
7. Linton, R. R., Morrison, Ph. J., Ulforder, H., and Libby, A. L.: Am. Heart J. 21: 721, 1941.
8. Weiss, S.: Personal communication.
9. Schade, H., and Wohlleben, T.: quoted by K. J. Franklin in A Monograph on Veins, Springfield, Ill., 1937, Charles C Thomas, Publisher.
10. McCann, W. S., with the collaboration of Romansky, M. J.: J. A. M. A. 115: 573, 1940.
11. Riskind, L. A., and Greene, H. H.: J. A. M. A. 119: 1016, 1942.
12. Sahli: quoted by A. M. Fishberg in Heart Failure, London, 1937, Henry Kimpton.
13. Gallavardin, L.: quoted by A. M. Fishberg.
14. Suequet, J. P.: quoted by K. J. Franklin.
15. Hoyer, H.: quoted by K. J. Franklin.
16. Masson and Popoff: quoted by Harpuder, Stien, and Byer.
17. Lewis, T.: quoted by Harpuder, Stien, and Byer.
18. Spanner, R.: quoted by C. J. Wiggers in Physiology in Health and Disease, Philadelphia, 1939, Lea & Febiger.
19. Wright and Duryee: Arch. Int. Med. 52: 545, 1933.

was tried for six weeks without apparent effect. The wound was granulating at the time of discharge two weeks after operation.

September, 1940, the patient re-entered with a draining thoracic sinus and increased chest pain and cough. Sulfathiazole therapy was started and a blood level of 4 to 6 mg. per cent was maintained. After three weeks the patient developed sensitivity to sulfathiazole and a change to sulfanilamide was made without difficulty. The dosage varied between 4 and 6 Gm. daily. The previous chest wound was revised and a paravertebral abscess of the flank was drained and curetted. The patient was sufficiently improved three weeks later to warrant discharge home. Four grams of sulfanilamide daily were prescribed.

In December, 1940, the wound had completely healed for the first time. Sulfanilamide was reduced to 2 Gm. daily.

The thoracic sinus recurred in January, 1941 and sulfanilamide was restored to 4 Gm. daily.

March, 1941, all was healed, but sulfanilamide was continued. The patient returned to work.

Sulfanilamide was omitted in June, 1941, after nine months of treatment. In October, 1942 she had the last regular semiannual checkup (all healed and symptom-free). X-ray has shown continual decrease of the size of the pulmonary scar.

Comment.—A young woman with pulmonary infection due to *A. bovis* experienced a remission of her disease as a consequence of drainage of external abscesses and sulfanilamide therapy for nine months. No recurrence was noted in the following two years.

CASE 2 (M. G. H. No. 316319).—A 46-year-old white factory worker complained, January, 1940, of right flank pain. January, 1941, following a fall, the pain increased and became constant. Shaking chills were experienced and subsequently there was limitation of motion of the right thigh.

In March, 1941, there was operative drainage of "appendical abscess" with a persistent fistula and in June, revision of abdominal sinus and persistent fistula. The total weight loss was twenty-two pounds.

The patient entered the Massachusetts General Hospital for first time, August, 1941. Physical examination revealed a moderately emaciated man with operative scars of the right flank and right lower abdomen. An abdominal sinus six inches in depth and a flank sinus four inches in depth were noted. Sulfur granules were present in the pus, tissue biopsy revealed actinomycosis, and cultures showed an anaerobic actinomyces, coagulase positive staphylococci and anaerobic non-hemolytic streptococci.

Aug. 28, 1941, a right flank dissection with excision of diseased tissue was done. Sulfadiazine therapy was started in a dosage sufficient to maintain a blood level of 8 to 12 mg. per cent (4 to 6 Gm. daily). The patient was febrile for twelve weeks. The drug was discontinued after fourteen and one-half weeks of treatment and seventeen days after the temperature returned to normal. The patient remained in the hospital for a period of six weeks after omission of the drug. The temperature remained normal and the wound was healed at the time of discharge (Feb. 21, 1942).

The patient re-entered hospital, March 6, 1942, two weeks after discharge, complaining of recurrent pain in the right flank. X-ray examination showed obliteration of psoas shadow and distortion of the ureter on the right side. A small sinus was present anteriorly with a scanty purulent discharge yielding only staphylococcus and the patient gradually improved during the next eleven weeks. He was discharged home on a dosage of 3 Gm. of sulfadiazine daily.

September, 1942, recurrent sinus was discharging sulfur granules and the patient was readmitted to the hospital for flank exploration. A considerable [illegible]

monly encountered in pus and is most apt to be confused with diphtheroids. The pathogenicity of these strains for laboratory animals is usually minimal[1] and it may be difficult to evaluate their importance in established infections of human beings.

The accurate classification of actinomyces depends upon the identification of true sulfur granules, the aerobic or anaerobic characteristics of the organisms, and the acid-fast quality of the aerobic species.

The popularity of iodides in the treatment of actinomycosis resulted from the success of iodide therapy in the veterinary control of an infection of the subcutaneous tissues of the neck of cattle due to the actinobacillus, an aerobic Gram-negative bacillus producing granules in pus. Apparently, actinobacillosis is very rare in man.[2] The ineffectiveness of potassium iodide in true actinomycosis is now quite generally recognized and the value of thymol as suggested by Myers[4] has been confirmed.[5-7] However, Wangensteen[8] believes that surgical excision of diseased tissue is of greater importance than thymol. Our own experience has been in accord with this latter opinion. The preponderance of cervicofacial cases in the group reported cured by thymol is important because the prognosis is good in the cervicofacial infections and grave in the pulmonary and abdominal lesions.[9]

Numerous authors[10-16] observed recovery from serious actinomycotic infections as a consequence of sulfanilamide therapy. The literature now contains many reports of the efficacy of the various other sulfonamide compounds in abdominal and pulmonary infections. In vitro studies[19] have determined that sulfadiazine is the drug of choice and that it has a direct effect upon aerobic and anaerobic species of actinomyces. It seems clear that continuous treatment is necessary for cure because intermittent therapy and premature omission of drug have been followed by death.[18]

The following cases are reported to emphasize the necessity for long and continuous sulfonamide administration to effect healing and maintain remission of the disease.

CASE 1 (M. G. H. No. 178903).—A single, white, 31-year-old secretary, in February, 1937, developed a painful dry cough associated with pain in the lower right chest. The cough quickly became productive of one-half cupful of yellowish sputum occasionally streaked with blood.

In February, 1939, she entered the Massachusetts General Hospital for study and was discharged with a diagnosis of chronic unilateral bronchitis. There was no evidence of tuberculosis.

The patient re-entered, July, 1939, because of a persistent cough. The discharge diagnosis was unclassified lung tumor with collapse of the right upper lobe.

In September, 1939, she re-entered for study, without new findings and again in February, 1940, re-entered with a soft tissue swelling of the right chest wall. Sulfur granules were recovered in the sputum. The chest wall abscess was incised and curetted. Anaerobic *A. bovis* were recovered from the pus. Potassium iodide

was tried for six weeks without apparent effect. The wound was granulating at the time of discharge two weeks after operation.

September, 1940, the patient re entered with a draining thoracic sinus and increased chest pain and cough. Sulfathiazole therapy was started and a blood level of 4 to 6 mg. per cent was maintained. After three weeks the patient developed sensitivity to sulfathiazole and a change to sulfanilamide was made without difficulty. The dosage varied between 4 and 6 Gm. daily. The previous chest wound was revised and a paravertebral abscess of the flank was drained and curetted. The patient was sufficiently improved three weeks later to warrant discharge home. Four grams of sulfanilamide daily were prescribed.

In December, 1940, the wound had completely healed for the first time. Sulfanilamide was reduced to 2 Gm. daily.

The thoracic sinus recurred in January, 1941 and sulfanilamide was restored to 4 Gm. daily.

March, 1941, all was healed, but sulfanilamide was continued. The patient returned to work.

Sulfanilamide was omitted in June, 1941, after nine months of treatment. In October, 1942 she had the last regular semiannual checkup (all healed and symptom-free). X-ray has shown continual decrease of the size of the pulmonary scar.

Comment.—A young woman with pulmonary infection due to *A. bovis* experienced a remission of her disease as a consequence of drainage of external abscesses and sulfanilamide therapy for nine months. No recurrence was noted in the following two years.

CASE 2 (M. G. H. No. 316319).—A 46 year old white factory worker complained, January, 1940, of right flank pain. January, 1941, following a fall, the pain increased and became constant. Shaking chills were experienced and subsequently there was limitation of motion of the right thigh.

In March, 1941, there was operative drainage of "appendical abscess" with a persistent fistula and in June, revision of abdominal sinus and persistent fistula. The total weight loss was twenty two pounds.

The patient entered the Massachusetts General Hospital for first time, August, 1941. Physical examination revealed a moderately emaciated man with operative scars of the right flank and right lower abdomen. An abdominal sinus six inches in depth and a flank sinus four inches in depth were noted. Sulfur granules were present in the pus, tissue biopsy revealed actinomycosis, and cultures showed an anaerobic actinomyces, coagulase positive staphylococci and anaerobic non hemolytic streptococci.

Aug. 28, 1941, a right flank dissection with excision of diseased tissue was done Sulfadiazine therapy was started in a dosage sufficient to maintain a blood level of 8 to 12 mg. per cent (4 to 6 Gm. daily). The patient was febrile for twelve weeks. The drug was discontinued after fourteen and one half weeks of treatment and seventeen days after the temperature returned to normal. The patient remained in the hospital for a period of six weeks after omission of the drug. The temperature remained normal and the wound was healed at the time of discharge (Feb. 21, 1942).

The patient re entered hospital, March 6, 1942, two weeks after discharge, complaining of recurrent pain in the right flank. X ray examination showed obliteration of psoas shadow and distortion of the ureter on the right side. A small sinus was present anteriorly with a scanty purulent discharge yielding only staphylococcus and the patient gradually improved during the next eleven weeks He was discharged home on a dosage of 3 Gm. of sulfadiazine daily.

September, 1942, recurrent sinus was discharging sulfur granules and the patient was readmitted to the hospital for flank exp

granulation tissue was excised. The wound was closed anteriorly and drained posteriorly. The patient continued on sulfadiazine, 3 Gm. daily.

By December, 1942, the wound was entirely healed. Sulfadiazine was reduced to 2 Gm. daily.

Two sinuses appeared in the right flank in February, 1943. The patient was placed on 4 Gm. of sulfadiazine daily, but was not yet able to resume work after a disability period of three years. He was improved, but not cured.

Comment.—This patient had a true *A. bovis* infection of the right flank. The portal of entry was unknown. The infection was widespread and severe. Complete excision of the disease was impossible. Sulfadiazine therapy appeared to aid in the control of constitutional symptoms and to accelerate local healing. In spite of two years of sulfonamide therapy the patient continued to have local recurrence of the disease.

CASE 3 (M. G. H. No. 341910).—A 32-year-old white married carpenter noted, in September, 1941, a painful swelling of the left side of the face. Five teeth were extracted without relief. The left antrum was explored, in December, and the left temporomandibular joint was drained.

January, 1942, the left cheek was incised. A draining sinus was found. Severe chills were experienced on three occasions.

In February, 1942, the patient entered the Massachusetts General Hospital because of persistent draining sinus and increasing pain and swelling of the left side of the face. Physical examination revealed extensive inflammatory deformity of the soft tissues of the left side of the face and neck. The mandible was not involved. Sulfur granules were present in the pus and anaerobic *A. bovis* and coagulase negative staphylococci were cultured. Tissue biopsy showed acute inflammation. The patient was started on sulfadiazine and the abscess of the left face was drained at the angle of the jaw. Five weeks later the patient was entirely healed and symptomless. He was discharged home on 4 Gm. of sulfadiazine daily.

By September, 1942, there was no evidence of recurrence. Sulfadiazine was stopped after seven months of treatment.

Inflammation and sinuses recurred, November, 1942, ten weeks after the last dose of sulfadiazine. Drug therapy was resumed for one month with regression of the disease. His condition was apparently quiescent through the month of March.

Comment.—A cervicofacial infection with *A. bovis* showed an immediate favorable response to simple drainage and sulfadiazine therapy. Omission of sulfadiazine after seven months was promptly followed by a recurrence of the disease. This recurrence responded to sulfadiazine therapy.

CASE 4 (M. G. H. No. 376717).—A 24-year-old single white garage mechanic had had drainage of an appendical abscess at the age of 16. In 1939 he had an appendectomy with primary healing of the wound.

The patient developed, in 1940, a productive cough and the abdominal wound reopened and drained pus. He was admitted to tuberculosis sanatorium for treatment. Thoracentesis and sputum studies were negative for tubercle bacilli on smear and in guinea pigs.

A right thoracic sinus developed in July, 1941, and shortly thereafter multiple sinuses appeared over both sides of the thoracic cage.

The patient was admitted to the Massachusetts General Hospital in September, 1942, with draining sinuses of both chest walls and a right lower abdominal sinus. The diagnosis of abdominal and pulmonary actinomycosis with amyloid disease was established. Sulfur granules and anaerobic actinomyces were found. Sulfadiazine therapy was instituted and the patient was sufficiently improved in three weeks to return to sanatorium care.

March, 1943, after five months of treatment, the patient had gained thirty-five pounds and was working. The sinuses were healing slowly but there was still some purulent discharge containing sulfur granules.

Comment.—A patient with widespread *A. boris* infection of the lungs, chest wall, and abdomen made a dramatic initial improvement upon sulfadiazine therapy. The disease was so widespread that surgical excision was impossible.

CASE 5 (M. G. H. No. 282458).—A 33-year-old white housewife had (April, 1942) an indolent abscess on the left arm. In June, 1942, there were tenderness and induration of the right buttock without history of trauma.

Excision and successful primary suture of the abscess of the left arm was done July, 1942. One week later a fluctuant abscess of the right buttock was drained. This failed to heal.

July 13 to 21, 1942, sulfadiazine therapy with a blood level of 12 mg. per cent produced marked improvement of the wound of the buttocks. In October, 1942, there was revision of the wound of the buttocks for persistent suppuration.

November, 1942, the patient first entered Massachusetts General Hospital for persistent abscess of the buttock. There were no sulfur granules. Cultures demonstrated an abundance of aerobic, nonacid-fast actinomyces and coagulase positive *Staphylococcus aureus*. A biopsy showed abscess formation without evidence of specific infection. At operation the abscess cavity was opened widely and found to lie superficial to the deep fascia. Dakinization was instituted.

By Jan. 5, 1943, the wound was granulating and covered with a grayish film from which the aerobic actinomyces was recovered. Sulfadiazine was started. During the next month the wound improved considerably on the program of local Dakin's irrigation and general sulfadiazine in a dosage of 4 Gm. daily. The actinomyces disappeared.

The secondary closure of the wound was done Feb. 5, 1943, and Feb. 22, the patient was ready for discharge.

Comment.—An infection of the subcutaneous fat of the buttocks due to an aerobic, nonacid-fast actinomyces showed complete remission of the disease only after sulfonamide therapy was instituted.

DISCUSSION

Sulfonamide therapy has supplemented the surgical management of five patients infected with actinomyces. The etiologic agent was an anaerobic *A. boris* in four patients: one cervicofacial, one pulmonary, one pulmonary and abdominal, and one abdominal infection. An aerobic nonacid-fast actinomyces was found in another patient with an abscess of the buttocks. In every instance clinical improvement was noted within the first three weeks of sulfonamide treatment. This improvement was not maintained unless the sulfonamide was continued for a considerably longer period of time. Nine months of treatment with 4 Gm. daily produced healing for two years in one patient. Other patients treated with smaller doses for equal or longer periods of time showed recurrent abscesses and fistulous sinuses, but all patients appear improved.

It is our impression that the dramatic initial response of these infections to sulfonamides is somewhat misleading. The drugs induce a remission and apparently diminish the intensity of the recurrence but it can hardly be claimed that the disease has been completely cured. The inference as to the necessity of surgical excision of the infection is clear.

Until more effective therapeutic agents are available it is felt that the incidence of complete remission will reflect the surgeon's ability to excise all the infected tissue.

CONCLUSIONS

1. Sulfonamide therapy in a dosage of 4 Gm. daily over a period of months has induced striking remissions in aerobic and anaerobic actinomycotic infections of all clinical types.

2. The induced remission is characterized by the recurrence of localized abscesses and fistulous tracts which tend to heal under continued drug therapy.

3. Surgical excision of all the infected tissue is the most effective treatment of the disease.

4. Sulfonamide therapy is a valuable adjuvant to the surgical management of actinomycotic infections.

REFERENCES

1. Henrici, A. T.: Molds, Yeasts, and Actinomycetes, New York, 1930, John Wiley & Sons, Inc.
2. Topley, W. W. C., and Wilson, G. S.: The Principles of Bacteriology and Immunity, Ed. 2, Baltimore, 1937, William Wood & Company.
3. Gammel, J. A.: Etiology of Maduromycosis With Mycologic Report on Two New Species Observed in the United States, Arch. Dermat. & Syph. 15: 241, 1927.
4. Myers, H. B.: Thymol Therapy in Actinomycosis, J. A. M. A. 108: 1874, 1937.
5. Etter, L. E., and Schumacher, F. L.: Pulmonary Actinomycosis: Recovery After Thymol Therapy, J. A. M. A. 113: 1023, 1939.
6. Bancroft, F. W., and Stanley-Brown, M.: The Treatment of Actinomycosis With Thymol, Ann. Surg. 108: 910, 1938.
7. Joyce, T. M.: Thymol Therapy in Actinomycosis, Ann. Surg. 108: 910, 1938.
8. Wangensteen, O. H.: In discussion of Joyce, T. M.: Thymol Therapy in Actinomycosis, Ann. Surg. 108: 915, 1938.
9. Davis, M. I. J.: Analysis of Forty-Six Cases of Actinomycosis With Special Reference to Its Etiology, Am. J. Surg. 52: 447, 1941.
10. Miller, E. M., and Fell, E. H.: Sulfanilamide Therapy in Actinomycosis, J. A. M. A. 112: 731, 1939.
11. Walker, O.: Sulphanilamide in the Treatment of Actinomycosis, Lancet 1: 1219, 1938.
12. Poulton, E. P.: In section of medicine with section of therapeutic and pharmacology, joint discussion No. 1: Discussion on the Treatment of Bacterial Disease With Substances Related to Sulphanilamide, Proc. Roy. Soc. Med. 31: 163, 1937.
13. Jorge, J. M., Browne, A. M., and Mealla, E. S.: Tratamiento de la actinomicosis cérvico-facial (communicacion previa), Biol. y. trab. de la Soc. de cir. de Buenos Aires 22: 1002, 1938.
14. Sudler, M. T., and Johnson, C. B.: Treatment of Actinomycosis With Sulfanilamide—Report of Two Cases, J. Kansas M. Soc. 40: 330, 1939.
15. Ogilvie, W. H.: Abdominal Actinomycosis Treated With Sulphapyridine, Brit. M. J. 2: 254, 1940.
16. Dobson, L., Holman, E., and Cutting, W.: Sulfanilamide in the Therapy of Actinomycosis, J. A. M. A. 116: 272, 1941.
17. Christopher, F., and Karabin, J. E.: Abdominal Actinomycosis: Recovery Following Surgical Treatment and Use of Zinc Peroxide and Sulfanilamide, Am. J. Surg. 50: 371, 1940.
18. Dorling, G. C., and Eckhoff, N. L.: Chemotherapy of Abdominal Actinomycosis, Lancet 2: 707, 1940.
19. Cutting, W. C., and Gebhardt, L. P.: Inhibitory Effects of Sulfonamides on Cultures of Actinomyces Hominis, Science 94: 568, 1941.

SOLITARY EOSINOPHILIC GRANULOMA

Report of a Case

Graham A. Kernwein, M.D., and Frank B. Queen, M.D., Chicago, Ill.
(From the Department of Bone and Joint Surgery, Northwestern University, and Passavant Memorial Hospital)

SOLITARY eosinophilic granuloma is an uncommon benign destructive bone lesion of which only nineteen cases were reported in the medical literature. Although the lesion presents a distinct microscopic pathologic picture, the pathogenesis has not been established. Significant clinical data from the various cases are presented in Table I.

Clinical data are meager. The reports, however, demonstrate the condition to be most prevalent in the adolescent and young adult male. The presenting complaint was swelling, pain, or both. The lesions were solitary and twelve of the nineteen cases preferred the skull or ribs. Treatment consisted of surgery, alone or combined with roentgen therapy, but as none of the patients succumbed to the disease the x-ray therapy was probably of no benefit. In this report the lesion, treated by partial ostectomy and curettage, healed promptly. The patient, twenty-eight months later, was alive and well.

F. W., a white male, 20 years of age, while lifting a heavy sack, was seized with severe pain in his right groin. Examination revealed no cause for the pain. Intermittently, for about three weeks, he suffered with quadriceps muscle spasm. Pain in the hip gradually increased in duration and severity so that after two months it kept him awake at night. He also lost twenty-five pounds in weight. His temperature was normal.

Physical examination revealed a tall, muscular, white male without significant findings, but who looked ill.

Laboratory findings: Blood—R.B.C., 5,150,000; Hb., 15 Gm.; W.B.C., 7,650. Differential count: polymorphonuclear neutrophiles, 68; eosinophiles, 5; basophiles, 1; lymphocytes, 16; monocytes, 10. Calcium, 11.1 mg.; phosphorus, 3.22 mg.

Urine—Specific gravity, 1.020; albumin, negative; sugar, negative; leucocytes, occasional; and epithelium, ++.

Roentgenologic studies of the pelvis and left hip showed an irregular region of decreased density at the upper end of the femur, mesial and inferior to the lesser trochanter (Fig. 1). Films of the leg in internal rotation revealed the shadow of a thin strip of periosteal new bone (Fig. 2). No other lesions were found in studies of the chest and remainder of the skeleton.

One week after hospitalization, the upper end of the femur was exposed through a lateral incision. Grossly the bone appeared normal. A window was cut in the cortex and the underlying pink-gray, succulent marrow removed for biopsy. A

Received for publication, Nov. 30, 1942.



Fig. 1.—Roentgenogram of left hip. Just mesial and inferior to the lesser trochanter there is an irregularly shaped region of decreased density (A).

Fig. 2.—Roentgenogram of left hip in internal rotation showing periosteal new bone (A).

TABLE I

AUTHOR	SEX	AGE	BONE INVOLVED	DURATION OF SYMPTOMS	PRESENTING COMPLAINT	TEMPERATURE	LOSS OF WEIGHT	TREATMENT
Bass[1]	M.	4	skull	5 wk.	swelling, no pain, no inflammation		no	
	M.	12	rib		pain in chest	100.5	no	
Finzi[2]	M.	15	frontal					
	M.	11	skull	9 wk.				
Hatcher[3]	F.	8	humerus	2 mo.				
	F.	2	distal radius	1 mo.				
Kernwein and Queen	M.	20	upper left femur	2 mo.	severe pain	98.6	25 lbs.	complete local removal
Lichtenstein and Jaffe[4]	F.	4	upper left femur	2 wk.	swelling and pain	99.0 to 100.6		surgery and x-ray
Mallory[5]	M.	24	rib	2 yr.	pain in back			
Mignon[6]	M.	12	frontal					
	M.	11	rib	2 mo.	pain	101.0		surgery x-ray
Otani and Ehrlich[7]	F.	7	scapula	2 wk.	pain	99.2 to 100.6		surgery x ray
	F.	15	rib	several wk.	swelling			surgery x-ray
		35	rib skull sternum mastoid					
Schairer[8]	M.	9	parietal					
	M.	10	parietal					

diagnosis of solitary eosinophilic granuloma was made. One week later the wound was reopened and marrow from the upper third of the femur removed. The wound healed by primary intention and the postoperative course was uneventful.

The pain was relieved immediately. When he returned to work three months later, the patient had gained twenty two pounds in weight and there was definite healing of the bone lesion (Fig. 3). Twenty eight months later he was well and the operative defect in the femur was largely replaced with new bone (Fig. 4).

Microscopic examination of the tissues removed and stained with hematoxylin and eosin revealed that most of the cancellous bony trabeculae had been destroyed The marrow cavity was filled with a compact fibrous type of granulation tissue; disseminated throughout were isolated well encapsulated granulomas (Fig 5). Myriads of eosinophilic polymorphonuclear leucocytes arranged in sheets and cords with very little supporting stroma composed the most conspicuous feature of these granulomas. Interspersed throughout were numerous large polygonal cells with abundant pale cytoplasm and poorly outlined cell membrane (Fig. 6). They contained large oval or kidney shaped nuclei with occasional mitotic figures In older lesions many of the cells were fused to form multinucleated giant cells. Phagocytized eosinophilic leucocytes were present in some; in others the cytoplasm appeared vacuolated (Fig 7). Although most of the bony trabeculae had been destroyed, some newly formed bone was present on the surface of the few remaining spicules There were no areas of necrosis

Fig. 4.—Eighteen months after operation the bony contour is essentially restored. There is no evidence of recurrence of the disease.



Fig. 3.—Three months after operation the operative defect in the cortex is visible (*A*). Increased density of the bone throughout the operative site (*B*) attests that the lesion is healing.

In differentiating this condition from other granulomas, the phagocytic properties of the giant cells are perhaps the most significant and salient feature. Necrosis is absent and the giant cells are not of

Fig. 5.

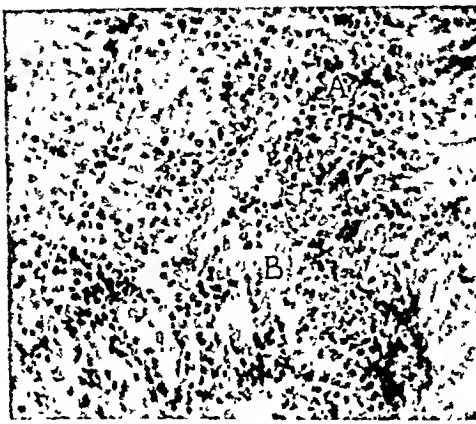

Fig. 6.

Fig. 5.—The granuloma (*A*) is surrounded by a compact type of fibrous tissue (*B*) in the meshes of which lie isolated spicules of bone (*C*). The closely packed eosinophiles comprise the dark-staining portions of the granuloma; the lighter regions are made up mostly of large pale-staining mononuclear cells (×65).

Fig. 6.—The clusters of small dark cells seen in region (*A*) are eosinophilic granulocytes. Interspersed among the eosinophiles as in region (*B*) there are clusters of large pale cells with poorly outlined cell membranes and huge oval or kidney-shaped nuclei (×310).

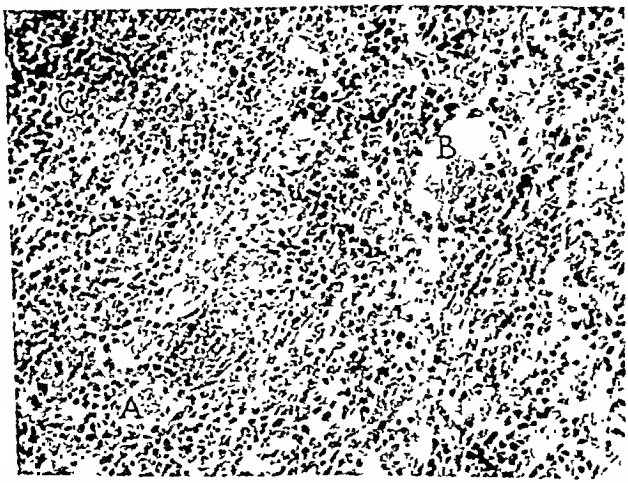

Fig. 7.—A region of the granuloma containing numerous multinucleated giant cells (*A*) formed by the fusion of the endothelial cells seen in (*B*) of Fig. 6. Some of the multinucleated giant cells (*B*) are phagocytic. The clusters of small dark cells seen in region (*C*) are polymorphonuclear leucocytes (×310).

the typical Langhans type. Therefore, tuberculosis is ruled out and the postoperative course does not resemble that of tuberculosis of the bone. Eosinophiles would be an extraordinary finding in syphilis. *Bacillus melitensis* infection is not ruled out histologically; clinically, however, the patient had no fever, weight loss occurred, lassitude disappeared following the operation, and the opsonocytophagic index, skin and agglutination tests were negative. The condition could be mistaken for Hodgkin's disease but against this are the phagocytic properties of the giant cells, the absence of involvement of the lymphatic system, and recovery with operation. The condition is incompatible with Schüller-Christian's disease clinically because of the single lesions and the universally favorable course.

REFERENCES

1. Bass, M. H.: Solitary Eosinophilic Granuloma of Bone, Am. J. Dis. Child. 61: 1254-1262, 1941.
2. Finzi, O.: Mieloma con prevalenza delle cellule eosinofile, circoscritto all'osso frontale in un giovane di 15 anni, Minerva med. 9: (pt. 1) 239-241, 1929.
3. Hatcher, Howard: To be published.
4. Lichtenstein, L., and Jaffe, H. L.: Eosinophilic Granuloma of Bone, With Report of Case, Am. J. Path. 16: 595-604, 1940.
5. Mallory, T. B.: Case Records of the Massachusetts General Hospital; Cabot Case No. 26302, New England J. Med. 223: 149-152, 1940.
6. Mignon, F.: Ein Granulationstumor des Stirnbeins, Fortschr. a. d. Geb. d. Röntgenstrahlen 42: 749, 1930.
7. Otani, S., and Ehrlich, J. C.: Solitary Granuloma of Bone Simulating Primary Neoplasm, Am. J. Path. 16: 479-490, 1940.
8. Schairer, E.: Ueber eine eigenartige Erkrankung des kindlichen Schädels, Zentralbl. f. allg. Path. u. path. Anat. 71: 113-117, 1938.

A STUDY OF THE PHYSICAL FACTORS CONCERNED IN INFLAMMATION

III. The Fixation of Bacteria in Inflamed Tissues*

Carroll J. Bellis,† M.D., Ph.D., Atlanta, Ga.

INTRODUCTION

WHATEVER physical factors appear to function in the inflammatory process, it appears that the development of immunity in an individual is, to a large extent, inherent in the cellular morphology itself. Nor can all the events in the inflammatory process be explained by the tendency of microorganisms to disseminate from an original focus of infection. However, no consideration of inflammation is complete unless the constitution of the tissues themselves is analyzed—a constitution built of the local reticulum and embodying those characteristics peculiar to cells: phagocytosis and antibody formation. Hand in hand with the establishment and increase in local inflammation there is a stimulation of new cellular activity called resistance, and it is this very resistance which is responsible for the enmeshing of colloidal particles and bacteria introduced locally or generally.

Fixation of Dyes and Bacteria.—It has long been known that if a part of an animal is injured, as by previous heating or injection of an irritant, subsequent intravenous injection of bacteria or colloidal dye will result in the latter's concentration in the inflamed area (Charrin;[9] Chesney, Turner, and Halley;[10] Eckstein and von Möllendorff;[11] Lurie;[20] Ramsdell;[34] Rich;[35] Rigdon;[36] Menkin;[25] Bowman, Winternitz, and Evans;[6] Lewis;[19] MacCurdy and Evans;[21] McClellan and Goodpasture;[23] McJunkin;[24] Okuneff;[30] Quednau;[33] Rous, Gilding, and Smith;[38] Schmidt;[41] Seyderhelm and Lampe;[45] Shmidzu;[46] Siengalewicz;[48] Winternitz and Hirschfelder[52]).

This phenomenon has been widely and thoroughly studied. If a filtrate of *Bacillus typhosus* is injected into a rabbit's skin, followed later by an intravenous injection of any bacterial filtrate, a local necrosis at the previous injection site occurs (Schwartzman[43]). In essence, there is a hyperimmunity at the previous injection site which is nonspecific (Calmette and Guerin;[7] Aner;[3] Bordet;[5] Cannon and Pacheco;[8] Falchetti and Carlinfanti;[12] Fox;[13] Freund;[14] Frisch;[15] Gerber;[16] Miller;[26] Moritz;[27] Noetzel;[29] Rivers and Tillett;[37] Ruffer;[39] Sager and Michel;[40] Seegal and Seegal;[44] Sickles;[47] Wadsworth;[50] and Willis[51]).

The localization is due to phagocytosis of the intravenously injected material or only absorption by the local histiocytes. Overloading the

*Section of a thesis submitted to the Graduate Faculty of the University of Minnesota, Minneapolis, in partial fulfillment of the requirements for the degree of Doctor of Philosophy in Surgery.

Received for publication, Nov. 20, 1942.

†Now at Lawson General Hospital, Atlanta (U. S. Army Medical Corps).

organism with intravenous dye may so involve the reticulo-endothelium that a so-called reticulo-endothelial blockade may result, allowing subsequent infection to progress unchecked (Adler and Singer;[1] Anitschkow;[2] Bickhardt;[4] Goldmann;[17] Higgins and Murphy;[18] Manwaring and Fritschen;[22] Nissen;[28] Petroff;[32] Schulemann;[42] and Stilwell[43]).

Statement of the Problem.—If there is a mechanical isolation of organisms by inflamed tissues, as Menkin has demonstrated, the isolation should be capable of demonstration by culture of inflamed and non-inflamed areas in the same animal after intravenous inoculation. It was proposed to study this phenomenon and the fixation of intravenously injected dyes.

METHODS AND EXPERIMENTS

Fixation in Traumatized Areas.—

Localization of dyes: In each of two rabbits, 0.2 c.c. of croton oil was injected subcutaneously in each ear. Twenty-four hours later, in one animal, multiple circumferential injections of 2 per cent aqueous trypan blue were made around the lesion in the left ear, and 0.1 c.c. of trypan blue injected directly into the lesion in the right ear. In the second animal, India ink was used in the same manner as was trypan blue.

Another rabbit was etherized and a hind extremity immersed in water at 60° C. for one minute. The following day 5 c.c. of 2 per cent trypan red solution were injected into the inflamed area. Heart serum samples were examined for dye at 0, 1, 2, 3, 4, and 6 hours. A control animal (uninflamed) received a similar subcutaneous injection and was similarly studied. The urine from each animal was also inspected for the presence of trypan red.

In another rabbit with a leg inflamed by heat as above, 5 c.c. of 1 per cent indigo carmine were injected into the burned area. Heart serum samples taken at 0, 1, 2, 3, 4, and 6 hours and urine samples were examined for dye.

In another series of animals, the fixation by inflamed areas of trypan blue injected intravenously was studied. The right hind extremity of an etherized 250 Gm. rat was heated in water at 60° C. for one minute. Four hours later, 0.5 c.c. of 2 per cent aqueous trypan blue solution was injected into the heart. Twenty-four hours after the burn, both hind extremities were compared for coloration.

In a rabbit, the right ear and right leg subcutaneous tissues were injected with 0.2 c.c. of croton oil. Four hours later, 4 c.c. of 2 per cent aqueous trypan blue were injected into an ear vein. The animal was sacrificed 24 hours later, and the inflamed members compared with the control sides. In addition, the volumes of the ears and legs were determined by the water displacement method.

In each of two other rabbits, inflammation of an ear and leg was induced by heating at 60° C. for one minute followed by intravenous

injection of 4 c.c. of 2 per cent aqueous trypan blue solution 4 hours later. Both animals were sacrificed 24 hours later, and the inflamed members compared with the other side. In one animal, volumes of the burned and normal members were determined. In the other animal, edema fluid protein, blood plasma protein, and tissue pressure were determined.

Localization of bacteria: Pawlowsky[31] found that after subcutaneous injection, bacteria may be found in the blood in 15 minutes and in the internal organs in 30 minutes. He used *Staphylococcus aureus* and *Staph. citreus, B. pyocyaneus,* and the *Staph. pyogenes.* If he injected the organisms intravenously after fractures, he found the bacteria localized in the fracture sites.

In this series of experiments it was determined to study the localization of intravenously injected bacteria in previously inflamed areas. In general, in a series of 102 rabbits, one leg of each was burned under ether anesthesia, and the following day a culture of bacteria was injected into an ear vein. Blood cultures were made immediately after the injection and at the time of sacrifice. When the animals were sacrificed, cultures were also made of the edema fluid and subcutaneous tissues of the burned side, the subcutaneous tissue of the nonburned extremity and of the spleen (and, occasionally, liver).

The organisms used for these experiments were: *Streptococcus viridans,* 33 rabbits; *Str. hemolyticus,* 16 rabbits; *Pneumococcus, type I,* 14 rabbits; *Staph. aureus,* 16 rabbits; *B. pyocyaneus,* 8 rabbits; *B. prodigiosus,* 7 rabbits; and *B. coli,* 8 rabbits.

Trauma was produced by heat in every experiment except one. In this exceptional experiment, it was done by subcutaneous injection of a 50-50 mixture of alcohol-acetone. For each experiment (one organism being used in each experiment) 7 rabbits were usually used. In each animal, one lower extremity was depilated with barium sulfide, the animal anesthetized with ether, and the depilated extremity immersed in water at 60° C. for one minute.

The following day, 0.5 to 1.0 c.c. of a broth suspension of the organism (the bacterial count having been made previously) was injected into an ear vein using a tuberculin syringe fitted with a No. 25 gauge hypodermic needle. One uninflamed extremity was present in each animal. The anterior chest wall having been depilated just before injection, two minutes after the injection a heart blood culture was made to verify the presence of bacteria in the circulating blood.

One rabbit was then sacrificed by a blow over the occiput (ether being avoided because of its intravital bacteriostatic action) usually at the end of 5 minutes, 15 minutes, 30 minutes, 1 hour, 2 hours, and 3 hours. Immediately after sacrifice, the abdominal skin was reflected and the superficial muscles iodized by pouring full strength tincture of iodine over the area. The abdomen was slit open through a long incision with

sterile instruments, the same instruments being used to hold the spleen out of the wound and the intestine to one side; then with a sterile syringe and needle, inferior vena cava blood was aspirated for culture, following which a piece of the spleen or liver was resected for culture. Inferior vena cava blood was taken instead of performing a second cardiac aspiration in order to avoid contamination of the second culture by bacteria present along the first needle tract in the pectoral muscles.

The nontraumatized extremity was then depilated with barium sulfide, washed, flushed with alcohol, followed by 0.9 per cent sodium chloride solution, and a sample of subcutaneous tissue excised for culture as a control. The burned side was gently cleaned with water, flushed with 70 per cent alcohol, and a sterile 0.9 per cent sodium chloride solution, following which a sample of the subcutaneous tissue was excised with sterile instruments for culture. In some cases, edema fluid was aspirated first with a tuberculin syringe and hypodermic needle and cultured. In other cases, the edema fluid which welled up into the incision was aspirated with a sterile pipette and cultured. All cultures were made in blood agar (rabbit blood) in Petri dishes at 38° C. In several animals, pieces of the liver and spleen and bits of the inflamed subcutaneous tissue were sectioned and photomicrographs made.

RESULTS

Trypan blue and India ink injected into inflammatory lesions tend to stay in those areas. If injected into the peripheral normal tissue, diffusion does not take place readily into the lesion (Table I, *A*). Trypan red and indigo carmine readily diffuse out of inflammatory sites and are found in the blood and urine (Table I, *B*).

TABLE I

PERMEABILITY OF INFLAMMATORY SITES TO DYES INJECTED LOCALLY IN RABBITS

DYE	INJECTED INTO LESION	INJECTED AROUND LESION
A. Croton oil inflammation:		
Trypan blue	not diffused	not diffused
India ink	not diffused	diffused into lesion
	APPEARANCE IN URINE	APPEARANCE IN BLOOD
B. Heat inflammation:		
Control (not inflamed)	trace	heavy
Trypan red into burned area	none	heavy (also heavy at injection site)
Indigo carmine	heavy	none (also fairly heavy at injection site)

If trypan blue is injected directly into the circulation, it is retained by inflamed tissues, which become colored with the dye (Table II).

Since extreme difficulty was encountered in aspirating enough cardiac blood for culture, rats were not used, rabbits being employed instead. Aspiration of edema fluid for culture was found to compare favorably

TABLE II

FIXATION BY INFLAMMATORY SITES OF INTRAVENOUSLY INJECTED TRYPAN BLUE

ANIMAL	TYPE OF INFLAMMATION	CONTROL LEG	BURNED LEG	CONTROL EAR	BURNED EAR
Rat	heat	unstained	blue	—	—
Rabbit	croton oil	unstained	blue	unstained	blue
		(Volume increase of ear: 10 c.c. Volume increase of leg: 10 c.c.)			
Rabbit	heat	unstained	blue	unstained	blue
		(Volume increase of ear: 20 c.c. Volume increase of leg: 70 c.c.)			
Rabbit	heat	unstained	blue	unstained	blue
		(Control plasma proteins: 4.5% Edema fluid proteins: 2.5%) (Subcutaneous tissue tension control: 2 mm. Hg Subcutaneous tissue tension, burned: 34 mm. Hg)			

with excision of tissues. Culture of the tissue itself may be positive where corresponding edema fluid is negative in the case of minimal infection. All cultures were usually counted in 48 hours, when the number of colonies appeared to reach a maximum.

Generally, intravenously introduced organisms, provided that the injected number is not overwhelming, are rapidly cleared from the blood, the blood cultures becoming negative within 15 minutes after the injection. At the same time, the reticulo-endothelial structures(spleen and liver) take up the organisms. The sterile blood apparently becomes re-inoculated after a variable time (usually after 2 hours) unless the injected dose of bacteria is small. Thus, in Table III, *C*, it can be seen that blood cultures after intravenous injection of pneumococci are positive within the first few minutes, but are negative from then to 3 hours. After that, organisms are constantly found in the blood, at least up to 5 days, when the experiment was discontinued.

Virulent organisms such as *Str. hemolyticus* are difficult to clear from the blood, but if the virulence is reduced by repeated subculture (Table III, *B*), the blood can be cleared rapidly, even when a greater number of organisms is intravenously injected.

Contamination in these experiments is invited by the nature of the trauma, air bacteria being the most common contaminants. *B. coli* is a frequent offender, and its presence in the burned tissues of uninjected rabbits testifies as to its prolific nature.

As demonstrated in previous experiments with intravenously injected trypan blue, intravenously injected bacteria have as great a predilection for traumatized areas as for reticulo-endothelium. Organisms are readily cultured from the traumatized subcutaneous tissues, while the control normal subcutaneous tissues of the same injected rabbits show no growth of the injected organism on culture (Table III).

DISCUSSION

The Local Defense Reaction.—Slowly spreading bacteria in tissues are probably arrested by local blockade or bacteriolysis. Inflammation stim-

TABLE III

LOCALIZATION OF INTRAVENOUSLY INJECTED BACTERIA IN PREVIOUSLY TRAUMATIZED AREAS IN RABBITS; RESULTS OF CULTURES OF BLOOD, TRAUMATIZED AND NON TRAUMATIZED AREAS (SUBCUTANEOUS TISSUES), LIVER, AND SPLEEN

NO. INJECTED	TISSUE	TIME OF OBSERVATION						
A. Str. viridans:								
46,000,000		2 min.	5 min	15 min.	30 min.	1 hr.	2 hr.	4 hr.
	inflamed	0	0	0	0	0	0	innum
	normal	0	0	0	0	0	0	0
	liver	innum	98	348	165	67	524	--
	spleen	--	innum	1342	16	10	98	29
	blood	innum	1520	0	0	0	0	0
4,500,000,000		2 min.	6 min.	9 min.	15 min.	20 min.	40 min	1 hr.
	inflamed	--	0	innum	92	0	innum	innum
	normal	--	0	0	0	0	0	0
	liver	--	innum	innum	innum	innum	innum	innum
	spleen	--	innum	innum	innum	2056	innum	innum
	blood	innum	innum	innum	194	innum	1005	120
80,000,000		2 min.	5 min.	15 min	30 min.	45 min	1 hr.	1½ hr. 2 hr.
	inflamed	--	276	--	140	0	65	205 450
	normal	--	0	0	0	0	0	0 0
	liver	--	--	--	--	--	--	-- --
	spleen	--	0	0	0	0	0	0 innum
	blood	innum	innum	0	0	0	0	0 0
	edema fluid	--	244	--	0	21	43	290 98
B. Str. hemolyticus:								
77,000,000		2 min.	5 min.	15 min	30 min	1 hr.	2 hr.	3 hr.
	inflamed	--	innum	innum	innum	innum	innum	innum
	normal	--	2	0	0	0	0	109
	spleen	--	5	10	0	23	5	23
	edema fluid	--	innum	innum	innum	innum	innum	innum
	blood	658	198					
		278		36				
		9			15			
		320				0		
		35					24	
		25						228
360,000,000								
	inflamed	--	innum	innum	innum	innum	169	innum
	normal	--	0	0	0	0	0	0
	spleen	--	83	--	innum	innum	3	0
	edema fluid	--	235	innum	innum	innum	0	innum
	normal fluid	--	0	0	0	0	0	0
	blood	innum	73	0	0	0	0	0
C. Pneumococcus, Type I.								
46,000,000		2 min	5 min.	15 min	30 min	1 hr.	2 hr.	3 hr.
	inflamed	--	0	0	0	0	--	0
	normal	--	0	0	0	0	--	0
	liver	--	50	11	5	0	--	innum
	spleen	--	54	1	60	0	--	innum
	edema fluid	--	0	0	0	0	--	0
	blood	innum	682	0	0	0	--	innum
60,000,000		2 min.	1 day	2 days	3 days	4 days	5 days	
	inflamed	--	innum	innum	innum	18	--	
	normal	--	0	0	0	0	0	
	spleen	--	innum	innum	62	3	0	
	edema fluid	--	innum	innum	innum	innum	--	
	blood	innum	innum	innum	innum	innum	11	

Innum = innumerable

TABLE III—CONT'D

NO. INJECTED	TISSUE	TIME OF OBSERVATION						
D. Staph. Aureus:								
—		2 min.	5 min.	15 min.	30 min.	1 hr.	2 hr.	3 hr.
	inflamed	--	innum	150	5	14	innum	innum
	normal	--	0	0	0	0	0	0
	spleen	--	143	145	18	120	25	19
	edema fluid	--	0	158	0	43	240	0
	blood	innum	332	0	21	0	0	0
E. B. Pyocyaneus:								
50,000,000								
	inflamed	--	innum	3	23	innum	45	innum
	normal	--	0	0	0	0	0	0
	edema fluid	--	innum	36	40	innum	8	innum
	spleen	--	16	25	8	1	3	8
	blood	innum	17	0	0	0	0	0
F. B. Prodigiosus:								
120,000,000								
	inflamed	--	0	0	0	0	0	0
	normal	--	0	0	0	0	0	0
	edema fluid	--	0	0	0	0	0	0
	spleen	--	90	43	93	92	27	51
	blood	innum	11					
		37		0				
		78			8			
		25				1		
		7					0	
		18						1
50,000,000								
	inflamed	--	innum	15	innum	103	--	235
	normal	--	0	0	0	0	--	0
	edema fluid	--	innum	123	innum	0	--	innum
	spleen	--	0	7	4	6	--	2
	blood	50	24					
		55		0				
		26			0			
		88				0		
		60						0
G. B. Coli:								
45,000,000								
	inflamed	--	77	350	10	82	50	innum
	normal	--	0	0	0	0	0	0
	normal fluid	--	0	0	0	0	0	0
	edema fluid	--	0	0	0	0	50	75
	spleen	--	9	15	6	3	1	0
	blood	innum	52	0	0	0	0	0
		388						0

ulates the normal reticulum to phagic activity, the reticular cells becoming quite like reticulo-endothelium, engulfing intravenously introduced dyes and bacteria In addition, there takes place a sort of valve-like action in the inflamed edematous tissues, particles are admitted but not so readily released. Bacteria or colloidal dyes can enter the area by way of the damaged capillaries, but become mechanically enmeshed by the fibrin of the edematous tissues and the coagulated matrix. Menkin has shown that there is a block to the lymphatics which prevents exit through these channels. In our photomicrographs, the organisms could be seen in the reticulo-endothelial cells of the liver and spleen and in the large reticular cells of the inflamed areas.

CONCLUSIONS

1. Lymph flow is restricted through an inflamed area as though a mechanical block to the current exists. Dyes injected into the site have difficulty in diffusing out; dyes injected into the adjacent normal tissue have difficulty diffusing in. Some diffusible dyes (trypan red and indigo carmine) diffuse readily.

2. *Inflammation stimulates the local reticulum so that intravenously* injected dye or bacteria are fixed in the inflamed area. The blood is cleared of circulating organisms in 15 minutes, the reticulo-endothelium (liver and spleen) being loaded with them. Apparently, the reticulo-endothelium acts as a safety valve, but growth of organisms in these tissues within a few hours becomes too great for further retention, and the bacteria are permitted to overflow into the general circulation.

REFERENCES

1. Adler, H., and Singer, E.: Septische Infectionen und Sepsistherapie, Med. Klin. 21: 429, 1925.
2. Anitschkow, N.: *Zur Frage der Verteilung Intravenös eingeführter Kolloid-*Substanzen im Organismus Klin. Wchnschr. 3: 1729, 1924.
3. Auer, J.: Local Autoinoculation of the Sensitized Organism With Foreign Protein as a Cause of Abnormal Reactions, J. Exper. Med. 32: 427, 1920.
4. Bickhardt, K.: Ueber morphologische Befundi bei Enzündungsvorgangen in Fällen von Leukämie, Folia haemat. Arch. 32: 83, 1925.
5. Bordet, P.: Contribution à l'étude de l'allergie, Ann. Inst. Pasteur 57: 357, 1936.
6. Bowman, F. B., Winternitz, M. C., and Evans, H. M.: Centralbl. f. Bakt. 65: 403, 1912.
7. Calmette, A., and Guerin, C.: Recherches sur la vaccine experimentale, Ann. Inst. Pasteur 15: 161, 1901.
8. Cannon, P. R., and Pacheco, G. A.: Studies in Tissue Immunity. Cellular Reactions of the Skin of the Guinea Pig as Influenced by Local Active Immunization, Am. J. Path. 6: 749, 1930.
9. Charrin: Mode d'action des produits secretes par les microbes sur le systeme nerveux vasomoteur. Deductions pathologiques, Verhandl. x Internat. Med. Congr. Berlin, 2: 29, 1890.
10. Chesney, A. M., Turner, T. B., and Halley, C. R. L.: Studies in Experimental Syphilis. viii. On the Localization of Syphilitic Lesions in Inflamed Areas, Bull. Johns Hopkins Hosp. 42: 319, 1928.
11. Eckstein, A., and von Möllendorff, W.: Histophysiologische Untersuchungen über den Einfluss der Bestrahlung mit der Quecksilberquartzlampe.
12. Falchetti, E., and Carlinfanti, E.: L'etate anaphylactique provoquo chez le cobaye par l'inoculation de serum dans un foyer d'inflammation, Compt. rend. Soc. de biol. 112: 10, 1933.
13. Fox, J. P.: The Localization and Concentration of Blood-Borne Antibodies and Colloidal Dye in Areas of Inflammation of Various Ages, J. Immunol. 31: 293, 1936.
14. Freund, J.: Hemorrhages in Skin Lesions of Guinea Pigs Following Intravascular Injection of Toxins (Schwartzman Phenomenon), J. Exper. Med. 60: 661, 1934.
Freund, J., and Smith, W. F., Jr.: Hemorrhages in Skin Lesions After Intravenous Injection of Starch, Proc. Soc. Exper. Biol. & Med. 31: 1104, 1934.
Freund, J., and Whitney, C. E.: Distribution of Antibodies in the Serum and Organs of Rabbits. J. Immunol. 16: 109, 1929.
15. Frisch, J. A.: Demonstration of Local Immunity of the Peritoneum by Means of the Schwartzman Phenomenon, Arch. Int. Med. 46: 361, 1930.
16. Gerber, I. E.: Morphologic Aspects of the Local Schwartzman Phenomenon, Arch. Path. 21: 331, 1936.
17. Goldmann, E.: Die äussere und innere Sekretion des gesunden und kranken Organismus in Lichte der vitalen Färbung. Beitr. z. klin. Chir. 64: 192, 1909.
Studien zur Biologie der bösartigen Neubildungen, ibid. 72: 1, 1911.
Ueber die Beeinflussung des Blutdruckes in den Kapillaren der Haut durch verschiedene Temperaturen, Pflüger's Arch. f. d. ges. Physiol. 159: 51, 1914.

18. Higgins, G. M., and Murphy, G. T.: The Phagocytic Cells (v. Kupffer) in the Liver of Common Laboratory Animals, Anat. Rec. 40: 15, 1928.
Experimentally Induced Localized Inflammatory Reactions in the Liver, Arch. Path. 9: 659, 1930.
19. Lewis, P. A.: The Distribution of Trypan Red to the Tissues and Vessels of the Eye as Influenced by Congestion and Early Inflammation, J. Exper. Med. 23: 669, 1916.
20. Lurie, M. B.: On the Mechanism of Immunity in Tuberculosis; the Host-parasite Relationship Under the Conditions of a Localized Focus of Infection and the Generalization of the Disease in Normal and Immunized Rabbits, J. Exper. Med. 63: 923, 1936.
Lurie, M. B., and Zappasodi, P.: Relative Spread of Particulate and Diffusible Substances in the Skin of Male and Female Rabbits, Proc. Soc. Exper. Biol. & Med. 42: 741, 1939.
21. MacCurdy, J. T., and Evans, H. M.: Experimentelle Läsionen des Centralnervensystems, untersicht mit Hilfe der vitalen Färbung, Berl. klin. Wchnschr. 49: 1695, 1912.
22. Manwaring, W. H., and Fritschen, W.: Study of Microbic-Tissue Affinity by Perfusion Methods, J. Immunol. 8: 83, 1923.
23. McClellan, R. H., and Goodpasture, E. W.: A Method of Demonstrating Experimental Gross Lesions of the Central Nervous System, J. M. Research 44: 201, 1923.
24. McJunkin, F.: A Simple Technique for the Demonstration of a Phagocytic Mononuclear Cell in Peripheral Blood, Arch. Int. Med. 21: 59, 1918.
The Origin of the Phagocytic Mononuclear Cells of the Peripheral Blood, Am. J. Anat. 25: 27, 1919.
Effect of Stimulation on Phagocytic Activity of Vascular Endothelium, Proc. Soc. Exper. Biol. & Med. 26: 294, 1929.
Origin of the Perivascular Phagocytes of Granulation Tissue, Am. J. Path. 6: 39, 1930.
25. Menkin, V.: An Aspect of Inflammation in Relation to Immunity, Arch. Path. 12: 802, 1931.
Inflammation, Arch. Int. Med. 48: 249, 1931.
A Note on the Mechanism of Fixation in an Area of Sterile Inflammation, Proc. Soc. Exper. Biol. & Med. 30: 1069, 1932-33.
The Role of Inflammation in Immunity, Physiol. Rev. 18: 366, 1938.
Studies on Inflammation. I. Fixation of Vital Dyes in Inflamed Areas, J. Exper. Med. 50: 171, 1929.
Menkin, V., and Menkin, M. F.: II. A Measure of the Permeability of Capillaries in an Inflamed Area, ibid. 51: 285, 1930.
Menkin, V.: III. Fixation of a Metal in Inflamed Areas, ibid. 51: 879, 1930.
The Accumulation of Iron in Tuberculous Area. IV. The Effect of Ferric Chlorid on the Course of Tuberculosis in Reinfected Rats, ibid. 60: 463, 1934.
Menkin, V.: Studies on Inflammation, V. The Mechanism of Fixation by the Inflammatory Reaction, J. Exper. Med. 53: 171, 1931.
VI. Fixation of Trypan Blue in Inflamed Areas of Frogs, ibid. 53: 179, 1931.
VII. Fixation of Bacteria and of Particulate Matter at the Site of Inflammation, ibid. 53: 647, 1931.
VIII. Inhibition of Fixation by Urea; a Further Study on the Mechanism of Fixation by the Inflammatory Reaction, ibid. 56: 157, 1932.
X. The Cytological Picture of an Inflammatory Exudate in Relation to Its Hydrogen ion Concentration, Am. J. Path. 10: 193, 1934.
XII. Mechanism of Increased Capillary Permeability; a Critique of the Histamine Hypothesis, J. Exper. Med. 64: 485, 1936.
XIII. Carbohydrate Metabolism, Local Acidosis, and the Cytological Picture in Inflammation, Am. J. Path. 13: 25, 1937.
XIV. Isolation of the Factor Concerned With Increased Capillary Permeability in Injury, ibid. 67: 129, 1938.
Fixation of Foreign Protein at Site of Inflammation, ibid. 52: 201, 1930.
Some Problems of Inflammation Related to Surgery, Lancet 228: 981, 1935.
Inflammation and Bacterial Invasiveness, Am. J. M. Sc. 190: 583, 1935.
A Factor in the Mechanism of Invasiveness by Pyogenic Bacteria, J. Exper. Med. 57: 977, 1933.
Invasiveness and Virulence in Relation to Resistance, J. Infect. Dis. 58: 81, 1936.
Local Acidosis in Inflammation, Am. J. Path. 12: 725, 1936.
Mechanism of Inflammation, Arch. Path. 24: 65, 1937.
The Accumulation of Iron in Tuberculous Areas; II. Survival Time of

Tuberculous Rabbits Injected With Ferric Chlorid, J. Exper. Med. 55: 101, 1932.
The Accumulation of Iron in Tuberculous Areas; iii. Effect of Ferric Chlorid Injections on the Course of Development of Tuberculosis in Rabbits, Am. J. M. Sc. 185: 40, 1933.
Menkin, V., and Menkin, M. F.: The Accumulation of Iron in Tuberculous Areas, J. Exper. Med. 53: 919, 1931.
Menkin, V., and Walston, H. D.: Role of Coagulating Principle of Staphylococcus Aureus in Relation to Invasiveness of This Organism, Proc. Soc. Exper. Biol. & Med. 32: 1259, 1935.
26. Miller, C. P., Jr.: Untersuchungen über die sogenannte lokale Immunität bei experimentellen Staphylokokken- u. Streptokokken-Infection der Haut. Ztschr. f. Hyg. u. Infektionskr. 107: 253, 1927.
27. Moritz, A. R.: The Relation of Altered Local Tissue Reactivity (Schwartzman Phenomenon) to Infection and Inflammation, J. Exper. Med. 66: 603, 1937.
28. Nissen R.: Der Einfluss kolloidal gelöster Metalle auf die blutbereitenden Organe mit besonderer Berücksichtigung des reticuloendothelialen Systems, Klin. Wchnschr. (No. 1 & 2) 1986, 1922.
29. Noetzel, W.: Ueber die Infection Granulirenden Wunden, Arch. klin. Chir. 55: 513, 1897.
Ueber die Bacterienresorption frischen Wunden, Verhandl. d. deutsch. Gesellsch. f. Chir. 1: 27, 1898.
Ueber die bactericide Wirkung der Stauungshyperämie nach Bier, Arch. klin. Chir. 60: 1, 1900.
Weitere Untersuchungen über die Wege der Bakterienresorption von frischen Wunden und die Bedeutung derselben, Arch. klin. Chir. 60: 25, 1900.
30. Okuneff, N.: Die Abwanderung aus dem Blute eines ins Blut injizierten Farbstoffes von kolloidaler Natur, Pflügers Arch. f. d. ges. Physiol. 201: 579, 1923.
Ueber den Einfluss lokaler thermischer Reize auf die Abwanderung eines intravenös injizierten kolloidalen Farbstoffs aus dem Blute, Pflügers Arch. f. d. ges. Physiol. 204: 261, 1924.
Ueber die Resorption des Farbstoffs Trypanblau aus dem subkutanen Bindegewebe, Biochem. Ztschr. 226: 147, 1930.
31. Pawlowsky, A. D.: Zur Frage der Infektion und Immunität. Das Schicksal einiger (hauptsächlich pyogener) Mikroben im Organismus empfänglicher u. immunier Tiere, Ztschr. rat. Med. 33: 261, 1900.
Das Schicksal einiger pathogener (hauptsächlich pyogener) mikroben bei ihrem Eindringen in den Tierorganismus von den Gelenken, der Pleura, dem Auge, der Mundhöhle, dem Darmkanale, und der Vagina aus, Ztschr. f. Hyg. u. Infektionskr. 62: 433, 1909.
32. Petroff, J. R: Ueber die Vitalfärbung der Gefässwandungen, Beitr. z. path. Anat. u. z. allg. Path. 71: 115, 1922.
33. Quednau, F.: Der Erweichungsherd des Gehirns also Bakterienfänger, Beitr. z. path. Anat. u. z. allg. Path. 83: 471, 1929.
34. Ramsdell, S. G.: The Use of Trypan Blue to Demonstrate the Immediate Skin Reaction in Rabbits and Guinea Pigs, J. Immunol. 15: 305, 1928.
35. Rich, A. R.: The Mechanism Responsible for the Prevention of Spread of Bacteria in the Immune Body, Bull. Johns Hopkins Hosp. 52: 203, 1933.
Inflammation in Resistance to Infection, Arch. Path. 22: 228, 1936.
Rich, A. R., and McKee, C. M.: The Protective Action of Antibody in Immunized Animals Deprived of Leukocytes, Arch. Path. 14: 284, 1932.
A Study of the Character and Degree of Protection Afforded by the Immune State Independently of the Leukocytes, Bull. Johns Hopkins Hosp. 54: 277, 1934.
36. Rigdon, R. H.: A Study of Capillary Permeability and Inflammation in the Skin of Rabbit Given Adrenalin, SURGERY 8: 839, 1940.
Capillary Permeability in Areas of Inflammation Produced by Xylol, Arch. Surg. 41: 101, 1940.
37. Rivers, T. M., and Tillett, W. S.: Local Passive Immunity in the Skin of Rabbits to Infection With (1) a Filterable Virus, and (2) Hemolytic Streptococci, J. Exper. Med. 41: 185, 1925.
38. Rous, P., Gilding, H. P., and Smith, F.: The Gradient of Vascular Permeability, J. Exper. Med. 51: 807, 1930.
Rous, P., McMaster, P. D., and Hudack, S.: The Relation of Hydrostatic Pressure to the Gradient of Capillary Permeability, ibid. 55: 203, 1932.
Rous, P., and Smith, F.: The Gradient of Vascular Permeability. III. The Gradient Along the Capillaries and Venules of Frog Skin, ibid. 53: 219, 1931.

Rous, P.: The Relative Reaction Within Living Mammalian Tissues, VI. Factors Determining the Reaction of Skin Grafts; a Study by the Indicator Method of Conditions Within an Ischemic Tissue, ibid. 44: 815, 1926.
39. Ruffer, M. A.: The Destruction of Micro-Organisms During the Process of Inflammation. Brit. M. J. 1: 1177, 1890.
Recherches sur la destruction des microbes, Ann. Inst. Pasteur 5: 673, 1891.
40. Sager, W. W., and Michel, A. C.: Localization of Bacteria in Tissues of Lowered Resistance, Arch. Surg. 19: 1086, 1929.
41. Schmidt, E. A.: Experimentelle und histologische Untersuchungen über den Einfluss de Röntgenstrahlen auf die vitale Färbarkeit der Gewebe, Strahlentherapie, 12: 517, 1921.
42. Schulemann, W.: Beiträge zur Vitalfärbung, Arch f. mikr. Anat. 79: 223, 1912.
Die vitale Färbung mit säuren Farbstoffen in ihrer Bedeutung für Anatomie, Physiologie, Pathologie, und Pharmakologie, Biochem. Ztschr. 80: 1, 1917.
43. Schwartzman, G.: Studies on Bacillus Typhosus Toxic Substances; 1. Phenomenon of Local Skin Sensitivity to *B. typhosus* Culture Filtrate, J. Exper. Med. 48: 247, 1928.
Grading of Local Skin Reactivity to Bacterial Filtrates, ibid. 61: 383, 1935.
44. Seegal, B. C., and Seegal D.: Local Organ Hypersensitiveness, VI. An Indirect Method for Its Production in the Rabbit Eye, J. Immunol. 25: 221, 1933.
45. Seyderhelm, R., and Lampe, W.: Ueber neue intravitale Verwendungsmöglichkeiten kolloidaler Farbstoffe, Deutsche med. Wchnschr. 32: 1049, 1923.
46. Shmidzu, Y.: On the Permeability to Dyestuffs of the Placenta of the Albino Rat and the White Mouse, Am. J. Physiol. 62: 202, 1922.
47. Sickles, G. M.: Local Skin Reaction Obtained by Intravenous Injection of Agar Following Intracutaneous Inoculation of Meningococcus Toxin, J. Immunol. 20: 169, 1931.
48. Siengalewicz, S. S.: The Action of Neo-salvarsan and Carbon Monoxide on the Chloroid Plexus and Meninges, J. Pharmacol. & Exper. Therap. 24: 289, 1925.
49. Stilwell, F.: On the Phagocytic Capacity of the Blood Vessel Epithelium of the Frog's Tongue and Its Presumed Transformation Into Wandering Cells, Folia haemat. Arch. 33: 81, 1926.
50. Wadsworth, A.: Experimental Studies on the Etiology of Acute Pneumonitis, Am. J. M. Sc. 127: 851, 1904.
51. Willis, H. S.: Studies on Tuberculosis Infection. X. The Early Dissemination of Tuberculosis Bacilli After Intracutaneous Inoculation of Guinea Pigs of First Infection, Am. Rev. Tuberc. 11: 427, 1925.
52. Winternitz, M. C., and Hirschfelder, A. D.: Studies Upon Experimental Pneumonia in Rabbits, J. Exper. Med. 17: 657, 1913.

UNUSUAL INTRA-ABDOMINAL FOREIGN BODY

HERBERT T. WIKLE, M.D., F.A.C.S., BROOKLYN, N. Y.

CROSSEN and Crossen[1] in their volume, *Foreign Bodies Left in the Abdomen*, cited a case reported by V. J. Schwartz[2] where a clinical thermometer was removed from the esophagus by esophagoscopy, also a case reported by G. K. Nutting,[3] who removed a swallowed clinical thermometer by milking it from the cecum into the appendix and then removing the appendix.

So far as I can ascertain there are no reports of a thermometer having been removed from the abdominal cavity.

CASE REPORT

A boy, aged 12 years, was admitted Dec. 8, 1941. His chief complaint was abdominal pain for three weeks. It started with sharp, sticking pain in the mid-epigastrium, which would come and go, and sometimes radiated to the right shoulder; there was also burning on urination, but no frequency. The family doctor had found pus in urine one week prior to admission. During this week the patient vomited twice and had a chilly sensation. The mother stated that the boy had a poor appetite, was losing weight and getting pale.

Past history revealed poliomyelitis at 9 years of age, with no residual paralysis; he also had bilateral running ears at 10 years of age and was hospitalized at this time for ten days. All systems were essentially negative except burning on urination for three weeks prior to admission.

Social history showed the patient to be one of four children, the mother divorced. Diet was stated to be adequate.

Examination.—Twelve-year-old boy, anemic looking, not acutely ill, old healed perforated left drum. Neck, firm enlarged cervical nodes on left; chest, clear; abdomen, flat, slight tenderness in right lower quadrant; no masses, hernias, or palpable organs. Genitalia, normal male; rectal, negative; reflexes negative, no weakness or deformities; Wassermann, negative. Blood chemistry: Sugar, 93.0; urea nitrogen, 21.0; uric acid, 2.5. Complete blood count: Hemoglobin, 63 per cent; red cells, 4,000,000; white cells, 10,750; neutrophiles, 52; monocytes, 6; lymphocytes, 41; eosinophiles, 1; and anisocytosis, 2 plus. Urinalysis: 1,028, alkaline; sugar, negative; albumin, negative. Microscopic, many sulfathiazole crystals. X-ray: On Dec. 13, 1941, an intravenous pyelogram was made. A foreign body, an unbroken rectal thermometer measuring about 11 cm., was noted in the ascending colon, occupying the entire length of the ascending colon. Dec. 16, 1941, examination by means of barium enema showed the foreign body to be definitely outside of the colon lying in oblique position from behind, forward at an angle of about 30 degrees to the longitudinal axis of the lumbar spine, probably intraperitoneal.

Presented at a meeting of the New York Gastroenterological Association, Oct. 30, 1942.
Received for publication, Nov. 28, 1942.

The patient was accepted on surgery from genitourinary service on Dec. 15, 1941. On Dec. 17, 1941, under open-drop ether anesthesia, the abdomen was opened by a right pararectus incision 4 cm. below the level of the umbilicus.

Findings.—Foreign body (rectal thermometer reading 97.4° F.) was located in the right lumbar gutter at, and immediately above, the plane of the umbilicus; the long axis of the thermometer was lying in the anteroposterior plane with the mercury bulb posterior and immediately adjacent to the posterolateral aspect of the ascending colon. The thermometer was definitely intraperitoneal although the bulb may have been retroperitoneal, inasmuch as that part was not visualized. The appendix was located lying free and containing a few small fecaliths, and was removed. The thermometer was removed by blunt and sharp dissection.

Pathology.—

Sinus Tract: Macroscopic: Membranous fragment of tissue measuring 3 cm.; surface was smooth, glistening, and yellow in color, outer surface was hemorrhagic, one portion felt firm and calcified.

A. *B.*

Fig. 1.—Roentgenogram showing clinical thermometer. *A*, Scout film; *B*, barium film indicating thermometer outside of confines of colon.

Microscopic of Membrane.—Microscopic examination showed concentrate layers of dense, partly hyalinized fibrous connective tissue devoid of lining. Portions of the wall were infiltrated with round cells, other portions contained deposits of calcium crystals, while others show the presence of ossifications.

Pathologic Diagnosis.—1. Calcification and ossification of fibrous membrane. 2. Fibrosis of appendix.

The patient had an uneventful convalescence, and was discharged on the tenth postoperative day.

SUMMARY

1. A case is reported in which the patient had a rectal thermometer in the abdominal cavity.

UNUSUAL INTRA-ABDOMINAL FOREIGN BODY

HERBERT T. WIKLE, M.D., F.A.C.S., BROOKLYN, N. Y.

CROSSEN and Crossen[1] in their volume, *Foreign Bodies Left in the Abdomen*, cited a case reported by V. J. Schwartz[2] where a clinical thermometer was removed from the esophagus by esophagoscopy, also a case reported by G. K. Nutting,[3] who removed a swallowed clinical thermometer by milking it from the cecum into the appendix and then removing the appendix.

So far as I can ascertain there are no reports of a thermometer having been removed from the abdominal cavity.

CASE REPORT

A boy, aged 12 years, was admitted Dec. 8, 1941. His chief complaint was abdominal pain for three weeks. It started with sharp, sticking pain in the mid-epigastrium, which would come and go, and sometimes radiated to the right shoulder; there was also burning on urination, but no frequency. The family doctor had found pus in urine one week prior to admission. During this week the patient vomited twice and had a chilly sensation. The mother stated that the boy had a poor appetite, was losing weight and getting pale.

Past history revealed poliomyelitis at 9 years of age, with no residual paralysis; he also had bilateral running ears at 10 years of age and was hospitalized at this time for ten days. All systems were essentially negative except burning on urination for three weeks prior to admission.

Social history showed the patient to be one of four children, the mother divorced. Diet was stated to be adequate.

Examination.—Twelve-year-old boy, anemic looking, not acutely ill, old healed perforated left drum. Neck, firm enlarged cervical nodes on left; chest, clear; abdomen, flat, slight tenderness in right lower quadrant; no masses, hernias, or palpable organs. Genitalia, normal male; rectal, negative; reflexes negative, no weakness or deformities; Wassermann, negative. Blood chemistry: Sugar, 93.0; urea nitrogen, 21.0; uric acid, 2.5. Complete blood count: Hemoglobin, 63 per cent; red cells, 4,000,000; white cells, 10,750; neutrophiles, 52; monocytes, 6; lymphocytes, 41; eosinophiles, 1; and anisocytosis, 2 plus. Urinalysis: 1,028, alkaline; sugar, negative; albumin, negative. Microscopic, many sulfathiazole crystals. X-ray: On Dec. 13, 1941, an intravenous pyelogram was made. A foreign body, an unbroken rectal thermometer measuring about 11 cm., was noted in the ascending colon, occupying the entire length of the ascending colon. Dec. 16, 1941, examination by means of barium enema showed the foreign body to be definitely outside of the colon lying in oblique position from behind, forward at an angle of about 30 degrees to the longitudinal axis of the lumbar spine, probably intra-peritoneal.

Presented at a meeting of the New York Gastroenterological Association, Oct. 30, 1942.
Received for publication, Nov. 28, 1942.

TRAUMATIC RUPTURE OF THE SPLEEN WITH DELAYED HEMORRHAGE

With Reference to the Condition as a Complication of Rib Fractures; Report of Two Cases

Richey L. Waugh, M.D., F.A.C.S., and John A. Prior, M.D., Boston, Mass.

(From the Surgical Service, U. S. Marine Hospital, Boston)

DELAYED hemorrhage is an unusual and an extremely dangerous complication of splenic injury. Until recently there has been relatively little literature on the subject and apparently it is not generally realized that splenic rupture may be associated with fractures of the ribs on the left side.

Much of our present better understanding of the subject is due to the contribution of McIndoe[28] who, in 1932, collected and reviewed forty-six cases of secondary hemorrhage following injury to the spleen. Of these forty-six cases with delayed hemorrhage, there were ten cases (22 per cent) associated with fracture of the ribs, which, like other associated conditions, often completely masked the underlying splenic injury. Wright and Prigot,[42] in their very excellent paper on the subject, give credit to Chalier,[8] in 1927, as the first to report the occurrence of traumatic rupture of the spleen as a complication of rib fracture. Chalier in his article, however, refers to two other cases previously reported, one by Pierre Duval and the other by Guibe. It was the opinion of Chalier that traumatic rupture of the spleen could occur only with fracture of the ribs but that the latter usually was unrecognized.

In this connection there should be noted Hinton and Steiner's[21] series of 279 cases of fractures of the ribs serious enough to warrant hospitalization, of which twenty-nine (10.4 per cent) resulted fatally. Of these 279 patients with fractures of ribs, there were two with rupture of the spleen. Furthermore, both of these cases by slowly progressing primary hemorrhage terminated in death, one on the second and the other on the sixth day. According to McIndoe,[28] the syndrome of delayed hemorrhage following splenic rupture is definite and should include only those cases in which the primary rupture is followed by complete, or almost complete, hemostasis for a latent period of more than forty-eight hours and then a delayed hemorrhage of dramatic onset and fulminating character. McIndoe also states that patients should not be included in this category who gradually sink under the influence of a slowly progressing splenic hemorrhage, even though the duration of symptoms is more than forty-eight hours.

Received for publication, Dec. 7, 1942.

2. The thermometer had probably been in the abdominal cavity for two years.

3. There was nothing in the patient's history to indicate a perforation of the bowel.

REFERENCES

1. Crossen, H. S., and Crossen, D. F.: Foreign Bodies Left in Abdomen, St. Louis, 1940, C. V. Mosby Company.
2. Schwartz, V. J.: Thermometer as Foreign Body in Esophagus, J. A. M. A. 110: 950, 1938.
3. Nutting, G. K.: Appendectomy for Swallowed Clinical Thermometer, J. A. M. A. 100: 572, 1933.

of a left pneumothorax. The abdominal examination revealed no areas of tenderness and no masses were palpated. Urine examination was reported as containing sugar and numerous fine granular and hyaline casts. The blood Wassermann was negative.

Roentgen examination of the chest showed fractures of the tenth, eleventh, and twelfth ribs, left, at the posterior axillary line.

The diagnoses were multiple fractures of the ribs, left and subcutaneous emphysema. The treatment was chest strapping and bed rest.

For the following two days he continued to complain of severe pain in his left chest. The subcutaneous emphysema, although not marked, was noted to be present over the entire left side extending from the left occipital region down to the left iliac crest. During this time he had several small hemoptyses. On the third day the emphysema began to lessen and it was barely noticeable by the fifth day. However, at times he complained of slight faintness with nausea and he vomited on several occasions. Also, the sputum became more productive and was frankly purulent and bloody. The abdomen remained soft and no distension was noted. Roentgenograms of the chest were repeated and showed partial obliteration of the left costophrenic angle with findings suggestive of slight degree of hemopneumothorax. The patient, although showing general improvement, was kept in bed during this period. However, during the evening of April 8, 1937 (fifth day), he got out of bed and went to the bathroom, where he collapsed. The patient was immediately returned to bed and except for moderate pallor did not show any apparent ill effects of the episode. The blood count, however, showed red cells 2,350,000 and hemoglobin 50 per cent, and internal hemorrhage was suspected.

The next day (the sixth day after injury) the patient, although stating that he felt better, showed a marked pallor. Now the abdomen was moderately distended and tympanitic with definite tenderness in the left upper quadrant. The temperature was 99.2° F., the pulse rate 122, and the respiratory rate 24. The red cell count was 1,700,000 and hemoglobin 40 per cent. Sugar and granular and hyaline casts were again reported in the urine (he had received no intravenous dextrose solution). The probability of hemoperitoneum due to traumatic rupture of the spleen was considered and exploratory laparotomy was advised.

Operation.—On April 9, 1937, following whole blood transfusion, a laparotomy was done under spinal anesthesia using 15 mg. of pontocaine. There was much dark and also much bright red blood mixed with clots in the left half of the abdominal cavity. The spleen was found to be ruptured transversely in the midportion and surrounded by many blood clots. After clamping and doubly ligating the pedicle, the spleen was removed. Two Penrose drains were placed in the lateral angle and the wound was closed in layers.

Postoperative Course.—The immediate postoperative condition of the patient was very good and the subsequent convalescence was uneventful. Repeated urinalyses were negative. The serial blood counts during convalescence are shown in Table II.

TABLE II

SHOWING SERIAL BLOOD COUNTS DURING PERIOD OF CONVALESCENCE AFTER SPLENECTOMY (CASE 1)

DATE	R.B.C.	HB.	W.B.C.	TIME AFTER SPLENECTOMY (DAYS)
4/12/37	2,150,000	50	13,800	3
4/22/37	3,160,000	60	14,600	13
4/28/37	4,100,000	85	10,400	19

In a rather critical review of cases published in the American and English literature since McIndoe's report, we have found twenty-two cases (see Table I) that fulfill his criteria. This brings the total of reported cases of delayed hemorrhage to sixty-eight. We wish, in this communication, to report two additional cases both of which were complicated by rib fractures on the left side. These two cases bring up the total reported cases of splenic rupture with delayed hemorrhage to seventy, with the total complicating fractures of the ribs to eighteen (26 per cent) (see Table 1).

TABLE I

NUMBER OF REPORTED CASES OF TRAUMATIC RUPTURE OF SPLEEN WITH DELAYED HEMORRHAGE, LATENT PERIOD, AND NUMBER OF CASES ASSOCIATED RIB FRACTURE

YEAR	AUTHOR	NUMBER OF CASES	LATENT PERIOD	NUMBER ASSOCIATED WITH RIB FRACTURES
1932	McIndoe (45 cases collected and 1 of own)	46	"48 hr. to 6 mo. average 8 to 14 days"	10
1933	Wells	1	2 days	0
1934	Dodd	2	(1) 2½ days; (2) 7 days	0
1935	Bronaugh	1	4 days	0
1935	Gardiner	1	7 days	0
1935	Hunter	1	6 days	0
1936	Lovatt-Wenger	1	7 days	1
1937	Bonfield	1	2 days	0
1937	Ghey	1	4 days	0
1938	Guy	2	(1) 10 days; (2) 15 days	1
1939	Webb	1	4 days	0
1939	Wright and Prigot	2	(1) 14 days; (2) 21 days	1
1940	Foster and Prey	1	6 days	0
1940	Puestow	1	3 days	0
1940	Steenrod	1	14 days	1
1940	Fey and Turow	1	9 days	1
1941	Deaver	1	23 days	1
1941	Rousselot and Illyne	1	15 days	0
1942	Harkins	1	4 days	0
1942	Lommen	1	7 days	0
1942	Waugh and Prior	2	(1) 5 days; (2) 6 days	2
	Total	70		18

CASE 1.—W. H., white, aged 32 years, was admitted to the hospital* 2:00 P. M. on April 4, 1937. He complained of pain in his left chest accentuated by deep breathing. The history was that at about 10:00 P. M. April 3, 1937, while walking across a street, he had been "knocked unconscious for about ten minutes" when struck on his left side by an automobile. He had been ambulant, but the pain in the left chest had been constant since the injury. There was no hemoptysis and no dyspnea. The history otherwise contained nothing of importance.

Physical examination at the time of admission to the hospital showed the patient to be ambulant, fairly well nourished, and not acutely ill. He had a temperature of 99.8° F., a pulse rate of 80, and a respiratory rate of 20. There was a superficial laceration over the right temporal region. In the region of the eighth to twelfth ribs, left, posterior axillary line, there was a soft mass about four inches in diameter. This mass was tender and gave a crackling sensation upon palpation. The crackling sensation also extended over the entire left chest and was indicative of subcutaneous emphysema. The chest findings were those

*Treated by one of us (R.L.W.) at the U. S. Marine Hospital, New Orleans, La.

Operation.—On June 9, 1941, laparotomy was performed under spinal anesthesia using 15 mg. of pontocaine. On opening the abdomen there was marked gushing of dark red blood. The spleen showed multiple lacerations, and there was at least one quart of dark clotted blood present. The spleen was removed and the abdomen closed in layers with a Penrose tube inserted through a lateral stab wound. Immediately after operation the patient was given a transfusion of 500 c.c. of whole blood.

Postoperative Course.—The patient's immediate postoperative reaction was satisfactory. Although he appeared pale and weak, he stated he felt greatly improved. The blood count the day after operation was red cells, 2,500,000, white cells, 7,650, with neutrophiles 68 per cent and hemoglobin 45 per cent. The highest temperature was 101° F. on the third day after operation, but this had returned to normal by the seventh day. Convalescence was uneventful except for a hematoma in the lateral portion of the incision. The wound, however, healed rapidly after excision of the hematoma. He was discharged as recovered on July 24, 1941.

The blood counts taken in the course of the patient's convalescence and in the follow-up, showing the physiologic leucocytosis and lymphocytosis, are given in Table III.

TABLE III

SHOWING SERIAL BLOOD COUNTS DURING PERIOD OF CONVALESCENCE AFTER SPLENECTOMY (CASE 2)

DATE	R.B.C.	Hb.	W.B.C.	POLY-MORPHO-NUCLEAR (PER CENT)	LYMPH-OCYTES (PER CENT)	MONO-CYTES (PER CENT)	TIME AFTER SPLENECTOMY
6/10/41	2,500,000	45	7,650	68	20	2	1 day
6/19/41	3,000,000	50	16,250	78	19	1	10 days
7/ 1/41	4,100,000	55	14,600	72	26	2	22 days
7/ 7/41	4,200,000	61	13,600	60	39	1	28 days
7/17/41	4,900,000	79	17,000	48	50	2	38 days
10/ 7/41	5,200,000	85	8,850	62	34	2	4 months

The report of histopathologic examination of the spleen was as follows:

"*Gross:* The spleen measures 14.5 by 9 by 5 cm. and weighs 260 Gm. The capsule and the parenchyma are ruptured at several places. There are areas where the capsule is pulled into folds. There are several large subcapsular hemorrhages. The surface of the spleen is covered in many places by thick blood clots.

"*Microscopic:* There are occasional areas of the spleen which are congested and there are interstitial hemorrhages which appear some days old. No other significant pathology is seen.

"Diagnosis: Multiple lacerations, spleen."

COMMENT

In splenic rupture with delayed hemorrhage, the so-called latent or silent period may last from forty-eight hours to six months. The majority, however, are from four to six days. This silent period is more comparative than absolute, because in many cases there is evidence of some underlying injury, particularly persistence of pain in the left side. Also, there may be an accompanying slight increase in splenic dullness and slight rigidity in the left upper quadrant of the abdomen.

It is during this period of silence that the diagnosis is most difficult and as a result many lives are lost from delay in operation. Close

The report of histopathologic examination of the spleen was as follows: "Extensive areas of old and recent pulp thrombosis are present; the older areas are margiuated by deposits of blood, pigment and infiltration of polymorphonuclear leucocytes. Hemorrhagic extravasations are present beneath the capsule and a heavy deposit of fibrin is present upon it.

"Diagnosis: Traumatic infarction of the spleen."

CASE 2.—J. B., white, aged 43 years, was admitted to the hospital on a stretcher at 6:04 P. M. on June 3, 1941. He complained of pain in the left chest, particularly upon motion or deep breathing. He had been well until 4:00 P. M. of that day, at which time he had fallen sidewise striking his left chest over a narrow bar. He stated that the injury had "knocked the wind out of me." The remaining history disclosed nothing of importance.

Physical examination revealed a well-developed and nourished white male lying in bed but in no apparent distress. He had a temperature of 98° F., pulse rate of 72, and respiratory rate of 20. Examination of the chest showed slightly limited expansion on the left. There were two transverse reddened welts over the lower left chest beginning about 6 inches below the left nipple and extending laterally to the posterior axillary line. The area was tender and painful upon deep respiration or manual compression of the chest. There was no local swelling and no ecchymosis present. The lungs were clear. The heart showed no signs of enlargement and the sounds were normal. The blood pressure was 106 systolic and 74 diastolic.

The examination of the abdomen showed no tenderness or muscle spasm and no masses were palpable. Physical examination was otherwise negative.

The urinalysis and the Hinton and Kahn blood tests were negative. The roentgenogram of the chest revealed fractures of the eighth, ninth, tenth, and eleventh ribs, left, at the anterior axillary line and a fracture of the eleventh rib, left, about two inches distal to the costovertebral articulation.

The diagnosis was multiple fractures of the ribs, left. Although considerable relief of pain was obtained for the patient by chest strapping, further observation of him as a bed patient was advised.

The following day, the patient complained of slight nausea in addition to the pain in the left chest. However, there was no vomiting and no cough. The temperature was 99° F., the pulse 96, and the respiratory rate 20. The abdomen showed slight distension, and there was slight tympanites upon percussion. However, there was no abdominal tenderness, even upon deep palpation.

During the next few days the patient continued to improve. His only complaint was discomfort in the lower left chest. There was no nausea or vomiting. The slight abdominal distension and tympanites were no longer present. However, the temperature varied between 98 to 100° F., the pulse rate from 80 to 100, and the respiratory rate from 18 to 24.

In the afternoon of June 9, 1941 (six days after the injury), the patient complained of sudden onset of pain in the left upper abdomen associated with considerable weakness. He soon became dyspneic and appeared quite pale. His temperature dropped to 97.6° F., his pulse rate rose to 130 with only fair volume, and the respiratory rate became 28. Examination of the abdomen showed diffuse tenderness, more marked in the upper left quadrant. There was moderate distension anteriorly and dullness in the flanks, particularly on the left. Ballance's sign was present but Kehr's sign was absent.

A complete blood count at this time showed red cells 3,100,000 and white cells 18,250. The differential white cell count was 85 per cent neutrophiles, 12 per cent lymphocytes, and 3 per cent monocytes. The hemoglobin was 61 per cent. The red blood cells were reported as showing anisocytosis and hypochromia.

The diagnosis of hemoperitoneum probably due to rupture of the spleen was made and immediate operation was advised.

Operation.—On June 9, 1941, laparotomy was performed under spinal anesthesia using 15 mg. of pontocaine. On opening the abdomen there was marked gushing of dark red blood. The spleen showed multiple lacerations, and there was at least one quart of dark clotted blood present. The spleen was removed and the abdomen closed in layers with a Penrose tube inserted through a lateral stab wound. Immediately after operation the patient was given a transfusion of 500 c.c. of whole blood.

Postoperative Course.—The patient's immediate postoperative reaction was satisfactory. Although he appeared pale and weak, he stated he felt greatly improved. The blood count the day after operation was red cells, 2,500,000, white cells, 7,650, with neutrophiles 68 per cent and hemoglobin 45 per cent. The highest temperature was 101° F. on the third day after operation, but this had returned to normal by the seventh day. Convalescence was uneventful except for a hematoma in the lateral portion of the incision. The wound, however, healed rapidly after excision of the hematoma. He was discharged as recovered on July 24, 1941.

The blood counts taken in the course of the patient's convalescence and in the follow-up, showing the physiologic leucocytosis and lymphocytosis, are given in Table III.

TABLE III

SHOWING SERIAL BLOOD COUNTS DURING PERIOD OF CONVALESCENCE AFTER SPLENECTOMY (CASE 2)

DATE	R.B.C.	Hb.	W.B.C.	POLYMORPHONUCLEAR (PER CENT)	LYMPHOCYTES (PER CENT)	MONOCYTES (PER CENT)	TIME AFTER SPLENECTOMY
6/10/41	2,500,000	45	7,650	68	20	2	1 day
6/19/41	3,000,000	50	16,250	78	19	1	10 days
7/ 1/41	4,100,000	55	14,600	72	26	2	22 days
7/ 7/41	4,200,000	61	13,600	60	39	1	28 days
7/17/41	4,900,000	79	17,000	48	50	2	38 days
10/ 7/41	5,200,000	85	8,850	62	34	2	4 months

The report of histopathologic examination of the spleen was as follows:

"*Gross:* The spleen measures 14.5 by 9 by 5 cm. and weighs 260 Gm. The capsule and the parenchyma are ruptured at several places. There are areas where the capsule is pulled into folds. There are several large subcapsular hemorrhages. The surface of the spleen is covered in many places by thick blood clots.

"*Microscopic:* There are occasional areas of the spleen which are congested and there are interstitial hemorrhages which appear some days old. No other significant pathology is seen.

"Diagnosis: Multiple lacerations, spleen."

COMMENT

In splenic rupture with delayed hemorrhage, the so-called latent or silent period may last from forty-eight hours to six months. The majority, however, are from four to six days. This silent period is more comparative than absolute, because in many cases there is evidence of some underlying injury, particularly persistence of pain in the left side. Also, there may be an accompanying slight increase in splenic dullness and slight rigidity in the left upper quadrant of the abdomen.

It is during this period of silence that the diagnosis is most difficult and as a result many lives are lost from delay in operation. Close

observation during this period is most essential. The fatality rate of untreated delayed hemorrhage cases has been reported to vary from 90 to 100 per cent which is the same as for untreated primary hemorrhage cases. McIndoe[28] in his review stated that of the 46 cases, there were 7 patients who died of secondary hemorrhage before operative intervention could be attempted.

McCartney[27] reviewed 25,000 consecutive autopsies performed at the University of Minnesota and found no instances of healed splenic injuries. In this connection, Bell[2] is unable to recall any instance of autopsy findings indicating spontaneous recovery from a traumatic rupture of the spleen. Also, Wright and Prigot's[42] review of 3,000 autopsies at Harlem Hospital showed no evidence of healed injuries to the spleen. Novak[30] and Starr,[35] on the other hand, report instances of healed injuries to the spleen observed in cadavera.

The onset of delayed hemorrhage is usually very abrupt and is followed by the classical signs of primary rupture, i.e., shock and severe abdominal pain, tenderness and rigidity. Also, very often it will be noted that the acute onset of symptoms is preceded by some slight effort such as coughing, sneezing, or bending movements. If the patient recovers from the initial collapse, the signs of internal hemorrhage soon become manifest. Increasing and nonshifting dullness in the splenic region and left lower quadrant of the abdomen (Ballance's sign) with signs of free fluid in the right lower quadrant is usually present. Also, there may be pain referred to the left shoulder (Kehr's sign) and elevation of the left leaf of the diaphragm. Wright and Prigot[42] recommend abdominal tap as a diagnostic measure and state that it was of positive value in thirteen of the fifteen times that it was used by them.

The pathologic changes which occur in delayed hemorrhage may be in the form of (1) a minor superficial capsular rupture with ecchymosis and also hemorrhage, (2) an intrasplenic hematoma and subcapsular hemorrhage with subsequent capsular rupture, or (3) a capsular and parenchymal rupture with an encapsulated perisplenic hematoma with the omentum tending to wall off the lesion.

The treatment is always surgical, splenectomy being the operation of choice. Tamponade has been resorted to but is generally condemned because of its uncertainty in controlling the bleeding. Hinton,[22] on the other hand, reports the case of a 14-year-old boy with a splenic rupture followed by delayed hemorrhage, who made an excellent recovery following a tamponage operation. Blood transfusion may be necessary. The removal of the spleen has not been found to produce any ill effects. However, Naegeli[29] and others[32, 33] have noted in some instances a leucocytosis and lymphocytosis for a transitory period up to six months.

An interesting side light is that autoplastic transplantation of splenic tissue within the peritoneal cavity following splenectomy for traumatic rupture of the spleen has been observed by Buchbinder and Lipkoff[7]

and others. These implants of splenic tissue have been designated as "splenosis" and apparently are more likely to occur in young individuals who survive traumatic rupture of the spleen. It has been shown that these bodies or implants have the same structure as normal spleen, and that any function that these transplants might have would be that of normal splenic tissue.

Kracke and Garver[24] point out that lymphatic tissue is widely distributed throughout the body. The spleen is said to contain normally from one-third to one-half of the lymphoid tissue of the body and approximately one-fourth of the reticulo-endothelium. The immediate effect of the removal of the spleen is simply a sudden decrease in the amount of lymphoid tissue. This causes a sudden increase in the formed elements of the blood. Following this there is usually a gradual compensation in the form of a slight generalized lymphoid hypertrophy so that within a few months the individual may have nearly as much functional lymphatic tissue as he had before the splenectomy. The blood picture then, within a few weeks to a year, reverts to normal.

Ziegler[13] does not believe that the disappearance of leucocytosis and lymphocytosis necessarily signifies the presence of autoplastic transplants. It is reasonable, however, to conclude that autoplastic transplants of splenic tissue, if large enough, might assume, along with the other lymphatic tissue of the body, the function of the absent spleen.

In this connection, Boyd[5] presents some interesting observations. In some invertebrates the splenic tissue is not collected into a definite organ but is found scattered beneath the serous coat of the gastrointestinal tract. Some of the higher fish exhibit splenic tissue which is divided into separate nodules. In man it is not uncommon to find accessory spleens. One case was reported in which there was no spleen but 400 spleniculi. Cases of congenital absence of the spleen have been reported. It is common knowledge that the spleen is not essential to life as has been well demonstrated by surgical removal and by cases of congenital absence.

SUMMARY

1. The subject of traumatic rupture of the spleen followed by delayed hemorrhage is reviewed briefly and discussed with particular reference to the condition as a complication of rib fractures on the left side.

2. The criteria for delayed hemorrhage following splenic rupture as stated by McIndoe is emphasized. In a rather critical review of cases published in the American and English literature including those of McIndoe, we have found a total of sixty-eight cases of splenic rupture followed by delayed hemorrhage that fulfills his criteria. Two additional cases are reported, both of which were complicated by rib fractures on the left side. These two cases bring up the total reported cases of splenic rupture with delayed hemorrhage to seventy, with the total complicating fractures of the ribs to eighteen (26 per cent).

3. It is reasonable to conclude that in traumatic rupture of the spleen, either with or without delayed hemorrhage, a considerable number of associated rib fractures on the left side are overlooked. This is due, no doubt, to attention being focused on the more important intra-abdominal traumatisms and the failure to have roentgenograms made in all such cases. Therefore, because of this frequent association, it would seem wise to bear in mind the possibility of splenic rupture with delayed hemorrhage in all patients with rib fractures on the left side.

4. It is during the so-called latent or silent period that the diagnosis of splenic rupture is most difficult or impossible and death may result from delay in operation. Close observation during this period is most essential.

5. The onset of delayed hemorrhage is usually very abrupt and is followed by the classical signs of primary rupture, i.e., shock and abdominal pain, tenderness and rigidity.

6. The pathologic changes which occur in delayed hemorrhage are described.

7. The treatment is always surgical, splenectomy being the operation of choice. The removal of the spleen does not produce any ill effects. In some instances leucocytosis and lymphocytosis have been reported for transitory periods up to six months.

8. Attention is called to the autoplastic transplantation of splenic tissue within the peritoneal cavity following splenectomy for traumatic rupture of the spleen. These implants have been observed by several authors and have been designated as "splenosis"; apparently they are more likely to occur in young individuals who survive traumatic rupture of the spleen.

9. Autoplastic transplants of splenic tissue within the peritoneal cavity assume, very likely, along with other lymphatic tissue of the body, the function of the absent spleen. However, the possible relationship between these autoplastic transplants and the disappearance of the leucocytosis and lymphocytosis is not definitely known. In this connection, attention is called to some invertebrates in which the splenic tissue is not collected into a definite organ but is found scattered beneath the serous coat of the gastrointestinal tract.

REFERENCES

1. Baker, Russell L.: Rupture of Spleen, Northwest Med. 40: 250-251, 1941.
2. Bell, E. T.: Quoted by R. C. Webb, Journal-Lancet 59: 545-547, 1939.
3. Blocker, T. G., Jr.: Traumatic Rupture of Spleen, Report of 9 Cases With Special Reference to Complete Detachment of Spleen From Its Pedicle and to Delayed Rupture, Texas State J. Med. 35: 478-483, 1939.
4. Bonfield, J. P.: Rupture of Spleen, Canad. M. A. J. 36: 290, 1937.
5. Boyd, William: The Pathology of Internal Diseases, Philadelphia, 1940, Lea & Febiger, p. 630.
6. Bronaugh, W.: Traumatic Rupture of Spleen: Case Showing Delayed Rupture With Operation and Recovery, West Virginia M. J. 31: 363-367, 1935.
7. Buchbinder, J. H., and Lipkoff, C. G.: Splenosis: Multiple Peritoneal Splenic Implants Following Abdominal Injury, SURGERY 6: 927-934, 1939.

8. Chalier, M. Andre: Le role des lesions costales dans les ruptures traumatiques de la rate, Lyon chir. 24: 69-71, 1927.
9. Deaver, J. M.: Delayed Hemorrhage Following Traumatic Rupture of the Spleen, Ann. Surg. 113: 477-480, 1941.
10. Dodd, Harold: Ruptured Spleen After Trifling Mishaps, a Record of Two Cases, Brit. M. J. 2: 1094-1095, 1934.
11. Dudgeon, Howard, Jr.: Spontaneous Rupture of the Spleen, South. M. J. 34: 1247-1249, 1941.
12. Fey, D. W., and Turow, I. L.: Traumatic Rupture of Normal Spleen With Delayed Hemorrhage, Am. J. Surg. 53: 363-366, 1941.
13. Foster, J. M., and Prey, D.: Rupture of the Spleen, Am. J. Surg. 47: 487-501, 1940.
14. Gardiner, Robert: Delayed Haemorrhage From Ruptured Spleen, Brit. M. J. 1: 416-417, 1935.
15. Ghey, P. H. R.: Rupture of Spleen From Slight Injury, Lancet 2: 628-629, 1937.
16. Guy, C. C.: Rupture of Spleen, Illinois M. J. 74: 423-428, 1938.
17. Haden, Russell L.: Selection of Cases for Splenectomy, Illinois M. J. 79: 421-426, 1941.
18. Hall, D. P.: The Spleen: A Surgical Consideration, South. M. J. 34: 566-571, 1941.
19. Hamrick, Robert A., and Bush, Jasper D.: Autoplastic Transplantation of Splenic Tissue in Man, Following Traumatic Rupture of the Spleen, Ann. Surg. 115: 84-92, 1942.
20. Harkins, Henry N.: Delayed Splenic Rupture, Am. J. Surg. 57: 159-161, 1942.
21. Hinton, Drury, and Steiner, Charles A.: Fractures of the Ribs, J. Bone & Joint Surg. 22: 597-607, 1940.
22. Hinton, Drury: Personal communication, March, 1942.
23. Hunter, E. A.: Rupture of Spleen With Delayed Hemorrhage and Spontaneous Cure, Brit. M. J. 2: 256, 1935.
24. Kracke, Roy R., and Garver, H. E.: Diseases of the Blood and Atlas of Hematology, Philadelphia, 1937, J. B. Lippincott Company, p. 218-219.
25. Lommen, Ralph G.: Delayed Rupture of the Spleen, Illinois M. J. 81: 135-139, 1942.
26. Maes, U., and Rives, J. D.: Surgery of the Spleen, Section IX in Bancroft, F. W., Operative Surgery, Vol. 1, New York, 1941, D. Appleton-Century Co., Inc.
27. McCartney, James S.: Quoted by R. C. Webb, Journal-Lancet, 59: 545-547, 1939.
28. McIndoe, A. H.: Delayed Hemorrhage Following Traumatic Rupture of the Spleen, Brit. J. Surg. 20: 249-268, 1932.
29. Naegeli, O.: Blutkrankheiten und Blutdiagnostik, ed. 5, Berlin, 1931, Julius Springer.
30. Novak, E. R.: Large Nonparasitic Cysts of the Spleen, Surg., Gynec. & Obst. 95: 586, 1927.
31. Puestow, C. B.: Traumatic Rupture of the Spleen, S. Clin. North America 20: 195-205, 1940.
32. Rousselot, L. M., and Illyne, C. A.: Traumatic Rupture of the Spleen, S. Clin. North America 21: 455-467, 1941.
33. Singer, Karl, Miller, Edward B., and Dameshek, William: Hematologic Changes Following Splenectomy in Man, Am. J. M. Sc. 202: 171-187, 1941.
34. Singleton, A. E.: Splenectomy, Surg., Gynec. & Obst. 70: 1051-1053, 1940.
35. Starr, F. N. G.: Blood Cyst of the Spleen, Arch. Surg. 98: 919, 1933.
36. Steenrod, E. J.: Traumatic Rupture of the Spleen With Delayed Hemorrhage, Am. J. Surg. 49: 129-131, 1940.
37. Webb, R. C.: Traumatic Rupture of the Normal Spleen With Delayed Hemorrhage, Journal-Lancet 59: 545, 1939.
38. Webb, R. C.: Traumatic Rupture of Normal Spleen With Delayed Hemorrhage, Minnesota Med. 22: 505-506, 1939.
39. Wells, A. G.: Rupture of the Spleen—Splenectomy—Recovery, J. Roy. Army M. Corps 60: 139-141, 1933.
40. Wenger, R. A. Lovatt: Delayed Haemorrhage From Ruptured Spleen, Brit. M. J. 1: 1253, 1936.
41. Willis, Byrd Charles, and Cole, Herman A.: Traumatic Rupture of the Spleen and Eventration of the Spleen, South. Surgeon 10: 393-408, 1941.
42. Wright, L. T., and Prigot, A.: Traumatic Subcutaneous Rupture of the Normal Spleen, Arch. Surg. 39: 551-576, 1939.
43. Ziegler, Edwin E.: Personal communication, March, 1942.

SURGICAL SIGNIFICANCE OF THE MIDDLE PALMAR SEPTUM OF THE HAND

J. Edward Flynn, M.D., Boston, Mass.

CONSIDERABLE controversy has been raised during the past few years about the middle palmar septum of the hand. Some investigators deny the existence of a middle palmar which divides the hand into two main fascial spaces. Other investigators admit the existence of this septum, but state that the septum is so thin that it can be no barrier to infection.

Kanavel described a fascial septum which arises from beneath the flexor tendons of the mid-finger, with its deep surface fusing with the fibrous tissue overlying the middle metacarpal bone. He states that this septum divides the palm into two main fascial spaces, the thenar space, and the midpalmar space.

Brickel states that in his dissections and injections no special septum was found extending from beneath the flexor tendons to the middle metacarpal bone.

METHODS

There were two methods of investigating the middle palmar septum: Anatomic dissection of hands with especial consideration of the fascial distribution and clinical study of deep fascial space infection of hands.

Anatomic Dissection.—One hundred hands were dissected with especial consideration of the fascial distribution. Anatomic dissection is considered the most important method in investigating the distribution and structure of the middle palmar septum.

Clinical Study.—One hundred cases of deep fascial space infection of the hand were studied at the Boston City Hospital. This method was of value in determining the localization and course of infections in the deep fascial spaces of the hand. This method also gives one an understanding of the adequacy of the middle palmar septum as a barrier in the prevention of spread of infection from one deep fascial space to another.

Anatomic Investigation.—Some knowledge of the entire fascial distribution of the hand is of value in arriving at an understanding of the middle palmar septum. One longitudinal and one transverse incision were carried through the center of the palm. The skin and superficial fascia were reflected backward. The superficial fascia connects the skin to the underlying palmar aponeurosis, and was found to be composed of septa which are usually longitudinal in their direction.

Received for publication, Dec. 26, 1942.

The palmar aponeurosis was cut from its proximal attachment with the palmaris longus tendon and transverse carpal ligament, also from its medial and lateral attachments, and reflected backward.

The central, medial, and lateral parts of the palmar aponeurosis have been often, and well, described. However, some attachments of the palmar aponeurosis have not been well described. The palmar aponeurosis is a part of the fibrous investment of the entire hand, and is a complicated structure in the mid-palmar region. From the superior surface of the palmar aponeurosis longitudinal septa, the superficial fascia are given off and are attached to the superjacent skin. From the distal one-third of the deep surface of the palmar aponeurosis, septa are found which become firmly attached to the subjacent interosseous and adductor fascia (Fig. 1). These septa divide the distal part of the mid-palmar space into smaller compartments. They also separate the flexor tendons from the lumbrical muscles. The central part of the palmar aponeurosis also gives off two larger septa from the medial and lateral aspects. These septa are deeply continuous with the interosseous fascia, and separate the collateral from the intermediate group of muscles of the palm.

Another distinct thin layer of fascia is found deep to the palmar aponeurosis. This is the so-called subaponeurotic layer of fascia and seems to supply the greatest confusion in descriptions of fascia of the hand (Fig. 1).

The thin subaponeurotic layer of fascia follows the internal aspect of the palmar aponeurosis, but in no place is attached to it. It is distinct over the floor as well as the roof of the palmar cavity. The thin subaponeurotic fascia surrounds and interwinds the flexor tendons and holds the tendons in a semifixed position. The middle palmar septum has its origin from the subaponeurotic fascia, beneath the flexor tendons of the mid-finger.

The Middle Palmar Septum.—A definite septum of thin fascia was found arising from subaponeurotic fascia on the undersurface of the flexor tendons of the mid-finger and attached to the periosteum of the middle metacarpal bone throughout its entire length. This surgically important septum was found in each of the 100 cases examined, and divides the palmar cavity into mid-palmar and thenar spaces (Fig. 2).

The septum extends proximally at least as far as the distal edge of the transverse carpal ligament. In 25 per cent of cases the septum extended one inch proximal to the distal edge of the transverse carpal ligament, into the carpal tunnel (Fig. 3).

The middle palmar septum assumes a definite structure. This septum is a single membrane as it leaves its attachment to the middle metacarpal bone. The distal one-half of the septum splits in a Y-shaped fashion. The medial arm of the Y is continuous with the subaponeurotic

fascia, beneath the flexor tendons of the mid-finger, as it forms the lateral boundary of the mid-palmar space (Fig. 3).

The lateral arm of the Y courses laterally as it forms part of the medial boundary of the thenar space (Fig. 4). As this lateral arm courses laterally, it surrounds the flexor tendons of the index finger, covers the adductor pollicis muscle loosely, and then continues over the lateral edge of the adductor muscle to be attached to the posterior aspect of the adductor pollicis muscle.

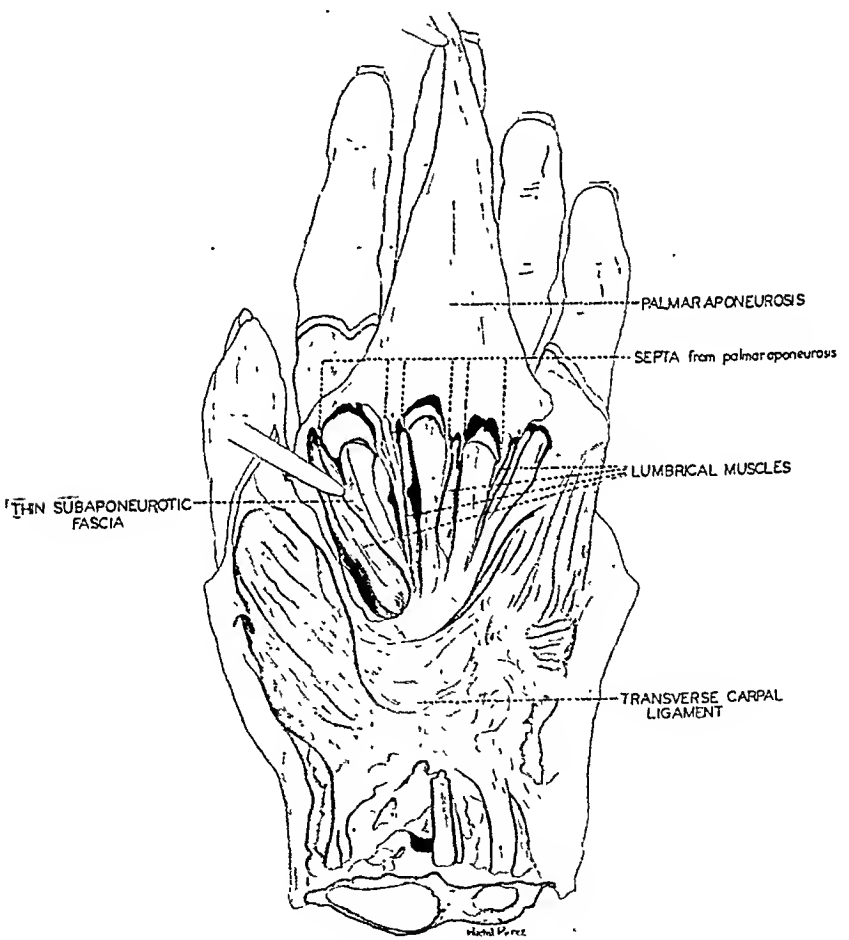

Fig. 1.—Drawing of septa from palmar aponeurosis forming compartments for flexor tendons and lumbrical muscles.

In view of the fact that this mid-palmar septum divides the palmar cavity into thenar and mid-palmar spaces, it seems appropriate to describe the boundaries of these spaces as found in the anatomic dissections.

The Mid-Palmar Space.—The mid-palmar space extends from the middle of the middle metacarpal bone to the radial side of the metacarpal bone of the little finger. The anterior boundary is formed by the flexor tendons of the middle, ring, and little fingers, the third and fourth lumbrical muscles, and the thin subaponeurotic fascia which connects these tendons and muscles. The posterior boundary is composed of fascia, covering the second and third volar interosseous muscles, and the third, fourth, and fifth metacarpal bones. The medial boundary is the fascia on the radial side of the hypothenar muscles. The lateral boundary is the middle palmar septum which extends from the undersurface of the flexor digitorum profundus tendon of the middle finger to the middle metacarpal bone. The distal boundary is composed mainly

Fig. 2.—The middle palmar septum coming from the under surface of the third flexor digitorum profundus tendon to the third metacarpal bone dividing the palm into mid-palmar and thenar spaces.

of septa which extend from the palmar aponeurosis to the floor of the space, and some transverse fasciculi. The distal boundary is found about 2 cm. proximal to the webs of the fingers. The proximal boundary is a septum of fascia found at the proximal end of the transverse carpal ligament. However, despite the location of the proximal fascial

boundary, abscesses do not tend to enter the carpal tunnel. In the distal one-third of the floor of the mid-palmar space, small compartments are formed as septa coming from the under surface of the palmar aponeurosis, and are attached to the fascia of the volar interosseous muscles (Fig. 5).



Fig. 3 —The middle palmar septum as it forms the lateral boundary of the midpalmar space.

Fig. 4.—The middle palmar septum as it forms the medial boundary and roof of the thenar space.

The Thenar Space.—The thenar space is bounded posteriorly by the adductor pollicis muscle. The medial boundary is the middle palmar septum which extends from beneath the flexor tendons of the mid-finger to the middle metacarpal bone. Proximally, the boundary is formed by thin fascia, a portion of the adductor fascia, which is found at a level of the distal edge of the transverse carpal ligament. The anterior

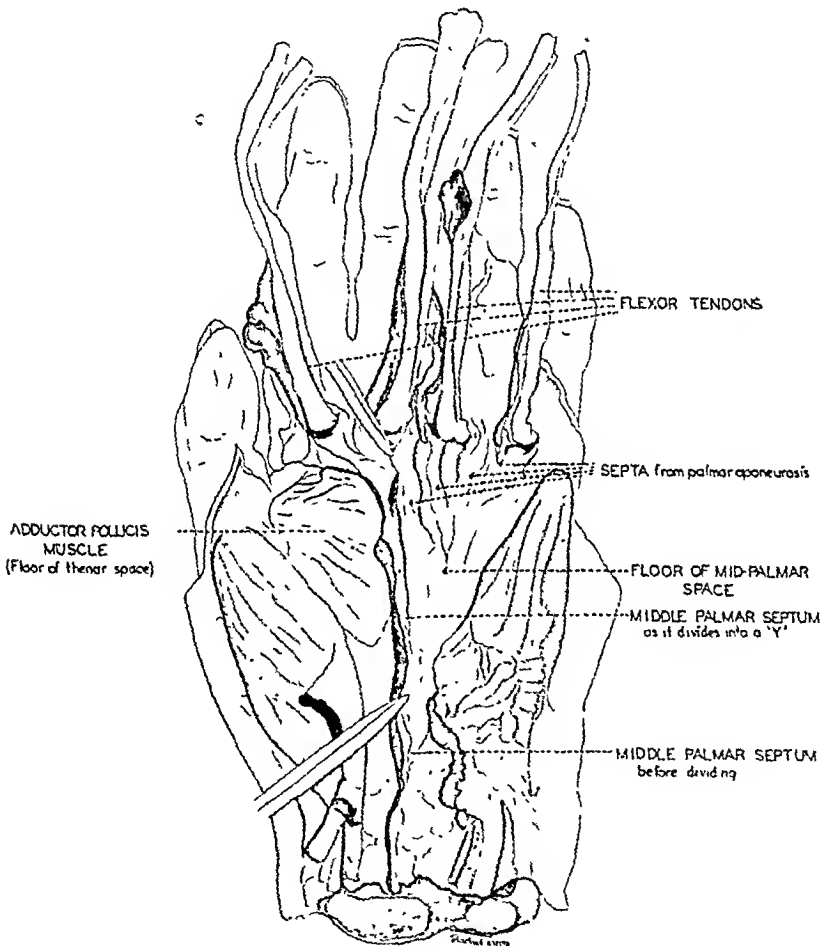

Fig. 5.—Drawing of floor of mid-palmar and thenar spaces. Septa are seen in distal one-half of mid-palmar space; the middle palmar septum is seen as it divides in a Y-shaped fashion.

boundary is the thin subaponeurotic fascia, formed as the middle palmar septum splits and courses laterally. In its lateral course, the fascia ensheaths the flexor tendons of the index finger. The lateral boundary is formed by the thin fascia as it extends over the lateral edge of the adductor pollicis muscle, and is attached to the dorsal edge of this muscle.

This distribution of fascia over the anterior lateral and dorsal aspects of the adductor pollicis muscle indicates why abscesses of the thenar space occasionally extend to the dorsal aspect of the muscle.

Clinical Study.—One hundred cases of deep fascial space infections of the hand were studied at the Boston City Hospital to determine localization.

Thenar space abscesses were encountered more than twice as frequently as mid-palmar space abscesses. In this series, the thenar space was involved in seventy cases, and the mid-palmar space in thirty cases.

Etiologically, puncture wounds were the most common causes of deep fascial space abscesses. It was interesting to note that septic tenosynovitis of the mid-finger could develop into a thenar or mid-palmar space abscess. In this series there were two cases of septic tenosynovitis of the mid-finger which developed thenar space abscesses, and two cases of septic tenosynovitis of the mid-finger which developed mid-palmar space abscesses.

Differential Diagnosis.—In all cases a definite diagnosis was made preoperatively. Tenderness over the palmar aspect of the space involved is the most important sign. Swelling is of value. With thenar space abscess, there is usually rapid increase in the size of the thenar area. There is a ballooning of the tissues from the radial longitudinal crease. With mid-palmar space abscess there is obliteration of the concavity of the palm, and a slight bulge over the palm. Swelling over the dorsum of the hand is usually extensive with both infections.

Position of the finger is of some value. With thenar space abscess the index finger is usually flexed. The middle and ring fingers may be flexed with mid-palmar space abscess.

Complications.—There was a 3 per cent mortality in this series. The causes of death were bronchopneumonia, septicemia, and uncontrolled diabetes.

There were five cases complicated by osteomyelitis. Three cases of thenar space abscess were complicated by osteomyelitis. The second metacarpal bone was involved in two cases, and both the second and third metacarpal bones were involved in one case. Two cases of mid-palmar space abscess were complicated by osteomyelitis. The third metacarpal bone was involved in one case, and the fourth metacarpal bone was involved in another.

Six cases of tendon slough occurred with thenar space abscess, and one case of tendon slough was found with mid-palmar space abscess.

In this series, there was a tendency for infections to remain localized in one space. In no case was an extension of the infection to wrist or forearm spaces found.

In two of the 100 cases, both spaces were involved. In each case the thenar space was involved first, and after extensive local necrosis the

infection spread to the mid-palmar space. In each case osteomyelitis was present.

CONCLUSION

There is a middle palmar septum extending from the undersurface of flexor tendons of the mid-finger to the middle metacarpal bone which divides the palmar concavity into thenar and mid-palmar spaces. This septum is a constant finding, and was found in each of 100 dissections.

Clinical evidence shows that the middle palmar septum is a definite barrier in preventing spread of infection from one deep fascial space to another. In only two of 100 cases were both thenar and mid-palmar space involved, and in each case osteomyelitis was present.

It may be concluded that the middle palmar septum is surgically important in mechanically and physiologically maintaining deep fascial space infections, localized to one space.

REFERENCES

1. Kanavel, A. B.: Infections of the Hand, Philadelphia, 1939, Lea & Febiger.
2. Briekel, A. C. J.: Surgical Treatment of Hand and Forearm Infections, St. Louis, C. V. Mosby Company.
3. Flynn, J. E.: Clinical and Anatomical Investigations of Deep Fascial Space Infections of the Hand, Am. J. Surg. 55: 467-475, 1942.
4. Gray, H.: Anatomy of the Human Body, Philadelphia, 1939, W. B. Saunders Company.
5. Anson, B. J., and Ashley, F. L.: Midpalmar Compartment, Associated Spaces and Limiting Layers, Anat. Rec. 78: 389-407, 1940.
6. Collander, C. I.: Surgical Anatomy, Philadelphia, 1938, W. B. Saunders Company.
7. Pemberton, P. A.: Infection of Fascial Spaces of Palm, Am. J. Surg. 50: 512-515, 1940.
8. Koch, S. L.: Prevention and Treatment of Infections of the Hand, J. A. M. A. 116: 1365-1367, 1941.
9. Wilkie, D.: Septic Hand, Brit. M. J. 12: 1127-1130, 1938.
10. Bellone, A.: Osteoaponeurotic Cavities of the Palm, Roentgen Processes, Arch. di radiol. 14: 491-495, 1939.
11. Toldt, C.: Human Anatomy, New York City, 1938, Rebman Co.
12. Von Stapelmahr, S.: Cavities of the Hand From a Surgical Point of View, Nord. med. tidskr. 10: 1341-1344, 1935.
13. Russell, E. P.: Deep Infections of Hand, J. Iowa Med. Soc. 26: 689, 1936.
14. Flack, F. L.: Fascial Space and Bursae Infections, J. Oklahoma M. A. 27: 314-318, 1936.
15. Spaulding, J. E.: Fascial Spaces of Palm: Surgical Anatomy, Guy's Hosp. Rep. 88: 432-439, 1938.
16. Garlock, J. H.: Infections of the Hand, Surg., Gynec. & Obst. 39: 165, 1924.
17. Auchincloss, H.: Surgery of the Hand, Nelson Loose-leaf Surgery 3: 459, 1927.

Recent Advances in Surgery

CONDUCTED BY ALFRED BLALOCK, M.D.

EARLY POSTOPERATIVE WALKING

II. COLLECTIVE REVIEW

BERNHARD NEWBURGER, M.D., CINCINNATI, OHIO

HISTORY

DURING the early days of modern surgery patients were kept in bed after clean laparotomies and herniorrhaphies for periods of three weeks or more. Immobility of the wound was felt to be so important that plaster spicas were applied after herniorrhaphies.[12] Even today such prolonged periods of enforced bed rest are not unheard of.[179] Rehn,[144] in 1902, sensed the danger to the patient as a whole in contradistinction to the wound itself in this regimen of immobilization and proposed respiratory and muscular activity as well as a sitting position for the patient while still confined to bed. The Spaziergang im Bett of Henle,[59, 85] conceived as a substitute for early walking, dates from before 1908.

The most violent break in traditional postoperative care had its inception in the chance observation of Emil Ries that a patient in Morrisani's clinic had a wound which healed well in spite of the patient having walked across the room the night after operation. Ries[153] began to get patients up out of bed in twenty-four to forty-eight hours after vaginal hysterectomy and soon extended the method to laparotomies. He attributed his courage to Abel, who had demonstrated that the avoidance of incisional hernia depends upon accurate layer closure and the prevention of infection.

By 1906, Ries' teachings were the subject of discussion at the Southern Gynecological Society Meeting at Baltimore.[14] It was brought out at this meeting[119] "that Dr. McDowell in reporting the case of Mrs. Crawford, who is the subject of the first ovariotomy, stated on the eighth day, he found her up making her bed. . . ."

About this time, Kümmell[100, 101] of Hamburg was practicing and strongly advocating early postoperative walking. The method received rather general acclaim in Central Europe, so that a pertinent questionnaire[172] sent to such surgeons as Bier, Koenig, v. Haberer, Witzel, and Döderlein, among others, was published in 1912.

From then on it has retained many adherents and lost some others.[65, 123] It received favorable notice in the famous surgical text of Bier, Braun, and Kümmell[10] and was discussed at many surgical meetings. The use of the method spread throughout all Europe and was reported from Africa[117] and South America.

Rather remarkably, except for the Central European Clinics about 1908 to 1912, and with the notable exception of Paul Clairmont's[1, 40] clinic in Zürich and Schumacker's at Giessen, university clinics have had no part in the development or evaluation of early postoperative walking.

Andrè Chalier[28-36] of Lyon has done much to popularize early postoperative walking in Latin countries. He considers this to mean getting patients out of bed from the second to the fifth day postoperatively. In contrast to him, Havlicek,[81, 82] Mermingas,[120, 121] and Paschoud,[130-133] among others, have, by their example and publications, advocated what is called immediate arising, that is walking from the operating table back to the room and continued activity out of bed until discharge. This method now has a fairly wide following.[24, 43, 48, 70, 156, 186]

It is of more than passing interest that this method of early mobilization of patients after operation was forced on one surgeon[4] by lack of adequate bed space in his hospital and on another by[117] the spontaneous adoption of it by his patients.

In this country, Kelly[92] reported, in 1911, that Ries' example had been followed "by others too numerous to mention." A reaction away from and disillusionment with the method were inherent in the then prevalent gross technique involving the use of coarse catgut and running sutures. Some surgeons[172, 187] kept the tradition alive in Chicago. The last few years have brought a renewal of interest.[108, 118, 125, 126, 128, 168, 187]

DEFINITION

As indicated previously, the distinction between early and immediate postoperative walking is clear. The daily postoperative continuation of bodily activity, including walking (not just being placed in a chair), self-care in matters of toilet, dressing, and feeding,[1, 4, 10, 22, 25, 26, 28-36, 40, 63, 64, 93, 94, 120, 121, 130-133, 181] and even actual gymnastics[3, 107, 158] is considered an integral part of a regimen directed toward an uncomplicated and rapid convalescence. In those cases in which early postoperative walking is contraindicated, deep breathing and leg exercise in bed are substituted for it by most of those who have written on the subject. If an arbitrary temporal limit is set, early postoperative walking may be said to mean walking within the first twenty-four hours postoperatively. The rationale for this time limit lies in Henle's[81] demonstration, in 1900, that pulmonary complications occur largely within forty-eight hours[170] after operation, the belief that other complications appear or have their silent inception within a few hours after operation if not during the actual operation itself, and certain observations on the physiology of rest and exercise which will be mentioned later.

INDICATIONS, CONDITIONING CIRCUMSTANCES, AND CONTRAINDICATIONS

Aseptic operations with firm closure of the incision are ideal for the use of early postoperative walking.[10, 28, 40, 63, 93, 94, 100, 101, 130-133, 153, 158, 183] Some[24, 25, 26, 183] have extended it, however, even to drained wounds. Neither the length of the incision nor its location has any bearing on the problem.[40] It is of importance mainly in laparotomies and herniorrhaphies because of the ensuing high incidence of the so-called postoperative syndrome.[95] Therefore, it is only in connection with them that the method is here considered.

Local anesthesia permits immediate or early postoperative walking at any elected time. Other anesthetics require a variable recovery period; none, though, except in the presence of complications, longer than twelve to twenty-four hours. Some[23, 61] consider a special suture technique imperative; this opinion, however, is not generally held. The need of scrupulous attention to hemostasis as well as to other surgical fundamentals scarcely merits mention.

The obvious contraindications[24, 43, 64, 138] to the use of the method fall into two categories—general and local. Cardiac insufficiency, shock, severe anemia or cachexia, hemorrhage or the fear of hemorrhage, the presence or even possible presence of thrombi or emboli, as well as prolonged preoperative bed confinement make up the first group. To the second belong such suppurative conditions as peritonitis, cholangitis, pancreatitis, and liver infections. To these may be added potentially infected incisions and insecure gastroenteric anastomoses, such as occur, for example, in resection for exclusion of duodenal ulcer or in colon resections. Copious tamponade also precludes early postoperative walking, but a simple telltale drain through a stab wound, such as is commonly practiced after cholecystectomy, does not.

Such complications as postspinal-anesthesia headache, unexpected wound infection, or other complications[4] may force the return to bed of patients who have been up and walking.

ADVANTAGES OF EARLY WALKING

Although some[67, 162] merely admit the basic correctness of the principle of early postoperative walking, but apparently rarely use it, certain favorable results are almost universally cited.[1, 4, 6, 10, 13, 15, 16, 18, 19, 20, 24-38, 40-43, 45, 46, 48, 50-54, 56, 59, 62, 63, 70-72, 76, 78, 81, 82, 87, 93, 94, 100, 101, 105, 107, 110-112, 116, 117, 120, 121, 124, 130-133, 137, 138, 147, 148, 150, 151, 153, 155, 157-159, 161, 167, 182, 183, 185, 186] They are as follows:

1. Asthenia is avoided. This has impressed all who have used the method. Floercken,[63] indeed, compared patients with general surgical conditions of the abdomen to patients with fractures who, treated by Boehler's technique, are considered "not sick but healthy men who only accidentally had the misfortune of breaking a bone."

2. Morale of the patient is greatly lifted by the feeling that since he is up and leading a relatively normal life the dangers of the operation and the discomforts of the postoperative period are over or have been unduly exaggerated.

3. Economy to both patient and hospital is attained through the more rapid convalescence, discharge, and return to work, and through the reduction in the needed nursing personnel and the more efficient use of bed space.

4. Military surgery may be rendered less hazardous.[25, 168]

5. Simplification of postoperative care is attained.

6. Pulmonary complications are reduced four- to fivefold.[138] Kimbarovskiy's[94] comparative series is most striking. This marked diminution is readily credible since this same prophylactic course has been suggested by conservative surgeons[129] for years in both elderly patients and after gastric resections where the danger of pulmonary complications is high. It is for this reason the more surprising, that, recognizing the value of having patients out of bed in these restricted groups, this knowledge has not been applied to other groups of patients of only slightly less risk. Even with the lowering of mortality from pneumonia attained by use of the sulfonamide drugs, a drop of morbidity such as is indicated from the use of early postoperative walking should be welcome.

Certain other benefits said to occur from the use of early postoperative walking are either less apparent than the above or might be more difficult to demonstrate.

7. Polichetti,[138] for example, claims a reduction of adhesions.

8. Chalier[28] believes that operability is extended to Rehn's embolic type.

9. Many[4, 10, 13, 14, 24-26, 28, 47, 40, 41, 45, 48, 49, 62, 64, 70, 76, 80, 90, 93, 94, 99, 100, 101, 104, 110, 111, 120, 121, 130-133, 135, 138, 153, 155, 158, 163, 165] call attention to the absence of hollow viscus atony with the consequent avoidance of the use of catheter and laxative.

10. Still another contention[98, 100] to the effect that laparotomy and herniorrhaphy wounds heal more benignly and rapidly with the motion of early postoperative walking than with immobilization has received experimental corroboration.[124]

11. Lastly, the moot but most important question of reduction of thrombosis and embolism is bound up with early postoperative walking. Of the three major factors commonly premised in the etiology of inferior caval tributary thrombosis, decreased rate of venous return is felt by many to be the most important and is the one affected by early postoperative walking. Vein wall trauma can be controlled only by careful operative technique. Through the use of heparin and dicoumarin, pos-

sibly along the lines indicated by Bergquist,[8] changes in prothrombin time give promise of being brought under prophylactic restraint. No matter what progress may be made in influencing the last two factors, and they should not, of course, be neglected, neither can the first be neglected with impunity. Previous attempts, such as those of Lennander,[109] Rehn,[144, 145] Henle,[85] Payr,[134] and Frykholm,[68] and the rediscoverers or modifiers[69, 139, 141] of their methods, to decrease venous stasis and so thrombosis by position or bed exercise, have so far apparently failed.[134] Barnes[5] found that, after the use of measures directed at the prophylaxis of thrombosis and embolism, such as active and passive leg exercises in bed, massage of the lower extremities and deep breathing, pulmonary embolism, over a ten-year period, still accounted "for 5.8 per cent of our surgical deaths despite our efforts at prevention." Actual walking, however, is said by many[1, 26, 28, 76, 89, 90, 103, 113, 124, 138, 154, 160, 164, 169, 183] to minimize the occurrence of thrombosis, both the dangerous latent or silent kind and the classical saphenous and femoral. Schumacker's[160] careful extensive study deserves special mention. Nehrkorn's[124] reduction of both thrombi and emboli by one-third in a series of 4,600 laparotomies must also be singled out, as should Stich's[169] experience. Possibly Chalier[28] is correct in saying that if early postoperative walking does not entirely circumvent thrombus formation it surely does not "assist in a cataclysmic accident but in the migration of embolic showers without danger to life. Actually those emboli that kill demand from the first a larger thrombus which does not form without a number of days of immobility. . . ." Nonetheless, others[9, 45, 46, 55, 56, 83, 97, 102, 127, 134, 174, 178, 186, 189] doubt the ability of early postoperative walking to combat the occurrence of emboli or have seen fatal emboli occur in spite of its use. Whether this was due to too tardy a use of the method cannot be ascertained. Most of these patients were out of bed on the third postoperative day. As Folliasson and Baudry[64] noted, "venous stasis has had time to have effect" in cases so long in bed. Von Jasehke,[89] with an extensive statistical background, claimed that postponement of early postoperative walking from the second to the third postoperative day increased the incidence of thrombosis. Loute and Machurot[113] confirm this. Further, the preoperative existence of thrombi in these fatal cases cannot be excluded and there is no good reason to believe that the embolism might not have as readily occurred on the operating table as after early postoperative walking.[136] All things considered, though, the effect is most likely prophylactic to a degree. Final judgment in this matter will rest on future well-controlled clinical observations duplicating and extending those of Schumacker. This will, of course, entail thorough statistical breakdown. Even if early postoperative walking does not prove to be a safeguard against thrombo-embolism, its other proved advantages would seem to make it worthy of extensive adoption.[46, 56, 149]

THE PHYSIOLOGY OF REST AND EXERCISE WITH ITS IMPLICATIONS TOWARD PULMONARY AND VASCULAR COMPLICATIONS AND EARLY POSTOPERATIVE WALKING

Postoperative hypoventilation, with its potential consequent atelectasis and pneumonia, is well known, varying from 50 per cent in inguinal herniorrhaphies and McBurney incisions to as high as 66 per cent in upper abdominal operations.[142] The recumbent position in itself reduces vital capacity more than 15 per cent.[114] There is some doubt as to whether moderate exercise increases vital capacity or not, but it is known that a ninefold increase in resting ventilation is possible.[91] Ellis[58] found no increase in vital capacity in normal subjects. However, Khromov[93] found a lessened reduction of vital capacity and a more rapid return to normal with the use of early walking in postoperative patients. Further, Coryllos[44] believed that the recumbent position decreased the efficiency of the cough reflex. Possibly having a bearing on the incidence of postoperative lung complications is the fact that the following values are increased by mild exercise: tidal volume, ventilation coefficient, alveolar oxygen tension, and the oxygen content and saturation of arterial blood.[91]

The contention of Virchow and Aschoff that retardation of the venous circulation is the basic cause of thrombus formation is conceded,[5, 8, 89, 128, 163, 165, 181] either in its original or modified form. After operation, a high degree of slowing of venous return is known to occur.[165] On the other hand, the foot-carotid sinus time is decreased by elevation of the feet or by exercise in the supine position.[166] The decrease in the arm-carotid sinus time is marked[58] with exercise. It is not known how great the increase in the velocity of venous return from the foot is with walking. Presumptively, it is more marked than the findings of Smith, Allen, and Craig would indicate and of even a higher order than found in bicycling by Ellis for the arm-carotid sinus time. The admitted increase in cardiac output with exercise confirms the increase in venous return. Muscle activity of the lower extremities is known to have an accessory "peripheral heart" effect.[7]

WOUND HEALING AND WOUND COMPLICATIONS AS EFFECTED BY EARLY POSTOPERATIVE WALKING

Function[184] and rest have both, paradoxically, been accorded great importance in growth and the healing of wounds. Larrey has been cited[146] as the outstanding early advocate of rest, yet the following passage[106] from his works bearing on the evacuation of the wounded from the battlefield can scarcely be so construed: "The wounded should be removed to different places immediately after an engagement. The exterior and interior motion, which takes place while transporting them from one place to another, excites and promotes the functions of the organs; all the muscles are in motion, the circulation is accelerated, and

sibly along the lines indicated by Bergquist,[8] changes in prothrombin time give promise of being brought under prophylactic restraint. No matter what progress may be made in influencing the last two factors, and they should not, of course, be neglected, neither can the first be neglected with impunity. Previous attempts, such as those of Lennander,[109] Rehn,[141, 145] Henle,[85] Payr,[134] and Frykholm,[68] and the rediscoverers or modifiers[69, 139, 141] of their methods, to decrease venous stasis and so thrombosis by position or bed exercise, have so far apparently failed.[124] Barnes[5] found that, after the use of measures directed at the prophylaxis of thrombosis and embolism, such as active and passive leg exercises in bed, massage of the lower extremities and deep breathing, pulmonary embolism, over a ten-year period, still accounted "for 5.8 per cent of our surgical deaths despite our efforts at prevention." Actual walking, however, is said by many[1, 26, 28, 76, 89, 90, 103, 113, 124, 138, 154, 160, 164, 169, 183] to minimize the occurrence of thrombosis, both the dangerous latent or silent kind and the classical saphenous and femoral. Schumacker's[160] careful extensive study deserves special mention. Nehrkorn's[124] reduction of both thrombi and emboli by one-third in a series of 4,600 laparotomies must also be singled out, as should Stich's[169] experience. Possibly Chalier[28] is correct in saying that if early postoperative walking does not entirely circumvent thrombus formation it surely does not "assist in a cataclysmic accident but in the migration of embolic showers without danger to life. Actually those emboli that kill demand from the first a larger thrombus which does not form without a number of days of immobility. . . ." Nonetheless, others[9, 45, 46, 55, 56, 83, 97, 102, 127, 134, 174, 178, 186, 189] doubt the ability of early postoperative walking to combat the occurrence of emboli or have seen fatal emboli occur in spite of its use. Whether this was due to too tardy a use of the method cannot be ascertained. Most of these patients were out of bed on the third postoperative day. As Folliasson and Baudry[64] noted, "venous stasis has had time to have effect" in cases so long in bed. Von Jaschke,[89] with an extensive statistical background, claimed that postponement of early postoperative walking from the second to the third postoperative day increased the incidence of thrombosis. Loute and Machurot[111] confirm this. Further, the preoperative existence of thrombi in these fatal cases cannot be excluded and there is no good reason to believe that the embolism might not have as readily occurred on the operating table as after early postoperative walking.[136] All things considered, though, the effect is most likely prophylactic to a degree. Final judgment in this matter will rest on future well-controlled clinical observations duplicating and extending those of Schumacker. This will, of course, entail thorough statistical breakdown. Even if early postoperative walking does not prove to be a safeguard against thrombo-embolism, its other proved advantages would seem to make it worthy of extensive adoption.[46, 56, 149]

less moment, are that patients are too miserable postoperatively to be subjected to any activity,[92] that bed rest is of value to laborers,[17] and that the heart is weakened[88] or that the cardiac minute volume is reduced[79] following operation. They have all been proved, with more or less certainty, to be fallacious.

REFERENCES

1. Abel, A. L.: Comfort After Laparotomy, Post-Grad. M. J. 13: 435, 1937
2. Aievoli, E.: Sulla precoce levata dei laparotomizzati, Morgangni 76: 968, 1934.
3. Alimova: Cited by Salischew and Aisiks.[158]
4. Backer-Grondahl, N.: Liggetiden efter operasjoner, Nord. med. 3: 2630, 1939.
5. Barnes, A. R.: Pulmonary Embolism, J. A. M. A. 109: 1347, 1937.
6. Baumecker, H.: Ruhe und Bewegung als Heilmittel und Schaedigung in der Chirurgie, Med. Klin. 35: 1044, 1939.
7. Best, C. H., and Taylor, N. B.: The Physiological Basis of Medical Practice, Ed. 2, Baltimore, 1939, Williams & Wilkins Company, p. 216.
8. Bergquist, G.: Über post-operative Thrombosen, Acta chir. Scandinav. 83: 415, 1940.
9. Bier: Cited by de Quervain.[143]
10. Bier, Braun, and Kümmell: Operationslehre, Ed. 4, vol. 3, Leipzig, 1923, Johann Ambrosius Barth, p. 55.
11. Billroth, T.: Die allgemeine chirurgische Pathologie und Therapie, Berlin, 1882, G. Reimer, p. 120.
12. Bloodgood, J. C.: Operations on 459 Cases of Hernia in the Johns Hopkins Hospital from June, 1889, to January, 1899. The Special Consideration of 268 Cases Operated on by the Halsted Method, and the Transplantation of the Rectus Muscle in Certain Cases of Inguinal Hernia in Which the Conjoined Tendon Is Obliterated, Johns Hopkins Hosp. Rep. 7: 223, 1898-99.
13. Boldt, H. J.: The Management of Laparotomy Patients and Their Modified After-Treatment, New York State J. Med. 85: 145, 1907.
14. Boldt, H. J.: How Long Must Patients Observe Absolute Rest in Bed After Abdominal Operations? Tr. Am. Gynec. Soc. 32: 181, 1907.
15. Brisset: Cited by Chalier.[36]
16. Brothers: Cited by Tovey.[171]
17. Buedinger, K.: Über das Aufstehen nach chirurgischen Operationen, Wien. klin. Wchnschr. 21: 1694, 1908.
18. Carvalho: Cited by Correa.[43]
19. Cachin: Cited by Salischew and Aisiks.[158]
20. Čacin, W., and Čacina, E.: Cited by Mermingas.[120]
21. Caeiro, J. A.: El levantamiento inmediato de los operados, Bol. y trab., Soc. de cir. de Buenos Aires 20: 365, 1936.
22. Calcagno, B. N.: El lavantamiento inmediato de los operados, Bol. y trab., Soc. de cir. de Buenos Aires 20: 442, 1936.
23. Camargo, J.: Levontar precoce dos laporatomizados, Brasil-med. 40: 31, 1926.
24. Campeanu, L.: 1300 operati si alzano direttamente dal tavlo operatorio. Il Movimento promotore della guarigione, Arch. ital. di chir. 51: 12, 1938.
25. Campeanu, L.: Le lever précoce des opérés in liaison avec l'evacuation des blesses, Presse méd. 45: 1208, 1937.
26. Campeanu, L., and Papp, M.: Die Wichtigkeit des Fruehaufstehens Bauchoperierter, Zentralbl. f. Chir. 64: 1573, 1937.
27. Cecchini, N.: Alzata precoce degli operati, Bollettino 11: 49, 1937.
28. Chalier, A.: La methode du lever précoce en chirurgie abdominale, Lyon chir. 31: 261, 1934.
29. Chalier, A.: Le lever précoce après les opérations abdominales, Lyon chir. 26: 834, 1929.
30. Chalier, A.: L'embolie post-opératoire mortelle, Lyon chir. 26: 865, 1929.
31. Chalier, A.: Au sujet du lever précoce après les laparotomies, Lyon chir. 27: 387, 1930.
32. Chalier, A.: Le bilan de la méthode du lever précoce en chirurgie abdominale après 4 ans, Lyon chir. 30: 122, 1933.

the secretions go on. Suppuration takes place in a proper degree; the sloughs are soon detached by the increased oscillation of the subjacent vessels, the wounds become clean, their edges develop, and approach each other by the gradual expansion of the vessels; and by this gradual excitement they close together, or contract adhesions by means of the slight inflammatory swelling which succeeds." Whether Larrey did or did not hold rest as an essential in wound healing, Billroth[11] unquestionably did and it was probably he who most greatly influenced modern American and European surgeons. The present attitude of the majority toward this problem, obviously the major deterrent to the use of early postoperative walking[23, 26, 73, 81, 94, 97, 176, 183] may best be epitomized by quoting Pool[139] to the effect that "a fairly prolonged stay in bed after celiotomy (usually from one to two weeks) is recommended by most surgeons, largely that the coapted tissues may unite firmly before considerable strain is allowed to bear on them. On the other hand, some surgeons, among whom is Kümmell, advise getting patients out of bed as early as the first day after a celiotomy. But it is manifest that a premature rising from bed is done at the sacrifice of proper wound repair which demands rest of the parts involved, and this can be secured in many classes of operations only by confinement to bed for a reasonable length of time. The adoption of exercises during this period provides almost all the advantages gained by a shortened stay in bed, without interfering with the best conditions for the repair of the wound." This prevalent fear of wound rupture as a consequence of early postoperative walking may well date from the tragic experiences of some of the early surgeons, who, as described by Koenig,[96] in 1905, "were delighted they could operate on the belly and even more delighted if they could operate even during their office hours and treat their patients as ambulant. That was the time when one could find perhaps a dozen reports in a journal as follows: laparotomy, oophorectomy, discharge in eight days. On the tenth day they come back to the hospital with their guts in a cloth. This era lasted roughly till the beginning of the eighties." Contrary to this orthodox opinion those who have used early postoperative walking have found no resulting deleterious effect such as increase in incisional pain, dehiscence, or incisional hernia[1, 4, 23, 26, 28, 64, 76, 82, 86, 94, 125, 135, 138, 157, 158, 180, 183, 185, 187] while others, as noted, have claimed even a smoother and more rapid healing. Too few detailed reports[38, 125] pertinent to this important phase of the subject exists, and, here again, definitive judgment must await their appearance.

OBJECTIONS TO THE USE OF EARLY POSTOPERATIVE WALKING

Most of the objections are theoretic,[2, 21, 22, 30, 47, 60, 66, 74, 122, 173, 175, 177, 178] while others have been arrived at after experience. Two are failure to protect against fatal emboli and interference with wound healing, bound up with the fear of medicolegal consequences.[17] Others, of much

70. Gautier, J.: La chirurgie sous les rayons infra-rouges et ultra-violets, Gaz. méd. de France 44: 791, 1937.
71. Getota and Budescu: Cited by Floercken.[63]
72. Ghiron: Cited by Coniglio.[42]
73. Gibbon, J. H.: Postoperative Treatment, Ann. Surg. 46: 298, 1907.
74. Goldspohn, A.: Discussion of Chase, W. B.[39]
75. Gregoire: Cited by Chalier.[36]
76. Gullotta, G.: Il "lever precoce" degli operati, Minerva med. 26: 322, 1935.
77. Häberlin: Zum Frühaufstehen nach Operationen und Geburten, Schweiz. med. Wchnschr. 50: 148, 1920.
78. Hanselmann, M.: Cited by Ducuing and Guilhem.[56]
79. Harild, S.: Om sengelejets varighed efter operationer, Nord. med. 4: 2988, 1939.
80. Hartog, C.: Das frühe Aufstehen nach Laparotomien, Berl. klin. Wchnschr. 46: 492, 1909.
81. Havlicek, H.: Das Sofortaufstehen nach Bauch-operationen, Arch. f. klin. Chir. 183: 42. 1935
82. Havlicek, H.: U. V. Strahlen-Behandlung der eitrigen Peritonitis, Copenhagen, 1932, 2nd Cong. internat. de la Lumiere.
83. Hell: Cited by de Quervain.[143]
84. Henle: Über Pneumonie und Laparotomie, Verhandl. d. deutsch. Gesellsch. f. chir. 30 (pt. 2): 240, 1901.
85. Henle: Discussion of papers of Trendelenburg et al., Verhandl. d. deutsch. Gesellsch. f. chir. 37 (pt. 1): 13, 1908.
86. Henriksen, E.: The Role of the Superior Hypogastric Plexus in Gynecology. West. J. Surg. 49: 1, 1941.
87. Herff: Cited by Loute and Machurot.[113]
88. Hofmann, W.: Über das Frühaufstehen nach Operationen, Berl. klin. Wchnschr. 51: 354, 1914.
89. v. Jaschke, K. T.: Theorie und Praxis in der Frage der postoperativen (und puerperalen) Thrombose und Embolie, Arch. f. Gynäk. 129: 951, 1926-27.
90. Jeanneney, G.: Le lever précoce, Bull. et mém. Soc. nat. de chir. 59: 1214, 1933.
91. Kaltreider, N. L., and McCann, W. S.: Respiratory Response in Emphysema, J. Clin. Investigation 16: 36, 1937.
92. Kelly, H. A.: Getting Up Early After Grave Surgical Operations, Surg., Gynec. & Obst. 13: 78. 1911.
93. Khromov, B. M.: Postoperative Function of the Lungs With Early Rising, Sovet. khir. 9: 389, 1936.
94. Kimbarovskiy, M. A.: Early Rising in the Post-operative Period, Novy khir. arkhiv. 35: 57, 1935.
95. King, D. S.: Postoperative Pulmonary Complications, J. A. M. A. 100: 21, 1933.
96. Koenig: Discussion Madelung, O.[115]
97. Koerte: Discussion of papers of Trendelenburg, Kümmell, Frankel, and Ranzi, Verhandl. d. deutsch. Gesellsch. f. chir. 37 (pt. 1): 13, 1908.
98. Kohlschnetter: Ein Wort zur Frage des fruehen Aufstehens nach Bauch-operationen. Eine eigene Erfahrung, München. med. Wchnschr. 60: 1379, 1913.
99. Krecke, A.: Über Vor- und Nachbehandlung bei Bauch-operationen, inbesondere über das fruhzeitige Aufstehenlassen. München. med. Wchnschr. 57: 2037, 1910.
100. Kummell, H.: Abkurzung des Heilungsverlaufs Laparotomierter durch frühzeitiges Aufstehen. Arch. f. klin. Chir. 86: 494, 1908.
101. Kummell, H.: Weitere Efahrungen über frühzeitiges Aufstehen Laparotomierten zur Sicherung und Abkürzung des Heilverfahrens, Deutsche med. Wchnschr. 35: 1865, 1909.
102. Kuettner, H.: Umfrage.[172]
103. Kunz, W.: Die postoperativen Thrombosen und Lungenembolien auf der chirurgischen Klinik des St. Marienkrankenhauses zu Frankfurt A. M. in den Jahren 1921-1929, Beitr. z. klin. Chir. 155: 453, 1932.
104. Laduron: Les irradiations infra rouges et ultra-violettes dans les interventions chirurgicales, J. de chir. et ann. Soc. belge de chir. 36: 546, 1937.
105. Lambret: Cited by Jeanneney.[90]
106. Larrey, D. J.: Mémoires et chirurgie militaire, et campagnes, Vol. 3, Paris, 1812, J. Smith & F. Buisson, p. 45.

33. Chalier, A.: La prèvention et le traitement abortif des phlébites post-opératoires, Presse méd. 46: 1345, 1938.
34. Chalier, A.: Le lever précoce des operes de l'abdomen, Avenir méd. 29: 251, 1932.
35. Chalier, A.: Sur la prophylaxie des phlèbites et embolies post-opératoires en gynécologie, Bull. et mém. Soc. nat. de chir. 57: 216, 1931.
36. Chalier, A.: Le lever précoce en chirurgie abdominale, Bull. et mém. Soc. nat. de chir. 59: 1211, 1933.
37. Charbonnier, A.: Le lever précoce en chirurgie abdominale, Helvet. med. acta. 2: 182, 1935.
38. Charbonnier, A.: La méthode du lever précoce en chirurgie abdominale, Rec. méd. de la Suisse Rom. 55: 402, 1935.
39. Chase, W. B.: The Mobility of the Patient After Laparotomy, Am. J. Obst. & Gynec. 58: 790, 1908.
40. Clairmont, H. E.: Shortening of Postoperative Convalescence, Lancet 1: 487, 1922.
41. Cohn, F.: Das Fruehaufstehen der Laparotomierten, Zentralbl. f. Gynäk. 32: 1233, 1908.
42. Coniglio, G.: Sopra L'alzata precoce degli operati, Riv. san. siciliana 23: 120, 1935.
43. Correa, B.: Lever précoce et lever immediat de nos operes, Lyon chir. 34: 37, 1937.
44. Coryllos, P. N.: Postoperative Pulmonary Complications and Bronchial Obstruction, Surg., Gynec. & Obst. 50: 795, 1930.
45. Cotte, G.: Embolie mortelle au 8e jour chez une malade levée precocement, Lyon chir. 36: 441, 1939.
46. Cotte, M. G.: Le lever précoce dans la chirurgie gynècologique, Bull. et mém. Soc. nat. de chir. 60: 358, 1934.
47. Crossen, H. S., and Crossen, R. J.: Diseases of Women, Ed. 9, St. Louis, 1941, C. V. Mosby Company.
48. Cvitanovitch: Le lever immediat des operes, Presse méd. 45: 1471, 1937.
49. Daumierie, L.: A propos du lever précoce, Bruxelles-méd. 18: 534, 1938.
50. Delagénière, H.: Du lever précoce chez les malades qui ont subi une opération chirurgicale, Arch. méd. d'Angers 14: 185, 1910.
51. Delagénière, Y.: Note sur la vieille methode du lever précoce des opérés, et sur son complément la gymnastique au lit, Presse méd. 42: 1669, 1934.
52. Delbet: Cited by Ducuing and Guilhem.[56]
53. Dell'Oro and Corones: Cited by Floercken.[63]
54. Le Dentu: Cited by Ducuing and Guilhem.[56]
55. Devraigne, L.: Le lever précoce des accouchées et des opérées, Médecine 1: 434, 1919-20.
56. Ducuing, J., and Guilhem, P.: Lever precoce et "Promenade au Lit" dans le traitement des phlébites chirurgicales et obstetricales, J. méd. franç. 23: 74, 1934.
57. Duval: Cited by Jeanneney.[90]
58. Ellis, L. B.: Circulatory Adjustments to Moderate Exercise in Normal Individuals, With Particular Reference to the Interrelation Between the Velocity and Volume of the Blood Flow, Am. J. Physiol. 101: 494, 1932.
59. v. Eiselsberg: Discussion of papers of Trendelenburg, Kümmell, Frankel, and Ranzi, Verhandl. d. deutsch. Gesellsch. f. chir. 37 (pt. 1): 21, 1908.
60. Fasiani: Cited by Cecchini.[27]
61. Ferguson, L. K.: Discussion of McCloskey, J. F., and Lehman, J. A.[118]
62. Finsterer: Cited by Chalier.[28]
63. Floercken, H.: Über das Aufstehen nach chirurgischen Operationen, München. med. Wchnschr. 83: 917, 1936.
64. Folliasson, A., and Baudry, G.: Le lever précoce en chirurgie abdomino-pelvienne, Gaz. méd. de France, 1933, p. 679.
65. Forgue, E.: Après la laparotomie, Ann. de gynée. et d'obst. 72: 1, 1916-17.
66. Frederick, C. C.: The Care of Patients After Abdominal Section, J. A. M. A. 51: 834, 1908.
67. Friedemann, M.: Nachbehandlung nach Operationen, Zentralbl. f. chir. 63: 2412, 1936.
68. Frykholm, A.: The Pathogenesis and Mechanical Prophylaxis of Venous Thrombosis, Surg., Gynec. & Obst. 71: 307, 1940.
69. Gamble, H. A.: The Prevention of Postoperative Embolism and Thrombosis: With Description of Apparatus Employed, Am. J. Surg. 28: 93, 1935.

141. Potts, W. J., and Smith, S.: Pulmonary Embolism. An Experimental Study of Variations in the Volume Blood Flow in the Inferior Vena Cava of the Dog, Arch. Surg. 42: 661, 1941.
142. Powers, J. H.: Vital Capacity. Its Significance in Relation to Postoperative Pulmonary Complications, Arch. Surg. 17: 304, 1928.
143. de Quervain, F.: Thrombose et embolie post opératoires, Schweiz. med. Wchnschr. 55: 497, 1925.
144. Rehn: Über die Behandlung infectiös eitriger Processe im Peritoneum, Arch. f. Klin. Chir. 67: 790, 1902.
145. Rehn: Discussion of papers of Trendelenburg, Kummell, Frankel, and Ranzi, Verhandl. d. deutsch. Gesellsch. f. chir. 37 (pt. 1): 13, 1908.
146. Reid, M. R.: Some Considerations of the Problems of Wound Healing, New England J. Med. 215: 703, 1936.
147. Reinking, J. J.: Bestrahlung wachrend der operation mit Ultraviolett nach Havlicek, Zentralbl. f. Chir. 64: 1579, 1937.
148. Reynès, H.: Bon effets du lever precoce des laparotomisés, 17th Internat. Cong. Med., London, 1913, Sect. Obst. and Gynec., part 2, p. 249.
149. Ricard, P.: Embolies et lever precoce, Lyon chir. 36: 448, 1939.
150. Ricci, G.: Sobre el levantamiento inmediato de los operandos, An. de cir. 2: 175, 1936.
151. Ricciordelli: Cited by Coniglio[42].
152. Richter, H. M.: Personal communication.
153. Ries, E.: Some Radical Changes in the After Treatment of Celiotomy Cases, J. A. M. A. 33: 454, 1899.
154. Ritter: Cited by Loute and Machurot[113].
155. Robertson, G.: Short Hospital Convalescence Following Common Abdominal Operations, Practitioner 119: 162, 1927.
156. Rost: Neue Gesichtspuncte bei der Vor- und Nachbehandlung Operierter, Arch. f. klin. Chir. 148: 30, 1927.
157. Rowlands, R. P.: The Value of Freedom and Exercise After Operation, Brit. M. J. 1: 52, 1922.
158. Salischew, B. E., and Arsiks, I. T.: The Active Method in the Postoperative Period, Novy klin. arkhiv. 35: 260, 1936.
159. Sauve: Cited by Chaher.
160. Schumacker, P.: Über die Ursachen der postoperativen und puerperalen Thrombose und Embolie. Ein Beitrag auf Grund Klinischer Beobachtung, Arch. f. Gynäk. 129: 929, 1926-27.
161. Schweninger, F.: Cited by Ducuing and Guilhem[56].
162. v. Seemen, H.: Operation und Gewebeschonung. II. Teil. Beziehungen zwischen Operationswunde und Entstehung, Vermeidung und Bekämpfung der mittelbaren Operationschaedigungen (spontan Venenthrombose und Pneumonie), Deutsche Ztschr. f. Chir. 223: 85, 1930.
163. Silberberg, M.: The Causes and Mechanism of Thrombosis, Physiol. Rev. 18: 197, 1938.
164. Siller: Cited by Loute and Machurot[113].
165. Smith, L. A., and Allen, E. V.: Circulation Time From Foot to Carotid Sinus and From Arm to Carotid Sinus of Man. II. Effects of Operation and of Administration of Thyroid Gland, Postoperative Phlebitis and Pulmonary Embolism, Arch. Surg. 41: 1377, 1940.
166. Smith, L. A., Allen, E. V., and Craig, W. McK.: Time Required for Blood to Flow From the Arm and From the Foot of Man to the Carotid Sinuses. I. Effect of Temperature, Exercise, Increased Intramuscular Tension, Elevation of Limbs and Sympathectomy, Arch. Surg. 41: 1366, 1940.
167. Smith, P.: Le lever precoce en chirurgie abdomino-pelvienne (Étude basée sur 900 cas personnels), Union med. du Canada 69: 921, 1940.
168. Sparkman, R. S., and Williams, W. H.: The Employment of Cotton Suture Material in the Field, SURGERY 11: 698, 1942.
169. Stich, R.: Post-operative Embolie, Arch. f. klin. Chir. 183: 301, 1935.
170. Tondeur, P.: Les complications respiratoires après les interventions chirurgicales, J. de chir. et ann. Soc. belge de chir. 36: 177, 1937.
171. Tovey, D. W.: Ten Years Experience With Early Mobilization After Abdominal Pelvic Operations, Am. J. Obst. 77: 237, 1918.
172. Umfrage über das Frühaufstehen nach Operationen und Geburten, Med. Klin. 8: 1499, 1912.
173. Vance, J.: How Long Shall the Patient Stay in Bed After Abdominal Section? New York State J. Med. 85: 302, 1907.

107. Lebedov, J. F.: Cited by Salischew and Aisiks.[158]
108. Leithauser, D. J., and Bergo, H. L.: Early Rising and Ambulatory Activity After Operation; A Means of Preventing Complications, Arch. Surg. 42: 1086, 1941.
109. Lennander, K. G.: Über die Moeglichkeit Thrombose in den Venen der unteren Extremitaeten nach Operationen zu verhueten, nach denen langeres still-Liegen noethig ist, Zentralbl. f. Chir. 26: 553, 1899.
110. Leriche, R.: Des moyens de réduire au minimum la malade postoperatoire. De l'operation sous rayons infra-rouges, Rev. de chir., Paris 74: 99, 1936.
111. Lino, G.: Su L'alzata precoce degli operati, Ann. ital. di chir. 13: 1178, 1934.
112. Lino, G.: Su L'alzata précoce degli operati, Boll. d. Soc. med.-chir., Catania. 2: 430, 1934.
113. Loute, L., and Machurot, M.: Le lever précoce (L.P.) en chirurgie gynecologique abdominale, J. de chir. et ann. Soc. belge de chir. 36: 228, 1937.
114. MacLeod, J. J. R.: Physiology in Modern Medicine, Ed. 8, St. Louis, 1938, C. V. Mosby Company, p. 474.
115. Madelung, O.: Über den postoperativen Vorfall von Baucheingeweiden, Verhandl. d. deutsch. Gesellsch. f. chir. 34: 168, 1905.
116. Marshall, V. F., and Quick, E. W.: Report of One Hundred Consecutive Laparotomies; With Some General Observations, and a Special Reference to Appendicitis, M. Rec. 70: 809, 1906.
117. Marty: Lever précoce en chirurgie abdominale chez les noirs, Gaz. Hebd. des Sci. Med. de Bordeaux 55: 390, 1934.
118. McCloskey, J. F., and Lehman, J. A.: Living Fascial Suture in the Repair of Inguinal Herniae, Ann. Surg. 111: 610, 1940.
119. McMurtry, L.: Discussion of Boldt.[14]
120. Mermingas, K.: Das Sofortaufstehen nach chirurgischen Operationen, Zentralbl. f. chir. 66: 1390, 1939.
121. Mermingas, K.: Das Aufstehen nach der Operation, Zentralbl. f. chir. 57: 2424, 1930.
122. Miller, R. T., Jr.: How Long Shall Patients Be Kept in Bed After Operation? Pennsylvania M. J. 15: 269, 1911-12.
123. Morris, R. T.: Cited by Boldt.[13]
124. Nehrkorn: Discussion of Rost.[156]
125. Nelson, E. W., and Collins, C. G.: Cotton Suture Material and Early Ambulation in Gynecology and Obstetrics, SURGERY 12: 109, 1942.
126. Newburger, B.: Early Postoperative Walking. I. The Influence of Exercise on Wound Healing in Rats, SURGERY 13: 692, 1943.
127. Noble, C. D.: Discussion of Boldt.[14]
128. Ochsner, A., and Debakey, M.: Therapeutic Considerations of Thrombophlebitis and Phlebothrombosis, New England J. Med. 225: 207, 1941.
129. Pack, G. L., and Livingston, E. M.: Treatment of Carcinoma and Allied Diseases, Vol. 2, New York, 1940, Paul Hoeber, Inc., p. 1015.
130. Paschoud, H.: Die post-operativo Krankheit, Deutsche Ztschr. f. Chir. 251: 298, 1938-39.
131. Paschoud, H.: 59 Tag. Deutsche Gesel. f. Chir., Arch. f. klin. Chir. 183: 41, 1935.
132. Paschoud, H.: Betrachtungen über einige Neuheiten in der Prophylaxe der postoperativen Thrombophlebitis, Abst. Zentralbl. f. Chir. 67: 981, 1940.
133. Paschoud, H.: Le lever immédiat en chirurgie abdominale, Helvet. med. acta. 2: 127, 1935.
134. Payr, E.: Gedanken und Beobachtungen über die Thrombo-Emboliefrage, Zentralbl. f. Chir. 57: 961, 1930.
135. Pepe, C. J.: El abandono precoz del lecho en los enfermos laparatomizados, Rev. Asoc. méd. argent. 47: 2846, 1933.
136. Petterson, G.: Drei Faelle von Lungenembolie auf dem Operationstisch, Acta chir. Scandinav. 84: 321, 1941.
137. Pettinari: Cited by Cecchini.[27]
138. Polichetti, E.: L'alzata tempistiva dei laparotomizzati e negli interventi chirurgici in genere, Gazz. d. osp. 54: 1337, 1933.
139. Pool, E. H.: Systematic Exercises in Postoperative Treatment, J. A. M. A. 60: 1202, 1913.
140. Portis, B., and Roth, H. A.: Prophylaxis and Treatment of Postoperative Thrombosis, S. Clin. North America 16: 287, 1936.

Book Reviews

Disability Evaluation Principles of Treatment of Compensable Injuries. By Earl D. McBride, M.D. Ed. 3, revised. Philadelphia, 1942, J. B. Lippincott Co. $9.

This revised edition contains over 600 pages. The volume is profusely illustrated with photographs, roentgenograms, and line drawings.

McBride states that a very careful analysis of each case is required to arrive at a just compensation of industrial accidents and other medicolegal injuries. He has devised a very elaborate scheme for the evaluation of functional loss as it relates to the economic incapacity of the injured. Seven factors are considered in determining the partial permanent disability rating, allowable to the patient. Each factor has been allowed a certain percentage and with careful study a more accurate estimation of disability can be arrived at than with any method so far devised. However the above method is unduly complex and probably will not be accepted as very practical in a busy office practice.

Nevertheless, this book is excellent for reference and will enable anyone to check a point on which he is not clear. Every conceivable problem with which one might be confronted has been either illustrated or discussed.

This book will stimulate more thought among men doing industrial work and undoubtedly will bring out other new systems of disability evaluation.

Roentgen Treatment of Diseases of the Nervous System. By Cornelius G. Dyke, M.D., F.A.C.R., and Leo M. Davidoff, M.D., F.A.C.S., Columbia University Jewish Hospital, Brooklyn, N. Y. Pp. 198, with 12 illustrations. Philadelphia, 1942, Lea & Febiger, $3.25.

This book is an extensive review of the literature on the effect of radiation on normal nervous tissue and on pathologic lesions of the nervous system with a bibliography of approximately 150 references. In addition, it includes the authors' experience in roentgen therapy of the nervous system. It collects, in monograph form, a large amount of information which makes it a valuable reference work and a practical aid to the radiotherapeutist, the neurosurgeon, and neurologist.

The discussion of results of roentgen therapy and the conclusion drawn concerning its favorable effect would seem to express the viewpoint of a roentgenologist enthusiastic about his mode of therapy rather than that of a neurosurgeon who sees these results from a more disinterested standpoint.

Some, if not most, neurosurgeons would disagree with the statement in the preface that "it is now generally recognized that the treatment of pituitary adenomas belongs primarily to the radiotherapeutist with a neurosurgeon always available to assume the responsibility of treatment should radiation fail." However, elsewhere (p. 132) a less positive attitude toward radiation of pituitary tumors is expressed.

In their discussion of the chromophobe adenomas of the pituitary, the authors point out the sophistry of Henderson's comparison of surgical results in Cushing's material, with radiation results as reported by Dyke and Hare. They show that these data are not comparable.

174. Vanverts, J.: Quelques mots sur le lever des opèrées, Rev. franç. de gynéc. et d'obstet. 11: 106, 1920.
175. Victor, J. A.: Clinical Considerations of Thrombosis and Embolism, Ann. Surg. 82: 193, 1925.
176. Villard: Discussion of Chalior, A.[29]
177. Villard: Deux cas d'embolies mortelles au cours du lever précoce, Lyon chir. 30: 606, 1933.
178. Violet, H.: Au sujet du lever précoce des opérés, Avenir méd. 29: 247, 1932.
179. Vollmer, A. M.: In discussion of Henriksen.[86]
180. Waugh, W. G.: Experiments in the Acceleration of Wound Healing, Brit. M. J. 1: 249, 1940.
181. Wilson, L. B.: Fatal Post-operative Embolism, Ann. Surg. 56: 809, 1912.
182. Witzel, O.: Umfrage.[172]
183. Wohlleben, T.: Frühaufstehen nach Operationen, Arch. f. klin. Chir. 189: 382, 1937.
184. Wolff, J.: Über die innere Architectur der Knochen und ihre Bedeutung fuer die Frage vom Knochenwaschstum, Virchows Arch. f. path. Anat. 50: 389, 1870.
185. Zava, L.: Sui vantaggi del levar precoce degli operati, Policlinico 47: 865, 1940.
186. Zeno, A.: Cited by Ricci.[150]
187. Zimmerman, L.: Inguinal Hernia. II. The Surgical Treatment of Direct Inguinal Hernia, Surg., Gynec. & Obst. 66: 193, 1938.
188. Zoraquin: El tratamiento ambulatorio immediato—o precoz—de los operados, Bol. y trab., Soc. de cir. de Buenos Aires 18: 226, 1934.
189. Zweifel: Cited by v. Jaschks.[89]

Book Reviews

Disability Evaluation Principles of Treatment of Compensable Injuries. By Earl D. McBride, M.D. Ed. 3, revised. Philadelphia, 1942, J. B. Lippincott Co. $9.

This revised edition contains over 600 pages. The volume is profusely illustrated with photographs, roentgenograms, and line drawings.

McBride states that a very careful analysis of each case is required to arrive at a just compensation of industrial accidents and other medicolegal injuries. He has devised a very elaborate scheme for the evaluation of functional loss as it relates to the economic incapacity of the injured. Seven factors are considered in determining the partial permanent disability rating, allowable to the patient. Each factor has been allowed a certain percentage and with careful study a more accurate estimation of disability can be arrived at than with any method so far devised. However the above method is unduly complex and probably will not be accepted as very practical in a busy office practice.

Nevertheless, this book is excellent for reference and will enable anyone to check a point on which he is not clear. Every conceivable problem with which one might be confronted has been either illustrated or discussed.

This book will stimulate more thought among men doing industrial work and undoubtedly will bring out other new systems of disability evaluation.

Roentgen Treatment of Diseases of the Nervous System. By Cornelius G. Dyke, M.D., F.A.C.R., and Leo M. Davidoff, M.D., F.A.C.S., Columbia University Jewish Hospital, Brooklyn, N. Y. Pp. 198, with 12 illustrations. Philadelphia, 1942, Lea & Febiger, $3.25.

This book is an extensive review of the literature on the effect of radiation on normal nervous tissue and on pathologic lesions of the nervous system with a bibliography of approximately 150 references. In addition, it includes the authors' experience in roentgen therapy of the nervous system. It collects, in monograph form, a large amount of information which makes it a valuable reference work and a practical aid to the radiotherapeutist, the neurosurgeon, and neurologist.

The discussion of results of roentgen therapy and the conclusion drawn concerning its favorable effect would seem to express the viewpoint of a roentgenologist enthusiastic about his mode of therapy rather than that of a neurosurgeon who sees these results from a more disinterested standpoint.

Some, if not most, neurosurgeons would disagree with the statement in the preface that "it is now generally recognized that the treatment of pituitary adenomas belongs primarily to the radiotherapeutist with a neurosurgeon always available to assume the responsibility of treatment should radiation fail." However, elsewhere (p. 132) a less positive attitude toward radiation of pituitary tumors is expressed.

In their discussion of the chromophobe adenomas of the pituitary, the authors point out the sophistry of Henderson's comparison of surgical results in Cushing's material, with radiation results as reported by Dyke and Hare. They show that these data are not comparable.

Revival of postoperative radiation of cerebellar astrocytomas is advised, on theoretical grounds rather than on the results obtained in treated cases. So, also, in craniopharygioma it would seem that the results reported did not fully support the attitude expressed in favor of postoperative radiation.

Photomicrographs would have increased the value of some of their case reports, for example, in description of the extradural sarcomas of the spine in which very excellent results were reported following radiation.

A Short History of Cardiology. By J. B. Herrick, M.D. Springfield, 1942, Charles C. Thomas, Publisher.

It may be assumed that the purpose of this book is to present as simply and concisely as possible the principal characters and achievements which constitute the history of cardiology. The author has not only succeeded admirably in this aim, but he has also provided a narrative of men and events which should prove interesting even to one quite untutored in the subject. The earlier chapters dealing with the contributions of Hippocrates to Harvey to Laënnec are of particular charm quite apart from their factual historic data. The story of the early Italian school, and especially the contributions of Leonardo da Vinci, Vesalius, and Servetus, is of outstanding interest. The same may be said of the delineation of the great Irish cardiologists of the eighteenth and nineteenth centuries. One of the later chapters of the book deals very clearly with the history of coronary artery disease and myocardial infarction. It is characteristic of the author that his own classic description of the clinical features of coronary occlusion is referred to only in a modest footnote.

The illustrations consist for the most part of well-selected reproductions of portraits and photographs of the famous cardiologists. The format and construction of the book are quite in conformity with the high standard of the publisher.

SURGERY

VOL. 14 AUGUST, 1943 No. 2

Original Communications

A CONSIDERATION OF THE NONOPERATIVE TREATMENT OF CARDIAC TAMPONADE RESULTING FROM WOUNDS OF THE HEART

ALFRED BLALOCK, M.D., AND MARK M. RAVITCH, M.D., BALTIMORE, MD.
(From the Department of Surgery of the Johns Hopkins Medical School and Hospital)

ALTHOUGH it is rather generally agreed that the treatment of wounds of the heart, with resulting tamponade, should consist of pericardiotomy with suture of the wound, aspiration instead of open operation has been suggested by several surgeons. Felsenreich[1] stated that the treatment of penetrating wounds of the ventricles of the heart should be by operation, whereas wounds of the auricle should be treated by nonoperative means. This distinction is made because of the smaller pressure in the auricles as compared with the ventricles and the greater likelihood of cessation of bleeding into the pericardium from a wound of the auricle. Singleton[2] reported ten patients with wounds of the heart; one of them, in whom a shot lodged in the right ventricle, was treated successfully by aspiration alone. Singleton stated: "Therefore, we are of the opinion that prevention or relief of 'Herz tamponade' will save life in a certain number of heart injuries. This may be done for temporary relief, giving time for operative intervention in some cases, and occasionally aspiration alone results in recovery as in the case reported." Several years ago Bigger[3] described the results of operations on seventeen patients with wounds of the heart. He stated: "In the past we have been inclined to operate upon all patients with signs of tamponade or with signs of cardiac injury and moderate or massive intrapleural hemorrhage. As a result of our experience and a review of the literature we now believe that patients with heart wounds should be operated upon promptly if the indications are clear and urgent, but if the indications are not urgent some form of conservative treatment should be considered." Specific suggestions were made by Bigger as to the nature of the nonoperative treatment.

Received for publication, Nov. 2, 1942.

In discussing this paper, Elkin[4] reported the death of a patient three weeks after the receipt of a wound of the heart, the patient having been treated by nonoperative means. Necropsy showed that death resulted from rupture of a traumatic aneurysm of a coronary artery. Strieder[5] reported a case of a stab wound of the heart in which aspiration of the pericardial cavity was carried out and the patient had an uneventful convalescence. He warns, however, that "not operating upon a patient with a stab wound of the heart is a very hazardous course to follow." In a recent paper, Elkin[6] says that operation should be carried out as soon as the diagnosis is established. In a personal communication, Dr. Turner of the Meharry Hospital in Nashville informs us that recovery has followed the nonoperative treatment of two of his patients with stab wounds of the heart.

The reported mortality rate[3] from wounds of the heart which have been treated by operative means is approximately 50 per cent. Most of the deaths have been ascribable to the effects of the injury itself, but a good many are due to untoward incidents during the operative procedure or to complications which followed the operation. The question arises as to whether the mortality rate would be reduced if nonoperative treatment was used in those instances in which a rapid reaccumulation of blood does not ensue following paracentesis.

The present communication consists of a report of several cases of wounds of the heart in which nonoperative treatment was employed. These cases are similar to a number of others which have been observed.

CASE REPORTS

The first case report presents an example of recovery from what was apparently a stab wound of the heart, neither aspiration nor operation being employed. A slow, favorable response followed the administration of blood plasma.

CASE 1.—G. W. (J. H. H. No. 255213), a colored man, aged 28 years, was carried into the Accident Room at 3:30 A.M. on March 21, 1942, after having been stabbed at 3:20 A.M. On arrival he was unconscious, cold, perspiring profusely, and restless; the pulse could not be felt. The veins were engorged, the blood pressure was unobtainable, the heart sounds were muffled, and the second sound was inaudible at the base. There was a small stab wound in the third interspace to the left of the sternum. Venous pressure as obtained in an antecubital vein was 230 mm. of water. On fluoroscopic examination there was found to be almost complete absence of pulsations of the heart. There was no evidence of an accumulation of blood in either of the pleural cavities. An intravenous infusion of 250 c.c. of human blood plasma was given shortly after admission. The patient recovered consciousness soon after. The pulse was palpable and the systolic arterial pressure rose to 40 mm. of mercury. By 5 A.M., which was a little more than one hour after admission, the venous pressure was 255 mm. of water and the pulse was stronger.

The patient was taken to the operating room. It was observed on his arrival there that the systolic pressure was 70 mm. of mercury and the pulse had improved in quality. It was decided that further observation was indicated. There was a

slowly progressive rise in the arterial pressure to 90 mm. of mercury, and the patient was sent to the ward without operation. He was conscious, the skin was dry, and the quality of the pulse was improved, the rate being 88 per minute. An x-ray film of the chest which was taken twelve hours after the injury showed "an increase in the transverse diameter of the heart due chiefly to enlargement of the left ventricular shadow." Twenty-four hours after admission the patient's temperature was 101° F. and the administration of sulfadiazine was begun. The heart sounds were heard with ease and the lungs appeared clear. There was no indication of air or blood in the pleural cavities. The report of an electrocardiographic examination twenty four hours after admission was as follows: "Normal sinus rhythm. Normal axis. T I and T II and T4F upright. T III upright but low. Marked elevation of S T I, II and 4F. Initial upward deflection in chest lead. Changes suggest hemopericardium or pericarditis and have been noted in other cases with stab wounds of the heart."

The patient was permitted to sit up on the sixth day after the injury since he had been afebrile for three days and was asymptomatic. He was discharged from the hospital nine days after the injury. He was last seen one month after discharge from the hospital and then complained of shortness of breath on exertion, which was relieved by rest. The physical examination was negative. On x-ray examination the heart and aorta were seen to be normal. An electrocardiographic examination showed T I still inverted.

Comment—The patient was admitted in apparently desperate condition, but recovered with the administration of human plasma. Fluoroscopic examination, venous pressure determination, and electrocardiographic studies supported the clinical impression of intrapericardial hemorrhage.

The second case presents an example of the treatment of a patient with a wound of the heart by aspiration and the administration of fluids intravenously, an operation not being performed.

CASE 2.—N. J. (J. H. H. No. 262265), a colored man, aged 48 years, was carried into the Accident Room at 2 25 A.M. on June 6, 1942, about ten minutes after he had been stabbed in the chest. The wound was 3 cm. in length and was located in the third interspace to the left of the sternum. At first glance he was thought to be dead, and the surgical intern who was engaged in attending to other patients requested a medical intern to pronounce the patient "dead on arrival." It was found, however, that faint heart sounds could be heard. The patient was unconscious, cold, and pulseless, and the blood pressure was unobtainable. Glucose saline solution was administered intravenously in the amount of 100 c.c., and this was followed by the giving of unmatched Group O blood from the blood bank. While the blood was being administered the pericardial cavity was aspirated in the fourth interspace to the left of the sternum, and 30 c.c. of blood were removed. The response was dramatic; the patient stopped perspiring and became violently restless, showing considerable strength. Twenty five minutes after the patient's admission the pulse became easily palpable and the blood pressure was obtained at 90/60 mm. of mercury. On fluoroscopic examination the pulsations of the heart were visible but diminished. Approximately thirty minutes after the patient was first seen the venous pressure was 170 mm. of water. Physical signs and x-ray examination demonstrated hemothorax in the left pleural cavity. An electrocardiographic examination was carried out about fifteen hours after the admission of the patient. The report was as follows: "Normal sinus rhythm. Normal axis. Intraventricular conduction time is prolonged. S I is very prominent and broad. T I and II are upright. T III is sharply inverted. T4F is diphasic. The record is characteristic of tracings associated with acute pericarditis."

A small amount of bloody fluid was aspirated from the left pleural cavity and was found to be sterile. The evidence of pleural fluid disappeared in a week. The patient was discharged from the hospital seventeen days after admission.

Comment.—The patient was at the point of death on admission. His condition improved dramatically following the aspiration of only 30 c.c. of blood from the pericardial sac and after the administration of blood intravenously. Convalescence was uneventful.

It is important to appreciate the fact that a prolonged period of low blood pressure and inadequate blood flow may result in serious complications if not in irreparable damage. Edward S. Stafford observed and reported[7] a case in which acute renal failure developed as a result of cardiac tamponade which was not recognized until twelve hours after the injury of the heart. An abbreviated account of this case follows.

CASE 3.—J. S. (J. H. H. No. 165590), a colored man, aged 27 years, entered the hospital at 9:15 P.M. on March 11, 1939. He had been stabbed shortly before in the second left intercostal space. His clothes were bloodsoaked and the radial pulses were imperceptible. He was considered to have a wound of one of the great vessels at the base of the heart. He was given glucose solution intravenously and the systolic blood pressure rose to 60 mm. of mercury. It remained between 60 and 80 mm. of mercury throughout the night. The following morning, twelve hours after admission, the pulse and blood pressure were unobtainable. The venous pressure was 200 mm. of water. Cardiac tamponade was suspected and aspiration of the pericardial sac yielded 140 c.c. of dark blood. The systolic blood pressure rose immediately to 90 mm. of mercury and the venous pressure declined to 100 mm. of water. Despite a total fluid intake of more than eight liters in the first twenty-four-hour period, the patient did not void and the bladder was not distended. The following day the blood pressure was 146/96 mm. of mercury, and it remained at essentially this level during the rest of his stay in the hospital.

On the fourth day after admission the nonprotein nitrogen was 148 mg. per cent and the volume of urine was small. Urine examination showed erythrocytes, leucocytes, casts, and albumin. Glucose solution was administered intravenously and a retention catheter was inserted into the bladder. The patient continued for several days to show signs of renal failure. The nonprotein nitrogen rose to 229 mg. per cent and the excretion of phenolsulphonephthalein in two hours was only 17 per cent. A few days later the patient began to improve, and there was no evidence of residual renal damage on discharge from the hospital forty-one days after the injury.

Comment.—The experience with this patient, who had cardiac tamponade for twelve hours before it was recognized and in whom acute renal failure developed, emphasizes the importance of prompt recognition and treatment of tamponade. Aspiration of the pericardium resulted in relief of the tamponade and an operation was unnecessary. The acute renal failure probably would not have occurred had the aspiration been performed soon after the patient's admission to the hospital.

The following case report presents an example of a patient with a wound of the heart who was treated by aspiration of the pericardial cavity and by open operation. The condition found at operation indicated that the patient would probably have survived even though this procedure had not been carried out.

CASE 4.—J. W. (J. H. H. No. 252711), was a colored man, aged 17 years. Supported by two friends, the patient was admitted into the Accident Room at 11:15 P.M. on Feb. 17, 1942. He collapsed on arrival. The pulse was palpable at first but then became imperceptible. The heart sounds were audible but suppressed. The peripheral veins were distended. There was a stab wound in the fifth interspace to the right of the sternum. Pericardial aspiration was carried out at once and yielded 60 c.c. of dark blood. This procedure was immediately followed by improvement in the pulse and return of consciousness. The intravenous administration of fluids was begun and the patient was taken to the operating room.

Twenty-five minutes after the patient's arrival in the Accident Room a left parasternal incision was made. The pericardium was exposed and opened. In the pericardial cavity there was only a blood clot of moderate size which conformed to the shape of the heart and pericardium. A wound 1 cm. in length was seen near the apex of the heart. There was no active bleeding. It was closed with a single silk suture, and the incision in the chest was closed. A perforation of the left pleura, made at operation, was repaired. The patient was given whole blood plasma and glucose-saline solution during the operative procedure. His condition at the end of the operation was good.

Tension pneumothorax developed on the right side following the operation; this was relieved by repeated aspirations and finally by the insertion of a needle which was left in place for twenty-four hours. Twelve hours after admission the patient's temperature was 103.6° F., and sulfadiazine was administered. The temperature and pulse remained elevated for three days and then dropped abruptly. The subsequent convalescence was smooth. The patient was discharged from the hospital sixteen days after admission.

Comment.—The patient responded dramatically to pericardial aspiration. He was not kept under further observation, however, but was taken to the operating room and the pericardial cavity was opened. The pericardium was found to be empty of blood save for a single clot, and the wound in the heart was not bleeding. It seems likely that aspiration alone would have accomplished the desired result and that an operation was unnecessary.

DISCUSSION

Many patients with heart wounds succumb as a result of hemorrhage very soon after the injury. The mortality rate in those reported cases in which the patients reached a hospital and were operated upon is almost 50 per cent. The mortality rate is high even in the hands of those who have performed a number of such operations, and it is likely that the rate is considerably higher when the procedure is carried out by persons of less experience. It is well to remember that isolated unsuccessful cases are usually not reported.

The question arises whether the sum total of successful end results will not be greater if a more conservative policy in regard to immediate operation is adopted in those instances in which there is not active bleeding through the chest wound or into the pleural cavity. In other words, is one not warranted in delaying operation and in using nonoperative means, including aspiration, in those instances in which the patient's symptoms are due to tamponade rather than to continued active bleeding? If a positive answer to this question is the correct one, it is nevertheless important to realize that all facilities should be available for immediate operation if it becomes necessary and that

A small amount of bloody fluid was aspirated from the left pleural cavity and was found to be sterile. The evidence of pleural fluid disappeared in a week. The patient was discharged from the hospital seventeen days after admission.

Comment.—The patient was at the point of death on admission. His condition improved dramatically following the aspiration of only 30 c.c. of blood from the pericardial sac and after the administration of blood intravenously. Convalescence was uneventful.

It is important to appreciate the fact that a prolonged period of low blood pressure and inadequate blood flow may result in serious complications if not in irreparable damage. Edward S. Stafford observed and reported[7] a case in which acute renal failure developed as a result of cardiac tamponade which was not recognized until twelve hours after the injury of the heart. An abbreviated account of this case follows.

CASE 3.—J. S. (J. H. H. No. 165590), a colored man, aged 27 years, entered the hospital at 9:15 P.M. on March 11, 1939. He had been stabbed shortly before in the second left intercostal space. His clothes were bloodsoaked and the radial pulses were imperceptible. He was considered to have a wound of one of the great vessels at the base of the heart. He was given glucose solution intravenously and the systolic blood pressure rose to 60 mm. of mercury. It remained between 60 and 80 mm. of mercury throughout the night. The following morning, twelve hours after admission, the pulse and blood pressure were unobtainable. The venous pressure was 200 mm. of water. Cardiac tamponade was suspected and aspiration of the pericardial sac yielded 140 c.c. of dark blood. The systolic blood pressure rose immediately to 90 mm. of mercury and the venous pressure declined to 100 mm. of water. Despite a total fluid intake of more than eight liters in the first twenty-four-hour period, the patient did not void and the bladder was not distended. The following day the blood pressure was 146/96 mm. of mercury, and it remained at essentially this level during the rest of his stay in the hospital.

On the fourth day after admission the nonprotein nitrogen was 148 mg. per cent and the volume of urine was small. Urine examination showed erythrocytes, leucocytes, casts, and albumin. Glucose solution was administered intravenously and a retention catheter was inserted into the bladder. The patient continued for several days to show signs of renal failure. The nonprotein nitrogen rose to 220 mg. per cent and the excretion of phenolsulphonephthalein in two hours was only 17 per cent. A few days later the patient began to improve, and there was no evidence of residual renal damage on discharge from the hospital forty-one days after the injury.

Comment.—The experience with this patient, who had cardiac tamponade for twelve hours before it was recognized and in whom acute renal failure developed, emphasizes the importance of prompt recognition and treatment of tamponade. Aspiration of the pericardium resulted in relief of the tamponade and an operation was unnecessary. The acute renal failure probably would not have occurred had the aspiration been performed soon after the patient's admission to the hospital.

The following case report presents an example of a patient with a wound of the heart who was treated by aspiration of the pericardial cavity and by open operation. The condition found at operation indicated that the patient would probably have survived even though this procedure had not been carried out.

NONPENETRATING ABDOMINAL TRAUMA

EMERSON CROSBY KELLY, M.D., ALBANY, N. Y.
(From the Department of Surgery, Albany Hospital and Albany Medical College)

THIS review of the incidence and mortality rate of nonpenetrating abdominal trauma covers a period of fifteen years from Jan. 1, 1927, to Dec. 31, 1941, at the Albany Hospital, a general hospital of about 600 beds, which receives the usual proportion of highway, home, and industrial accidents. Approximately 30 per cent of admissions are to the surgical service. A study of nonpenetrating abdominal trauma in this institution should, therefore, indicate the frequency and seriousness of these injuries.

The number of admissions at the Albany Hospital has steadily increased from 6,848 in 1927, to 13,229 in 1941. The total number for this period was 157,344. Of this total, 74 patients had nonpenetrating abdominal trauma. They were distributed among 21 doctors. Hence, most of the doctors saw very few patients with this type of injury and there was no uniformity in treatment. Thirty-three of these patients died. The mortality rate for this type of injury was therefore 44 per cent.

For comparison with other serious traumas, during the same period 269 patients or approximately 0.17 per cent of the total number were admitted with fractures of the vertebrae, and 207 patients or approximately 0.13 per cent with fracture of the pelvis.

It is therefore apparent that nonpenetrating abdominal trauma is infrequent but has a very high mortality rate.

Table I shows the type of lesion with the number of patients who died or recovered and the mortality percentage. Table II also shows the type of lesion year by year and reveals that a specific type of lesion may be found only at intervals of several years. Table III gives the type of injury received and shows that 55 per cent of the patients were injured as the result of automobile accidents. Table IV gives the time of operation after the injury was received. Fifty of the seventy-four patients were not operated on, either because their condition was in extremis on admission or because they improved under expectant treatment, which occurred most frequently in cases of contusions of the kidney. In this small series of so many different types of trauma a figure giving deaths in relation to time of operation would be of no value. Table V shows time of death after the patient was injured; almost half the patients died within the first twenty-four hours.

Received for publication, Dec. 17, 1942.

there is a limit to the length of time (probably two hours) that tamponade may be allowed to persist. If blood reaccumulates rapidly following aspiration, it is agreed that exposure and suture of the heart wound is indicated. If more than one aspiration is necessary, one should allow at least fifteen minutes between paracenteses in order that the chances of closure of the would by a clot may be increased. If one has good reason to believe an auricle rather than a ventricle has been injured, one may more safely defer operation.

The observations and opinions which are expressed here support the directions[8] prepared recently for medical officers in the U. S. Army by E. A. Graham, I. A. Bigger, E. D. Churchill, and Leo Eloesser. These directions refer to the treatment of penetrating heart wounds with resulting tamponade and are as follows:

"(a) Aspirate the blood from the pericardium by the costoxiphoid route, if possible.

"(b) Repeat if there is a recurrence.

"(c) If it again recurs, perform a cardiorrhaphy through an extrapleural exposure."

It is to be emphasized that our paper deals with the treatment of heart wounds with associated cardiac tamponade rather than those in which there is continued bleeding into the pleural cavity or through the opening in the chest wall. It is obvious that an operation is necessary in those instances in which active bleeding continues.

REFERENCES

1. Felsenreich, F.: Konservative oder operative Therapie bei Vorhofsverletzungen des Hersens, Arch. f. klin. Chir. 166: 694-703, 1931.
2. Singleton, A. O.: Wounds of the Heart and a Discussion of the Causes of Death, Am. J. Surg. 20: 515-541, 1933.
3. Bigger, I. A.: Heart Wounds, J. Thoracic Surg. 8: 239-253, 1939.
4. Elkin, D. C.: Discussion of article by Bigger.[3]
5. Strieder, J. W.: Stab Wound of the Heart, J. Thoracic Surg. 8: 576-577, 1939.
6. Elkin, D. C.: The Diagnosis and Treatment of Cardiac Trauma, Ann. Surg. 114: 169-185, 1941.
7. Stafford, E. S.: Renal Failure as a Complication of Cardiac Tamponade, J. Thoracic Surg. 9: 652-655, 1939.
8. United States War Department: Guides to Therapy for Medical Officers (March 20, 1942). P. 185. Technical Manual 8-210. Washington, D. C.

TABLE IV

TIME OF OPERATION

AFTER INJURY

TIME	NO.
Within 6 hr.	10
Within 12 hr.	7
Within 24 hr.	3
Over 24 hr.	4
No operation	50
Total	74

TABLE V

TIME OF DEATH

AFTER INJURY

TIME	NO.
Within 1 hr.	3
Within 24 hr.	12
Within 48 hr.	8
Within 1 wk.	6
Over 1 wk.	4
Total	33

Bladder.—Only five patients with rupture of the urinary bladder were admitted. The one patient who had no associated injuries was a 60-year-old man who fell while intoxicated and died within twenty-four hours. The cause of death was given as peritonitis but in view of the short history, some associated condition was probably present. The two patients who recovered had fractures of the pelvis and one had also a compound fracture of the tibia and fibula with gas bacillus infection. The two additional patients who died had severe associated injuries and multiple fractures.

The mortality rate in this small number of cases is 60 per cent. This rate cannot be compared with some other recent figures found in the literature because there all types of injuries of the bladder are recorded and our cases were only those of severe nonpenetrating trauma, four out of the five patients having fractures. Peacock,[1] in 1939, reported a mortality rate of 14.4 per cent for rupture of the bladder but he reported only those cases complicating fracture of the pelvis. Culver and Baker,[2] in 1940, reported only 6.25 per cent mortality but they included all types of rupture of perforation; their only death was of a man injured during catheterization.

ASSOCIATED INJURIES AND COMPLICATIONS

BLADDER

1 L with fracture of pelvis
1 L with fracture of pelvis, compound fracture of tibia and fibula, and gas bacillus infection of leg
1 D with fracture of femur, tibia and fibula, rupture of kidney, and cerebral concussion
1 D with fracture of ribs, clavicle, humerus, and sternum
1 D with peritonitis

TABLE I

TYPE OF LESION

	TOTAL	DIED	RECOVERED	DIED (PER CENT)
Bladder	5	3	2	60
Intestine	13	9	4	69
Kidney	29	3	26	10
Liver	16	12	4	75
Mesentery	1	0	1	0
Spleen	9	5	4	55
Stomach	1	1	0	100
	74	33	41	44

TABLE II

TYPE OF LESION BY YEARS

YEAR	BLADDER	INTESTINE	KIDNEY	LIVER	MESENTERY	SPLEEN	STOMACH
1927				2 D			
1928		1 D	1 L				
1929			1 L				
1930	1 L	1 D	1 L				
			1 D				
1931		1 L	1 L	1 L		1 D	
				1 D			
1932			2 L	1 D			
			2 D				
1933	1 D	2 D				1 D	
1934	1 D		4 L	3 D		3 D	
1935	1 D	1 D	1 L	3 D			
1936		2 L	4 L	1 D			
		2 D					
1937			3 L	1 D			
1938			1 L			2 L	
1939		1 L	1 L	2 L		1 L	1 D
		1 D					
1940	1 L	1 D	3 L	1 L	1 L		
1941			3 L			1 L	
Total	2 L	4 L	26 L	4 L	1 L	4 L	1 D
	3 D	9 D	3 D	12 D		5 D	

D, died.
L, lived.

TABLE III

TYPE OF INJURY

	BLADDER	INTESTINE	KIDNEY	LIVER	MESENTERY	SPLEEN	STOMACH	TOTAL
Fall	2	1	8	3	1	1		16
Blow		8	4	1		2	1	16
Hit by vehicle	1	2	7	6		4		20
Driving automobile	1		1	2				4
Riding in automobile	1	1	9	4		2		17
Taxis on hernia		1						1
								74

Total number due to automobiles 41, or 55 per cent.

TABLE IV

TIME OF OPERATION

AFTER INJURY

TIME	NO.
Within 6 hr.	10
Within 12 hr.	7
Within 24 hr.	3
Over 24 hr.	4
No operation	50
Total	74

TABLE V

TIME OF DEATH

AFTER INJURY

TIME	NO.
Within 1 hr.	3
Within 24 hr.	12
Within 48 hr.	8
Within 1 wk.	6
Over 1 wk.	4
Total	33

Bladder.—Only five patients with rupture of the urinary bladder were admitted. The one patient who had no associated injuries was a 60-year-old man who fell while intoxicated and died within twenty-four hours. The cause of death was given as peritonitis but in view of the short history, some associated condition was probably present. The two patients who recovered had fractures of the pelvis and one had also a compound fracture of the tibia and fibula with gas bacillus infection. The two additional patients who died had severe associated injuries and multiple fractures.

The mortality rate in this small number of cases is 60 per cent. This rate cannot be compared with some other recent figures found in the literature because there all types of injuries of the bladder are recorded and our cases were only those of severe nonpenetrating trauma, four out of the five patients having fractures. Peacock,[1] in 1939, reported a mortality rate of 14.4 per cent for rupture of the bladder but he reported only those cases complicating fracture of the pelvis. Culver and Baker,[2] in 1940, reported only 6.25 per cent mortality but they included all types of rupture of perforation; their only death was of a man injured during catheterization.

ASSOCIATED INJURIES AND COMPLICATIONS

BLADDER

1 L with fracture of pelvis
1 L with fracture of pelvis, compound fracture of tibia and fibula, and gas bacillus infection of leg
1 D with fracture of femur, tibia and fibula, rupture of kidney, and cerebral concussion
1 D with fracture of ribs, clavicle, humerus, and sternum
1 D with peritonitis

Intestine.—Rupture of the intestine occurred in thirteen cases, or 17 per cent, of this series of seventy-four. The mortality rate was 69 per cent.

Perforation of duodenum	2	Died	2
Perforation of jejunum	4	Died	3
Perforation of ileum	6	Died	4
Perforation of colon	1	Died	0
Total	13		9

One interesting case was that of a patient 42 years old, who was carrying a tub of ground meat in front of him and ran into a butcher's chopping block. Operation four hours later revealed a perforation of the sigmoid colon. The rent was closed with silk sutures and the patient recovered.

One patient, a man of 25 years, was crushed between two trucks. Operation was performed within one hour but no intra-abdominal pathology was found. The patient died within twenty-four hours and examination revealed a rupture of the third part of the duodenum with extensive retroperitoneal infiltration which had ruptured into the general peritoneal cavity.

The second case of rupture of the duodenum was in a 22-year-old boy who drove his motorcycle into a car. He had fractures of the fourth and fifth cervical vertebrae with paralysis, and died in twenty-one hours. Examination showed a rupture of the third part of the duodenum with generalized peritonitis.

One patient was a man of 72 years who had had an indirect inguinal hernia for many years. At 1 A.M. he found his hernia irreducible and at 8 A.M. his family doctor attempted reduction. Severe abdominal pain ensued, operation was performed at 4 P.M., a generalized peritonitis was found, and death followed.

Another patient, a young man of 21 years, fell out of a truck at 9 A.M. Six hours later he was admitted to the hospital in a state of shock. Diagnosis of rupture of the liver was made, treatment of shock was instituted, and the patient died thirty-five hours after injury without benefit of surgery. Examination revealed a rupture of the jejunum, hemoperitoneum, and also laceration of the lung with hemothorax.

Still another patient was a man of 62 years, who was struck in the abdomen by a pole of an auto trailer at 2 P.M. Nine hours later he was admitted and operated upon at once. A perforation of the ileum one foot proximal to the ileocecal valve was closed and then bilateral direct hernias were repaired. The abdomen was drained by means of two wicks, two tubes, and one piece of vioform gauze. The patient died thirty-nine hours after being injured with generalized peritonitis.

Poer and Woliver,[3] in 1942, reviewed and reported on 1,476 cases of rupture of the intestine and mesentery with a total mortality of 72.1 per cent. Operation was performed on 1,014 patients, of whom 603 died, an operative mortality of 59.5 per cent. But 462 patients died without operative intervention.

INTESTINE

13 cases

1 L with perforation of jejunum, pelvic abscess drained on ninth day
1 L with perforation of ileum
1 L with perforation of ileum, bronchopneumonia, and hydrothorax
1 L with perforation of sigmoid
1 D with perforation of duodenum
1 D with perforation of duodenum, fracture of the fourth and fifth cervical vertebrae
1 D with perforation of jejunum and hemothorax
1 D with perforation of jejunum
1 D with perforation of jejunum and fracture of tibia and fibula
2 D with perforation of ileum
1 D with perforation of ileum, strangulated hernia
1 D with perforation of ileum, bilateral direct hernias repaired

Kidney.—Of twenty-nine patients with injuries of the kidney, eighteen showed only hematuria and were discharged after an uneventful hospitalization. One patient required nephrectomy seventeen days after injury and the only other patient operated on underwent nephrectomy three years after injury. The three patients who died had serious associated injuries with multiple fractures.

Injuries of the kidney represent 39 per cent of this series. Three died, giving a mortality of 10 per cent.

Prather,[4] in 1940, reported twenty patients with injury of the kidney. Ten were listed as contussions with no deaths. One was listed as subcapsular rupture but did not die. Of the nine patients with lacerations, four died, giving a total mortality of 20 per cent. Lewis and Trimble,[5] in 1933, reported thirty cases of injury of the kidney. Twenty-one showed only hematuria. There were three deaths in their series, giving a mortality of 10 per cent.

KIDNEY

29 cases

18 showed only hematuria, rapidly improved
1 L with fracture of ribs and second and third lumbar vertebrae
2 L with fracture of pelvis
1 L with fracture of ribs
1 L with fracture of ribs, concussion of brain
1 L with fracture of ribs, radius, and ulna, and concussion of brain
1 L with concussion of brain
1 L with fracture of femur
1 D with fracture of ribs, tibia, and fibula, and fat embolism
1 D with fracture of ribs, clavicle, and hemothorax
1 D with fracture of skull, tibia, and fibula

Liver.—Sixteen patients, or 21 per cent of this series, had a diagnosis of rupture of the liver. Twelve died, giving a mortality rate of 75 per cent.

Operation was performed on only two patients. One was operated upon within twenty-four hours and died. The other was operated upon two months after being kicked by a horse, and a liver abscess and subdiaphragmatic abscess were drained; the patient recovered.

Three patients died within one hour after admission and four others died within twenty-four hours, so that 58 per cent of the deaths oc-

Intestine.—Rupture of the intestine occurred in thirteen cases, or 17 per cent, of this series of seventy-four. The mortality rate was 69 per cent.

Perforation of duodenum	2	Died	2
Perforation of jejunum	4	Died	3
Perforation of ileum	6	Died	4
Perforation of colon	1	Died	0
Total	13		9

One interesting case was that of a patient 42 years old, who was carrying a tub of ground meat in front of him and ran into a butcher's chopping block. Operation four hours later revealed a perforation of the sigmoid colon. The rent was closed with silk sutures and the patient recovered.

One patient, a man of 25 years, was crushed between two trucks. Operation was performed within one hour but no intra-abdominal pathology was found. The patient died within twenty-four hours and examination revealed a rupture of the third part of the duodenum with extensive retroperitoneal infiltration which had ruptured into the general peritoneal cavity.

The second case of rupture of the duodenum was in a 22-year-old boy who drove his motorcycle into a car. He had fractures of the fourth and fifth cervical vertebrae with paralysis, and died in twenty-one hours. Examination showed a rupture of the third part of the duodenum with generalized peritonitis.

One patient was a man of 72 years who had had an indirect inguinal hernia for many years. At 1 A.M. he found his hernia irreducible and at 8 A.M. his family doctor attempted reduction. Severe abdominal pain ensued, operation was performed at 4 P.M., a generalized peritonitis was found, and death followed.

Another patient, a young man of 21 years, fell out of a truck at 9 A.M. Six hours later he was admitted to the hospital in a state of shock. Diagnosis of rupture of the liver was made, treatment of shock was instituted, and the patient died thirty-five hours after injury without benefit of surgery. Examination revealed a rupture of the jejunum, hemoperitoneum, and also laceration of the lung with hemothorax.

Still another patient was a man of 62 years, who was struck in the abdomen by a pole of an auto trailer at 2 P.M. Nine hours later he was admitted and operated upon at once. A perforation of the ileum one foot proximal to the ileocecal valve was closed and then bilateral direct hernias were repaired. The abdomen was drained by means of two wicks, two tubes, and one piece of vioform gauze. The patient died thirty-nine hours after being injured with generalized peritonitis.

Poer and Woliver,[3] in 1942, reviewed and reported on 1,476 cases of rupture of the intestine and mesentery with a total mortality of 72.1 per cent. Operation was performed on 1,014 patients, of whom 603 died, an operative mortality of 59.5 per cent. But 462 patients died without operative intervention.

One patient alone showed a latent bleeding time of five days. Harkins,[6] in 1942, reported that 48 per cent of cases had a latent period of two to six days and 28 per cent had a latent period of seven to eleven days. Macs and Rives,[7] in 1941, reported twenty-six cases with nine deaths, or 35 per cent mortality. Berger[8] reported, in 1902, that in 220 cases in which operation was not performed the mortality was 92.3 per cent.

Wright and Prigot,[9] in 1939, reported that among 20,000 patients admitted to their traumatic service, there were thirty cases of subcutaneous rupture of the spleen, or 0.15 per cent; among their patients with subcutaneous abdominal injuries, 48 per cent had rupture of the spleen. Mazel,[10] in 1932, reported an incidence of 30 per cent ruptures of the spleen with the same injuries.

SPLEEN

3 L with splenectomy
1 L with splenectomy and fracture of skull
1 D with fracture of ribs, tibia, and fibula, and laceration of kidney
1 D with "tear in spleen packed"
1 D with fracture of ribs, rupture of diaphragm, and hemothorax
1 D with fracture of ribs, second cervical vertebra, and femur
1 D with fracture of ribs and pelvis

Stomach.—One patient with rupture of the stomach is in this series. He was a youth of 18 years who was riding a motorcycle at night, ran into a car and received a blow by the handle bar. He was admitted to the hospital and operated upon at once. There was found a rupture of the left rectus muscle and a rupture of both the anterior and posterior walls of the stomach. Operation required two hours. Death occurred twenty-four hours after operation, from generalized peritonitis.

DISCUSSION

The differences in rates of incidence and mortality which are found in the literature are due possibly to the small number of cases of nonpenetrating abdominal trauma which any one writer is able to report. It must be noted that some reports cover operative mortality while others cover total mortality. Under these conditions a comparison of statistics is meaningless.

Estes,[11] in 1942, stated that of 2,217 injured patients admitted, thirty-two or 1.4 per cent were nonpenetrating abdominal trauma. Cody,[12] in 1939, wrote that of 5,744 accidents in Iowa, fifty-three or 0.9 per cent were of this type. Our statistics are not of the same type and therefore cannot be used for comparison.

Table VI shows the mortality rate by five-year periods. There has been a marked drop in the rate in the past five years. This improvement is due partly to the prompt operation on the last four patients with rupture of the spleen and recovery of all of them. In the last three years, of eighteen patients, five have received some type of sulfa drug. Of these eighteen, only three died. The drug probably had

curred during the first hospital day. All of these patients had serious associated injuries with multiple fractures.

Lewis and Trimble[5] reported, in 1933, twenty cases of rupture of the liver. Fourteen of the patients were operated on, of whom six died, giving an operative mortality of 40 per cent. Four patients not operated upon died, so that the total mortality was 50 per cent.

LIVER

16 cases
2 L with no complications
1 L with subdiaphragmatic abscess
1 L with fracture of ribs and hemothorax
1 D with no complications
1 D with fracture of ribs
1 D with fracture of ribs and femur
1 D with fracture of ribs, mandible, and skull
1 D with fracture of ribs, rupture of spleen
1 D with fracture of ribs, hemothorax, and subdural hemorrhage
2 D with fracture of ribs and skull
1 D with fracture of ribs and hemothorax
1 D with fracture of pelvis, radius, and ulna, contusion of kidney, gas bacillus infection of arm, and fat embolism of lungs
1 D with fracture of ribs, pelvis, and humerus
1 D with fracture of ribs and femurs

Mesentery.—There was apparently only one case of rupture or tear of the mesentery without injury to other organs. The patient was in the psychiatric ward where he either fell or threw himself against the foot of the bed. Laparotomy revealed about 350 c.c. of blood in the peritoneal cavity and a rupture of the mesentery of the ileum. The patient recovered from the injury.

Pancreas.—A boy, aged 2 years, was hit by a truck, on the left side of the abdomen. Five hours later he was admitted to the hospital because of shock, pain in the left side of the abdomen and left side of the chest, and vomiting. An x-ray of the chest was negative. Two hours after admission laparotomy was performed and a rupture of the spleen was packed with one piece of viaform gauze. The patient died eighteen hours after operation and examination showed, in addition to the ruptured spleen, a laceration of the tail of the pancreas. This case is included with the injuries of the spleen.

Spleen.—There were nine patients with rupture of the spleen in this series, or 12 per cent. Five patients died, giving a mortality rate of 55 per cent.

All four patients who recovered underwent a splenectomy, even though one patient also had a fractured skull. It is interesting that the last four patients admitted to the hospital were the only ones recovering from this injury in the past fifteen years. There has been no death from rupture of the spleen since 1934. One patient died following a packing of the splenic tear. The other four patients that died had serious associated injuries and multiple fractures; three deaths occurred within the first twenty-four hours after admission.

THE THERAPY OF SHOCK IN EXPERIMENTAL ANIMALS WITH SERUM PROTEIN SOLUTIONS

II. Fate in the Body of Concentrated and Dilute Serum and Saline Solutions

E. E. Muirhead, M.D., C. T. Ashworth, M.D., L. A. Kregel, M.D., and J. M. Hill, M.D., Dallas, Texas

(From the William Buchanan Blood, Plasma and Serum Center of Baylor University Hospital, Dallas)

A SEVERE freeze of one hind limb of a dog leads to a marked decrease in the plasma volume following thawing and fatal shock after six to eleven hours.[1] The animals expire after a variable interval of hypotension. In the present study the fate in the body of intravenously administered concentrated serum, dilute or half-strength serum, and 5 per cent glucose in physiologic saline solution in this type of shock was observed. No attempt at survival was made and the damaged limb was left intact.

VOLUMES OF SOLUTIONS USED

The average protein concentration for dilute serum was 3.8 Gm. per cent and for concentrated serum 15.8 Gm. per cent. In comparing the fate of these two solutions two criteria were observed, namely, (a) the volume of solution administered and the expected plasma volume increment in the body, and (b) the total grams of protein (albumin plus globulin) given in the entire infusion. Accordingly, two different volumes of each solution were selected (Table I, Part A).

Part B of Table I contains the average plasma volume and total circulating protein deficit for the corresponding groups during shock at the time the solutions were given.

METHODS

Mongrel dogs on meat and dog biscuit rations were used. Food was withheld for twelve to twenty hours prior to the experiment. The animals were subjected to pentobarbital sodium anesthesia approximately one hour before the freeze.

The procedure for producing the freezing injury and the methods used in studying the changes in shock and following therapy have been described.[1]

The plasma concentrations of T-1824 dye and thiocyanate were made with the aid of a dual-cell photoelectric colorimeter. A stable hemoglobinemia developed and corrections for hemoglobin staining of

Received for publication, March 5, 1943.

some value in decreasing the mortality rate, but the number of cases is too small to be broken down into different types of injury. Certainly chemotherapy, especially the direct implantation of the sulfa drug into the peritoneal cavity in patients with perforation of the intestine, is strongly recommended.

TABLE VI

MORTALITY RATE BY FIVE-YEAR PERIODS

PERIOD	NO. PATIENTS	NO. DIED	RATE (PER CENT)
1927-1931	14	7	50
1932-1936	35	22	63
1937-1941	25	4	16

CONCLUSIONS

1. Seventy-four cases of nonpenetrating abdominal trauma are reviewed.

2. The incidence of these cases is small but the mortality is very high.

3. Mortality should be lessened by (a) proper training of first-aid workers, internes in accident rooms and wards and doctors; (b) use of plasma in shock; (c) operation within six hours if indicated; (d) proper use of the sulfa drugs intraperitoneally.

REFERENCES

1. Peacock, A. H.: Rupture of the Bladder, J. Urol. 42: 1204-1206, 1939.
2. Culver, H., and Baker, W. J.: Rupture of the Urinary Bladder, J. Urol. 43: 511-531, 1940.
3. Poer, D. H., and Woliver, E.: Intestinal and Mesenteric Injury Due to Nonpenetrating Abdominal Trauma, J. A. M. A. 118: 11-15, 1942.
4. Prather, G. C.: Traumatic Conditions of the Kidney; Clinical Observations, J. A. M. A. 114: 207-210, 1940.
5. Lewis, D., and Trimble, I. R.: Subcutaneous Injuries of the Abdomen, Ann. Surg. 98: 685 692, 1933.
6. Harkins, H. N.: Delayed Splenic Rupture; Report of a Case, Am. J. Surg. 57: 159-161, 1942.
7. Maes, U., and Rives, J. D.: Surgery of the Spleen, in F. W. Bancroft: Operative Surgery, New York, 1941, D. Appleton-Century Company, Inc., section XIX, p. 1,012.
8. Berger, E.: Die Verletzungen der Milz und ihre chirurgische Behandlung, Arch. f. klin. Chir. 68: 865-914, 1902.
9. Wright, L. T., and Prigot, A.: Traumatic Subcutaneous Rupture of the Normal Spleen, Arch. Surg. 39: 551-576, 1939.
10. Mazel, M. S.: Traumatic Rupture of the Spleen, Illinois M. J. 62: 170-173, 1932.
11. Estes, W. L., Jr.: Non penetrating Trauma of the Abdomen, South. Surgeon 10: 427-440, 1941. Also: Surg., Gynec. & Obst. 74: 419-424, 1942.
12. Cody, W. E.: Treatment of Traumatic Injuries of Abdominal Cavity, Its Wall and Contents, J. Iowa M. Soc. 29: 549-555, 1939. Quoted by Estes, W. L., Jr. Loc.[11]

reasonable since in the human being we usually give 50 to 150 c.c. in two to ten minutes and wait fifteen to thirty minutes before the next dose.

Dilute serum and saline solutions were given continuously by drip system. The average rates of administration were 10.5 c.c. per minute (1 c.c. per minute per kilogram weight) for dilute serum and 11.5 c.c. per minute (1.2 c.c. per minute per kilogram weight) for glucose-saline solution.

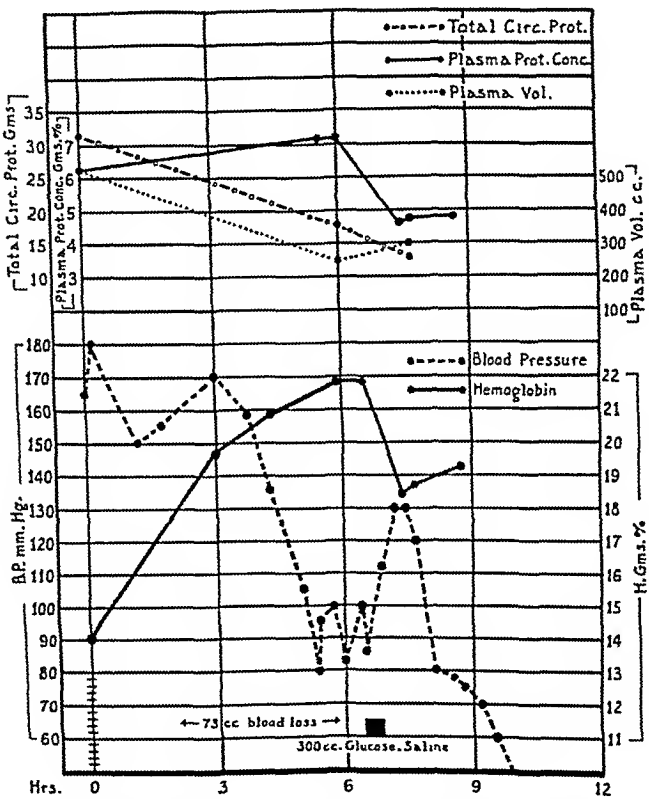

Fig. 1.—This figure represents a typical example in the glucose-saline group. Notice that the venous hemoc [illegible] to 21.9 Gm. per cent in shock from a control level of 14 Gm [illegible] the infusion a dilution to 18.3 Gm. per cent occurred but a [illegible] 5 Gm. per cent reappeared 1.5 hours later. At the same ti [illegible] concentration dropped from 7.1 Gm. per cent during shock to 1.6 after therapy and persisted at this level. (Dog weight 9.8 kg.)

RESULTS

I. Effects on Hemodilution and Plasma Volume.—A. *Saline Solution:* This solution produced a dilution of red cells and circulating plasma proteins. The venous hemodilution was not complete or persistent and by the time the animals died a hemoconcentration approaching that of the shock level reappeared, but, at the same time, the dilution of the plasma proteins remained pronounced (see Table II).

TABLE I

SOLUTION		PART A* AVG. VOL. (C.C.)	PART A* AVG. PROTEIN CONTENT (GM.)	PART B† AVG. DECREASE IN PLASMA VOL. IN SHOCK (C.C.)	PART B† AVG. DECREASE IN CIRC. PROTEIN IN SHOCK (GM.)
5% glucose in saline		300	none	279	17.58
Dil. serum	(1)	325	11.5	428.7	26.5
	(2)	595	25.6	427	29.9
Conc. serum	(1)	86.2	12.5	348	21.2
	(2)	107	18.2	288	17.4

*The average volume and grams of proteins for each type of solution used are given.
†The average decrease in plasma volume (cubic centimeters) and decrease in total circulating proteins (grams) for each group are given.

plasma were not made for the dye method. Following therapy, methemoglobinemia was present in several experiments.

One hour was allowed for thiocyanate equilibration. The thiocyanate levels varied from 3 to 11 mg. per cent.

Hemoglobin and plasma protein concentrations were determined on venous blood periodically after therapy until death ensued. The samples of blood were obtained from exposed femoral and jugular veins and purified heparin was used as anticoagulant.

At the time the hypotension (50 to 80 mm. Hg) developed the peripheral veins and arteries were contracted, and the blood was thick and dark. The intravenous solutions were given at this time.

Serum and dialysed plasma were used because previously we[2] had noted that concentrated plasma prepared from citrated blood contained a sufficient concentration of sodium citrate to precipitate tetany in dogs when rapid injections of 25 to 50 c.c. were made. This transient calcium binding effect, if sufficiently severe, may be fatal to dogs in shock. It thus became apparent that conclusions of shock therapy with concentrated citrated plasma in animals were subject to doubt unless rates and volume of injections comparable to those observed in human beings on body weight basis be observed.

Eleven animals received serum obtained by defibrination and desiccation by the adtevac process.[3] Three animals received plasma after the citrate was dialysed out. All preparations were tested for toxicity by injecting 25 to 50 c.c. of the concentrate intravenously into normal dogs. No toxic effects were observed.

The concentrated serum was injected into the femoral vein (normal side) by means of 50 c.c. syringes. The rate of injection averaged 3.1 c.c. per minute (0.35 c.c. per minute per kilogram weight) when the entire time elapsing for the administration is considered. It is emphasized, however, that the injections were given intermittently, usually 5 to 10 c.c. in one minute or less followed by an interval of three to five minutes for physiologic accommodation. This procedure seemed

For this group the average plasma volume decrease in shock was 279 c.c. (51.1 per cent of control level). Thus the 300 c.c. infusion was greater than the determined deficit. Plasma volume determinations 33 minutes after the infusions revealed an average volume of 303.2 c.c. (47.3 c.c. greater than shock level) indicating that within one-half hour as much as 84.2 per cent of the infused solution escaped from the circulation.

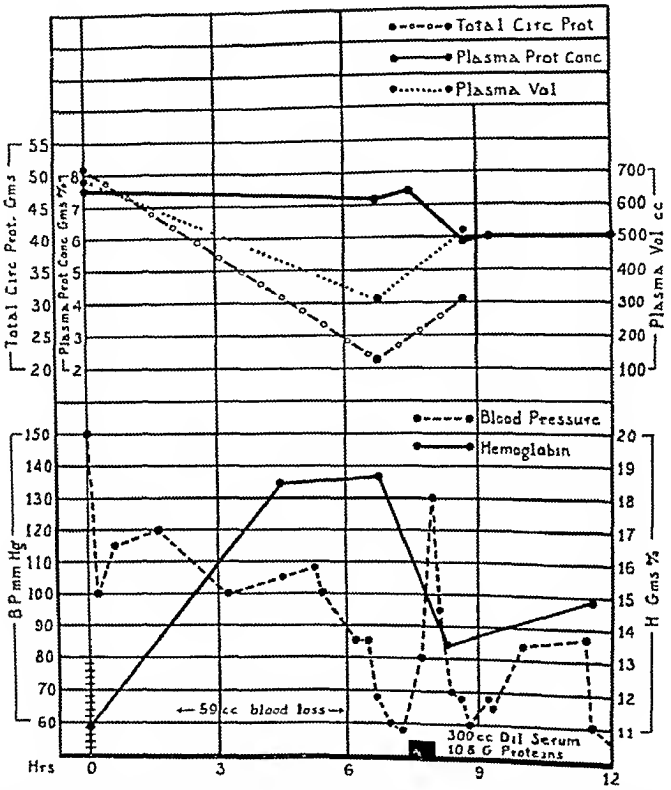

Fig. 2.—A typical example receiving a smaller volume (300 c.c.) dilute serum. The hemoglobin concentration was increased from a control level of 10.95 Gm per cent to 18.65 in shock. Within thirty minutes after the infusion it had dropped to 13.4 Gm per cent but at 3.6 hours after the infusion it was 14.9. Thus there was an increase of 7.7 Gm per cent in shock with an ultimate decrease of 3.75 Gm after the infusion. The plasma protein concentration was lowered from 7.1 Gm per cent in shock to 5.9 Gm per cent thirty minutes after the infusion and remained at this level (6 Gm per cent) 3.6 hours later. (Dog weight 10 kg.)

B *Dilute Serum:* This solution is actually composed of one-half volume of normal serum and one-half volume of saline solution.

The smaller volume of dilute serum (avg. 325 c.c.) produced a hemodilution more marked thirty minutes after the infusion than at any subsequent period. About two hours the hemoglobin concentration reached a temporary stable level, which was approximately halfway between the control and the shock levels. At the same time the red cells were diluted there was a persistent dilution of the circulating

REMARKS	INTERVALS	MEAN ARTERIAL PRESSURE MM./HG	HEMOGLOBIN (GM.)	HEMATOCRIT (%)	R.B.C. (MIL.)	PL. VOL. (C.C.)	PL. VOL. DECREASE (% OF CONTROL)	PL. VOL. DECREASE (% OF BODY WT.)	PL. PROT. CONC. (GM. %)	T. C. P. (GM.)	CHANGE T. C. P. (GM.)
Average figures	Control	156.0	13.43	43.3	6.12	535.2			6.17	35.95	
5 dogs, wt. 8.52 kg.	7.4 to 7.9 hr. shock	62.0	20.7	72.7	9.63	256.0	-51.14		6.09	18.61	-17.58
glucose-saline group	12 min. after R	88.4	15.5	47.2	7.05						
blood loss 85 c.c.	33 min. after R	99.0	16.85			303.2		-3.26	3.73	12.46	- 6.15
died 2 hr.	1.75 hr. after R	63.2	18.44						4.73		
Average figures	Control	142.0	13.05	38.2	6.23	855.0			6.65	55.9	
3 dogs, wt. 11.4 kg.	8.1 to 9 hr. shock	61.0	18.9	64.2	9.9	426.3	-51.0	-3.76	6.55	27.76	-26.5
325 c.c. dil. ser. with	0.83 hr. after R	112.0	14.2	44.8		630.1			5.55	34.8	+ 7.06
11.5 Gm. prot. blood	2.9 hr. after R	57.6	15.9	48.5					5.88		
loss 58 c.c.											
Average figures	Control	142.5	13.1	39.7		735.0			6.75	49.6	
2 dogs, wt. 9.1 kg.	10.5 to 11.25 hr. shock	55.0	19.25	68.0		308.0	-57.85	-4.8	6.68	20.7	-29.2
595 c.c. dil. ser. with	0.94 hr. after R	112.5	11.95						5.7	37.3	+16.6
25.6 Gm. prot. blood	2.5 hr. after R	123.0	13.55						6.48		
loss 48 c.c.											
Average figures	Control	162.5	13.2	40.2	6.33	646.0			6.0	38.7	
4 dogs, wt. 9.85 kg.	5.45 hr. shock	65.2	18.94	62.5	9.68	298.0	-53.5	-3.53	5.84	17.47	-21.2
conc. prot.	27.5 min. after R	120.7	15.3	47.0	7.0	476.0			6.71	30.4	+14.36
Solutions 86.2 c.c.	1.2 hr. after R	129.5							6.39		
with 12.5 Gm., prot.	4.12 hr. after R	76.5	15.1								
blood loss 68 c.c.											
Average figures	Control	141.0	13.3	41.6	6.11	583.0			6.2	36.7	
5 dogs, wt. 9.08 kg.	6.0 hr.	96.8	19.3								
conc. serum 107 c.c.	8.15 hr. shock	57.8	18.9	64.4	9.7	295.0	-49.1	-3.17	6.5	19.3	-17.4
with 18.2 Gm. protein	34.8 min. after R	103.8	13.8	41.1	6.18	624.4			6.9	43.0	+23.8
blood loss 84.4 c.c.	1.24 hr. after R	103.8	12.76								
	5.75 hr. after R	84.0	16.4								

The figures given are average figures for each group. The blood loss was the loss sustained through the blood samples for the various determinations. Average figures are given because the individual experiments were observed to display the same trend.
Abbreviations. Pl. Vol., plasma volume, Pl. Prot. Conc., circulating plasma protein concentration; T. C. Prot., total circulating plasma proteins; change in T. C. P., the decrease in total circulating proteins in shock and the change after therapy; R, therapy (infusion); hr., hours.

C. *Concentrated Serum:* This solution contains not only concentrated proteins but also concentrated salts of serum, mainly sodium chloride. Upon its injection intravenously there followed a prompt hemodilution, i.e., a decrease in hemoglobin concentration, red cell count, and hematocrit.

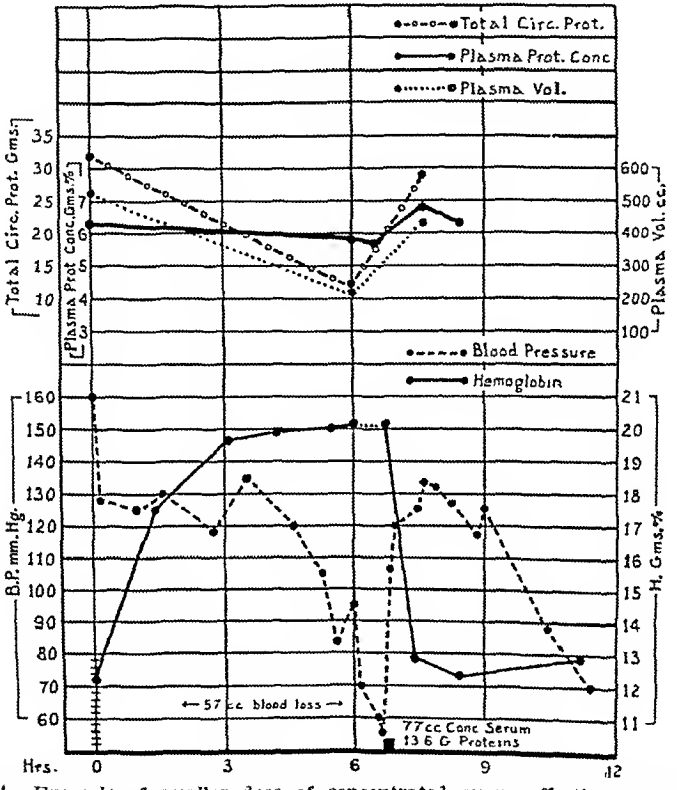

Fig. 4.—Example of smaller dose of concentrated serum effecting near complete replacement of plasma volume (compare with Fig. 5). The prompt hemodilution and increase in plasma volume with slight elevation of plasma protein concentration are demonstrated. (Dog weight 9.1 kg.)

The estimation of the circulating plasma volume in shock on the basis of the changes in venous hemoglobin concentration, red blood cell count, or hematocrit is grossly inaccurate as a result of the sequestration of red blood cells in the capillaries and venules during shock (vide infra). The venous hemodilution following concentrated serum was greater than expected from the volume of fluid injected but not always as great as expected from the amount of protein given. This discrepancy seemed to result from the release of sequestrated red cells from the capillary regions to the general circulation; particularly noticeable on the venous side (vide infra). When one examines the plasma volume studies, however, it becomes apparent that the plasma volume increment following the concentrate far

plasma proteins, a dilution half as pronounced as following saline solution alone. The hemodilution occurred in conjunction with an increase in the plasma volume, but 0.83 hour after the infusion the average plasma volume increment accounted only for 62.7 per cent of the volume infused. Thus, at this time 37.3 per cent of the infused solution had escaped the circulation and in view of subsequent hemoconcentration it is safe to state that eventually at least 50 per cent of the infused volume left the circulation.

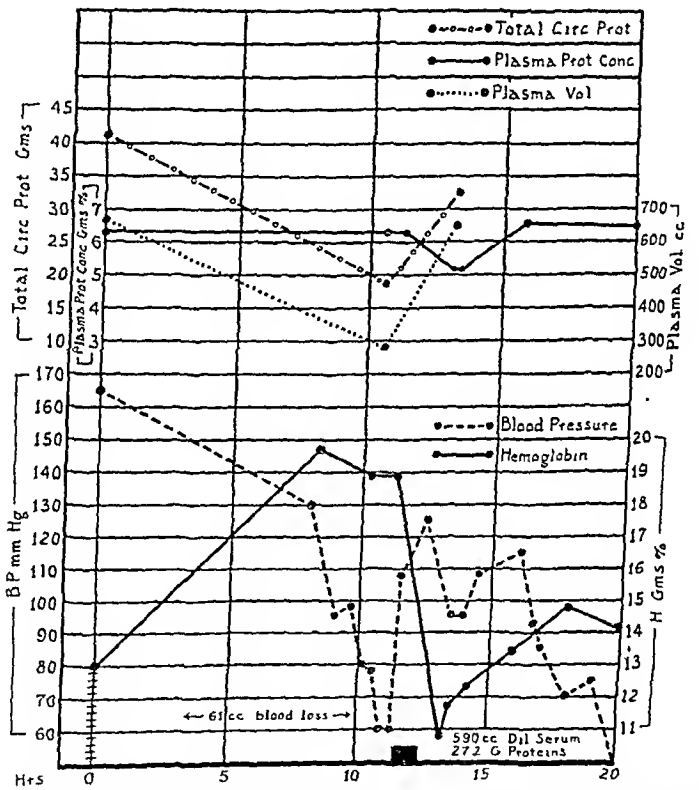

Fig. 3.—Example of large volume dose (590 c.c.) of dilute serum group. Notice the reappearing hemoconcentration and an increase in plasma volume much less than expected from the volume infused. The transient decrease in plasma protein concentration is depicted in the troughlike curve. (Dog weight 10 kg.)

The initial hemodilution following the larger volume of dilute serum (avg. 595 c.c.) was, as expected, twice the magnitude of that following the lesser volume of similar solution. Again the hemoglobin level progressively increased indicating an escape of fluid from the circulation. According to the plasma volume studies at an average of 0.94 hour after the infusions the plasma volume increment accounted for only 56.9 per cent of the volume infused. The plasma protein concentration of the recipient was lowered for three hours during and after the infusions indicating further the entrance and loss of fluid from the circulation.

Discussion of Plasma Volume Changes.—The Starling-Landis[4, 5] concept of capillary fluid exchange offers a means of analyzing the observations made. With the onset of the severe hypotension of shock a substantial drop in capillary pressure must occur for several reasons: venous hemoconcentration becomes stabilized, the head pressure maintaining the capillary pressure is critically lowered, the capillaries are generally dilated and packed with red cells (stasis).* Any elevation of the arterial pressure at this time must be partly transmitted to the capillaries, a change substantiated by the increase in size of the damaged limb following glucose-saline solution.

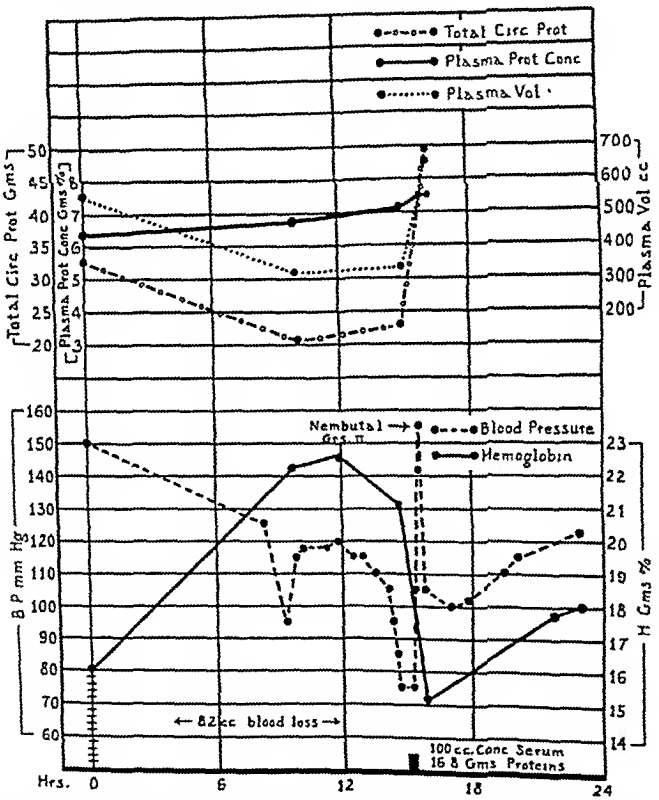

Fig. 6.—Example from large volume of concentrated serum group. The trend of changes are similar to those following a smaller volume but replacement is more complete. The depression of blood pressure following nembutal is demonstrated. (Dog weight 8.8 kg.)

Following an infusion of glucose-saline solution most, if not all, of the solution leaves the circulation in a short time. During this change the plasma protein concentration is lowered and the arterial pressure is transiently elevated. A situation seems to be created whereby the out-

*Landis[5] has described the series of events in the development of stasis. When the capillary is damaged it becomes permeable to whole plasma fluid and as the plasma escapes into the tissues, the red blood cells become packed at the venous end, producing a partial block. Plasma fluid loss is temporarily enhanced, red cell packing becomes more pronounced until the capillary is stuffed with erythrocytes. At this time the capillary pressure drops markedly.

exceeded the amount of fluid injected. In the examples graphed (Figs. 4, 5, and 6) the plasma volume increment amounted to 3 to 3.5 times the volume of fluid injected as expected in view of the degree of concentration of approximately 3 to 3.5 times normal.

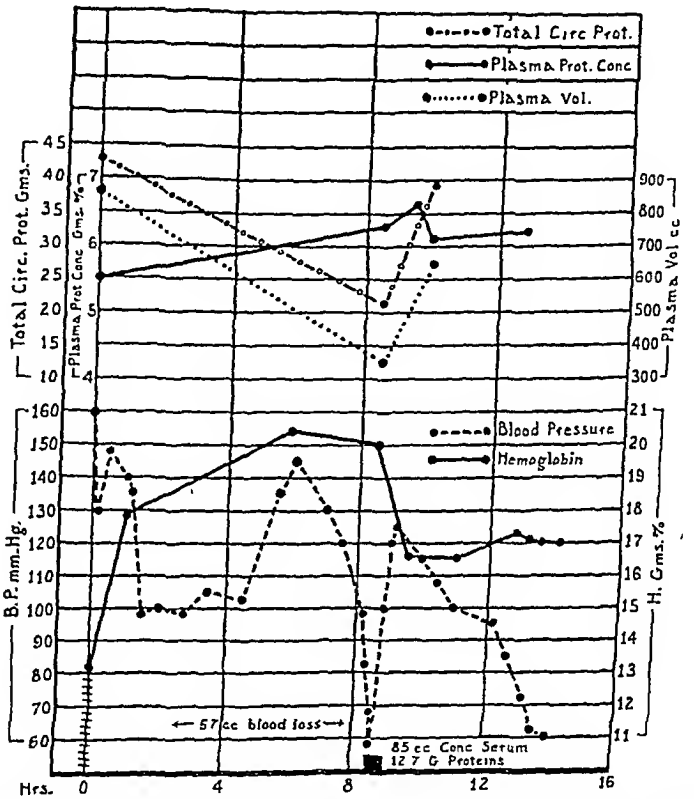

Fig. 5.—Example of smaller dose of concentrated serum. The trend of events is similar to that in Fig. 4, but failure of complete replacement of plasma volume is demonstrated. (Dog weight 10 kg.)

Animals of fairly similar body weights and having the same degree of hemoconcentration (elevation of venous hemoglobin) may display different degrees of hemodilution following similar doses of concentrated serum (Figs. 4 and 5). The demonstrated explanation for this discrepancy is that certain animals normally have larger plasma and red blood cell volumes than others despite the similarity in body weights. For reasons not completely understood, a severe freeze of hind limb gives rise to a fairly constant plasma volume decrement on a percentage basis (50 to 60 per cent). Thus, similar doses of concentrated serum may constitute adequate plasma replacement (Fig. 4) or may fail by 40 per cent in replacement in other animals (Fig. 5) despite similar hemoglobin concentrations before and during shock in such cases. In each of these cases, however, the actual plasma volume increment was as expected from the amount of protein given (vide infra).

TABLE III

A Comparison of the Theoretical Expected Volume Increment in the Recipient on the Basis of the Total Grams of Protein Given and the Actual Volume Increment as Measured by the Dye Method

SOLUTION	VOLUME (C.C.)	PROTEIN CONTENT (GM.)	THEORETICAL EXPECTED VOLUME INCREMENT		ACTUAL VOLUME INCREMENT DYE METHOD		
			VOLUME (C.C.)	% OF VOLUME GIVEN	VOLUME (C.C.)	% OF VOLUME GIVEN	INTERVAL AFTER INJECTION (MIN.)
Glucose-saline	300	0	0	0	47	15.6	33
Dilute serum	325	11.5	173	53.2	204	62.7	50
Dilute serum	595	25.6	379	63.8	337	56.6	56
Conc. serum	86.2	12.5	173	200.0	178	206.4	27
Conc. serum	107	18.2	294	274.8	329	307.4	35

hematocrit of capillary blood were much higher than similar simultaneous studies on venous blood in cases of wound (traumatic) shock. This change in red cell-plasma ratio has been interpreted as resulting from a sequestration of red cells in capillaries.

The plasma volume changes in our experiments as obtained by the degree of venous hemoconcentration in shock and venous hemodilution following therapy* were compared with the plasma volumes as determined by the dye technique.

It was observed that in each instance (eighteen dogs) the plasma volume in shock as obtained by the dye method was substantially lower than the volume obtained by the hemoglobin factor and the venous hemoconcentration. This discrepancy is taken to indicate that the venous hemoconcentration, although pronounced, did not reflect the degree of plasma fluid loss within reasonable limits. The failure of venous hemoconcentration to reflect the degree of plasma deficit attains greater significance when it is considered that actually a greater number of red cells were present in the general circulatory system after the freeze since the spleen was firmly contracted at this time, a change which tends to produce results converse to those obtained. These findings are demonstrated in Table IV.

The only logical explanation for the above findings is that red cells become trapped in the capillaries in great numbers, as Cannon pointed out, and that this removal of red cells from the venous circulation accounts for the failure of the venous hemoconcentration to account for all of the plasma deficit. Microscopic examination of various tissues support this contention.[1] Let us examine the relation of the sequestration of erythrocytes in capillaries and therapy with saline, dilute serum, and concentrated serum solutions.

*The procedure used was as follows. The product of the control plasma volume and the venous hemoglobin concentration prior to anesthesia yielded a factor (hemoglobin factor). Subsequent changes in plasma volume, expressed as multiples of 100, were obtained by the ratio of this factor and subsequent venous hemoglobin concentrations. The loss of blood through samples collected was fairly even in the various experiments and comparison of results between groups seemed grossly unmodified by this one variant.

going force in the capillaries appears to be increased but the fluid-withholding force (effective colloidal osmotic pressure) is lowered. Such changes must upset markedly the fluid-withholding factors which, together with the increased capillary permeability, precipitate a rapid passage of fluid into the tissues. There follows then a rapid reversion to the former state of circulatory insufficiency.

In a similar manner dilute serum appears to upset the fluid withholding forces but only about half of the solution is lost initially, apparently as a result of the fluid-withholding properties of the injected proteins.

The increase in plasma volume following concentrated serum is greater than the volume of fluid injected. The solution has a greater osmotic pressure than the ordinary body fluids. When given into a vein it must increase the effective plasma colloidal osmotic pressure which at the capillaries pulls fluids from the tissues into the blood stream. The shift of fluid swells the plasma volume and the plasma fluid plus red cells are conducted back to the heart via venules and veins.

The plasma protein concentration is normally well protected. The present observations indicate that fluid is lost from the circulation following the dilution of the proteins and fluid is added to the circulation following the concentration of the proteins. Theoretically, after a period of equilibration, the plasma volume increment following the injection of protein solutions, expressed as multiples of 100, should be equal to the ratio of the total grams of protein injected and the normal plasma protein concentration of the recipient. A formula may be stated for this purpose as follows:

$$\text{Plasma volume increment of recipient in c.c.} = \frac{\text{Total Gm. of protein injected}}{\text{Plasma protein concentration of recipient}} \times 100$$

The volume given by this formula is strictly a theoretic one and it may be termed the expected plasma volume increment. Under the conditions of the present experiments it is modified by the presence of capillary damage, a factor encouraging the loss of proteins from the circulation and affecting the ultimate soundness of these assumptions. The formula, therefore, will be used only for an analysis of the immediate effects of the solution.

In Table III a comparison is made between the theoretic expected volume increment by the various solutions on an injection protein basis and the actual volume increment as determined by the dye method. The two volumes, expected and actual, compare favorably and demonstrate grossly that the volume increment by the solutions is dependent on the amount of protein injected.

II. Effects on the Sequestration of Red Blood Cells in Capillaries and Venules.—Cannon,[6] as a result of studies during World War I, pointed out that the red cell count, hemoglobin concentration, and

Following therapy with glucose-saline and dilute serum solutions the plasma volume as estimated by the hemoglobin factor and the lowered venous hemoglobin concentration (venous hemodilution) continues to be far greater than the plasma volume as determined by the dye method. Yet, the plasma volume increment by each method was approximately the same, being slightly greater by the hemoglobin factor method in the saline group and slightly less in dilute serum group. These findings suggest that neither of these solutions appreciably alters the sequestration of red cells in capillaries. This concept is further supported by microscopic studies of the viscera following these solutions (vide infra). Capillaro-venous stasis, as gauged by the latter method, is not appreciably changed. By utilizing the averaged data given in the tables in a similar manner, it is observed that the above relationship between the dye method and the hemoglobin method of observing plasma volume changes holds true for all of the experiments in these two groups.

When the data for the concentrated serum groups are analyzed different results are obtained. In the several experiments in which dye volumes were determined and the degree of blood loss through samples was about even, only one revealed an appreciably greater volume by the hemoglobin method following therapy. In all instances the plasma volume increment following therapy was substantially lower by the hemoglobin method as compared to the dye technique. The usual finding (Table IV) revealed that the venous hemoglobin dilution accounted for less than one-half of the plasma volume increment. Further, microscopic examination of the tissues following concentrated serum demonstrated a decrease in the degree of capillaro-venous stasis.

The above findings suggest that concentrated serum produces a release of red cells from the capillaries into the general circulation.

Table IV also demonstrates that computation of the whole blood volume and total red blood cell mass by the venous hematocrit in this form of shock is grossly unreliable.

III. Effects on the Plasma Protein Concentration and Total Circulating Proteins.—In the present studies the plasma protein concentration was not consistently increased or decreased as shock development. On eight occasions the protein concentration was slightly increased, in seven instances it was slightly lowered, and three times it remained unchanged. In each case there was a considerable decrease in the total circulating proteins, a drop which in seventeen dogs averaged 50 per cent of the control level, indicating that the fluid lost from the circulation was whole plasma fluid. With this background in mind the effect of the three solutions on these two factors will be analyzed.

A. *Saline Solution:* The plasma protein concentration of the recipient was markedly lowered following this infusion of slightly greater volume than the plasma volume deficit. This was a persistent lowering

TABLE IV

EXPERIMENT	REMARKS	HB. (GM. %)	HB. FACTOR	PLASMA VOL. DYE (C.C.)	PLASMA VOL. HB. (C.C.)	PLASMA VOL., INCREMENT DYE METHOD (C.C.)	PLASMA VOL., INCREMENT HB. METHOD (C.C.)	HEMATOCRIT (%)	WHOLE BLOOD (VOL. C.C.)	R.B.C. (VOL. C.C.)
300 c.c. glucose saline solution. Blood loss, 73 c.c.	Control	14.0	72.3	517				43.1	909	392
	6 to 6.5 hr. shock	21.9		250	330			77.0	1087	837
	16 min. after R				395			63.1		
	33 min. after R	18.65		300	387	50	57	65.3	864	564
	1.5 hr. after R	19.15			376			6.76		
375 c.c. dil. serum with 14.1 Gm. prot. Blood loss, 62 c.c.	Control	12.65	130.3	1030				35.3	1592	563
	8.5 to 9 hr. shock	18.9		545	689			68.0	1703	1158
	1.5 hr. after R	14.15		810	920	265	231	52.0	1687	877
	2.75 hr. after R	15.4		846						
590 c.c. dil. serum, 27.2 Gm. prot. Blood loss, 61 c.c.	Control	13.0	83.8	660				40.4	1107	447
	11 to 11.5 hr. shock	18.9		291	454			68.0	909	618
	53 min. after R	10.8		645	793	354	339	33.6	971	326
	3.5 hr. after R	13.4			640			44.5		
	5.5 hr. after R	14.8			580					
85 c.c. conc. serum with 12.7 Gm. prot. Blood loss, 57 c.c.	Control	13.1	112.0	855				41.4	1459	604
	8.5 hr. shock	20.0		345	560			75.0	1380	1035
	30 min. after R	16.6			674			52.4		
	1 hr. after R			645		300	114		1372	727
	4 hr. after R	17.2			651			53.0		
	5 hr. after R	17.0			658					
100 c.c. conc. serum with 18 Gm. prot. Blood loss, 60 c.c.	Control	13.2	62.0	470				38.5	764	294
	6.5 to 6.8 hr. shock	19.5		272	318			60.0	680	408
	36 min. after R	14.4		600	430	328	112	43.0	1052	452
	1.1 hr. after R	14.4			430					
	3 hr. after R	15.5			400					
	5 hr. after R	15.0			413					

A comparison of the plasma volume as determined by the T-1824 dye method and the plasma volume as calculated from the degree of venous hemoconcentration in shock and venous hemodilution following therapy is given. The whole blood volume and red cell mass as determined by the plasma volume and venous hematocrit are also included. Notice the marked discrepancies in the latter.

None of the solutions produces a lasting elevation of the blood pressure. The glucose-saline solution was least effective and the sudden drop in pressure was closely associated with the just as sudden decrease in plasma volume. Next in line in the order of effectiveness were smaller volume of dilute serum, smaller volume of concentrated serum, larger volume of dilute serum, and larger volume of concentrated serum. In the last two groups the arterial pressure eventually declined despite an adequate circulating volume indicating that other complications were responsible for eventual death.

Arterial Pressure Changes Immediately Following Intravenous Concentrated Solutions: A rapid intravenous injection of certain volumes of concentrated serum was observed to produce a transient depression of the mean arterial pressure. When 5 to 10 c.c. of concentrated serum were injected in twenty seconds or less the arterial pressure dropped to 5 to 20 mm. Hg for an interval of 30 to 120 seconds. On each occasion the pressure came back to a level near or slightly above the pre-injection level. This depressor effect gave rise to a steppage curve in which the ultimate effect was a substantial elevation of the pressure (see Fig. 7). In the entire concentrated serum groups there was an ultimate arterial pressure rise which averaged 57 mm. Hg above the average shock level.

The transient depressor effect was observed to vary according to the volume injected and the level of the arterial pressure. The animals appeared to be most sensitive in the region of 50 to 70 mm. Hg. A larger volume produced a more marked depression. Thus, in Fig. 7 it can be observed that the 10 c.c. doses produced a more prominent depression than the 5 c.c. doses. One animal (8 S) to which 35 c.c. of the concentrate were given when the arterial pressure reached the level of 20 mm. Hg showed a prompt elevation and the depressor effect became evident only when the pressure reached levels between 70 and 85 mm. Hg. At the time the injection was begun in this animal, terminal gasping respirations with side movements of the jaw were present. The latter ceased when the arterial pressure was elevated. Later on a second larger dose of 27 c.c. produced a prominent transient depressor effect.

These transient arterial pressure depressions following injection of concentrated serum by vein in animals in a severe state of oligemia do not correspond to the depressions termed speed shock by Herschfeld and Hyman, for several reasons. These investigators observed a transient arterial pressure drop following 1 to 5 c.c. intravenous injections of various solutions, yet we did not observe this effect following numerous rapid injections of Evans blue dye and thiocyanate solutions of 2 to 5 c.c. volumes. Moreover, the administration of glucose-saline and dilute serum at the rate of 10 c.c. per minute was not accompanied by such changes, but on the contrary, these solutions gave rise to a steady pressure increment. In addition, the ultimate effects of the

and remained after most of the saline fluid had escaped from the circulation.

These observations, similar to those of Beard and Blalock,[7] indicate that protein leaves the circulation following such infusions. This point was evident when the plasma volume studies were analyzed. By the latter method the decrease ranged from minus 3.95 Gm. to minus 12.5 Gm., an average of thirty-three minutes after the infusions were completed. By the average figures (Table II) it is observed that decrease amounted to an average of minus 6.15 Gm. below shock total protein level. The secondary decrease following the infusions produced an over-all decrease (shock exudation plus postinfusion loss) amounting to 66 per cent of the control level.

B. *Dilute Serum:* A smaller volume of this solution produces a persistent decrease in plasma protein concentration of the recipient, half as marked as that following glucose-saline infusions. The plasma volume studies indicated that the increase in total circulating proteins of the recipient was less than expected from the total number grams infused. An average of 11.5 Gm. of protein were infused but fifty minutes later there was an average increase of only 7.06 Gm. or 61.3 per cent of the amount given.

When the larger volume of dilute serum was given there was a decrease in protein concentration for 1.5 hours. An average of 25.6 Gm. of protein was infused but after fifty-six minutes the increase amounted to 16.6 Gm. or 60.9 per cent of the amount given.

C. *Concentrated Serum:* The plasma protein concentration was slightly increased, average of 0.5 Gm. per cent after 1.5 hours for both doses. According to the plasma volume studies, the total circulating proteins were increased to an extent slightly greater than the amount given.

Conclusion: Immediately following infusions of glucose-saline and dilute serum in shock further protein is lost from the circulation as the saline fractions pass to the tissues. By considering the volume of infusion lost according to the plasma volume studies and the amount of protein lost, it is calculated that the fluid escaping the circulation contained 2.4 Gm. per cent of protein for the glucose-saline group and 2.27 Gm. per cent for dilute serum.

IV. Effects on the Mean Arterial Pressure.—The mean arterial pressure following a severe freeze of one hind limb passes through certain fairly consistent stages. Immediately following the freeze there is usually a prominent drop which averaged 36 mm. Hg. Following the primary drop, there is a period of several hours during which the pressure is elevated toward the control level, following which severe hypotension ensues. If no therapy is instituted at this time, the animal dies either shortly thereafter or after a varying period of hypotension.

The solutions were administered in each case when the stage of severe hypotension ensued. The subsequent average arterial pressure changes are given in Table V.

of thiocyanate has been considered to represent, for the most part, the extracellular fluid. Previously, it was pointed out[1] that without any evidence of an increased external loss of fluid, the fluid available for sodium thiocyanate solution is markedly reduced in freezing shock when the severe hypotension ensues. At the same time an elevation of the plasma sodium concentration, greater than expected from the degree of hemoglobinemia, was observed.

TABLE V

MEAN ARTERIAL (CAROTID) PRESSURE CHANGES*

REMARKS	5% GLUCOSE IN SALINE SOLUTION	DIL. SERUM SMALLER VOL.	CONC. SERUM SMALLER AMT.	DIL. SERUM LARGER VOL	CONC. SERUM LARGER AMT.
Number of dogs	5	3	3	2	5
Hr. before shock, avg.	7.9	8.8	6.5	11.2	8.2
Before freeze	156.0	142.6	161.0	147.5	141.0
Primary drop	164.0	109.6	122.6	112.5	104.2
Severe hypotension	64.0	61.0	60.7	55.0	57.8
		AFTER THERAPY			
Immediately	99.7	1.26	120.0	127.5	112.6
15 to 30 min.	101.5	111.0	126.0	130.0	101.8
1 to 1.5 hr.	78.8	93.3	125.6	111.0	106.7
1.5 to 2 hr.	58.5		117.5	119.0	
2.5 to 3 hr.		72.6		114.0	
3.5 to 4.5 hr.			88.5	93.0	102.0
5 to 6 hr.				75.0	84.0

*The pressure is given as mm. Hg.

The effects of the three solutions on these two factors were observed.

A. *Glucose-Saline Solution:* There was an increase in the thyocyanate fluid and at the same time the plasma sodium concentration was reduced. In view of the failure to increase substantially the plasma volume, the increase in thiocyanate fluid must have occurred in an extravascular location.

B. *Dilute Serum:* Solution of dilute serum gave rise to a further lowering of the thiocyanate fluid.

C. *Concentrated Serum:* An increase in the thiocyanate fluid was observed in four cases and there was no change in one. The plasma sodium concentration was decreased in the former and appreciably unchanged in the latter.

Discussion: One observation in these studies seems apparent, i.e., that concentrated serum and glucose-saline solutions produced a lowering of the plasma sodium concentration. The former solution precipitated this effect at the same time that fluid was being drawn into the circulation, while in the latter case the same effect was observed when fluid was being lost from the vascular system. In both instances the thiocyanate fluid was increased. For the sake of analysis and future critical review, if one considers the thiocyanate fluid as being extracellular in location, then concentrated serum draws fluid into the extracellular compartment but mainly into the blood stream and glucose-

concentrated serum injections were in each case a substantially higher pressure than before the injection.

In a subsequent paper we will discuss further the transient depressor effect. The effect seems to depend on the rate of injection and the action of the concentrate in the heart-lung region. The effect can be completely eradicated by injecting the solution more slowly. Similar doses of normal solution have not initiated the depressor response in our hands. On a body weight basis the doses given per unit of time are grossly much greater than the usual doses given to patients clinically, which probably accounts for the fact that we have not observed this brief depressor effect clinically.

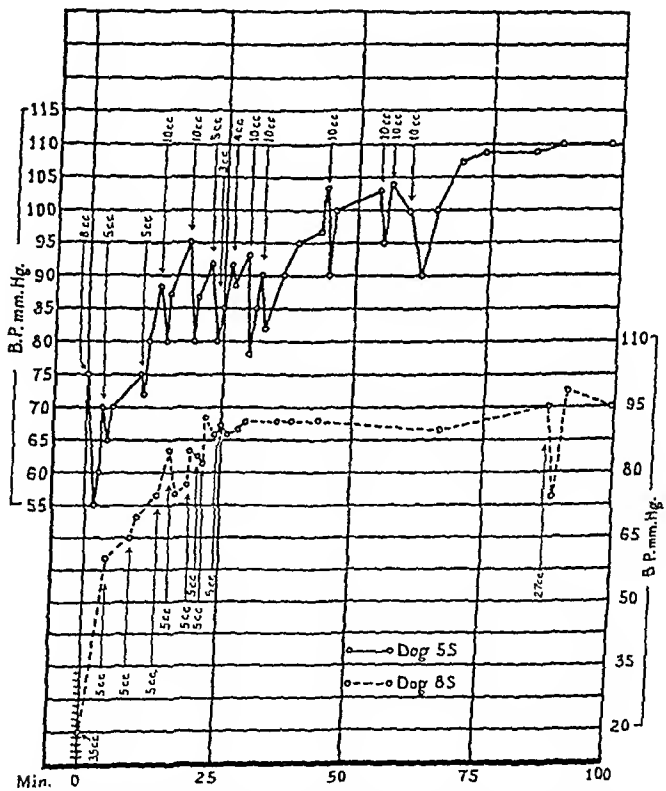

Fig. 7.—This figure represents the depressor effect resulting from the rapid administration of concentrated serum. Ordinarily the 10 c.c. doses were injected in ten seconds. Notice the difference between the effect at 50 to 75 mm. Hg and at 20 mm. Hg.

Fig. 6 demonstrates the effect of pentobarbital sodium on the arterial pressure following a successful elevation by concentrated serum. This procedure became necessary because of awakening by the animal on four occasions, but did not appear to mar the subsequent course completely.

V. *Effects on the Fluid Available for the Solution of Thiocyanate and Plasma Sodium Concentration.*—The fluid available for the solution

The modifications of these findings by the three solutions used were observed. Autopsy material from seventeen dogs was studied, including five dogs from the glucose-saline group, five from the dilute serum groups, and seven from the concentrated serum groups.

In all groups the parenchymatous findings were unchanged by the therapy, parenchymatous degeneration and focal necrosis were prominent. The infiltration of pulmonary alveolar walls and suprarenal cortex by leucocytes was also unaffected. The glucose-saline group and all but one animal in the dilute serum groups displayed prominent capillaro-venous stasis, pulmonary edema, and capillary hemorrhages. The latter findings were definitely reduced following concentrated serum therapy, particularly when death occurred less than six hours after therapy. The emptying of lung capillaries and liver sinusoids was particularly evident with concentrated serum. In addition, the larger vessels contained the pink precipitate indicative of the presence of plasma fluid suspending the red cells.

COMMENT

The abnormalities occurring in freezing shock simulated the changes described in wound (traumatic) shock and other types of shock without large hemorrhages. The abnormalities included a loss of plasma fluid from the circulation averaging 52.3 per cent of the control plasma volume (3.7 per cent of body weight), hemoconcentration, hypotension, decrease in total circulating proteins, acidosis, a decrease in the thiocyanate available fluid, plasma sodium concentration, hemoglobinemia, capillaro-venous stasis, and other visceral changes. When the state of severe hypotension ensued, the re-establishment of the plasma volume improved the circulation temporarily but did not effect lifesaving recovery. The fate of glucose-saline, dilute serum, and concentrated serum in this irreversibly fatal period was observed. Concentrated serum produced an increase in plasma volume greater than the volume given, indicating a shift of fluid into the plasma stream, probably from the tissues. The shift of fluids constituted a directional flow opposite to that occurring in the pathogenesis of shock and with it there was an increase in plasma volume, hemodilution, increase in total circulating proteins, improvement of the acidosis, increase in thiocyanate available fluid, decrease in plasma sodium concentration, and a release of red cells from the capillaro-venous areas. These effects of concentrated serum were in direct proportion to the volume given.

Dilute serum in large volumes improved the circulation but at the same time fluid escaped from the vascular system in substantial volumes, protein was further lost, and capillaro-venous stasis was not substantially improved.

Glucose-saline solution was rapidly lost from the circulation and the ultimate effects were deleterious since further protein was lost and the circulatory insufficiency became more pronounced.

TABLE VI

EXPERIMENT	REMARKS	THIOCYANATE AVAILABLE FLUID (C.C.)	WHOLE BLOOD LOSS	PLASMA CO_2 COMB. POWER (VOL. %)
Wt. 9.1 kg. Conc. dog serum 77 c.c., 13.6 Gm. protein	Control	4040	57	53.4
	6.7 hr. shock	2650		25.3
	1.5 hr. after R	3360	23	31.6
Wt. 9 kg. Conc. dog serum 111 c.c., 18.4 Gm. protein	Control	4840	71	53.7
	6.5 hr. shock	3740		32.8
	1.1 hr. dose I	3880	21	43.4
Wt. 8.5 kg. 300 c.c. 5% glucose in saline	Control	2450	79	55.5
	9.5 hr. shock	1520		37.0
	0.75 hr. after R	2050	31	33.0
Wt. 10 kg. 300 c.c. 5% glucose in saline	Control	3125	57	68.0
	7.5 hr. shock	1540		41.5
	2.5 hr. after R	2140	40	37.5
Wt. 13 kg. Dilute serum 375 c.c., 14.1 Gm. protein	Control	5050	62	54.0
	9 hr. shock	4590		26.3
	21 hr. after R	4050	28	41.0
Wt. 10 kg. Dilute serum 300 c.c., 10.8 Gm. protein	Control	4040	59	
	7.5 hr. shock	3250		

Changes in sodium thiocyanate available fluid and CO_2 combining power are given. The whole blood loss represents the amount of blood removed as samples.

saline increases the same compartment but mostly outside the blood stream. A similar theoretical explanation for the action of dilute serum is more difficult, as it appears that fluid continued to escape from the extracellular area.

VI. *Effects on the Carbon Dioxide Combining Power of Plasma.*—Thirteen animals in whom the carbon dioxide combining power of plasma was determined revealed a decrease during shock amounting to an average of 36.6 per cent of the control value. Glucose-saline therapy gave rise to a further decline in the combining power accountable on the basis of dilution of the plasma. Dilute serum in larger volume also produced a further decline. Dilute serum, in smaller volume, gave rise to a slight increase in the combining power. Concentrated serum, in smaller amount, produced a decline in the combining power of a slight degree in four animals and a slight increase in one. Concentrated serum in larger amount caused an elevation in this determination varying between eight and thirteen points.

VII. *Effects on the Microscopic Appearance of Fixed Tissue Sections.*—The changes occurring in the tissues following prolonged freezing shock have been described.[1] These changes may be divided into (a) vascular: capillaro-venous stasis and small hemorrhages; (b) interstitial: edema and infiltration by neutrophilic leucocytes; and (c) parenchymatous: acute parenchymatous degeneration, focal necrosis with pyknosis, karyorrhexis, and karyolysis (liver, kidneys, suprarenal cortex). When hypotension ensued, at the time the solutions were given, these changes were generalized throughout the body.

CLINICAL EXPERIENCE WITH THROMBIN AS AN HEMOSTATIC AGENT*

R. T. Tidrick, M.D., W. H. Seegers, Ph.D., and E. D. Warner, M.D.
Iowa City, Iowa
(From the Departments of General Surgery and Pathology, State University of Iowa)

During the past four years steady progress has been made in our laboratory in the isolation and purification of prothrombin and thrombin.[1-4, 7] The probability that purified thrombin would be useful in the clinic as a hemostatic agent was a motivating factor in this work. Early clinical and laboratory studies[5, 6] with some of our purified material were so encouraging that the data were presented to the research department of Parke, Davis & Co. With the aid of extensive production facilities, that company has undertaken to produce thrombin in quantity sufficient to ensure more complete clinical and experimental studies. It is our present purpose to present a brief summary of clinical results obtained with thrombin which we have received from this source.

THE PRODUCT THROMBIN AND MODE OF APPLICATION

The thrombin preparation, "Thrombin Topical,"† is a white powder. Its sterility has been proved repeatedly by cultures made both aerobically and anaerobically. Each vial contains approximately 10,000 units (the thrombin unit is defined[2] as that amount required to clot 1 c.c. of standard fibrinogen solution in fifteen seconds).

The sealed vial containing the sterile thrombin powder is sterilized by immersion in antiseptic solution. We have placed the vials in Bard-Parker solution for ten minutes. Before opening the vial it is rinsed with water to remove the antiseptic solution, for if the latter were to gain entrance to the vial the thrombin would be weakened. On addition of 10 c.c. of sterile water the thrombin dissolves promptly and completely. At this concentration, approximately 1,000 units per c.c., the thrombin solution causes clotting of an equal volume of human blood in less than one second. It will clot ten times this volume within three seconds, or 1,000 times its volume in twenty-three seconds.

In applying the thrombin solution to the bleeding surfaces, a spray is useful, but a syringe and fine needle are generally sufficient to flood the surface. Uniform and rapid covering of the entire surface is often facilitated by the simple expedient of gently rubbing the surface with

*Aided by a grant from the John and Mary R. Markle Foundation.
†The thrombin used was supplied by Parke, Davis & Co.
Received for publication Feb. 20, 1943.

The comparison of dilute serum and concentrated serum on the basis of the total amount of protein administered revealed a superiority of concentrated serum over dilute serum in coping with the circulatory abnormalities in this type of shock.

CONCLUSIONS

1. The comparison of the effects of glucose-saline, dilute serum, and concentrated serum on the circulation during shock on the basis of volume given and total protein injected revealed the following ascending order of efficiency: least effective glucose-saline solution, then dilute serum smaller volume, concentrated serum smaller amount protein, dilute serum larger volume, and most effective, concentrated serum larger amount of proteins injected.

2. Concentrated serum was observed to produce consistently a shift of fluids from the tissues into the blood stream. The fluid shift reversed several of the abnormal mechanisms occurring in the capillaries.

3. The most important factor in the therapy of shock appears to be the total amount of proteins administered.

REFERENCES

1. Muirhead, E. E., Ashworth, C. T., Kregel, L. A., and Hill, J. M.: Experimental Freezing Shock, Changes in Body Fluids and Tissues, Arch. Surg. 45: 863, 1942.
2. Muirhead, E. E., Ashworth, C. T., and Hill, J. M.: The Therapy of Shock in Experimental Animals With Plasma Protein Solutions, I. Concentrated Plasma as a Hemodiluting Agent, SURGERY 12: 14, 1942.
3. Hill, J. M., and Muirhead, E. E.: Problems of Military Importance in the Preparation and Use of Desiccated Plasma or Serum, Texas State J. Med. 38: 195, 1942.
4. Starling, E. H.: On the Absorption of Fluid from the Connective Tissue Spaces, J. Physiol. 19: 312, 1896.
5. Landis, E. M.: Capillary Pressure and Capillary Permeability, Physiol. Rev. 14: 404, 1934.
6. Cannon, W. B.: Traumatic Shock, New York, 1923, D. Appleton-Century Company, Inc.
7. Beard, J. W., and Blalock, A.: Intravenous Injections: Study of the Composition of the Blood During Continuous Trauma to the Intestines When No Fluid Is Injected and When Fluid Is Injected Continuously, J. Clin. Investigation 11: 249, 1932.

CLINICAL EXPERIENCE WITH THROMBIN AS AN HEMOSTATIC AGENT*

R. T. Tidrick, M.D., W. H. Seegers, Ph.D., and E. D. Warner, M.D.
Iowa City, Iowa
(From the Departments of General Surgery and Pathology, State University of Iowa)

During the past four years steady progress has been made in our laboratory in the isolation and purification of prothrombin and thrombin.[1-4, 7] The probability that purified thrombin would be useful in the clinic as a hemostatic agent was a motivating factor in this work. Early clinical and laboratory studies[5, 6] with some of our purified material were so encouraging that the data were presented to the research department of Parke, Davis & Co. With the aid of extensive production facilities, that company has undertaken to produce thrombin in quantity sufficient to ensure more complete clinical and experimental studies. It is our present purpose to present a brief summary of clinical results obtained with thrombin which we have received from this source.

THE PRODUCT THROMBIN AND MODE OF APPLICATION

The thrombin preparation, "Thrombin Topical,"† is a white powder. Its sterility has been proved repeatedly by cultures made both aerobically and anaerobically. Each vial contains approximately 10,000 units (the thrombin unit is defined[2] as that amount required to clot 1 c.c. of standard fibrinogen solution in fifteen seconds).

The sealed vial containing the sterile thrombin powder is sterilized by immersion in antiseptic solution. We have placed the vials in Bard-Parker solution for ten minutes. Before opening the vial it is rinsed with water to remove the antiseptic solution, for if the latter were to gain entrance to the vial the thrombin would be weakened. On addition of 10 c.c. of sterile water the thrombin dissolves promptly and completely. At this concentration, approximately 1,000 units per c.c., the thrombin solution causes clotting of an equal volume of human blood in less than one second. It will clot ten times this volume within three seconds, or 1,000 times its volume in twenty-three seconds.

In applying the thrombin solution to the bleeding surfaces, a spray is useful, but a syringe and fine needle are generally sufficient to flood the surface. Uniform and rapid covering of the entire surface is often facilitated by the simple expedient of gently rubbing the surface with

*Aided by a grant from the John and Mary R. Markle Foundation.
†The thrombin used was supplied by Parke, Davis & Co.
Received for publication Feb. 20, 1943.

the gloved finger. The use of gauze to wipe the surface has the disadvantage of breaking up the clot as it forms and also of removing any excess thrombin solution before it has had time to act fully. The wound should, however, be relatively free of blood at the time the thrombin is applied. If a thick layer of blood is present on the surface, the thrombin tends to clot merely the surface layers and the bleeding continues underneath the clot. Firm anchorage of the clot occurs most readily when the emergent blood is allowed to mingle with the thrombin the moment it reaches the surface. It is important to bear in mind that the hemostatic effect of thrombin is dependent, in large measure, upon the clot which forms in and on the surface of the bleeding tissues, rather than upon the formation of thrombi in the vessels in the depth of the tissues. For this reason, it is essential that the hemostatic clot be left in place. Undue sponging, to remove the clot, disrupts its anchorage and oozing often begins again. We believe that in most cases no harm results from leaving thin films of clotted blood in place. In fact, the thin clot, which forms subsequently in any event, is actually essential to fibroblastic repair rather than detrimental.

Application of the dry thrombin powder, though more wasteful of the thrombin preparation, is also effective, and at times, a more convenient method of application. We have used the dry powder, particularly in certain bone operations in which deeply situated bleeding surfaces were to be closed tightly, immediately. In wounds of this type, the dry powder, which can be rubbed into the surfaces, has the advantage of avoiding the introduction of any fluid deep into the wound and permits tight closure without danger of seepage.

The use of cotton pledgets or bits of gauze saturated with the thrombin solution is at times a convenient method of application, but, in general, this method does not give satisfactory results. The clot which forms is firmly anchored in the cotton, and when the latter is removed, more often than not, the clot is disrupted from its anchorage in the tissue with the result that the bleeding is reinitiated.

CLINICAL RESULTS

Thrombin has been employed for its hemostatic effect in somewhat over 225 cases in the University Hospitals. In these cases, the bleeding has varied widely, both in type and in the difficulty with which it could be controlled by ordinary means.

The largest and most uniform group consisted of 102 cases in which we have used thrombin to control operative bleeding from donor skin graft sites. We have found the thrombin to be of especial aid on the denuded surfaces following removal of split-thickness sheet grafts. Many of the patients in these cases bleed rather profusely at the time of operation and ooze into the dressings afterward. A considerable number of these patients are chronically debilitated and we believe the

prevention of blood loss here is a definite factor in reducing both operative morbidity and mortality. In a total of seventy-eight split-thickness grafting operations of this type the results have been very gratifying. In forty of the cases complete hemostasis was obtained in a few minutes and although rather bulky clots formed in some patients, there was no significant postoperative bleeding. In thirty-two cases there was immediate cessation of oozing with the formation of a uniform, thin clot and no subsequent bleeding into the dressings. There were only two cases in which the thrombin appeared to have little effect, and pressure was needed to control fully the initial oozing.

Thrombin was used twenty-four times in conjunction with pinch graft donor areas. The results in these were excellent in six cases, satisfactory in thirteen, fair in four cases, and in one case, hemostasis was not obtained with the thrombin. Since the central portion of the pinch graft extends through the total thickness of the skin, small arteries are occasionally encountered which require other hemostatic measures. In general, hemostasis was effected less promptly and with the formation of more bulky clots in this type of case than in the split-thickness type of graft.

In twenty-seven cases, thrombin has been employed in the control of operative bleeding from cancellous or cortical bone. In fifteen instances the hemostasis was prompt and complete. In seven cases, hemostasis was somewhat less prompt but was considered satisfactory by the operator. In only two of the cases did the thrombin fail to check the bleeding. In the remaining two cases the results were indeterminate due to simultaneous employment of other hemostatic measures. In many cases of stubborn oozing from the cut surface of bone, the effect of the thrombin has been very dramatic and has obviated the undesirable plugging of the cancellous bone spaces or haversian canals with bone wax or other foreign bodies. In the control of bleeding from bone we have generally used the thrombin in solution, but in many instances have found the dry powder more convenient.

When a tourniquet is employed in operations on the extremities it is usually desirable to release the constrictor, at least temporarily, before applying thrombin. By so doing, larger vessels may be recognized and ligated. If the thrombin solution is applied first, these vessels may be held temporarily in check, only to resume serious bleeding after the wound is closed.

During cholecystectomy persistent oozing from the gall bladder bed is occasionally very difficult to control. We have used thrombin in two such cases in which suture ligatures were ineffectual. Application of the thrombin to the profusely oozing surfaces brought about prompt clotting and effectively checked the bleeding. In a third similar case, complete hemostasis was not obtained until additional ligatures were placed. Animal experiments[5, 6] indicate that the thrombin may also be of great aid in operations upon the liver itself.

We have found thrombin to be a useful adjunct in two cases for the control of the oozing of the cut margin of the pylorus in the Rammstedt pyloroplasty procedure.

The surgeon not infrequently encounters difficulty in obtaining satisfactory hemostasis incident to drainage, excision, or débridement in areas of acute or chronic inflammation. This is particularly true when the procedure is associated with trauma to friable granulation tissue or when there are many small bleeding vessels situated in dense scar tissue. In twenty-seven operative procedures in wounds falling in these categories, the results have been very gratifying in all but two cases. We have also used thrombin to control oozing at the mucocutaneous margin, or where there was mild bleeding at the margin of the eschar, in hemorrhoidectomy operations of the clamp and cautery type. Its use was considered efficacious on three of the four occasions applied.

Thrombin has been used in nine patients to control oozing from mastectomy skin flaps with good hemostasis in seven instances. The results were somewhat equivocal in the other two cases. There is some evidence that its use may reduce the incidence of postoperative fluid collections beneath the flaps and play a part in promoting early agglutination and healing.

Thrombin has been used in six patients with various forms of blood dyscrasia, following biopsy or traumatic wounds. In three of these, excellent hemostasis was obtained. In the fourth case, a patient with an undiagnosed bleeding tendency, the thrombin appeared to have little effect. In the fifth case thrombin was used on two occasions but without definite benefit. In a second undiagnosed dyscrasia with a bleeding ulcer of the lip the results were good on two occasions. On one occasion, the bleeding point could not be reached with the thrombin and hemostasis was not effected.

In eight cases of delayed postoperative bleeding the thrombin has proved to be very helpful in five, of some aid in one, and of no definite benefit in another. In this latter case, there was a small artery in the depths of the wound, and it was necessary to reopen the wound and ligate this vessel before the bleeding could be checked. In this type of case, thrombin can sometimes be introduced into a bleeding sinus or tract by means of a small catheter, and thus minimize the need for disrupting the wound in order to obtain hemostasis. Care must of course be taken to see that the thrombin is never injected intravenously.

We have had occasion to use thrombin to control bleeding from ulcerated neoplasms in five instances. In all of these hemostasis was effected. In two of the cases, there had been large blood loss preceding this measure and the usual hemostatic measures had failed.

Thrombin has been utilized in some thirteen or more miscellaneous cases of soft-tissue bleeding associated chiefly with operative wounds. In several of these, the bleeding was so trivial as to make analysis of

the usefulness of thrombin difficult, but in at least nine of these cases it has been thought by the operator to be of definite aid.

All cases were studied closely to detect the existence of thromboses, but all were negative in this respect. In earlier work[5, 6] this problem of thrombosis was studied experimentally in rats and dogs. Thrombin in large amounts was injected directly into soft tissues. In no case was there any evidence of thrombosis in the vessels nearby. The direct injection of thrombin into human tissues would probably be harmless also, but we have avoided this procedure for fear that the thrombin might be injected accidentally into a vein. From animal experiments[5, 6] the intravenous injection of thrombin is known to cause widespread thrombosis.

The postoperative course of the wounds treated with thrombin was carefully recorded, with special attention to any suggestion that the thrombin produced local irritation. In no case was there any evidence of this. Infected wounds showed no more redness or suppuration than ordinarily exists. Clean wounds healed promptly by primary intention without any evidence that the thrombin had caused irritation. Even when the thrombin was applied repeatedly over a period of many weeks, there was no evidence to indicate the development of hypersensitivity. We were particularly interested in this, for the thrombin is prepared from beef plasma and might be expected to act as a foreign protein in this respect.

The use of large amounts of the sulfonamide group of drugs in the wounds is not a contraindication to the simultaneous use of thrombin, nor do the drugs interfere with the hemostatic action of the thrombin preparation.

SUMMARY

Experience with the hemostatic effects of "Thrombin Topical" in a wide variety of cases indicates that it provides a very useful adjunct to surgical technique. In general, oozing of blood from capillaries and small venules can be checked promptly whenever the bleeding surfaces are accessible. Even in the case of small arteries application of thrombin is often effective, particularly if digital pressure can be applied to the bleeding points momentarily in order to permit the clot to become firmly anchored in the tissue.

There has been no evidence that the thrombin produced local irritation nor that patients, in whom the preparation was used repeatedly, became hypersensitive to it. None of the patients showed evidence of untoward effects from absorption of the thrombin, or from local thrombosis of vessels.

In approximately one-half of the cases the operative work was done by one of us (R. T. T.). For the remainder of the cases, we are indebted to other members of the Department of General Surgery and to the Orthopedic Surgical staff, especially Dr. L. A. Williams.

Since this report was submitted for publication, we have found thrombin to be particularly useful for control of the oozing of blood from brain tissue.

REFERENCES

1. Seegers, W. H., Smith, H. P., Warner, E. D., and Brinkhous, K. M.: The Purification of Prothrombin, J. Biol. Chem. 123: 751-754, 1938.
2. Seegers, W. H., Brinkhous, K. M., Smith, H. P., and Warner, E. D.: The Purification of Thrombin, J. Biol. Chem. 126: 91-95, 1938.
3. Seegers, W. H.: Purification of Prothrombin and Thrombin: Chemical Properties of Purified Preparations, J. Biol. Chem. 136: 103-111, 1940.
4. Seegers, W. H.: The Purification of Prothrombin, J. Biol. Chem. 140: 677, 1941.
5. Seegers, W. H., Warner, E. D., Brinkhous, K. M., and Smith, H. P.: The Use of Purified Thrombin as an Hemostatic Agent, Science 89: 86, 1939.
6. Warner, E. D., Brinkhous, K. M., Seegers, W. H., and Smith, H. P.: Further Experience With the Use of Thrombin as a Hemostatic Agent, Proc. Soc. Exper. Biol. & Med. 41: 655-657, 1939.
7. Seegers, W. H.: Further Purification of Thrombin: Probable Purity of Products, J. Biol. Chem. 146: 511-518, 1942.

METABOLIC STUDIES IN PATIENTS WITH CANCER OF THE GASTROINTESTINAL TRACT

VI. Disorders in Alimentary Digestion and Absorption in Patients Who Have Undergone Total Gastrectomy for Carcinoma of the Stomach*

P. E. Rekers, M.D.,† George T. Pack, M.D., and C. P. Rhoads, M.D., New York, N. Y.

(From the Memorial Hospital for the Treatment of Cancer and Allied Diseases New York)

During the past twenty years steady progress has been made in the postoperative care of patients who have undergone surgical treatment for diseases of the alimentary tract. Patients who have undergone total gastrectomy, however, uniformly have had a difficult postoperative course. Even after a survival period which would be expected to be adequate, these patients seldom returned to their original weight. They complained of intestinal disorders, developed anemia, and, occasionally, evidence of vitamin deficiencies. The investigation here reported was undertaken to ascertain whether or not the cause of these disorders in patients after total gastrectomy is to be found in an abnormal digestion of simple dietary constituents.

Previous metabolic studies following gastric resection for ulcer and carcinoma of the stomach do not show uniform results but some of these studies indicate an excess of fat in the stools.[1, 2] However, many of these studies were carried out with inadequate quantitative methods. In general, previous investigators concluded that the stomach could be removed from animals and from man without seriously incapacitating the individual.[1-4]

CLINICAL MATERIAL

This report is based on the results of study of four different groups of patients. The first is composed of eight individuals who were used as controls. They were admitted to the hospital for treatment of disorders entirely unrelated to the gastrointestinal tract. There was no reason to believe that any of them had ever had gastrointestinal disease. Two of these eight control subjects received diets identical with those given to the patients following total gastrectomy. The remaining six received routine hospital diets which contained daily approximately 80

*The authors gratefully acknowledge the assistance given by the Jane Coffin Childs Memorial Fund for Medical Research, The Standard Brands, Inc., and the National Cancer Institute Fund.

†Trainee in the diagnosis and treatment of cancer, National Cancer Institute.

Received for publication, Dec. 5, 1942.

REFERENCES

1. Seegers, W. H., Smith, H. P., Warner, E. D., and Brinkhous, K. M.: The Purification of Prothrombin, J. Biol. Chem. 123: 751-754, 1938.
2. Seegers, W. H., Brinkhous, K. M., Smith, H. P., and Warner, E. D.: The Purification of Thrombin, J. Biol. Chem. 126: 91-95, 1938.
3. Seegers, W. H.: Purification of Prothrombin and Thrombin: Chemical Properties of Purified Preparations, J. Biol. Chem. 136: 103-111, 1940.
4. Seegers, W. H.: The Purification of Prothrombin, J. Biol. Chem. 140: 677, 1941.
5. Seegers, W. H., Warner, E. D., Brinkhous, K. M., and Smith, H. P.: The Use of Purified Thrombin as an Hemostatic Agent, Science 89: 86, 1939.
6. Warner, E. D., Brinkhous, K. M., Seegers, W. H., and Smith, H. P.: Further Experience With the Use of Thrombin as a Hemostatic Agent, Proc. Soc. Exper. Biol. & Med. 41: 655-657, 1939.
7. Seegers, W. H.: Further Purification of Thrombin: Probable Purity of Products, J. Biol. Chem. 146: 511-518, 1942.

3. A study of the hematologic picture of those patients who have had total resection of the stomach for carcinoma.

Metabolic studies in a control group of patients and in those who have had total resection of the stomach for carcinoma.—The daily fecal excretion of fat by the eight individuals used as controls was measured in fifty-four specimens of stool collected in periods of from one to four days. The fat* content of these specimens varied from 1.0 to 6.5 Gm. per day. The average excretion of fecal fat by each individual ranged from 2 to 6 Gm. per day (Table I).

The fecal outputs of nitrogen were determined in fifteen stool specimens excreted by four of the control individuals. The collection periods were from one to four days, each, in duration. The nitrogen content of the specimens varied from 0.6 to 1.5 Gm. per day and the average daily fecal excretion of nitrogen varied from 0.7 to 1.5 Gm. These values for fecal fat and nitrogen are in good agreement with those reported by others[8] (Table I).

TABLE I

DIETARY INTAKE AND FECAL AND URINE EXCRETION IN A CONTROL GROUP OF PATIENTS

PATIENT	DISORDER	TYPE OF DIET	DIET PER DAY		FECES PER DAY			URINE PER DAY NITROGEN (GM.)
			FAT (GM.)	NITROGEN (GM.)	FAT (GM.)	FAT EXCRETED (PER CENT)	NITROGEN (GM.)	
A. F.	Hemangioma of foot	(a)	35	11.2	3	9	0.7	10.1
A. D.	Oral leucoplakia	(a)	35	10.1	4	13	0.9	9.0
P. R.	Varicose veins	(c)	105	14.4	4	4	0.8	15.0
F. P.	Plantar wart	(c)	135	16.0	6	4	1.5	14.6
A. S.	Osteitis fibrosa cystica	(d)	75	18.0	2	3		
H. Z.	Chronic lymphatic leucemia	(d)	75	18.0	3	4		
I. D.	Xeroderma pigmentosa	(d)	50	12.0	3	6		
F. B.	Arrested amoebiasis	(d)	75	18.0	3	4		

(a) Analyzed diet.
(c) Calculated diet.
(d) Regular hospital diet.

In distinct contrast to the findings in the control group were those obtained from study of the three patients who had undergone total gastrectomy. Stool and urine collections were made for thirteen basal periods, each of which lasted from three to four days. During these periods the patients were found to excrete daily from 8 to 50 Gm. of fat. The average excretion of fecal fat by each individual ranged from 11 to 23 Gm. per day. It is interesting to note that whereas the control patients who ingested from 35 to 80 Gm. of fat never excreted more than 6 Gm. per day, these individuals without stomachs never

*In the present communication the term "fat" is used to express the stearin equivalent of the stool.

Gm. of fat, 18 Gm. of protein nitrogen, and 175 Gm. of carbohydrate. It is to be noted that the amount of fat they ingested is twice that fed to the patients who had undergone total gastrectomy.

The second group is composed of three patients who had undergone total gastrectomy for carcinoma of the stomach and had survived the operation for more than six months. At the time of observation they were free from evidence of neoplastic disease. The case histories of these three patients are presented in detail in a subsequent section of this communication.

A third group is represented by one patient who had undergone a partial gastrectomy for carcinoma of the prepyloric region of the stomach and still secreted considerable quantities of both free and combined hydrochloric acid.

A fourth group is represented by one patient bearing a carcinoma of the prepyloric region of the stomach. The growth was deemed inoperable because it was adherent to the pancreas and large vessels posteriorly. There was no gross evidence of metastasis.

METHODS AND CRITERIA

Metabolic studies were not made on any patient until the basal diet had been taken for at least three days and, in the case of the patients who had undergone gastrectomy, at least one week. No vitamins or treatment for anemia had been administered for at least two months. The patients who had been subjected to total gastrectomy had survived their operation for at least six months and were still free from evidence of neoplastic disease.

The diets given to two of the patients in the control group, to all of those that had undergone total gastrectomy, to the one that had undergone partial gastrectomy, and to the one who bore a gastric cancer were analyzed diets in which a constant source of meat was used. The diets of the remaining patients in the control group have been described previously.[1] The excreta were collected from one- to four-day periods, the nitrogen and fat contents calculated on a per diem basis. Multiple periods of study were used in most instances.

Methods for the chemical analysis and vitamin assay of blood and excreta have been described in the previous publications of this series.[5, 6, 7]

RESULTS

The results of the experiments herein described may be grouped under three headings:

1. Studies of the excretion of fat and nitrogen by a control group of patients and by patients who have had a total resection of the stomach for carcinoma.

2. Experiments to determine the nature and the cause of the faulty digestion and absorption of dietary constituents in patients who have had total resection of the stomach for carcinoma.

TABLE IIB

TABULATION OF BLOOD COUNT AND SERUM PROTEIN CONCENTRATION IN PATIENTS WHO HAVE UNDERGONE TOTAL GASTRECTOMY FOR CARCINOMA

PERIOD	RED BLOOD CELLS (MILLIONS)	HEMOGLOBIN (PER CENT)	LEUCOCYTES	HEMATOCRIT (PER CENT)	MEAN CORPUSCULAR VOLUME (CU. MICRONS)	RETICULOCYTES (PER CENT)	SERUM PROTEIN		
							TOTAL (GM. PER CENT)	ALBUMIN (GM. PER CENT)	GLOBULIN (GM. PER CENT)
Patient D. S. (a)									
Basal	4.2	88	5,400	35	83	0.8	6.3		
High fat	4.1	91	7,750			0.6	7.5		
High protein (*beef*)	3.8	91	5,000	33	87	0.8	6.4		
Patient J. C. (a)									
Basal	3.9	76	8,200	31	81	1.2	6.7		
High fat	3.9	78	6,950	32	82	1.0	6.6		
High protein (beef)	3.5	76	6,500	33	92	1.2			
Oral liver extract (b)	3.5	72	7,700	33	92	1.8	6.5		
Patient A. Z. (a)									
Basal	4.6	96	6,300	43	93	0.8	7.3	4.8	2.5
Fat free (start)	3.8	77	4,300	39	104	0.8	6.4	4.6	1.8
Fat free (end)	4.0	82	5,000	35	88	0.6	6.8		
Basal (after fat free)	4.1	85	6,250	35	84	0.6	6.6		
High protein (gelatin)	3.8	80	4,500	32	84	1.0	6.6		
High protein (beef)	4.1	84	5,000	37	90	0.8	6.4	4.7	1.7
Lipoenic	4.1	87	5,100	39	90	0.7	6.8	4.7	2.1
Pancreatic enzymes (start)	4.1	84	4,700	35	85	0.8	6.9		
Pancreatic enzymes (*end*)	3.8	74	5,400	33	88	1.0	7.3		
High fat	4.2	85	5,800	37	89	0.8	6.5	4.3	2.2
Ventriculin	4.0	82	5,200	39	98	0.6	6.9	4.9	2.0
Liver extract crude (intramuscular) (c)	4.1	83	4,900	37	90	0.8	6.8	4.7	2.1

(a) Analyzed diet.
(b) Eli Lilly and Company.
(c) Eli Lilly and Company, No. 370.

TABLE IIA

DIETARY INTAKE AND FECAL AND URINE EXCRETION IN PATIENTS WHO HAVE UNDERGONE TOTAL GASTRECTOMY FOR CARCINOMA

PERIOD	DIET PER DAY		FECES PER DAY			URINE PER DAY
	FAT (GM.)	NITROGEN (GM.)	FAT (GM.)	FAT EXCRETED (PER CENT)	NITROGEN (GM.)	NITROGEN (GM.)
Patient D. S. (a)						
Basal	50	4.0	12	24	1.0	3.1
High fat	100	4.5	13	13	0.8	2.8
High protein	50	17.1	8	16	1.1	8.6
Patient J. C. (a)						
Basal	70	12.4	11	16	1.3	9.8
High fat	125	14.6	12	10	1.7	9.2
High protein	75	23.2	7	9	1.7	9.5
Oral liver extract (b)	70	11.0	6	8	1.2	9.5
Patient A. Z. (a)						
Basal	40	10.0	23	57	2.2	8.8
Fat free (start)	2	10.0	19	100 +	3.4	7.3
Fat free (end)	2	10.0	7	100 +	2.6	7.0
Basal (after fat free)	40	10.0	38	95	3.0	9.2
Gelatin	40	18.6	30	75	2.6	18.0
Beef	60	16.0	28	47	4.2	16.1
Lipocaic	40	10.0	26	65	2.7	10.3
Pan. enzymes (start)	40	10.0	37	93	2.8	10.7
Pan. enzymes (end)	40	10.0	8	20	1.2	11.9
High fat	220	10.0	125	57	6.8	9.3
Ventrieulin	40	10.0	28	70	1.9	18.8
Liver extraet erude (intramuscular) (e)	40	10.0	17	14.3	2.2	11.2
Bile salts	40	10.0	33	80	5.0	7.1

(a) Analyzed diet.
(b) Eli Lilly and Company.
(c) Eli Lilly and Company, No. 370.

excreted less than 8 Gm. of fat per day although they ingested only 40 Gm. of fat (Table IIA).

The patients who had undergone total gastrectomy excreted in their stool from 0.8 to 3.3 Gm. of nitrogen per day and, in their urine, from 5.3 to 14.4 Gm. of nitrogen per day. The average excretion of fecal nitrogen by each individual ranged from 1.0 to 2.2 Gm. per day. The values of fecal nitrogen excretion in two of these three individuals were within normal range of less than 1.5 Gm. per day. The third individual (A. Z.) excreted from 1.3 to 3.3 Gm. of nitrogen per day in his stool, values distinctly above the normal range (Table IIA). From these results it is apparent that all three patients who had undergone total gastrectomy manifested a conspicuous steatorrhea and one of these three patients manifested a conspicuous creatorrhea.*

Experiments to ascertain the source and nature of the faulty digestion and absorption of the dietary constituents.—

A. Are the steatorrhea and creatorrhea of those patients without stomachs of intrinsic or extrinsic origin? In order to determine whether or

*Creatorrhea used to indicate excess fecal nitrogen.

puts ranging from 13 to 18 Gm. and averaging 16 Gm. in the daily fecal excretion. No creatorrhea existed (Table IV). Furthermore, the daily addition of 35 Gm. of a substance* potent in the intrinsic factor, for ten days, to the basal diet of patient A. Z. with total gastrectomy, failed to alter the existing severe steatorrhea (Table IIA).

TABLE III

DIETARY INTAKE AND FECAL AND URINE EXCRETION IN A PATIENT BEARING GASTRIC CANCER

PERIOD	DIET PER DAY		FECES PER DAY			URINE PER DAY
	FAT (GM.)	NITROGEN (GM.)	FAT (GM.)	FAT EXCRETED (PER CENT)	NITROGEN (GM.)	NITROGEN (GM.)
Patient A. Z.						
Basal (a)	50	10	8	16	1.6	7.3
Basal (c)	90	14	5	10	1.1	8.0
High fat	230	14	16	7	1.6	7.7

(a) Analyzed diet.
(c) Calculated diet.

TABLE IV

DIETARY INTAKE AND FECAL AND URINE EXCRETION IN A PATIENT WHO HAD UNDERGONE PARTIAL GASTRECTOMY

PERIOD	DIET PER DAY		FECES PER DAY			URINE PER DAY
	FAT (GM.)	NITROGEN (GM.)	FAT (GM.)	FAT EXCRETED (PER CENT)	NITROGEN (GM.)	NITROGEN (GM.)
Patient E. P.						
Basal (a)	35	10	16	45	1.3	5.8

(a) Analyzed diet.

In addition, small jejunal pouches or reservoirs of approximately 200 ml. capacity were demonstrated by roentgenography in the two patients (J. C. and D. S.) studied, while increased motility of the intestines was not demonstrated by fluoroscopic studies in any patient in this series.

No further evidence seemed necessary, therefore, to establish beyond reasonable doubt that the steatorrhea as noted in these patients without a stomach was not due to a lack of gastric chyme, an intrinsic factor in the gastric juice, sufficient reservoir to hold the ingested food nor increased intestinal motility.

(2) Previous existence of cancer. It may be assumed that the previously existing cancer of the stomach altered the gastric mucosa and resulted in defective digestion and absorption of the dietary constituents, fat in particular. Hence, it became important to determine whether or not a steatorrhea and creatorrhea existed in a patient who bore a carcinoma of the stomach. Accordingly, a patient was selected for similar

*Ventriculin.

not the steatorrhea and creatorrhea were of dietary origin, it was necessary to vary the dietary fat and protein intake, respectively, and to note any associated changes in the steatorrhea and creatorrhea. Accordingly, one patient, A. Z., was placed on a fat-free diet for fourteen days. This regime of the fat-free diet was associated with a pronounced decrease in the steatorrhea. The stool fat outputs fell from 39 to 7 Gm. per day, a value within the normal range. There was no significant change in the fecal excretion of nitrogen (Table IIA).

The subsequent daily addition of 40 Gm. of fat to the fat-free diet of patient A. Z. was followed by an immediate rise in the fecal fat excretion from 7 to 38 Gm. per day and by no appreciable alteration in the fecal nitrogen output. Furthermore, the addition of a single feeding of 180 Gm. of fat in the form of butter and cream to the basal diet which contained 40 Gm. of fat resulted in the excretion of 125 Gm. of fat and 6.8 Gm. of nitrogen in the stool during the next twenty-four-hour period (Table IIA).

The daily addition of from 40 to 60 Gm. of dietary fat in divided feedings in the form of butter to the basal diet of the remaining two patients resulted in no significant change in either the fecal excretion of fat or nitrogen (Table IIA).

From the results it would appear that in one individual who had a severe steatorrhea, this abnormality was directly related to the amount of fat ingested. The creatorrhea in this patient was related not only to the dietary protein but also to the dietary fat, since it increased with the increased intake of fat. The results are in agreement with the findings of others who studied the fat absorption in patients with idiopathic steatorrhea.[9]

B. Cause of the steatorrhea and creatorrhea: The more probable explanations for the steatorrhea and creatorrhea were considered to be: (1) absence of the stomach; (2) disturbances of alimentary digestion and absorption because of the previously existing cancer of the stomach; (3) deficient biliary secretion; (4) deficiency of an unknown pancreatic factor of an exocrine nature (such as lipocaic); (5) lack of an adequate secretion of pancreatic enzymes into the intestines; (6) diets deficient in protein; and (7) insufficient amounts of an unknown substance called an extrinsic factor as found in liver extract.

(1) Absence of the stomach. Since the stomach provides gastric chyme, an intrinsic factor in the gastric juice, serves as a reservoir for recently ingested food, and regulates the flow of food into the intestines, it was important to determine if any of these factors were the cause of the steatorrhea and creatorrhea in the patients investigated. Accordingly, one patient was selected for study who had undergone partial resection of the stomach for cancer of that organ and still retained adequate amounts of both free and combined hydrochloric acid. Over one-third of the stomach was free of evidence of neoplastic disease. This patient (E. P.) was found to have a steatorrhea, the out-

of dietary fat and protein in animal and man,[11, 12] and their absence must be considered among the possible causative factors for the steatorrhea in the patients under consideration. However, in none of the three patients who underwent gastrectomy was organic disease of the pancreas demonstrable at the time of operation and none had their pancreatic ducts ligated. Two of these three patients showed no evidence of creatorrhea, hence their digestion and absorption of the dietary protein were probably adequate (Table IIA).

The daily administration to one patient (A. Z.) of 25 Gm. of pancreatic enzymes, a dose found to be effective in pancreatic insufficiency,[13] was found to reduce the fecal output of fat from about 20 to 8 Gm. per day and the fecal nitrogen from 2.8 to 1.2 Gm. daily. These findings indicated that the steatorrhea and creatorrhea might be related to either an insufficiency of the fat and protein-splitting enzymes or to an improper mixing of the intestinal contents with their pancreatic enzymes (Table IIA).

(6) An adequate supply of dietary protein. Inasmuch as some observers believe that protein restriction in the diet results in a decreased utilization of the dietary fat,[14] it was important to exclude as a causative factor for the steatorrhea an insufficient supply of dietary protein. Accordingly, in two of the three patients, the basal diet was supplemented with from 70 to 80 Gm. of protein in the form of cooked beef for a period of fourteen days each. During the period in which the beef supplement was administered, there was a reduction in the average daily fecal fat excretion from 11 and 12 Gm. to 7 and 8 Gm., respectively, fat outputs close to the normal range. Furthermore, such protein supplements were not associated with any appreciable changes in the fecal nitrogen excretion.

Since beef is a complex dietary protein and contains appreciable amounts of choline, a substance with known lipotropic activity, it became desirable to employ a protein supplement free from such lipotropic material. Accordingly, the third patient (A. Z.) received 100 Gm. of gelatin as his protein supplement for fourteen days. No appreciable change in the degree of his steatorrhea or creatorrhea followed. Furthermore, when the gelatin was replaced for fourteen days with 100 Gm. of cooked beef there was no appreciable change in the steatorrhea, but the fecal excretion of nitrogen rose from 2.7 to 4.2 Gm. per day (Table IIA).

The findings in two patients of an apparent fat-sparing action of dietary protein for dietary fat were not confirmed in the third patient. These results deserve confirmation and further study.

(7) Insufficient quantities of extrinsic factor. Patients with tropical sprue and intestinal anastomosis and strictures frequently manifest steatorrhea, which in many instances may be alleviated by the administration of large quantities of crude liver extract.[15, 16] In order

study who bore a carcinoma of the stomach but no evidence of metastases, gastric obstruction, bleeding, or pyrexia.

Stool and urine collections were made on this patient for nine periods of from one to four days each, during which a basal diet was fed. For the first four periods the basal diet was exactly the same as that fed to the patients with total gastrectomy. This diet contained 50 Gm. of fat, 11 Gm. of protein nitrogen, and 300 Gm. of carbohydrate. During the next five periods the basal diet contained 90 Gm. of fat, 14 Gm. of protein nitrogen, and 180 Gm. of carbohydrate.

During the basal periods the patient excreted daily from 5 to 9 Gm. of fat, from 1.0 to 1.8 Gm. of nitrogen in the stool, and from 5.4 to 7.2 Gm. of nitrogen in the urine. His oral glucose tolerance test was normal. The average daily fecal excretion of fat was 6.0 Gm. and of nitrogen was 1.0 Gm. Thus, this individual with carcinoma of the stomach in situ presented findings essentially in keeping with the findings obtained in the control group of patients (Table III).

It would appear, therefore, that the presence of the cancer does not play a direct mechanical role in disturbing the digestion and subsequent absorption of the dietary protein and fat.

(3) An inadequate supply of bile in the intestine. Since the presence of bile in the intestine is considered to be essential for the proper digestion and absorption of fat, it became necessary to consider an inadequate supply of bile as a causative factor for the steatorrhea in the patients without stomachs.

None of these patients in the present study who underwent total gastrectomy showed evidence of biliary tract disease at the time of operation, nor was the biliary tract interfered with surgically. All stool specimens presented gross evidence of bile pigment at all times. Finally, in one patient (A. Z.), the addition of 4 Gm. of bile salts per day to the diet caused abdominal cramps, accentuation of the loose bulky stools, and an increase of the daily stool fat output from 22 to 33 Gm. and an increase of the nitrogen output from 3.3 to 5 Gm. Therefore, further evidence was not deemed necessary to indicate that an inadequate supply of bile was a cause for the existing steatorrhea (Table IIA).

(4) Insufficiency of pancreatic hormone. Inasmuch as abnormal lipid metabolism with excess fatty infiltration of the liver has been ascribed to a deficiency of a pancreatic hormone,[10] such as lipocaic, it became desirable to determine whether or not such a hormone deficiency was related to the steatorrhea in the patients under study.

Six grams of lipocaic were administered daily for ten days to one patient (A. Z.) who had a conspicuous steatorrhea without appreciable alteration in the existing steatorrhea and creatorrhea (Table IIA).

Thus, it appeared that the steatorrhea and creatorrhea were not caused directly by a deficiency of the pancreatic hormone, lipocaic.

(5) Insufficiency of pancreatic enzymes. Pancreatic enzymes have been demonstrated repeatedly to be necessary for the proper utilization

of dietary fat and protein in animal and man,[11, 12] and their absence must be considered among the possible causative factors for the steatorrhea in the patients under consideration. However, in none of the three patients who underwent gastrectomy was organic disease of the pancreas demonstrable at the time of operation and none had their pancreatic ducts ligated. Two of these three patients showed no evidence of creatorrhea, hence their digestion and absorption of the dietary protein were probably adequate (Table IIA).

The daily administration to one patient (A. Z.) of 25 Gm. of pancreatic enzymes, a dose found to be effective in pancreatic insufficiency,[13] was found to reduce the fecal output of fat from about 20 to 8 Gm. per day and the fecal nitrogen from 2.8 to 1.2 Gm. daily. These findings indicated that the steatorrhea and creatorrhea might be related to either an insufficiency of the fat and protein-splitting enzymes or to an improper mixing of the intestinal contents with their pancreatic enzymes (Table IIA).

(6) An adequate supply of dietary protein. Inasmuch as some observers believe that protein restriction in the diet results in a decreased utilization of the dietary fat,[14] it was important to exclude as a causative factor for the steatorrhea an insufficient supply of dietary protein. Accordingly, in two of the three patients, the basal diet was supplemented with from 70 to 80 Gm. of protein in the form of cooked beef for a period of fourteen days each. During the period in which the beef supplement was administered, there was a reduction in the average daily fecal fat excretion from 11 and 12 Gm. to 7 and 8 Gm., respectively, fat outputs close to the normal range. Furthermore, such protein supplements were not associated with any appreciable changes in the fecal nitrogen excretion.

Since beef is a complex dietary protein and contains appreciable amounts of choline, a substance with known lipotropic activity, it became desirable to employ a protein supplement free from such lipotropic material. Accordingly, the third patient (A. Z.) received 100 Gm. of gelatin as his protein supplement for fourteen days. No appreciable change in the degree of his steatorrhea or creatorrhea followed. Furthermore, when the gelatin was replaced for fourteen days with 100 Gm. of cooked beef there was no appreciable change in the steatorrhea, but the fecal excretion of nitrogen rose from 2.7 to 4.2 Gm. per day (Table IIA).

The findings in two patients of an apparent fat-sparing action of dietary protein for dietary fat were not confirmed in the third patient. These results deserve confirmation and further study.

(7) Insufficient quantities of extrinsic factor. Patients with tropical sprue and intestinal anastomosis and strictures frequently manifest steatorrhea, which in many instances may be alleviated by the administration of large quantities of crude liver extract.[15, 16] In order

to ascertain whether or not the steatorrhea in the patients without stomachs was due to a lack of such a substance as an extrinsic factor which is found in liver extract, one patient (A. Z.) was given 5 ml. of crude liver extract intramuscularly daily for fourteen days. No appreciable alteration in the fecal excretion of fat or nitrogen followed. A second patient, without a stomach (J. C.), was fed 12.8 Gm. of liver extract orally daily for twelve days. No significant change occurred in this patient (J. C.) in the fecal excretion of fat and nitrogen which were within the normal range at that time. From these studies, therefore, it does not appear that the existing steatorrhea was affected by the administration of liver extract (Table IIA).

From the evidence at hand, it was possible to conclude only that the steatorrhea in these patients who had undergone total gastrectomy was related directly to the dietary fat, possibly related to the protein content of the diet, and probably related to fat-splitting enzymes found in the pancreas.

The creatorrhea, as noted in one patient only, is related not only to the dietary protein but also to the dietary fat.

A study of the hematologic picture of those patients who have had a total gastrectomy for carcinoma of the stomach.—Since various derangements of the stomach such as achlorhydria and mucosal changes have been found to be associated frequently with a macrocytic anemia,[17] it became important to determine if those patients who had undergone total gastrectomy manifested alterations in blood formation. Accordingly, weekly studies were made on the circulating blood of each patient in the present study to ascertain the hematologic picture. Anemias were demonstrated in each of the three patients that had undergone total gastrectomy (Table IIB). The anemias were of varied degrees but all essentially of the normochromic, normocytic type. A persistent macrocytic anemia was not present in any patient.

A. Causes for the anemia: The more probable causes for the anemias were considered to be:

(1) The patients lacked an extrinsic factor as found in liver extract or an intrinsic factor as found in the normal stomach.

(2) The patients were deficient in dietary protein.

(3) The patients harbored an infection.

(4) The patients had a disturbance of bone marrow function.

(5) The patients suffered from disturbances of alimentary digestion and absorption.

(6) The patients had a blood loss or increased blood destruction.

(1) Extrinsic and intrinsic factors. Since substances containing an extrinsic factor have been found to be effective in the treatment of certain deficiency anemias,[18] it was important to determine whether or not the anemia in the patients in the present study was due to a deficiency of a principle as found in liver extract. Therefore, one patient (A. Z.) was given 5 ml. of crude liver extract intramuscularly, daily for four-

teen days, and a second patient (J. C.) was given 12.8 Gm. of liver extract orally, daily for twelve days without any significant alteration in the blood picture in either patient (Table IIB).

Likewise, since an intrinsic factor from the stomach has been found to be effective in the treatment of certain deficiency anemias,[19] it became desirable to determine whether or not the anemia of the patients who had undergone gastrectomy was due to a deficiency of such a principle as found in ventriculin. Accordingly, the basal diet of patient A. Z. was supplemented with 33 Gm. of a substance potent in the intrinsic factor* daily for ten days without alteration in the existing anemia (Table IIB).

From this evidence it does not appear that a deficiency of either the intrinsic or extrinsic factors was the cause for the anemia in those patients studied.

(2) Dietary protein. It has been well established that hemoglobin production in anemia can be controlled by diet;[20] more specifically, that iron and protein stores or intake are the essential factors. Meats have been shown to be potent in these diet factors that are necessary for hemoglobin formation.[20] With these fundamental concepts in mind the basal diet of each of the patients who had undergone gastrectomy was supplemented with 100 Gm. of beef daily for at least fourteen days. Such feedings, however, were not associated with any significant alteration in the existing anemia (Table IIB).

Thus, it did not appear that a deficiency of dietary protein was the causative factor for the anemia in those patients who had undergone total gastrectomy.

(3) Infection. Since the presence of infection may profoundly influence hemoglobin production, in spite of adequate dietary protein,[20] it became desirable to exclude such an inhibiting factor as a possible cause for the anemia in those patients who had undergone total gastrectomy. A careful search in each instance failed to reveal the presence of an infection.

(4) Marrow function. Inasmuch as the hematologic picture may be altered by disturbances in function of the bone marrow,[21] it became necessary to investigate, when possible, the bone marrows of these individuals who had undergone total gastrectomy. Microscopic study of the sternal marrow of patient A. Z. revealed an essentially normal picture. Patient D. S. was reported to have died with evidence of metastatic carcinoma in the bones of the skull, cervical vertebrae, and pelvis.

From this evidence it is possible that one patient in this study manifested an anemia because of alterations in the function of the bone marrow.

(5) Alimentary digestion and absorption. Finally, the anemia in the patients in this study might be considered to be due to a disturbance in alimentary digestion and absorption. To examine this possibility,

*Ventriculin.

the excretion of fat and nitrogen in the stools was determined in each patient. During the basal periods these individuals excreted in their stools from two to six times more fat than a control group of patients. Likewise, during the basal periods two individuals excreted normal amounts of nitrogen in their stools, while the third subject (A. Z.) excreted from two to three times more nitrogen than the control individuals (Table IIB).

It would appear, then, that those patients who had undergone total gastrectomy manifested a pronounced steatorrhea in all instances and a conspicuous creatorrhea in one instance. This demonstration of a disturbance in alimentary digestion and absorption presented a strong argument indicating the association of anemia with alimentary tract dysfunction.

(6) Blood loss or increased blood destruction. It has been well established that continued blood loss from the body or increased blood destruction within the body as with intravascular hemolysis will cause or aggravate an anemia.[22] In order to investigate this possibility as a cause for the anemia in the patients in the present study, frequent examinations were carried out on each patient to ascertain blood loss in the excreta and the oral cavity and increased amounts of bilirubin in the circulating blood. Hematuria, blood from the oral cavity, blood in the stools, and hyperbilirubinemia were not demonstrated in any instance.

Thus, it can be concluded that the anemia in those patients having undergone gastrectomy was not due to blood loss or increased blood destruction.

To summarize.—It seems probable that the anemia in the patients having undergone total gastrectomy was not due to a deficiency of dietary protein, intrinsic or extrinsic factors, or to the presence of an infection. However, there may have been a relationship between the anemia and a disturbance in alimentary digestion and/or absorption and, in one instance, to a disturbance in the bone marrow function.

DISCUSSION

It has been demonstrated in this investigation that patients who have undergone total gastrectomy for carcinoma of the stomach manifest a steatorrhea and an anemia and, in one instance, a creatorrhea, despite a survival period which would be expected to be adequate and allow for physiologic adaptation to the altered alimentary tract as the result of resection of the stomach. These experiments have demonstrated that the steatorrhea and creatorrhea were of dietary origin. The finding of an interrelationship between dietary protein and fecal nitrogen is in contrast to the observations of Coffey, Mann, and Bollmann,[12] who believed that excess nitrogen elimination in the stools was related to the bulk of the stools and not to the dietary nitrogen.

From the results of the experiments presented it appears that the steatorrhea may have been due to a pancreatic enzyme insufficiency and a dietary protein deficiency. The evidence for such a conclusion was that (1) the administration of pancreatic enzymes and (2) the administration of large amounts of dietary protein was followed by a decrease in the steatorrhea. The explanation for a pancreatic insufficiency was not clear since organic disease of the pancreas was not demonstrated in any patient at the time of operation nor suspected from the clinical course or history. Furthermore, repeated experimental and clinical observations have indicated that as long as small amounts of exocrine function of the pancreas persist the intestinal digestion dependent upon pancreatic enzymes will be carried out in a normal fashion.[23]

A "primary" or macrocytic anemia was not demonstrated in any of the patients studied. The follow-up period in no case exceeded twenty months, so it is possible that sufficient time had not elapsed for a "primary" anemia to develop as the result of the absence of a stomach.

The anemias demonstrated in this study were of the normochromic, normocytic type and refractory to the administration of increased dietary protein, intrinsic and extrinsic factors. The anemia may be dependent upon defective or deficient nutrition. Such a nutritional deficiency state may arise from an inability to utilize and distribute the necessary substances from the diet as well as from a dietary deficiency or defect itself. It has been our clinical experience that patients with cancer of the gastrointestinal tract frequently manifest a mild or moderate anemia, despite a seemingly adequate diet, that is refractory to the usual forms of therapy, i.e., iron compounds, high protein diet, and liver extract. Macrocytosis has been frequently demonstrated in patients with cancer of the gastrointestinal tract, however.[6] The present study has indicated the inability of these patients to utilize properly the dietary fat and, in one instance, the dietary protein. Other studies from this hospital have indicated that patients with cancer of the gastrointestinal tract have difficulty in utilizing such substances as vitamin A and vitamin K.[6, 7]

CONCLUSION

Patients who have had total gastrectomy for carcinoma of the stomach have an impaired ability either to digest or absorb the fat of the diet and, in one patient, the protein of the diet.

A deficiency of bile salts or a pancreatic hormone, lipocaic, could not be considered causative factors for the disturbed lipid metabolism.

Pancreatic enzyme appeared to be effective in reducing the steatorrhea in the one patient studied.

Beef supplements to the diet were effective in reducing the steatorrhea in two of the three patients studied.

A refractory rather than a macrocytic anemia was demonstrated.

CASE REPORTS

PATIENT A Z (total gastrectomy for carcinoma of the stomach) —A Z, a 59 year old man, was admitted to the hospital August, 1940, complaining of alternating bouts of diarrhea and constipation associated with mild postprandial, substernal, and epigastric pain Roentgenographic studies showed an irregular polypoid lesion in the upper portion of the stomach and rigidity along the lesser curvature

Total gastrectomy was performed with an end to side anastomosis between the end of the esophagus and loop of jejunum and a side to side jejunojejunostomy A Maiwedel type of jejunostomy was established for temporary feeding purposes

From September, 1940, to August, 1941, the patient was able to eat three regular meals each day with only occasional distress There was a five to eight pound weight gain in three months There was no diarrhea No specific vitamin or enzyme therapy was given during this period

In August, 1941, the patient was readmitted to the hospital for metabolic studies He was given a basal diet which consisted of carbohydrate 380 Gm, protein from 60 to 70 Gm, and fat 40 Gm No metabolic studies were performed for a period of seven days in order to allow the patient to become adjusted to the diet and hospital routine The present investigation was then begun

These investigations were performed

Basal diet	8 periods
Fat free diet	4 periods
Basal diet + 70 Gm gelatin daily	3 periods
Basal diet + 100 Gm beef protein daily	7 periods
Basal diet + 6 Gm lipocaic daily	3 periods
Basal diet + 12 Gm pancreatic enzymes daily	1 period
Basal diet + 25 Gm pancreatic enzymes daily	2 periods
Basal diet + 4 Gm bile salts daily	1 period
Basal diet + 180 Gm fat	1 period
Basal diet + 50 Gm ventriculin daily	3 periods
Basal diet + 5 ml crude liver extract daily	4 periods

Periods of basal diet feedings were placed between each of these tests Periods were of three to four days each in all instances except one

Large feedings occasionally caused some epigastric distress which could be relieved by smaller and more frequent feedings Otherwise the metabolic studies were tolerated well and the patient was finally discharged to the outpatient clinic for follow up studies His weight, blood, and physical picture have remained unchanged

Pathologic Study —The specimen was a totally excised stomach measuring 10 cm along the greater curvature and 16 cm along the lesser curvature Portions of the great and gastrohepatic omenta were attached to the stomach There was no evidence of lymph nodes involved with carcinoma along the greater curvature In the region of the lesser curvature there was a great deal of induration and definite evidence of infiltration by tumor in the fat The lymph nodes in this region were quite soft Tumor was seen in a diffuse and shotty distribution just beneath the serosa on the anterior and posterior surfaces bordering on the lesser curvature On opening the stomach there was a very bulky, widely ulcerated carcinoma, the edges of which were firm and elevated to a height of nearly 1 cm The tumor extended for a distance of 11 cm along the lesser curvature and 3 cm down the anterior and posterior walls The proximal edge was approximately 3 cm from the line of amputation The gastric mucosa was covered by a copious layer of mucinous material The usual gastric rugae markings were largely obliterated except for about 5 cm of the prepyloric area

Microscopic Study.—Adenocarcinoma, grade 4, with fat invasion at the lesser curvature, was found; no definite nodal metastases. Mucosal atrophy was marked. Intestinal metaplasia was present.

Laboratory Data.—At time of metabolic studies laboratory data revealed urine normal, except for an occasional faint trace of albumin; urinary glucuronates, 800 mg. per twenty-four hours. Stools were yellow-brown, soft, bulky, and somewhat foul. Guaiac test for blood was negative on repeated examinations and negative for sugar after acid hydrolysis. Blood chemistry was: bilirubin, 1.0 mg. per cent; cholesterol, total, 164 mg. per cent, free, 49 mg. per cent, esters, 115 mg. per cent; prothrombin, 92 mg. per cent; alkaline phosphatase, 4.9 units; calcium, 11.9 mg. per cent; phosphorus, 4.33 mg. per cent; plasma vitamin A, 175 U.S.P. units; and carotene plasma, 0.08 U.S.P. units.

Glucose tolerance test, after ingestion of 100 Gm. of glucose, showed:

Time (minutes)	Fasting	30	60	120	180
First test					
Glucose in blood (mg. per cent)	83	200	238	70	61
Second test	76	213	170	64	63

A preoperative gastric analysis showed:

	Free Acid (N/10 HCl)	Combined Acid (N/10 HCl)
Before histamine	0 ml.	36 ml.
15 min. after histamine	0 ml.	36 ml.
30 min. after histamine	0 ml.	46 ml.
60 min. after histamine	0 ml.	18 ml.

The first specimen was positive for blood; all subsequent specimens were negative for blood and bile.

The sternal marrow was found to be normal bone marrow.

PATIENT J. C. (total gastrectomy for carcinoma of the stomach).—J. C., a man, aged 55 years, was admitted to the hospital March, 1940, complaining of postprandial distress and gaseous eructation not relieved by soda or food. Roentgenographic studies showed a circular defect in the mid portion of the antrum of the stomach and a loss of rugal pattern throughout the pars media.

A total gastrectomy was performed with an end to side anastomosis between the end of the esophagus and loop of jejunum and a side to side jejunojejunostomy. A Marwedel type of jejunostomy was established for temporary feeding purposes. The patient was discharged on his thirty ninth postoperative day on a liquid diet supplemented with purées and gruels. Follow up studies were carried out in the outpatient department during the next three months when it was noted that the patient ate fairly well but experienced some distress after eating large meals. He continued to lose weight slowly

The patient was rehospitalized in July, 1940, for metabolic studies. He was placed on a basal analyzed diet made up from foodstuffs from a regular hospital menu and containing 300 Gm of carbohydrate, 70 to 80 Gm. of fat and 80 Gm. of protein After a period of seven days for adjustment to the diet and hospital routine the following studies were performed:

Basal diet	2 periods
Basal diet + 50 Gm of fat	2 periods
Basal diet + 70 Gm of beef protein	2 periods
Basal diet + oral liver extract	1 period

Periods of basal diet feeding were placed between the fat and beef supplement periods.

The metabolic studies were tolerated well. Frequent small feedings caused less epigastric distress and a slight gain in weight.

The patient was followed in the outpatient department, where studies with yeast and bile salts, supplements to the diet, were attempted, but proper evaluation of these agents could not be carried out due to dietary indiscretions and lack of cooperation on the part of the patient.

The patient died at home in October, 1941. Necropsy was not performed.

Pathologic Study.—The stomach was involved by an extensive scirrhous type of cancer with serosal infiltration but without visible or palpable metastases to nodes or adjacent mesothelial surfaces. The growth extended to within 1 cm. of the esophagus on the lesser curvature. The specimen appeared to be a total gastrectomy with a small portion of the duodenum. A large tumor measuring 8 by 4.5 by 2.5 cm. extended along the lesser curvature 8 cm. distant from the duodenal line of excision to 2 cm. distance from the esophageal line of excision. The mucosa over the tumor was flat, had lost its rugae, and was paler than the surrounding mucosa. There were three ulcerated areas over the tumor proper. Three and one-half centimeters from the duodenal incision was a soft sessile polyp 2 cm. in diameter. The remaining gastric mucosa was moderately infected.

Microscopic Study.—Examination showed adenocarcinoma, grade 3 or 4, perforating to the serosal surface. The polyp was adenomatous only. No nodes were found.

Laboratory Data.—At postoperative study, urine showed an occasional slight trace of albumin, with normal sediment and urinary gluconates, 460 mg. per twenty-four-hour period; a Fishberg concentration test carried out July 31, 1941, showed a maximum specific gravity of 1.014. Stools were brown, well formed, and of the usual consistency. Guaiac test for blood was negative. Blood chemistry showed urea nitrogen, 11.1 mg. per cent; bilirubin, 0.5 mg. per cent; cholesterol, total, 147 mg. per cent; cholesterol, free, 66 mg. per cent; cholesterol esters, 81 mg. per cent; prothrombin, 96 mg. per cent; calcium, 10.8 mg. per cent; phosphorus, 4.3 mg. per cent; plasma vitamin A, 130 U.S.P. units; carotene (plasma), 0.10 U.S.P. units; thiamine, red blood cells, 10 micrograms per 100 ml.; and leucocytes, 101 micrograms per 100 ml.; Kahn and Kline serologic tests were negative.

Glucose tolerance test, after ingestion of 100 Gm. of glucose, revealed:

Time (minutes)	Fasting	30	60	120	180
Glucose in blood, mg. per cent	101.5	129.2	247	120.5	60.4

No glycosuria

A preoperative gastric analysis showed:

	Free Acid (N/10 HCl)	Combined Acid (N/10 HCl)
Before histamine	0 ml.	8 ml.
15 min. after histamine	0 ml.	10 ml.
30 min. after histamine	0 ml.	10 ml.
45 min. after histamine	0 ml.	8 ml.
60 min. after histamine	0 ml.	8 ml.

There was insufficient postoperative material for analysis.

PATIENT D. S. (total gastrectomy for carcinoma of stomach).—D. S., a 42-year-old woman, was admitted to the hospital in January, 1940, for metabolic studies. Total gastrectomy for a linitis plastica type of carcinoma of the stomach had been performed at another hospital in November, 1938. An end-to-side esophagojejunostomy and side-to-side jejunojejunostomy were established as well as a jejunostomy for temporary feeding purposes. In the twelve months' interval between hospitalizations there was a weight loss of thirty pounds despite a fair appetite and the consumption of a fairly adequate diet.

On admission to the hospital, in January, 1940, the patient was given a basal diet made up from regular hospital foodstuffs which consisted of 30 to 35 Gm. of protein, 60 Gm. of fat, and 450 Gm. of carbohydrate. No metabolic studies were performed for a period of six days in order to allow the patient to become adjusted to the diet and new environment.

The following studies were then carried out:

Basal diet	2 periods
Basal diet + 50 Gm. of fat daily	2 periods
Basal diet + 80 Gm. beef protein daily	2 periods

Basal period feedings were inserted between the fat and beef supplement periods.

It was found desirable to feed the patient six feedings a day to relieve a slight postprandial epigastric distress. Otherwise the metabolic studies proceeded in a smooth fashion.

The patient was discharged to her home and care of her family physician.

In October, 1940, multiple and diffuse carcinoma metastases were demonstrated in the peripheral lymph nodes, the operative wound, and bony skeleton. Death occurred in November, 1940. Necropsy was not performed.

Laboratory Data.—At postoperative examination at Memorial Hospital, urine was normal and urinary glucuronates 400 mg. per twenty-four hours. Stools were brown, well formed, and of usual consistency. Guaiac test for blood was negative. Blood chemistry showed urea nitrogen, 7.4 mg. per cent; bilirubin, 0.25 mg. per cent; serum protein, 6.0 mg. per cent; serum sodium chloride, 700 mg. per cent; total cholesterol, 91.2 mg. per cent; free cholesterol, 47.6 mg. per cent; cholesterol esters, 43.6 mg. per cent; bilirubin, 0.5 mg. per cent; prothrombin, 78 mg. per cent; plasma vitamin A, 126 U.S.P. units; and carotene plasma, 0.08 U.S.P. units.

Glucose tolerance test, after ingestion of 100 Gm. of glucose, revealed:

Time (minutes)	Fasting	30	60	120	180
Glucose in blood, mg. per cent	73.5	140.8	157.4	132	56

No glycosuria

Pathologic Study of Stomach (November 9, 1938):

Gross: The specimen was a small contracted stomach with firm, cartilage-like thickening of the wall of the upper half encircling it and extending into the fundus. There was diffuse thickening and edema of the entire stomach wall. The wall measured 1 cm. in thickness. The stomach measured 22.0 cm. in length and 7 cm. in its greatest diameter. No abnormal lymph nodes were encountered. The mucosa was flattened and rugae were absent. There was no ulceration.

Microscopic: The character of the fibrosis was that of linitis plastica. There was a chronic gastritis. Clusters of cells were seen in the desmoplastic submucosa, which were diagnosed as cancer.

Laboratory Data: Study revealed urine normal. The stools were small, brown, and well formed, and blood was demonstrated preoperatively but not postoperatively.

Blood chemistry:

	Oct. 5, 1940	Oct. 25, 1940
Urea nitrogen	17.6 mg. per cent	19.6 mg. per cent
Bilirubin	0.6 mg. per cent	
Calcium	9.8 mg. per cent	11.5 mg. per cent
Phosphorus	4.6 mg. per cent	
Phosphatase		6.4 units
Serum albumin		3.9 mg. per cent
Serum globulin		1.9 mg. per cent

Glucose tolerance test, after ingestion of 70 Gm of glucose, showed:

Time (minutes)	Fasting	30	60	120	180
Glucose in blood, mg. per cent	115	280	260	153	114
Glucose in urine	0	1+	0	0	0

The basal metabolic rate was −8 per cent and −11 per cent

A preoperative gastric analysis showed

	Free Acid (N/10 HCl)	Combined Acid (N/10 HCl)
Before histamine	8 ml	20 ml
5 min after histamine	14 ml	24 ml
15 min after histamine	18 ml	28 ml
30 min. after histamine	12 ml	22 ml
60 min after histamine	10 ml	20 ml

REFERENCES

1. Gordon Taylor, G., Hudson, R. V., Dodds, E. C., Warner, J. L., and Whitby, L. E. H. The Remote Results of Gastrectomy, Brit. J. Surg. 16: 641-667, 1929.
2. Wroblewski, A. Eine chemische Notiz zur Schlatter'schen totalen Magenexstirpation, Centralbl. f. Physiol. 11: 665-668, 1897.
3. Schlatter, C. Ueber Ernahrung und Verdauung nach vollstandiger Entfernung des Magens. Oesophagoenterostomie beim Menschen, Beitr. z. klin. Chir. 19: 757-776, 1897.
4. Lublin, H. On Late Symptoms After Gastroenterostomy and Resection of Stomach (Billroth II) for Gastric and Duodenal Ulcer, Acta med. Scandinav. supp. 41, 1: 131, 1931.
5. Rekers, P. E., Abels, J. C., and Rhoads, C. P. Metabolic Studies in Patients With Cancer of the Gastrointestinal Tract. IV. Fat Metabolism—a Method of Study, J. Clin. Investigation 22: 243-248, 1943.
6. Abels, J. C., Rekers, P. E., Binkley, G. E., Pack, G. T., and Rhoads, C. P. Metabolic Studies in Patients With Cancer of the Gastrointestinal Tract. II. Hepatic Dysfunction, Ann. Int. Med. 16: 221-240, 1942.
7. Abels, J. C., Gorham, A. T., Pack, G. T., and Rhoads, C. P. Metabolic Studies in Patients With Cancer of the Gastrointestinal Tract. I. Plasma Vitamin A Levels in Patients With Malignant Neoplastic Disease, Particularly of the Gastrointestinal Tract, J. Clin. Investigation 20: 749-764, 1941.
8. a. Thaysen, T. E. H. Non-Tropical Sprue, a Study in Idiopathic Steatorrhea, Copenhagen 1932, Levin & Munksgaard.
   b. Thaysen, T. E. H. Ten Cases of Idiopathic Steatorrhea, Quart. J. Med. 4: 359-395, 1935.
9. Bassett, S. H., Keutmann, E. H., Hyde, H. V., and Van Alstine, H. E. Metabolism in Idiopathic Steatorrhea. I. Influence of Dietary and Other Factors on Lipid and Mineral Balance, J. Clin. Investigation 18: 101-120, 1939.
10. Dragstedt, L. The Present Status of Lipoidic, J. A. M. A. 114: 29-32, 1940.
11. Beazell, J. M., Schmidt, C. R., and Ivy, A. C. On Effectiveness of Orally Administered Diastase in Achylia Pancreatica, J. Nutrition 13: 29-37, 1937.
12. Coffey, R. J., Mann, F. C., and Bollman, J. L. III. The Influence of the Pancreas on the Utilization of Foodstuffs, Am. J. Digest. Dis. 7: 144-149, 1940.
13. Rekers, P. E., Pack, G. T., and Rhoads, C. P. Metabolic Studies in Patients With Cancer of the Gastrointestinal Tract. V. Pancreatic Insufficiency in a Patient Treated Surgically for Carcinoma of the Ampulla of Vater, J. A. M. A. (In press.)
14. Munk and Rosenheim. Quoted by Magnus-Levy, Adolf. The Physiology of Metabolism, in: von Noorden, Carl. Metabolism and Practical Medicine, Chicago, 1907, W. T. Keener & Co., vol. I, p. 112.
15. Barker, W. H., and Hummel, L. E. Microcytic Anemia in Association With Intestinal Strictures and Anastomoses, Bull. Johns Hopkins Hosp. 64: 215-256, 1939.

16. Castle, W. B., Rhoads, C. P., Lawson, H. A., and Payne, G. C.: Etiology and Treatment of Sprue, Arch. Int. Med. 56: 627-699, 1935.
17. Meulengracht, E.: Etiological Factors in Pernicious Anemia. Univ. Wisconsin, Symposium on Blood, Madison, 1939, pp. 72-82.
18. Minot, G. R., and Murphy, W. P.: A Diet Rich in Liver in the Treatment of Pernicious Anemia. Study of 105 Cases, J. A. M. A. 89: 759-766, 1927.
19. Castle, W. B.: Observations on the Etiologic Relationship of Achylia Gastrica to Pernicious Anemia. I. The Effect of Administration to Patients With Pernicious Anemia of the Contents of the Normal Human Stomach Recovered After the Ingestion of Beef Muscle, Am. J. Med. Sc. 178: 748-764, 1929.
20. Whipple, G. H.: Hemoglobin and the Plasma Proteins: Their Production, Utilization and Inter-relation, Am. J. Med. Sc. 203: 477-489, 1942.
21. Rhoads, C. P.: Aplastic Anemia. Univ. Wisconsin, Symposium on Blood, Madison, 1939, pp. 31-40.
22. Haden, R. L.: The Nature of Hemolytic Anemia, Univ. Wisconsin, Symposium on Blood, Madison, 1939, pp. 83-104.
23. Graham, E. A., and Hartmann, A. F.: Subtotal Resection of the Pancreas for Hypoglycemia, Surg., Gynec. & Obst. 59: 474-479, 1934.

UNILATERAL DECAPSULATION OF KIDNEY FOR TRANSFUSION OLIGURIA

SPENCER C. FLO, M.D., AND HARWOOD W. CUMMINGS, M.D.
GREENFIELD, MASS.

DECAPSULATION of the kidney has been so discredited in the past that the medical profession has accepted it somewhat reluctantly as a lifesaving measure in cases of transfusion oliguria. Very little has been written in recent years on this subject, but Nichol[1] has reviewed the theories covering the mechanism of decapsulation and we are quoting liberally from his article. The operation was first performed by Reginald Harrison of England,[1] in 1878. Later Rovsing and Edebohls did a similar operation for Bright's disease. Many hundreds of such cases so treated were reported at that time, but the classification was so confused and the results so equivocal, that the procedure was condemned.

The anatomy of the renal capsule has been clearly described by Rolnik[1] of Chicago:

> The renal capsule, the true or fibrous capsule, is a fibromuscular structure which contains some smooth muscle and elastic fibers. It envelops the kidney somewhat loosely, but quite securely, and covers it much in the manner of a hood, being firmly attached at its neck or hilus where the pelvis and vessels enter, and covering its surface rather loosely. Due to this arrangement the capsule can be readily freed from the surface of the kidney, and thus decapsulation can be done without injury to the parenchyma. All other parenchymatous organs have a capsule which is firmly attached and which cannot be removed, except by tearing of the surface, and often producing considerable trauma. The elastic fibro-muscular structure of the capsule, together with its rather loose attachment to the surface of the kidney, permits it to accommodate itself readily to any rapid variation in the size of the kidney, which may occur as result of change in intrarenal tension.

The following theories have been advanced to show why decapsulations are of value for nephritis:

1. Harrison stated that decapsulation simply relieves tension in the kidney.
2. Volhard thought the mechanical effect of handling and squeezing the kidney at operation probably caused a protein shock.
3. Horder[5] compared the operation with a simple wet cupping, i.e., oozing from the denuded cortex.
4. R. K. Sen of Vienna suggested that the opening of lymphatic channels from the cortex is the important factor, and through these chan-

Received for publication, Dec. 31, 1942.

nels it is possible to drain an infected renal cortex. In support of this theory he drew attention to the fact that there is frequently a profuse flow of clear discharge from the draining tract leading to the kidney cortex.

5. Many believe the good effects of decapsulation for nephritis are brought about by a profuse collateral circulation developed immediately following operation. This has been definitely disproved by Haslinger and Rolnick,[1] who have shown that the new capsule is thicker than the original, but the benefits of the operation long outlast the short period required to develop a new capsule. It has been found by experimenters that within a period of seven to ten days after decapsulation, a newly formed capsule is on its way to development and is well established within three weeks. This continues to increase in thickness for two months. The new capsule which replaces the old is not similar to the original, for it consists of scar tissue only. It has no elasticity, is firmly adherent to the kidney surface, and infiltrates the cortex. While some European surgeons speak of repeated decapsulations, it is not possible to separate this new capsule without tearing the renal parenchyma. There is no space between the cortex and the new capsule allowing for free interchange of fluid and lymph. It has been demonstrated that indigo carmine injected under one normal capsule is rapidly excreted from both kidneys, so there must be a free interchange between the renal parenchyma and this fluid.

6. Fisher did much work on anastomosis of sympathetic nerves of the kidney capsule. In general, these nerves run independently of the vessel nerves in the kidney parenchyma adjacent to the capsule. A network of all the capsular nerves lies at the hilus, and Fisher is of the opinion that this in some reflex manner influences the flow of blood through the kidney. He claims that faradic and mechanical stimulation of the capsule decreases the volume of the kidney without any appreciable effect on the blood pressure. He concludes that the renal capsule is a reflex-regulating apparatus for blood flow through the kidney. Decapsulation breaks up the sympathetic connections between the cortex and the capsule, and thus in reality is a sympathectomy. In inflammation of the kidney spasms of blood vessels play a major part and in decapsulation the breaking up of the sympathetic system causes the vessels to lose their vasomotor tone. Accordingly, by decapsulation, the blood circulation of the kidney is improved and the damage caused by stagnant toxins is eliminated, as these toxins are harmful to the secretory and excretory systems of the kidney.

Regardless of the mechanism involved in decapsulation, when used for transfusion oliguria, where bilateral operation was done, the results have been spectacularly good. Of course, it will always be debated whether or not the beneficial effect is purely coincidental. A great deal of experimental work could still be done in this field. Notwithstanding

the immediate benefits, there is little question that the kidneys remain permanently damaged, because of the denseness and adherence of the newly formed capsules. Ravich,[2] for example, refers to cases which have had bilateral decapsulation, where subsequent intercurrent infections caused fresh embarrassment of the kidneys, and ended in death because further decapsulation could not be performed.

Very few cases of unilateral decapsulation have been reported, but Forbes and Packard[3] did a unilateral decapsulation for nephritis, following an appendectomy, with diuresis and recovery, although they failed to describe the condition of the kidneys postoperatively. Ravich[2] described a case of unilateral decapsulation for transfusion oliguria with diuresis and recovery, but he too, failed to show the postoperative state of the kidneys, except to say that they functioned normally. If it is true that both kidneys will respond to unilateral decapsulation, then we feel that it is the procedure of choice, because if anything should happen to the decapsulated kidney, there would still be a definite margin of safety, an intact kidney.

REPORT OF A CASE

A 48 year old woman who had always enjoyed good health had been transfused seven days prior to her admission to this hospital. The day before her transfusion she had had a diagnostic curettage and amputation of the cervix because of vaginal bleeding of twelve days' duration. The preoperative blood studies showed a red count of 3,550,000 and a hemoglobin of 71 per cent, but because the patient had felt "washed out" and tired, her local doctor thought the giving of some blood would hasten her recovery. After 450 c.c. of citrated blood had been injected, it was noted that she was in severe shock. She rapidly responded to the usual supportive treatment, but upon catheterization twelve hours later, 200 c.c. of black urine were obtained. At this time we saw the patient in consultation. Nausea and vomiting had begun shortly after transfusion, necessitating Wangensteen drainage. It was estimated that her stomach drainage was 1,000 to 1,200 c.c. daily and insensible fluid loss 1,000 c.c. She was given 3,000 c.c. of intravenous fluids daily, consisting of 1,000 c.c. 5 per cent glucose in physiologic saline solution, and 2,000 c.c. 5 per cent glucose in distilled water. Her local doctor attempted to combat acidosis by soda bicarbonate orally but this was ineffectual because of vomiting.

During the next week her urinary output was 60 to 90 c.c. for each twenty-four-hour period. The urine was very concentrated, showing 4 plus albumin, slight acetone, and many white blood cells. During the latter part of the week she began to have edema of the face and extremities and became very drowsy. Her blood pressure had risen from 120/60 to 140/80. At this time it was thought wise to transfer her to the Franklin County Public Hospital.

Our examination revealed a woman with generalized edema. The lungs were clear and the abdomen slightly distended, possibly due to edema of the overlying subcutaneous tissues. Both kidneys were markedly enlarged and tender. The heart was normal and the blood pressure 140/70. Pelvic examination was not done, but she had very little vaginal bleeding since operation. The blood chlorides were 490 mg. The red blood count was 1,775,000, hemoglobin 35 per cent, white blood count 8,700, polymorphonuclears 86 per cent, and the blood nonprotein nitrogen 118 mg.

The following day the urinary output was about the same and general condition had not changed. The next day, nine days after transfusion, she seemed more

stuporous. The nonprotein nitrogen had risen to 180 mg. On this day her hemoglobin was 28 per cent, red blood count 1,920,000, white blood count 16,300, with 94 per cent polymorphonuclear cells. A unilateral decapsulation was elected because of severe secondary anemia and poor general condition.

The left kidney was operated upon under local anesthesia, a subcostal incision was made and great care was taken throughout the operation to ligate vessels as we went along, using No. 50 cotton. The kidney was markedly enlarged, purplish blue, and bulged through the incised capsule, with some escape of fluid. It was stripped to the hilus. There were no remaining areas of constriction, and no apparent injury to the parenchyma during the procedure. A drain was placed in the depth of the wound and the incision closed in layers, using No. 30 cotton. The patient's condition at the end of the operation was no worse than before.

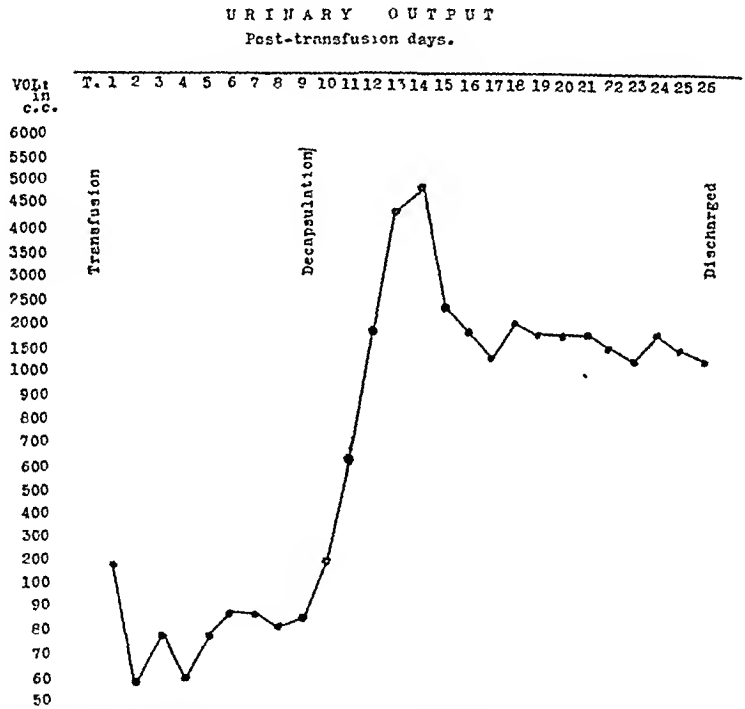

Fig. 1.—Intake of fluids, from two days after transfusion until two days after decapsulation, was consistently 3000 c.c. intravenous (2000 c.c. of 5 per cent glucose in distilled water, and 1000 c.c. of 5 per cent glucose in normal saline solution).

Immediately after surgery she seemed better; vomiting ceased, she was more alert, and her spirits improved. The intravenous fluids were continued as before, as well as large doses of ascorbic acid. Plasma or any other proteins were not given for replacement, because we were fearful of what any foreign protein might do to the already damaged kidneys. She was catheterized every twelve hours postoperatively. The first twenty four hour period produced 211 c.c. of urine with a foul odor, cultures of which showed colon bacillus. At this time the Wangensteen tube was clamped and she was able to take cracked ice without further vomiting. The second twenty four hour postoperative period produced 625 c.c. of much clearer urine. Now the nonprotein nitrogen was 215 mg., the blood pressure was 160/60, the patient was taking liquids by mouth, and intravenous therapy was discontinued. In

the third twenty-four-hour period 340 c.c. of urine were obtained by catheter, but during the night marked diuresis started, and she had large involuntary voidings. At this time there was a large amount of serous drainage from the wound. Thereafter she was able to pass much urine (Fig. 1). The edema rapidly disappeared and her kidneys were no longer palpable. As soon as tolerated, a high protein diet was given, as well as large doses of iron, but the blood and hemoglobin regenerated slowly. She continued to improve from this time on, except for marked mental confusion on the fifth postoperative day. The psychiatrist who saw her felt this condition was probably due to sudden loss of fluids, and the confusion was controlled by paraldehyde.

She was discharged on the eighteenth postoperative day. The red blood count was then 2,440,000, hemoglobin 42 per cent, white blood count 6,100, and the nonprotein nitrogen 20 mg. per cent. The wound healed by first intention. The pathologic report of the previous operation had returned and, as it showed no malignancy, she was sterilized by x-ray for functional uterine bleeding.

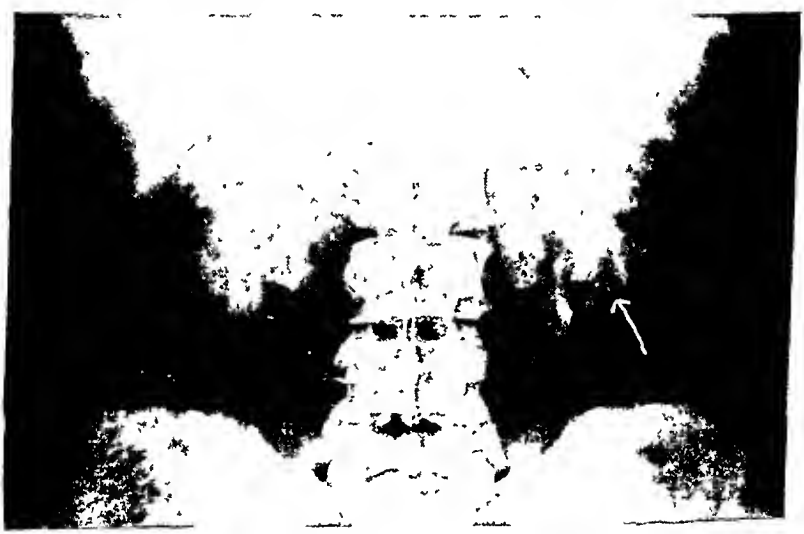

Fig. 2.—Eight minutes after injection of diodrast. (Courtesy of Dr. Felix G. Fleischner, Beth Israel Hospital, Boston.

In her home-town the patient had been typed as of Group II, by the Moss technique, and the donor as of Group IV. A recheck by us revealed the patient to be a type IV and the donor type II. The cross-matching showed rapid agglutination with hemolysis, so that within five minutes, no clumping was observed, as the clumps had been hemolyzed.

The patient was seen two months later. She was feeling very well except for multiple joint pains, although she had never had rheumatism in the past, presumably menopausal arthralgia or some joint change resulting from the transfusion reaction. Hemoglobin was 75 per cent, the red blood count 4,000,000, the nonprotein nitrogen 20 mg. Complete urologic studies were made and cystoscopic examination revealed a normal bladder; catheters were placed in each kidney pelvis, and there was a clear, intermittent drip bilaterally. A split function showed appearance of dye on the right in 3 minutes, and on the left in 3½ minutes. Intravenous pyelograms were carried out and the results can be seen by the following photographs, with a report by the roentgenologist. Fleischner of Boston says:

The left kidney is slightly lower than normal. Intravenous pyelography, performed with diodrast, showed good excretion of dye on either side after eight minutes. On the eight minute film, groups of pinhead sized deposits of dye were seen in the medial lower quadrant of the left kidney, otherwise the calyces and kidney pelvis were well outlined. The films taken after twenty minutes showed these small deposits communicating and emptying into the lower calyx and the pelvis. On the left there is a kink at the ureteropelvic junction and atony of the upper third of the ureter. The significant result of this examination is the fact that the left as well as the right kidney showed normal excretion and good concentration of dye with the intrarenal passages well preserved in width and shape. There was a single unusual finding; the small deposits of dye, for which observation we have been unable to find an analogy in the literature accessible to us. Thus, we feel compelled to advance a tentative interpretation of this observation. The small "cavities," as visualized by the dye, located in the cortex of the medial lower quadrant of the kidney, receive their dye from the excretory system of the kidney. There has been, apparently, minimal traumatization of this portion of the kidney parenchyma, resulting in interference with some of the collecting tubules. Small pools have been formed, and by some kind of recanalization, drainage of these pools to the calyx has been established to compensate for the supposed localized damage.

Fig. 3.—Twenty minutes after injection of diodrast. (Courtesy of Dr. Felix G. Fleischner, Beth Israel Hospital, Boston.)

It is to be understood that decapsulation is not to be employed until medical and supportive measures have failed. We feel the most important medical treatment is the intelligent use of fluids. Coller[4] states that "water balance should be maintained with isotonic glucose solution, taking into account the insensible loss and that lost by vomiting and Wangensteen drainage. Sodium chloride solution should be used only to cover salt losses by vomiting and drainage, and aside from this should never exceed more than one-half liter a day. The CO_2 combining power should be kept above 60 by use of sodium lactate solutions, 1/6 molar,"

After an arbitrary period of about one week of medical and supportive treatment which has failed to increase appreciably the urinary output, decapsulation must be considered, as the patients in a few of the reported cases of late decapsulation have died, even after the onset of brisk diuresis, and autopsy has revealed severe necrosis of the kidney. We feel that no case should be allowed to terminate fatally for the patient without the benefit of surgery.

We have presented a case of uremia, following transfusion reaction, apparently cured by unilateral decapsulation of the kidney. The exact mechanism is not clearly understood and certainly deserves investigation, both clinically and experimentally. Since the patient's condition was becoming progressively worse, and spontaneous recovery was despaired of, we felt that a unilateral decapsulation would do less harm than bilateral, and that bilateral might cause enough shock to result in an unfavorable outcome. If a unilateral decapsulation will break the vicious chain of events, this is the procedure of choice, especially in view of the damage to the kidney such an operation must entail.

REFERENCES

1. Nichol, J. E.: Indications for Decapsulation of Kidney, Canad. M. A. J. 43: 577, 1940.
2. Ravich, A.: Transfusion Reaction With Anuria and Uremia Cured by Unilateral Renal Decapsulation, M. Rec. 154: 403, 1940.
3. Forbes, R. P., and Packard, G. B., Jr.: Treatment of Anuria by Kidney Decapsulation, Colorado Med. 29: 74, 1932.
4. Coller, Frederick: Ann Arbor, Mich. Personal Communication.

URINARY RETENTION FOLLOWING THE COMBINED ABDOMINOPERINEAL RESECTION

FREDERICK A. COLLER, M.D., AND PETER F. EASTMAN, M.D.
ANN ARBOR, MICH.
(From the Department of Surgery, University of Michigan, Ann Arbor)

INTRODUCTION

THE incidence and cause of urinary retention following the operation of combined abdominoperineal resection for rectal neoplasm are not clearly known despite many studies of this problem, some of which have appeared in the literature of the subject.[1-3] The occurrence of this complication is probably so variable with differing surgical techniques that observations made upon this point by any individual are of limited value so that one cannot safely generalize from them. However, the nature of certain possible pathophysiologic changes in the act of micturition can be studied by accurate yet relatively simple means and such a study should furnish valuable information of both prognostic and therapeutic value.

Adequate emptying of the bladder depends, to a considerable extent, upon proper function of the detrusor mechanism[5] which receives its major motor nerve supply from sacral roots of the second, third, and fourth parasympathetics. The position of these sacral roots and the pelvic nerves of their peripheral extension in the sacral plexus has led some previous investigators[2, 3] to conclude that a marked degree of operative trauma to these structures is inevitable during removal of the rectum and that subsequent urinary retention is due, at least in part, to atony of the bladder. Therefore, a study was made at the University Hospital to determine the effect of the one-stage combined abdominoperineal resection upon the motor activity of the urinary bladder.

METHODS AND PROCEDURE

Twenty-two unselected patients undergoing one-stage combined abdominoperineal resection with spinal anesthesia (nupercaine, 15 c.c.) were studied by means of pre- and postoperative cystometrograms. The technique employed was that described by McClellan.[4] A simplified water cystometer was used for these determinations. The preoperative study was made on the morning of operation. At this time, the bladder was filled to ultimate capacity, that is until uncontrolled voiding about the catheter was noted and readings taken. The postoperative determi-

Aided by The James and Elizabeth Inglis Fund for Surgical Research.
Received for publication, Dec. 14, 1942.

TABLE I

CYSTOMETROGRAMS*

PATIENT	SEX	AGE (YR.)	NEOPLASM	LOCATION	I. V. P. (CM. H_2O)	CAPACITY (C. C.)	HOT AND COLD	REMARKS
D. H.	M	67	Adenoca. G II	Ant. wall, 1½ in. above sphincter	35	235		Small capacity bladder, multiple urethral strictures
O. H.	M	59	Adenoca. G II	Ant. wall, low	75	100	++	Small capacity bladder, chronic cystitis
E. W.	M	51	Adenoca. G III	Ant. wall, at sphincter	80	600	++	
A. B.	F	63	Adenoca. G II	Annular, midrectum	26	400	++	
O. C.	F	59	Adenoca. G II	Post wall, midrectum	11	200	++	Not ultimate capacity
D. P.	M	59	Adenoca. G II	Midrectum, annular	28	500	++	
L. S.	M	47	Adenoca. G III	Annular, low rectum	27	625	++	
L. L.	M	41	Adenoca. G II	Annular, low rectum	50	450	++	
McN. W.	M	54	Adenoca. G II	Annular, low rectum	48	450	++	
A. F.	F	50	Adenoca. G II	Annular, low rectum	54	650	++	
M. M.	F	65	Adenoca. G II	Midrectum	30	500	++	
N. L.	F	57	Adenoca. G II	Left lat. wall, midrectum	25	525	++	
A. B.	F	67	Adenoca. G II	Annular, midrectum	29	750	++	
A. A.	F	55	Adenoca. G II	Annular, rectosigmoid	50	700	++	
D. M.	M	46	Adenoca. G II	Rectosigmoid	23	150		Small capacity bladder, cause unknown
A. R.	M	82	Adenoca. G II	Low rectum, ant. wall	50	500	++	
G. H.	M	45	Adenoca. G II	Midrectum, annular	55	500	++	
S. S.	M	45	Adenoca. G II		65	350	++	Small capacity bladder, cause unknown
G. R.	M	41	Adenoca. G II	Midrectum, post. wall	9.5	600	++	Low I. V. P., normal voiding, cause unknown
B. S.	M	70	Adenoca. G II	Low rectum, ant. wall	60	275	++	
W. N.	M		Adenoca. G II	Low rectum, ant. wall	35	300	++	
F. S.	F	28	Adenoca. G II	Small polyp. just at sphin.	24	525	++	

*Showing intravesical pressure, bladder capacity, and thermal sensation for all patients. The location and nature of the rectal neoplasm are also indicated.

nations were made twenty-four to forty-eight hours following operation, 300 c.c. of fluid were introduced into the bladder, and again cystometrograms were made. This procedure was considered adequate to demonstrate normal or abnormal detrusor activity since the intravesical pressure developed in response to this fluid volume could be compared with the intravesical pressure developed in response to a similar fluid volume in the complete cystometrogram recorded before operation. Therefore, if the patient could empty his bladder completely, as determined by postvoiding catheterization performed several days after the inlying catheter had been withdrawn (on three to seven postoperative days), no further studies of bladder motor activity were made. However, if urinary retention did develop following the catheter withdrawal, further cystometrograms, with complete bladder filling, were recorded during this period of retention. Bladder thermal sensation was determined at the time of each study by the injection of 60 c.c. of first warm and then cold water. Microscopic examination of the urinary sediment was made at the time of the other observations.

OBSERVATIONS

In Table I are presented the "normal" bladder capacity and intravesical pressure at capacity for each patient. Table II presents a comparison of the intravesical pressure developed in response to a given fluid volume before operation with that developed at a similar fluid volume following operation by all patients on whom the one-stage combined resection of the rectum was performed. The patients who developed urinary retention following operation are indicated by an asterisk, and the further complete cystometrograms performed upon these patients during this period of retention are compared in Table III, with the normal preoperative findings taken from Table I.

Table IV presents for comparison data collected by similar observations on patients on whom colostomy was performed.

COMMENT

It will be noted in Table I, that "normal" bladder capacity and intravesical pressure vary considerably from patient to patient within this group. Although this could be attributed to previous or extant genitourinary disease in some, in others no such explanation could be found. This implies clearly that accurate evaluation of the effect of the resection of the rectum or of any other operation upon the bladder motor activity cannot be made from postoperative cystometrograms alone. It can be seen (Table II) that bladder motor activity was not weakened following operation and that thermal sensation was not lost. This was equally true whether or not the patient developed urinary retention (Table III). A significant increase in intravesical pressure at a given fluid volume will be observed in the postoperative recording in several cases where the complete resection was performed; however,

TABLE I

CYSTOMETROGRAMS*

PATIENT	SEX	AGE (YR.)	NEOPLASM	LOCATION	I. V. P (CM. H_2O)	CAPACITY (C. C.)	HOT AND COLD	REMARKS
D. H.	M	67	Adenoca G II	Ant wall, 1½ in above sphincter	35	235		Small capacity bladder, multiple urethral strictures
O. H.	M	59	Adenoca G II	Ant wall, low	75	100	++	Small capacity bladder, chronic cystitis
E. W.	M	51	Adenoca G III	Ant. wall, at sphincter	80	600	++	
A. B	F	63	Adenoca G II	Annular, midrectum	26	400	++	
O. C.	F	59	Adenoca G II	Post wall, midrectum	11	200	++	Not ultimate capacity
D. P.	M	59	Adenoca G II	Midrectum, annular	28	500	++	
L. S.	M	47	Adenoca G III	Annular, low rectum	27	625	++	
L. L	M	41	Adenoca. G II	Annular, low rectum	50	450	++	
McN. W.	M	54	Adenoca G II	Annular, low rectum	48	450	++	
A. F	F	50	Adenoca G II	Annular, low rectum	54	650	++	
M. M	F	65	Adenoca G II	Midrectum	30	500	++	
N. L.	F	57	Adenoca G II	Left lat wall, midrectum	25	525	++	
A. B	F	67	Adenoca. G II	Annular, midrectum	29	750	++	
A. A	F	55	Adenoca G II	Annular, rectosigmoid	50	700	++	
D. M	M	46	Adenoca G II	Rectosigmoid	23	150		Small capacity bladder, cause unknown
A. R	M	82	Adenoca G II	Low rectum, ant wall	50	500	++	
G. H.	M	45	Adenoca G II	Midrectum, annular	55	500	++	
S. S	M	45	Adenoca G II		65	350	++	Small capacity bladder, cause unknown
G. R	M	41	Adenoca G II	Midrectum, post. wall	95	600	++	Low I. V. P., normal voiding, cause unknown
B. S.	M	70	Adenoca G II	Low rectum, ant wall	60	275	++	
W. N	M		Adenoca G II	Low rectum, ant. wall	35	300	++	
F. S	F	28	Adenoca G II	Small polyp just at sphin.	24	525	++	

*Showing intravesical pressure, bladder capacity, and thermal sensation for all patients. The location and nature of the rectal neoplasm are also indicated.

all patients exhibited during the period of inlying catheterization afford sufficient explanation for this increase in bladder motor activity.

Although urinary retention did develop in five patients, in four it was of short duration. Two patients were unable to void upon catheter withdrawal. Two voided easily at this time but accumulated a residuum of urine over several succeeding days. In all cases daily catheterization for a short period gave complete relief and all of these individuals were voiding easily and carried no residual urine at the time of leaving the hospital. The fifth patient developed extensive abscesses of both anterior and posterior wounds and remained a bed patient for two months following operation. She required continuous inlying catheter drainage during this period but repeated cystometrograms showed no evidence of increased vesical capacity or decreased intravesical pressure at any time. At the time of her discharge from the hospital, two and one-half months following operation, she was voiding normally and carried no residual urine.

These observations, although they indicate that the bladder nerve supply was functionally intact following operation, still offer no explanation for the mild urinary retention which did take place in five of the patients studied. It is possible that edema of the lower urinary tract incident to trauma played some part in the two individuals who experienced acute retention when the catheter was withdrawn, since daily catheterization for a short period gave them complete relief. It is also possible that operative transection of the vesicosacral ligaments may have caused alteration in the anatomic relations between the vesical neck and membranous urethra producing mechanical obstruction to proper urine outflow. The importance of this relationship in normal voiding has been stressed by Rose in his discussion of the physiology of micturition.[6] Further study of this aspect of the problem by pre- and postoperative urethrocystogram (x-rays) is necessary to elucidate this point. In addition, urinary retention may and does occur in the absence of demonstrable bladder nerve disease or obstructive uropathy as after herniorrhaphy, hemorrhoidectomy or any laparotomy. This type of urinary retention has never been adequately explained and it is probable that such explanation will not be forthcoming until the physiology of normal voiding is better understood.

The microscopic examination of the urinary sediment indicated that all patients had pyuria and bacteriuria twenty-four to forty-eight hours after the inlying catheter had been inserted. In only one patient did any clinical evidence of lower tract infection develop. One man developed bilateral epididymitis on the tenth postoperative day, which responded within six days to orally administered sulfadiazine (3 Gm. daily) and local heat with scrotal support. The pyuria and bacteriuria had subsided prior to the discharge of the patients from the hospital. All patients were given sulfadiazine, 1.5 Gm. daily, during the period that

TABLE II

PATIENT	FLUID VOLUME (C. C.)	PREOPERATIVE		POSTOPERATIVE	
		I. V. P. (CM.)	THERM. SENSE	I. V. P. (CM.)	THERM. SENSE
D. H.	235	35	++	38	++
O. H.	100	75	++	75	++
E. W.*	150	10.5	++	13.5	++
A. B.*	250	20	++	38.0	++
O. C.	200	11.0	++	11.0	++
D. P.	150	9.0	++	8.0	++
L. S.	475	18.0	++	24.0	++
L. L.	200	10.5	++	21.5	++
McN. W.	250	15.0	++	25.0	++
A. F.	200	19.0	++	20.0	++
A. B.*	250	14	++	17.0	++
D. M.	150	9.5	++	9.5	++
A. A.	350	6.0	++	16.0	++
A. R.	250	25	++	27.0	++
S. S.*	300	60	++	60	++
G. R.	300	6.0	++	6.0	++
B. S.	300	12.0	++	16.0	++
W. N.*	300	35	++	35.0	++
N. L.	300	12.5	++	14.0	++

Intravesical pressure developed in response to a given fluid volume before and after the combined abdominoperineal resection.

Asterisk indicates patients who developed urinary retention.

TABLE III

PATIENT	PREOPERATIVE		POSTOPERATIVE		REMARKS
	CAPACITY	I. V. P.	CAPACITY	I. V. P.	
E. W.	600	80	575	80	Cath. out 5 days; acute retention relieved by cath. for 48 hours
A. B.	400	26	450	33	45 days cath. drainage; postoperative abscesses
A. B.	750	29	750	29	Partial retention; cath. daily 5 days
S. S.	350	65	350	63	Partial retention; cath. daily 3 days
W. N.	300	35	275	35	Partial retention; cath. daily 48 hours

Pre- and postoperative bladder capacity and intravesical pressure in patients who developed urinary retention following combined abdominoperineal resection

TABLE IV

PATIENT	FLUID VOLUME (C.C.)	PREOPERATIVE		POSTOPERATIVE	
		I. V. P.	THERM. SENSE	I. V. P.	HOT AND COLD
M. M.	325	21.0	++	23.5	++
G. H.	150	15	++	57.0	++
B. S.	275	60	++	60	++

Presenting data similar to Table I for patients undergoing only sigmoid colostomy.

since this also took place in those patients who underwent only a palliative colostomy, it was probably due to causes other than traumatic irritation or disruption of the bladder nerve supply. Certainly the irritation of the lower genitourinary tract by the indwelling catheter, the continuous decompression of the urinary bladder, and the pyuria which

TISSUE REACTIONS TO MEDICAMENTS USED IN THE LOCAL TREATMENT OF BURNS

MARK E. MAUN, M.D., RICHARD C. SCHNEIDER, M.D.,
MATTHEW A. PILLING, M.D., AND JOHN WINSLOW HIRSHFELD, M.D.
DETROIT, MICH.

(From the Department of Pathology and the Department of Surgery, Wayne University College of Medicine, and the Surgical Service of Receiving Hospital, Detroit)

MANY surgeons have compared a burn to an open wound and have advocated treating it as such. This comparison is an apt one, since in both the continuity of the surface epithelium has been destroyed. If we accept the dictum that a burn must be regarded as an open wound, then no material should be applied to its surface which will produce further tissue damage or, in effect, make the burn more severe. Our purpose in this communication is to call attention to the tissue alterations produced on the fresh wounds of dogs by materials commonly used in the treatment of burns.

We had had the opportunity of observing the behavior of burned surfaces in seventy-five human patients treated by the application of agents commonly recommended for the local treatment of burns.[1] Many of the patients had been burned in several areas; thus each area could be treated with a different agent, and we were able to compare a large number of agents. Our observations led us to suspect that some of the eschar-forming agents increased the tissue damage, since the healing time of burns treated with these drugs was slower than that of apparently comparable burns treated with an inert ointment beneath a voluminous pressure dressing. Clinical observations of this sort are necessarily open to question, for it is difficult to estimate the depth of burns when they are first seen. In order to determine definitely whether or not our clinical impression was correct, we compared by means of biopsies the effects of tannic acid and silver nitrate and of quebracho tannin with those of vaseline gauze on human donor sites from which split-thickness grafts had been removed with the Padgett dermatome. Except for the covering of burned tissue such surfaces simulate second degree burns. This study demonstrated the destructive power of tannic acid plus silver nitrate and of quebracho tannin on human tissues in such a striking fashion that we were led to speculate about the action of other eschar-forming substances commonly employed for the local treatment of burns. Since the number of patients requiring skin grafts is limited, we were forced to resort to experimental animals.

Received for publication, March 10, 1943.

the catheter was inlying and for twenty-four to forty-eight hours following its withdrawal.

SUMMARY

Bladder motor activity and thermal sensation were studied in twenty-two unselected cases before and after operation for rectal cancer:

1. Preoperative cystometrograms in this series indicate a great variation in bladder capacity and intravesical pressure in subjects who have normal bladder function.

2. A comparison of pre- and postoperative cystometrograms disclosed no evidence of injury of nerves governing vesical function.

3. The etiology of the temporary urinary retention which did develop in five patients is not known; certain possible causative factors are mentioned and methods for their further elucidation are suggested.

4. Oral administration of sulfadiazine, 1.5 Gm. daily, did not prevent the development of pyuria and bacteriuria in all patients after forty-eight hours of inlying catheter drainage.

5. Abdominoperineal resection of the rectum destroys neither the autonomic nor the somatic nerve supply to the bladder.

In view of these facts it is probable that postoperative urinary retention after this operation as after some other operations, such as hemorrhoidectomy, is due to local trauma and reflex inhibition.

REFERENCES

1. Whipple, Allan O.: Complications Associated With Major Proctectomy, Ann. Surg. 96: 916, 1932.
2. Hill, M. R., Barnes, R. W., and Courville, C. B.: Vesical Dysfunction Following Combined Abdominoperineal Resection, J. A. M. A. 109: 1184, 1188, 1937.
3. Mullen, T. F., and Lestrohon, P.: Urologic Complications of Cancer of the Rectum, Ann. Surg. 1: 6, 18, 1942.
4. McClellan, F. C.: The Neurogenic Bladder, Baltimore, 1939, Charles C Thomas, Publisher.
5. Langworthy, O. R., Kolb, L. C., and Lewis, L. G.: Physiology of Micturition, Baltimore, 1940, Williams & Wilkins Company.
6. Rose, D. K.: Physiology of the Bladder, J. Urol. 1: 190, 198, 1940.

TISSUE REACTIONS TO MEDICAMENTS USED IN THE LOCAL TREATMENT OF BURNS

MARK E. MAUN, M.D., RICHARD C. SCHNEIDER, M.D.,
MATTHEW A. PILLING, M.D., AND JOHN WINSLOW HIRSHFELD, M.D.
DETROIT, MICH.

(From the Department of Pathology and the Department of Surgery, Wayne University College of Medicine, and the Surgical Service of Receiving Hospital, Detroit)

MANY surgeons have compared a burn to an open wound and have advocated treating it as such. This comparison is an apt one, since in both the continuity of the surface epithelium has been destroyed. If we accept the dictum that a burn must be regarded as an open wound, then no material should be applied to its surface which will produce further tissue damage or, in effect, make the burn more severe. Our purpose in this communication is to call attention to the tissue alterations produced on the fresh wounds of dogs by materials commonly used in the treatment of burns.

We had had the opportunity of observing the behavior of burned surfaces in seventy-five human patients treated by the application of agents commonly recommended for the local treatment of burns.[1] Many of the patients had been burned in several areas; thus each area could be treated with a different agent, and we were able to compare a large number of agents. Our observations led us to suspect that some of the eschar-forming agents increased the tissue damage, since the healing time of burns treated with these drugs was slower than that of apparently comparable burns treated with an inert ointment beneath a voluminous pressure dressing. Clinical observations of this sort are necessarily open to question, for it is difficult to estimate the depth of burns when they are first seen. In order to determine definitely whether or not our clinical impression was correct, we compared by means of biopsies the effects of tannic acid and silver nitrate and of quebracho tannin with those of vaseline gauze on human donor sites from which split-thickness grafts had been removed with the Padgett dermatome. Except for the covering of burned tissue such surfaces simulate second degree burns. This study demonstrated the destructive power of tannic acid plus silver nitrate and of quebracho tannin on human tissues in such a striking fashion that we were led to speculate about the action of other eschar-forming substances commonly employed for the local treatment of burns. Since the number of patients requiring skin grafts is limited, we were forced to resort to experimental animals.

Received for publication, March 10, 1943.

METHODS AND MATERIALS

By means of a Padgett dermatome it is possible to obtain skin injuries of almost constant depth. This machine, devised for the purpose of cutting Thiersch and split-thickness grafts, enables one to remove a uniform layer of skin of desired thickness. The knife usually removes the epidermis plus a small portion of the papillary layer of the corium. The hair follicles and the sebaceous glands in the remaining corium are left unharmed. These structures serve as a source of cells which will re-epithelize the surface of the naked dermis. The lesion produced (Fig. 1), except for the presence of a layer of burned epidermis, simulates a second degree burn. If the eschar-forming materials are capable of destroying normal tissues, their action should be manifest upon their application to such a surface.



Fig. 1.—Control, donor site immediately after preparation (magnification ×100)

Eighteen dogs were anesthetized with nembutal, their hair was clipped, and their flanks and thorax were shaved; their skin was then washed thoroughly with soap and water. Next it was cleansed with 70 per cent alcohol followed by ether in order to provide a dry surface. The cement used in conjunction with the Padgett dermatome was applied, and after it had dried, a layer of skin approximately 0.008 inch in thickness was removed from either side of the animal. Bleeding was controlled by pressure with gauze moistened with warm physiologic saline solution. As soon as the bleeding was controlled, the donor

site on one side of the animal was treated with a preparation of one of the following substances:

1. Triple dye compound
2. Sulfadiazine in triethanolamine with methocel
3. Thrombin and thrombin with fibrinogen
4. Paraffin
5. 10 per cent tannic acid
6. 5 per cent silver nitrate
7. 10 per cent tannic acid plus 5 per cent silver nitrate
8. Quebracho tannin

On the opposite side of each dog vaseline gauze dressings were applied to the similar donor site. Biopsies were taken from both wounds in each animal before application of the medicament and at approximately two, six, ten, and twenty-four hours after. In a few animals biopsies were taken more frequently and for longer periods of time than twenty-four hours. All biopsy specimens were fixed in 10 per cent formalin, embedded in paraffin, and stained with hematoxylin and eosin.

MICROSCOPIC OBSERVATIONS

*Triple Dye.**—Examination of the biopsies removed after two hours from donor sites on which triple dye had been placed revealed collections of fibrin and red blood corpuscles on the exposed surface of the corium. On this surface and between the collagenous bundles, small brownish granules were found. The superficial collagenous fibers adjacent to the granules presented a homogeneous appearance and were poorly outlined while the bundles in the deeper portions of the corium were sharply separated (Fig. 2). In the biopsies removed after four hours of treatment with the dye, almost one-half of the entire corium presented a homogeneous acidophilic appearance interrupted by irregular crevices. Only at the innermost portion of this homogeneous zone were normal collagenous fibers recognized. A few focal collections of leucocytes were seen about the vessels near the advancing edge of the eschar; these were granulocytes and lymphocytes. Hair follicles found in the homogeneous mass showed a marked loss of staining qualities. In the several sections available for examination at the end of six hours the lesion was little different from that seen at the end of the four-hour period (Fig. 3). In contrast, biopsies from donor sites covered by vaseline gauze showed, two to six hours after preparation of the site, small collections of fibrin and red blood cells on their dermal surface and normal collagenous bundles (Fig. 4).

Sections taken ten hours after application of the dye showed the eschar to be still thicker. It appeared as a dense, deeply staining mass sharply separated from the collagenous bundles of the deeper portion of the corium. The brittleness of the eschar was demonstrated by fragmentation produced by the microtome knife. Within the eschar,

*Two per cent gentian violet, 1 per cent brilliant green, and 0.1 per cent neutral acriflavine.



Fig. 2.—Donor site two hours after treatment with triple dye; note superficial homogeneous zone (magnification ×175).



Fig. 3.—Donor site six hours after treatment with triple dye; note early eschar formation (magnification ×175).

remnants of hair follicles were present, and at the edge numerous perivascular focal collections of leucocytes were found.

In sections taken twenty-four hours after the application of the dye, the eschar had extended through almost the entire dermis. The leucocytic exudate had increased to form a thick layer of cells extending into the subcutis. Numerous hair follicles were enmeshed in the brittle eschar, which was separating at many points from the underlying normal corium (Fig. 5). The donor sites covered by vaseline-impregnated gauze showed no evidence of damage to the collagenous fibers (Fig. 6).

Fig. 4.—Donor site at six hours, covered by vaseline gauze; note well-preserved collagenous fibers (magnification ×175).

One case in a human being in which triple dye had been applied to a prepared donor site was available for study. In the biopsy obtained one hour after its application the dye had provoked an exudate of fibrin and many red blood corpuscles. A comparable site treated with vaseline gauze showed little reaction. Six hours after application of the dye a rather marked exudate of fibrin and red blood corpuscles was seen on the surface of the wound. The eschar production in the dye-treated wound was evidenced by the appearance of a homogeneous, deeply staining, acidophilic zone. No leucocytic infiltration was yet in evidence. At six hours comparable wounds treated by vaseline gauze showed comparatively little reaction.

Examination of biopsies obtained at the end of fourteen hours showed the donor site which had been treated with vaseline gauze to be moder-

Fig. 5.—Eschar produced by triple dye at twenty-four hours (magnification ×100).

Fig. 6.—Donor site at twenty-four hours, covered by vaseline gauze, note lack of damage to dermis (magnification ×100).

ately infected, and numerous leucocytes were seen on the surface of the dermis. In contrast, a brittle eschar had formed on the wound treated by the triple dye, and the superficial portion of the dermis was almost replaced by this deeply staining homogeneous mass. Beneath it large collections of leucocytes were present.

*Sulfadiazine in Triethanolamine With Methocel.**—Eight donor sites were prepared for the application of this material, and opposite control sites were prepared for vaseline gauze. In biopsies obtained at two hours only small clumps of fibrin and a few red blood corpuscles were found on the surface of the dermis. The most superficial collagenous bundles were indistinct and appeared to coalesce. Between them an eosin-staining fluidlike material containing small granules was observed. In sections taken at four hours these bundles of collagenous fibers appeared to fuse, and the entire area stained more uniformly with eosin. An exudate made up of small groups of granular leucocytes separated the damaged from the deeper normal collagenous fibers. Sections prepared from biopsies of the donor sites six hours after application of vaseline gauze showed only small collections of fibrin and leucocytes on the surface, but in biopsies taken from the wounds treated by sulfadiazine in triethanolamine with methocel, the now familiar changes found in eschar production were observed. The most superficial collagenous bundles were deeply staining and almost homogeneous. Collagenous fibers immediately beneath the deeply staining area were almost indistinct, and about them focal collections of leucocytes were present. The damage to the dermis was variable in extent in all biopsies and was not always uniform in the same tissue section.

Examination of the biopsies removed ten hours following therapy revealed only a continuation of the previously related process, characterized by an increased penetration of the triethanolamine compound, destruction of hair follicles, and an increased leucocytic exudate. From twenty-four to thirty hours following therapy a large portion of the corium was destroyed by production of a brittle eschar, which eschar was apparently shattered by the microtome knife. In addition, an intensive leucocytic exudate was seen beneath the eschar and about the homogeneous collagenous fibers which had been damaged by the medicament.

It was possible to obtain biopsies from a human donor site treated by the triethanolamine compound at three, twelve, and thirty hours after treatment. The tissue reaction and formation of the eschar varied little from that seen in dogs. In the biopsies at three hours there was a mild fibrinous and leucocytic exudate present on the surface of the dermis. The collagenous fibers stained normally. At twelve hours, however, the superficial bundles had been converted into a narrow homogeneous eosin-staining zone, at the base of which a few leucocytes were present. In sections prepared from the biopsies thirty hours after

*Sulfadiazine 1.5 per cent, triethanolamine 5 per cent, aerosol OT, 0.1 per cent, methocel 1.67 per cent, sodium benzoate 0.2 per cent, and water q. s. ad 100 per cent. Furnished by Lederle Laboratories, Inc. New York.

application of the medicament the eschar was practically identical with that found in the biopsies taken at the end of the twenty-four-hour period.

Thrombin and Thrombin With Fibrinogen.*—Examination at two hours of sections from wounds covered by thrombin revealed on the surface a marked exudate of red blood corpuscles. A few leucocytes and small quantities of fibrin were also present. The application of thrombin and fibrinogen reduced the erythrocytic exudate, and the dermal surface was found to be covered with a loosely adherent eosin-staining granular mass. It seemed to push into the adjacent collagenous bundles but produced no evident tissue changes. In the biopsies taken after four to six hours, few additional changes were noted in the sections. In certain areas some collagenous bundles showed mild retrogressive changes and were surrounded by small collections of leucocytes. Similar retrogressive changes were noted when a donor site was covered by vaseline gauze or left untreated. In biopsies taken ten to twenty-four hours after application, numerous leucocytes were found on the dermis and throughout the superficial portion of it while the collagenous bundles often showed retrogressive changes. These findings were attributed to infection of the donor sites.

Paraffin.†—Examination of sections from donor sites covered by paraffin showed no damage to the dermis after two to four hours. The only constant finding was an increased number of granular leucocytes between the more superficial collagenous fibers. In sections taken after six hours the donor sites showed no evidence of tissue destruction nor alteration apparently due to the applied paraffin.

10 per cent Tannic Acid; 5 per cent Silver Nitrate; 10 per cent Tannic Acid plus 5 per cent Silver Nitrate; and Quebracho Tannin.‡—After comparing the biopsies from the donor sites treated by the above agents we concluded that the tissue changes produced were similar; hence these medicaments will be considered as a group in the following descriptions. In the biopsies taken after two hours of therapy these tanning substances were found as brown to brownish-black masses of refractile granules on the surface of the freshly denuded corium and between its collagenous bundles. Some of the material was also found in the incised hair follicles. In many of the sections the more superficial collagenous bundles stained more intensely and appeared glossy; these changes were interpreted as the earliest evidence of damage to the dermis.

Sections taken six hours following application of the tanning agents showed their deeper penetration between the collagenous bundles. The affected fibers now stained deeply with eosin and appeared as a com-

*Purified thrombin from beef plasma diluted with water to give 3,000 units per cubic centimeter. Furnished by Parke Davis & Co., Detroit, Mich.

†Paraffin wax 670 Gm., petrolatum 250 Gm., liquid petrolatum 120 Gm., cod liver oil 50 c.c., sulfanilamide powder 50 Gm., menthol 1 Gm., camphor 1 Gm., oil of eucalyptus 1 c.c.

‡Quebracho tannin, 75 per cent in water-soluble form and dihydroxylin 1,000 (meta-di-hydroxy-dihydrocinnamic acid). Furnished by Parke Davis & Co., Detroit, Mich.

pact homogeneous mass containing many hair follicles and sebaceous glands. This newly formed eschar was separated from the deeper normal corium by a thick layer of leucocytes. Biopsies taken from donor sites treated by vaseline gauze showed only a slight reaction to the medicament and surgical trauma. Small masses of fibrin and clusters of red blood cells were seen on the surface of the wounds. There was no evidence of tissue destruction.

Biopsies from donor sites treated by tanning agents showed striking changes after twenty-four hours of therapy. Beneath the tanning agents the eschar appeared as a structureless acidophilic mass separating at numerous points from the more normal dermis. These lines of separation were often limited by an intense leucocytic exudate which was embedded in collagenous bundles showing marked retrogressive changes. In subsequent biopsies these collagenous bundles formed a part of the complete eschar or slough, and complete re-epithelization occurred beneath them. In the wounds treated by vaseline gauze a varying degree of leucocytic extravasation probably dependent on secondary infection was found. Notably there was a little damage to the dermis and very little exudate between the collagenous bundles.

Examination of the donor sites at forty-eight hours showed them to be infected because of difficulty in keeping the dressings intact and the wounds clean. Tanning agents had produced extensive damage with destruction of the corium to a great depth, leaving undamaged only a thin strip of collagenous bundles and in some sections only the fatty subcutis. Vaseline gauze-treated wounds showed some damage to the superficial portions of the dermis, damage probably due to the observed infection.

DISCUSSION

Agents that produce a firm eschar have been used extensively in the treatment of burns. Although many advantages are cited favoring the use of such medicaments, very little attention has been given either to the clinical complications or to the tissue changes resulting from the application of eschar-forming agents. We are more concerned at present with the latter problem.

Since its introduction in 1927, tannic acid[2] has been used widely in the treatment of burns. Aldrich,[3] in 1933, applied aniline dyes which he believed formed an eschar superior to that formed by tannic acid, since (1) the eschar did not crack, (2) there was an instantaneous analgesia, and (3) the eschar supposedly sterilized the burn by neutralizing bacteria. He was of the opinion that burn "toxemia" paralleled infection. After some experience Aldrich added brilliant green and acriflavine to gentian violet solution to prevent the growth of gram-negative organisms. More recently, in 1941, Pickrell[4] advocated the use of 3 per cent sulfadiazine in 8 per cent triethanolamine to be sprayed upon burned areas. This likewise forms an eschar and in most instances prevents infection. Rothman and his co-workers[5] have just

application of the medicament the eschar was practically identical with that found in the biopsies taken at the end of the twenty-four-hour period.

Thrombin and Thrombin With Fibrinogen.*—Examination at two hours of sections from wounds covered by thrombin revealed on the surface a marked exudate of red blood corpuscles. A few leucocytes and small quantities of fibrin were also present. The application of thrombin and fibrinogen reduced the erythrocytic exudate, and the dermal surface was found to be covered with a loosely adherent eosin-staining granular mass. It seemed to push into the adjacent collagenous bundles but produced no evident tissue changes. In the biopsies taken after four to six hours, few additional changes were noted in the sections. In certain areas some collagenous bundles showed mild retrogressive changes and were surrounded by small collections of leucocytes. Similar retrogressive changes were noted when a donor site was covered by vaseline gauze or left untreated. In biopsies taken ten to twenty-four hours after application, numerous leucocytes were found on the dermis and throughout the superficial portion of it while the collagenous bundles often showed retrogressive changes. These findings were attributed to infection of the donor sites.

Paraffin.†—Examination of sections from donor sites covered by paraffin showed no damage to the dermis after two to four hours. The only constant finding was an increased number of granular leucocytes between the more superficial collagenous fibers. In sections taken after six hours the donor sites showed no evidence of tissue destruction nor alteration apparently due to the applied paraffin.

10 per cent Tannic Acid; 5 per cent Silver Nitrate; 10 per cent Tannic Acid plus 5 per cent Silver Nitrate; and Quebracho Tannin.‡—After comparing the biopsies from the donor sites treated by the above agents we concluded that the tissue changes produced were similar; hence these medicaments will be considered as a group in the following descriptions. In the biopsies taken after two hours of therapy these tanning substances were found as brown to brownish-black masses of refractile granules on the surface of the freshly denuded corium and between its collagenous bundles. Some of the material was also found in the incised hair follicles. In many of the sections the more superficial collagenous bundles stained more intensely and appeared glossy; these changes were interpreted as the earliest evidence of damage to the dermis.

Sections taken six hours following application of the tanning agents showed their deeper penetration between the collagenous bundles. The affected fibers now stained deeply with eosin and appeared as a com-

*Purified thrombin from beef plasma diluted with water to give 5,000 units per cubic centimeter. Furnished by Parke, Davis & Co., Detroit, Mich.

†Paraffin wax 670 Gm., petrolatum 250 Gm., liquid petrolatum 150 Gm., cod liver oil 50 c. c., sulfanilamide powder 50 Gm., menthol 1 Gm., camphor 1 Gm., and oil of eucalyptus 1 c. c.

‡Quebracho tannin, 7½ per cent in a water-soluble base and dihexylin 1:1000 (meta-di-hydroxy-di-secondary-hexyl-benzene). Furnished by Parke, Davis & Co., Detroit, Mich.

THE RELATIONSHIP OF ACUTE ANEMIA TO WOUND HEALING

An Experimental Study*

E. L. Besser, M.D., and J. L. Ehrenhaft, M.D., Iowa City, Iowa
(From the Departments of Surgery, Pathology and Internal Medicine, University of Iowa School of Medicine)

IN REVIEWING the literature on wound healing, one frequently finds statements to the effect that wounds do not heal well in patients with anemia.[1-4] We were unable to find any experimental work to substantiate or disprove this postulate.

Certain systemic factors are known to influence wound healing. It has been shown that vitamin C is necessary for the production of collagen.[5, 6] Both experimental studies and clinical observations have shown that an adequate intake of vitamin C is necessary for normal wound healing.[6-9] Epithelial healing is delayed when there is a deficiency in vitamin A.[2] When hypoproteinemia exists, fibroplasia is decreased, wound healing is delayed, and evisceration is common.[10-13]

The problem of anemia and wound healing presents two aspects: first, the relation of acute anemia to wound healing, and, second, the relation of chronic anemia to wound healing. Chronic anemia is often found in debilitated patients who also have vitamin deficiencies or hypoproteinemia. Since it is definitely established that these latter factors influence wound healing, and chronic anemia usually does not exist without some degree of these other deficiencies, it is difficult to draw conclusions from patients of this group. Acute blood loss from traumatic wounds or extensive operations causes acute anemia which is usually uncomplicated by other deficiency states. In a series of cases in which the patients developed shock during operative procedures at the University Hospitals, dextrose-citrate plasma was found to be efficacious in the treatment of this condition.[14] In certain cases, whole blood loss had been marked, and there was a resultant acute anemia. Our interest was aroused as to whether the course of these patients would be as satisfactory as if they had been given whole blood transfusions to combat both red cell and plasma loss. The question arose—would their wounds heal as readily? It was felt that this problem could be adapted to experimental study.

Experimental Procedure.—The first extensive studies of tensile strength of wounds in experimental animals were carried out by

*This study was made with the cooperation of Dr. Elmer DeGowin of the Department of Medicine. The blood chemical determinations were carried out by Dr. Irving Friedman.

Received for publication, March 1, 1943.

reported a group of cases in which the patients were treated in a similar manner and exhibiting few infections.

Several investigators[6, 7] have studied the effects of tannic acid and similar medicaments on experimental burns, and their work has suggested that eschar-forming agents may delay healing. Clinical tests[8] have also been made wherein various agents were tested on donor sites of man, and we were able to obtain biopsies from prepared human donor sites which permitted a comparison of tissue reactions to several tanning agents and to vaseline gauze. In order to test further the medicaments used in burn therapy we placed them on prepared donor sites of dogs, and we have been able to study the reactions of normal tissue to the medicaments in serial biopsies. The procedure discussed in this paper should be useful in estimating the deleterious effects of any substance that might be used on burned surfaces. The demonstration that most of the agents commonly employed in the treatment of burns have the ability to destroy normal tissues and thereby increase the depth of the burn, demands that one question the wisdom of employing them. If they are used, one must be certain that the beneficial effects offset the harm done by the increased tissue damage.

It may be that in the future a substance will be supplied having all the features desired for the treatment of burns. From these studies we may well wonder whether any material can be found which will become closely enough adherent to the surface of a fresh wound or burned area without damaging normal tissues. At present it would seem that eschar-forming agents produce the eschar over burned surfaces by necrotizing normal tissues. In order to stick to a moist surface without combining with the surface and thereby damaging it, an inert substance would have to form a mechanical union with the cells of the epidermis or with the collagenous bundles of the corium. The existence of a material having the capacity to form such a union seems highly unlikely. The alternative is to maintain a nonirritating substance over the burn by a suitable dressing or adhesive attached to adjacent normal structures.

REFERENCES

1. Hirshfeld, John W., Pilling, Matthew A., and Maun, Mark E.: A Comparison of the Effects of Tanning Agents and of Vaseline Gauze on Fresh Wounds of Man, Surg., Gynec. & Obst. 76: 556-561, 1943.
2. Davidson, Edward C.: Tannic Acid in the Treatment of Burns, Surg., Gynec. & Obst. 41: 202-221, 1925.
3. Aldrich, R. H.: Role of Infection in Burns; Theory and Treatment With Special Reference to Gentian Violet, New England J. Med. 208: 299-309, 1933.
4. Pickrell, K. L.: New Treatment of Burns; Preliminary Report, Bull. Johns Hopkins Hosp. 69: 217-221, 1941.
5. Rothman, Milton, Tamerin, Joseph, and Bullowa, Jesse G. M.: Treatment of Burns With 2.5 Per Cent Sulfadiazine in 8 Per Cent Triethanolamine Solution, J. A. M. A. 120: 803-805, 1942.
6. Taylor, Frederic: The Misuse of Tannic Acid, J. A. M. A. 106: 1144-1146, 1936.
7. Anagnostidis, Nikos: Histologische experimentelle Untersuchungen über die Wirkung einzelner örtlich angewandter Arzneimittel bei Verbrennungen dritten Grades, Deutsche Ztschr. f. Chir. 252: 248-256, 1939.
8. Conn, Bradford, and Cope, Oliver: Rate of Epithelial Regeneration, Ann. Surg. 117: 85-92, 1943.

6TH DAY SERIES					BO	PO 1	PO-6	BO	PO-1	PO 6		
Anemic dogs	1	750	575	525	46	17	21	6.41	5.94	5.97	80	
	2	600	500	450	48	19	22		5.05	5.95	118	99
Control dogs	1	720			47		45	6.28		5.94	92	
	2	800			46		46	5.06		5.45	116	104
7TH DAY SERIES					BO	PO-1	PO-7	BO	PO-1	PO-7		
Anemic dogs	1	1600	400	360	50	10	15		6.30		195	
	2	720	500	480	52	32	38		5.60	5.80	180	
	3	720	500	450	50	30	36	6.10	6.20		185	
	4	640	400	350	54	31	35		5.90		148	
	5	880	640	550	54	11	16	6.45	6.10	6.20	154	
	6	860	750	700	48	14	20	5.40	5.80	5.70	172	
	7	840	640	500	53	12	17	6.10	5.90	6.20	150	
	8	1680	1100	1000	52	19	22	5.80	5.80	5.60	148	166
Control dogs	1	640			49						160	
	2	1100			51			6.20			200	
	3	800			39		44			5.76	250	
	4	1140			47		46			5.71	172	
	5	680			43		39	5.35		5.51	172	190
9TH DAY SERIES					BO	PO 1	PO 9	BO	PO-1	PO-9		
Anemic dogs	1	880	700	480	52	25	26.5	5.92	4.89	6.06	260	
	2	1150	820	750	47	21	28	5.29	6.10	5.69	264	262
Control dogs	1	750			43		44	8.55		6.19	164	
	2	640			38		48	4.97		6.01	290	227
11TH DAY SERIES					BO	PO-1	PO-11	BO	PO-1	PO-11		
Anemic dogs	1	840	700	450	48	20	36	7.11	6.00	7.18	300	
	2	800	600	600	39	18	30	5.90	6.19	6.43	210	255
Control dogs	1	930			50		47	6.08		6.43	170	
	2	880			42		44	5.64		5.28	276	223

*Blood volume was estimated as 8 per cent of body weight.
†BO—Before operation, PO—postoperative days.

TABLE I

EXPERIMENTAL DATA CONCERNING THE RELATIONSHIP OF ACUTE ANEMIA TO WOUND HEALING

DAYS POST-OPERATIVE	EXP. NO.	EST. BLOOD VOL.* (C.C.)	AMT. BLED (C.C.)	PLASMA GIVEN (C.C.)	HEMATOCRIT† (PER CENT)			PLASMA PROTEINS (GM. PER 100 C.C.)			TENSILE STRENGTH (MM/HG)	AVERAGE TENSILE STRENGTH
2ND DAY SERIES					BO	PO-1	PO-2	BO	PO-1	PO-2		
Anemic dogs	1	800	660	550	51		20	5.94	5.95		48	
	2	880	600	450	51		19	5.42			62	55
Control dogs	1	800			43			6.49			100	
	2	1000			43			5.94			106	103
3RD DAY SERIES					BO	PO-1	PO-3	BO	PO-1	PO-3		
Anemic dogs	1	1080	850	500	39	20	24	7.17	6.04	5.36	74	
	2	920	800	500	41	21	19	6.45	6.48	5.97	34	
	3	1360	1150	950	41	16	17	6.56	6.33	5.56	60	56
Control dogs	1	1200			50						50	
	2	1520			53						50	
	3	1600			55						74	
	4	700			38		40.5	5.66		5.73	82	
	5	750			44		45	5.87		6.35	50	
	6	1200			52			6.12			54	60
4TH DAY SERIES					BO	PO-1	PO-4	BO	PO-1	PO-4		
Anemic dogs	1	720	550	550	50	24	24	5.95	5.80	6.04	45	
	2	680	570	600	43	17	20	4.95	5.77		50	
	3	700	550	450	41	23	22	5.68	5.94	6.74	62	52
Control dogs	1	1200			49		47	5.45		5.68	88	
	2	720			48		50	6.23		5.94	70	
	3	1152			38		36	6.27		6.54	36	62
5TH DAY SERIES					BO	PO-1	PO-5	BO	PO-1	PO-5		
Anemic dogs	1	680	450	400	50	22	24	5.70	5.80	5.90	64	
	2	840	650	625	52	19	23	6.30	6.10	6.30	76	
	3	1040	780	700	54	25	27		6.0	6.10	55	
	4	680	500	550	50	14		6.45	6.20	6.0	52	
	5	830	560	320		34	35	5.98		5.92	100	65
Control dogs	1	680			50			6.20			72	
	2	680			51			5.90			52	
	3	960			53						80	68

tion as those reported by Howes and Harvey[4] and other workers.[15-18] Immediate tensile strength of the sutured wound was between 150 and 200 mm. of mercury. A lag period occurred until the fourth or fifth day, and a rapid increase in tensile strength then followed during the sixth and seventh days. It was found that the mean values

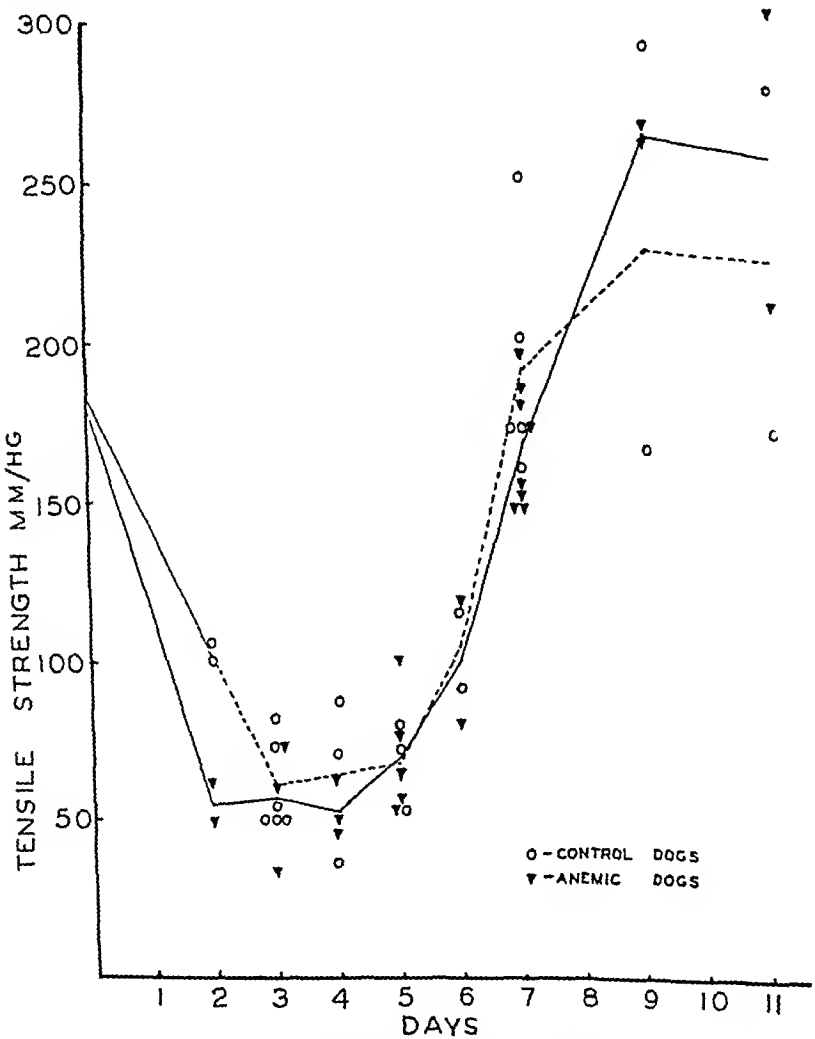

FIG. 1.—The relationship of acute anemia to wound healing as shown by tensile strength of incisions in the stomach of the dog.

of the tensile strengths of the incisions in the anemic and control dogs showed no significant differences. Although experimental error is considerable in this type of procedure, the values overlap and the averages are close.

Microscopic studies showed essentially the same picture in both the anemic and control dogs. Fibroplasia could be seen on the second

Harvey and Howes[1, 15] and their co-workers. They found that the tensile strength was dependent upon the growth and maturation of the fibroblast and noted that after a lag period of three to five days, fibroplasia began abruptly and proceeded with decreasing velocity until a maximal strength was reached about the twelfth to fourteenth day. In most of these experiments, small incisions were made in the stomachs of guinea pigs or rats and the wounds were closed with 000 plain catgut. The tensile strengths were determined by distending the stomachs with air. Other investigators have used this method with slight modifications and have found similar curves for the tensile strength of healing wounds.[16-18]

Our experiments were carried out on stock dogs of varying sizes and ages. The dogs were fed adequate and uniform diets. While consistent results were reported by those who distended the entire stomachs of guinea pigs or rats, we found that distending the entire stomach of the dog resulted in wide variations. It was felt that these differences were based largely on the variations in the size of the stomachs. Therefore, we found it expedient to open the stomach and place the incision to be tested over the open end of an Erlenmeyer flask, and this fixed area of stomach was then distended by air under manometric control. Our procedure was as follows: Two incisions, each 4 cm. in length, were made through all layers of the stomach wall. One incision was made near the pylorus and was used for determination of tensile strength. The other incision was made in the cardia and this was used for microscopic study. Suture material consisted of 0000 plain catgut. A continuous Lembert suture was used to approximate the muscularis and submucosa. The serosa was closed by three interrupted sutures. The abdominal wound was closed with silk. The animals were killed on subsequent days and the tensile strength of the incisions determined as described above. Twenty-six dogs were used as controls. Acute anemia was produced in twenty-six dogs by withdrawing blood from the femoral artery. The plasma was immediately replaced at the time by intravenous infusion of pooled plasma from donor dogs. Hematocrit and total protein determinations were made preoperatively, on the day following operation, and on the day when the tensile strength determination was carried out. These data are given in Table I. Vitamin C levels were determined in the early experiments. The dogs, however, were fed on known adequate diets for several weeks prior to operation, and the levels were consistently normal. It was thought unnecessary to continue these determinations.

Results.—There was no significant change in plasma proteins between the pre- and postoperative levels. The anemia produced varied from moderate to extreme, and, in most instances, was below the levels usually found clinically in cases of hemorrhage. The curves of tensile strengths of the incisions in relation to days following operation are shown in Fig. 1. These curves have the same general configura-

tion as those reported by Howes and Harvey[4] and other workers.[15-18] Immediate tensile strength of the sutured wound was between 150 and 200 mm. of mercury. A lag period occurred until the fourth or fifth day, and a rapid increase in tensile strength then followed during the sixth and seventh days. It was found that the mean values

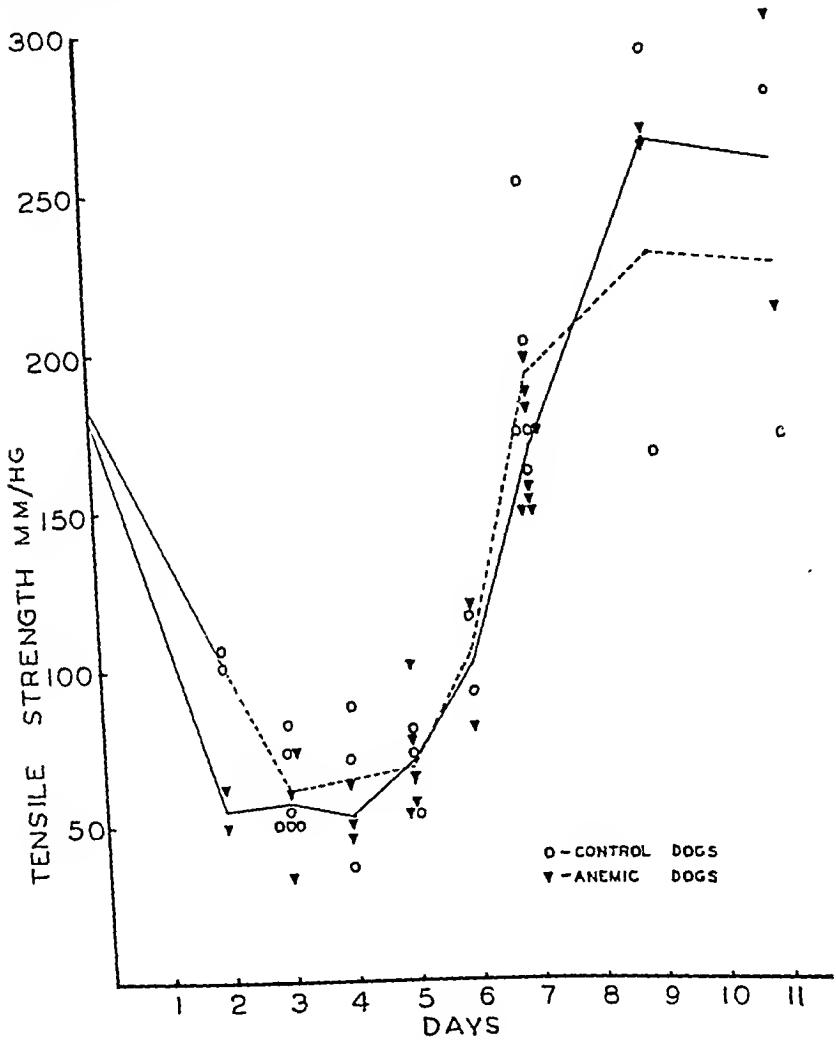

Fig. 1.—The relationship of acute anemia to wound healing as shown by tensile strength of incisions in the stomach of the dog.

of the tensile strengths of the incisions in the anemic and control dogs showed no significant differences. Although experimental error is considerable in this type of procedure, the values overlap and the averages are close.

Microscopic studies showed essentially the same picture in both the anemic and control dogs. Fibroplasia could be seen on the second

day. The fibroblasts were bridging across rapidly until the fifth day, at which time bridging seemed complete, and this coincides with a rapid rise in tensile strength on this day. On the sixth day, definite contraction of the wound had occurred and inflammatory reaction was minimal. Some interstitial fibrillar material could be seen as early as the seventh day. On the ninth day and eleventh day, newly formed fibrous tissue appeared to be very dense and firm. Epithelium started to bridge across on the second day and was fused by the third day. Glandular formation was seen about the ninth day.

The dogs recovered from the anemia rapidly and by the eleventh day the hematocrit values were nearly normal. Therefore, it was felt unnecessary to carry the experiments further than eleven days post-operatively.

DISCUSSION

When whole blood is unobtainable, plasma is being used extensively in treating shock due to hemorrhage in military surgery and to a lesser extent in civil practice. These experiments suggest that the acute anemia found as the result of this procedure does not retard wound healing. This should not be interpreted as complete endorsement of the use of plasma rather than whole blood in the treatment of shock due to hemorrhage since it has not yet been proved that acute anemia does not have other detrimental effect, such as lowering the resistance of the patient to infection.

SUMMARY

Acute anemia produced in dogs does not retard wound healing as shown by determination of tensile strength and microscopic study. The clinical significance of this finding has been discussed.

REFERENCES

1. Glenn, Frank, and Moore, S. W.: The Disruption of Abdominal Wounds, Surg., Gynec. & Obst. 72: 1041, 1941.
2. Arey, Leslie B.: Wound Healing, Physiol. Rev. 16: 327, 1936.
3. Mason, Michael: Wound Healing, Internat. Abstr. Surg. 69: 303, 1939.
4. Howes, E. L. and Harvey, S. C.: The Clinical Significance of Experimental Studies in Wound Healing, Ann. Surg. 102: 941, 1935.
5. Wolbach, S. B.: Controlled Formation of Collagen and Reticulum: A Study of the Source of Intercellular Substance in Recovery from Experimental Scorbutus, Am. J. Path. 9: 689, 1933.
6. Wolfer, J. A.: The Surgical Aspect of Vitamin C Deficiency, S. Clin. North America 20: 225, 1940.
7. Lanman, T. H., and Ingalls, T. H.: Vitamin C Deficiency and Wound Healing, Ann. Surg. 105: 616, 1937.
8. Wolfer, J. A., and Hoebel, F. C.: The Significance of Cevitamic Acid Deficiency in Surgical Patients, Surg., Gynec. & Obst. 69: 745, 1939.
9. Holman, Emile: Vitamin and Protein Factors in Pre-Operative and Post-Operative Care of the Surgical Patient, Surg., Gynec. & Obst. 70: 261, 1940.
10. Thompson, W. D., Ravdin, I. S., and Frank, I. L.: Effect of Hypoproteinemia on Wound Disruption, Arch. Surg. 36: 500, 1938.
11. Thompson, W. D., Ravdin, I. S., Rhoads, J. E., and Frank, I. L.: Use of Lyophile Plasma in Correction of Hypoproteinemia and Prevention of Wound Disruption, Arch. Surg. 36: 509, 1938.

12. Rhoads, J. E., Fliegelman, M. T., and Panzer, L. M.: The Mechanism of Delayed Wound Healing in the Presence of Hypoproteinemia, J. A. M. A. 118: 21, 1942.
13. Koster, Harry, and Shapiro, Arthur: Serum Proteins and Wound Healing, Arch. Surg. 41: 723, 1940.
14. Besser, E. L.: Stored Dextrose-citrate Plasma in the Treatment of Operative Shock, Arch. Surg. 43: 451, 1941.
15. Harvey, Samuel C.: The Velocity of the Growth of Fibroblasts in the Healing Wound, Arch. Surg. 18: 1227, 1929.
16. Ellis, J. D.: The Rate of Healing of Electro-Surgical Wounds as Expressed by Tensile Strength, J. A. M. A. 96: 16, 1931.
17. Botsford, T. W.: The Tensile Strength of Sutured Skin Wounds During Healing, Surg., Gynec. & Obst. 72: 690, 1941.
18. Bricker, E. M., and Graham, E. A.: The Inhibitory Effect of Sulfanilamide on Wound Healing, J. A. M. A. 112: 2593, 1939.

MALIGNANT NEOPLASMS OF THE SPLEEN

Review of the Literature and Report of a Case of Primary Lymphosarcoma (Reticulum-Cell Type)

Paul F. Hausmann,* M.D., and Fred W. Gaarde,† M.D.
Rochester, Minn.

At the Boston City Hospital,[31] out of a total of 4,000 surgical procedures, splenectomy was performed only twice for primary splenic malignant disease. Smith and Rusk, in 1923, extensively reviewed the literature and added two cases to the 102 recorded instances of such malignant disease. Of this number, in twenty-two cases the condition was described as lymphosarcoma; two of the cases had been reported from the Mayo Clinic.

Careful review of the literature subsequent to 1923[1-4, 6-11, 18, 19, 21, 23, 24, 27, 28, 34, 35, 39, 40, 41] revealed reports of forty-five additional corroborated cases of splenic malignant disease, including nine of lymphosarcoma.[5, 12, 13, 16, 17, 22, 30, 33] Reports of twenty other cases were indexed but had been printed in journals that were not available. If this latter group is accepted, the total is brought to 169. Two cases of lymphosarcoma[15, 26] and seven others of malignant disease of the spleen in which the diagnosis was confirmed histologically at the clinic,[37, 38] brought the total of known cases of all types of malignant splenic neoplasms to 178, of which thirty-three were lymphosarcomas.

We report a case of primary reticulum-cell lymphosarcoma of the spleen which we recently observed.

REPORT OF CASE

A tall, thin merchant, 38 years old, registered on Aug. 20, 1940. The following history was elicited.

From January to April, 1940, the patient had had vague, unreferred and momentary epigastric pain which occurred at any time of day. In April, immediately after a late night lunch, he had experienced severe sharp pain in the left shoulder and boring pain in the left upper abdominal quadrant. This pain caused him to writhe and toss all night but it subsided by morning, leaving a residual tenderness which continued for two or three days. The results of physical examination and roentgenologic examination of the stomach, gall bladder, and colon carried out at that time elsewhere were negative. The man was then free from symptoms until July 31, 1940, three weeks prior to registration, when he experienced slight pain in the left shoulder and severe pain in the left upper abdominal quadrant for which administration of morphine and hospitalization were necessary. Further roentgenologic examination elsewhere revealed in the left upper abdominal quadrant a

*Fellow in Surgery, Mayo Foundation.
†Division of Medicine, Mayo Clinic, Rochester, Minn.
Received for publication, Feb. 24, 1943.

tumor which was causing deformity of the splenic flexure of the colon. After the attack of pain, slight residual tenderness persisted in the left upper quadrant and was present when the patient was admitted to the clinic.

Physical examination yielded only the following positive findings: There was an occasional coarse râle in the apex of the left lung anteriorly. Small, soft, nontender inguinal nodes were palpated bilaterally. The region of the left upper abdominal quadrant was tender to deep palpation and on deep inspiration—the lower margin of the spleen, which was firm and smooth, could be felt but with difficulty. Percussion over the left lumbar region was moderately painful.

Roentgenograms revealed an extrarenal mass in the left upper abdominal quadrant.

Examination of the blood revealed nothing abnormal. The results of serologic tests were negative as were those of the urinalysis, microscopically, although albumin, grade 1, on the basis of 1 to 4, was present.

Fig. 1.—Gross appearance of surface of reticulum-cell lymphosarcoma of spleen, made by sectioning.

On Aug. 23, 1940, surgical operation was performed. The spleen was round, tense, and enlarged to about four times normal size. Splenectomy was difficult because of adhesions to the undersurface of the diaphragm. There was no evidence of extension of disease to any of the other abdominal organs or of involvement of any of the lymph nodes.

Convalescence was uneventful and the patient was dismissed from the hospital on the fourteenth postoperative day. Roentgen therapy over both upper abdominal quadrants and over both inguinal regions was given. On his return to the clinic for further roentgen therapy on Oct. 16, 1940, approximately two months post-

operatively, there was no evidence of extension or of generalization of disease and his only complaints were of occasional slight pains over the incision and of residual weakness. He had gained fourteen pounds (6.4 kg.). Small, soft, inguinal nodes were still palpable but not enlarged.

The spleen weighed 810 Gm. and measured 14 by 12 by 7 cm. It was firm and reddish, with firm yellowish nodules easily visible beneath the surface of the capsule which was everywhere smooth and unbroken except on the diaphragmatic surface where it was roughened by several dense fibrous adhesions. The capsule was not invaded anywhere by neoplastic tissue. Cut surfaces (Fig. 1) revealed numerous round and oval, yellowish-brown nodules, 1 mm. to 8 cm. in diameter, almost completely replacing the normal splenic parenchyma, which was recognizable only as narrowed, compressed, reddish-brown bands coursing between the oval yellowish masses. There were no regions of hemorrhage or of degeneration.

Fig. 2.—Reticulum-cell lymphosarcoma of spleen; only a small strand of recognizable splenic architecture can be noted (magnification ×55).

Histologically, as in the gross, only a few small regions of recognizable splenic parenchyma containing scattered malpighian corpuscles were observed (Fig. 2). The remainder of the tissue consisted of undemarcated, solidly packed, round cells, slightly larger than mature lymphocytes, retaining none of the architectural characteristics of splenic or of lymphoid structure. Here and there, small blood vessels were visible, and in a few regions evidence of hemorrhage into the tissue was seen. Only a few vestiges of fibrous trabeculae remained. Under high magnification (Fig. 3) it was seen that the tumor cells were about twice the size of lymphocytes and that they contained hyperchromatic nuclei with large nucleoli. The cytoplasm, large in amount, had the "misty" appearance described as characteristic of the cells of reticulum.

On Feb. 7, 1941, the patient returned to the clinic. For five or six weeks he had had transient dull and sharp pain in the left upper abdominal quadrant and pain in the epigastrium. He had lost twenty pounds (9.1 kg.) since his last visit and weakness was so pronounced that he had spent most of the past month in bed.

Physical examination revealed two hard lymph nodes about the size of walnuts, in the left supraclavicular fossa, and a questionable mass in the left upper abdom-

inal quadrant, but there were no other nodal enlargements. Palliative roentgen therapy was given over the two regions and the masses disappeared. The patient left the clinic in two weeks somewhat stronger but the subsequent course of his disease was gradually downward, and on July 7, 1941, he died at his home.

CLASSIFICATION OF MALIGNANT SPLENIC NEOPLASMS

Much of the confusion which exists regarding the terminology employed in designating the histologic diagnosis in reported cases of malignant disease of the spleen could be obviated if it were remembered that there are four types of tissue in the spleen from which tumors can arise. Enumerated in outline form, these tissues are:

I. The capsular and trabecular framework from which arise fibroma, fibrosarcoma, and spindle-cell sarcoma.



Fig. 3.—Characteristic tumor reticulum cells (magnification ×210).

II. The lymphoid elements which give rise to lymphoma and lymphoblastoma. Lymphoblastomatous tumors we choose to classify further as follows:

A. Lymphosarcoma.

1. Large round-cell (reticulum-cell type).
2. Small round-cell (lymphoblastic type).
3. Giant lymph follicle hyperplasia.

B. Hodgkin's granuloma.

III. The vascular or sinusal endothelium from which arise angiomas as well as their malignant counterparts, endothelioma, endothelial sarcoma, and angiosarcoma.

IV. The reticulo-endothelial system, or portion of the framework of the spleen, which gives rise to splenic enlargement in the syndromes of

Gaucher, of Niemann-Pick, and of Christian, and to reticulo-endothelioma and reticulo-endothelial sarcoma.

Although there is not any tissue in the spleen from which carcinoma might arise, primary carcinoma of the spleen was reported in the medical literature prior to 1923. Unless the theory of embryonic cell rests is accepted, and an authentic instance of such a rest has not been observed, the diagnosis must be regarded as untenable.

There are observers who distinguish sharply between lymphosarcoma and giant lymph follicle hyperplasia. We have included the latter as a subclassification of lymphosarcoma until further knowledge allows its classification elsewhere.

Analysis of the available accounts of primary malignant lesions in forty-five cases, reported from 1923 through 1940, established the incidence of the various types of splenic neoplasms (Table I).

TABLE I

INCIDENCE OF MALIGNANT NEOPLASMS OF THE SPLEEN IN 45 CASES, 1923-1940 INCLUSIVE

GROUP	DIAGNOSIS	CASES	TOTAL
	Primary carcinoma	1	1
I	Primary sarcoma	8	
	Large round-cell sarcoma	7	
	Small round-cell sarcoma	1	
	Unspecified round-cell sarcoma	2	18
II	Lymphosarcoma	9	
	Reticulum-cell sarcoma	1	
	Giant lymph follicle hyperplasia	3	13
III	Endothelioma	1	
	Endothelial sarcoma	1	
	Angioblastoma	1	
	Angiosarcoma	3	
	Hemangio-endothelioma	3	
	Malignant hemangioma	1	10
IV	Reticulo-endothelioma	1	
	Reticulo endothelial sarcoma	2	3
	Total		45

The pathologist's diagnosis in the cases of splenic neoplasm observed at the clinic, not including the two cases of lymphosarcoma reported prior to 1923, are recorded in Table II.

TABLE II

PATHOLOGIC DIAGNOSIS IN NINE CASES OF SPLENIC NEOPLASM

GROUP	DIAGNOSIS	CASES	TOTAL
I	Primary sarcoma	1	
	Fibrosarcoma	3	4
II	Lymphosarcoma	1	
	Reticulum-cell lymphosarcoma	1	
	Giant lymph follicle hyperplasia	1	3
III	Endothelial sarcoma	1	1
IV	Reticulo-endotheliosis	1	1
	Total		9

In spite of the varied terminology employed by different authors, all of the reported tumors were included easily and conveniently in one of four groups of our outline according to the tissue from which they sprang. The pathologic diagnosis thus served to indicate the predominance of a particular type of cellular element or the degree and direction of differentiation of the tumor. The greatest variation of nomenclature was observed in descriptions of the neoplasms which we have listed in group III, a fact which might justify MacCallum's hesitancy to accept endothelioma because of his fear that its inclusion would prove to be a wastebasket for unusual tumors lacking characteristics permitting ready recognition.

The only reported instance of primary carcinoma of the spleen[36] from the years 1923 to 1940, inclusive, which we were able to find concerned a patient whose first demonstrable lesion was a nodule on a buttock. Necropsy revealed extensive carcinomatous infiltration of the liver and spleen. Inasmuch as convincing evidence of primary origin of the disease was not presented, the carcinoma of the spleen, in our opinion, must be regarded as metastatic from an unrecognized primary lesion.

The predominant number of tumors were included in group I (Table I) although, as was pointed out by Smith and Rusk, many tumors of this group could be classified as lymphosarcoma, since small round-cell sarcoma is practically indistinguishable from the lymphoblastic type, and the large round-cell sarcoma is identical with the reticulum-cell type of lymphosarcoma. Accepting this fact, it appears that subsequent to 1923, as prior to this date, lymphosarcoma has been the type of primary splenic malignant disease most commonly encountered.

Sex incidence in the cases reviewed by Smith and Rusk was fifty-one men and thirty-two women; in twenty-one instances, the sex was not stated. Cases of malignant splenic neoplasm reported subsequently elsewhere included seventeen men and eighteen women, whereas at the clinic there were five men and four women. In the cases of lymphosarcoma reported elsewhere five patients were men and four were women, while both patients observed at the clinic were men.

The average age of patients in cases reported elsewhere, subsequent to 1923, was 46.7 years; in the majority the disease occurred in the fifth and sixth decades. The average age of the patients who were reported as having lymphosarcoma was 43.6 years; the majority were in the sixth decade. The patients observed at the clinic averaged 52.3 years; most of them were in the seventh decade. Both patients who had lymphosarcoma were 62 years old.

In contrast to incidence of malaria in 13 per cent of cases reported prior to 1923, there was an incidence of only 4.4 per cent of malaria in cases reported subsequently. Of the patients observed at the clinic, one of nine, or 11 per cent, gave a history of malaria, and he was one of the two who had lymphosarcoma.

Syphilis was present in 4 per cent of the cases in the series reported by Smith and Rusk, in 4.4 per cent of the series reviewed by us, and in 33.3 per cent of cases (nine) seen at the clinic. None of the patients who had lymphosarcoma were syphilitic.

In 2 per cent of the series of Smith and Rusk, there was a history of tuberculosis, but tuberculosis had not existed in any of the subsequent cases, either in those reported in the literature or in those observed at the clinic.

SURGICAL PROCEDURES

Splenectomy was performed in eighteen of forty-five cases reported in the literature in the years 1923 through 1940. Four of the splenectomized patients died within the first thirty hours after operation, and of the remaining fourteen patients, two died within a year from generalized involvement of lymph nodes, in one case the disease being lymphosarcoma and in the other, giant lymph follicle hyperplasia. Twelve of the patients were living and well at the time the cases were reported, the periods of survival ranging from thirty days to eight years.

Exploratory laparotomy was performed in four cases but in each case the disease was found to be too extensive to justify surgical intervention. Splenectomy was possible in seven of the nine cases observed at the clinic, including both cases of lymphosarcoma. One of the seven patients died immediately postoperatively and the survival periods of four others were nineteen days, three months, nineteen months, and four years, respectively. The patient with giant lymph follicle hyperplasia had generalized involvement of the lymph nodes five months after operation, but he received roentgen therapy one, four, and six years postoperatively and was living and well more than seven years after splenectomy. One of the patients who had lymphosarcoma survived splenectomy three months and died of metastases to bones and brain without involvement of lymph nodes; the other patient was living and well, without evidence of recurrence or metastasis, when last heard from in February, 1940, four years after removal of the spleen. Exploratory laparotomy in two cases revealed fibrosarcoma too extensive for splenectomy, so that only biopsy was done.

STATISTICAL COMMENT

It has been repeatedly observed that the lymphoblastomas, particularly lymphosarcomas, are multicentric in origin, frequently involving almost simultaneously many lymph nodes, in various anatomic situations; namely, the cervical, axillary, mediastinal, and inguinal regions, as well as the spleen, the gastrointestinal tract, and the abdominal lymph nodes.

In an attempt to determine whether isolated splenic lymphosarcoma is a precursor of generalized lymphosarcomatosis and therefore to be regarded as a part of the generalized process, or whether it is a similar

condition which is confined to the spleen, the following statistics were obtained.

Of the nine cases of splenic lymphosarcoma reported in the literature, there was generalized involvement of the lymph nodes of the groin within one year in only one case.[29] In another case,[16] the disease was generalized when the patient first was examined, but because of the immense size of the spleen, the condition was reported as primarily splenic. Metastasis to the spinal cord, without lymph nodal enlargements, was present in another case.[12] In two instances there was extension to adjacent structures; Krumbhaar[22] reported involvement of liver, pancreas, stomach, and bladder, whereas Gerundo and Miller[14] noted extension to the diaphragm. In a case reported by Cabot, Mallory hesitated to state whether the tumors were primary in the stomach or in the spleen, both of which were involved. One of Frank's patients died twenty-four hours after splenectomy, and the other patient died eight months postoperatively. In the second case[32] the cause of death was unstated, but the disease was not generalized. In another case the extent of disease was not noted postoperatively. In two of nine cases, or 22.2 per cent, primary lymphosarcoma, therefore, was a precursor of lymphosarcomatosis.

In one of the two cases reported from the clinic prior to 1923,[15, 25] lymph nodal involvement took place within four months postoperatively. The other patient lived more than seven years without evidence of recurrence. One of two patients observed at the clinic, subsequent to 1923, died within three months of metastasis to the bone and brain, without lymph nodal involvement. The other patient, as stated previously, was living and well without any evidence of recurrence four years postoperatively. In only one of the four cases studied at the clinic, or 25 per cent, did lymphosarcomatosis develop subsequent to splenectomy for what was thought to be a primary splenic neoplasm. In the case reported herein, generalized involvement of nodes was not present and it is problematic whether the lesions in the supraclavicular nodes were metastatic or gave evidence of the multicentricity of the disease.

Review of the three closely related instances of giant lymph follicle hyperplasia which are reported in the medical literature discloses that one patient[20] had generalized involvement within one year after splenectomy; another,[26] who had nodes in the groin at the time splenectomy was performed, died four hours after operation; the third patient survived four years and succumbed, finally, to recurrence in the left upper abdominal quadrant. The results in these cases reveal generalization of involvement in two of three, or 67 per cent, of cases.

The only patient with giant lymph follicle hyperplasia who was observed at the clinic, as mentioned earlier, had involvement of lymph nodes in the groin and axilla within three months after splenectomy,

but was alive and well at the time this paper was written, seven years postoperatively.

CONCLUSIONS

1. Although the series of cases of lymphosarcoma studied was not large enough to permit any final conclusions to be drawn, in the light of the figures in the preceding paragraphs, splenectomy appears justifiable for lymphosarcoma confined to the spleen.

2. The number of cases of giant lymph follicle hyperplasia studied in this series was small, also, but it appears that although the disease usually progresses more slowly than lymphosarcoma, the condition is more likely to become generalized.

REFERENCES

1. Adam, Ludwig: Primäre Milzgeschwulst, Zentralbl. f. Chir. 55: 481-484, 1928.
2. Beasely, B. T.: Sarcoma of the Spleen, J. M. A. Georgia 13: 395-396, 1924.
3. Berman, Adolf: Ein Fall von primärem Milzsarkom, Wien. klin. Wchnschr. 37: 1237-1238, 1924.
4. Biller, S. B.: Primary Endothelioma of the Spleen, Arch. Path. 25: 534-538, 1938.
5. Cabot Case 15311: Case Records of the Massachusetts General Hospital, Clinicopathological Exercises, New England J. Med. 201: 228-229; Discussion 229-231, 1929.
6. Caldwell, G. T.: Endothelioma of the Spleen With Report of a Case, South. M. J. 26: 120-125, 1933.
7. De Brun, H. C. W. S.: Primary Sarcoma of the Spleen, New York M. J. 118: 85-88, 1923.
8. De Fourmestraux, M. J.: Tumeur de la rate. Splénectomie, Bull. et mém. Soc. de chirurgiens de Paris. 49: 941-943, 1923.
9. De Navasquez, S.: Angioblastoma of the Spleen With Metastases in the Liver, J. Path. & Bact. 42: 651-656, 1936.
10. Del Buono, Pietro: Alterazioni dello scheletro nell 'emo-angiosarcoma della milza, Radiol. med. 19: 609-630, 1932.
11. Eickenbusch, F.: Ein Fall von primärem Sarkom der Milz, Frankfurt. Ztschr. f. Path. 35: 464-476, 1927.
12. Ferrando, Hugo, and Saloz, Hugo: Some Interesting Cases From the Medical Clinic of the University of Geneva, With Remarks on Pathology and Diagnoses, Internat. Clinics, 3: 223-258, 1923.
13. Frank, Louis: Sarcoma of the Spleen, Am. J. M. Sc. 183: 77-81, 1932.
14. Gerundo, Michael, and Miller, M. B.: Reticulum-cell Sarcoma of the Spleen, Am. J. Cancer 35: 528-533, 1939.
15. Giffin, H. Z.: Present Status of Splenectomy as a Therapeutic Measure, Minnesota Med. 4: 132-138, 1921.
16. Grayzel, D. M.: Sarcoma of the Spleen; Report of Five Cases, Am. J. Cancer 36: 237-242, 1939.
17. Howard, Tasker: Primary Sarcoma of the Spleen (Reticulum Celled), J. Lab. & Clin. Med. 14: 1157-1161, 1929.
18. Jackson, R. H.: Quoted by Jones, A. P.[19]
19. Jones, A. P.: Unusual Spleen Cases, Ann. Surg. 109: 960-969, 1939.
20. Kellert, Ellis: Lymphoblastoma of the Spleen, Am. J. Cancer 15: 844-849, 1931.
21. Köhler, Hans: Ueber primäres Milzsarkom, Arch. f. klin. Chir. 135: 194-202, 1925.
22. Krumbhaar, E. B.: The Incidence and Nature of Splenic Neoplasms With a Report on Forty Recent Cases, Ann. Clin. Med. 5: 833-860, 1927.
23. Krumbhaar, E. B., and Scott, J. P.: Tumors, of the Spleen With a Report on Twenty-eight Recent Cases, S. Clin. North America 7: 61-81, 1927.
24. Langenstrass, K. H., and Neumann, Meta: Reticulo-endothelial Sarcoma of the Spleen, Arch. Path. 20: 752-759, 1935.
25. MacCallum, W. G.: A Textbook of Pathology, Ed. 5, Philadelphia, 1932, W. B. Saunders Company, 1036 pp.
26. Mayo, W. J.: Principles Underlying Surgery of the Spleen With a Report of Six Splenectomies, J. A. M. A. 54: 14-18, 1910.

27. McNee, J. W.: Sarcoma of the Spleen, J. Path. & Bact. 39: 83-88, 1934.
28. Orlandi, Noël: Primäres, diffuses Hämangioendotheliom der Milz, Virchows Arch. f. path. Anat. 269: 152-159, 1928.
29. Paine, C. G.: Malignant Neoplasm of Spleen and Bone Marrow With Metastases in Liver, J. Path. & Bact. 34: 139-142, 1931.
30. Sherwood, W. A., and Smith, A. L.: Primary Lymphosarcoma of the Spleen, Report of a Case, S. Clin. North America 7: 1069-1078, 1927.
31. Smith, C. E., and Rusk, G. Y.: Endothelioma of the Spleen; a Study of Two Cases With Review of the Literature of Primary Malignancies of the Spleen, Arch. Surg. 7: 371-414, 1923.
32. Stevenin, Henri, Bergeret, Andre, Albot, Guy, and Lelourdy, Jean: Le réticulo-sarcome de la rate, Presse méd. 20: 382-384, 1935.
33. Sturgeon, C. T., and Ware, E. R.: Primary Lymphosarcoma of the Spleen, S. Clin. North America 11: 1163-1169, 1931.
34. Terzian, E.: Symptomatology and Diagnosis of Primary Sarcoma of the Spleen With the Report of a Case, M. J. & Rec. 128: 526-528, 1928.
35. Ugriumow, B.: Über zwei seltene Fälle von Gefässneubildungen in der Milz und Leber, Virchows Arch. f. path. Anat. 259: 366-372, 1926.
36. Werwath, K.: Über primäre maligne Milztumoren, Zentralbl. f. Chir. 62: 2716-2719, 1935.
37. Wilson, L. B.: The Pathology of Splenomegaly: A Study of the Operative and Autopsy Material From the Mayo Clinic, Surg., Gynec. & Obst. 16: 240-251, 1913.
38. Wilson, L. B.: Studies in the Pathology of the Spleen, Pathology of Spleens Removed for Certain Abnormal Conditions of the Blood, Col. Papers, Mayo Clin. 7: 500-510, 1915.
39. Wright, A. W.: Primary Malignant Hemangioma of the Spleen With Multiple Liver Metastases, Am. J. Path. 4: 507-524, 1928.
40. Wright, J. H., and Stevenson, E. M. K.: Case of Primary Sarcoma of the Spleen, Glasgow M. J. 114: 1-9, 1930.
41. Zeno, Artenio, and Cid, J. M.: Hémangio-endothéliome de la rate, Ann. d'anat. path. 7: 583-588, 1930.

THE USE OF CURARE IN THE TREATMENT OF TETANUS

Case Report

Stuart C. Cullen, M.D., and C. S. Quinn, M.D., Iowa City, Iowa
(From the Division of Anesthesiology, Department of Surgery and the Department of Medicine, State University of Iowa College of Medicine, Iowa City)

THE obstruction of breathing, the prolonged respiratory depression, the accumulation of mucus, and the infrequent changes of position associated with the use of tribromethanol with amylene hydrate (Avertin fluid*) for the control of the muscle spasm of tetanus predispose to pulmonary complications. With its use, there is difficulty in maintaining adequate nutrition because of the inability of the patient to eat and drink. Constant, close supervision by both nurse and physician is also essential. Although this means of controlling muscle spasm has proved beneficial in the treatment of persons affected with tetanus, it seems that control without such a marked general depression would be more desirable. In an attempt to simulate the latter state, curare was used on one patient.

CASE REPORT

The patient, H. H., a 48 year old carpenter, entered the University Hospital Nov. 11, 1942, complaining of stiffness of the jaw and pain and stiffness of the back. He gave the history of having struck his finger with a hammer, breaking the skin, while working about a chicken coop five weeks before admission. The onset of symptoms occurred one week before admission. At that time the patient developed a tingling sensation in the right hand, followed by aching of the muscles of that arm. Several days later he noticed stiffness of the jaws which interfered with eating. The trismus progressed rapidly within a few hours, until he had difficulty opening his mouth. Soreness, stiffness, and aching pain appeared in the shoulder muscles two days before admission, and soon involved the muscles of the back and those of the chest.

The patient was a normally developed white man in a good state of nutrition. He was mentally clear, but appeared physically exhausted. He was dehydrated, and the mucous membrane of the mouth was slightly cyanotic. Spasm of the facial muscles had produced the classical risus sardonicus. Trismus prevented his opening his mouth more than 2 cm between the upper incisors and the lower edentulous gum. His speech was thick, and he spoke with his hand to his jaw in attempt to lessen the great effort of opening his mouth. Inspection of the musculature showed spasm of the muscles of the jaw, neck, back, thorax, and abdomen, and hypertonicity of the extremities, with exaggerated reflexes. The pulse rate was 120 and the temperature not elevated. The respiratory rate was 25, and he breathed with effort. The leucocyte count was 11,050. With the exception of a small, almost healed laceration of the left index finger, the remainder of the examination was negative. A diagnosis of tetanus was made.

*Winthrop Chemical Company, Inc.

Received for publication, Feb. 6, 1943.

No sooner had the examination been completed than the patient had a paroxysm of painful muscular spasm. His body was straightened and then arched in opisthotonos. The jaw was tightly clenched, the abdomen rigid, and the extremities stiff. The thoracic and other respiratory muscles were fixed in a state of tonic contraction, so that respiratory movements ceased and cyanosis deepened. Relaxation sufficient to permit diaphragmatic motion occurred spontaneously within a few minutes. Similar spasms recurred every few hours.

COURSE AND TREATMENT

The patient was given 20,000 units of tetanus antitoxin intramuscularly, and 30,000 units intravenously, on the night of admission, followed by 50,000 units intravenously the next day. The small local lesion was opened, débrided, and dressed with zinc peroxide paste. For the first forty-eight hours the patient was given avertin per rectum. The degree of relaxation of the abdominal wall was used as a guide to dosage. The doses of the drug and time of administration are listed in Table I. In spite of marked general depression, intermittent spasms of the entire body still occurred, with clonic jerking of the extremities. There was considerable respiratory depression, obstruction, and mucous production. The latter was somewhat controlled with atropine.

Twenty-four hours after admission, the pulse rate, temperature, and respiratory rate began to rise, and, in another twenty-four hours, the pulse rate was 150, the temperature, 104° F., and the respiratory rate, 48. There were coarse râles in the bronchial tree. It was felt that the patient was probably developing pneumonia. The presence of pneumonic infiltration in the upper part of the right lung was later verified roentgenologically. Avertin was discontinued, and the administration of curare begun. The drug used was Intocostrin (extract of unauthenticated curare*). The drug was supplied as an extract, standardized by biological assay to contain the equivalent of 0.02 Gm. per cubic centimeter of a standard drug. It was administered either intravenously or intramuscularly. It is ineffective when given subcutaneously or perorally.

In this case there was no apparent difference in the duration of the effect produced by intravenous and intramuscular injection of curare. The onset of action was, of course, much more rapid with intravenous administration.

After the depression from avertin had disappeared, and the patient was conscious, the curare effect was spectacular. At the height of a spasm, when the patient was suffering excruciating pain, the intravenous injection of curare produced marked relief in a matter of seconds. One could see the jaw relax, the opisthotonos disappear, and the respirations become easier. It was gratifying to see the patient in a reactive state, able to cough, expectorate, drink, and move about in bed.

The day after the discontinuance of avertin administration, the temperature fell and the respirations became slower. No specific or chemotherapy was used for the pneumonia.

*The Intocostrin was supplied through the courtesy of E. R. Squibb & Sons.

As with avertin, the frequency of administration of curare was determined by the tone of the rectus abdominis. The doses used are shown in Table I. There seemed to be much variation in the length of

TABLE I

DATE (1942)	TIME OF ADMINISTRATION	DRUG	DOSAGE (MG. PER KG.)	MODE OF ADMINISTRATION	DURATION OF EFFECT	
					HR.	MIN.
11/7	9:05 P.M.	Avertin	50	P. R.*	2	00
11/8	11:05		40	P. R.	10	05
	9:00 A.M.		70	P. R.	5	00
	2:00 P.M.		100	P. R.	2	10
	4:10		30	P. R.	0	50
	5:00		30	P. R.	0	55
	5:55		30	P. R.	0	25
	6:20		30	P. R.	1	25
	7:45		70	P. R.	5	30
11/9	1:15 A.M.		100	P. R.	9	05
	10:20		100	P. R.	4	55
	3:15 P.M.	Curare	60	I.V.†	8	05
	11:20		40	I.V.	9	10
11/10	8:30 A.M.		60	I.V.	6	50
	3:20 P.M.		70	I.V.	1	45
	5:05		50	I.M.‡	2	32
	7:37		70	I.M.	1	51
	9:28		50	I.M.	2	28
	11:50		50	I.M.	4	26
11/11	4:16 A.M.		50	I.M.	2	29
	6:45		50	I.M.	3	45
	10:30		50	I.V.	3	12
	1:42 P.M.		50	I.M.	2	13
	3:55		50	I.M.	3	30
	7:25		50	I.M.	3	30
	10:55		50	I.M.	1	10
11/12	12:05 A.M.		25	I.M.	1	55
	2:00		50	I.M.	3	45
	5:45		50	I.M.	1	00
	6:45		50	I.M.	2	25
	9:10		50	I.M.	3	15
	12:25 P.M.		50	10 mg. I.V.: 40 mg. I.M.	2	30
	2:55		50	I.M.	2	50
	5:45		50	I.M.	2	30
	8:15		50	I.M.	3	50
11/13	12:05 A.M.		50	I.M.	4	37
	4:42		70	20 I.V.: 50 I.M.	3	22
	8:10		50	10 I.V.: 40 I.M.	8	10
	4:20 P.M.		30	I.M.	0	40
	5:00	Beta-erythroidine	500	I.V.	3	51
	8:51		300	I.V.	3	44
11/14	12:35 A.M.		300	I.V.	2	55
	3:30		300	I.V.	4	33
	8:03		300	I.M.	2	22
	10:25		300	I.V.	1	25
	11:50		300	I.V.	1	55
	1:45 P.M.		300	I.V.	3	33
	5:20		300	I.V.	2	57
	8:17		300	I.V.	3	13
	11:30		300	I.V.	9	30
11/15	8:35		300	I.V.		

*P.R., per rectum.
†I.V., intravenous.
‡I.M., intramuscular.

the intervals between attacks, as well as in their duration and severity. It was found, however, that usually 0.050 Gm. of curare would keep the patient comfortable and free from acute spasm for about three hours. The amount of drug administered was determined by the response of the patient. Roughly speaking, 0.008 to 0.010 Gm. per kilogram was satisfactory.

On the seventh day, the last of the supply of curare was used. Treatment was continued with beta-erythroidine, a drug similar to curare in its action. Three hundred milligrams of a ten per cent solution produced approximately the same effect as 0.050 Gm. of curare. With the injection of beta-erythroidine, the patient experienced a slight feeling of faintness. On two occasions, there was momentary fall in systolic blood pressure of about 30 mm. No fall in blood pressure was observed when curare was used.

Beta-erythroidine was not needed after the ninth day. By this time, the spasms were no longer severe enough to endanger the patient's life or even discomfit him. He was then given 4.5 gr. (0.240 Gm.) of phenobarbital daily, in divided doses.

Until late in the course of the disease, sedatives were used only occasionally to control restlessness and irritability. There was no objection to moderate use of morphine or barbiturates, but in this case they were seldom needed because the patient often lapsed into sleep after receiving curare.

Nutrition and hydration were maintained by giving fluids intravenously and a liquid diet. Difficulty in swallowing was never a prominent symptom in this case during the early stages of treatment, but the possibility of regurgitation and aspiration during a sudden severe spasm, as well as the great fluid loss with sweating, made us prefer the intravenous route.

The generalized hypertonicity was slow in leaving, and was still present to some extent when the patient was discharged on the eighteenth day.

DISCUSSION

The treatment of tetanus with curare is not a new idea. Curare was first used in the treatment of tetanus in 1894, by Hoche.[1] Since that time, a small number of cases in which tetanus was treated with curare have been reported.[2-6]

Lack of a good, standardized preparation of curare has hindered the development of this treatment. Most of the preparations which have been used were obtained from independent pharmacologists who were interested in the drug, and hence have varied in potency and purity.

The site of action of curare is peripheral, rather than central. It is said to act by interrupting the synaptic transmission of nerve impulses at the myoneural junction by depressing the nicotinic action of acetylcholine, thus producing paralysis without central depression.

It is selective in its action, and affects the muscles of the body in the following order: (1) muscles innervated by cranial nerves, (2) muscles of the trunk and extremities, and (3) muscles of respiration (the diaphragm is the last to be paralyzed). It is this sequence of action which makes possible the release of the convulsive patient from the asphyxiating tonic fixation of the chest, without complete paralysis of the respiratory muscles.

The side actions of curare, namely the reported tendency to produce bronchial spasm and hypersecretion,[2] were not troublesome. When questioned after the injection of the drug, the patient expressed relief, and stated that otherwise his only sensation was one of great weakness.

Provisions were made for the relief of undue respiratory depression after the injection of curare or beta-erythroidine, although none occurred in this patient. An anesthetic face mask, rebreathing bag, and oxygen supply were immediately available for artificial respiration. Although it has been recommended[5] that a mechanical respirator of the Drinker type be on hand, the respiratory paresis after the administration of curare is so sudden in onset and short lived that, by the time the patient could be placed in the respirator, the respiratory paresis would be spontaneously relieved. Physostigmine and prostigmine, because of their ability to depress cholinesterase, are suitable for use in combatting undue respiratory depression from curare.

Since beta-erythroidine was used in the terminal stage of the disease, little can be said about the relative effectiveness of this drug and curare. The circulatory depressant effect of beta-erythroidine, which was evident in this case, is undesirable.

SUMMARY

The use of curare for the control of muscle spasm in a case of tetanus is reported. It is felt that curare possesses certain advantages, and this case is presented in the hope that it will stimulate further clinical investigation into the value of this therapeutic agent.

Since the submission of this paper for publication, curare has been used in the treatment of three additional cases of tetanus. All three terminated fatally. The experience gained in these later cases leads us to believe that curare will effectively control the muscle spasm. The experience emphasizes, however, the necessity of having an individual or individuals experienced in the actions of curare and the course of the disease who can devote his or their entire time to the patient in the early stages of the disease. The variations in the manifestations of the disease and the variations in the response to the curare make mandatory this constant supervision by trained personnel. With this supervision, curare should be effective in the treatment and possess the advantages of a patient awake, able to move, void, defecate, and respire freely.

REFERENCES

1. Hoche, A.: Use of Curarine in Tetanus, Centralbl. Neurol. 13: 289-296, 1894.
2. West, Ranyard: *Intravenous Curarine in the Treatment of Tetanus*, Lancet 1: 12-16, 1936.
3. Mitchell, J. S.: Case of *Tetanus Treated With Curarine*, Lancet 1: 262, 1935.
4. Cole, L. B.: Tetanus Treated With Curare, Lancet 2: 475-477, 1934.
5. Isaacson, S. E., and Swenson, S. A., Jr.: *Curare in the Treatment of Tetanus*, Nebraska M. J. 26: 136-137, 1941.
6. Hale-White: Textbook of *Pharmacology*, London, 1901, P. Blakiston Son & Co., p. 199.

THE USE OF CURARE FOR THE IMPROVEMENT OF ABDOMINAL MUSCLE RELAXATION DURING INHALATION ANESTHESIA

Report on One Hundred and Thirty-One Cases

Stuart C. Cullen, M.D., Iowa City, Iowa

(From the Division of Anesthesiology, Department of Surgery, State University of Iowa College of Medicine, Iowa City)

SURGICAL manipulations within the abdomen are always facilitated by a state of complete muscular relaxation associated with quiet breathing and contracted intestine. If this state can be achieved without increased hazard to the patient during anesthesia or without predisposing toward undesirable postanesthetic sequelae, the added convenience to the surgeon expedites his work and directly contributes to a smoother, more complete, and more rapid convalescence of the patient. In an effort to simulate this ideal condition, curare was administered during inhalation anesthesia.

The popular concept of the principal usefulness of curare as a means of paralyzing the game of foraging South American Indians or as a demonstrating drug in the pharmacology laboratory is gradually being displaced by a succession of interesting and valuable clinical applications. Since 1857, it has been used practically in the treatment of convulsive states such as tetany, strychnine poisoning, and chorea.[1] Burman[2] has advocated its use in the treatment of spastic disorders. Bennett[3] has found it useful in controlling the frequency of fractures accompanying the convulsions of metrazol shock therapy. Through the publications and exhibits of the latter men, I was tempted in 1940, to use curare as a means of improving the relaxation of abdominal musculature during inhalation anesthesia. At that time, a few dogs were given curare. In doses giving abdominal muscle relaxation, they salivated profusely, had extreme respiratory depression and asphyxial convulsive movements. These effects deterred the clinical application of curare for this purpose. Interest was, however, restimulated on the appearance of the report of Griffith and Johnson[4] of its use in twenty-five patients anesthetized with cyclopropane. An ample supply of Intocostrin* (extract of unauthenticated curare) was obtained and administered to 131 patients. The drug was supplied as an extract standardized by biological assay to contain the equivalent of 0.02 Gm. per cubic centimeter of a standard drug.

*Through the courtesy of Dr. L. H. Wright of E. R. Squibb & Sons.

Received for publication, March 9, 1943.

It is selective in its action, and affects the muscles of the body in the following order: (1) muscles innervated by cranial nerves, (2) muscles of the trunk and extremities, and (3) muscles of respiration (the diaphragm is the last to be paralyzed). It is this sequence of action which makes possible the release of the convulsive patient from the asphyxiating tonic fixation of the chest, without complete paralysis of the respiratory muscles.

The side actions of curare, namely the reported tendency to produce bronchial spasm and hypersecretion,[2] were not troublesome. When questioned after the injection of the drug, the patient expressed relief, and stated that otherwise his only sensation was one of great weakness.

Provisions were made for the relief of undue respiratory depression after the injection of curare or beta-erythroidine, although none occurred in this patient. An anesthetic face mask, rebreathing bag, and oxygen supply were immediately available for artificial respiration. Although it has been recommended[5] that a mechanical respirator of the Drinker type be on hand, the respiratory paresis after the administration of curare is so sudden in onset and short lived that, by the time the patient could be placed in the respirator, the respiratory paresis would be spontaneously relieved. Physostigmine and prostigmine, because of their ability to depress cholinesterase, are suitable for use in combatting undue respiratory depression from curare.

Since beta-erythroidine was used in the terminal stage of the disease, little can be said about the relative effectiveness of this drug and curare. The circulatory depressant effect of beta-erythroidine, which was evident in this case, is undesirable.

SUMMARY

The use of curare for the control of muscle spasm in a case of tetanus is reported. It is felt that curare possesses certain advantages, and this case is presented in the hope that it will stimulate further clinical investigation into the value of this therapeutic agent.

Since the submission of this paper for publication, curare has been used in the treatment of three additional cases of tetanus. All three terminated fatally. The experience gained in these later cases leads us to believe that curare will effectively control the muscle spasm. The experience emphasizes, however, the necessity of having an individual or individuals experienced in the actions of curare and the course of the disease who can devote his or their entire time to the patient in the early stages of the disease. The variations in the manifestations of the disease and the variations in the response to the curare make mandatory this constant supervision by trained personnel. With this supervision, curare should be effective in the treatment and possess the advantages of a patient awake, able to move, void, defecate, and respire freely.

REFERENCES

1. Hoche, A.: Use of Curarine in Tetanus, Centralbl. Neurol. 13: 289-296, 1894.
2. West, Ranyard: Intravenous Curarine in the Treatment of Tetanus, Lancet 1: 12-16, 1936.
3. Mitchell, J. S.: Case of Tetanus Treated With Curarine, Lancet 1: 262, 1935.
4. Cole, L. B.: Tetanus Treated With Curare, Lancet 2: 475-477, 1934.
5. Isaacson, S. E., and Swenson, S. A., Jr.: Curare in the Treatment of Tetanus, Nebraska M. J. 26: 136-137, 1941.
6. Hale-White: Textbook of Pharmacology, London, 1901, P. Blakiston Son & Co., p. 199.

Except for two infants who received 0.004 Gm. and 0.006 Gm., respectively, the smallest initial dose was 0.04 Gm. and the largest initial dose 0.1 Gm. After more experience in estimating the initial amount required, the usual first dose for patients between 20 and 70 years old was 0.060 Gm. If this proved insufficient, 0.040 Gm. was added. If more drug was still indicated, 0.020 Gm. was added at three- to five-minute intervals until the optimal state was reached. Except in very resistant cases, 0.040 to 0.060 Gm. at the time of peritoneal closure was sufficient. The largest total dose (0.240 Gm.) was given over a three-hour period to a 39-year-old man who had a resection of a portion of the ileum and colon. The average total dose, excluding the two infants, was 0.0925 Gm.

EFFECTS

It was found from experience that the amount of drug necessary to produce the ideal abdominal state of muscular relaxation and quiet gut often appreciably depressed the respiration. This respiratory depression progressed to complete paresis in five patients for periods varying from two to five minutes. In the others, the depression was manifested by loss of intercostal muscle function and jerky diaphragmatic movements. These more severe degrees of depression persisted for only five to twenty minutes and relatively normal ventilation reappeared long before the abdominal muscle tonus returned. Artificial respiration with intermittent inflation of the lungs by manual compression of the rebreathing bag was all that was necessary in those patients having complete respiratory arrest. In the others in whom ventilation was incompetent, the inspiratory phase was accentuated by manual compression of the rebreathing bag. These experiences emphasize the necessity for an immediately available and efficient means of ventilating the alveoli with oxygen when curare is being used. During inhalation anesthesia by the carbon-dioxide absorption technique, it is a simple matter and causes little inconvenience and minimal hazard.

Undesirable circulatory effects resulting from the administration of curare were infrequent and limited to those cases in which large amounts were given in a short period of time. In these cases, the systolic blood pressure dropped 30 to 40 mm. and the pulse pressure diminished. The pulse was unaffected and recovery was prompt. In other cases, blood pressure and pulse responses were not appreciably different from the changes associated with cyclopropane anesthesia. There was some evidence that with unrelieved respiratory depression an accumulation of carbon dioxide caused an elevation in blood pressure. From the clinical experience gained in these cases, it would seem that curare exerts no direct effect on the peripheral circulation or the heart unless excessive doses are administered.

No studies were made of the effect of curare on the liver or kidneys. No thrombosis or phlebitis was noted in the veins used for injection, even when relatively frequent injections were made.

PHARMACOLOGIC PROPERTIES

As early as 1865, Claude Bernard[5] described the action of the drug on the neuromuscular junction and confirmed the observations of Watterton and Brodie, in 1814, that asphyxia from respiratory paralysis was the cause of death. Brown and Feldberg[6] demonstrated that the drug interferes with the transmission of impulses across sympathetic ganglia. It is selective in its action, and affects the muscles of the body in the following order: (1) muscles innervated by cranial nerves, (2) muscles of the trunk and extremities, and (3) muscles of respiration (the diaphragm is the last to be paralyzed). Respiratory depression of central origin has been reported.[7] Smooth muscle is not affected. In the pure form, no significant direct effect on heart or peripheral circulation is noted. No analgesic or anesthetic action has been demonstrated. Its effect, when given intravenously, is obtained in one minute. When given intramuscularly, its maximum effect is obtained in ten to fifteen minutes. It is not effective when administered subcutaneously or perorally. It is said to be completely eliminated in about two hours by destruction in the liver and excretion through the kidney. The action of the drug is said to persist for but twenty to thirty minutes, but, as will be pointed out later, the muscular relaxation produced by curare during inhalation anesthesia lasts much longer. There is little cumulative action and the drug can be repeated relatively frequently. Overdose causes respiratory paralysis, and treatment for it is artificial respiration with oxygen. Physostigmine and prostigmine are of value in specific antidotal therapy because they inhibit choline esterase.

METHOD

The anesthetic procedure during which curare was employed was performed as usual. The patients were premedicated with morphine and scopolamine according to their requirements and the requirements of the agent to be employed. They were anesthetized by means of the carbon dioxide absorption technique to the first or second plane level of third stage anesthesia and maintained there. The curare was introduced intravenously about the time the skin incision was made so that by the time the peritoneum was opened, the full effect of the dose had been obtained. With the introduction of the curare, the flow of anesthetic agent was discontinued for a few minutes until the degree of respiratory depression was determined. The optimum effect desired was complete muscular relaxation and quiet intestine. If this was not achieved, intravenous injections were repeated at three- to five-minute intervals until the desired effect was manifest. Relaxation then usually persisted for 60 to 120 minutes, or until closure of the peritoneum. After relaxation was established, it was unnecessary to repeat the curare during the course of long operations. It was, however, frequently necessary to inject more curare for closure of the abdomen if the operative procedure lasted longer than forty-five minutes.

Except for two infants who received 0.004 Gm. and 0.006 Gm., respectively, the smallest initial dose was 0.04 Gm. and the largest initial dose 0.1 Gm. After more experience in estimating the initial amount required, the usual first dose for patients between 20 and 70 years old was 0.060 Gm. If this proved insufficient, 0.040 Gm. was added. If more drug was still indicated, 0.020 Gm. was added at three- to five-minute intervals until the optimal state was reached. Except in very resistant cases, 0.040 to 0.060 Gm. at the time of peritoneal closure was sufficient. The largest total dose (0.240 Gm.) was given over a three-hour period to a 39-year-old man who had a resection of a portion of the ileum and colon. The average total dose, excluding the two infants, was 0.0925 Gm.

EFFECTS

It was found from experience that the amount of drug necessary to produce the ideal abdominal state of muscular relaxation and quiet gut often appreciably depressed the respiration. This respiratory depression progressed to complete paresis in five patients for periods varying from two to five minutes. In the others, the depression was manifested by loss of intercostal muscle function and jerky diaphragmatic movements. These more severe degrees of depression persisted for only five to twenty minutes and relatively normal ventilation reappeared long before the abdominal muscle tonus returned. Artificial respiration with intermittent inflation of the lungs by manual compression of the rebreathing bag was all that was necessary in those patients having complete respiratory arrest. In the others in whom ventilation was incompetent, the inspiratory phase was accentuated by manual compression of the rebreathing bag. These experiences emphasize the necessity for an immediately available and efficient means of ventilating the alveoli with oxygen when curare is being used. During inhalation anesthesia by the carbon-dioxide absorption technique, it is a simple matter and causes little inconvenience and minimal hazard.

Undesirable circulatory effects resulting from the administration of curare were infrequent and limited to those cases in which large amounts were given in a short period of time. In these cases, the systolic blood pressure dropped 30 to 40 mm. and the pulse pressure diminished. The pulse was unaffected and recovery was prompt. In other cases, blood pressure and pulse responses were not appreciably different from the changes associated with cyclopropane anesthesia. There was some evidence that with unrelieved respiratory depression an accumulation of carbon dioxide caused an elevation in blood pressure. From the clinical experience gained in these cases, it would seem that curare exerts no direct effect on the peripheral circulation or the heart unless excessive doses are administered.

No studies were made of the effect of curare on the liver or kidneys. No thrombosis or phlebitis was noted in the veins used for injection, even when relatively frequent injections were made.

The postoperative course of these patients was unaltered. A lower incidence of pulmonary pathology was expected because of the opportunity to use a nonirritating gaseous agent which is quickly eliminated postanesthetically. An evaluation of this factor will be deferred until more patients have been studied. The nursing staff shared the enthusiasm of the surgeons for the use of the cyclopropane-curare combination because the patients awoke promptly and required minimal immediate postanesthetic care.

One death occurred in a 60-year-old man brought to the operating room in a moribund state with a wound dehiscence. He was anesthetized to the first plane of the third stage with cyclopropane and given 0.060 Gm. of curare intravenously for the extreme relaxation required to effect the secondary closure. He died of sudden circulatory failure ten minutes after the injection of the curare. A fulminating peritonitis was found at autopsy.

An interesting case in the series was that of a 44-year-old woman who was difficult to examine bimanually because of marked voluntary abdominal muscle spasm. Without premedication of any type, she was given 0.060 Gm. of curare intravenously in an attempt to produce muscular relaxation of the abdomen. With this dose, she had some ptosis and masseter muscle relaxation, but no significant decrease in recti muscle tone. After five minutes, she was given 0.040 Gm. of curare intravenously. She then promptly presented the same clinical picture as the dogs mentioned early in this article. There was complete respiratory paralysis, marked salivation, and muscular twitching. She was given artificial respiration with oxygen by face mask and manual compression of the rebreathing bag of a gas machine. Her blood pressure taken at this time was elevated 20 to 30 mm. over her original pressure, but the pulse was essentially unchanged. However, there was still insufficient abdominal muscle relaxation to permit satisfactory examination. At this point, and although effective voluntary respiration had not returned, she was given morphine sulfate, gr. $\frac{1}{6}$ (0.010 Gm.), and scopolamine, gr. $\frac{1}{150}$ (0.00045 Gm.), intravenously. Voluntary and efficient respiration was almost immediately resumed by the patient. Relaxation of the recti was somewhat improved and the results of the bimanual examination led the surgeon to feel that a vaginal hysterectomy was indicated. The patient was then anesthetized with cyclopropane and the operation and anesthetic procedure carried out without further untoward incident. With only first plane anesthesia, abdominal muscle relaxation was excellent.

This case was interesting because it seemed to indicate that one of the premedicating drugs, probably scopolamine, is necessary for the uncomplicated use of the curare. It helps to explain why the dogs, which were unpremedicated, behaved in such a discouraging fashion. The case also indicates that complete abdominal muscular relaxation is difficult to achieve with curare alone in safe dosages, and that,

in addition to providing the necessary analgesia, the inhalation agent contributes a significant share in the production and maintenance of that relaxation.

OPERATIVE PROCEDURES AND ANESTHETIC AGENTS AND TECHNIQUES

In Table I are listed the operative procedures performed on the patients included in this report. It will be noted that all are procedures requiring excellent relaxation and quiet intestine, a state which cannot usually be obtained with gaseous agents alone. The two infants, on whom the Rammstedt procedure was done, were anesthetized by procaine infiltration of the line of incision, but because of the crying and straining, it was extremely difficult to restore the intestine to the peritoneal cavity. Small doses of curare intravenously permitted nontraumatic and easy restoration of the bowel to the abdominal cavity. Two patients had nitrous oxide anesthesia. One was a man, 72 years of age, who had a gastric resection, and the other a woman 62 years of age, who had an exploratory laparotomy. Curare successfully provided the relaxation which could not be achieved with the impotent nitrous oxide. Curare was also used to provide relaxation for the closing of an abdomen on one patient in whom the motor effect of the spinal anesthesia was wearing off.

TABLE I

OPERATIONS	NO.
Cholecystectomy	19
Mikulicz resection of the sigmoid	5
Choledochostomy	4
Gastric resection	13
Abdominoperineal resection of the rectum	5
Cholecystgastrostomy	1
Hysterectomy	29
Colostomy	4
Closure perforated peptic ulcer	2
Exploratory laparotomy	14
Total gastrectomy	1
Appendectomy	3
Resection of colon	2
Ureteronephrectomy	1
Incisional herniorrhaphy	9
Excision internal iliac aneurysm	1
Secondary closure abdomen	1
Ureterosigmoidostomy	1
Closure of enterovaginal fistula	1
Resection of ileum	3
Inguinal herniorrhaphy	1
Gastroenterostomy	2
Rammstedt operation	2
Oophorectomy	2
Abdominal sterilization	1
Uterine suspension	1
Relief of acute intestinal obstruction	1
Ureterolithotomy	1
Dilatation and curettage, examination under anesthesia	1

Four patients were given curare in conjunction with ether anesthesia. Two of these patients had no significant respiratory depres-

sion, but the other two had pronounced and prolonged respiratory depression from moderate amounts of curare. As a consequence of this experience, curare is not used in patients to whom ether is administered. This interesting effect is now being investigated. The remaining 122 patients were given cyclopropane. This combination appeared particularly effective. The scope of usefulness of cyclopropane was extended because it could be used for anesthesia for surgical procedures requiring extreme relaxation. The hazard of cardiac arrhythmia was reduced because it was no longer necessary to use high concentrations in an effort to secure relaxation.

SUMMARY

In an effort to secure improved abdominal muscle relaxation and quiet intestine with inhalation anesthesia, particularly by cyclopropane, curare was used in 131 patients. A brief review of the history and pharmacologic actions of the drug, as well as a report of its use on these patients, was included. Experiences of Griffith and Johnson[4] are confirmed by this report, and warrant its continued experimental use. These reports also indicate the need for extended investigation into the effect of curare in combination with other agents.

Since the submission of this article for publication, curare has been used in 370 additional cases. The results continue to be quite satisfactory. With this added experience, it has been possible to estimate better the required dose and obtain the desired state without marked respiratory depression.

REFERENCES

1. West, Ranyard: Intravenous Curarine in Treatment of Tetanus, Lancet 1: 12-16, 1936.
2. Burman, M. S.: Therapeutic Use of Curare and Erythroidine Hydrochloride for Spastic and Dystonic States, Arch. Neurol. & Psychiat. 41: 307-327, 1939.
3. Bennett, A. E.: Preventing Traumatic Complications in Convulsive Shock Therapy by Curare, J. A. M. A. 114: 322-324, 1940.
4. Griffith, Harold R., and Johnson, Enid: The Use of Curare in General Anesthesia, Anesthesiology 3: 418-421, 1942.
5. Bernard, C.: Note Sur la Curarine et Ses Effets Physiologiques, Bull. gén. de thérap. 69: 23, 1865.
6. Brown, G. L., and Feldberg, W.: Differential Paralysis of the Superior Cervical Ganglion, J. Physiol. 86: 10P, 1936.
7. Felger, J.: The Action of Curare on the Respiratory Center, J. Physiol. 100: 417-422, 1942.

PRELIMINARY OBSERVATIONS CONCERNING PARAVERTEBRAL INJECTION OF THE SYMPATHETIC SYSTEM IN HYPERTENSION

HENRY G. SCHWARTZ, M.D., AND THOMAS FINDLEY, M.D., ST. LOUIS, MO.
(From the Departments of Surgery and Medicine, Washington University School of Medicine)

IT CAN no longer be doubted that sympathectomy with section of the splanchnic nerves is an effective adjunct in the treatment of some cases of hypertension, but there is no agreement concerning the type of operation which should be employed. The technique advocated by Peet[1] consists of bilateral supradiaphragmatic resection of the tenth, eleventh, and twelfth thoracic ganglia and the intervening chain, together with the splanchnic nerves; in a series of 290 patients, it produced a significant reduction in blood pressure in 51.4 per cent and satisfactory symptomatic improvement in 96.6 per cent.[2] The operation popularized by Adson and co-workers[3] consists of subdiaphragmatic removal of the splanchnic nerve and the first and second lumbar sympathetic ganglia; in a series of 224 patients, it resulted in a significant blood pressure reduction in 31 per cent and produced satisfactory symptomatic improvement in more than 80 per cent.[4] Smithwick[5] has advocated a combination of these two procedures. Whatever procedure is employed, the effect on blood pressure is often disappointing. However, all authors have noted frequent subsidence of papilledema and have stressed the fact that neither the degree of symptomatic improvement nor the amount of retinal healing is proportional to the drop in blood pressure.

In a much more limited experience we too have been impressed by the lack of correlation between the severity of symptoms and the height of the blood pressure. It is obvious that the surgical treatment of hypertension would be on a firmer basis if there were a more reliable method for identifying preoperatively those patients in whom good results will be obtained. The criteria suggested to date have not been particularly successful. This report concerns three patients upon whom bilateral paravertebral alcoholic blocks were performed for this purpose. We believe that the effects of novocain injection alone would be too transitory to allow adequate evaluation of any response.

The technique followed was similar to that described by White[6] for injection of the upper thoracic trunk in the treatment of angina pectoris

Received for publication, Nov. 11, 1942

but modified to effect roughly those areas denervated by the combined Peet and Adson operations; i.e., the tenth, eleventh, and twelfth thoracic segments, first lumbar segment and the splanchnic nerves. After light morphine-scopolamine analgesia was produced, spinal needles were inserted at the appropriate levels, first on the right side about three fingerbreadths lateral to the midline; they were passed just below the lower borders of the transverse processes or articulating portions of the ribs and then directed medially at an angle of 20 to 30 degrees to a depth of 3 to 3½ cm. beyond the level of the rib articulations. At this depth, the needle point comes to rest against the anterolateral surface of the vertebral bodies where the ganglionated chain lies. In the case of the splanchnic nerves themselves, their point of entry between the medial and intermediate crura of the diaphragm lies very close to the vertebral body. Customary precautions were taken to make sure that the needle tips did not lie within the pleural space, blood vessels, or intervertebral foramina. Injection of 2 c.c. of 1 per cent solution of procaine hydrochloride at each level was followed by the slow instillation of 3 to 4 c.c. of 80 per cent alcohol. Both sides were injected at a single sitting. In the two male cases, the second lumbar segment was also injected on the right side and probably should be included bilaterally. Completeness of injection was then determined by means of a sweat test, using cobalt chloride as an indicator.

CASE REPORTS

CASE 1.—G. H., a 29-year-old white man, had suffered for more than ten years from attacks of headache, vertigo, nausea, and transient amaurosis. For six months prior to injection these attacks had occurred from two to four times a week with such violence that he was unable to perform his duties as a truck driver. During several weeks of hospital observation and bed rest his arterial pressure varied from 150/110 to 210/130, and he had an almost constant headache. Despite the chronic history, his retinal vessels were virtually normal, the heart was only slightly enlarged, and kidney function was intact. The urine was clear and intravenous urograms were negative. He refused operation but readily consented to injection.

Paravertebral alcoholic block was done on July 17, 1940. Before and during the procedure, his blood pressure ranged from 170/120 to 230/160. Five hours later it was 130/90; at twenty-four hours it was 140/95; at forty-eight hours 150/100. He walked out of the hospital on the third day with a reading of 160/110, complaining only of slight soreness in the back and stating that his head was unusually clear and comfortable.

Within a week the blood pressure had returned to its former level, the readings usually being in the neighborhood of 170/110. He resumed his work within a month, however, and from July, 1940, until November, 1941, he experienced only three or four abortive attacks, each lasting less than five minutes and extremely mild. For a few weeks after injection, he had a moderately uncomfortable neuritis on the left side of the trunk but he repeatedly expressed his delight over the results of the "treatment." We had expected the symptoms to recur in about six months and to recommend operation at that time but he remained in good health for nearly eighteen months. The patient himself noted that during this period of freedom from symptoms there was no visible sweating of his abdomen at any

time. During the latter part of the summer of 1941 he noted return of sweating, and symptoms recurred shortly thereafter.

In November, 1941, he had three severe attacks in quick succession and voluntarily requested another injection. At this time his physical examination had not changed perceptibly but the blood pressure was about 175/135. A sweat test revealed no areas of anhydrosis. On Nov. 22, 1941, he was reinjected as before except that this time the second lumbar segment was included on the right side. Again, there was a moderate but temporary drop in pressure for about twenty-four hours. Completeness of injection was proved by another sweat test (Fig. 1). He was back at work within a week with a pressure of 165/125 but stated that he felt very well.

On July 28, 1942, he reported that he had had only two mild attacks since his second injection. All visual difficulties had disappeared. He regarded himself as being at least "80 per cent improved." On the basis of these two experiences he was advised to submit to surgery.

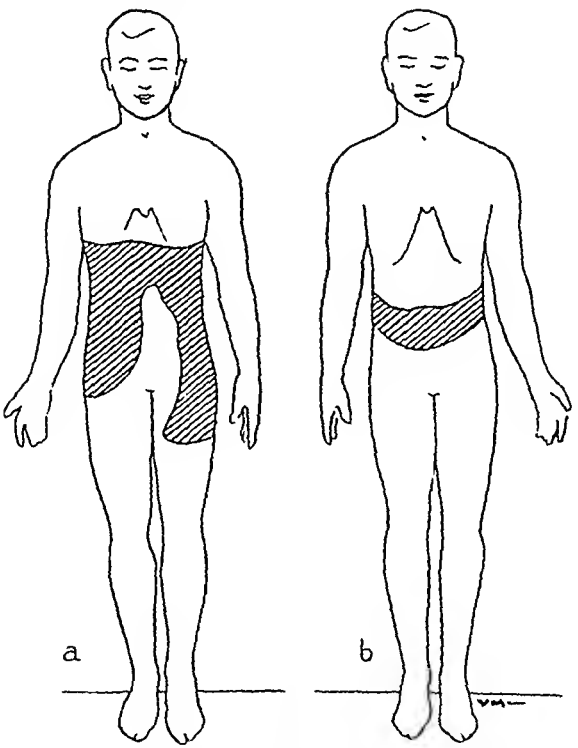

Fig. 1.—Areas of anhydrosis following paravertebral alcoholic block in (*a*) patient G. H. and (*b*) patient J. F.

CASE 2.—B. D., a 24 year old white girl, for three years had experienced paroxysms of headache, palpitation, dyspnea, and flushing of the face four to six times monthly. Between attacks she felt perfectly well but had a persistent hypertension, the blood pressure fluctuating between 145/110 and 210/130. Her physical and laboratory examinations were negative except for questionable cardiac hypertrophy and minimal retinal sclerosis. During one such attack, her blood pressure was recorded as 180/130. She did not have paroxysmal tachycardia.

Paravertebral alcoholic block was done on July 18, 1940, without pain or difficulty. When she left the hospital forty eight hours later, her blood pressure was 130/80 No neuritis developed. When next seen about six months later the arterial pressure had reached its preinjection level but she was symptomatically greatly improved. The paroxysms were far less frequent and severe, and she considered herself virtually well. No sweat test was done.

On Aug. 14, 1942, she reported that she had gone six more months without any symptoms whatever. More recently, the attacks had recurred in a very mild form and never oftener than once a month. Her physician stated that her blood pressure averaged about 160/115. She also was advised to submit to operation

CASE 3.—J. F., a 44 year old white physician, for three months had noted increasingly severe headaches, dimness of vision, exertional dyspnea, and precordial pain. Ophthalmoscopic examination revealed marked narrowing and tortuosity of the retinal arteries, arteriovenous compression of a high degree, a few scattered hemorrhages, and beginning papilledema but no exudates. The heart was moderately enlarged but there was no congestive failure. The urine contained small amounts of protein and a few casts. Urea clearance test was 50 per cent of normal; intravenous urograms, negative; spinal fluid pressure was 240 mm. water; initial arterial blood pressure, 215/140. No important drop occurred after three weeks of bed rest and thiocyanate administration, and the symptoms continued unabated. Visual acuity was so diminished that he was unable to read the newspaper or to sign his name.

On Oct. 4, 1941, the following segments were injected with procaine hydrochloride and alcohol: on the right side, the ninth, tenth, eleventh, and twelfth thoracic, and the first lumbar segments; on the left the first lumbar ganglion was omitted. For the next twenty four hours his blood pressure varied between 155/60 and 170/90. He walked out of the hospital on Oct 10, 1941, stating that he felt "like a different person" The headaches and vomiting had promptly subsided; he felt clearer mentally and was able to read without difficulty. Several observers thought the edges of the optic discs were more distinct. His blood pressure was 200/110 The area of anhydrosis is shown in Fig. 1.

In this instance, even the symptomatic improvement was short lived. Within a month the cerebral complaints returned with such violence that he sought treatment elsewhere Subdiaphragmatic splanchnicectomy was performed in November, 1941, with again temporary relief from headache Blood pressure was essentially unaltered and he died on Jan. 25, 1942.

COMMENTS

We thoroughly agree with those who prefer operation to injection on the grounds of safety and certainty. If there were reliable means for predicting postoperative results, injection methods could have no defense. However, patients who are asked to undergo operation should be selected with all possible care. In cases where doubt exists concerning probable benefit from surgery, preliminary paravertebral alcohol injection may be of considerable prognostic value. Completeness of injection can be readily demonstrated by sweat tests It remains to be seen whether there is consistent parallelism between the recurrence of symptoms and the disappearance of anhydrosis.

CONCLUSION

In three patients with hypertension, paravertebral alcoholic block has produced striking temporary symptomatic relief. It is suggested that the procedure be adopted as a method of preoperative selection of patients.

REFERENCES

1. Peet, M. M.: Splanchnic Section for Hypertension: a Preliminary Report, Univ. Hosp. Bull., Ann Arbor 1: 17, 1935.
2. Peet, M. M., Woods, W. W., and Braden, S.: The Surgical Treatment of Hypertension. Results in 350 Consecutive Cases Treated by Bilateral Supradiaphragmatic Splanchnicectomy and Lower Dorsal Sympathetic Ganglionectomy, J. A. M. A. 115: 1875, 1940.
3. Adson, A. W., Craig, W. McK., and Brown, G. E.: Surgery in Its Relation to Hypertension, Surg., Gynec. & Obst. 62: 314, 1936.
4. Allen, E V., and Adson, A. W.: The Treatment of Hypertension; Medical Versus Surgical, Ann. Int. Med. 14: 288, 1940.
5. Smithwick, R. H.: The Technic for Splanchnic Resection for Hypertension, SURGERY 7: 1, 1940.
6. White, J. C.: Technic of Paravertebral Alcohol Injection: Methods and Safeguards in Its Use in the Treatment of Angina Pectoris, Surg., Gynec. & Obst. 71: 334, 1940.

TRAUMATIC RUPTURE OF THE DUODENUM

With a Case Report

Jacob Sarnoff, M.D., and Benjamin H. Oremland, M.D.
Brooklyn, N. Y.

AMONG the many types of casualties in civil life and in the Armed Forces, crushing injuries of the abdominal viscera will demand our increasing attention, as the momentum and force of our war production and its execution are stepped up. This applies to those employed in the various industries, to those engaged in combat, and to civilians under air attack.

Solid organs, as well as hollow viscera, may be ruptured by the impact of external force. The liver, spleen, kidney, and pancreas may be ruptured by the direct crushng effect of an external object. A hollow viscus such as the bladder, stomach, or intestines either may be crushed, or may burst by the hydraulic pressure exerted on the distended organ[1] (Fig. 1). It was hydraulic pressure that was probably responsible for the rupture of the duodenum in the case to be reported.

Guibe,[2] in 1910, collected all the cases from the literature from 1835 to 1940 inclusive. There were 134 cases. In 17 of these, the rupture occurred at the duodenojejunal angle. Of these 17, 1 patient survived. In all, there were 62 operations with 4 recoveries. Eighty-four cases were collected from 1910 to 1940, with 37 recoveries. These improved results, no doubt, are in part due to the advances made in surgery during this period. Duodenal rupture occurred in about 10 per cent of all intestinal ruptures.

When one reasonably suspects such an injury, it is much safer to do an exploratory laparotomy, rather than procrastinate. One should not indulge in wishful thinking, hoping that the injury may be trivial and will require no surgical intervention. The high mortality in cases of duodenal rupture may be explained by: (1) the frequency of associated serious injuries, (2) operative delay, (3) nonrecognition of the rupture before or during the operation. The dangers of procrastination in intraabdominal injuries are mainly hemorrhage and peritonitis. The symptoms are those of shock due to hemorrhage or perforation.

During operation one may overlook a rupture of the duodenum if it occurs retroperitoneally. Emphysema and crepitation over the second and third portions of the duodenum, accompanied by a green spot or area overlying the rupture, are due to the extravasation of the duodenal secretion. These findings should put one on guard and make one search deeper for such an injury.

In a good many of the reported cases the condition was not recognized or treated until many hours or days after the accident. The

Received for publication, Feb. 17, 1943.

case to be presented illustrates some of the points discussed, as evidenced by the character of the accident, the operative findings, the clinical course and the end result.

CASE REPORT

History.—Nov. 26, 1942, at 1 P.M., M. M., a boy of 15 years, attempted to catch a fly ball during a baseball game. As he jumped for it, he ran into the tailboard of a parked truck. Bystanders said that the impact was so great that the truck actually moved when he struck it.

His abdomen struck the tailboard just below the costal margin and the boy collapsed. He then stood up and was taken to the family doctor's office by automobile. Examination at that time revealed a well developed, muscular young man in great pain. Temperature was normal. The right side of the abdomen was tender, but no rigidity was present. There was no obliteration of liver dullness. A diagnosis of intra-abdominal injury was made and close observation advised.

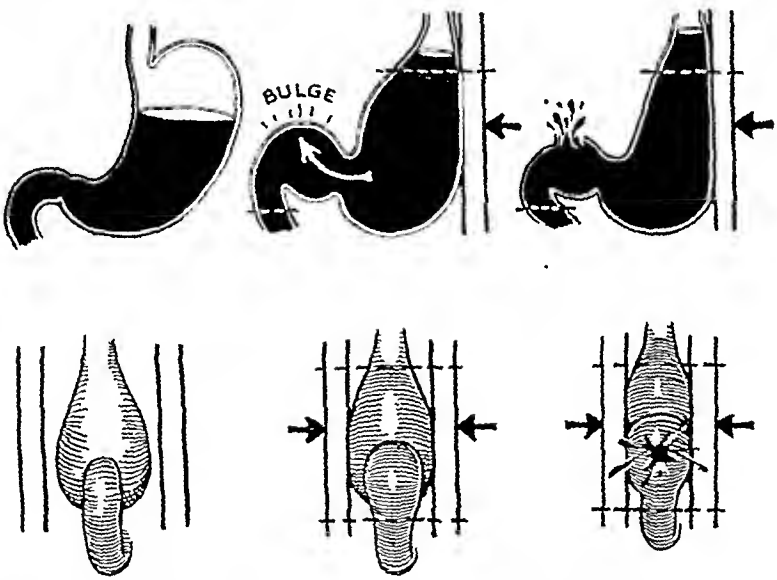

Fig. 1.—Mechanism of rupture of the duodenum by hydraulic force. A sudden blow to the abdomen may compress and block the contents of the stomach and duodenum causing it to burst by hydraulic pressure.

The drawing demonstrates diagrammatically the pressure on these organs as indicated by the arrows, and their blockage as indicated by the dotted lines.

The patient was taken home by automobile and put to bed. He vomited at 3 and 5 P.M. The vomitus was described as greenish black. The abdominal pain became more intense and the doctor was called again and saw him at 5:30 P.M. Examination then showed rigidity and marked tenderness on palpation, and rebound tenderness on the right side. Immediate hospitalization was advised. The patient was admitted to the hospital about 6:30 P.M. He was suffering from excruciating abdominal pain, more marked in the upper right quadrant. Pain was greatly aggravated by any motion. Examination showed the abdomen to be rigid and markedly tender. Immediate abdominal exploration was advised.

At 8 P.M. operation was performed by one of us (J. S.) under spinal anesthesia. A right rectus supraumbilical incision was made. On incising the peritoneum, there was an escape of a moderate amount of greenish fluid from the peritoneal

cavity. The liver and spleen were palpated and were found free of injury. The gall bladder appeared normal. The gastrocolic and the gastrohepatic omenta in the region of the pylorus appeared infiltrated with bile-stained fluid, and were quite swollen and edematous. In attempting to pass through the anterior layer of the omentum, there was an escape of many gas bubbles and bile, suggestive of an injury to the duodenum or bile ducts. After penetrating and separating a good deal of the infiltrated gastrohepatic omentum, deep down, extraperitoneally, there was found a rupture of the second portion of the duodenum, probably just below the Ampulla of Vater. The opening extended transversely across the duodenum, involving about two-thirds of its circumference (Fig. 2). The edges were found

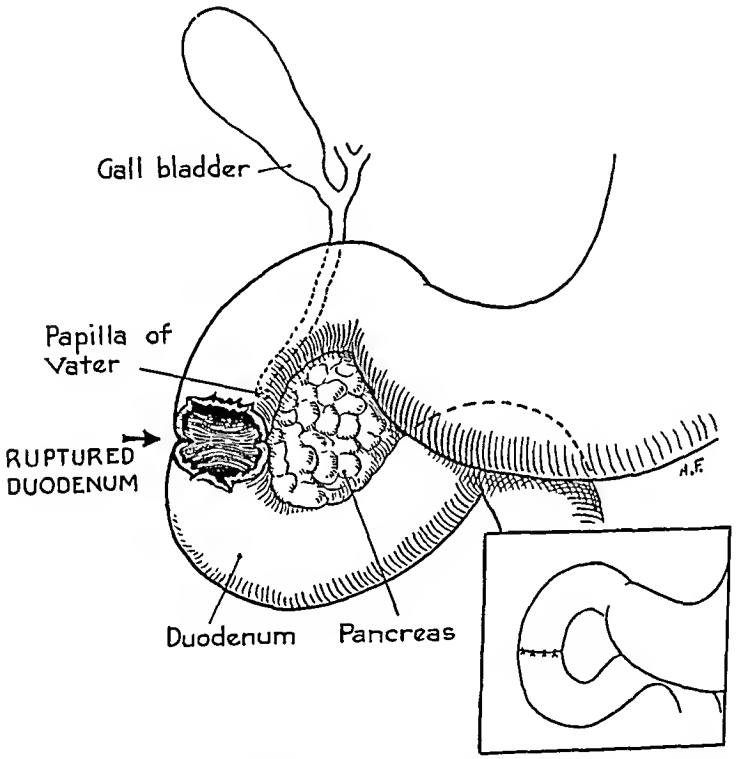

Fig. 2.—Rupture of the duodenum, just below the Papilla of Vater, involving about two-thirds of its circumference. The rupture was sutured in a transverse direction to avoid constriction of lumen, as shown in insert.

everted with the mucous membrane pouting. There was no bleeding, nor could any other injury be found. The head of the pancreas, adjoining the laceration, appeared normal and pinkish white in color, with no evidence of any trauma.

The fact that the pancreas and other adjoining structures were not in the least traumatized, led one to believe that the rupture of the duodenum in this case was due to hydraulic pressure (Fig. 1), and not to the direct crushing of the organ, although the duodenum is liable to be crushed because of its fixed position against the bodies of the vertebra. The fact that it is protected by the costal arch, liver, and floating intestines accounts for its less frequent injury. The muscles of the abdominal wall reflexly contract to protect the viscera from an oncom-

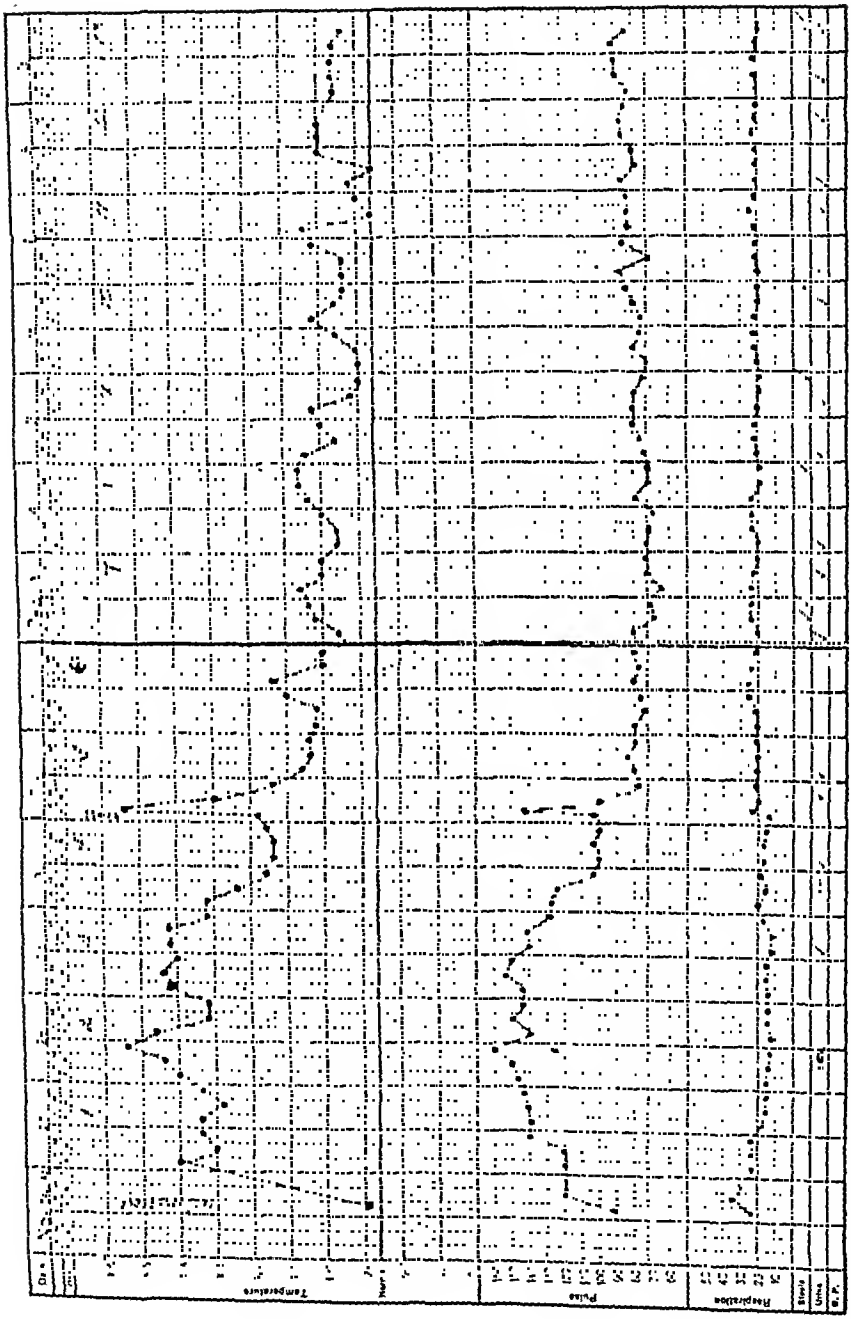

FIG. 3.—Graphic chart of the temperature, pulse, and respiration. The respirations were unusually slow, at about 20 per minute, in contrast to the rapid pulse reaching as high as 160, and high temperature topping 105° F. during the first week.

ing blow, when anticipated. The reason for the rupture of the duodenum may be partly explained by the fact that in this case the abdomen struck the tail end of the truck without the patient being aware of it as he concentrated his efforts on catching the ball The abdominal muscles were momentarily relaxed, allowing the force of the blow to reach the duodenum.

Fig 4 —X-ray Dec 30, 1942, reveals no evidence of any pathology in the stomach or duodenum, except that there is a constant shelf or pocket (see insert) situated in the inner aspect of the duodenal curve which is at the site where the rupture was repaired

The duodenum was closed transversely by interrupted 00 Lembert sutures, followed by a continuous seromuscular layer of sutures and a few interrupted sutures to reinforce the line of closure. Two cigarette drains were inserted toward the head of the pancreas, close to the line of anastomosis Ten grams of sulfanilamide were introduced into the peritoneal cavity and the abdomen was closed in layers A Levin tube was passed and 5 per cent glucose was administered intravenously.

About 4 A M. or about eight hours after operation, the temperature rose to 104° F., pulse 120, respirations 22, and the patient became stuporous On Nov. 28, the temperature rose to 105 4° F., pulse 160, respirations 12 The bladder was found to be markedly distended. The patient was catheterized and 25 ounces of urine were obtained He was given 3000 c c. of glucose intravenously, and a continuous Harris drip was started. The dressing was changed, moderate drainage found, and one Penrose drain removed. The condition of the patient grew worse, the pulse at times was imperceptible and respirations were 16 per minute (abnormally slow as compared to the rapid pulse and high temperature). Some crepitation was felt in the abdominal wall, a short distance away from the incision. This emphysema may have been an extension from the retroperitoneal site of the duodenal rupture, which

gradually came to the surface. The Levin tube drained bile-colored fluid. The patient was given a transfusion of 400 c.c. of whole blood, 10 c.c. of cortical extract were given intravenously, oxygen was administered, and 5 Gm. sodium sulfathiazole were given intravenously.

Nov. 29, the condition of the patient was poor, but better than the previous day. The temperature was 104.2° F., pulse 140, respirations 13 per minute. The abdomen continued to be soft, with no increased crepitation. Drainage from the Levin tube was less bile-stained and more clear; 10 per cent glucose was given intravenously, tea and water were given by mouth. Oxygen was continued, and cortical extract and 5 Gm. of sodium sulfathiazole were given intravenously.

Nov. 30, his condition took a marked turn for the better. The patient became rational and temperature was down to 101.4° F. in the afternoon. From then on, he continued to improve.

On Dec. 1, he had a chill with a rise of temperature to 105.2° F. which lasted a few hours. This chill was probably nonspecific in origin, and probably due to pyrogens in the intravenous fluids. The blood counts were as follows: On admission, 17,000 white cells and 76 polymorphonuclears. On Nov. 28, the red cells were 5,000,000, hemoglobin 82 per cent, white 14,600, and polymorphonuclears 72. On Nov. 30, red cells 4,150,000, hemoglobin 82 per cent, white 15,600, polymorphonuclears 72 per cent. The clinical course from Dec. 2, to date of discharge, Dec. 12, was uneventful. The temperature (Fig. 3) ranged from 100.5° to 98.5° F., the pulse and respirations were within the normal range. The drain was removed on the sixth day, and sutures were removed on the eighth day, with primary union, except at the site of drainage. The patient was discharged on the seventeenth postoperative day and when last seen, Dec. 29, 1942, was in good health. An x-ray checkup revealed no evidence of any obstruction at the site of injury (Fig. 4). The stomach contents passed freely through the duodenum as evidenced on fluoroscopy. There was slight retention of barium (a few cubic centimeters) at the site of the repair of the rupture.

SUMMARY

1. Rupture of the duodenum may not be recognized until some time after the injury.

2. Vomiting immediately after the injury is due to a reflex contraction of the pylorus with reverse peristalsis, a protective measure in cases of gastrointestinal involvement.

3. Injury to the duodenum may be overlooked during the operation especially if the rupture is extraperitoneal. The emphysema and greenish spots are clues which should lead us to search for such a perforation.

4. The stormy clinical course in this case: Hyperpyrexia, very rapid pulse, and unconsciousness for days, probably was due to the toxic absorption of the duodenal contents that seeped through retroperitoneally.

The introduction of sulfanilamide intraperitoneally and parenterally, together with blood transfusion, and intravenous glucose, intravenous cortical extract, and the administration of oxygen, no doubt were helpful supportive measures to tide the patient over the critical period.

REFERENCES

1. Robertson, Hugh: The Injured Abdomen, Am. J. Surg. 14: 412, 1931.
2. Hinton, Drury: Rupture of the Duodenum by Blunt Trauma, J. Internat. Coll. Surgeons 3: 485, 1940.

TRAUMATIC CHYLOTHORAX—A CASE TREATED WITH INTRAVENOUS CHYLE

EDWARD SCHNUG, M.D., AND JOSEPH RANSOHOFF, M.D.
CINCINNATI, OHIO
(From the Department of Surgery, College of Medicine of the University of Cincinnati, and the Cincinnati General Hospital)

THE treatment of chylothorax by intravenous injection of aspirated chest fluid has been carried out in eight reported cases to date. In 1908, Oeken[1] suggested this form of therapy and reported the first patient thus treated. The results in these cases are as follows: three recovered, three died, and two unchanged. The mortality recently reported by Seoville and Whiteomb[2] was apparently an anaphylactic death. One of the most carefully studied cases is that of Little, Harrison, and Blalock,[3] who observed this disease in a 17-year-old girl for almost two years, with the patient reported as alive but unimproved. They withdrew 550 liters of chylous pleural fluid and gave 23 liters intravenously during a six-month period. Nowak and Barton[4] recently reported a cure of spontaneous chylothorax after eight months by a phrenicotomy.

We wish to report briefly an additional case treated by intravenous administration of the aspirated fluid.

CASE REPORT

W. C., a 23-year-old Negro man, was admitted to the surgical service of the Cincinnati General Hospital shortly after having been shot in the right midclavicular line between the fifth and sixth ribs. He was vomiting and complaining of severe abdominal pain and pain over the dorsal spine. Physical examination revealed a normal man, not in shock, with a rigid, tender abdomen, and point tenderness over the eleventh dorsal vertebra. His white count was 16,000. X-rays showed a large caliber bullet to be lodged in the left posterior portion of the body of the eleventh dorsal vertebra.

Under cyclopropane anesthesia an exploratory laparotomy was performed. A small amount of blood in the peritoneal cavity was seen to have come from a half-centimeter wound in the upper right lobe of the liver. This wound was not bleeding. Although a complete exploration was performed, no other intra-abdominal injuries were found. Approximately 6 Gm. of sulfanilamide were placed in the abdominal cavity and the incision closed without drainage. The bullet wound was excised, cleansed, and closed.

The patient had a smooth postoperative course, taking water by mouth on the third day and an increasing diet thereafter. He received a course of sulfadiazine therapy totaling 54 Gm. over a period of nineteen days.

Received for publication, Jan. 8, 1943.

On the sixth postoperative day the patient developed moderate dyspnea. X-rays of the chest showed a massive right-sided accumulation of fluid and on the seventh day the first thoracentesis was performed. The culture of the fluid as well as that of all subsequent ones proved to be negative. The patient was placed on a fat-free, high protein diet. Following this, as shown on the accompanying chart, thirty-four taps were performed over a period of fifty days with a removal of 56,450 c.c. of chylous fluid. During an interval of twenty-seven days, 16,800 c.c. of this fluid were given to the patient intravenously according to the method described by Smith and Wolivers[5] of this hospital. On occasions, slight chilly sensations formed the only systemic reaction to the injections; no significant change in pulse or blood pressure occurred.

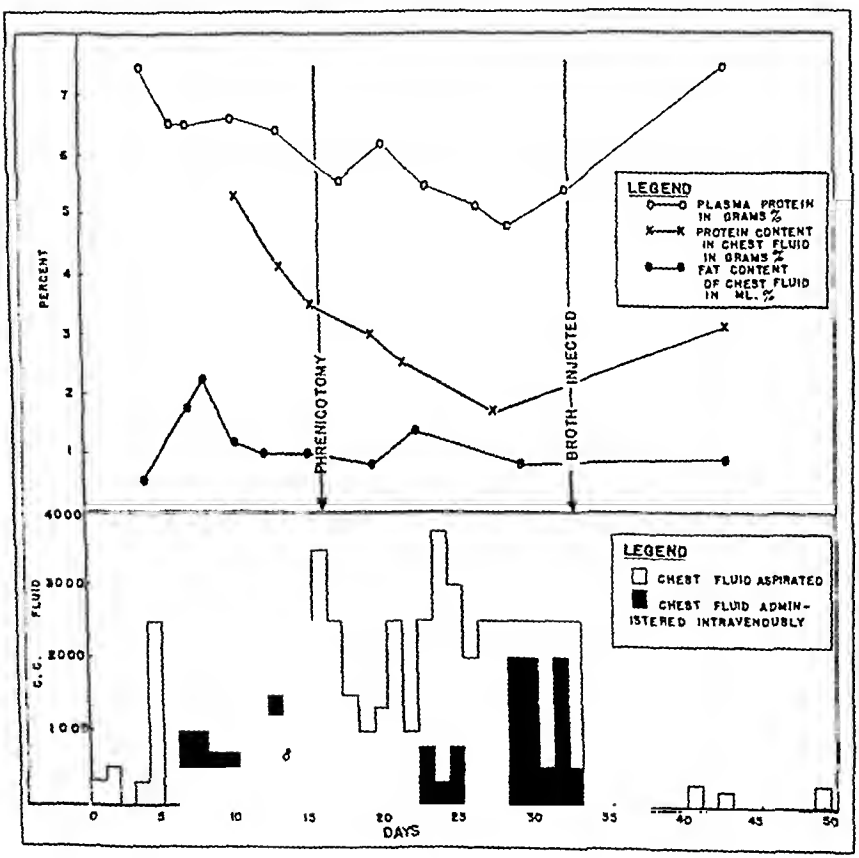

Fig. 1.

On the fifteenth day a right phrenicotomy was performed. Following this there was no apparent decrease in the rate of accumulation of fluid. From the sixteenth to the twenty-ninth days the intravenous therapy was very difficult to maintain because of a phlebothrombosis in all extremities. As can be seen from the chart, the patient's plasma proteins dropped steadily in spite of 1500 c.c. of blood plasma administered by hypodermoclysis.

On the twenty ninth day and thereafter, at the suggestion of Louis G. Herrmann, heparin was used as an anticoagulant rather than sodium citrate. The heparin was

added in the ratio of 4 mg. to each liter of chest fluid. In the next five days it was possible to administer 7000 c.c. of chest fluid intravenously. The patient's plasma proteins rose towards normal levels (Fig. 1).

In spite of the patient's improved condition, there was no apparent decrease in the rate of collection of chylous fluid in the chest. It was therefore decided to inject 50 c.c. of sterile broth into the pleural cavity in order to stimulate a fibrinous reaction, as reported by Reinhoff,[2] and thus seal off the leaking duct. However, when attempting to aspirate as much fluid as possible before injecting the broth, only 2500 c.c. could be obtained. Previous to this date over 3500 c.c. had been withdrawn without the development of respiratory embarrassment. The broth was injected in spite of this sudden significant improvement. After the injection of the broth there was no leucocytic or temperature response to indicate a pleuritic reaction.

Following this day, there was apparently a complete cessation of leakage from the duct and small amounts of fluid were aspirated in order to hasten the re-expansion of the lung. The patient recovered completely.

DISCUSSION

This case demonstrates the efficacy of replacing the protein and fat lost into the chest cavity in chylothorax by intravenous administration of the aspirated chyle. In the interval between the sixteenth and twenty-ninth days, when there was a great disproportion between the amount of fluid withdrawn and that given intravenously, there occurred a precipitous drop in plasma proteins. Once this disproportion was wiped out, the plasma proteins again rose toward normal levels.

In spite of absence of untoward reactions in our patient, it is probably wise to take special precautions when first reinjecting the chylous fluid. A skin test with the fluid, as well as very slow injection of small amounts intravenously, should probably be carried out. It has also occurred to us that the size of the fat droplets may be important in the production of deleterious side effects.

The use of heparin as an anticoagulant in the fluid to be injected appears to be a valuable adjunct in the treatment of these patients. Blalock and co-workers[3] reported the extension of a pre-existing thrombophlebitis in their case on the administration of aspirated chyle. This complication was also the limiting factor in the intravenous replacement therapy in our patient until heparin was substituted for sodium citrate. The phlebothrombosis evoked by the fluid was then definitely decreased.

The injection of sterile broth or other fibrinogenic agents into the chest cavity may be of value in sealing off the leaking duct. It is unfortunate that in this instance the instillation of broth was carried out coincident with the apparently spontaneous cessation of the leak.

In our case neither diet nor phrenicotomy had any noticeable effect on the course of the disease. It is impossible, however, to predict what would have been the outcome here if these procedures had been omitted.

SUMMARY

The intravenous replacement of chylous fluid aspirated from the pleural cavity in cases of chylothorax represents a physiologic method of maintaining these patients. Energetic attempts toward these ends are indicated while other therapeutic measures are being carried out.

REFERENCES

1. Oeken: München. med. Wchnschr. 55: 1182, 1908.
2. Scoville, W. B., and Whitcomb, B. B.: Arch. Surg. 45: 747, 1942.
3. Little, J. M., Harrison, C., and Blalock, A.: SURGERY 12: 392, 1942.
4. Nowak, S. J. G., and Barton, P. N.: J. Thoracic Surg. 10: 628, 194
5. Woliver, E., and Smith, D.: Arch. Surg. 43: 327, 1941.
6. Reinhoff, W.: Bull. Johns Hopkins Hosp. 53: 390, 1933.

CARCINOMA OF THE PARATHYROID GLAND

KARL A. MEYER, M.D., F.A.C.S., AND ALEX B. RAGINS,* M.D.
CHICAGO, ILL.

(From the Surgical Service of Karl A. Meyer, the Department of Surgical Pathology, Cook County Hospital, and the Cook County Graduate School of Medicine, Chicago)

CARCINOMA of the parathyroid gland is rare. Although a number of cases have been reported,[1] the diagnosis of carcinoma of the parathyroid gland is questionable in view of the fact that the blood chemistry and x-ray examinations in these cases have been incomplete or have failed to show the characteristic changes. In some instances, however, one may concede the diagnosis of a carcinoma of the parathyroid gland, as reported by Petersma[2] and Sainton and Millot,[3] although no follow-up of their cases has been submitted in the literature.

Hall and Chaffin[4] have reported the autopsy findings on a case diagnosed as carcinoma of the parathyroid gland[1] which they have observed for six years. However, in view of their incomplete blood chemistry work-up and incomplete examination of the bones at autopsy, one hesitates to accept the final diagnosis of carcinoma of the parathyroid gland.

In a previous publication[1] we have had the opportunity to present a case of a diffuse fibrocystic disease of the bone due to a carcinoma of the parathyroid gland; the patient's response to surgical and medical management was reported. We would like to report now the complete clinical course of the patient and the post-mortem findings.

CASE REPORT

The following history is a brief abstract of the case up to September, 1938,[1] and the subsequent course of the disease until the patient's death on Dec. 24, 1940.

J. H., a white Greek man, was admitted to the Cook County Hospital on Oct. 8, 1937, at which time he presented clinical, laboratory, and x-ray findings diagnostic of hyperparathyroidism and diffuse fibrocystic disease of the bone (Table I and Fig. 1, *A*). In addition, calculi were observed in both renal pelves.

Following the extirpation of the tumor of the right parathyroid gland in October, 1937, there was a distinct relief from the subjective symptoms associated with a normal serum calcium and slight recalcification of bone. However, the relief from the subjective symptoms was temporary, and in March, 1938, the patient began to complain of recurring pain in the bones. In July, 1938, the patient had his right fifth finger amputated. At that time blood chemical analysis revealed a hypercalcemia and a hypophosphatemia, but the x-ray findings showed definite areas of recalcification in the bones (Fig. 1, *B*). At that time, too, a hard nodule about

*Major, Medical Corps, Army U. S., 297th General Hospital, Temple, Texas.
Received for publication, Dec. 31, 1942.

3 cm. in diameter was noted in the region of the right lobe of the thyroid fixed to the right jugular vein and carotid artery.

In view of the recurrent nodule fixed to the major blood vessels and failure of the patient to improve, he was readmitted to the hospital on Oct. 19, 1938, for further observation and x ray therapy. He received approximately 3,000 r. through each of the three ports over the lateral and anterior aspect of the neck. He received weekly treatments of about 250 r. per treatment over a period of eight

A. B. C.

Fig. 1.—A, X-rays of the right radius and ulna showing the fibrocystic changes in the bone prior to surgical removal of the parathyroid tumor in the latter part of 1937. B, Eleven months postoperatively, showing tendency toward recalcification. C, Showing exaggerated fibrocystic changes of the right ulna and radius two years postoperatively, due to the persistent action of the recurring parathyroid carcinoma

months. In addition, he received about 3,200 r. to his right wrist and both legs. The factors used were 200 KVP, 25 Ma., 50 and 62 cm. skin target distance, ½ mm. copper and 1 mm. aluminum filter, 0.9 c cm. half value layer. The size of the ports was approximately 25 sq. cm.

Following the induction of x ray therapy the patient left the hospital, only to return the following April, and for the last time in October, 1939. At this time a physical examination revealed a poorly nourished, poorly developed white man, who appeared ill. The blood pressure was 122/70; temperature, 98.6° F.; pulse, 76; respiration, 20. Teeth were in poor condition. The thyroid was not palpable, but

TABLE I

DATE	SERUM CALCIUM (MG. PER 100 C.C. N-9 TO 11)	SERUM PHOSPHORUS (MG. PER 100 C.C. N-3.5 TO 5)	PHOSPHATASE (BODANSKY UNITS)	VARIATION
10/21/37	16.1	3.1	22.0	Urea N., 21
10/26/37	15.1	3.0		Blood sugar, 75
10/27/37	10.1			Tumor removed
11/11/37	8.0			Calcium lactate, 30 gr. t.i.d.
11/18/37	9.1			
11/22/37	9.1	3.0		
11/27/37	9.1			
12/ 8/37	9.0	2.4		Calcium lactate 10 gr. b.i.d.
6/ 8/38	12.9	1.99		
8/11/38	12.86	1.45	7.5	Pains return
11/18/38	15.05	2.05	7.8	N.P.N., 32
1/ 5/39	14.65	2.38	9.7	Total proteins, 7.9%
2/20/39	14.65	4.31	13.1	Total proteins, 7.2%
10/23/39	13.66	3.13	27.6	Urea N., 27.5
4/ 7/40	14.31	2.70		
6/13/40				Total proteins, 5.72%
11/14/40	13.70	10.00	40.0	

a hard, stony mass in the right side of the neck at its mid-portion and beneath the sternocleidomastoid muscle was palpable.

There was a marked deformity of the chest and the lower half of both anterior chest walls (Fig. 2). The left fifth to ninth ribs felt as if they were matted together. Expansion was poor bilaterally with distinct dullness over the lower half of the right and left chest wall posteriorly. Tactile fremitus and breath sounds were diminished over these areas.

The abdomen was scaphoid. The liver, kidneys, and spleen were not palpable. On rectal examination a small, hard nodule over the left lateral lobe of the prostate was palpated.

The left upper extremity showed a fracture through the left humerus and a marked fusiform swelling of the ulnar bone of the right forearm (Fig. 1, *C*). The right lower extremity revealed an almond-sized mass over the anterior upper third of the tibia, which was of a stony consistency. Beneath this was a soft mass involving the bones. The left leg showed an area of diffuse induration, swelling, and tenderness just below the knee joint. A distinct orange-sized mass in the medial side of the upper third of the tibia was also noted.

Blood chemistry analysis at the time of the last admission revealed a hypercalcemia, hypophosphatemia, and an increase in phosphatase (Table I). The patient was semiambulant and remained in the hospital. During his stay he fell while attempting to leave a wheel chair and sustained a fracture of the left tibia and fibula.

This fracture confined the patient to bed, where he remained up to the time of his death. While confined to bed he began to complain of pain in the left hip. A portable x-ray revealed a pathologic fracture of the left femur.

The condition of the patient became progressively worse and he developed generalized pain and moist râles in the chest. On Dec. 24, 1940, the patient died, approximately three years and eight months after the onset of illness.

The autopsy done by one of us (A. B. R.) revealed the following important autoptic findings.

External Findings.—The body was that of an emaciated white man. Over the neck was a healed surgical transverse scar measuring 12 cm. The right sternocleidomastoid muscle was more prominent than the left, and in the mid-portion an

irregular firm mass was palpated which seemed adherent to the underlying structures. The teeth were carious in the upper jaw and absent in the lower jaw. Both clavicles were prominent, the left being greater than the right, with a distinct bowing. The chest was deformed and there were numerous prominences beneath the skin, extending over all the ribs. The abdomen was retracted three fingerbreadths below the level of the chest. Finger tips were slightly cyanotic. The lower portion of the right ulna showed distinct bulging over the dorsal, lateral, and volar surface, measuring 7 by 3 by 5 cm. The right little finger was missing (amputated

Fig. 2.—Chest x-ray showing extensive fibrocystic changes in the ribs and area of increased density of the lungs and marked deformity of the chest.

at the carpal-phalangeal joint). On twisting the right leg a distinct crepitus was elicited at about the middle of the right femur. A similar crepitus was elicited at the upper third of the left femur. On the medial aspect of the left knee was an ancient 5 cm. scar. Both tibiae showed irregular nodular processes extending above the surface of the bone. The skin over the legs was edematous, and on movement the crepitus feeling was elicited through the mid-portion of the left tibia. The skin over the legs was brown gray and edematous. The left leg was shorter than the right by 4 cm. In the right lower quadrant was an ancient healed 10 cm. herniotomy wound.

Internal Findings.—Lungs: The *right lung* was crepitant to subcrepitant throughout. The surface was smooth, light purple gray to pink gray and at the apex were small fibrous tags. The free surface lower lobe contained single nodes measuring from 2 to 4 mm. in diameter. The free surface of these nodes was light purple gray and extended buttonlike above the surface of the pleura (Fig. 3). On section

the node extended into the parenchyma for 3 mm., light purple gray mottled by opaque areas of gray white. The sectioned surface of the right lung was light purple gray. The mucosa of the bronchi was pale purple gray and smooth.

The *left lung* was dark purple gray, crepitant in the upper lobe and subcrepitant in the lower lobe. The surface was studded by nodes measuring from 0.4 to 2.5 cm. in diameter and pink tan gray in color (Fig. 3). On section these nodes were similar to those described in the right lung. The sectioned surface of the upper lobe was purple red and contained a small amount of frothy bloodstained fluid. The lower lobe was dark purple gray and contained small granular areas of consolidation. In the middle lobe the mucosa of the bronchi was purple red and covered by a small amount of bloodstained mucoid material. The mucosa of the trachea was pink gray, smooth and shiny.

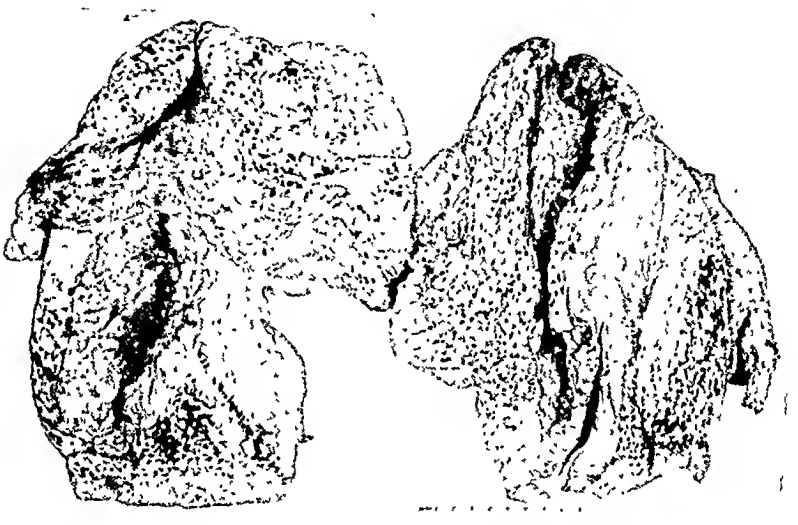

Fig. 3.—Lungs showing nodular buttonlike metastases of parathyroid tumor tissue of the pleural surfaces of the lungs.

Thyroid: The thyroid measured 5 by 3.5 by 1 cm. The left lobe was light purple gray tan. In the upper pole was a small oval-shaped nodule within the capsule measuring 4 by 3 by 1 mm. (Fig. 4, *D*). The left lobe of the thyroid measured 3 by 2 by 1 cm., was considerably firmer than the right, was purple gray, and on section was light pink gray.

Lymph Nodes: Adherent to the right jugular vein (Fig. 4, *B*) and compressing it from the posterior aspect was a firm mass measuring 3.5 by 2.5 by 2 cm. On section it was firm, gray white and in places distinctly calcified. The left subclavicular lymph node and peritracheal lymph node (Fig. 4, *C*) were enlarged up to 2 cm. On section this was light purple gray and in places centrally liquefied and partially calcified. The periaortic lymph node measured up to 2.5 cm.; on section it was purplish gray. The iliac lymph node measured up to 2.5 cm. and on section it was purple gray. The left iliac lymph node measured up to 1.5 cm. and was purple gray mottled by areas of red gray.

Kidneys: The kidneys, together, weighed 480 Gm. The *right kidney*, 180 Gm., measured 12 by 7.5 by 3.5 cm. The capsule stripped with ease. The surface was light purple gray, finely and coarsely gray. Over the convex surface of the kidney was a superficial depression 2 by 1.5 cm. and a darker brown gray. The cortex, up to 8 mm., was purple tan gray, with indistinct markings. The pelvis was slightly dilated; the upper calix was filled with small urinary concretions measuring

from pin point to 3 mm. in diameter. The lower and middle calix and pelvis were occupied by an irregular staghorn stone measuring 3 by 1.5 by 3.5 cm. In the lower pole of the kidney extending above the surface was a small gray white nodule, 4 mm., which extended into the parenchyma for a distance of 3 mm. (Fig. 5).

Fig. 4.—*A*, Showing the marked fibrocystic changes of the vertebrae. *B*, Perijugular lymph nodes contain tumor tissue with areas of calcification. *C*, Peritracheal lymph node showing metastases of tumor. *D*, Nodule in upper pole of lobe of thyroid showing invasion into the cricothyroid muscle.

The *left kidney* weighed 300 Gm. and measured 13.5 by 7 by 7 cm. The capsule was markedly adherent. The cortex in the upper pole was reduced to 1 mm., and the lower pole varied from 3 to 4 mm. The upper pelvis is markedly distended and filled by a creamy yellow purulent material (Fig. 5). The mucosa was pale purple gray, mottled by thicker areas of bright light yellow. The lower portion of the pelvis and its respective calices were occupied by a huge staghorn stone measuring 7 by 1.5 by 4.5 cm. and were brown gray and very firm. In addition, there were several facetted brown-gray stones with granular surface measuring 1 cm. in the greatest dimension.

The urinary bladder was filled by green gray to yellow-gray urine. The mucosa was purple gray mottled by pin-point to 3 mm. sized vesicles filled with a slightly cloudy fluid and surrounded by a distinct brown-gray zone.

The prostate measured 4 by 5.5 by 4.5 cm. On section it was diffuse light purple, tan gray. In the right lateral lobe was a small irregular zone, 2 cm. in its greatest dimension, which was greenish gray.

Bones: All *ribs* were exceedingly fragile. These foci on section showed a soft red-gray medullary canal. There was a slight right-sided scoliosis of thoracic vertebrae, and practically all vertebrae, particularly the lumbar, show a marked thinning of cortex, and the medullary portion was composed of soft, purple-gray tissue (Fig. 3, *A*).

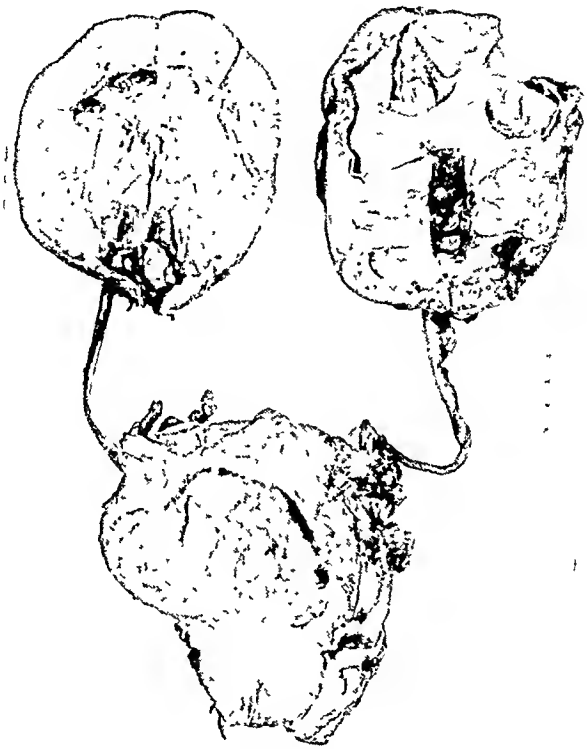

Fig. 5.—Showing bilateral renal calculi and a left-sided pyonephrosis of the left kidney and tumor metastases in the lower pole of right kidney as indicated by arrow

The *right femur* showed a tremendous destruction of the cortex. The muscle tissue about the fracture area was infiltrated with blood. The cortex of the bone cut with very little resistance. The pelvic bone cut like butter, and the bone marrow cavity likewise was filled with purple-gray tissue.

The *left tibia*, at the site of fracture, showed a marked destruction of the cortex, the periosteum in this region was thickened and on scraping away left a roughly granular, yellow-gray to purple-gray surface. At the site of fracture the cortex was easily cut and the bone marrow appeared purple red. The lower third of the right ulna showed similar changes in the bone as described previously.

Practically the entire *sternum* was replaced by a soft, purple-red marrow mottled by areas of yellowish gray. The cortex in places was markedly thinned.

The spinous processes of thoracic and lumbar vertebrae were completely transformed into a reddish purple-gray mass.

The skull measured 18 by 14 cm.; the average thickness was 7 mm. The inner aspect was purple gray and granular. The bone was somewhat flexible and sawed

with ease. The sphenoid bone and the petrous portion of the temporal bone were purplish gray, and the consistency was markedly diminished.

Microscopic Examination.—Sections were made of all organs and the following are some of the pertinent findings.

Urinary Bladder: The transitional cell layer of the mucosa of the urinary bladder was markedly flattened and in places was missing. In some areas there was a slight downgrowth of the epithelial cells forming small nests of cells with oval-shaped nuclei and pale-staining vacuolated cytoplasm. Some of these nest cells were distinctly calcified. The submucosa was heavily infiltrated by round cells and plasma cells, and in places the submucosa was composed almost entirely of discrete nests of lymphocytes with single histiocytes filled with golden brown pigment and a few dilated blood vessels. The muscle bundles of the muscular layer were widely separated by edematous connective tissue and did not show any inflammatory changes.

Prostate: The *right lateral lobe* of the prostatic gland showed a moderate hypertrophy and hyperplasia of the epithelial cells lining the gland and in places showed papillary proliferations into the lumen which were filled and distended by numerous polymorphonuclear leucocytes. The fibromuscular stroma about these infected glands was infiltrated with lymphocytes, plasma cells, and polymorphonuclear leucocytes. In other areas the hyperplastic glands were not infected.

Kidney: In the *left kidney* many of the glomeruli were intact and of normal size. Others showed a slight to moderate thickening of Bowman's capsule. Still others, on the other hand, showed a partial to complete hyalinization of the glomerular tufts and glomeruli. The proximal and distal convoluted tubuli were dilated and in places filled with amorphous debris. The epithelial cells showed a slightly cloudy swelling and in places a moderate atrophy of the cell. Scattered throughout the cortex were small areas in which the tubules were widely separated by dense fibrous connective tissue proliferations which were occasionally infiltrated by round cells. The interstitial capillaries, arterioles, and venules were moderately dilated.

Throughout the section, both in the convoluted tubuli and in the collecting tubuli, were minute deposits of bluish-staining calcium material. Not infrequently, similar calcium deposits were seen in the interstitial connective tissue (Fig. 6, *B*). The epithelial lining in some of the collecting tubules was dissociated and filled the lumen. The larger blood vessels are slightly thickened.

The description of the *right kidney* was similar to that of the left, except for the fact that the small nodule described grossly in the lower pole of the kidney was composed of small nests and cords of cells containing large, irregular, hyperchromatic vesicular nuclei (Fig. 4, *C*). These nuclei were round to oval in shape. Occasionally, they were elongated and slightly indented. The chromatin granules were fairly coarse and in places appeared to be lodged on thin chromatin threads radiating toward the eccentric center of the nucleus where often a distinct nucleolus was discernible. The cell membrane was fairly distinct. The cytoplasm of most of the cells was pinkish staining and finely granular. Some cells possessed a clear nonstaining cytoplasm (Wasserhelle cells). The nuclei made up two-thirds of the diameter of the cell. These nests and cords of cells were widely separated by dense fibrous connective tissue strands which were slightly edematous and were continuous with a semiformed capsule separating the cortical renal parenchyma from the tumor nodule. However, within the capsule were single cords of the previously described cells. In the outer portion of the capsule were also present several atrophic tubuli.

Lungs: The tumor nodules found on the pleural surface of the lung as well as the one located beneath the pleura were composed of cords and nests of polygonal shaped large cells with round to oval-shaped vesicular nuclei (Fig. 6, *D*). Some of them stained rather deeply with hemalum. The cytoplasm of the greatest number of cells was pinkish staining and granular. Occasionally the cytoplasm was clear

and unstained, thus resembling water-clear cells. The cords and nests of cells were separated by thin fibrous connective tissue bands containing dilated capillaries filled with blood. The center of some of the cell nests were centrally necrotic, and occasionally a slightly atypical mitotic figure was seen. The tumor nodules in places appeared to be definitely surrounded by a thin connective tissue capsule which slightly compressed the adjacent alveolar structures of the lung. The alveolar

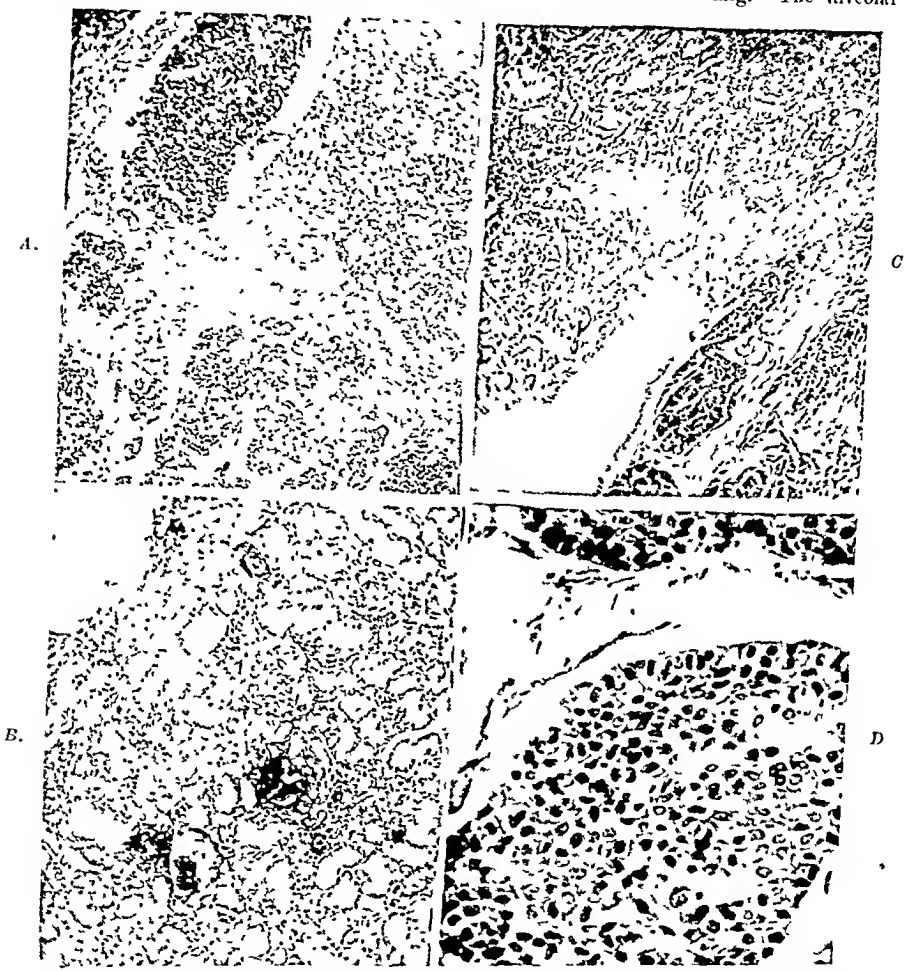

Fig. 6.—*A*, Metastasis of carcinoma of parathyroid to lymph node (magnification ×100). *B*, Nephrocalcinosis of kidney (magnification ×100). *C*, Metastasis of carcinoma of parathyroid to kidney (magnification ×100). *D*, Metastasis of carcinoma of parathyroid to lung (magnification ×440).

septal capillaries were slightly dilated. In places the small bronchioles were filled with desquamated epithelial cells and a few polymorphonuclear leucocytes. About the subpleural nodule the interstitial tissue in the region of the tumor metastases was widely thickened and infiltrated by polymorphonuclear leucocytes. In one area a large lymphatic vessel was obstructed by the tumor thrombus, as were some of the veins.

Lymph Nodes: The normal architecture of the *peritracheal* lymph node was altered, particularly at the periphery of the node, by large nests of tumor cells (Fig. 3, *A*) similar to those described in the lung. These tumor cells were in the

form of tumor thrombi filling the peripheral sinusoids and extending for a short distance into the cortical sinusoids. These cells were chiefly of the eosinophilic cell type. Occasionally a water-clear cell type was seen. The capillaries of the lymph node were dilated and filled with blood. The pulp was predominantly lymphocytic, although the sinusoids showed slight proliferation of the reticulum cells.

The periaortic, inguinal, and peripancreatic lymph nodes revealed a uniform picture characterized by lymphocytic hyperplasia of the germinal follicles which seemed to merge with the rest of the cortical and medullary stroma. The sinusoids appeared to be markedly dilated and filled by proliferated endothelial cells lining the sinusoids The cytoplasm of many of the cells was vacuolated and the nuclei were eccentrically placed. In addition, a few polymorphonuclear leucocytes and eosinophiles were seen in the sinusoids. The trabeculae were thickened, as was the capsule of the lymph node.

The left retroclavicular lymph node was completely replaced by anastomosing cords and nests of polyhedral cells, most of them containing granular eosinophilic cytoplasm. Occasionally the cytoplasm of some of the cells was water clear in character. The nuclei were large, round, oval, or elongated and distinctly vesicular. The chromatin was deeply staining and coarsely granular. These cells in places appeared to form rosettes in which the nuclei were markedly elongated and slightly lighter staining. Mitotic figures were seen but occasionally. These cords and nests of cells were surrounded by thick fibrous hyaline connective tissue bands in which were small nests of tumor cells, some of them lying within lymphatic spaces. In addition, there were scattered deposits of calcium, particularly about the blood vessels. The outer portion of the capsule of this mass was covered by fat. Between the anastomosing cords of tumor cells were thin walled dilated blood vessels and focal extravasations of blood

Left Parathyroid Gland: The left parathyroid gland revealed small nests of pale pink staining cells with relatively ample cytoplasm surrounded by irregular nests of cells whose nuclei were markedly hyperchromatic and surrounded by small amounts of pale staining cytoplasm with indistinct cell membranes and bands of fibrous connective tissue (Fig. 7, *C*).

Testicles: The left testicle showed marked atrophy of the seminiferous tubules The cells for the most part were devoid of their nuclei and the cytoplasm of these was homogeneously pink staining The interstitial tissue was small in amount and slightly edematous In places there were small to large accumulations of Leydig cells, some of them containing a brownish pigment. The right testicle showed the seminiferous tubule in a somewhat better preserved state but definitely atrophic In the interstitial tissue there were larger accumulations of Leydig's cells.

Hypophysis The anterior lobe was composed of numerous eosinophilic cells arranged in small cords and occasional alveoli. In the alveoli were small accumulations of a pinkish blue staining colloid In the periphery of the anterior lobe and near the middle lobe there was a greater accumulation of basophilic and chromophobe cells which assumed an alveolar formation. The posterior lobe appeared normal histologically The pars media contained few dilated cysts filled with a bluish material There was no evidence of basophilic cell invasion of the pars posterior.

Adrenal The cortex revealed that the cytoplasm of the reticular and fascicular layer cells was markedly vacuolated and relatively rich in lipoids, whereas the stratum granulosa cells had a homogeneous pink staining cytoplasm. In one area there was a diffuse hyperplasia of the cortex In this area the capillaries were slightly dilated The medulla was composed of a normal number of large polygonal cells with dilated blood vessels

Microscopic section of the thyrohyoid muscle revealed bundles of striated muscle which were superficially infiltrated by nests of tumor cells (Fig 7, *D*) similar to

those described in the left retroclavicular mass. The major portion of the tumor mass, however, appeared to lie on the surface of the muscle.

The node about the jugular vein was composed of large nests of tumor cells similar to those described in the left retroclavicular mass. These nests were arranged in small anastomosing cords and were suggestive of small acini, some of them containing a pink-staining colloid material and others containing desquamated

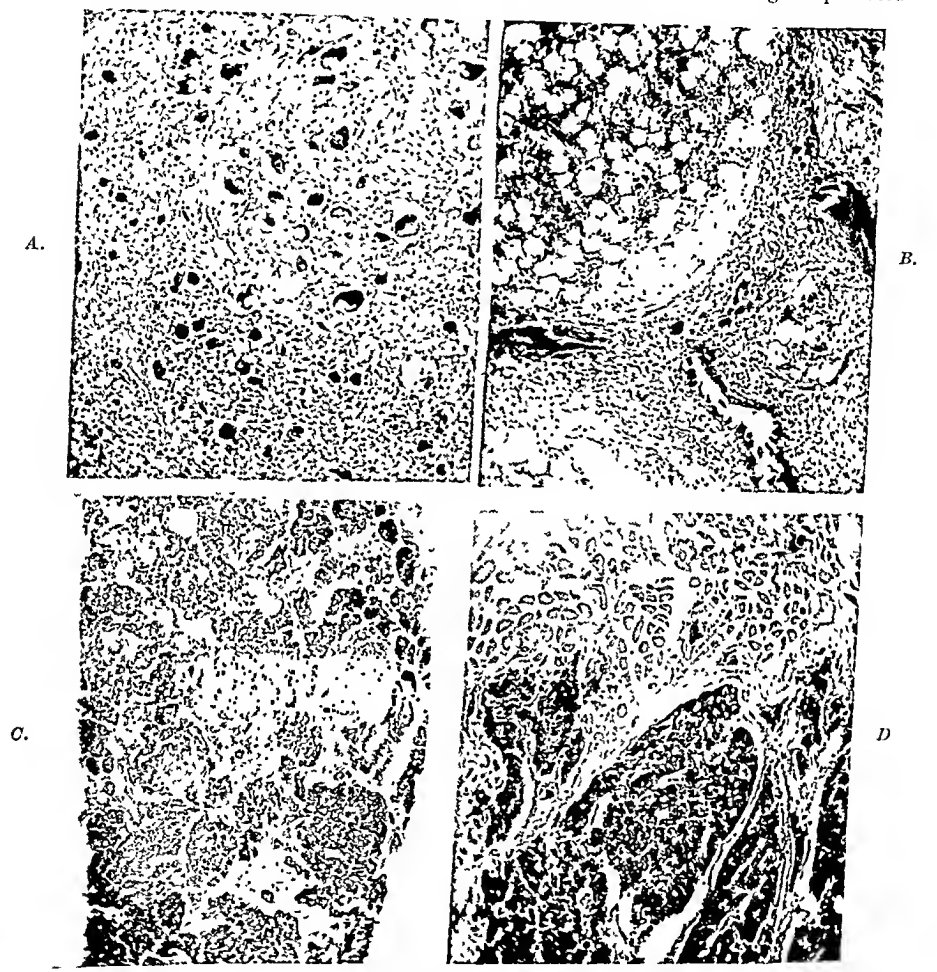

Fig. 7.—*A*, Spinous process of cervical vertebra showing severe fibrocystic changes of bone. *B*, Rib, showing active hematopoiesis and partial fibrocystic changes. *C*, Parathyroid gland from left side of neck showing nests of pale-staining eosinophilic cells. *D*, Infiltration of muscle tissue of neck adjacent to the cricoid bone.

tumor cells. These tumor cell nests were separated by wide bands of connective tissue, some of which were distinctly hyalinized. In other places the fibrous connective tissue bands contained small solid nests of tumor cells. Attached to the outer layers of the dense fibrous connective tissue were islands of fat which were infiltrated by small nests of tumor cells. Similar accumulations were seen about the blood vessels.

Bones: Sections of bone taken from the skull, temporal bone, middle and internal ear, right and left femur, right tibia, right ulna, ribs, skull, and spinous processes of the cervical vertebrae (Fig. 7. *A*) showed, for the most part, rather

uniform changes, except for the ribs, which will be described as to variations. The bone structures were replaced by a loose proliferating fibroblastic tissue which in places contained numerous giant cells, which, in turn, contained as many as fifteen to twenty oval-shaped, deeply staining, rather small nuclei. The chromatin of these nuclei was rather vesicular. The cytoplasm was rather homogeneous, deeply pink staining. Here and there were seen spicules of bone, some of them surrounded by large numbers of osteoblasts. Other spicules seemed to show atrophy and were surrounded by a few osteoclasts.

In the rib fibrosis of bone marrow spaces and atrophy of the bone were the predominating characteristics. Only a few scattered giant cells were seen. In the central portion of the rib there was still present active hematopoiesis (Fig. 7, *B*). The cortex of the bones was destroyed in all instances by the fibrous connective tissue proliferation. The stroma in all bones contained large focal areas of extravasations of blood. The petrosal portion of the temporal bone showed extensive rarification of the compact bone surrounding the cochlea. The giant cells in these areas of fibrosis lay adjacent to the bone spicules.

The final diagnosis reached then was recurrent carcinoma of the parathyroid gland, with metastases to the peritracheal, subclavian, and perijugular lymph nodes and to the lungs and right kidney; diffuse osteitis fibrosis cystica involving practically all the bones in the body; multiple pathologic fractures of the right and left femurs and the left tibia; bilateral nephrolithiasis, nephrocalcinoses; chronic ascending bilateral pyelonephritis and pyonephrosis of the left kidney, with severe atrophy of the parenchyma; chronic purulent cystitis and cystitis cystica; atrophy of the testicles with proliferation of the Leydig cells; marked edema of the leptomeninges; and cortical adenoma of the left adrenal gland.

DISCUSSION

The opportunity presented in doing a complete post-mortem examination in this unusual case proved that we were dealing with a malignant parathyroid tumor. In addition there were several other interesting findings which supported the clinical diagnosis.

The blood chemistry findings (Table I), although they showed a definite improvement in the blood calcium and phosphatase values, after a period of time (about 8 months after the removal of the tumor surgically) began to show higher values.

The blood phosphorus was almost always below the normal value, except for five weeks prior to the patient's death, when it rose to the unusual high of 10 mg. per 100 c.c. This finding was rather important in so far as it pointed to the fact that renal decompensation, independent of the previously existing malignant tumor of the parathyroid gland, had set in and had already induced a secondary parathyroid hyperplasia, as characterized by the slight enlargements of the parathyroid glands on the opposite sides with hyperplasia of the chief cells (Fig. 7, *C*). Johnson[5] reports similar findings in a case of a benign adenoma of the right lower parathyroid gland. In his case, however, hypertension associated with a severe arteriosclerosis presented itself, whereas in our case, despite the apparent renal decompensation, apparently due to nephrolithiasis associated with hydronephrosis, hypertension was not present.

those described in the left retroclavicular mass. The major portion of the tumor mass, however, appeared to lie on the surface of the muscle.

The node about the jugular vein was composed of large nests of tumor cells similar to those described in the left retroclavicular mass. These nests were arranged in small anastomosing cords and were suggestive of small acini, some of them containing a pink-staining colloid material and others containing desquamated

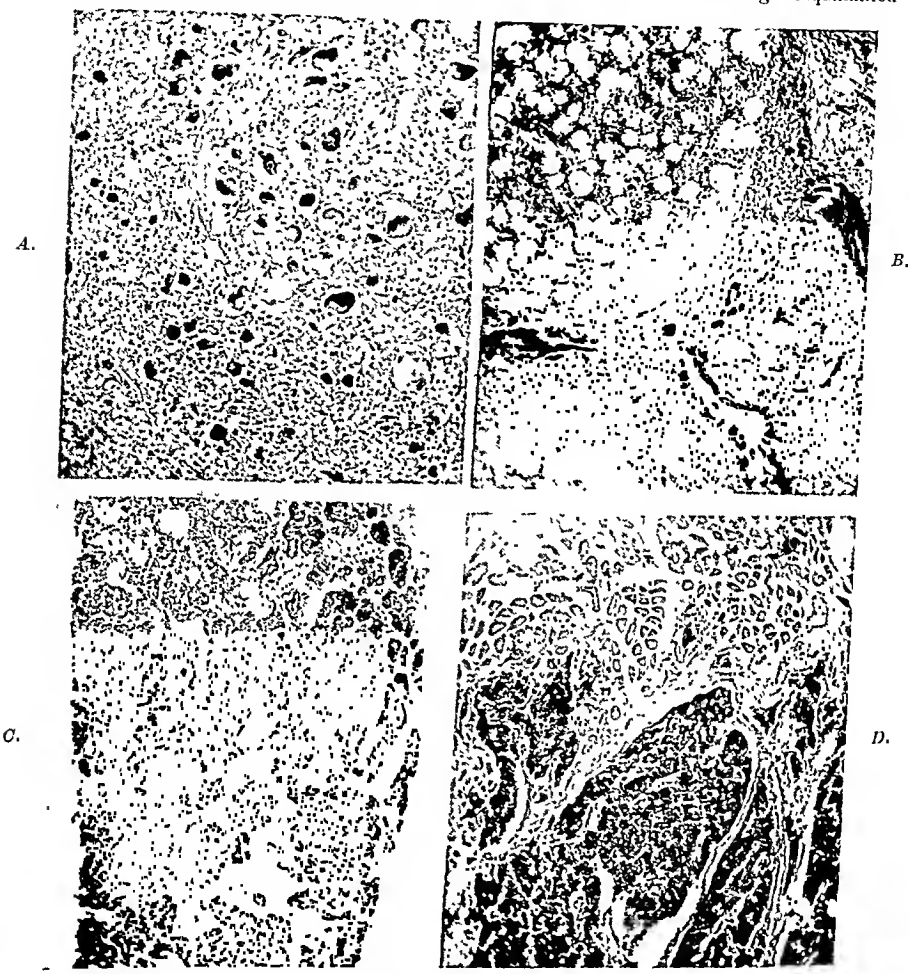

Fig. 7.—*A*, Spinous process of cervical vertebra showing severe fibrocystic changes of bone. *B*, Rib, showing active hematopoiesis and partial fibrocystic changes. *C*, Parathyroid gland from left side of neck showing nests of pale-staining eosinophilic cells. *D*, Infiltration of muscle tissue of neck adjacent to the cricoid bone.

tumor cells. These tumor cell nests were separated by wide bands of connective tissue, some of which were distinctly hyalinized. In other places the fibrous connective tissue bands contained small solid nests of tumor cells. Attached to the outer layers of the dense fibrous connective tissue were islands of fat which were infiltrated by small nests of tumor cells. Similar accumulations were seen about the blood vessels.

Bones: Sections of bone taken from the skull, temporal bone, middle and internal ear, right and left femur, right tibia, right ulna, ribs, skull, and spinous processes of the cervical vertebrae (Fig. 7, *A*) showed, for the most part, rather

tive and subjective symptoms following extirpation of the tumor mass some twenty-six months before death. Eight months following the operation, the subjective symptoms reappeared, and a year later the fibrocystic changes of the bone became progressively worse, despite x-ray irradiation to tumor mass and bone. This was followed by a number of pathologic fractures. Six weeks before death the serum phosphorus rose to 10 mg., indicating renal decompensation.

The essential findings of the post-mortem examination were as follows: recurrent carcinoma of the parathyroid gland with metastasis to the peritracheal, subclavicular, and perijugular lymph nodes, the lungs, and the right kidney; generalized osteitis, fibrosis cystica of the bones; bilateral nephrolithiasis, bilateral chronic ascending pyelonephritis, left pyonephrosis with atrophy of the renal cortex and nephrocalcinosis.

REFERENCES

1. Meyer, K. A., Rosi, P. A., Ragins, A. B.: Carcinoma of the Parathyroid Gland, SURGERY 6: 190-200, 1939.
   Hall, E. M., and Chaffin, L.: Malignant Tumor (Adenoma) of the Parathyroid Gland, West. J. Surg. 42: 578, 1934.
   Guy, C. C.: Tumor of the Parathyroid Gland, Surg., Gynec. & Obst. 48: 557, 1929.
2. Petersma, J. P.: Een Genal von Ziekte von Recklinghausens (osteitis fibrosa cystica generalisata) met clinichse genezing na Verwizdering van een Maligna Adenoom von Byschildklier, Nederl. tijdschr. v. geneesk. 81: 2225, 1937.
3. Sainton, P., and Millot, J. S.: Degenerescence maligne d'un adenome Parathyroidien eosinophile on cour d'un maladie de recklinghausen, Ann. d'anat. path. 10: 813, 1933.
4. Hall, E. M., and Chaffin, L.: Final Report of a Case of Malignant Adenoma of the Parathyroid Gland, West. J. Surg. 48: 685, 1940.
5. Johnson, J. W.: Primary Hyperthyroidism With Extensive Renal Calcification and Secondary Hyperplasia, Am. J. Path. 15: 111, 1939.
6. Brindle, H. D., and Herman, N. G.: Diffuse Calcification Deposits Outlining the Kidney Lobules, Associated With Parathyroid Adenoma, Am. J. Roentgenol. 41: 601, 1939.
7. Albright, F., and Aub, B.: Renal Lesions in Hyperparathyroidism, J. A. M. A. 102: 1276, 1934.
8. Anderson, W. A. B.: The Renal Lesion in Hyperparathyroidism, Endocrinology 24: 372, 1939.
9. Bergstrand, H.: Tumors of the Parathyroid Gland, Acta chir. Scandinav. 85: 25, 1941.
10. Castleman, B., and Mallory, T.: The Pathology of the Parathyroid Gland in Hyperparathyroidism, Am. J. Path. 11: 1-72, 1935.
11. Rappaport, F. G.: Contribution to the Study of Osteitis Fibrosa, Vestnik Khir. 16: 271, 1929.
12. Huguet, E.: Un cas de maladie fibro-kystique de recklinghausen avec presentation de malade, Bull. et mém. Soc. de radiol. méd. de France 20: 82, 1932.
13. Schmayer, J.: Ein Beitrag zum behandlung der osteitis fibrosa generalisata (Recklinghausen), Fortsch. a. d. geb. d. Röntgenstrahlen 36: 1062, 1927.
14. Quick, A. J., and Hunsberger, A., Jr.: Hyperparathyroidism, Clinical Picture in Far Advanced Stages, J. A. M. A. 96: 746, 1931.
15. Quick, A. J., Hunsberger, A., Jr., Eleason, E. L., and Hudson, N.: Hyperparathyroidism, Clinical Picture in Far Advanced Stages, J. A. M. A. 104: 2248, 1935.

It is interesting to note that Johnson,[5] as well as Brindle and Herman,[6] and Albright and Aub,[7] show calcification of the pyramids, and the two latter report of calcification in the cortex and medulla of the kidney. This calcification was demonstrated by x-ray visualization. Anderson[8] has demonstrated that in chronic hyperparathyroidism there are destructive microscopic changes in the kidney characterized by interstitial fibrosis, calcification, and infiltration by lymphocytes which lead to renal failure, and yet despite the marked renal failure the blood pressure need not necessarily be increased.

Calcification in the kidney was not the only site of calcification noted in our case. It was also observed in the metastatic lesion of the tumor to the lymph nodes, the thyroid, the urinary bladder, and the blood vessels of the heart. Although one must consider the x-ray irradiation as a possible cause of calcification following necrosis of tissue, we find evident support in the work of Bergstrand[9] that the calcification is part of the disease under discussion. In nine cases of primary (benign) hyperparathyroidism he found calcification in some of the tumors.

A factor which is quite important in the support of the diagnosis of the malignant tumor of the parathyroid gland is the marked progressive, diffuse, fibrocystic changes of the bones (Figs. 1 and 2). These are but single examples. Films taken ten days prior to the patient's death showed almost a complete destruction of the cortex of the bones. The marked fibrocystic changes are represented by the proliferating osteoclasts in the spinous process of the vertebrae (Fig. 6, *A* and *B*). Despite the extensive destruction of bone and bone marrow, the red blood cell count was rather constant, although terminally the hemoglobin was rather low. This may be explained on the basis that in the ribs there were still active foci of hematopoiesis and erythropoiesis (Fig. 6, *B*).

The predominating cell in our case resembled the chief cell, although the transitional cell and the water-clear cells were seen occasionally. This finding runs parallel with Castleman and Mallory's[10] observations in their report on benign adenomas of the parathyroid gland.

The effect of x-ray irradiation on primary hyperplasia of the parathyroid is still a moot question. Rappaport,[11] Huguet,[12] and Schnayer[13] report favorably on the therapeutic effect of x-ray irradiation in adenomas of the parathyroid and the associated bone changes.

Sainton and Millot[3] and Quick and Humsberger[14, 15] are skeptical about the outcome of x-ray therapy, in so far as their patients failed to improve.

Our patient also failed to improve under rather extensive x-ray irradiation. However, we must be somewhat guarded in our opinion since we are dealing with a carcinoma of the parathyroid gland.

SUMMARY AND CONCLUSIONS

A case of carcinoma of the parathyroid gland with post-mortem findings is presented showing only a temporary improvement in the objec-

disability in the right lower limb and for attacks of hemorrhage from varicose veins in the lower leg. Along the outer thigh reaching from the lower ribs to the foot, ran huge, tortuous varicose veins, and the whole right leg was enlarged. Thrombi were palpable in the veins, some of them organized and a few probably calcified. There was a pulsating swelling in Scarpa's space and along the femoral artery. Over this a thrill was felt most intensely about the middle of the thigh. In the abdomen was another pulsating tumor eight inches across and occupying most of the hypogastrium and right iliac fossa. The pulsation here, too, was expansile in character and over it a thrill could be feebly felt. The abdominal tumor was thought by Dr. Osler to be a large venous sinus associated with enormous venous dilatation above a traumatic arteriovenous aneurysm.

The occasional occurrence of a true aneurysm of the artery above the level of an arteriovenous fistula, led Reid[2] to believe that the abdominal tumor noted by Osler was probably an aneurysm of the iliac artery rather than a venous dilatation. The following case is evidence of the fact that such extreme venous dilatation can occur, although it must be quite uncommon.

W. H., a Negro man, 49 years of age, was admitted to the Passavant Hospital in January, 1942, for treatment of an arteriovenous fistula of the right femoral vessels and a mass in the right lower abdominal quadrant. He had been shot in the posterolateral aspect of the right thigh eighteen years before, the bullet traversing the thigh and lodging just beneath the skin about three inches below the medial aspect of Poupart's ligament. There had apparently been very little bleeding at the time, and after a brief and uneventful recovery, he returned to work as a janitor, with no residual other than a slight amount of swelling of the right leg and the presence of a purring sensation in the groin. He had no other signs or symptoms until two years before admission when he began to have dyspnea on exertion and occasional attacks of precordial pain with radiation to both shoulders, which gradually increased in severity until he was forced to give up his work. Six months before admission, he noticed for the first time a painless swelling in the right lower abdominal quadrant which slowly increased in size until it reached the size of a grapefruit, and coincident with this there was marked increase in the size of the right leg with the appearance of varicosities and ulcers. The past medical history was essentially negative.

The positive findings on physical examination were limited entirely to the cardiovascular system. The heart was enlarged in all directions, with the maximal apex impulse in the sixth left intercostal space in the anterior axillary line. There was a systolic murmur which was best heard over the apex and which was transmitted to the left axilla and the right sternal border. There was a large mass in the right lower abdominal quadrant, which measured 14 by 10 by 7 cm. (Fig. 1). The right leg was much larger than the left, there being 15 cm. difference in circumference at the mid thigh and 7 cm. at the mid calf. There were varicosities and pigmentation, and in the region of the ankle there were two scars of healed varicose ulcers. There was a constant thrill and bruit over the right groin just below Poupart's ligament, the bruit being transmitted to the abdominal mass. The popliteal and dorsalis pedis vessels were not palpable.

Obliteration of the fistula by digital pressure produced a drop in the radial pulse rate from eighty eight to sixty six beats per minute, and caused the abdominal mass to disappear, giving the clinical impression that it was a saccular dilatation of the external iliac vein. With the collapse of the mass a large, somewhat tortuous external iliac artery could be outlined just lateral to it.

ARTERIOVENOUS FISTULA OF THE COMMON FEMORAL VESSELS WITH EXTREME DILATATION OF THE EXTERNAL ILIAC VEIN

Report of a Case

James R. Watson, M.D., and R. B. Miller, M.D.
Pittsburgh, Pa.
(From the Passavant Hospital and the John C. Oliver Memorial Research Fund of the St. Margarets Memorial Hospital, Pittsburgh)

INJURIES to the major blood vessels of the extremities, resulting in the formation of arteriovenous fistula, produce profound changes in the circulatory system. These changes are both structural and physiological and, while they involve both the arterial and the venous sides, the latter is the more adversely affected of the two, and is responsible for most of the signs and symptoms which characterize the disease.

The structural changes in the vein consist essentially of hypertrophy and dilatation. The hypertrophy involves the intima and media, at times giving it an appearance not unlike an artery, a change which had been referred to as "arterialization" of the vein. The dilatation may be diffuse and may extend for some distance proximal to the level of the fistula, or may be maximal locally at the site of the fistula, where it represents an almost constant finding. The degree of hypertrophy and dilatation varies considerably according to the size of the blood vessels involved and the size and duration of the fistula. The dilatation is also probably influenced by the resistance offered by adjacent structures, and would thus be apt to be less marked in an extremity, where the vein is surrounded by muscles and their fascial compartments, than in one of the body cavities where there is nothing more resistant than areolar tissue. In cases of arteriovenous fistula of the femoral vessels, the proximal dilatation has been frequently described as enormous, and Osler[1] demonstrated a case before the Johns Hopkins Medical Society in 1904, in which it extended for some distance proximal to the fistula and was sufficiently large to produce an abdominal tumor. The tumor's "origin was, however, not perfectly clear, and, so far as he knew, there were no other cases like this one in the literature." His case is reported as follows:

> The man—now 31 years of age—had, in his eleventh year, received a knife wound just above the right knee. This was soon followed by swelling of the calf of the leg and a little later pulsation was noticed along the femoral artery with the development of a swelling in that region. The patient's health had remained good and he was exceptionally vigorous except for some

Received for publication, Jan. 25, 1943.

branches entering the fistula, for the most part on its posterior aspect. The artery could not be separated from the vein above the level of the fistula, so an attempt was made to free them en masse from the underlying tissue. They were quite adherent and, in spite of careful dissection, the vein ruptured, resulting in a sudden and profuse hemorrhage. Large packs were immediately inserted in the wound and firm pressure was applied. Nitrous oxide and oxygen anesthesia was started in order to expedite the control of the bleeding. A vertical incision was made just above Poupart's ligament and the ligament was divided over the course of the vessels. The external iliac artery and vein were separated and freed without difficulty where they passed over the anterior ramus of the pubis, and were tied using umbilical tape. The large saccular dilatation of the external iliac vein was readily visible at the upper angle of the incision (Fig. 3) and was seen to collapse when the vein was tied. The incision above the ligament was closed using fine silk, and the repair of the fistula continued under local anesthesia.

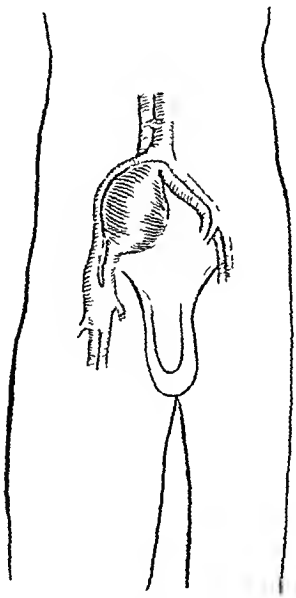

Fig. 3.—Diagrammatic sketch of the relationship between the arteriovenous fistula and the saccular dilatation of the iliac vein.

The packs were removed from the lower incision and the wound was found to be dry. A tape was then passed beneath the artery and vein below the fistula and tied, it also being impossible to separate them here for separate ligation. In view of the difficulties already encountered in attempting to separate the vessels from the underlying tissue above the level of the fistula, it did not seem advisable to attempt it again even though such a course meant abandoning removal of the fistula. Several sutures of No. 2 silk were passed around the vessels at the level of the fistula and tied in an effort to obliterate it in this manner. Although the vessels tended to fill slowly between the sutures, auscultation with a sterile stethoscope failed to reveal a bruit and there was no palpable thrill. The wound was thoroughly irrigated with sterile normal salt solution and closed in layers with fine silk. The operation required four and one-half hours. In spite of the hemorrhage the pulse was steady between ninety and one hundred beats per minute throughout the operation, there being no evident drop when the vessels were tied or the fistula sutured. The blood pressure, which was 175 mm. of mercury systolic and 80 mm.

Repeated urinalyses were negative except for a slight trace of albumen. The blood count showed 4,220,000 red blood cells per cubic millimeter of blood, with 87 per cent hemoglobin and 10,300 white blood cells. The differential count was normal. The nonprotein nitrogen was thirty-six and the creatinine 1.6 mg. per 100 c.c. of blood. The Kolmer and Kahn tests were negative. A cystogram (Fig. 2), made to determine the size and position of the abdominal tumor, showed the bladder to be displaced toward the left side by a large mass which occupied the right half of the pelvis. The mass appeared to extend several centimeters above the superior border of the bladder.

Fig. 1.

Fig. 2.

Fig. 1.—Illustration showing the location of the abdominal mass and the marked enlargement of the involved leg.

Fig. 2.—Cystogram showing the deformity and displacement of the bladder produced by the dilated iliac vein.

The patient was kept in bed with the right leg elevated for a week in an unsuccessful attempt to decrease the edema.

Operation was performed on January 10, under local anesthesia. A vertical incision was made over the common femoral vessels below Poupart's ligament. Many dilated and tortuous veins were immediately encountered in the subcutaneous tissue. These were divided and the incision gradually deepened to expose the fistula. Poupart's ligament was not divided as we did not want to expose the venous mass in the pelvis. The fistula was found to be about 5 cm. below Poupart's ligament and was embedded in dense fibrous tissue with the anterior femoral cutaneous branch of the femoral nerve intimately adherent to it on its lateral aspect. The artery and vein above the fistula were each approximately 4 cm. in diameter, although measurement of the vein was inaccurate as part of it lay beneath the artery. There was some sclerosis of the artery. The wall of the vein was thickened, although it was not as thick as that of the artery. The vessels below the level of the aneurysm were small, the artery measuring 1 cm. in diameter while the vein was even smaller. There were several large arterial and venous

the retroperitoneal tissues do not offer any resistance. The studies of Reid and McGuire,[3] which demonstrated the tremendous increase in blood volume in the proximal vein, cause one to wonder why the dilatation is usually not more marked. The extreme dilatation of the external iliac vein found in the case described appears to be unusual, and with the exception of the case reported by Osler, we have been unable to find any similar reports in the literature. The venous origin of the abdominal tumor is beyond dispute in view of the fact that it was necessary to expose it at its lower margin through a misadventure during the operation. It apparently represents a late complication for, according to the patient's history, it occurred seventeen and one-half years after the inception of the fistula. Although there is no mention of the duration of the abdominal tumor in Osler's case, the fistula had been present for twenty years. In our case it was interesting to observe the collapse of the abdominal tumor when the fistula was obliterated by digital compression, and we offer this test as a method to differentiate between tumors of arterial and venous origin which occur proximal to an arteriovenous fistula.

SUMMARY

1. A case of arteriovenous fistula of the common femoral vessels is reported in which there was a saccular dilatation of the external iliac vein of sufficient size to produce an abdominal tumor.

2. A diagnostic sign is described which will permit a clinical differentiation between a venous dilatation and an arterial aneurysm occurring proximal to an arteriovenous fistula.

REFERENCES

1. Osler, Wm.: A Case of Arteriovenous Aneurysm, Johns Hopkins Hosp. Bull. 16: 146, 1905.
2. Reid, Mont R.: Abnormal Arteriovenous Communications, Acquired and Congenital. III. The Effects of Abnormal Arteriovenous Communications on the Heart, Blood Vessels and Other Structures, Arch. Surg. 11: 25-42, 1925.
3. Reid, Mont R., and McGuire, Johnson: Arteriovenous Aneurysm, Ann. Surg. 108: 643-690, 1938.

diastolic at the beginning of the operation, was 145 and 120 mm., respectively, at the end.

The patient made an uneventful recovery and left the hospital twenty-two days after operation with both incisions healed. The improvement noted was dramatic. The heaving sensation which had been present in his chest before operation had entirely disappeared. The heart was quieter and the murmur was only faintly audible. The systolic and diastolic blood pressures were maintained at their post-operative levels and were 140 mm. of mercury systolic and 110 mm. diastolic at the time of dismissal. The most pronounced change was in the size of the heart, the transverse diameter decreasing from 20.3 cm. before operation to 16.6 cm. eighteen days after operation. Electrocardiographic studies made before and after operation showed only a right axis deviation, with no essential alteration after operation other than a decrease in the pulse rate. The tissues of the leg were not as tense as they had been and measurements showed a decrease of 3 cm. in circumference at the calf and thigh. The mass in the right lower abdomen reappeared during the first few days after operation and gradually returned to its original size. It possessed a firmness, however, which had not been present before. The only disquieting feature, and this was not entirely unexpected in view of the fact that the fistula had not been removed, was the reappearance of a faint thrill and bruit over the operative area on the fifteenth day.

The discharge note stated that "A thrill and bruit are still present over the femoral triangle, although they are not nearly as loud as they had been before operation. The abdominal tumor is as large as it was originally, but is now firm and not compressible, and does not decrease in size when pressure is made over the site of the arteriovenous fistula. It is apparently filled with blood clot and should gradually decrease in size as the clot organizes. The patient will have to be watched closely and if the heart shows any tendency to enlarge, another operation on the fistula will be necessary. The patient has been advised to spend most of his time at home and in bed for the next two months, and to avoid all exertion."

When last seen, six months after operation, he had no complaint other than cramping pain in the calf of the right leg after walking for a distance of a block and a half. It was readily relieved by a brief period of rest and he was contemplating returning to his job. There had been a slow but progressive decrease in size of the leg, there being now only 5 cm. difference in the circumference of the two thighs. The thrill and bruit were scarcely discernible over the femoral triangle. The abdominal mass was firm and was decreasing in size. The artery lateral to it was also firm and less distinct and, according to the patient, had suddenly stopped pulsating about three weeks previous. The heart was quiet and regular in rhythm, and on x-ray examination was found to have decreased another 0.8 cm. in its transverse diameter. Branham's brachycardic sign was negative, pressure over the fistula producing no decrease in the pulse rate of ninety-two beats per minute. It is still too early to predict a complete cure, although so far the result has been entirely satisfactory.

DISCUSSION

For anatomic reasons it is difficult to determine the extent and degree of dilatation of the vein proximal to an arteriovenous fistula of the common femoral vessels. It is quite possible that saccular dilatation of the external iliac vein can occur and still not be of sufficient size to be apparent. The vein, regardless of the degree of dilatation at the level of the fistula, is necessarily decreased in size where it passes beneath Poupart's ligament, and is then apt to become dilated above it where

as much as water. This absorptive capacity is also elevated in ligaments, bones, spinal white matter, liver, and spleen. Following tissue saturation, a sudden release in pressure results in "bubbling." These numerous bubbles or gas emboli account for the multiplicity of symptoms. The possibilities for damage as a result of these numerous gas emboli are numerous, and depend upon the initial degree of saturation and the speed of the return to normal pressure. Thus, obstruction to circulation, rhexis, and tissue pressure are the basic sources of the ensuing symptoms. If the individual is returned to normal atmospheric pressure gradually, body equilibrium takes place by slow release of nitrogen and emboli formation is obviated.

The symptomatology must necessarily be strange and varied because of the extensive involvement of tissues. Improper decompression, or lack of it, will affect the patient accordingly. The onset of symptoms is immediate in severe cases but generally averages one hour. Death may ensue shortly after return to atmospheric pressure and is attributable to pulmonary, cardiac, or cerebral involvement. This applies particularly to obese individuals. An excellent description and classification of the symptoms is that of Behnke,[3] namely, bends, chokes, and paralysis. The bends are most common, consisting of pains in the extremities and joints. Abdominal cramps accompanied by nausea and vomiting are also common. The unyielding tissues of the extremities, particularly in the joints, account for the pain. In chokes, involvement of the pulmonary vessels is responsible for the asphyxia picture which is often associated with bloody frothy expectoration. Paralysis is less common than bends and is a grave sign. Here the pathology lies chiefly in the central nervous system. Paresis, paraplegia, and hemiplegia are rare findings.

Briefly, the treatment consists of recompression to the original high level followed by decompression in stages and reduction of previous pressures by one-half. This method has proved more efficacious than a steady gradual decompression. Helium-oxygen mixtures (80 and 20 per cent) have been found to be a valuable adjunct in the decompression. Helium, an inert gas, is one-seventh as dense as nitrogen and is less readily put into solution while its diffusibility is greater and thus more readily freed from solution.

The following case report presents a new complication in caisson disease, namely, leg ulcers.

CASE REPORT

J. C. (No. 131523) was admitted June 23, 1941 and discharged Dec. 30, 1941. The patient, a former caisson worker, aged 58 years, was admitted to the Metropolitan Hospital with a chief complaint of multiple leg ulcers of about four years' duration. The ulcerations were preceded by the appearance of multiple bullae on both legs. After a few days, the blisters broke down and the resulting ulcerations have persisted up to the present time. The patient states that his knees have been "stiff" for about six years. He had had several attacks of the "bends." Both legs had felt slightly numb for many years.

LEG ULCERS AS A COMPLICATION OF CAISSON DISEASE

S. THOMAS GLASSER, M.D., F.A.C.S., NEW YORK, N. Y.

(From the Department of Surgery, New York Medical College, Flower and Fifth Avenue Hospitals and Metropolitan Hospital; Louis Rene Kaufman, M.D., F.A.C.S., director, New York)

CAISSON disease presents a great variety of symptoms inherent upon the generalized pathology. However, the complications are surprisingly limited chiefly to the bones and joints. Our presentation of a case of caisson disease complicated by leg ulcers is prompted following a careful search of the literature which failed to reveal this complication.

Caisson disease classified in various texts[1-2] under the heading of high barometric pressure is also known as: aeropathy; compressed-air illness; divers' paralysis; divers' palsy; the bends. The present war makes this disease of particular interest because of its association with deep-sea diving, bridge building and other related work. It is also of importance because the knowledge obtained in studying this disease has been of inestimable value in aviation medicine. Exposures to high pressure occur in bell, caisson, diving suits, and tunnels.

The pathologic physiology is extremely interesting. It must be remembered that the disease is not attributable to anoxia as supposed by those unfamiliar with this entity, but is the result of the return from high atmospheric pressure. In other words, high pressures are well tolerated but the ill effects are evidenced when the individual returns to atmospheric pressure. When this occurs, the nitrogen, which had been forced into solution in the plasma and tissues, will be released. Under increased pressure, the component gases of the air go into fluid solution after passing from the pulmonary alveoli to the circulation. This solution is in direct proportion to the partial pressures (Dalton's Law) of the air's components, nitrogen and oxygen. The two gases must be distinguished because nitrogen is an inert gas which is not utilized by the body and tends to free itself when the external pressure is lowered. On the other hand, oxygen is readily utilized by the hemoglogin and body tissues. Of further importance is the fact that nitrogen is not absorbed equally by the various tissues. Consequently, the degree of pressure and the time it is exerted determine the amount of nitrogen absorbed by the individual tissues. The same applies to the subsequent lowering of pressure when the nitrogen is eventually expelled in the alveoli. Tissues which have a comparatively poor blood supply are slower in their absorption of nitrogen, but when saturated, take up greater amounts than well-vascularized tissue. Fat absorbs five times

Received for publication, Feb. 18, 1943.

in the circulation." In this author's large experience the only cutaneous manifestations noted were "pruritus, erythema, purplish mottling and blotching." This occurred in only 20 of the 300 cases. Most observers agree that skin manifestations are early or impending signs of caisson disease. By analogy, one might expect skin ulceration for the same reason that damage to the central nervous system with paralysis results from pressure necrosis. We cannot account for the apparent rarity (no reports in the literature) of skin breakdown and ulcer formation except by the fact that the skin is elastic and pliable. In discussing the complications of caisson disease, Thorne notes that "the complications of caisson disease are limited to the bones and joints. The symptoms of onset are insidious and are delayed from six months to a year or more following repeated attacks of the disease."

A consideration of the differential diagnosis is pertinent in this discussion. Varicose and arteriosclerotic ulcers are definitely ruled out by the aforementioned findings. Against the type of multiple ulcerations seen in erythrocyanosis frigida is the absence of evidence of vasospastic phenomena and the patient's sex. The question arises as to whether the ulcers are of the postphlebitic variety. This diagnosis is not tenable in the absence of a history suggestive of previous phlebitis, the painless character of the ulcers, the absence of straight hard palpable veins, the absence of induration and dermatophytosis.

SUMMARY

A case of chronic leg ulcers as a complication of caisson disease is described. This complication is not mentioned in the literature and must be considered as an exceptionally rare finding.

REFERENCES

1. Meakins, J. C.: Practice of Medicine, Ed. 3, St. Louis, 1940, The C. V. Mosby Company, pp. 1339-1340.
2. Best, C. H., and Taylor, N. B.: Physiological Basis of Medical Practice, Ed. 2, Baltimore, 1939, Williams & Wilkins Company, pp. 579-580.
3. War Medicine—A symposium: New York Philosophical Library, 1942, Lt. Com. A. R. Behnke, Jr., M.C., U. S. Navy, pp. 4, 6, 7.
4. Mellinghoff, K.: Skin Manifestations in Caisson Disease, Ztschr. f. klin. Med. 127: 457, 1934.
5. Thorne, E. J.: Caisson Disease: A Study Based on Three Hundred Cases Observed at the Queens Midtown Tunnel Project, 1938, J. A. M. A. 117: 585, 1941.

On examination, the patient appeared well developed and in no apparent distress. Except for the local conditions, the physical findings were normal. There was marked bilateral pitting edema of both lower extremities. The absence of varicosities and scars, was noted. The popliteal, femoral, and femoral pulses were readily palpable. There were on the lower extremities of many small ulcers and one large ulcer on the lower third of both legs. The ulcers appeared indolent, were tender only due to edema, and were covered by fairly healthy granulations and had an amount of sero-purulent discharge. The edges were neither undermined nor indurated, and there was only little evidence of fibrosis at the bases. The extremities had a bluish red color and the knees showed limitation of movement (about 50 per cent), probably due to partial ankylosis.

During the subsequent course of treatment, wet dressings, adhesive strapping, and Unna boots, no improvement resulted. On Aug. 16, 1941, many of the ulcers were "dressed" grafted with the third skin donor site. Unna boots were again applied. On Sep. 24, 1941, further grafting was performed using Thiersch grafts. The "takes" following both operations were only about 50 per cent successful. Although the ulcers were kept clean and bed rest maintained, healing remained refractory. Unna boots were applied on Dec. 20, 1941, and the patient was discharged to the outpatient department. Follow up examination revealed only slight improvement. In Feb. 1943, the patient was in a hospital for chronic diseases and the ulcers remained about the same as on discharge from the Metropolitan Hospital.

DISCUSSION

The formation of ulcers is probably attributable to ischemia. Behnke's investigations showed that gas bubbles could be seen only in the vessels. He states, "Supporting the vascular ischemia origin of bends is the fact that application of pressure promptly relieves symptoms. This response might not be anticipated were the injury due to extravascular bubble formation which would imply cellular destruction." The only reference to skin manifestations in the literature is that of Mellinghoff.[4] His patient was admitted with evidence of peripheral circulatory collapse and some symptoms of the "chokes." Most interesting was the "marble" appearance of the extremities in which the pale blue areas of skin turned to a dark blue color. The marmoration of the skin was accentuated on coughing (Valsalva test). These blue spots had sharp outlines. Marmoration disappeared in a few days and no residual signs remained. The author explains the marmoration by the capillary stasis due to the increasing size of nitrogen bubbles which block capillaries. The stasis in the capillaries clears up when the nitrogen is carried away. The marmoration is apparently more marked with peripheral circulatory collapse and this stasis starts a vicious cycle with added circulatory collapse due to stasis. It is surprising to me that with these marmoration phenomena, in the more acute cases, more instances of breakdown in the skin do not occur. In my case, the probability of local thrombosis and extravasation of blood into the skin and neighboring tissues may be the cause of the subsequent ulceration. Thorne,[5] in his study based on 300 cases, made the observation that "the appearance of mottling and blotching with subcutaneous hemorrhages is further evidence denoting large amounts of free gas

devitalized tissue remains following sac closure. As stated earlier, the use of the Furniss clamp in herniopiasty will reduce the operative time by several minutes and converts an oftentimes troublesome technical and retractive labor into an incidental step of the operative procedure.

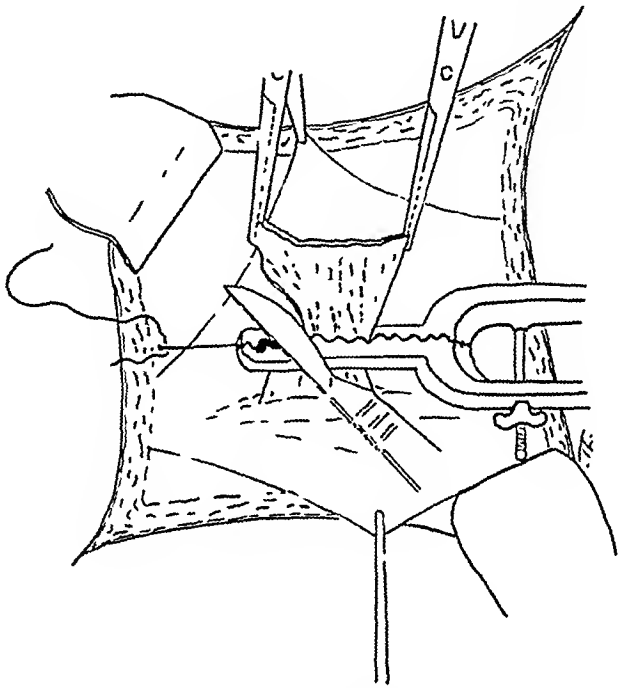

Fig 1 —Furniss-Clute clamp applied, with needle in place and amputation of hernial sac in progress

SUMMARY

A new, simple, rapid, and positive method for hernial sac closure is outlined employing the Furniss clamp, originally advocated for intestinal anastomosis, which will prove its value to the surgeon following a single trial.

Erratum

On page 946 of the June, 1943, issue in the article "Resection of the Colon in Six Cases of Hirschsprung's Disease" by Louise Yeazell, M.D., and H. Glenn Bell, M.D., San Francisco, Calif., the dosage mentioned at the end of the fifth line should read "syntropan 0.05 Gm. twice a day."

A NEW SIMPLE AND RAPID METHOD FOR HERNIAL SAC LIGATION

Robert Lich, Jr., M.D., M.S.,* and Ralph B. Samson, M.D.†
Pittsburgh, Pa.
(From the Department of Surgery of the United States Marine Hospital)

THE various operations and modifications of operations for the repair of hernia are virtually limitless and it seems almost beyond the realm of possibility to offer another which would be wholly original. However, it is not our purpose to advocate another method of herniorrhaphy, but indeed to offer an original simple and rapid procedure, applicable to all, which will reduce the time of hernial sac ligation from minutes to a mere matter of seconds.

Some two years ago Robert D. Mansfield‡ and one of us (R. L.) experimented with several original methods in order to effect hernial sac closure both more quickly and easily. Several methods were developed and though seemingly of value, none demonstrated the desired attributes of simplicity, speed, and positive closure in every instance. The present idea, though conceived at that time, was later put in use and proved so amazingly simple, rapid, and absolute that we are reporting our experience.

The hernial sac is exposed in the conventional way and the redundant tissue extracted so that the neck is well isolated. The sac is then maintained under tension and a Furniss clamp applied across the point of desired ligation (Fig. 1). Vision within the sac is necessarily maintained so that no intestinal loop or omental tag is caught in the jaws of the clamp. After the clamp is closed and tightened, a needle threaded with the suture (No. 8 spool cotton in our work) is inserted between the jaws of the clamp and certainty is made that the needle penetrates the entire breadth of the now corrugated hernial sac. It is important that tension be maintained on the redundant sac until the needle is in place. The distal portion of the sac is now excised with a scalpel, the clamp removed, and the suture pulled into position and tied. This will effect a very tight purse-string closure of any peritoneal sac irrespective of its fragility and width provided it can be placed within the jaws of the Furniss clamp. Also, it is to be noted that only a negligible amount of tissue remains above the point of ligation so that only a minimum of

*Chief of Surgery, P. A. Surgeon (R), U. S. Public Health Service.
†Assistant Surgeon (R), U. S. Public Health Service.
‡Major R. D. Mansfield, Medical Corps, U. S. Army.
Received for publication, March 17, 1943.

or sulfonamide-derivative radical. The amino group must be in the para position. The solubilities of the various compounds are clinically important and are as follows for water at 37.0° C. in milligrams per 100 cubic centimeters: sulfanilamide 1,400, sulfapyridine 49.5, sulfathiazole 94, and sulfadiazine 12.3.[11] The sodium salts of sulfathiazole and sulfadiazine are soluble up to 5 per cent and are suitable for intravenous administration when dissolved in sterile distilled water. The solubility of sulfanilamide and sulfapyridine is the same in urine as in water, but sulfathiazole is soluble up to 230 mg. per 100 c.c., and sulfadiazine up to 60 mg. per 100 c.c., particularly if the urine is slightly alkaline. Acetylsulfadiazine is even more soluble than sulfadiazine in urine.

The sulfonamide drugs are harmless to the body tissues in therapeutic doses, but bacteriostatic to the organisms against which they are effective, thereby distinguishing them as chemotherapeutic agents. They are absorbed readily by any channel, the peak of intestinal absorption being at four to six hours. Sulfadiazine is absorbed more readily and constantly than sulfathiazole, permitting an easier control of an effective blood concentration. Following absorption these drugs remain in the blood for a variable time depending upon the rate of absorption, the degree of acetylation, and the rate of excretion. Again, sulfadiazine is excreted less rapidly than sulfathiazole. Sulfapyridine is absorbed and excreted erratically. Large doses of these drugs, particularly sulfanilamide, lead to methemoglobinemia with a lowering of the oxygen saturation of the blood, but sulfanilamide is the only one producing acidosis. All of them have some direct antipyretic effect which is most marked with sulfapyridine. These drugs, once absorbed, are distributed relatively uniformly in all body tissues, the concentration being lowest in the skin, brain, bone, and fat. Sulfathiazole yields a low concentration in normal spinal fluid but filters readily through inflamed meninges.

It is well recognized that sulfathiazole and sulfadiazine are much more soluble in biologic fluids than in water. The hydrogen-ion concentration of blood is 7.5, and at this concentration sulfathiazole is 83.4 per cent ionized in the form of salt, and sulfadiazine 92.9 per cent. Sulfathiazole and sulfadiazine are, therefore, probably transported in the blood chiefly in the form of sodium salts.[11]

A physiologic attempt at detoxification occurs by acetylation of the para-amino group, probably in the liver. The acetyl compounds are therapeutically inactive. Acetylation is greatest for sulfapyridine (45 to 75 per cent), less for sulfanilamide and sulfathiazole (10 to 30 per cent), and least for sulfadiazine (0 to 20 per cent). The acetyl salts of sulfapyridine and sulfathiazole are insoluble in urine, and their precipitation in the urinary tract may lead to hematuria, renal concretions, or anuria. Acetylsulfadiazine is more soluble than sulfadiazine, and urinary complications are less likely to occur from the acetylation of this drug. Forcing fluids and maintaining the urinary output at

Recent Advances in Surgery

Conducted by Arthur Blocq, M.D.

SULFONAMIDES IN SURGERY

Victor Richards, M.D., San Francisco, Calif.
(From the Department of Surgery, Stanford University School of Medicine)

ALTHOUGH the sulfonamide group of drugs has been known to organic chemists for more than thirty years, it first achieved clinical importance in 1935, when Domagk[1] showed experimentally that prontosil was effective in combating streptococcal infections in mice. Since 1935, more than 1,300 sulfonamide compounds have been studied but few of these have endured clinically. It was soon discovered that sulfanilamide was not effective in treating staphylococcal and pneumococcal infections, and research with these organisms led to the development of sulfapyridine, in 1938, by Whitby,[2] and of its more soluble sodium salt, in 1939, by Marshall and Long.[3] Frequently, sulfapyridine produced nausea and vomiting, and it proved no more effective against staphylococcal and pneumococcal infections than sulfathiazole, which was introduced a year later by Fosbinder and Walter,[4] and by Lott and Bergeim.[5] In 1940, Roblin, Williams, Winnick, and English[6] presented sulfadiazine as a still less toxic and equally active drug in combating pneumococcal, streptococcal, staphylococcal, and Friedlander organisms. Sulfadiazine has proved to be the drug of choice for systemic administration against these organisms.[7] In 1940, Marshall and co-workers[8] offered sulfaguanidine in an effort to produce intestinal antisepsis, and now this drug is being supplanted for this purpose by succinylsulfathiazole (or sulfasuxidine) following recent studies of Poth and Firor.[9] That sulfanilamide is both safe and effective when introduced locally into wounds was demonstrated, in 1939, by Jensen, Johnsrud, and Nelson,[10] who employed the drug in the management of compound fractures in civilians.

Chemistry and Pharmacology.—All of the sulfonamide drugs are white, odorless, and nearly tasteless. The sodium salts are soluble, alkaline (hydrogen-ion concentration 8 to 10), and unstable to heat. One per cent solution of sodium sulfapyridine has a hydrogen-ion concentration of 10.1, sodium sulfathiazole 9.4, and sodium sulfadiazine 8.7.[11] The essential chemical structure of the group is a benzene ring with an amino group in the para position with respect to the sulfonamide

rapid. This theory has been further correlated with Lockwood's observations, for areas of tissue destruction and abscess formation are high in para-amino-benzoic acid. Practically, the procaine anesthetics are derived from the para-amino-benzoic acid series and inhibit sulfonamides. Para-amino-benzoic acid may be added to culture media to promote bacterial growth in the presence of sulfonamides.

4. *Oxidation Theory* (Fox[19] and Shaffer[20]): In vivo the sulfonamides are converted to active oxidation products, it is postulated, and, in fact, oxidation products of the sulfonamides are found in the urine, chiefly in the form of glucuronides and sulfates. Sulfonamide bacteriostasis rests upon the production of oxidizing conditions which serve to inactivate enzymes necessary for bacterial growth. This correlates with Mellon's theory. However, the sulfonamides are effective in anaerobic media.

To summarize, the action of sulfonamides is bacteriostatic, preventing overwhelming infections and permitting the mobilization of natural tissue defenses to eradicate the bacteria and evoke recovery. It is assumed that bacteriostasis rests upon the production of oxidizing conditions which inactivate an enzyme or enzyme-substrate necessary for bacterial growth. Peptone and para-amino-benzoic acid are strong sulfonamide inhibitors.

Drug Resistance.—It is recognized that certain organisms that are usually affected greatly by sulfonamides are resistant to them. This resistance may be natural or acquired, and exists for all organisms susceptible to sulfonamide therapy. Clinically, drug resistance is produced most commonly by giving suboptimal doses of the drugs for a relatively long period. Once developed, the organism is resistant to all members of the sulfonamide group, and usually this resistance is permanent.

Dosage.—Optimum concentrations should be obtained rapidly by a large initial dose, and this concentration should be maintained for seventy-two hours. If the drug is effective, beneficial results should be obtained by the third or fourth day at the latest. The drug should be discontinued if ineffective.

For practical purposes the initial oral dose is approximately 0.10 Gm. per kilogram of body weight for sulfanilamide, sulfathiazole, and sulfadiazine. The subsequent maintenance dose is approximately 0.10 Gm. per kilogram of body weight given orally in six divided doses at regular four-hour intervals. For the normal adult this amounts to an initial dose of 4 to 6 Gm., followed by 1 Gm. orally every four hours, day and night.

If oral medication is interdicted, sodium sulfathiazole or sodium sulfadiazine may be given intravenously. The initial dose is 5 Gm. given as a 5 per cent solution in sterile distilled water. The subsequent daily dose for sulfadiazine is 5 Gm., one-half of it to be given in the morning and one-half in the evening. For sulfathiazole, 1½ to 2 Gm.

more than 1,200 c.c. daily are essential in avoiding urinary complications with the sulfonamide drugs, particularly sulfapyridine, sulfathiazole, and sulfadiazine. Alkalinization of the urine with oral sodium bicarbonate will aid in the ionization of these drugs to the sodium salts, thereby increasing their solubility in urine.

Excretion occurs almost entirely in the urinary tract, although small amounts of sulfathiazole are excreted in the feces. Excretion is rapid with sulfathiazole and slower with sulfadiazine. Impaired renal function will lead to a retention of these drugs. Renal complications are greatest with sulfapyridine, small with sulfadiazine and sulfathiazole, and least with succinylsulfathiazole and sulfanilamide.

Mode of Action. Briefly, the mode of action of the sulfonamides is unknown. In clinical doses the drugs are bacteriostatic, not bacteriocidal. Experimentally, phagocytes are not necessary for sulfonamide action, but clinically phagocytosis of the bacteria is an important feature in the tissue immunity which is ultimately responsible for the eradication of the offending organisms. The sulfonamides have no direct effect on bacterial toxins. Bacteriostasis apparently results from an interference in bacterial cell metabolism or inactivation of an enzyme-substrate essential for bacterial growth. The main theories of sulfonamide action may be summarized as follows.

1. *Lockwood's Peptone Theory*[12-14]: Peptones or split protein nitrogen interfere with sulfonamide action. Sulfonamide combines with free amino nitrogen of protein degradative product, thereby rendering them unsuitable for bacterial utilization. The clinical implication is clear. The drugs are ineffective in the presence of pus; peptone is a definite sulfonamide inhibitor, and abscesses must be drained surgically. Necrotic tissue also is a sulfonamide-inhibitor substance.

2. *Mellon's Peroxide-Catalase Theory*[15]: Catalase is an enzyme normally destroying the hydrogen peroxide liberated by bacteria. Sulfonamides act as an anticatalase, permitting accumulation of peroxide about cells and bacteria. The high concentration of peroxide produces bacteriostasis. Apparently, the tissues convert sulfonamide into anticatalase. The sulfonamides, however, are effective against some non-peroxide-forming bacteria.

3. *Para-Amino-Benzoic Acid Theory:* Stamp[17] and Woods[18] found a para-amino compound of low molecular weight was necessary for the growth of many bacteria. Because of a close identity to sulfonamide they postulated it to be para-amino-benzoic acid. In vitro and in vivo para-amino-benzoic acid is a strong sulfonamide inhibitor, but it has not been isolated from growing bacteria. The "competitive enzyme" theory has been evolved. Sulfonamide and para-amino-benzoic acid compete for a place in the enzyme substrate system essential for bacterial multiplication. If sulfonamide wins, the enzyme system is inactivated and bacteriostasis results. If para-amino-benzoic acid predominates in the tissues the enzyme system is activated and bacterial multiplication is

Local Use.—The mere instillation of one of the "wonder drugs" into a wound may lull the thoughtless surgeon into a careless complacency, and deter him from the observance of other fundamental principles essential to kindly healing in a contaminated wound. It must be emphasized at the outset that the local use of sulfonamide in wounds is only one of the present-day adjuncts in the prevention and treatment of infection in contaminated wounds. The vast and recent experiences of the numerous surgeons who have clarified the concepts underlying the management of contaminated wounds have been admirably discussed and summarized by Whipple in a recent monograph.[23] Briefly, Whipple states that the local factors governing wound healing are: (1) amount of necrotic or devitalized tissue present, (2) local blood supply, (3) amount and character of exudate in the wound spaces, (4) number and virulence of infecting organisms, and (5) number and character of foreign bodies. Systemic conditions as (1) age of tissues, (2) hydration of tissues, (3) normal tissue protein, (4) proper vitamin balance, especially of vitamin C, and (5) general circulation and blood picture also influence wound healing. Surgical methods aid wound healing by preventing infection, utilizing the techniques of débridement, instillation of sulfonamides locally both before and after débridement, providing adequate drainage for infected wounds (Orr-Trueta method), avoiding suturing of wounds under tension or the formation of "dead spaces," and insuring adequate immobilization and rest of damaged parts. Chemotherapy, débridement, closed plaster method of Orr and Trueta, blood transfusions, vitamins, plasma, and proper fluid balance are all essential to kindly healing of wounds.

The sulfonamide drugs are valuable aids when properly employed in the management of contaminanted or infected wounds. In civilian practice an increasing number of contaminated or compound wounds may be closed successfully per primam after the local use of sulfonamides, but war wounds must still be permitted to close by secondary intention in the majority of instances, with the possible exceptions of open wounds of the abdomen, chest, hand, or brain. Aside from the fact that more serum may appear in wounds and that healing may be slightly retarded, it has been repeatedly demonstrated that sulfonamides are harmless in the healing of tissues whether implanted in compound fractures, burns, or peritoneal, pleural, or cranial cavities. According to recent reports, sulfathiazole may produce convulsions when applied to the brain.[24]

The factors influencing sulfonamide action are (1) concentration of the drug, (2) concentration and virulence of the offending organisms, (3) amount of sulfonamide-inhibitor substance, and (4) the local blood supply. The solubilities of the various sulfonamides in tissue fluid or plasma at 37° C. are approximately as follows[25]: sulfanilamide, 1,970 mg. per liter; sulfathiazole, 330 mg.; and sulfadiazine, 161 mg. per liter. The rationale for the local use of sulfonamides rests upon the

should be given every six hours. By this method of administration approximately uniform blood concentrations will be maintained.

Recent work, both experimentally and clinically[11, 21, 22] demonstrates the safety of subcutaneous administration of 0.5 per cent sodium sulfathiazole and 1 per cent sodium sulfadiazine solutions. Sulfanilamide may also be given subcutaneously in 1 per cent solution, but sodium sulfapyridine must never be used subcutaneously.

The dosage of succinylsulfathiazole is discussed separately. Evidence suggests that sulfates, arsenic and gold compounds, x-ray therapy, and large doses of avertin should not be given simultaneously with sulfonamides. Many prefer to administer vitamins, especially vitamin C, in large doses during sulfonamide medication, believing it diminishes toxicity.

Toxicity.—Toxic symptoms from sulfonamide medication are not uncommon, and one should avoid giving a sulfonamide to a patient known to be sensitive to this group of drugs. Serious toxic manifestations are infrequent in the average patient when a good fluid intake and a daily urinary excretion of more than 1000 c.c. are maintained.

Sulfanilamide very frequently produces nausea and vomiting, cyanosis, dizziness, headache, acidosis, fever, and rash. Agranulocytosis, hemolytic anemia, hepatitis, and jaundice may occur, but hematuria and crystalluria do not appear.

Sulfathiazole is of low toxicity, but hematuria, crystalluria, anuria, urinary tract stones, fever, and dermatitis occur and must be anticipated. Sulfadiazine is the least toxic sulfonamide drug now available. In general, its complications are similar but less frequent than with sulfathiazole. Succinylsulfathiazole is believed to be nontoxic.

It is advisable to stop the drug and force fluids if acidosis, agranulocytosis, hematuria, gastrointestinal disturbances, mental disturbances, fever, or rash appear. It is imperative to stop the drug with the occurrence of anuria, hemolytic anemia, hepatitis, leucopenia with granulocytopenia, or jaundice.

Choice of Sulfonamide.—Sulfanilamide is used rarely because of its frequent minor toxicity and limited range of effectiveness. Sulfathiazole is of low toxicity and is highly effective against staphylococci, pneumococci, hemolytic streptococci, gonococci, *Escherichia coli*, and meningococci. It has the disadvantage of being absorbed and excreted irregularly, and, hence, it is more difficult to maintain with sulfathiazole, a constant effective blood concentration. Also, renal complications occur slightly more frequently with it than with sulfadiazine. Sulfadiazine is less toxic, is rapidly and regularly absorbed, poorly excreted, and possesses a range of effectiveness equal to that of sulfathiazole, except, possibly, in the treatment of staphylococcal infections. With this possible exception, sulfadiazine, when administered systemically, is the drug of choice for all of the previously mentioned infections.

the tissues. Accurate wound hemostasis prevents lavaging of the sulfonamide from its seat of action, and permits adequate contact of the compounds with the contaminated tissues. It is necessary to repeat the local application of sulfonamide to the wound at each dressing until healing is complete.

In orthopedic surgery the incidence of infection in compound fractures in civilians is reduced remarkably by the use of sulfonamides locally, and primary closure is permissible in many cases in which débridement is carried out within the golden period of six to eight hours following injury. Sulfonamide is used also in acute osteomyelitis to tide the patient over the initial period of toxicity while localized abscesses are forming, but abscesses must be surgically drained.[26] In chronic osteomyelitis occasionally primary skin closure may be permitted following radical excision of all involved bone and local "frosting" with sulfonamide.

It has long been recognized that the necrotic or purulent material in wounds will nullify greatly the beneficial effects of sulfonamides in the wounds. Necrotic, contaminated, or purulent material is a strong sulfonamide-inhibitor, and these substances should be reduced to a minimum in the wound by gentle irrigation of the wound or by wet dressings. Recently, evidence has been offered to suggest a potentiation of sulfonamide activity by the concurrent use of mild oxidizing agents, particularly of 1:3,300 solution of azochloramide.[27] Allantoin or urea has also been suggested as effective in combating the effects of the sulfonamide-inhibitor substances in pus or necrotic material.[28] The entire field of sulfonamide potentiation has only recently been subjected to scientific investigation and future developments may soon alter the principles underlying the local application of sulfonamides.

Gas gangrene is best treated by initial débridement of the wound, application of a mixture of sulfanilamide-sulfathiazole locally, full doses of sulfadiazine by mouth, and the administration of antitoxin. If these measures fail, amputation may be necessary as a lifesaving procedure. X-ray therapy is of dubious value and should not be used with the sulfonamides.

For burns, innumerable dressings containing a sulfonamide have been suggested. A good sulfonamide dressing is 3 per cent sulfadiazine in 8 per cent triethanolamine,[29] applied hourly until a thin, pliable, elastic, and translucent eschar results. Sulfonamide in solid form or as wet dressings has been used to prepare areas for early skin grafting. Another excellent technique for preparing an infected area for skin grafting is to frost it daily with a sulfanilamide-sulfathiazole mixture and then cover it with wet dressings of 1:3,300 azochloramide. Potentiation of the sulfonamide activity may thereby occur.[27]

Sulfonamide applied locally into the peritoneal and other body cavities is beneficial in prevention of infection after contamination of these cavities has resulted from disease or accident. Either sulfanila-

ability to produce a local tissue concentration 50 to 100 times as high as can be obtained by systemic administration, and to have it persist for a period of twenty-four to forty-eight hours or longer while the implanted drug is being absorbed. The effectiveness of local sulfonamide implantation has been observed in the treatment of compound fractures, contaminated wounds, burns, peritonitis, and other affections. However, the results are not always brilliant and frequently it seems the bacterial infection is merely delayed or attenuated. It must be remembered that the sulfonamides are bacteriostatic in therapeutic doses, not bacteriocidal, and tissue immunity is essential for eradication of all organisms.

The absorption of sulfonamide after local implantation is good, regardless of site, and it is usually complete in eight to twenty-four hours. High blood concentrations can be obtained at that time. Sulfanilamide has a higher local solubility and greater diffusibility in the tissues than sulfathiazole, and creates less exudation of tissue fluids in the wound. At its upper limits of solubility it seems to be as effective an antibacterial agent as are the other sulfonamide compounds at their peaks of local solubility for the majority of organisms ordinarily present in contaminated wounds. Sulfathiazole is less soluble, tends to cake in the tissues, creates more foreign body reaction, and is absorbed over a twenty-four- to forty-eight-hour period or longer. But, since sulfathiazole is effective against a wider variety of organisms and remains longer locally, many surgeons consider it advisable to implant a mixture of equal parts of sulfanilamide-sulfathiazole for local use, using, if available, the microcrystals of sulfathiazole which are more soluble. Sulfadiazine has been shown to be effective on local application, but it has a low solubility. Because of the rapid local absorption of these drugs, it is important to administer a sulfonamide in full doses by mouth or parenterally, and for this sulfadiazine is the drug of choice, regardless of the offending organism. The administration of sulfadiazine should be continued in full doses for seven to ten days.

In an effort at prophylaxis of wound infection, particularly if definitive surgical treatment of the contaminated wound must be delayed for several hours or longer, immediate local implantation of sulfanilamide or a mixture of equal parts of sulfanilamide-sulfathiazole should be carried out. A prophylactic oral or parenteral dose of sulfadiazine is well administered simultaneously. The usual initial dose of sulfadiazine is 4 Gm., and the subsequent maintenance dose is 1 Gm. every six hours, day and night.

The dosage of sulfonamide for local use is approximately 0.10 Gm. per square inch. Up to 20 Gm. may be instilled into larger wounds. More sulfonamide may be instilled if the wound is left open. Practically, the wound need only be "frosted" or "sprinkled" with a thin uniform film of sulfonamide. It is important that the sulfonamide be distributed evenly and uniformly in the wound, and not thoughtlessly poured into

to sulfathiazole or sulfadiazine, sulfathiazole possibly being preferable for coagulase positive staphylococci. *P. vulgaris* and *Str. fecalis* respond poorly to sulfanilamide, and only moderately to full doses of sulfathiazole or sulfadiazine. Sulfathiazole or sulfadiazine in doses of 3 to 6 Gm. daily yields in the urine a concentration of 20 to 75 mg. per 100 c.c. This dosage is sufficient to inhibit the growth of most organisms commonly present in urinary tract infections whether one is dealing with a cystitis or pyelonephritis. Any obstruction to the free flow of urine must be removed, for stasis predisposes to and aggravates any infection of the urinary tract. Urinary diuresis in itself is of value in the treatment of urinary tract infections, and decreases the incidence of renal complications from sulfonamide therapy. Fluids should be forced to at least 3000 c.c. daily, and a daily output of more than 1000 c.c. must be maintained. Alkalinization of the urine by oral bicarbonate or sodium citrate is advisable. Also, sulfonamides in smaller doses are used prophylactically prior to instrumentation of the urinary tract and postoperatively for an inlying catheter.

The sulfonamide effect is one of bacteriostasis, and tissue immunity evokes final recovery. Chronic infections without demonstrable obstruction are difficult to cure by any drug.

Intestinal Antisepsis.—Sulfaguanidine was developed in an attempt to reduce the number of bacteria in the colon preceding operations upon the gastrointestinal tract. This drug reduced the coliform count in the stool to a great extent, but it proved to be absorbed irregularly, occasionally was toxic, and was inactive in the presence of ulcerative lesions of the intestines. Succinylsulfathiazole (sulfasuxidine) was introduced later by Poth and Knotts,[31] Firor,[32] and Poth,[33] and from the clinical and experimental studies reported this drug appears to be exceedingly promising as an intestinal antiseptic. It is strongly bacteriostatic, absorbed poorly, nontoxic, and is effective in the presence of ulcerative lesions of the bowel. At most 5 per cent of the drug is excreted in the urine, and because of its rapid excretion and relatively high solubility (450 mg. per cent) renal complications have not been encountered.

The initial dose is 0.25 Gm. per kilogram of body weight, and the subsequent daily dose is 0.25 Gm. per kilogram given in six divided doses. Larger doses are tolerated if given at hourly intervals, and up to 0.5 Gm. per kilogram per day may be given with safety. In one to seven days the stools become semifluid, odorless, more mucoid, and reduced in bulk. The count of colon bacilli falls from 10,000,000 per gram of wet stool to approximately 1000 per gram of wet stool. The mechanism of action is similar to that of other sulfonamides, and the active substance is probably sulfathiazole, formed by hydrolysis by bacterial cells in the large bowel. The concentration of sulfathiazole in the feces with clinical doses is 50 to 200 mg. per cent. To be effective

mide or a mixture of sulfanilamide-sulfathiazole may be used. Absorption is particularly rapid from the peritoneal cavity and systemic administration of the drug, preferably sulfadiazine, is imperative.

Sodium sulfapyridine is so alkaline (pH 10.6) that it must never be used for local implantation. Tissue necrosis with subsequent sloughing has commonly ensued. Recent experimental and clinical studies on the local use of the sodium salts of sulfathiazole and sulfadiazine[11] seem to indicate that these salts, especially the sodium sulfadiazine, may be safely implanted in the subcutaneous or intramuscular tissues. The pH of a concentrated solution of sodium sulfadiazine (over 5 per cent) is 9.4, of sodium sulfathiazole 9.8. The local application of the sodium salts of sulfathiazole and especially of sulfadiazine is an advance which would obviate the insolubility and caking of these drugs in the wound and would permit the far greater antibacterial potency of these two drugs over sulfanilamide. At present, however, insufficient evidence exists to warrant the intraperitoneal use of any of the sodium salts, and they should be used with caution in the wounds of soft tissues.

Perrin Long, in a recent article,[30] summarizes well the present status of local sulfonamide therapy. In his opinion a combination of systemic with local therapy offers the best chance for prevention of wound infection and for its cure once an infection has become established. He recommends sulfadiazine by mouth in doses high enough to maintain a blood concentration of 4 to 7 mg. per 100 c.c. as the most desirable drug for systemic administration; sulfanilamide alone is recommended for local use. "From all points of view, sulfanilamide seems at the present time to be the drug of choice for topical application. It is to be remembered that necrotic tissue and pus contain sulfonamide inhibitors and that every effort should be made to eliminate these inhibitors before sulfanilamide is applied locally. Care should always be taken to prevent the caking of sulfanilamide in the wound, and this can be accomplished by applying moist gauze dressings following the application of sulfanilamide to the wound. In the absence of clinical infection, there is little reason to continue oral therapy with sulfadiazine more than five to seven days. However, to prevent secondary infections from occurring after primary prophylaxis has been successful, it is necessary to apply sulfanilamide powder locally until wound healing is complete." No one disputes the effectiveness of sulfanilamide for local use in contaminated wounds, but many surgeons prefer a mixture of sulfanilamide-sulfathiazole in equal parts, for reasons already explained.

Urinary Tract.—The common offending organisms in infections of the urinary tract are *Esch. coli, Aerobacter aerogenes,* staphylococci, *Proteus vulgaris,* and *Str. fecalis.* Infections with the streptococci of Lancefield Group A, which are responsible for serious streptococcal infections in man, are extremely rare in the urinary tract. The organisms of the coli group and staphylococcal group are very susceptible

intraperitoneal use is still counseled against. Succinylsulfathiazole (sulfasuxidine) at the moment is the best drug for intestinal antisepsis. The sulfonamides are merely desirable surgical adjuncts and one must never fail to recognize the importance of well-established surgical principles. The sulfonamides are dangerous therapeutic weapons; their toxicity must be anticipated and toxic symptoms treated vigorously if they occur.

The author wishes to express his gratitude to F. L. Reichert, W. C. Cutting, and J. F. Menke for their assistance in the preparation of this paper.

REFERENCES

1. Domagk, G.: Deutsche med. Wchnschr. 61: 250, 1935.
2. Whitby, L. E. H.: Lancet 1: 1210, 1938.
3. Marshall, E. K., Jr., and Long, P. H.: J. A. M. A. 112: 1671, 1939.
4. Fosbinder, R. J., and Walter, L. A.: J. Am. Chem. Soc. 61: 2032, 1939.
5. Lott, W. A., and Bergeim, F. H.: J. Am. Chem. Soc. 61: 3593, 1939.
6. Roblin, R. O., Jr., Williams, J. H., Winnick, P. S., and English, J. P.: J. Am. Chem. Soc. 62: 2002, 1940.
7. Finland, M., Peterson, O. L., and Goodwin, R. A.: Ann. Int. Med. 17: 6, 920, 1942.
8. Marshall, E. K., Jr., Braxton, A. C., White, H. J., and Litchfield, J. T.: Bull. Johns Hopkins Hosp. 67: 163, 1940.
9. Poth, E. J., and Firor, W. M.: Ann. Surg. 114: 663, 1941.
10. Jensen, N. K., Johnsrud, L. W., and Nelson, M. C.: SURGERY 6: 1, 1939.
11. Fox, C. L., Jr.: Arch. Surg. 45: 754, 1942.
12. Lockwood, J. S., and Lynch, H. M.: J. Immunol. 35: 155, 1938.
13. Lockwood, J. S.: J. A. M. A. 115: 1190, 1940.
14. Lockwood, J. S.: Surg. Gynec. & Obst. 72: 307 (2A), 1941.
15. Lockwood, J. S., and Lynch, H. M.: J. A. M. A. 114: 935, 1940.
16. Locke, A., Main, E. R., and Mellon, R. P.: Science 88: 620, 1938.
17. Stamp, T. C.: Lancet 2: 10, 1935.
18. Woods, D. D.: Brit. J. Exper. Path. 21: 74, 1940.
19. Fox, C. L., Jr.: Am. J. M. Sc. 199: 487, 1940.
20. Shaffer, A.: Science 89: 547, 1939.
21. Lyons, J. J. A., Chimenko, D. R., and Gorham, L. W.: J. Clin. Investigation 41: 648, 1942.
22. Taplin, G. V., Custer, E. A., and Young, L. E.: J. A. M. A. 121: 5, 313, 1943.
23. Whipple, A. O.: Military Surgery Manual No. 5, Burns, Shock, Wound Healing, and Vascular Injuries, Philadelphia, 1943, W. B. Saunders Company, p. 177-194.
24. Pilcher, C., Angelucci, R., and Meacham, W. F.: J. A. M. A. 119: 927, 1942.
25. Clark, W. G., Strakosch, E. A., and Levitan, N. I.: J. Lab. & Clin. Med. 28: 188, 1942.
26. Wilson, J. C., and McKeever, F. M.: J. Bone & Joint Surg. 25: 41-48, 1943.
27. Schnelkes, F. C., and Wyss, O.: Proc. Soc. Exper. Biol. & Med. 49: 263, 1942.
28. Veal, J. R., and Klepser, R. G.: SURGERY 10: 947, 1941.
29. Pickrell, K. L.: Bull. Johns Hopkins Hosp. 69: 217, 1941.
30. Long, P. H.: J. A. M. A. 121: 303, 1943.
31. Poth, E. J., and Knotts, F. L.: Arch. Surg. 44: 208, 1942.
32. Firor, W. M.: Ann. Surg. 115: 829, 1942.
33. Poth, E. J.: J. A. M. A. 120: 265, 1942.

the drug must come into *prolonged intimate contact* with all portions of the bowel mucosa.

The action of the drug is impaired appreciably by diarrhea, constipation with inspissated stools, and the simultaneous use of liquid petrolatum or other cathartics. Larger doses are required in the presence of ulcerative lesions, but the drug remains effective. The proper preoperative preparation consists in the omission of enemas, cathartics, and petrolatum. A nonresidual diet is advisable. Full doses of the drug should be administered, and the optimum time for surgery may be judged by bacterial counts on the stool or by observations of the character of the stool. Since the drug is well tolerated, with little nausea and vomiting, it may be given postoperatively as soon as the patient takes water. Breaking the tablets up and dissolving them in water facilitates administration. In practice, the drug has failed only in the presence of severe diarrhea or of a blind loop obstruction.

It must be emphasized that succinylsulfathiazole is merely an adjunct to surgery of the gastrointestinal tract, and should never permit one to nullify the observance of well-established surgical principles in the pre- and postoperative care. Experience with this drug is still limited. However, it is not effective in combating typhoid, paratyphoid, *Str. fecalis*, or the proteus group of organisms.

SUMMARY

The sulfonamide drugs are powerful chemotherapeutic agents, specific in their action on certain organisms and without effect on others. Those organisms not affected may be resistant naturally, or they may have an acquired resistance. Their mode of action is not known accurately, but it is probable that bacteriostasis rests upon the inactivation of an enzyme or enzyme-substrate system necessary for bacterial growth. The main theories of the mode of action have been presented. Peptone, para-amino-benzoic acid, necrotic tissue, and certain bacterial and yeast extracts inhibit the bacteriostatic action of these drugs. The sulfonamides are essentially bacteriostatic not bacteriocidal, and the natural defense mechanisms of the body have to complete the destruction of the bacteria. Sulfonamides inhibit bacterial growth, and prevent overwhelming intoxication by bacterial infection but tissue immunity must be mobilized to realize complete recovery.

Sulfathiazole is regarded as the drug of choice for staphylococcal infections, but, clinically, it is probably no more effective than sulfadiazine, which is slightly less toxic. For all other infections which are susceptible to the sulfonamides, sulfadiazine is the drug of choice. For local use sulfanilamide or a mixture of sulfanilamide and sulfathiazole is the best, regardless of the site of local implantation. The local use of sodium sulfadiazine and sodium sulfathiazole for soft tissue wounds seems warranted in consideration of recent studies, but their

SURGERY

VOL. 14 SEPTEMBER, 1943 No. 3

Original Communications

Symposium on Surgical Management of Malignancy of the Colon

SURGERY OF THE TERMINAL ILEUM, CECUM, AND RIGHT COLON

ALLEN O. WHIPPLE, M.D., NEW YORK, N. Y.

(From the Department of Surgery, Columbia-Presbyterian Medical Center, New York, N. Y.)

THE scope and radical character of abdominal surgery, especially in the field of adequate cancer removal, has been greatly extended in the past few years. Several factors are responsible for this advance, among them a better understanding of the importance and the means of maintaining fluid, electrolyte and protein balance, the prevention and treatment of shock by plasma and whole blood transfusion before, during, and after operation, and the control of infection by means of the bacteriostatic sulfonamide drugs. Examples of these very radical procedures are the removal of cancers of the cardia and fundus of the stomach by abdominothoracic resection, or by total gastrectomies, and pancreaticoduodenectomies for cancer of the ampullary region, common duct, and pancreas.

However, in resections of the gastrointestinal tract there are certain fundamental principles that have always determined the kindly healing of the sutured intestine and the peritoneum. It is wise to remember these principles in these days of indiscriminate administration of the sulfonamide drugs locally and systemically. The first of these principles is the maintenance of an adequate blood supply to the zone of anastomosis by careful preservation of the blood vessels in the mesentery supplying that zone. Second, the placing of an accurate seromuscular or seroserous suture to provide an adequate apposition of peritoneum on either side of the suture line. This can be accomplished most certainly with a fine silk suture on a fine needle, using a Lembert or Cushing type

Received for publication, April 26, 1943.

Book Reviews

Physiology in Aviation. By Chalmers L. Gemmill, B.S., M.D., Commander, M.C., U.S.N.R., Associate Professor in Physiology, Johns Hopkins University, School of Medicine, Baltimore, Md., Instructor in Physiology, School of Medicine, Naval Air Station, Pensacola, Fla. Pp. 124, with 18 tables. Springfield, Ill., 1943, Charles C. Thomas, Publisher. $2.

This book by Gemmill is a primer on the subject covered by its title, although brief, it is not vague and reflects its author's valuable teaching experience. The preface states it to be material covered in the lectures on physiology in the School of Aviation Medicine, Naval Air Station, Pensacola, Fla. It would seem to be an excellent guide for medical personnel who give instruction to aviators on the physiologic disturbances encountered in flight.

The Management of Fractures, Dislocations, and Sprains. By John Albert Key, M.D., and H. Earle Conwell, M.D., F.A.C.S. Ed. 3. St. Louis, 1942. The C. V. Mosby Company. $12.50.

The new third edition of this book contains 1,300 pages with many illustrations, photographs, and roentgenograms. Since the publication of the first edition in 1934, this book represents the best in its field published by American authors, and is not overshadowed by any book in any language.

Along with revision of the chapter on compound fractures, a section also has been added on war wounds. This new feature will be both attractive and beneficial to men who will be called upon to treat patients in the armed forces.

The chapters on fractures of the spine, hip, humerus, and foot have been revised to some extent.

With the advent of war, many trained men have been and are being called into the services. This leaves more untrained men at home to care for the civilian population. It seems that a more thorough description of the technique of manipulation and operative treatment of fractures might be of great benefit to these men.

Not only have the authors considered the management of acute injuries, but they have, in many instances, discussed and outlined the treatment of old injuries requiring reconstructive surgery. Many photographs and x-rays have been included to elucidate better the diagnosis, treatment, and end result in a variety of cases.

This book should be in the hands of all men who are doing fracture work today.

TABLE II

MILLER-ABBOTT INTUBATION
ILEOCOLECTOMIES
1938 TO 1942*

ILEOCOLECTOMIES	NO	P.O. DEATHS	MORTALITY %	WITH M.-A. TUBE		WITHOUT M.-A. TUBE	
				CASES	P.O. DEATHS	CASES	P.O. DEATHS
Cancer	57	7	12.3	41	4	16	3
Other diseases	29	4	13.8	18	1	11	3
Total	86	11	12.8	59	5 (8.5%)	27	6 (22.2%)

Postoperative deaths with the Miller-Abbott Tube:

1. Patient did well with tube in stomach; died 7 days after the tube was removed of general peritonitis. (Other.)
2. Patient died of pneumonia; tube removed 24 hours before death, after colostomy was opened.
3. Tube well down and functioning well; Levine tube necessary.
4. Peritonitis, auricular fibrillation. Patient died 19 days postoperatively; first intubation successful, second intubation 15 days postoperatively unsuccessful.
5. Patient died of embolus when getting up the first time.

*Of 86 ileocolectomies, 59 or 68.6 per cent of the patients had the Miller-Abbott intubation prior to operation. In all but five of these, the tube passed beyond the stomach.

of stitch through peritoneum and submucosal layers. This is far more important than clumsy attempts at suturing the crushed mucosae. In fact, in the many techniques described for so-called aseptic anastomosis, the mucosal stitch is never used, and reliance is placed solely on the seromuscular mattress sutures. Third, and most important, is to prevent tension on the suture line with its accompanying tissue necrosis, by keeping the proximal segment of bowel empty of gas and fecal content. If the bowel proximal to the anastomosis is empty, if the blood supply to the zone of anastomosis is adequate, and if the peritoneal fusion of the anastomotic line has been accomplished, healing will always progress satisfactorily and drug therapy will not be necessary, unless gross contamination has occurred or unless other indications for drainage are present.

These principles have long been recognized by thoughtful and intelligent surgeons, and the maintenance of a collapsed proximal loop has been accomplished in the past by making an enterostomy proximal to the anastomosis, usually by means of a rubber tube or catheter, using the Witzel technique. In resections of the left colon a cecostomy is indicated for the same reason, and if obstruction has been present, the cecostomy should always be done a week or more before the resection.

Until recently these principles were at times difficult to carry out, especially in the cases where obstruction had resulted in long-standing distention and hypertrophy of the proximal loop. This was one of the chief reasons why side-to-side instead of end-to-end or end-to-side anastomosis was advocated, because in these patients the distended proximal bowel made it mandatory to use the side-to-side stoma. An enterostomy which was frequently done as a safety valve, to reduce tension on the suture line, provided one more chance of contamination and leak-

TABLE I

RADICAL COLON OPERATIONS
(1933 TO 1942)

ILEOCOLECTOMIES			RESECTIONS						RANKIN					MIKULICZ					
YEAR AND			LEFT COLON			TRANSVERSE			LEFT COLON			TRANSVERSE		LEFT COLON			TRANSVERSE		
CASES	P.O. DEATHS		CASES	P.O. DEATHS		CASES	P.O. DEATHS		CASES	P.O. DEATHS		CASES	P.O. DEATHS	CASES	P.O. DEATHS		CASES	P.O. DEATHS	
	NO.	%		NO.	%		NO.	%		NO.	%				NO.	%		NO.	%
Cancer																			
(1933-1937) 38	8	21	36	8	22.2	9	3	33.3	16	5	31.5	2	0	10	2	20	4	1	25
(1938-1942) 57	7	12.3	75	6	8	14	2	14.3	14	1	7.1	4	0	12	5	41.7	1	0	
(1933-1942) 95	15	15.8	111	14	12.6	23	5	21.7	30	6	20	6	0	22	7	31.8	5	1	20
Other Diseases																			
(1933-1937) 22	2	9.1	14	1	7.1	2	0		1	1		0		0			0		
(1938-1942) 29	4	13.8	14	2	14.3	4	2	50	2	0		0		1	0		0		
(1933-1942) 51	6	11.8	28	3	10.7	6	2	33	3	1	33.3	0		1	0		0		
Total (Cancer and Other Diseases)																			
146	21	14.4	139	17	12.2	29	7	24.1	33	7	21.2	6	0	23	7	30.4	5	1	20

TABLE V

RANKIN AND MIKULICZ PROCEDURES
CANCER AND OTHER DISEASES OF THE COLON
(EXCLUSIVE OF TRANSVERSE)
1933 TO 1942

	1933-1937		1938-1942		1933-1942	
	CASES	P.O. DEATHS	CASES	P.O. DEATHS	CASES	P.O. DEATHS
Rankin:						
Cancer	16	5 (31.5%)	14	1 (7.1%)	30	6 (20.0%)
Other diseases	1	1	2	0	3	1 (33.3%)
Total	17	6 (35.3%)	16	1 (6.25%)	33	7 (21.2%)
Mikulicz:						
Cancer	10	2 (20%)	12	5 (41.7%)	22	7 (31.8%)
Other diseases	0		1	0	1	0
Total	10	2 (20%)	13	5 (38.5%)	23	7 (30.4%)

In addition to the above procedures the following operations were also performed:

Rankin:
15 preliminary cecostomies (5 P.O. deaths)
1 accompanying enterostomy (1 P.O. death)
Mikulicz:
10 preliminary cecostomies (2 P.O. deaths)
2 accompanying cecostomies (1 P.O. death)

Average postoperative hospital days of the survivors in, Rankin type, 46.08 days (1,198 postoperative days for 26 survivors); Mikulicz, 48.75 days (780 postoperative days for 16 survivors).

TABLE VI

TRANSVERSE COLON
RADICAL OPERATIONS
CANCER OF COLON

	RESECTIONS		RANKIN		MIKULICZ	
	CASES	P.O. DEATHS	CASES	P.O. DEATHS	CASES	P.O. DEATHS
1933 1937	9	3 (33.3%)	2	0	4	1 (25%)
1938-1942	14	2 (14.3%)	4	0	1	0
Total	23	5 (21.7%)	6	0	5	1 (20%)
OTHER DISEASES						
1933-1942	6	2 (33.3%)	0		0	
Total	29	7 (24.1%)				

In addition to the above procedures the following operations were also performed:
Resections:

4 preliminary cecostomies (2 P.O. deaths)
9 accompanying cecostomies (1 P.O. death)
2 accompanying appendicostomies (0 P.O. death)
3 accompanying colostomies (1 P.O. death)
Rankin:
3 preliminary cecostomies (0 P.O. death)
Mikulicz:
1 preliminary cecostomy (0 P.O. death)

Average postoperative hospital days of the survivors in resections, 43.45 days (956 postoperative days for 22 survivors), Rankin, 44.5 days (267 postoperative days for 6 survivors), Mikulicz, 60.25 days (241 postoperative days for 4 survivors).

TABLE III

RESECTIONS OF LEFT COLON

CARCINOMA OF COLON

1933 TO 1942

YEARS	CASES	P.O. DEATHS	MORTALITY (%)
1933 - 1937	36	8	22.2
1938 - 1942	75	6	8
Total	111	14	12.6

In addition to the resections, the following operations were also performed in this group:

41* preliminary cecostomies (4 P.O. deaths)
22 accompanying cecostomies (2 P.O. deaths)
2 subsequent cecostomies (0 P.O. deaths)
4 preliminary colostomies (0 P.O. deaths)
13 accompanying colostomies (2 P.O. deaths)
2 preliminary appendicostomies (0 P.O. deaths)
5 accompanying appendicostomies (2 P.O. deaths)

*One of these was performed at another hospital.

Average postoperative hospital days of the survivors in this group; 10.06 days per patient (3,886 postoperative days for 97 survivors).

TABLE IV

RESECTIONS OF LEFT COLON

OTHER DISEASES EXCLUSIVE OF CANCER OF COLON

1933 TO 1942

YEARS	CASES	P.O. DEATHS	MORTALITY (%)
1933 - 1937	14	1	7.1
1938 - 1942	14	2	14.3
Total	28	3	10.7

DISEASE	RESECTIONS	P.O. DEATHS
Diverticulitis	6	3
Redundant colon	3	0
Ulcerative colitis	2	0
Megacolon	2	0
Intussusception	2	0
Cancer of rectum	2	0
Stricture	1	0
Fibromyoma	1	0
Endometrioma	1	0
Tuberculosis	1	0
Prolapsing colostomy	1	0
Fistula	1	0
Regional ileitis	1	0
Polyposis	1	0
Ileus	1	0
Volvulus	1	0
Lipoma	1	0
Total	28	3

In addition to the resections, the following operations were also performed in this group:

4 preliminary cecostomies (1 P.O. death)
8 accompanying cecostomies (0 P.O. death)
1 preliminary colostomy (0 P.O. death)
5 accompanying colostomies (1 P.O. death)

Average postoperative hospital days of the survivors in this group; 56 days per patient (1,350 postoperative days for 25 survivors).

an enterostomy done at the time of resection. Furthermore, the two-stage procedure was done away with in favor of the one-stage operation.

In our own experience we have found that with the proximal bowel decompressed, the hazard of spillage and contamination is eliminated and the anastomosis by the open method, with careful protection of the wound and remaining peritoneum and accurate suture technique, is as safe as the so-called aseptic methods, and more certain of giving an adequate stoma and avoiding subsequent leakage.

The tables summarize the results and are self-explanatory. Attention is called to Table II to compare the mortality in cases in which the intestinal intubation was done and in cases where it was not done.

TABLE VII

ILEOCOLECTOMIES
1933-1942

	1933-1937		1938-1942		1933-1942	
	CASES	P.O. DEATHS	CASES	P.O. DEATHS	CASES	P.O. DEATHS
Carcinoma of colon	38	8 (21%)	57	7 (12.3%)	95	15 (15.8)
Other diseases (see below)	22	2 (9.1%)	29	4 (13.8%)	51	6 (11.8)
Total	60	10 (16.7%)	86	11 (12.8%)	146	21 (14.4)

OTHER DISEASES

	1933-1937		1938-1942		1933-1942	
	CASES	P.O. DEATHS	CASES	P.O. DEATHS	CASES	P.O. DEATHS
Regional ileitis	9	0	14	1	23	1
Ulcerative colitis	3	0	2	1	5	1
Diverticulitis	2	0	0		2	0
Tuberculosis	4	1	2	0	6	1
Intussusception	1	0	1	0	2	0
Gangrene	1	1	2	1	3	2
Adenomatosis	2	0	0		2	0
Ileus	0		2	1	2	1
Fistula	0		3	0	3	0
Ulcer of cecum	0		1	0	1	0
Visceroptosis	0		1	0	1	0
Cancer of kidney	0		1	0	1	0
Total	22	2	29	4	51	6

Average postoperative days of the survivors in this group; 37.88 days (4,735 postoperative days for 125 survivors).

age, had to be done at the end of a difficult procedure, and very often did not work satisfactorily after operation. Furthermore, the presence of a distended bowel with the accompanying edema of the cancerous lesion in the presence of obstruction convinced many able surgeons that a two-stage operation for cancer of the cecum and ascending colon was necessary, using a side-to-side ileocolostomy as a first stage operation, to be followed later by the excision of the growth. This required two anesthesias, two operations, and in many instances the second stage was either refused because of a stormy first stage or because the patient delayed until the growth had metastasized or extended far beyond the site found at the first procedure.

Our strikingly favorable results in decompressing the small intestine in cases of inflammatory ileus and ileus due to bands and adhesions by the use of the Miller-Abbott tube, soon after its demonstration by the authors of this epoch-making discovery, led us to use it as a preoperative measure in resections of the terminal ileum, cecum, and right colon. The immediate improvement in the morbidity and mortality of our operations for carcinoma of the cecum, ascending colon, and hepatic flexure and for such lesions as regional enteritis, especially in terminal ileitis with resection of the cecum and right colon, with end-to-side ileocolostomy in all these procedures, has convinced us that preoperative and postoperative decompression of the proximal intestine, by means of the Miller-Abbott tube, is the method of choice and far superior to

A better understanding of the colon circulation may be had if we divide its arterial arrangement into three parts:

1. The main arterial trunks and branches
2. The marginal artery (of Drummond) with its vascular loops and vasa recta
3. The blood vessels within the bowel wall

These divisions may apply to the entire larger bowel, except the rectum, where the same arrangement of the circulation does not exist.

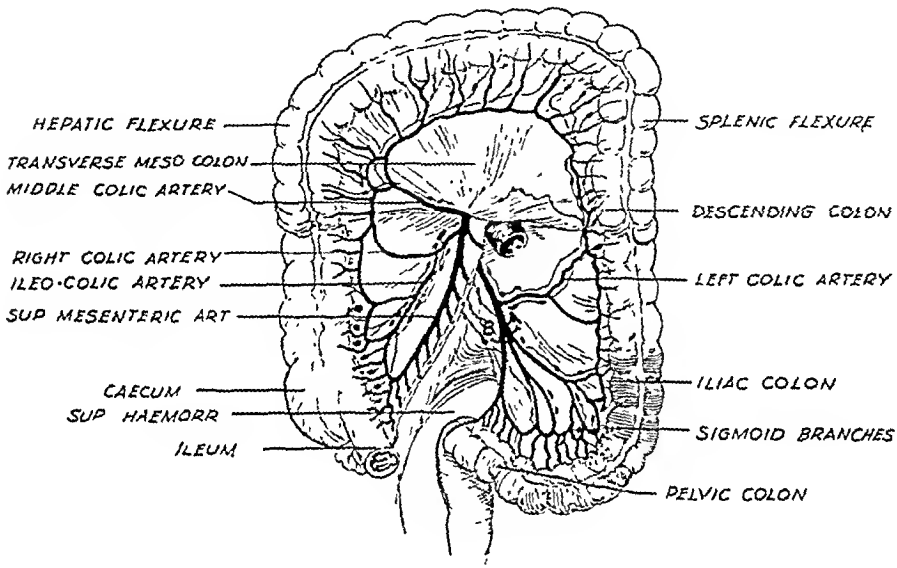

Fig. 1.—Diagram showing blood supply and the lymphatic distribution to the colon.

1. *The Main Arterial Trunks and Branches.*—The superior mesenteric through its right colic and middle colic branches, supplies the ascending colon, the hepatic flexure, and transverse colon. The remaining part of the colon and the upper half of the rectum are supplied by the left colic and sigmoid branches of the inferior mesenteric artery. One of these branches, the terminal branch of the inferior mesenteric, is the superior hemorrhoidal. The remainder of the rectum and the anus are supplied by the middle hemorrhoid from the internal iliac and the inferior hemorrhoidal from the internal pudic branch of the internal iliac. It is evident that the rectal circulation is much more adequate than the other sections of the large bowel (Fig. 2).

Abnormalities of the blood vessels of the colon are present occasionally. The superior mesenteric artery may be double, and it may supply the whole intestine from the duodenum to the end of the rectum, the inferior mesenteric artery being absent.

Again the superior mesenteric artery may give branches to the hepatic, renal, and middle colic arteries; also its left colic branch may

THE BLOOD SUPPLY OF THE LARGE BOWEL WITH REFERENCE TO RESECTION

ALBERT O. SINGLETON, M.D., GALVESTON, TEXAS
(From the Department of Surgery, Medical Branch, University of Texas)

THE large bowel lends itself to surgical procedures quite conveniently, provided the surgeon familiarizes himself with essential anatomical facts. This knowledge pertains particularly to its blood supply. The blood supply to the stomach is so abundant that one may here do almost any type of resection or plastic procedure with perfect confidence of sufficient vascularity of the remaining tissues for certain healing. This is generally true with the small intestine, but certainly not with the large intestine.

The arrangement of the arteries to the colon has been cleverly demonstrated by Jamieson and Dobson, Rubesch, Drummond, Steward and Rankin, and others. The injection of the main arteries with an opaque medium and the use of x-ray film have been the chief methods employed. These investigations have been stimulated by the failures in colon surgery due to an insufficient blood supply to the part of the bowel remaining after resection of certain segments for carcinoma and other diseases.

It will be noted in Fig. 1 that lymph glands are very numerous along the mesenteric border in the large intestine, and that lymphatic channels follow closely the blood vessels to the origin of the mesenteric arteries at the root of the mesenteries. The extent of lymphatic removal is often limited because to remove them means sacrificing blood vessels that are essential to the vitality of bowel which must be left. The necessity of wide removal of lymphatics is no less in cancer of the colon than elsewhere in the body. In one's zeal for extensive removal of lymphatic glands, such previously mentioned large vascular trunks may be ligated, endangering the circulation to the ileum at times, and in longer lengths of colon than anticipated, with immediate grave danger to the patient.

The blood supply to the large bowel is from three major sources (Fig. 1):

1. The superior mesenteric artery
2. The inferior mesenteric artery
3. The internal iliac branches: (1) middle hemorrhoidal, (2) inferior hemorrhoidal, and (3) pudic

Received for publication, July 12, 1913.

not anastomose with the middle colic artery, as is found in some rodents.

The *right colic artery* is quite inconstant. It originates from the superior mesenteric in 40 per cent of cases, from the middle colic in 30 per cent, from the ileocolic in 12 per cent, and in 18 per cent it is absent (Rankin and Graham). The middle colic artery is also irregular. It supplies the greater part of the circulation to the splenic flexure of the colon and a still greater part of the circulation of this area when the left colic is absent or not well developed. A failure of anastomosis of the middle colic and left colic arteries, which occurs in 5 per cent of cases (Grant), results in a break in the continuous flow of blood through the marginal arteries of the colon near its mesenteric border from the cecum through the sigmoid segment (Fig. 3).

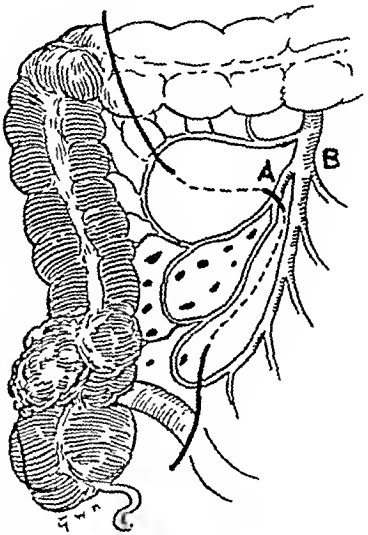

FIG. 4.—The area of resection of the cecum with ligation of ileocolic artery near the superior mesenteric at A. B, Main branch of superior mesenteric which may be ligated inadvertedly when an attempt is made to remove the lymphatic glands and would result in death of a large part of the small intestine.

A review of the circulation of the colon, by examining the illustrations, will make it evident that care should be taken in the placing of ligatures when resecting certain parts of the large bowel in order that the bowel to be left will not be endangered by inadequate blood supply. In the very fat mesocolon one may have difficulty in seeing the large blood vessels, but ordinarily by lifting the bowel up with the light on the opposite side they may be seen.

For example, in resection of the cecum the ileocolic artery should be ligated at A which denies several inches of the terminal ileum of its circulation but this part of the ileum is to be removed. The circulation of a large part of the small intestine will be impaired if (in going too high) the main trunk of the superior mesenteric is occluded at *B*.

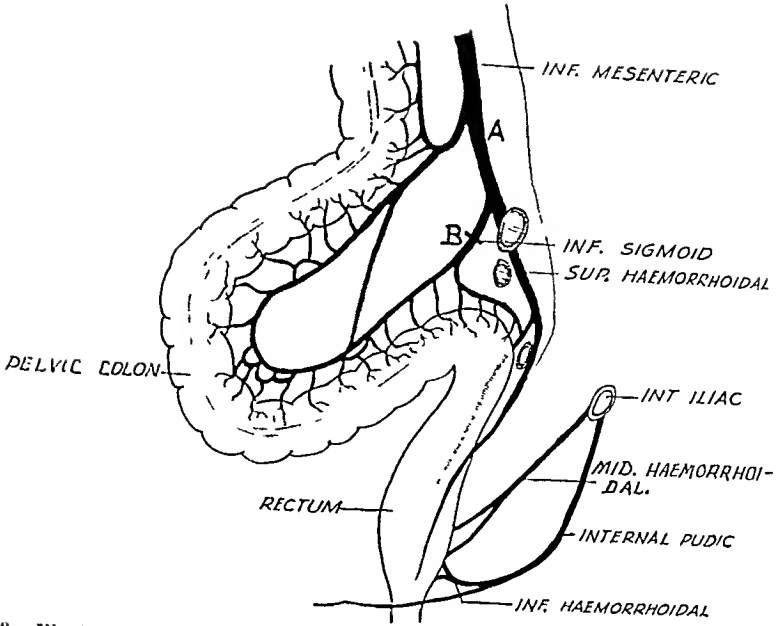

Fig. 2.—Illustration of the blood supply to the rectum which is more richly supplied with blood than the other parts of the large bowel.

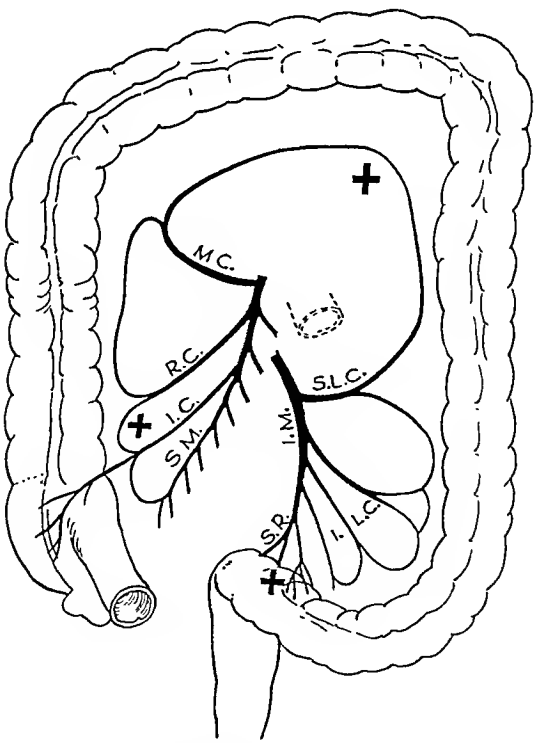

Fig. 3.—X denotes three weak points in the marginal anastomoses: (1) between the ileocolic and right colic, (2) between middle colic and superior left colic, (3) between the inferior left colic and superior rectal. (From Grant, *Method of Anatomy*, Williams and Wilkins Company.)

2. *The Marginal Artery (of Drummond) With Its Vascular Loops and Vasa Recta* (Fig. 7).—The superior mesenteric system is continuous with that of the inferior mesenteric through the junction of the middle colic branch of the former with the left colic branch of the latter. Drummond injected under pressure the inferior mesenteric ar-

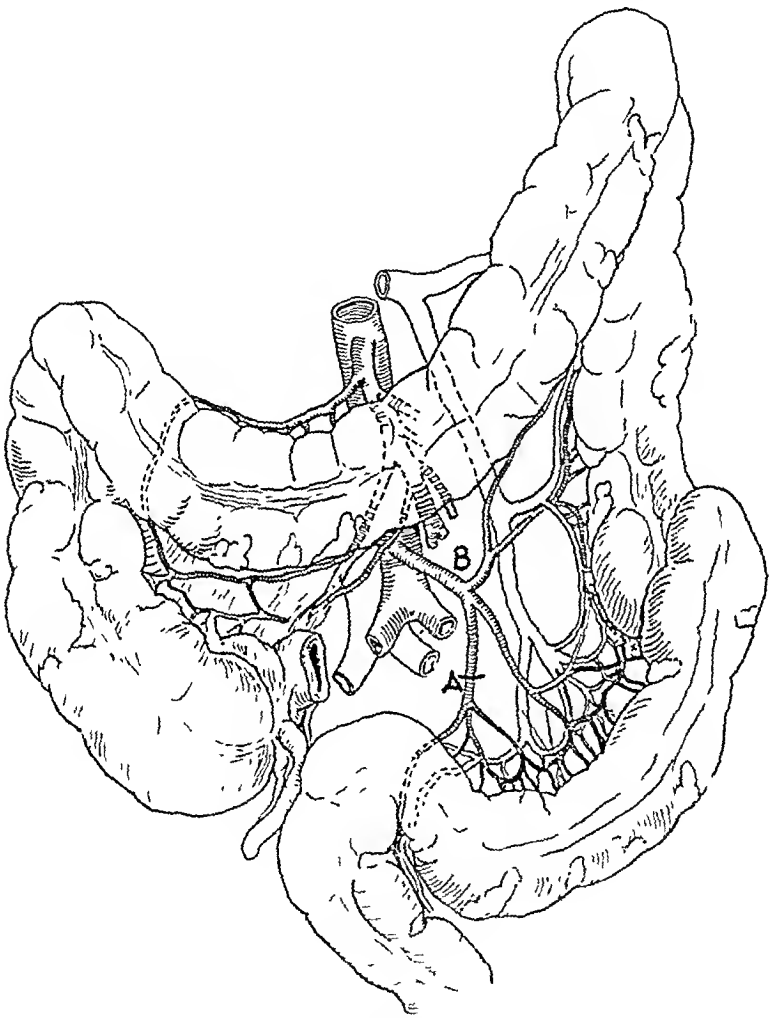

Fig. 6.—Position of ligatures for resection of the rectum. *A*, Ligation of the superior hemorrhoidal and inferior sigmoid allows wide excision and still preserves the circulation to the upper half of the sigmoid. *B*, If ligature is placed on inferior mesenteric above the origin of the left colic the circulation will be lost too high up on the sigmoid for satisfactory colostomy

tery, and the injection passed up through the left colic filling the branches of the superior mesenteric. Rubesch, by injecting through the superior mesenteric artery, pressed the fluid into the inferior mesenteric in the reverse direction. Though the circulation through Drummond's arch from the superior and inferior mesenteric arch is a con-

Again, if in resection of the cecum and right half of the transverse colon (Fig. 5) the *middle colic artery* is tied near its origin from the superior mesenteric at *A*, the middle and left half of the transverse colon may be devitalized, and this may necessitate the removal of almost all the transverse colon, or even the splenic flexure whose circulation may be so impaired due to an inconstant left colic artery, and it would not survive after anastomosis. To avoid devitalizing the middle portion of the colon, this artery should be carefully preserved when doing a gastrointestinal anastomosis through the mesocolon. We know of such accidents having occurred with disastrous results. Generally such an injury to the circulation of the colon by transmesenteric anastomosis is due to injury to the marginal colic artery or its vasa brevia, but occasionally the circulation of the left half of the colon and splenic flexure is dependent upon the middle colic artery where the left colic is poorly developed. (33 per cent of cases, according to Grant.)

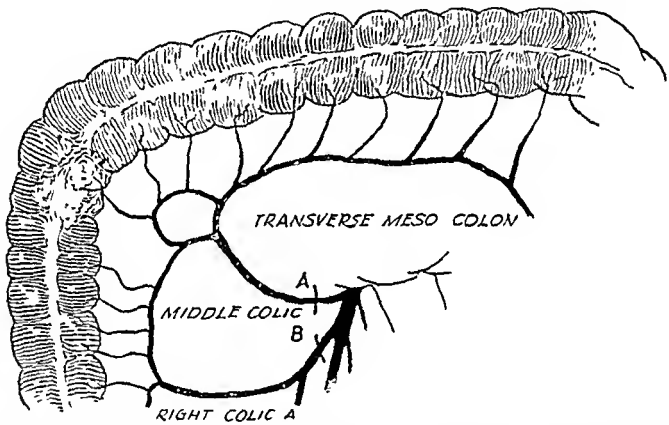

Fig. 5.—In a certain number of cases where the left colic artery does not anastomose too freely with the middle colic past the splenic flexure, resection of the cecum and hepatic flexure may result in extensive devitalizing of the transverse colon when the arteries are tied at *A* and *B*.

In resection of the sigmoid flexure (Figs. 1 and 2) one may impair seriously the circulation of the distal segment of the colon by ligating the inferior mesenteric artery at *A*, or the right sigmoid branch at *B*. This may make anastomosis of the proximal and distal ends of the remaining colon impossible.

In the resection of the *rectum* for cancer (Fig. 6), in order that adequate bowel is removed to include the high lymphatics, the inferior mesenteric artery should be ligated at *A*. This naturally results in devitalizing the sigmoid fairly high up, necessitating the removal of the lower half. But this is not a disadvantage because a more satisfactory sigmoid colostomy results if the terminal loop is short, and with such a short sigmoid terminus, function seems to be better and prolapse of the mucosa is much less likely to occur.

tinuous one, the anastomosis is not so free that one vessel may be occluded and the colon survive depending only upon the circulation from the other one.

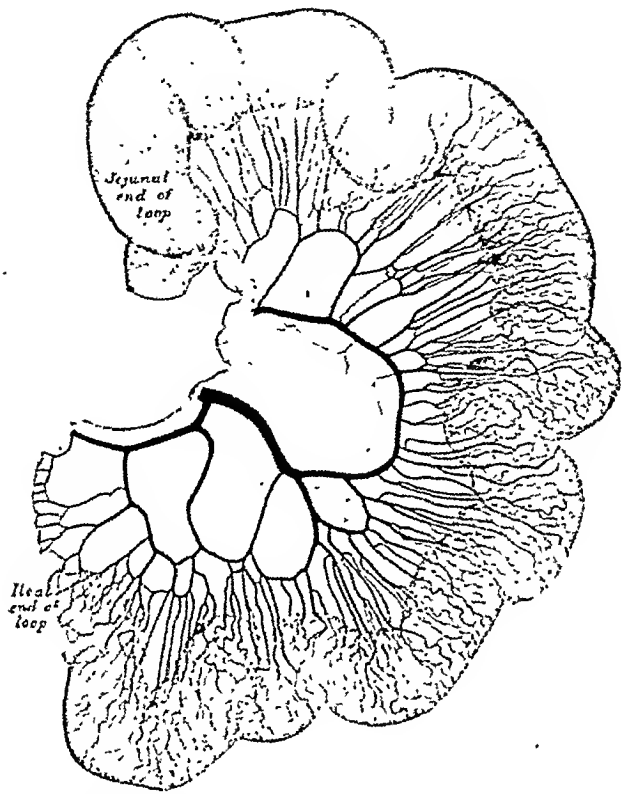

FIG. 9.—Loop of small intestine showing distribution of intestinal arteries. (From a preparation by Mr. Hamilton Drummond.) The arteries and arterioles are numerous in the bowel wall and anastomoses are very free in the ileum and less free in the jejunum (From Gray, *Anatomy*, Ed. 21, Philadelphia, 1924, Lea & Febiger.)

It is also well to call attention to the arrangement of the circulation nearer the bowel wall. Branches coming off the mesenteric arteries from the center of the abdomen form a continuous vessel which within the circle of the colon extends its entire length forming an arch (called the marginal arch) which is at a fairly constant distance from the mesenteric border. At certain places the arch may be broken into several arcades. From this arch and its arcades, vasa recta spring and pursue a straight course to enter the mesenteric border of the gut without anastomosing with one another. The anastomosis between these vasa recta in the bowel wall is not very free, and in operations which result in division and anastomosis of the intestine, injury to these

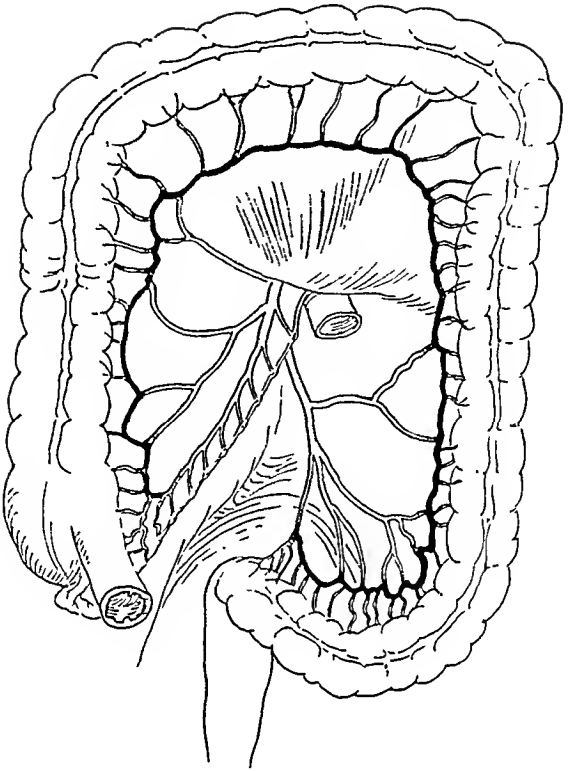

Fig. 7.—Branches coming off the mesenteric arteries form a continuous vessel within the circle of the colon a short distance from its margin throughout the length of the colon, through which the circulation from the two mesenteries communicate. Marginal artery of Drummond.

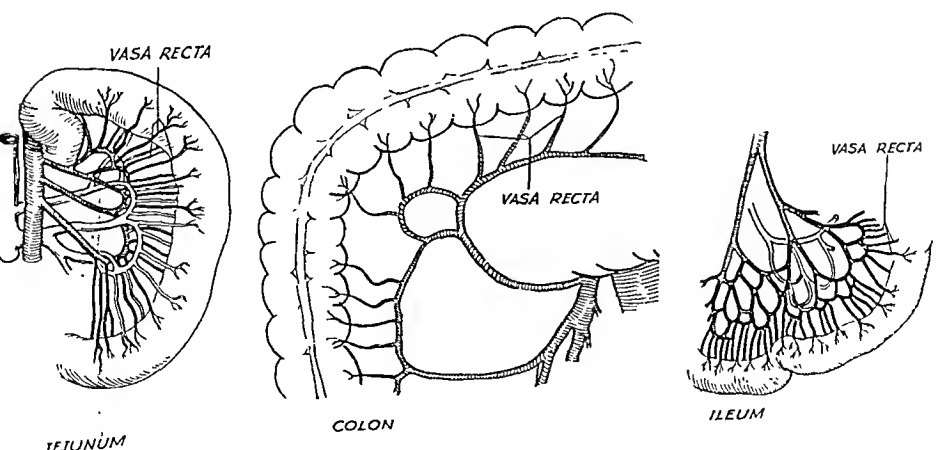

Fig. 8.—Illustration of the circulation near the bowel wall showing arcades and vasa recta to the jejunum, ileum, and colon. It is evident that the circulation to the jejunum is not so rich as to the ileum and that the colon circulation is much less adequate than other parts of the intestine. There are decidedly fewer vasa recta going to the large bowel and their anastomosis is very inadequate. Danger of devitalizing the bowel and freeing its mesentery for end-to-end anastomosis is very great as compared with the same procedure on the small bowel.

frequent in the large bowel and there is correspondingly a much poorer blood supply.

If we examine in more detail it will be seen that the terminal arteries as they approach the bowel are made up of short and long branches, the former entering the wall directly, while the long branches pass subserously directly toward the antimesenteric border and penetrate to the submucous layers much farther from the mesenteric border and on to the end in very fine fragments at the antimesenteric areas with scant anastomoses with the branches from the other side (Fig. 11). Therefore, the antimesenteric area of the colon, which is between the taenia, is poorly supplied with blood but does receive some from terminal vessels on either side.

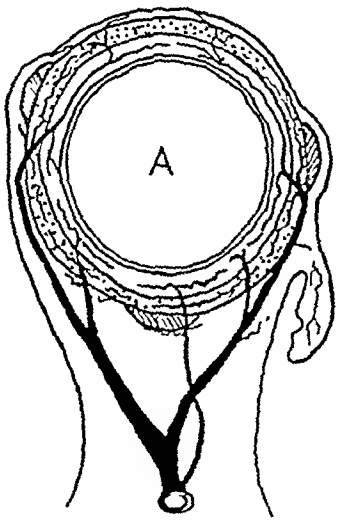

Fig. 11.—The arteries as they approach the bowel are made up of long and short branches, the former entering the wall directly while the long branches pass subserously toward the antimesenteric border and end in very fine fragments with scant anastomoses to the branches from the opposite side. (From Rankin and Graham, *Cancer of the Colon and Rectum* Springfield, Charles C Thomas, publisher.)

Based upon these anatomical facts it is suggested that:

1. In opening the bowel in a temporary colostomy the incision should be made at the antimesenteric border between the taenia and the long axis of the bowel.

2. In doing ileocolostomy with the end-to-side, or side-to-side anastomosis, this area of the colon should be the site of union.

3. Because of the poor anastomosis between the vasa recta, a minimum amount of freeing of the mesentery from the bowel should be done when making an end-to-end anastomosis of the colon following resection.

4. Because of the direction of the terminal vessels and their lack of anastomosis, when resecting the colon to be followed by end-to-end

border vessels must be avoided. The number of arcades and vasa recta are less numerous in the jejunum than in the ileum and still less numerous in the colon (Fig. 8).

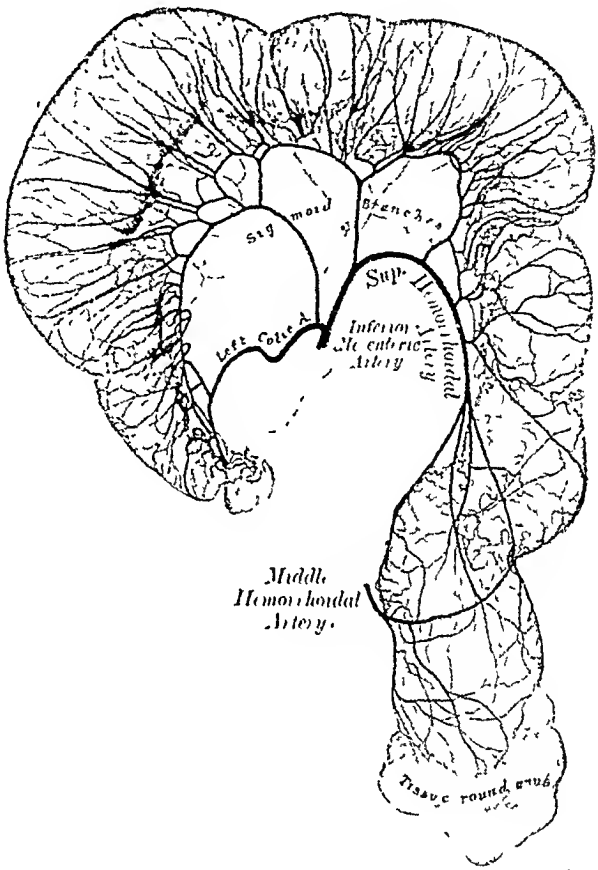

Fig 10.—Sigmoid colon and rectum, showing distribution of branches of inferior mesenteric artery and their anastomoses (From a preparation by Mr. Hamilton Drummond.) Illustration, by contrast, of the deficiency of the circulation in the colon The arteries and arterioles are much fewer and farther apart and the anastomosis is much less frequent (From Gray, *Anatomy*, Ed 24, Philadelphia, 1924, Lea & Febiger.)

3. *The Blood Vessels Within the Bowel Wall.*—The anastomosis of the vessels within the bowel wall is not a free one as stated before, and particularly so in the colon. If we examine Fig. 9 it will be seen that the number of arteries and arterioles in the jejunum are less numerous than in the ileum, and the anastomosis is correspondingly different. In Fig. 10 we can contrast the circulation in the wall of the colon with that in the wall of the small intestine It will be seen clearly that, not only are there fewer arteries in the colonic wall but they are much further apart. Also, the anastomosis between these vessels is much less

mesenteric side of the appendage. Rankin calls attention to the arrangement of their circulation which indicates that preservation of the epiploicae is advisable, but when it is found necessary to remove one, the artery passing through its base should be saved (Fig. 13).

The omentum (Fig. 14): The omentum may have a part in colon surgery. Its part cannot be said to be of major importance; on the other hand it may be very useful. Its power of rapidly becoming adherent to peritoneal surface, sealing over areas of bowel with questionable circulation, and reinforcing suture lines is well known. It establishes vascular connections with the tissues to which it becomes attached in a very short time, and may save bowel wall from necrosis

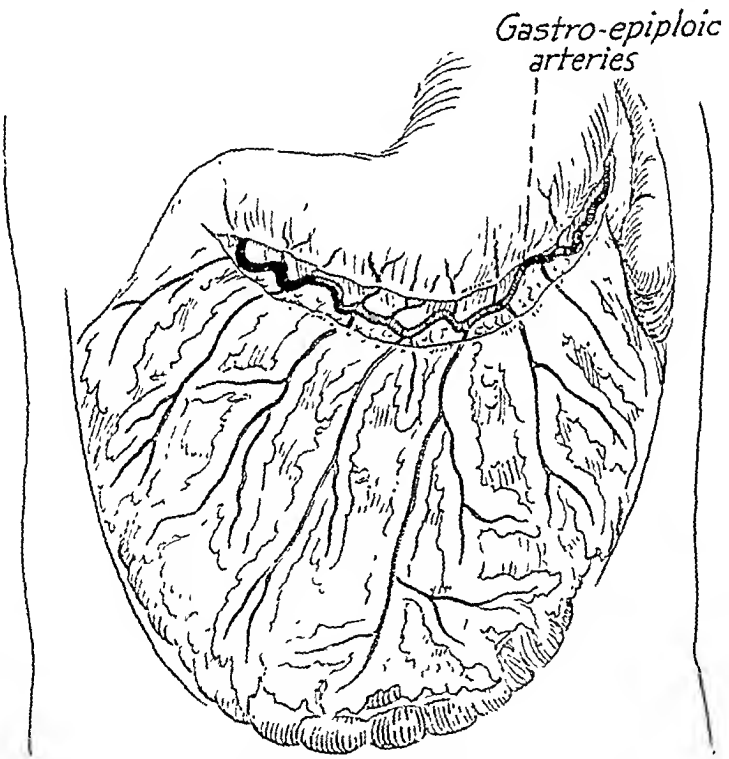

Fig. 14.—The omentum with its rich circulation may be used with advantage about anastomosis of the colon because of its power of adhering and rapidly supplying circulation to the sutured area in the colon.

in this manner. The blood supply to the omentum is very rich and entirely from the gastric vessels. Embryologically it identifies itself with the stomach and receives its circulation from the gastroepiploic arteries, and though it becomes attached to the transverse colon and upper surface of the mesocolon in embryonic life, strange to say practically no blood flows from the colon to the omentum except in small vessels through the phrenocolic ligament. Because of its rich blood

suture, the clamps should be placed across the bowel at a slight angle so that the circulation of the free border may be maintained (Fig. 12).

Appendices epiploicae: Because of the unreliability of the circulation of the colon, even the epiploicae are not to be overlooked by the surgeon. These fatty appendages may be useful to tack over suture

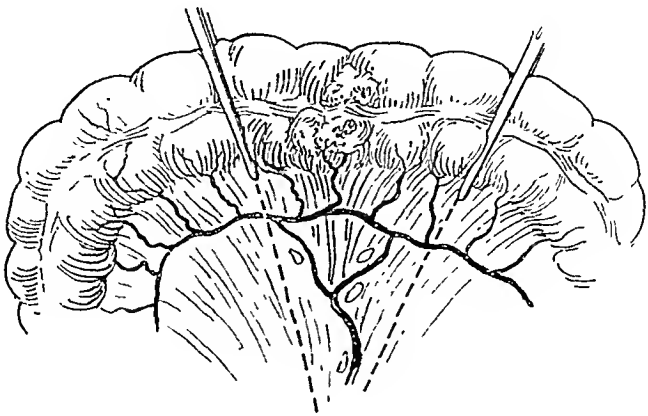

Fig. 12.—Because of the vertical course of the vasa recta over the bowel wall, it is advisable when resecting the colon and doing an end-to-end anastomosis, that the clamps be placed at an angle so that the circulation on the antimesenteric border will not have been interfered with.

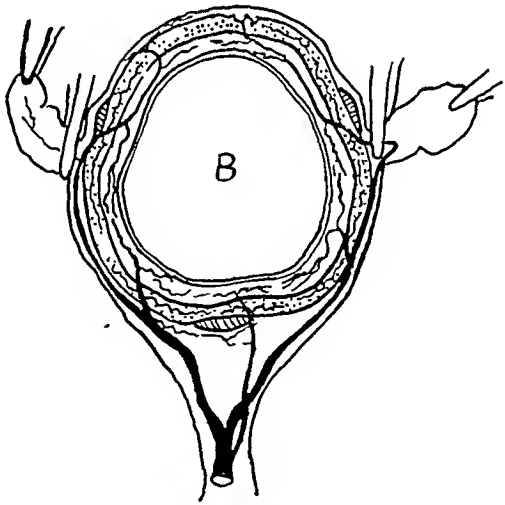

Fig. 13.—The correct (left) and incorrect (right) method for clamping epiploic appendages. (From Rankin and Graham, *Cancer of the Colon and Rectum*, Springfield, Charles C Thomas, publisher.)

lines for reinforcement by encouraging healing and preventing leaking. At times they may be in the way and interfere seriously with good apposition of serous surfaces of the colon in anastomosis. It is common knowledge that free hemorrhage occurs when one of these is cut off the bowel with frequently some blanching of the wall on the anti-

mesenteric side of the appendage. Rankin calls attention to the arrangement of their circulation which indicates that preservation of the epiploicae is advisable, but when it is found necessary to remove one, the artery passing through its base should be saved (Fig. 13).

The omentum (Fig. 14): The omentum may have a part in colon surgery. Its part cannot be said to be of major importance; on the other hand it may be very useful. Its power of rapidly becoming adherent to peritoneal surface, sealing over areas of bowel with questionable circulation, and reinforcing suture lines is well known. It establishes vascular connections with the tissues to which it becomes attached in a very short time, and may save bowel wall from necrosis

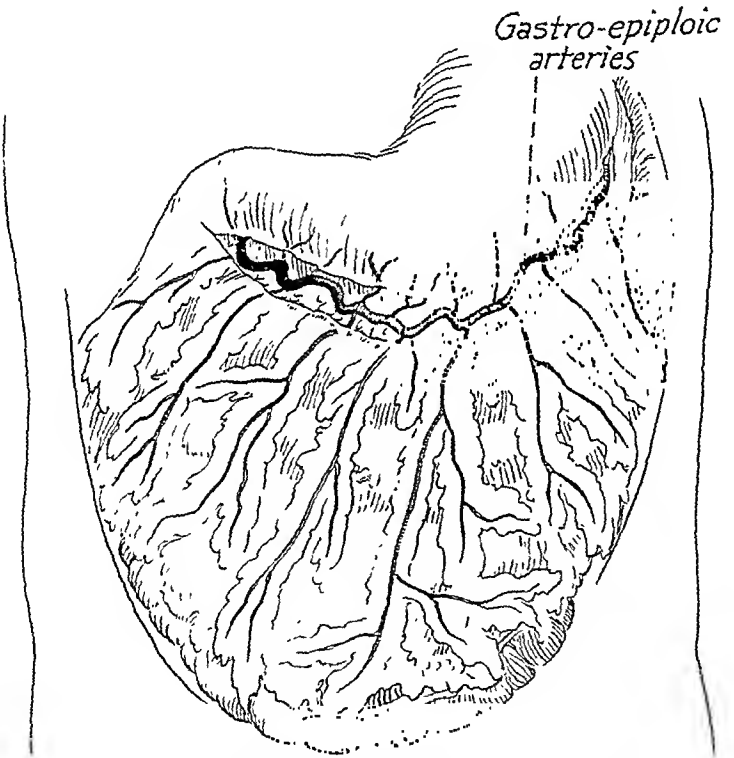

Fig. 14.—The omentum with its rich circulation may be used with advantage about anastomosis of the colon because of its power of adhering and rapidly supplying circulation to the sutured area in the colon.

in this manner. The blood supply to the omentum is very rich and entirely from the gastric vessels. Embryologically it identifies itself with the stomach and receives its circulation from the gastroepiploic arteries, and though it becomes attached to the transverse colon and upper surface of the mesocolon in embryonic life, strange to say practically no blood flows from the colon to the omentum except in small vessels through the phrenocolic ligament. Because of its rich blood

supply and its power to attach itself to the traumatized bowel and supply it with blood, it should be used to reinforce suture lines in the colon.

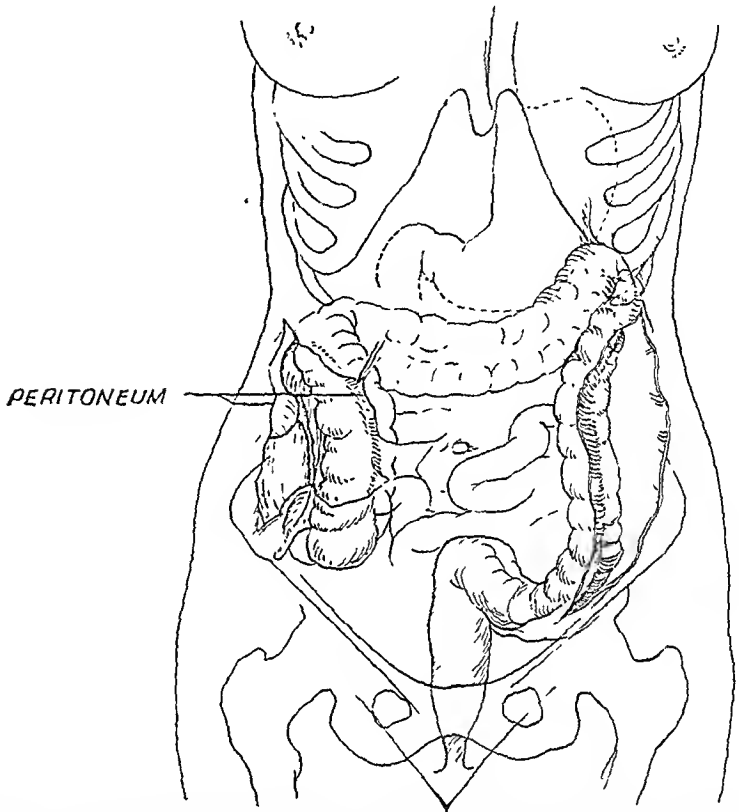

Fig. 15.—Because the entire circulation of the colon comes from the mesenteric vessels and radiates from the center of the abdomen to the colon it is possible to incise the lateral peritoneal reflection of the cecum and ascending colon on the right and the descending colon and sigmoid on the left without encountering blood vessels, permitting the free delivery of these parts of the bowel out of the wound in the process of excision.

Although as mentioned previously there are disadvantages in the arrangement of the blood supply of the colon from the standpoint of surgery, still there are some favorable facts in its arrangement. In surveying the blood supply to the large bowel, one should be aware of the fact that all its arteries come from the center of the rectangle formed by the colon and radiate from the center to the periphery. This means that the peritoneal reflection of the bowel on the lateral aspect of both the ascending and descending colon may be freely incised without encountering blood vessels. This permits the delivery of the cecum and ascending colon and the hepatic flexure through the wound and out of the abdomen, facilitating easy resection (Fig. 15). Similarly, on the left side at the splenic flexure and the descending colon, severing the lateral peritoneum is done with the same freedom

from important blood vessels, freeing this portion of the colon, allowing the same easy manipulation and greatly simplifying the operation. The splenocolic ligament at the splenic flexure may contain a small vessel which requires tying, but the hepatic flexure attachment may be severed with impunity.

REFERENCES

Grant, J. C. Boileau: A Method of Anatomy, Baltimore, 1940, Williams & Wilkins Company, 242.

Ochsner, Alton, and Storck, A. H.: Mechanical Decompression of the Small Intestine in Ileus, J. A. M. A. 108: 260-265, 1937.

Rankin, Fred, W., and Graham, A. S.: Cancer of the Colon and Rectum, Springfield, Charles C Thomas, Publisher.

Drummond, Hamilton: The Arterial Supply of the Rectum and Pelvic Colon, Brit. J. Surg. 1: 677, 1914.

Gray, Henry: Anatomy of the Human Body, Philadelphia, 1924, Lea & Febiger.

Larson, Lawrence M., and Bargen, J. A.: Physiology of the Colon, Arch. Surg. 27: 1-50, 1933.

Steward, J. A., and Rankin, Fred. W.: Blood Supply of the Large Intestine; Its Surgical Consideration, Arch. Surg. 26: 843-891, 1933.

Sobotta, Johannes, and McMurrib: Atlas of Human Anatomy, New York, 1930, G. E. Stechert & Company.

Cunningham's Text Book of Anatomy, Ed. 6, New York, 1931, Oxford University Press.

CONSIDERATION OF ELECTIVE SURGICAL PROCEDURES IN VARIOUS SEGMENTS OF THE COLON

THOMAS E. JONES, M.D., CLEVELAND, OHIO
(From the Cleveland Clinic)

ACTIVE interest in the surgical management of malignancy of the colon and rectum of the past twenty years is evidenced by the large number of contributions to the literature. Anatomy, of course, has not changed, surgeons have not suddenly become expert, but improvement in surgical technique and the application of physiologic principles have increased the scope of operability, lowered the mortality, decreased morbidity, and increased curability. Allied branches of medicine, such as x-ray, have contributed materially to the earlier recognition of malignancy, and the renewed interest of pathologists has led to a better understanding of its spread; this knowledge has been very helpful to the surgeon in his surgical approach. Early diagnosis, insistence on good preoperative preparation, improved anesthesia, and chemotherapy have all contributed to making the problem a much more hopeful one than formerly. From descriptions of operations performed, radical procedures seem to be the vogue, and curbed by the necessity of saving one kidney, a part of the stomach, or a part of the bladder, from an anatomical standpoint the surgeon has almost reached the limit in the eradication of malignant disease of the colon and rectum. Further benefits must come from earlier diagnosis, which obviously is lagging far behind improvement in surgical technique. Change in bowel habit or the presence of bleeding must be considered as being due to malignancy until disproved, if we are to make further progress.

From the standpoint of surgical technique there are admittedly many different ways of accomplishing a certain operation in a certain segment of the colon. The one fundamental prerequisite, however, is to do as extensive and as radical an operation as possible. Whether this is done by the closed or open method, by the one-stage or two-stage method, or by any other technique makes little difference provided the surgeon can show that his results from the standpoint of mortality and morbidity are equal to those of other techniques. Perfecting one technique is better than trying every new procedure that is introduced unless one has an abundance of material. It is advisable, of course, not to take an attitude of laissez faire and to be facile enough to adopt something new if it is proved to be distinctly better.

While one may prefer a certain standard procedure in certain segments of the colon, the findings at operation may necessitate a variation in technique. Obstruction, subacute perforation, or fixation must alter

Received for publication, May 31, 1913.

the course of even the staunchest advocate of the one-stage procedure. Graded procedures are necessary for utmost safety in this limited group of cases. In the final analysis the main controversy in surgery of the colon revolves around (1) the one-stage or two-stage procedure, and (2) the open and aseptic or closed method of anastomosis. There has been an active and healthy dispute regarding these principles, but certainly one can anticipate a better understanding of the methods involved, and the issues are not so unrelated as they would seem. Improvements along one line or another may cause a change of method. For instance, sulfanilamide may change a two-stage operator into a one-stage advocate, or the use of the Rankin clamp may cause an advocate of the open method to use the closed method. Broadly speaking, I am inclined to agree with Rives[1] when he says, "Less depends on the method used than the manner of its execution." A cursory review of mortality figures in recent years shows a disparity of 10 to 25 per cent for the same operation. This disparity is probably due to the manner of execution. Stone and McLanahan[2], in reporting 166 resections from the cecum to the rectum, show a preference for one-stage operations and closed anastomosis. Out of the entire series there were only eleven two-stage procedures. The overall mortality was an excellent one of 13.8 per cent. In cases of open anastomosis the mortality was 26.3 per cent (in nineteen cases), while in the closed anastomosis it was 11.2 per cent (in seventy-one cases). The reader may reflect that they have had four times as much experience with the latter, and that may play a part. I have always believed that peritonitis depends not so much on soiling as on leakage at the suture line or secondary to a bad wound infection, and since this can happen in the two-stage anastomotic procedure as well as the one-stage I prefer the one-stage procedure.

In all statistics a higher mortality is quoted for palliative anastomosis and resection than for completed cases. This probably demonstrates the importance of vitamin and plasma protein deficiency in infection and wound healing. The patient with advanced malignancy is probably lacking in both of these essentials and therefore cannot tolerate a minor procedure. However, cancer is a fatal disease and operative mortality cannot be viewed in the same light as in nonfatal cases. The surgeon must be courageous. His responsibility is to palliate as well as to try to cure. The decision in any individual case rests upon the surgeon's experience, his philosophy regarding malignant disease, the patient, and the lesion.

Lesions in the right colon whether in the cecum, ascending colon, or hepatic flexure are best treated by right colectomy. My preference in this group of cases is the one-stage right colectomy with ileotransverse colostomy with an end-to-side anastomosis over a Rankin clamp. It is applicable to practically all cases. Only the occasional case involves the ileocecal valve causing obstruction, and perforation is uncommon.

Formerly a small catheter was inserted by Witzel's method into the ileum about six or eight inches from the anastomosis to prevent tension on the suture line and to relieve pressure within the bowel. Lately this technique has been changed and the Miller-Abbott tube has been substituted with satisfactory results. However, if the tube is not proved to be in the ileum before operation, the catheter is still used. Because of the frequent difficulty in passing the tube, the intolerance of certain patients to it, and irritation from it which may produce pulmonary complications when necessary for many days, the ileostomy tube may be more satisfactory.

The great advantage of the one-stage over the two-stage procedure is economy in hospitalization and rehabilitation time, yet economy in time cannot be argued against safety. In either case these patients must have a few days of preoperative care in which transfusion is of first importance because so many have a secondary anemia. A review of forty-five unselected cases shows that the average hospitalization period was twenty days. This is considerably less than for the two-stage procedures. The mortality was 13 per cent. One of the greatest difficulties in resection of the right colon, particularly in the very obese patient, is peritonealization of the right gutter. Improperly completed, it will lead to adhesions and obstruction which is a definite factor in mortality. For several years we have obviated this by the use of the modified Mikulicz pack (Figs. 1*A* and 1*B*) described recently[3]. It prevents the small intestine from becoming adherent, and the postoperative convalescence is therefore much smoother. The combination of a well-prepared patient, decompression of the ileum either by Miller-Abbott tube or ileostomy tube, the use of the Mikulicz pack when indicated, the use of steel wire figure-of-eight sutures to prevent infection and disruption will, I feel confident, reduce the mortality considerably in this current series. If the surgeon has not had sufficient experience to be adept in the use of the Rankin clamp he should resort to other procedures. When it is impossible to use it because of immobilization of the colonic segment I do not hesitate to do an open anastomosis which is generally side-to-side.

I have had no experience with the modified Mikulicz operation on the right colon. It has been advocated by Lahey[4] in recent articles. Cattell[5] reports a mortality of 3 per cent by this method in over 100 cases. The objections to it, of course, are the same as for ileostomy in addition to the longer period of hospitalization. However, the discomfort does not last for many weeks and if it lowers the mortality over other operations by another 10 per cent it surely will become the method of choice.

The classical two-stage procedure is the side-to-side anastomosis between the ileum and transverse colon and the resection of the right colon at a later date. The objections are that (1) a person is running the risk of accidental death twice instead of once; (2) the hospital stay is greatly increased; (3) complications such as pneumonia, embolism,

phlebitis, infected wounds, etc. may delay or actually defer indefinitely the completion of the second stage procedure. Therefore, I use it only in cases where there is obstruction or perforation of the growth.

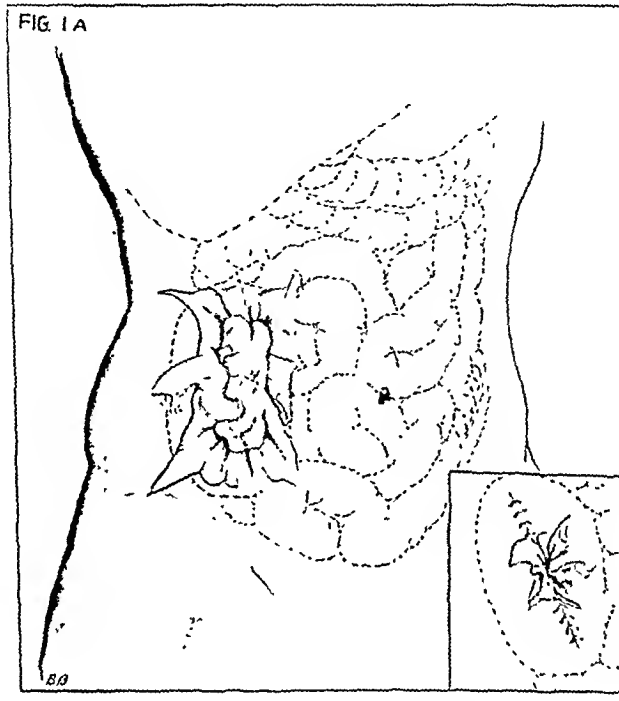

Fig. 1A.—Diagrammatic sketch of pack after closure.

In the transverse colon one has a variety of satisfactory procedures. Ordinarily mobilization is easy, and the blood supply is good. Mayo and Simpson[6] report a mortality of 11.1 per cent in resection and primary anastomosis in contrast to 20 per cent mortality in ninety-five cases of extraperitoneal resection. Stone reports a mortality of 7.1 per cent in fourteen cases by this procedure. In the past it has also been my choice. In my own twenty cases there were two deaths, or a mortality of 10 per cent. In the one-stage procedure with resection, done in the manner of choice to fit the case, I believe it is important to do a complementary tube cecostomy. It is simple to do through a McBurney incision. It will lower mortality and morbidity, and it does not prolong hospital stay, for if the tube is removed on the fifth or sixth day it will be closed by the time the patient is discharged from the hospital. In cases of marked obstruction, which generally is not the rule, the tube cecostomy should be done first under local anesthesia, followed in a week by resection. I thought my own mortality rate could be improved upon and, for that reason, am trying a series of Rankin obstructive resections. I have reason to believe that the mortality will be lower, al-

though sufficient cases have not been done for comparison. It would have to be materially lower to justify the extra ten days in the hospital and a longer convalescence. Most have to be closed secondarily, and this cannot be done until about eight weeks later. During this time the patient is unproductive because in ordinary times his employer will not re-employ him until the job is complete.

If the obstructive resection technique is employed it is better to make the incision through the rectus muscle, right or left, according to the location of the lesion. The application of the spur clamp is safer, and in the closure of the stoma a better abdominal wall will result with less danger of weakness or definite hernia.

FIG. 1 B

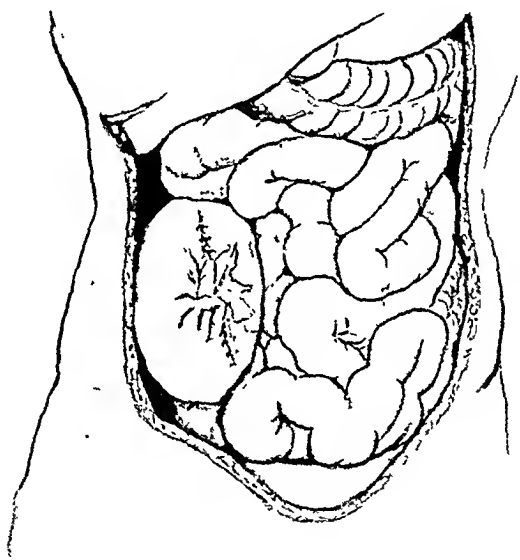

Fig. 1B.—Diagrammatic sketch of pack intraabdominally.

A lesion at the splenic flexure presents more difficulty than in any other segment of the colon. It generally lies very high and is frequently adherent to the spleen. In its mobilization the capsule of the spleen will tear and give rise to very troublesome bleeding. In two of our cases the spleen had to be removed before the operation could be proceeded with. In another case a gauze pack had to be placed tightly against it. I believe the obstructive resection is the best procedure here, and a left costal border incision makes it easier than a left rectus incision. In a total of twenty-four cases there were five deaths, a mortality of 20 per cent in all types of operations. An analysis of recent cases, in which the obstructive resection was used with the utilization of a Mikuliez pack in the large cavity which could not be peritonealized.

indicates that the mortality can be lowered to equal that of resections on other segments of the colon. The pack is brought out through a stab wound in the flank.

Previous to 1938, I favored resection of the sigmoid in one-stage procedure with end-to-end anastomosis and frequently with tube colostomy above the growth or tube cecostomy. The mortality in this group including descending colon and sigmoid in 128 cases was 14 per cent. Even though it compared favorably with other statistics, I felt it could be improved upon. With the use of sulfanilamide, as at present, it probably would have been lowered. I had objected to the Mikulicz type of resection on account of the frequent postoperative hernias, and I had seen many cases of recurrence in the scar, the cause of which was obvious. It seemed to me that the quoted mortality in this operation was also too high if it was designed to do away with the most frequent cause of death, viz., peritonitis from the open operation. Consequently, I started a series of the Rankin modification of obstructive resection. It seemed to me that one could do as radical an operation with this method as with the resection and anastomosis, a thing that the Mikulicz operation did not stress and the thing which caused the local recurrence. We reported this group of cases this year.[7] From January, 1938, to July, 1942, the series totalled seventy-seven cases, sixty-one being in the left colon. The mortality was five cases or 6.5 per cent. This definite drop in mortality seems to justify continuance of the procedure in preference to others. In this group spontaneous closure occurred in eleven cases or 14 per cent. The total hospital stay in this entire group of cases averaged twenty-eight days. This included preoperative treatment in all cases, in ten of which a cecostomy had to be performed for obstruction, and the hospital stay for closure of the colostomy, the latter averaging eight days. It was not necessary to do a second operation for closure in a single case. The technique is described in the article and will not be repeated here. Mayo and Simpson quote a hospital stay of fifty-nine days with this procedure.

As one reads the literature there is no apparent unanimity of opinion as to what constitutes the rectosigmoid. I take it to be the junction between the rectum and the sigmoid, and if the rectum is five inches long then the rectosigmoid should be a small segment of bowel beginning at about the peritoneal reflection and extending proximally for not more than two inches. Most lesions at this point obviously cannot be exteriorized, yet one frequently reads about the Mikulicz operation for rectosigmoidal cancer. As a working basis I consider a lesion whose lower edge borders on the peritoneal reflection, or a segment two inches above it, as rectosigmoid and subject it to the same operation as those listed under carcinoma of the rectum.

One of the most difficult decisions to make is the type of procedure best adapted to a lesion whose lower border is three inches above the peritoneal reflection in an obese patient. Even the most radical sur-

geon does not want to sacrifice the rectum unnecessarily. To save the rectum one must be committed to a higher mortality and morbidity. The choice lies between two procedures: (1) colostomy followed by resection and end-to-end anastomosis, and (2) the anterior resection, or Hartman procedure, of dividing the bowel at a safe margin below the growth, then turning in the rectum and bringing the proximal loop out as a permanent colostomy. The former will carry a higher mortality and a lower curability rate, in my opinion. In the very obese patient and

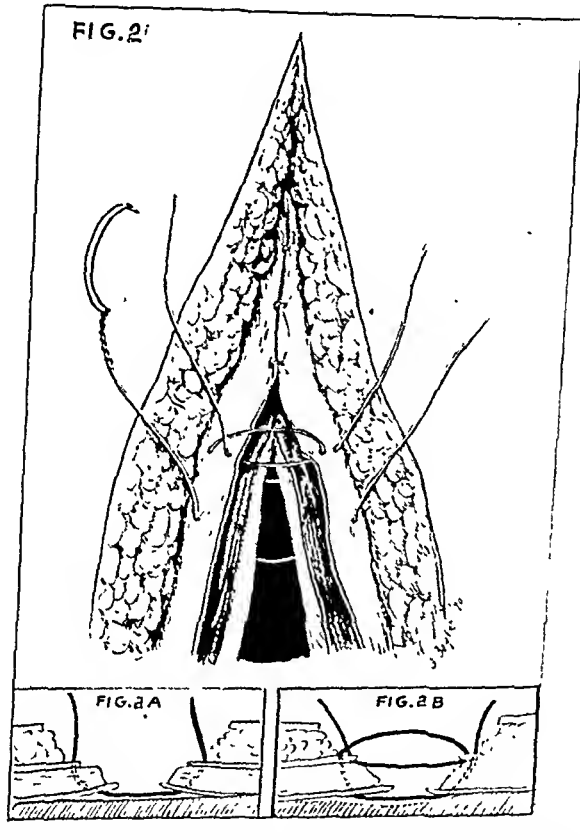

Fig. 2.—The suture passes first through the anterior fascia muscle, peritoneum (Fig. 2*a*) and again through the anterior fascia in the same direction (Fig. 2*b*).

frequently in cases of a very short sigmoid, the operation is mechanically impossible particularly if one is keeping curability as the foremost indication of the operation. The latter is a more radical resection, the mortality will be lower, and the curability higher. In this particular lesion I would base the decision on age of the patient alone. In the young I would do an anastomosis and preserve the continuity of the bowel. In people over 60 years of age I would do the anterior resection and eliminate the two other surgical procedures.

Dixon[8] has been advocating resection and end-to-end suture on lower lesions, even bordering on the peritoneal reflection after a colostomy has been done in preparation. Time only will tell whether the mortality, morbidity, curability, and prolonged hospital stay justify the procedure.

My views upon the choice of surgical procedure for cancer of the rectum have long been known. As I first believed with firm conviction even though with temerity, I am now more convinced than ever that the procedure of choice for this lesion and those in the rectosigmoid, as I interpret it, is the one-stage abdominoperineal resection, the Miles' operation. It offers the best hope of cure, the lowest mortality and morbidity, and the greatest palliation of all procedures. In a series of over 600 cases the mortality was 7.2 per cent. Since October, 1941, until May 1, 1943, we completed 128 consecutive cases without a single fatality. It must be apparent from this number that bad risks were given a chance as well as good risks. The patients in eight cases had liver involvement at the time of operation. Twenty-five had arteriosclerotic heart disease with hypertension; five had had coronary heart disease; four had diabetes. Twenty-seven had had previous abdominal operation, which, in general, is a complicating factor. The total hospital stay in this entire group averaged twenty-two and one-half days. Only ten had a stay of over thirty days. There were no disruptions, and only two abdominal wounds were infected. Attention has been called to this before[9] and has been attributed to the figure-of-eight alloy steel wire closure (Fig. 2). Elimination of infection reduces mortality and morbidity to a very low percentage which increases the scope of operability. To include those with metastatic lesions will of course decrease the curability rate. That makes little difference. We will make more people comfortable for a longer period of time.

REFERENCES

1. Rives, J. D.: J. A. M. A. 113: 2286, 1939.
2. Stone, H. B., and McLanahan, S.: J. A. M. A. 113: 2282, 1939.
3. Jones, T. E., Brubaker, R. E., and Paxton, J. R.: Ann. Surg. 117: 256, 1943.
4. Lahey, F. H.: Surg. Gynec. & Obst. 54: 923-939, 1932.
5. Cattell, R. B.: Connecticut M. J. 6: 361, 1942.
6. Mayo, C. W., and Simpson, W. C.: Ann. Surg. 109: 430, 1939.
7. Jones, T. E., Bondi, F. R., and Brubaker, R. E.: Surg., Gynec. & Obst. 76: 236, 238, 1943.
8. Dixon, C. F.: Proc. Staff Meet. Mayo Clin. 11: 384, 1936.
9. Jones, T. E., Newell, Jr., E. T., and Brubaker, R. E.: Surg., Gynec. & Obst. 72: 1056-1059, 1941.

CARCINOMA OF THE COLON

ARTHUR W. ALLEN, M.D.,* BOSTON, MASS.
(From the Surgical Service, Massachusetts General Hospital)

CARCINOMA of the colon occurs with sufficient frequency to make it a subject of interest at any time. The increasing awareness of this malady has come about through educational methods affecting both the medical profession and the public. The symptoms of this disease may be insidious to a point of complete hopelessness, but are usually sufficiently characteristic to cause the victim to seek investigation at a curable stage. Not only is the extirpation of the lesion possible in the majority of instances, but the survival rate is high. When one compares the outlook with cancer elsewhere in the body, it is obvious that the colon represents one of the most favorable sites for cure.

The *physician* to whom the patient appeals must exert every effort to make a diagnosis. This responsibility is too often delegated to the roentgenologist. The latter may have no help from the physician or from the patient regarding the symptoms that have initiated the study. This may lead to a negative report, which often has a marked bearing on the ultimate outcome. The patient is entitled to a careful consideration of abdominal discomfort, change in bowel habit, loss of blood from the bowel, fatigability, anorexia, and weight loss. A satisfactory history and a careful physical examination may afford only enough evidence to warrant further study. It is necessary to consider repeated investigations, setting a time-limit interval of one month, and the probability of a better opportunity for a correct deduction if the patient is hospitalized. Only by such methods can one expect to make the diagnosis early. The importance of early diagnosis cannot be overemphasized, since it is directly related to curability. The average delay between onset of symptoms and hospital admission in our clinic was eight months.[1] This is too long, and every effort must be made to decrease it. I am sure that the operability and cure rate will rise tremendously if this interval can be reduced.

The diagnosis of carcinoma of the colon having been established, the *patient* has the right to expect relief from his disorder. This can be brought about only by surgery, which he can further expect will be compatible with life, extirpation of his disease, and the restoration of his health. Although the necessary steps are often disagreeable to a point of feeling that the cure is worse than the disease, the end result

* Chief of East Surgical Service, Massachusetts General Hospital; Lecturer in Surgery, Harvard Medical School.
Received for publication, April 2, 1943.

should warrant cooperative effort on the part of the patient. The outlook, without surgical interference, is hopeless and if this fact could be properly linked with the probability of cure, less would be said concerning associated discomforts. Most of the fear and dread of the entire procedure can be eliminated by a careful explanation to the patient and his family of the program to be undertaken in his behalf.

The *surgeon,* to whom a patient with carcinoma of the colon is referred, has definite responsibilities. In order to fulfill his obligation to the patient, he must evaluate the entire situation with care; the general condition of the patient, his systems, obesity, anemia, and nutritional state must be considered. The time element of preoperative study and preparation will vary but, too often, the patient and his family, by their anxiousness "to get it over," precipitate surgical interference before the optimum time for surgery has arrived. According to the site of the lesion and the amount of obstruction present, the manner of handling the situation to the best interests of the patient are varied. All authorities agree that in the presence of acute obstruction, the immediate operative procedure must deal with that phase only. An attempt to extirpate the diseased segment, at this time, would be attended by an unreasonable risk. In the absence of obstruction, the surgeon may elect to handle the case in the manner that his own experience, added to that of his predecessors and contemporaries, predicates the best chance for an ideal outcome. This may be in one or more stages, since every surgeon must carry out the method in which he has the greatest confidence.

OPERABILITY OR RESECTABILITY

Attitude regarding operability has changed with the gradual improvement in surgical principles. A properly prepared patient subjected to surgery under ideal conditions will withstand procedures of such magnitude that operability has been extended to a debatable degree. There arises in our minds, at times, considerable doubt concerning the justification of effort expended. Many of us have sufficient confidence in the scientific safeguards of modern surgery to feel that any lesion not involving vital structures, which is movable after exposure, is resectable. This often leads us into complicated dissections necessitating the inclusion of neighboring structures that have become invaded by the direct extension of disease. All admit the importance of removing the vascular and lymph area supplying the region of the primary lesion; this, fortunately, is all that is needed in the majority of cases. It should be emphasized that such a dissection is even more important if the focus is small and the lymph nodes seem to be uninvolved, since it is in this group that we find our most favorable cases for cure. On the other hand, some have questioned the justification of a radical operation in the presence of liver metastases. Although, at times, I have felt discouraged about the extensive effort expended in some instances and, in

fact, have witnessed a difficult convalescence followed by a respite of such short duration that obviously poor judgment had been used, yet we have seen many incredible periods of good health and happiness follow resections of great extent, some even in the presence of liver metastases. It is this type of respite that has influenced surgeons to attempt the impossible and not for the reason I have heard quoted, "to perform a surgical stunt."

Segments of the parietes are now so often included in the block dissection for malignant disease of the colon that one no longer considers this as unusual. Lesions that have perforated to form abscesses involving the retroperitoneal area or the abdominal wall are compatible with curative surgery. Contact areas involving a ureter or kidney, the duodenum, stomach, small intestine, pancreas, spleen, edge of the liver, gall bladder, uterus and adnexa, urinary bladder, and other segments of colon can often be removed successfully. The mortality, under these conditions, will be higher than if one adopts the attitude that cure is so remote that the effort is unjustifiable. The morbidity will, of necessity, be greater and the patient may wonder whether the effort to live is worth while. The cure rate in one's statistics will be decreased proportionately by the inclusion of these extensive operations. On the other hand, a radical attitude has much to commend it. Not only does the patient have his best chance for a comfortable respite and the possibility of a cure, but the surgeon implants in the minds of his pupils the correct viewpoint toward the increasing scope of surgery.

In a previous communication,[1] we reported 107 consecutive cases of carcinoma of the colon in the regions requiring abdominal approaches, personally treated. The resectability in this group was 93.6 per cent. Since this time, we have operated upon patients in 79 additional cases, finding 10 inoperable or 87.4 per cent resectability, which shows that in patients referred to us the operable rate did not increase from 1939 to 1943. During this period a run of five lesions, originating in the right colon with such widespread metastases that only palliative ileocolostomy could be done, largely accounts for this variation. It gives, however, an overall resectability in the 186 cases of the combined groups of approximately 91 per cent.

I am sure there arises in the minds of some a doubt concerning the proper use of the term "operability." Should this term be used for resections that include all obvious disease and only when there is no evidence of liver metastases, unremovable nodes, or contact disease in neighboring structures? The word "operable" is apt to imply cure and still few of us would fail to extirpate all obvious disease, knowing full well that the chance of remote extension was likely. One does not need to believe too strongly in the possible retardation of metastatic areas by removing the primary focus. We have all seen long, comfortable respites under these circumstances. These periods of relief are

far more marked following successful extirpation of the primary disease than from palliative short-circuit anastomoses or proximal colostomy. Death from recurrent disease, especially if it occurs in the liver, is associated with fewer discomforts than it is when the primary lesion is still in situ. It seems to me that there is sufficient cause for confusion that we might do well to substitute the term *resectability* for *operability*.

MORTALITY

Any patient failing to leave the hospital alive, regardless of the time elapsed following operation, should be included in the failures of treatment. There are many ways of juggling figures to improve the facts of the situation but there seems no reasonable concept other than to include all postoperative deaths in the percentage values. In a clinic, such as ours, there will be a few moribund patients admitted, due to the accessibility of the institution to the community. If these are subjected to a palliative operation for obstruction or drainage of infection, they must be considered as surgical deaths if they fail to leave the hospital alive. Operability and mortality are closely related and if one fails to take into consideration the average type of patient seen in a large general hospital, as compared with those able to obtain private service, then figures concerning both groups are of less importance. Certainly, a larger percentage of favorable cases are seen in our private wards than in the general hospital. This definitely influences the operability and the mortality. Comparative values are possible in such a clinic on the basis of the type of operation done, since a variety of methods have been used. That deductions are useful, when applied to similar institutions only, is obvious. The results obtained in the private-patient group are likewise comparable only to similar groups elsewhere.

In the personally managed cases referred to above, 35 of the 186 patients died in the hospital, or an overall mortality rate of 18.8 per cent. This includes those whose lesions were not resectable. The operative mortality percentage can be made more attractive by eliminating the deaths in the inoperable cases and those deaths not directly related to the colon lesion or the operation undertaken to remove it. If our last group of 79 cases is analyzed in this respect, we find that of the 44 with resectable lesions of the left half of the colon only 3 patients died, a 6.8 per cent mortality. These deaths were in a 64-year-old woman who survived 38 days following resection of sigmoid, a portion of small intestine, and a total hysterectomy; a 57-year-old man who survived 30 days following resection of descending colon, part of the stomach, and the spleen; and a 69-year-old man who died from a cerebral accident 6 days following resection of the splenic flexure.

In the 25 patients with resectable lesions of the right and transverse colon suitable for right colectomy during this 4-year period, there were 10 deaths. One of these was a two-stage right and transverse colectomy

and death was due to peritonitis 9 days following the second stage. Autopsy showed an abnormality of the blood supply to the transverse colon accounting for necrosis of the turned-in segment. A 63-year-old woman died as a result of small bowel obstruction occurring between stages of a right colectomy for an extensive obstructive lesion of the hepatic flexure. This precipitated the second stage at too early a time, so that the benefits of the decompression were lost. The other 8 deaths were unrelated to technical procedures. A 76-year-old woman died of carcinomatosis 60 days after extensive resection, which included a segment of duodenum; a 51-year-old man died of subacute bacterial endocarditis 48 days after operation; a 63-year-old man, of gangrenous gall bladder with perforation 44 days after resection; a 74-year-old woman, of coronary occlusion 14 days postoperatively; a 73-year-old woman of pulmonary complications after 21 days, and a 43-year-old man died of coronary occlusion 8 days after a one-stage right and transverse colon including the splenic flexure. There were 2 deaths following the first stage in resectable lesions—one of these was in a 68-year-old man with advanced cirrhosis of the liver who succumbed in 5 days from liver failure; the other was in a 75-year-old man who had survived a two-stage resection of the sigmoid 2 years previously and had recently suffered a coronary occlusion (further coronary thrombosis occurred 5 days after ileotransverse colostomy).

Five of these deaths occurred in patients whose primary lesions were situated in the hepatic flexure. It is always dangerous to report a run of successful cases unless it is of sufficient length. In our previous report, we were foolish enough to call attention to 22 consecutive right colectomies in two stages without a death. It is of interest to us to find that in the last 67 resected lesions, there were only 2 deaths attributable to technical difficulties.

MORBIDITY

It is difficult to analyze our figures on the basis of morbidity. This, as a whole, represents a group of aged patients, many of them suffering from complicating disorders. It is desirable to attempt to improve their general condition before subjecting them to any operative procedure. This may not be possible, since acute obstruction or infection often makes an early attempt imperative. Although associated diseases account for many of the fatalities, it is to be remembered that many of the survivors also had serious concurrent maladies. This would be expected in any lesion affecting an older age group.

The time spent in the hospital hardly represents a fair estimate of morbidity, yet it seems to be the only tangible evidence available. It might be possible to search out the duration of invalidism prior to hospitalization and make some attempt to determine the further convalescence prior to returning to usual occupations. This would vary tre-

mendously, depending upon so many factors of age, sex, type of work, and the necessity for it, that it hardly seems feasible. Many of the individuals seeking relief have worked up to the day of admission, while others have long been retired. That a large percentage of the survivors do return to their usual occupations is evident.

One may attempt to analyze morbidity on the basis of cost of hospital care. This would entail the details necessary for modern surgical care and would include blood transfusions, expensive drugs, oxygen, and special nursing service. Although the private ward patients often are permitted luxuries in this respect, none of the General Hospital patients are restricted in these matters if such additional aid may make the difference between recovery and death. That useless expenditures in hopeless cases are often indulged in cannot be denied. There is, however, an educational element for the resident personnel that justifies these procedures to some extent.

Based on our own 93 cases in the past 5-year period, we find that preoperative preparation averaged 4 days. This is a short period due to the fact that even in those who did not have marked obstruction, a preliminary decompression of the bowel was the rule. The time interval between stages averaged 11 days. The total average time for hospitalization of the survivors was 39 days. In the General Hospital group for the same period, the preoperative days averaged 5½. The total days for the survivors averaged 44. All these figures include time necessary for the final closure of preliminary colostomies. Most of the cecostomies were of the type that spontaneously closed.[2]

That a shorter term of hospitalization was obtained in the patients subjected to one-stage procedures is admitted.[3] The increased mortality in the one-stage group, however, far outweighed the added morbidity in the two-stage group. At present, there is a definite tendency with the aid of preliminary succinylsulfathiazole and the Miller-Abbott tube to increase the number of one-stage operations. This may materially decrease morbidity. It only remains to be seen whether or not these measures will offset the safeguard our patients have had from two-stage operations. It may well become evident that we should include these precautions in addition to multiple stage procedures, thus further reducing mortality. The average added morbidity in the multiple stage procedures is, in fact, a matter of less than two weeks.

SURGICAL PROCEDURES

Consideration of surgical procedures for cancer of the colon involves the following general principle: First, the patient's life must be safeguarded and second, the patient's health must be restored. One can circumvent the first principle by doing only the most palliative operation to relieve the symptoms temporarily, or it is possible to adopt the attitude that radical operation carries such a great hazard that it is im-

justifiable. Both of these concepts are wrong and should be discouraged. It is delightfully enlightening to find that in this community a large number of excellent surgeons meet this problem so seldom that they feel incompetent to do a good operation for cancer of the colon and refer the patient to a clinic, where so many such cases are treated that an adequate understanding of the situation gives the patient a fair chance. These honest men inspire the confidence of their patients and the respect of their colleagues, while the surgeon who fails to recognize his limitations has neither. After all, there are estimated to be approximately 15,000 cases of cancer of the colon in the United States in one year.[4] If these are parceled out equally to all surgeons, no one man would have sufficient experience to deal with the case properly. The present attitude concerning the matter concentrates these patients in the larger teaching clinics. This serves the purpose of developing the best methods for successful treatment.

There are a variety of well-thought-out operative procedures for patients with colon cancer. Stress has been placed upon the importance of early extirpation of the growth. This is indeed desirable from the standpoint of the mental state of the patient and the convenience of the surgeon. Those who champion one-stage procedures are apt to lay great emphasis on the benefits derived from prompt removal of the diseased area. It must be recognized, however, that too much urgency in this direction may result in an unsuccessful outcome. Most of these growths produce a certain amount of obstruction. All of them are grossly infected. A combination of obstruction and infection presents a problem that has long been recognized as a serious hazard to abdominal surgery. Many nonresectable lesions can be made operable by preliminary bowel drainage. Consideration must be given to exteriorization methods, as well as to one- or two-stage procedures with anastomosis. So-called aseptic anastomosis versus open sutures must be discussed. Adjuncts to successful operations, such as proper preoperative preparation, chemotherapy, and the Miller-Abbott tube, will be taken up later. Since there is considerable difference in the mortality rate in the extirpation of malignant growths in various segments of the colon, it is desirable to discuss these regions separately.

The *right colon* is involved in about 25 per cent of the patients coming to our clinic. The disease in this area may fortunately manifest itself reasonably early by bleeding, by intermittent discomfort in the right lower quadrant, or by intussusception. Anemia and fatigability may lead to investigation that discloses a right colon lesion. Many of these cases, however, produce none of these symptoms forcibly and due to the natural elasticity and large caliber of this segment, obstruction is a late manifestation. In spite of this, it appears that survivors have a better chance for cure than those whose lesion affects other regions of the bowel. This is probably due to the anatomic arrangement which makes it easier

to include the entire vascular and lymph node area in the resection. All agree that the logical procedure must include the terminal ileum and the right half of the transverse colon. The operative mortality, however, remains greater on this segment than elsewhere:

A group of 83 cases has been reported by Mayo,[5] with a mortality of 8.4 per cent. He prefers a one-stage procedure with open anastomosis. In the presence of obstruction, occurring in a small percentage of his cases, a two-stage modification was used. Doubtless, his preoperative preparation is excellent and one must bow to his surgical technique and to his judgment in the selection of cases for the proper procedure. In the hands of less experienced and less skillful surgeons, this method of attack would be associated with a mortality rate of approximately 20 per cent.

Lahey and Sanderson[6] have championed a Mikuliez type of resection as a primary operation. The closure of the originally complete ileal fistula is enhanced by an approximation suture between the colon and small bowel. The operation for final closure of the fistula requires a short period of hospitalization. In 112 resections for cancer by this method, they report 19 deaths, a mortality rate of 17 per cent. This procedure has been so well liked by this group that they have preferred it to all others. It does allow an immediate dissection in a virgin field and has that same advantage of a one-stage resection with anastomosis. It eliminates the danger of anastomosis added to the resection. Although others have found the complete ileal fistula such a serious problem that they have abandoned this type of operation, there are doubtless many tricks learned by experience to lessen this hazard.

Stone and McLanahan[7] prefer a one-stage resection in the absence of complete obstruction and stress immediate aseptic anastomosis. In 16 patients treated in this manner, there were 3 deaths.

Garlock and co-workers,[8] in their excellent analysis of their colon cases, report 7 completed two-stage right colectomies without a death, while other procedures including nonresectable lesions brought their total mortality in 30 cases to 33 per cent.

McKittrick[9] reports 11 one-stage right colectomies with 3 deaths and 17 two-stage procedures with 1 death.

I[3] analyzed the results at the Massachusetts General Hospital between 1925 and 1936 and found that one-stage resections produced a mortality rate of 20.5 per cent in 73 cases, while 18 two-stage operations done by the same group of surgeons in poorer risk patients resulted in 2 deaths or a 11 per cent mortality. This caused me to advocate the two-stage attack and I still believe it is the safest and most logical procedure.

There are certain lessons that we have learned that are worth recording. In the first place, it is well to delay the preliminary ileotransverse colostomy until the patient is in the best preoperative condition that can be obtained. Preliminary use of succinylsulfathiazole and the

TABLE I

CARCINOMA OF COLON*

	1 STAGE	DEATHS	MORTALITY (%)	2 STAGE	DEATHS	MORTALITY (%)	TOTAL	DEATHS	MORTALITY (%)
Right colectomies	13	7	53.8	44	7†	15.9	57	14	24.5
Left colectomies‡	16	3	18.7	70	8	11.4	86	11	12.7
Total resectability of stage operations	29	10	34.4	114	15	13.1			
Other resections§							26		
Not resectable							17 >43	10	23.3
Grand total (Resectability, 91 per cent)							186	35	18.8

*Exclusive of carcinoma of the rectum. Personal cases, 1925-1942.
†Includes 2 deaths after first stage when 2-stage procedure was planned.
‡Complementary cecostomy was done in these 1-stage operations.
§Includes transverse colectomies not done with right or left colectomies, obstructive resections, turn-out operations, and combined abdominoperineal resections.

Miller-Abbott tube are recommended. Aseptic anastomosis of the modified Parker-Kerr type has, in our hands, been satisfactory. The objections to two operations are not too convincing. They are often a safeguard for the patient and, after explanation, are always accepted by them with little complaint. The so-called double opportunity for surgical complication has not proved to be such a menace as is so often quoted. There can be no doubt that the first operation increases the technical difficulties of the second. We have also had one fatal case, mentioned above, of obstruction of small bowel from herniation through the trap left by the preliminary ileotransverse colostomy. Other non-fatal obstructions have occurred and have, at times, hastened the second stage. The Miller-Abbott tube has been helpful in preventing and dealing with this complication. One may make this trap larger, and therefore less likely to permit obstruction, by placing the anastomosis more than 12 inches from the ileocecal valve. After trying division of the terminal ileum at the time of anastomosis, we have abandoned it because the cut, fat edge of the mesentery produces a hazard by affording an opportunity for the small bowel to become fixed to it between stages. Anastomosis in continuity should be done with the ileum lying without torsion or tension against the center of the transverse colon. This allows for a better closure of the trap and a smooth peritonealization of the inner side of the cut mesentery at the second stage, thus reducing to a minimum the opportunity for ultimate small bowel obstruction. After the second stage, it is rarely possible to peritonealize adequately the right gutter. Therefore, we routinely drain this area through a stab wound in the flank. This has proved satisfactory and rarely have we been faced with a residual abscess in this region. Various methods have been suggested to manage the large, often infected, dead space resulting

from resection of an extensive growth in this region. Sulfonamides and drains of one kind or another have been used. Recently, Jones and his associates[10] advocated the Mikulicz pack for this purpose.

The *transverse colon* has been involved in approximately 11 per cent of the cases we have studied. If the lesion is in the proximal third of this segment, we believe it can be best treated by the method used for the right colon. On the other hand, if the mid-portion of the gut is involved, we are convinced that preliminary ileocolostomy is disadvantageous. First of all, in this region one may not get an accurate idea of the extent of the lesion by roentgenograms. After exploration, it is well to have in mind various operative procedures. Due to the often heavy greater omentum, this segment lends itself poorly to obstructive resection. Resection with aseptic suture in one stage has much to commend it. Stone and McLanahan[7] had only one death in 16 consecutive cases of transverse colectomy treated in this manner.

If obstruction is present, one may use preliminary cecostomy to advantage in lesions beyond the midcolon. The danger of applying it may be that the lesion cannot be accurately localized so that the cecostomy handicaps the final procedure. Preliminary ileosigmoidostomy may be considered. This may lead to an unnecessarily wide resection or may ultimately leave behind sizable defunctioned segments of bowel. Under no circumstances will I concede that preliminary tube ileostomy is justifiable for obstruction. If ileostomy under these circumstances must be indulged in, it must be complete and placed low in the abdominal wall. In these regions, it is apparent that intelligent preliminary use of the Miller-Abbott tube will find great usefulness.

In addition to the objections already stated to the stereotyped two-staged operations for lesions of the middle or distal thirds of the transverse colon is the very humiliating experience, quoted previously, regarding the abnormality of the blood supply to this region. Apparently, the usual anastomotic artery arising from the inferior mesenteric is not always present. If the resection is done in a virgin field, it would be easier to determine the viability of the bowel ends even in the presence of an abnormal fat deposit.

In the *distal transverse, splenic flexure, and upper descending colon,* we have an ideal situation for preliminary cecostomy followed by resection and aseptic anastomosis. The resection is often best accomplished through some modification of the transverse incision. In obese patients, this is particularly helpful. One may, with justification, prefer obstructive resection in this region. Immediate resection with anastomosis without preliminary drainage appears to be more hazardous in this segment than in others. It has been our experience that obstruction is more common in the splenic flexure than elsewhere in the bowel. Contiguous structures, such as the tail of the pancreas and the spleen as well as segments of small bowel and the fundus of the

stomach, are often involved. This means that preliminary decompression is even more imperative in this region. The site is rare but appears to represent a good one for cure, since metastases occur late.

The *descending colon*, being a straight tube, is invaded by cancer with less frequency than any other segment of its length. In our cases, only 9.6 per cent were in this region and this figure includes the splenic flexure.[1] Representing one of the fixed areas of the colon, one cannot exteriorize the segment involved with the same ease that is met in the sigmoid. Mobilization, however, is not difficult and can be enhanced by dividing the suspensory ligaments to the splenic flexure. Obstructive resection can be accomplished if proper effort is made to free the lateral attachments. This method has been popular and, if properly done, gives a satisfactory result. Preliminary cecostomy, followed in approximately 10 days by resection and aseptic end-to-end anastomosis, has been the method of choice in our hands. When one includes the efforts expended in closing the colostomy following obstructive resection, there is little choice on the basis of morbidity. Although an occasional preliminary tube cecostomy may heal slowly, it rarely requires surgical closure. In the absence of obstruction, one may elect to do resection and suture with or without complementary cecostomy. If no cecostomy is used, one should take advantage of the preliminary and postoperative decompression afforded by the Miller-Abbott tube. Complementary cecostomies heal more promptly than preliminary cecostomies. This is due to the use of a smaller tube and the shorter period of need for it.

The *sigmoid* represents the most frequent site of cancer in the large bowel, 53.9 per cent in our series. Tortuosity, favoring stasis, may be the chief reason for this. Bleeding and early signs of obstruction occur with great frequency. Although the operability in this region is high and the operative mortality is low, the cure rate of survivors is considerably less than it is in the right colon. Lymphatic spread and earlier liver metastasis probably account for this discrepancy.

Many patients with these lesions present themselves with complete obstruction. In order to relieve the acute phase of this complication, many methods have been suggested. The simplest and safest of these is cecostomy, which, if done promptly and with proper technique, is spectacular in its immediate effect. If the growth is large or has produced an abscess by perforation, it is often necessary to follow cecostomy a few days later by complete transverse colostomy. The method of Devine[11] has met with considerable popularity in this country. Having tried this a number of times in our clinic, we find it has sufficient disadvantages to offset those of simple loop colostomy and it has been practically abandoned by most of our staff. It is necessary, however, to rest the infected bowel until the inflammatory reaction subsides sufficiently to allow a thorough cleansing by repeated irrigations before an attempt is made to resect the primary disease.

That safety and operability are increased by this procedure, there can be little doubt. The only price paid for these advantages is the increased morbidity of additional hospital days.

Although the majority of growths in the sigmoid produce some obstruction by the time the surgeon sees them, many can be made operable without preliminary decompression. Often the bowel can be prepared by catharsis and enemas. The laxative effect of succinylsulfathiazole is spectacular. While the patient is receiving adequate preparation for surgery by increased vitamin intake, restoration of fluid and chemical balance, the bowel can be made a safer structure for surgery. Although it is the feeling of some that nothing more than such preparations are necessary before resection and immediate suture, a large number of surgeons prefer some form of preliminary decompression if suture is contemplated. Whipple[12] and Cave[13] have had a satisfactory experience with the use of the Miller-Abbott tube for decompression in some colon lesions, particularly the right. At this writing, I personally prefer a routine preliminary tube cecostomy followed 10 days later by resection and aseptic anastomosis. If one prefers the obstructive resection of Rankin in the left colon, there will be no need for preliminary decompression save in those patients who have complete obstruction on entry. The use of a small catheter vent in the proximal segment, placed near the clamp, has been found helpful in many cases where obstructive resection is used.

If, on exploration, one finds a lesion that would be best treated by proximal decompression, there is little excuse for the often used sigmoidostomy a few inches above the growth. This procedure complicates the ultimate resection tremendously. If, under these circumstances, the surgeon would make a small transverse incision high in the abdomen and bring out a loop of transverse colon, closing the original incision without drainage, he would greatly enhance the ultimate curative procedure.

Often one meets the situation of a low growth in the sigmoid that requires a change of plan. If the extension has involved the pelvic floor, one usually finds that combined abdominoperineal resection is the safest and easiest procedure to use. There are, however, two definite alternatives in selected cases. In the elderly poor-risk patient, one may do well to consider the "turn-out" operation as practiced by D. F. Jones.[14] This consists of sectioning of the bowel below the growth and turning it in as a blind rectal stump. The tumor and mesentery are removed leaving an end colostomy. Care must be taken to leave the closed segment above the peritoneal floor. If this is not possible, one must establish drainage in the ischial fossa from the perineum. One should be especially careful here to add the procedure, advocated in all bowel resections, of adequate dilatation of the rectal sphincter or a division of the sphincter muscle. It is possible after the

turn-out operation to re-establish continuity of the bowel at a later date but usually this is not practical.

The other possibility, and one more frequently used, is a low anastomosis at the time of resection. This is greatly enhanced by a preliminary complete transverse colostomy, since this is the best method to allow proper preoperative cleansing of the bowel. In this region, aseptic anastomosis is more difficult and a well-prepared segment adds to the safety of open suture. Rankin has advocated the stepping down of the pelvic floor to allow this low suture to come within the peritoneal cavity and when possible this should be done. Stricture, requiring tedious dilation, results if the anastomosis is placed below the pelvic floor.

GENERAL CONSIDERATIONS

Chemotherapy is at the moment in great favor and much is still being learned about this tremendous aid in colon surgery. Intraperitoneal use of sulfanilamide has been received enthusiastically. Experience has shown that this drug may be detrimental to the liver when so used, since it is so rapidly absorbed through the portal system. This has led to a reduction in the amount of the drug used in this manner and to the consideration of preliminary use of sulfadiazine to an adequate blood level. Also, through the research of Poth,[15] there has been developed succinylsulfathiazole. This drug has many advantages in the preparation of patients with colon lesions for operation. It is supposed to be poorly absorbed into the general circulation and to have the effect of reducing the bacterial count of the colon contents. It further produces a laxative effect, which is advantageous in these cases. The daily dosage is worked out on the basis of kilograms of body weight which must be modified in obese patients. The preliminary use of 8 Gm. per day for five days in the average adult is perhaps a good general rule. We have been enthusiastic regarding the unusually smooth convalescence in combined abdominoperineal resection following its use.

Firor[16] has called attention to the tendency of bleeding from the tumor following its use. We have observed this complication in at least 3 patients in a small experience; in none of these was the hemorrhage of a dangerous degree and all took place on the fifth day, or the day prior to the planned operation. In one instance, petechial hemorrhages of the brain, as well as generalized gastrointestinal bleeding, occurred postoperatively which, we believe, contributed to the patient's death. The prothrombin time in this patient was not appreciatively elevated. It is fair to say that intravenous pentothal sodium, used as an adjuvant anesthesia in this case, may have played a role in the hemorrhagic tendency. At post-mortem, a moderate amount of local infection was found near the operative site, which had fol-

lowed an open anastomosis in the sigmoid. This is the only instance in which we have been able to observe the local area following its use, but we have been impressed by the lack of clinical evidence of intraperitoneal infection in all other cases.

Although we believe that proper use of the sulfonamides will prove helpful in dealing with colon surgery, we cannot overemphasize the caution that it is to be looked upon only as an aid and is not to permit the slightest breakdown in the proved surgical principles heretofore established. One may keep the blood level at a satisfactory point by the postoperative use of sulfadiazine. Delayed infection may be expected under these circumstances. Late abscess formation and wound sepsis, requiring drainage, have occurred occasionally in our cases following its use. There has been, however, no increase in these complications and aside from the occasional prolonged convalescence, it is a small price to pay for the obvious benefits derived. Pulmonary and urinary complications are greatly reduced.

The *Miller-Abbott tube* has been helpful in dealing with cancer of colon. We have previously referred to Whipple's enthusiastic report concerning its use. McKittrick and Warren[17] have stressed another use, which is worthy of emphasis. When a colectomy is planned, one often finds an abnormal interference from normally full small bowel. If the Miller-Abbott tube is introduced 36 hours before operation and suction has been maintained, one finds the small intestine decompressed and fluted on the tube in such a fashion to make it a simple procedure to get at the colon with very little need of trauma to the peritoneal surface of the bowel. This not only makes the operation easier to accomplish but leaves a decompression of the whole intestinal tract above the suture line. This prevents the occasional ileus seen following operations of this sort and is, in fact, at times a lifesaving procedure if used as an afterthought rather than as a precaution.

Experience with the Miller-Abbott tube causes me to mention these warnings. The use of the stylet, as advocated by Abbott[18] for introduction of the tube, is a tremendous advantage. If the technique is followed closely, no harm results and many needless roentgenograms are unnecessary. The time involved under the fluoroscope is short and one knows how much reliance can be placed on the tube. This technique is tremendously important in the presence of obstruction or ileus. One may wait for nature to propel the tube through the pylorus when using the tube for precautionary measures, but never if the need for it is immediate or urgent.

Having had the harrowing experience of not being able to deflate an apparently perfect balloon after operation and the need of an emergency laparotomy in the nick of time to prevent a fatal gangrene of the intestine in a patient on whom a preoperative tube was passed, I

turn-out operation to re-establish continuity of the bowel at a later date but usually this is not practical.

The other possibility, and one more frequently used, is a low anastomosis at the time of resection. This is greatly enhanced by a preliminary complete transverse colostomy, since this is the best method to allow proper preoperative cleansing of the bowel. In this region, aseptic anastomosis is more difficult and a well-prepared segment adds to the safety of open suture. Rankin has advocated the stepping down of the pelvic floor to allow this low suture to come within the peritoneal cavity and when possible this should be done. Stricture, requiring tedious dilation, results if the anastomosis is placed below the pelvic floor.

GENERAL CONSIDERATIONS

Chemotherapy is at the moment in great favor and much is still being learned about this tremendous aid in colon surgery. Intraperitoneal use of sulfanilamide has been received enthusiastically. Experience has shown that this drug may be detrimental to the liver when so used, since it is so rapidly absorbed through the portal system. This has led to a reduction in the amount of the drug used in this manner and to the consideration of preliminary use of sulfadiazine to an adequate blood level. Also, through the research of Poth,[15] there has been developed succinylsulfathiazole. This drug has many advantages in the preparation of patients with colon lesions for operation. It is supposed to be poorly absorbed into the general circulation and to have the effect of reducing the bacterial count of the colon contents. It further produces a laxative effect, which is advantageous in these cases. The daily dosage is worked out on the basis of kilograms of body weight which must be modified in obese patients. The preliminary use of 8 Gm. per day for five days in the average adult is perhaps a good general rule. We have been enthusiastic regarding the unusually smooth convalescence in combined abdominoperineal resection following its use.

Firor[16] has called attention to the tendency of bleeding from the tumor following its use. We have observed this complication in at least 3 patients in a small experience; in none of these was the hemorrhage of a dangerous degree and all took place on the fifth day, or the day prior to the planned operation. In one instance, petechial hemorrhages of the brain, as well as generalized gastrointestinal bleeding, occurred postoperatively which, we believe, contributed to the patient's death. The prothrombin time in this patient was not appreciatively elevated. It is fair to say that intravenous pentothal sodium, used as an adjuvant anesthesia in this case, may have played a role in the hemorrhagic tendency. At post-mortem, a moderate amount of local infection was found near the operative site, which had fol-

6. Resection with immediate aseptic anastomosis is our method of choice for the second stage. The Parker-Kerr type of anastomosis has been satisfactory to us.

7. Delayed closure of the abdominal wound by Coller's technique 48 hours after resection is recommended.

REFERENCES

1. Allen, A. W., and Welch, C. E.: Malignant Disease of the Colon, Am. J. Surg. 46: 171-180, 1939.
2. Allen, A. W., and Welch, C. E.: Cecostomy, Surg., Gynec. & Obst. 73: 549-552, 1941.
3. Allen, A. W.: Right Colectomy for Malignant Disease, J. A. M. A. 109: 923-927, 1937.
4. U. S. Public Health Report 53: 816, 1938.
5. Mayo, C. W.: Discussion on Papers of Drs. Lahey and Sanderson, and Drs. Stone and McLanahan, J. A. M. A. 120: 1365-1366, 1942.
6. Lahey, Frank H., and Sanderson, Eric: Lesions of the Right Colon Involving Right Colectomy, J. A. M. A. 120: 1356-1362, 1942.
7. Stone, H. B., and McLanahan, S.: Resection and Immediate Aseptic Anastomosis for Carcinoma of the Colon, J. A. M. A. 120: 1362-1367, 1942.
8. Garlock, J. H., Ginzburg, L., and Glass, A.: Complications and Causes of Mortality of the Surgical Treatment of Carcinoma of the Colon and Rectum, Surg., Gynec. & Obst. 76: 51-59, 1943.
9. McKittrick, L. S.: Carcinoma of the Right Colon; Its Diagnosis and Principles of Treatment, Rhode Island M. J. 24: 161-165, 1941.
10. Jones, T. E., Paxton, J. R., and Brubaker, R. E.: The Intra-Abdominal Uso of the Mikulicz Pack, Ann. Surg. 117: 256-263, 1943
11. Devine, H.: Operation on a Defunctioned Distal Colon, SURGERY 3: 165, 1938.
12. Whipple, Allen O.: Use of Miller-Abbott Tube in Surgery of Large Bowel, SURGERY 8: 289, 1940.
13. Cave, Henry W.: Discussion of Papers on Cachexia Colon, J. A. M. A. 120: 1365, 1942.
14. Jones, D. F.: Diagnosis and Principles of Treatment of Carcinoma of Colon and Rectum, Tr. Am. S. A. 49: 308, 1931.
15. Poth, E. J.: Succinylsulfathiazole: An Adjuvant in Surgery of the Large Bowel, J. A. M. A. 120: 265-269, 1942.
16. Firor, W. M.: Intestinal Antisepsis With Sulfonamides, Ann. Surg. 115: 829-832, 1942.
17. McKittrick, L. S., and Warren, R.: The Use of the Miller-Abbott Tube in Subtotal Colectomy and Other Surgical Procedures, J. A. M. A. 117: 345-346, 1941.
18. Abbott, W. O.: Indications for the Use of the Miller-Abbott Tube, New England J. Med. 225: 641-647, 1941.
19. Coller, F., and Valk, W.: The Delayed Closure of Contaminated Wounds, Tr. South. S. A. 52: 449-464, 1939.
20. Pemberton, J., and Black, B.: Delayed Closure of Incisions Made at Closure of Colonic Stomas, Surg., Gynec. & Obst. 76: 385-390, 1943.

wish to urge that all surgeons request the anesthetist to deflate the balloon while the abdomen is open. This, in addition to a careful construction of the balloon beforehand, may prevent others from encountering such a complication.

Delayed wound closure has been re-emphasized by Coller and Valk.[19] Although wound sepsis following operations upon the colon is not often fatal, it does occur in a certain percentage of cases. No matter how much care is used in protecting the wound surfaces or how accurately instruments and gloves used in the handling of the bowel are discarded, there can be no doubt that primarily closed wounds under these circumstances become infected in a greater number of cases than in the usual clean abdominal operations. We have used Coller's technique or a modification of it with great satisfaction. The sutures are often tied without anesthesia but in the timorous patient, a small dose of pentothal sodium permits the procedure without the patient's knowledge. Pemberton and Black[20] have modified Coller's technique somewhat and report the advantages of the delayed closure in their clinic. We feel that this adjunct to colon surgery should be particularly emphasized now, since so much reliance is being placed on the sulfonamides. Not only is the local use of sulfonamides in wounds of this kind detrimental to healing but delayed wound infection, occurring following the use of these drugs, frequently prolongs convalescence well beyond the usual period of time.

SUMMARY AND CONCLUSIONS

1. Carcinoma of the colon accounts for at least 11 per cent of the deaths from cancer in the United States. It is a favorable site for cure, when diagnosed and treated early. Further effort should be made to reduce the time interval between onset of symptoms and hospital admission.

2. Resectability should be substituted for the term operability. In our own 186 cases of colon cancer, 91 per cent were resectable.

3. Mortality and morbidity are directly related to resectability. Morbidity figures should include time used for closure of fistula.

4. Immediate removal of the growth is not as important as proper preoperative preparation. This includes the use of sulfonamides, cleansing the involved bowel, the preliminary use of the Miller-Abbott tube, and supportive measures.

5. Preliminary ileotransverse colostomy with aseptic suture is advocated for lesions of the right colon and the proximal third of the transverse colon. Preliminary tube cecostomy is advocated for lesions of the remaining colon. These procedures will increase the resectability rate in this group of patients, which to our minds offsets the added morbidity. It also appears to reduce our mortality rate.

cancer from the Cincinnati General Hospital and the Christian R. Holmes Hospital, performed by various members of the resident and visiting staffs. A total of seventy patients with cancer of the large bowel were seen, of which forty-five were treated by resection.

At the General Hospital twenty-five cases out of forty-eight were treated by resection. At the Holmes Hospital, working with private patients, twenty out of tweny-two were treated by resection. This illustrates vividly the difference in operability seen in a private and a charity clinic. The operability rate in the total group is shown in Table I.

TABLE I

OPERABILITY RATE

	CASES	RESECTIONS	OPERABILITY (%)
Right colon	28	17	60.7
Transverse colon	8	7	87.5
Left colon	34	21	61.7
Total	70	45	64.2

This rate of 64.2 per cent corresponds fairly well with rates reported from other clinics. It must be pointed out, however, that if General Hospital cases alone had been considered, the rate would have been only 52 per cent, while at the Holmes Hospital it was 90.9 per cent. It must be remembered in this connection that when dealing with private patients, one that is unquestionably inoperable may never be admitted to the hospital, but remains at home. In a charity institution, this situation is often entirely reversed, a family or a family doctor sending the patient to the hospital to die. At times there may be considerable difference of opinion as to what constitutes an operable case. Several of the patients at the General Hospital probably should not have had resections. At least three had liver metastases at the time of operation. One had a fistula from a perforated carcinoma of the sigmoid. One had a sigmoid colostomy performed elsewhere immediately above a carcinoma which was said to be inoperable. In this instance resection of the colostomy and tumor was carried out in one stage. In three, a palliative ileotransverse colostomy was done, although resection was never accomplished.

The following general plan of management is used here for patients coming to the hospital with signs of intestinal obstruction. A preliminary examination is first made to determine, if possible, whether the obstruction is in the small or large bowel. Such things as distension, intestinal patterns, peristaltic activity are, of course, looked for. In addition, especial attention is paid as to whether there is a palpable abdominal or pelvic mass, a scar of a previous operation, a strangulated hernia, or other localizing sign. If there is no strangulated hernia the patient next goes to the x-ray room for flat films of the abdomen. This is followed by a barium enema when flat films alone are not conclusive. If the obstruction can be localized in the large bowel, other than the

CANCER OF THE COLON

M. M. ZINNINGER, M.D., AND PAUL I. HOXWORTH, M.D., CINCINNATI, OHIO
(From the Department of Surgery, College of Medicine of the University of Cincinnati, and the Cincinnati General Hospital)

IN SPITE of improvements in both immediate and end results obtained by resection of the colon, reported during the past decade, the condition still constitutes an important public health problem, and surgeons are still not entirely agreed as to the best method of treatment. The chief problem, as with cancer elsewhere in the body, is how to get the patient to come to the doctor early in the course of the disease, and then how to get the first doctor who sees the patient to make the diagnosis promptly and arrange for resection to be done. That the condition can often be cured by resection, and by no other method at present available, has been amply demonstrated, and the differences of opinion among surgeons have to do largely with differences in the technique of resection and re-establishment of continuity of the bowel after resection. There is quite general agreement as to the amount of bowel and mesentery that needs to be removed, for this is based on anatomic studies of the regional lymphatic drainage and the blood supply to the parts which have been studied rather carefully. In most clinics a plan of management has been established which works well in the hands of the surgeons in that clinic, though it may differ considerably from methods used elsewhere. At this clinic our preference is for anastomosis, by either an open or a closed method, at the same time the resection is done, rather than for the use of delayed anastomosis by some modification of the Mikulicz principle. In our hands, over a period of years, delayed anastomosis has led to prolonged or repeated hospitalization, with no evidence of better results than by immediate anastomosis. At a municipal institution such as the Cincinnati General Hospital one sees probably the worst and most frequent instances of delay on the part of both patients and referring doctors as far as early diagnosis is concerned. Most of the patients seen by the surgical service here have had the disease for many months, often for years; most of them have complete obstruction when admitted to the hospital, and many have reached the stage when resection is no longer possible. Almost all of them come from lower income groups and many have been living on poor diets and under poor hygienic conditions. They present a sharp contrast to patients seen in private practice, such as those that present themselves at a private clinic. For the five-year period from the end of 1937 to January, 1943, we have reviewed the cases of resection of the large bowel for

Received for publication, April 2, 1942.

tomy through a right rectus incision, dividing the ileum and turning in the distal end. The diversion of the fecal current usually allows the inflammatory reaction to subside, and at a subsequent stage, the resection is carried out through a transverse incision. Ileotransverse colostomy as the first procedure was carried out five times, but in three of the cases it was only palliative and was not followed by resection (see Table II). In the other two cases, resection was carried out several weeks after the anastomosis. Only three of the seventeen patients with cancer of the right side of the colon which were resected showed obstruction. Of the twenty-eight resected for cancer of the transverse and left colon (see Table III), thirteen or almost one-half had complete or almost complete obstruction at the time of admission to the hospital. In all of these a cecostomy or transverse colostomy was done to relieve the obstruction, and the resection done subsequently. In eight others a preliminary decompression was done prior to the resection, leaving only seven of the twenty-eight that had resection without preliminary decompression. This does not mean that we favor preliminary decompression but we may be forced to use it due to the particular situation presented by the patient. In the absence of obstruction we do not hesitate to perform resection with immediate anastomosis without decompression.

TABLE II

RIGHT COLECTOMY WITH ILEOTRANSVERSE COLOSTOMY

Cecum	7	End-to-side (one stage)	2
Ascending colon	3	Side-to-side (one stage)	13
Hepatic flexure	7	Side-to-side (two stage)	2
Total	17		17

TABLE III

RESECTIONS TRANSVERSE AND LEFT COLON

Transverse	7	End-to-end	23
Splenic flexure	3	Side-to-side	3
Sigmoid	18	Mikulicz	2
Total	28		28

Anesthesia in practically all cases is obtained by nitrous oxide oxygen and ether induction, followed by ether through an intratracheal tube, using a closed system. With an anesthetist, properly trained in this method, it gives adequate relaxation, and a low incidence of postoperative pulmonary complications. At the completion of the operation, the trachea is sucked dry with a catheter through the intratracheal tube before it is removed. Preoperative medication consists usually of morphine and scopolamine in a ratio of 25 to 1 about three-fourths hour before induction. Nembutal, gr. 1½, is generally given about one and one-half hours before operation. Postoperatively, the patient is turned frequently. He is instructed to take ten deep breaths at least three times a day, preferably every two hours, during the first few days.

cecum, ascending colon, or hepatic flexure, a cecostomy is done under local anesthesia as soon as general preoperative measures have been carried out. In patients without definite obstruction, and in whom large bowel cancer is suspected, the diagnosis can generally be established by barium enema, and double contrast enema, or by sigmoidoscopy in low-lying lesions. It is often surprising to us to see how many patients have a palpable abdominal mass known to them or to their physician, without any adequate study having been carried out. The diagnosis having been established with reasonable certainty, a period of preoperative preparation is started. The general features of this preparation are the same, but may be varied depending upon special indications. The patient is placed on a high calorie, low residue diet, and an attempt is made to empty the large bowel as completely as possible. If a cecostomy has been produced, irrigations through the cecostomy tube are given daily as well as rectal enemas. If no enterostomy has been performed, the patient is given mild saline cathartics daily to give a watery stool which will pass through the partial obstruction if one is present, and this is supplemented with daily enemas. It is important to get rid of all the barium from the barium enema, for if this remains above the obstruction it may become inspissated and form hard, almost rocklike masses. If in doubt, fluoroscopic examination or x-ray films should be used to determine this point. Adequate vitamin intake either orally or parenterally is advisable. The blood count and plasma proteins should be brought to satisfactory levels if they are low, by blood or plasma transfusions. The giving of sulfonamide compounds by mouth preoperatively has been used sporadically, but has not been adopted as a routine. Further clinical trial is desirable before the value of such treatment can be assessed. Twenty-four hours before operation, the patient goes on a liquid diet and lead and opium pills I, t.i.d., are given to place the large bowel at rest.

The general management differs somewhat depending on whether the cancer is situated in the right or left half of the colon, and on whether obstruction is of high grade or is relatively unimportant. Signs of associated local inflammation may also influence what is done. Cancer of the cecum and ascending colon is rarely associated with high-grade obstruction. This is probably due to the fact that the lumen of this portion of the bowel is large and the contents fluid or very soft. The anemia which is described as characteristic of cancer in this location we have not found to be regularly present. Tumors here are often polypoid and bulky, and in many of the ones we have seen a mass was palpable at the time of admission to the hospital. In many of them, infection had occurred, and an inflammatory mass with or without abscess formation was present in addition to the tumor. The differential diagnosis between appendical abscess, diverticulitis, tuberculosis, and infected tumor may be exceedingly difficult in such instances. In managing infected tumors we usually perform first an ileotransverse colos-

back for a second row. This may be reinforced by several mattress sutures of silk. Each of these methods of inversion turns the bowel in completely so that there is no closed cavity such as is obtained when the bowel is tied before inversion.

After both ends of bowel are closed, the terminal ileum is held alongside the longitudinal band of the transverse colon, and a side-to-side anastomosis is done near the ends in order to leave as little blind stump as possible. The method used is that of the Halsted gastroenterostomy. The field is carefully walled off with gauze packs. Traction sutures of silk are placed at each end of the proposed anastomosis, and a posterior continuous suture of medium silk is placed (Fig. 1, *1*). Halsted mattress sutures of silk are then laid anteriorly (Fig. 1, *2*). These are next pulled aside, half to each end. Before opening the bowel, a temporary occlusion is produced to prevent gross soiling. Formerly rubber-shod clamps were used for this purpose. Recently, however, we have used a device made by our diener in the experimental laboratory. This consists of a bar of lead about 5 by 3 mm. in cross section. This is covered with soft rubber tubing. When bent on itself like a hairpin, it can be placed across the bowel and will hold approximately any position into which it is placed. It can be placed around the bowel with just the amount of pressure desired and will occlude sufficiently to prevent fluid and gas from escaping. Two such devices can be used, one across the terminal ileum, the other across the transverse colon. At the site of anastomosis itself no clamps are used. The bowel is held up by the assistant lifting the traction sutures, and there is ordinarily no escape of intestinal contents. The bowel is opened with a knife and scissors, and bleeding points are clamped and tied with 000 chromic catgut (Fig. 1, *3*). The posterior suture line is reinforced with a continuous lock stitch of 0 or 00 chromic catgut which goes through the entire thickness of both bowel walls (Fig. 1, *4*). The ends of the anterior row of mattress sutures are then pulled up, the traction sutures are cut or pulled aside, and when the mattress sutures are drawn up to approximate the bowel and tied, the anterior lip of the anastomosis is closed (Fig. 1, *5*). A Lembert suture of fine silk is then placed between each two mattress sutures. The angles of the anastomosis are reinforced with mattress sutures of silk, and the occluding rubber-shod clamps or lead bar clips are removed. After removing the protecting gauze packs, the gloves are changed before continuing the operation. The overlapping folds of mesentery are sutured together to close the defect, and the terminal ileum and its mesentery are dropped into the flank to cover and partly peritonealize the raw area. In recent months, sulfanilamide powder has been dusted into the peritoneal cavity before closure. The exact method of closure has differed with individual operators. As a rule, the peritoneum is closed with continuous catgut. The wound is then thoroughly but gently irrigated with saline solution, the muscle and fascia closed with interrupted figure-of-eight sutures of doubled medium

He is watched carefully for signs of atelectasis, and at the first evidence of this complication, he is turned with the affected side up and encouraged to cough. In most instances this leads to expulsion of the occluding plug, and aspiration with a catheter is not necessary, although aspiration with or without bronchoscopy is used if posture and coughing fails to accomplish the desired result.

In uncomplicated cancer of the cecum, ascending colon, or hepatic flexure, a one-stage resection and anastomosis is done. During recent years the procedure has been carried out through a transverse incision extending into the flank, similar to that described by Hoag[2]. The patient is turned slightly to the left side and usually the gall bladder bridge is elevated slightly to obtain better exposure. We believe that the exposure through this incision is better than that obtained by a vertical incision, peritonealization of the defect is easier, and the patient has less postoperative discomfort. After careful exploration of the abdomen to determine whether metastases to the regional glands or to the liver are present, the cecum and ascending colon are mobilized by dividing the lateral peritoneal reflection and rolling the bowel medially. The ureter and spermatic or ovarian vessels must be identified and the former traced down over the brim of the pelvis and up to the kidney. The rest of the fat and gland-bearing tissue in the flank must be freed and carried medially with the bowel and mesentery. The dissection is carried up to the origin of the right colic artery. At the upper end, the retroperitoneal portion of the duodenum is identified and carefully freed from the mesentery of the colon. In lesions of the hepatic flexure and first part of the transverse colon it may be necessary carefully to free the transverse mesocolon from the pyloric end of the stomach or first portion of the duodenum. After freeing the bowel well beyond the lesion, and deciding upon the site for its division, the mesentery is cut across from that point to the origin of the right colic artery. We prefer to divide the peritoneum first, and isolate and ligate each vessel separately with silk, rather than divide the mesentery between clamps and then tie off each clamp as is so often done. The mesentery of the terminal 5 to 6 inches of ileum is similarly treated by dividing the peritoneum on each side and isolating and transfixing each vessel with silk. In most instances we have closed both the terminal ileum and the transverse colon, and then done a side-to-side anastomosis, although in a few recent cases the colon only has been closed and the end of the ileum implanted into the side of the colon by a closed method. If side-to-side anastomosis is to be done, the bowel is divided at both ends of the portion to be resected with the cautery between straight Kocher clamps, and removed. The method of closure of the stump is important. A number of plans have been employed but two are used most often. One of these is simple closure with a series of Halsted mattress sutures of medium silk. The other is the use of an inverting right angle suture (Cushing suture) of catgut over the Kocher clamp, which is continued

back for a second row. This may be reinforced by several mattress sutures of silk. Each of these methods of inversion turns the bowel in completely so that there is no closed cavity such as is obtained when the bowel is tied before inversion.

After both ends of bowel are closed, the terminal ileum is held alongside the longitudinal band of the transverse colon, and a side-to-side anastomosis is done near the ends in order to leave as little blind stump as possible. The method used is that of the Halsted gastroenterostomy. The field is carefully walled off with gauze packs. Traction sutures of silk are placed at each end of the proposed anastomosis, and a posterior continuous suture of medium silk is placed (Fig. 1, *1*). Halsted mattress sutures of silk are then laid anteriorly (Fig. 1, *2*). These are next pulled aside, half to each end. Before opening the bowel, a temporary occlusion is produced to prevent gross soiling. Formerly rubber-shod clamps were used for this purpose. Recently, however, we have used a device made by our diener in the experimental laboratory. This consists of a bar of lead about 5 by 3 mm. in cross section. This is covered with soft rubber tubing. When bent on itself like a hairpin, it can be placed across the bowel and will hold approximately any position into which it is placed. It can be placed around the bowel with just the amount of pressure desired and will occlude sufficiently to prevent fluid and gas from escaping. Two such devices can be used, one across the terminal ileum, the other across the transverse colon. At the site of anastomosis itself no clamps are used. The bowel is held up by the assistant lifting the traction sutures, and there is ordinarily no escape of intestinal contents The bowel is opened with a knife and scissors, and bleeding points are clamped and tied with 000 chromic catgut (Fig. 1, *3*). The posterior suture line is reinforced with a continuous lock stitch of 0 or 00 chromic catgut which goes through the entire thickness of both bowel walls (Fig. 1, *4*). The ends of the anterior row of mattress sutures are then pulled up, the traction sutures are cut or pulled aside, and when the mattress sutures are drawn up to approximate the bowel and tied, the anterior lip of the anastomosis is closed (Fig. 1, *5*). A Lembert suture of fine silk is then placed between each two mattress sutures. The angles of the anastomosis are reinforced with mattress sutures of silk, and the occluding rubber-shod clamps or lead bar clips are removed After removing the protecting gauze packs, the gloves are changed before continuing the operation. The overlapping folds of mesentery are sutured together to close the defect, and the terminal ileum and its mesentery are dropped into the flank to cover and partly peritonealize the raw area In recent months, sulfanilamide powder has been dusted into the peritoneal cavity before closure. The exact method of closure has differed with individual operators. As a rule, the peritoneum is closed with continuous catgut. The wound is then thoroughly but gently irrigated with saline solution, the muscle and fascia closed with interrupted figure-of-eight sutures of doubled medium

black silk or of No. 1 chromic catgut, and the skin with interrupted fine silk. With catgut suture of the fascia, stay sutures may be used, but with silk closure ordinarily no stay sutures are placed. In a few cases closure with through-and-through silver wire was employed.

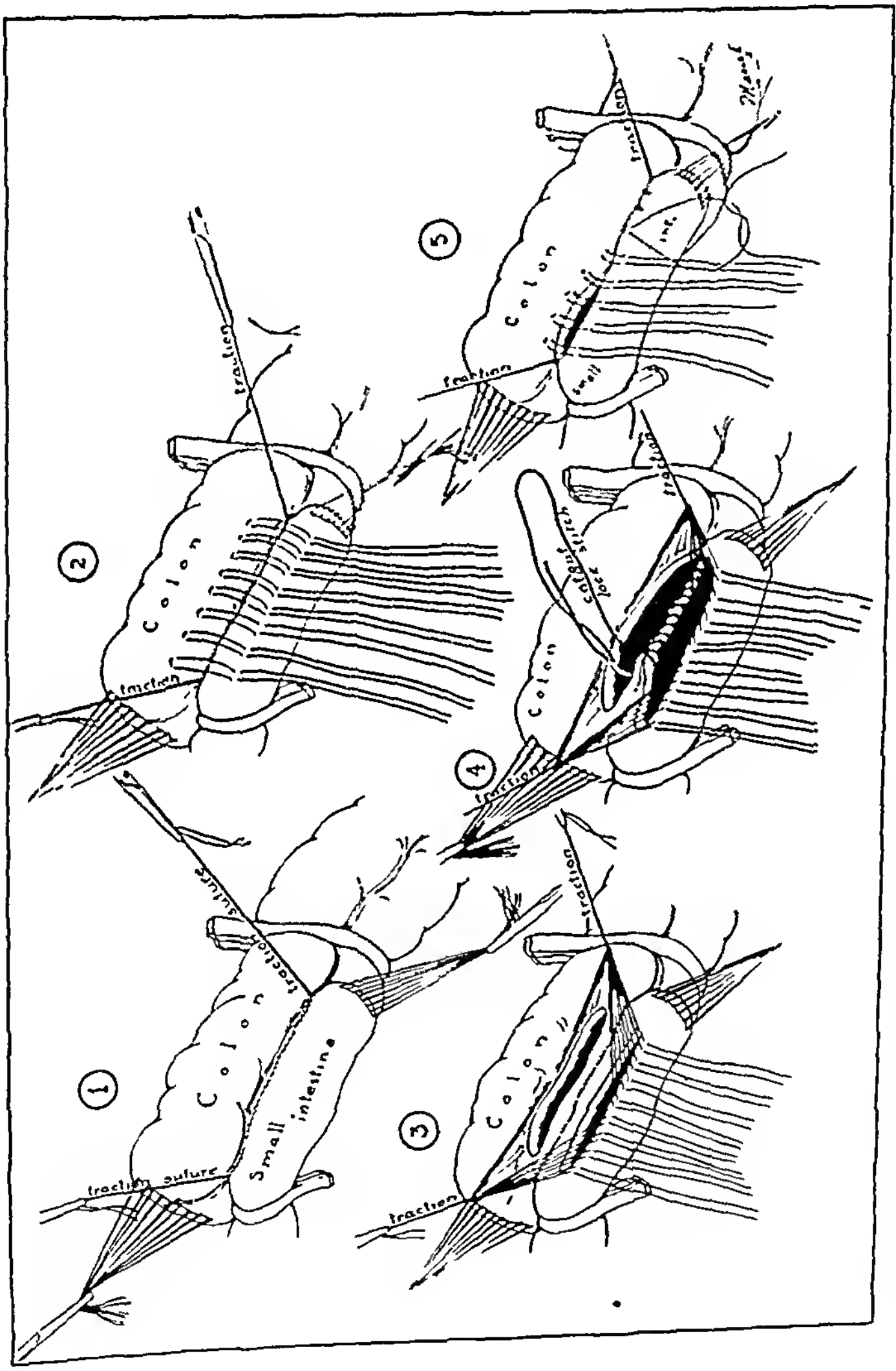

Fig. 1.—Steps in side-to-side ileocolostomy. (*1*) Posterior continuous suture of silk between two traction sutures. (*2*) Anterior row of Halsted mattress sutures placed. (*3*) Mattress sutures pulled aside; incisions made in bowel and vessels clamped and tied with catgut. (*4*) Posterior lock stitch of catgut through all layers of bowel. (*5*) Mattress sutures pulled up and tied.

In two recent cases in which end-to-side anastomosis was performed, the procedure used was a modification of a method described by Rankin.[1] After the cut end of the colon is closed, a site is selected for the anastomosis along the longitudinal band of the colon. A portion is tented up by grasping it with two Allis clamps. A straight Kocher clamp is then placed across this area longitudinally and the protruding portion, which is made to correspond in size with the diameter of the ileum, is excised

with the cautery (Fig. 2, *2*). The stump of the ileum, which is held in a Kocher clamp, is then approximated to the defect in the colon and the anastomosis is begun. Using an atraumatic needle a posterior running suture of chromic catgut is placed with a tie at the beginning and a lock at the other end, leaving both ends long in order to tie them later to each end of the anterior suture (Fig. 2, *3*). The Kocher clamps are then rotated inward and a continuous right angle (Cushing) suture is then placed anteriorly with no tie at either end (Fig. 2, *4*). The clamps are then withdrawn as the assistant makes traction on one end to begin the inversion. The operator completes the inversion by making traction on the other end of the anterior suture. Agglutination of the crushed

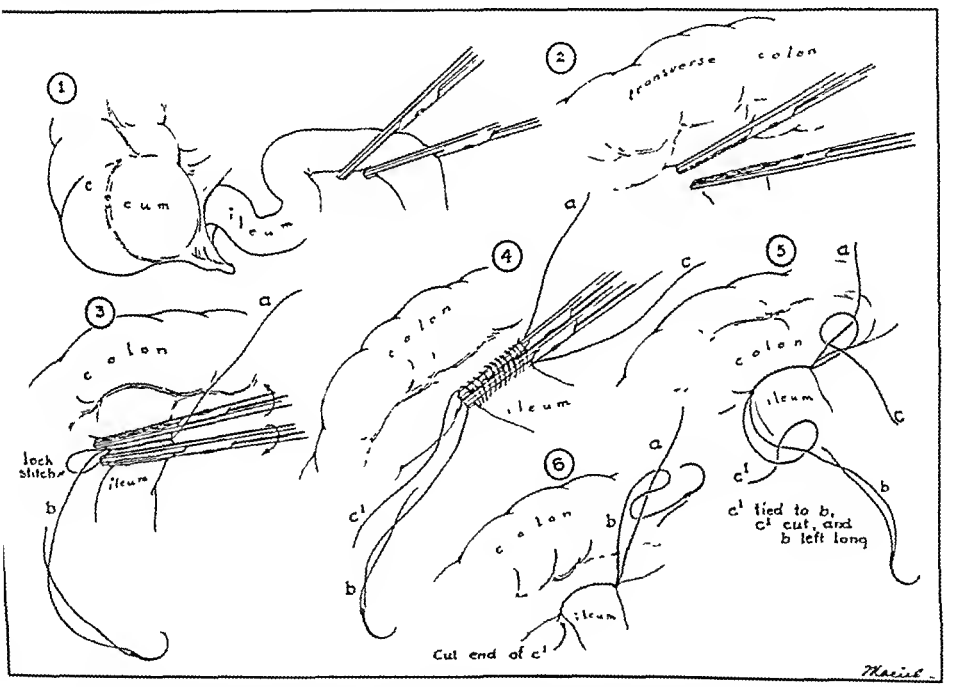

Fig. 2.—Steps in end-to-side ileocolostomy. (*1*) Division of terminal ileum. (*2*) Kocher clamp on side of colon. (*3*) Posterior continuous suture of catgut. (*4*) Anterior right angle (Cushing) suture of catgut over clamps. (*5*) Anterior suture pulled up after clamps are removed. (*6*) Posterior suture continued as second anterior layer.

ends of the bowel is depended upon to maintain closure until the inversion is accomplished. Corresponding ends of the anterior and posterior sutures are then tied (Fig. 2, *5*). The long end of the posterior suture is then continued around anteriorly and tied, forming a second anterior suture line (Fig. 2, *6*). The continuity of the lumen is established by invaginating the walls of the ileum and colon with the thumb and forefinger. The anastomosis is reinforced posteriorly and at the angles with interrupted Lembert sutures of fine silk. A portion of omentum is anchored loosely over the site of the anastomosis with fine silk and

sulfanilamide powder is dusted into the region. The same attention is directed to the mesentery and denuded area as described previously in the open type of anastomosis.

For lesions beyond the hepatic flexure, an end-to-end aseptic anastomosis is usually done. During recent years, this anastomosis has been done as a rule, using the Stone clamp. This clamp has been most satisfactory in our hands, and is the only clamp which we have tried that always seems to work well. Prior to the introduction of the Stone clamp, the anastomosis was made over straight Kocher clamps or over special clamps similar to a Kocher, but without teeth, and with the blades serrated lengthwise of the blade instead of crosswise. Extreme care is taken to remove carefully the appendices epiploicae and other fat tabs from the bowel at the proposed site of anastomosis. Only in this way can accurate, careful suture with serosal approximation be attained. Wide excision of the lesion and mesentery must be made, the cut ends must be free to come together without tension, and the blood supply must be preserved carefully to the cut ends. The clamps are usually placed somewhat diagonally so that the antimesenteric border is somewhat shorter than the mesenteric. Suture is ordinarily accomplished with a single row of Halsted mattress sutures of medium silk. After dividing the mesentery and preparing the bowel for suture, it is divided between clamps with the cautery. A row of mattress sutures is then laid posteriorly, just far enough from the clamps so that they can be pulled up and tied (*Fig. 3, 1, 2,* and *3*). The anterior row of mattress sutures is then laid (Fig. 3, *3*). A rubber-shod clamp or the rubber covered lead bar is then placed across the proximal loop to prevent bowel content from exerting pressure on the cut end of the bowel. The Stone clamps are then removed, the cautery searing being relied upon to prevent the bowel ends from opening, as described by Searff.[3] The anterior row of mattress sutures is then pulled up and tied, completing the stoma (Fig. 3, *4*). A Lembert suture of fine silk is placed between each two Halsted sutures. Serosal approximation at the mesenteric border is exceptionally important and must be obtained by careful placing of sutures. After the suture is completed, a finger must be invaginated through the anastomosis to make sure that the lumen is patent and that there is not too much of a cuff turned in. For resection and anastomosis of rectosigmoid lesions very low in the pelvis, it is important to put the clamps on in an anteroposterior direction rather than from side-to-side, and sometimes straight Kocher clamps can be used advantageously, the handles of the clamps coming out just above the symphysis pubis. In this position, two lateral rows of sutures are placed, one on the right side and the other on the left of the clamps instead of an anterior and posterior row, for low in the pelvis it is almost impossible to place a posterior row. Using this method, we have occasionally made anastomoses to the rectum below the peritoneal reflection.

It must be admitted that this entire method of aseptic end-to-end anastomosis with one row of Halsted mattress sutures is not suitable to the occasional operator or indeed to anyone who is not willing to pay attention to detail, to place each individual suture with care and precision, after careful preparation of the bowel to receive the sutures. As

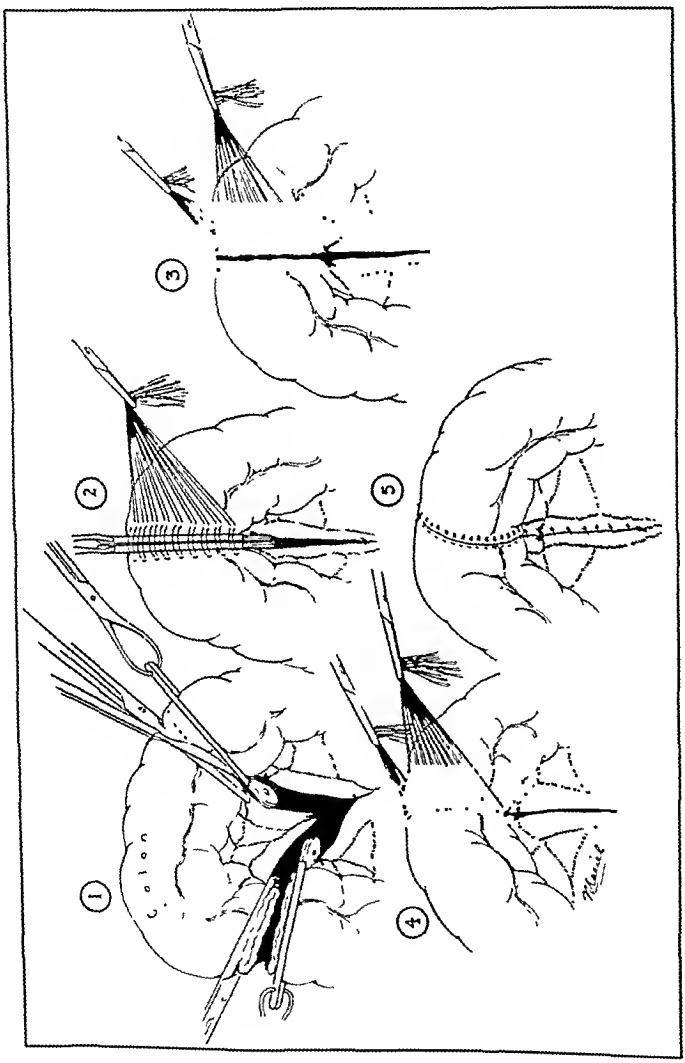

Fig. 3.—Steps in end-to-end aseptic intestinal anastomosis. (1) Division of bowel with cautery between Kocher and Stone clamps. (2) Clamps rotated and posterior layer of Halsted mattress sutures of silk placed. (3) Posterior sutures tied; anterior mattress sutures placed and clamps removed. (4) Anterior mattress sutures tied. (5) Completed anastomosis.

Halsted[4] pointed out many years ago, each suture should catch the submucosa, but not penetrate the mucosa. After completion of the suture of the bowel, the edges of the mesentery must be approximated carefully to leave no defect and no raw surfaces. Sulfanilamide powder is placed in the peritoneal cavity. The peritoneum is usually closed with continuous chromic catgut, after which the wound is washed carefully with

saline solution. The fascia is closed with interrupted figure-of-eight sutures of doubled black silk, no stay sutures being used as a rule, although here again some operators close the fascia with No. 0 or No. 1 chromic catgut, and use stay sutures in addition.

In some cases of lesions beyond the hepatic flexure, circumstances encountered at the time of resection prevented the operator from proceeding with end-to-end anastomosis. These occurred in five out of the twenty-eight cases in this group in which resection was done. In three cases great disparity in the size of the bowel proximal and distal to the lesion necessitated side-to-side anastomosis in the manner described above for right colon resections. In two of these cases a dilated proximal segment was present despite preliminary decompression by cecostomy and irrigations for thirty and sixteen days. No preliminary enterostomy had been done in the third case which presented the same problem. In two cases Mikuliez obstructive resection was employed. In one of these the sigmoid colon proximal to the lesion was filled with inspissated stool despite antecedent cecostomy and seventeen days of attempts to cleanse the bowel by irrigation. In the other, incision and drainage of an abdominal wall abscess secondary to a perforation of the transverse colon at the site of the lesion was required at the time of admission to the hospital (see Table III).

The postoperative care is important, but usually not difficult. The operation is ordinarily not accompanied by shock or loss of blood, and transfusion is often not necessary. Intravenous injection of solution of glucose or saline is given during or immediately after operation, and repeated as indicated. If a cecostomy is present, water by mouth is started immediately and soft diet as soon as tolerated. If no enterostomy has been provided, small amounts of water only are given for the first forty-eight to seventy-two hours. In some instances, especially if there have been mild obstructive symptoms, continuous gastric suction by Wangensteen's method is provided for one to two days. Exceptionally a Miller-Abbott tube has been used. In most instances, however, the patient is receiving some soft diet by the fifth to the sixth day. Mineral oil by mouth is usually started in small doses about this time, and a spontaneous bowel movement generally occurs by the seventh to ninth day.

TABLE IV

OPERATIVE MORTALITY IN CASES WITH RESECTION EQUALS 4 OF 45 CASES OR 8.8 PER CENT

	DEATHS	RESECTIONS	MORTALITY (%)
Cecum	1	7	14.2
Ascending colon	0	3	0.0
Hepatic flexure	0	7	0.0
Transverse colon	0	7	0.0
Splenic flexure	1	3	33.3
Sigmoid	2	18	11.1
Total	4	45	8.8

In the forty-five cases of resection there were four deaths, a mortality rate of 8.8 per cent divided as shown in Table IV. Two deaths were due to pneumonia and two to peritonitis.

The average hospital period for the thirty-nine patients treated by resection and immediate anastomosis and who survived was 30.8 days from resection to time of discharge from hospital. If we eliminate six patients who had prolonged hospitalization because of wound infection or other complication, the average hospital stay from the time of resection to discharge was 24.4 days. In patients in whom a cecostomy was performed, the average interval between the production of the cecostomy and resection was 15.4 days.

The follow-up information on these patients, especially those from the General Hospital, is so meager that no statement can be made regarding late results, but since the study is for the last five years only, this would not be valuable at this time. Several of the patients are known to have died with recurrence or from metastases, but the number that has survived is not known.

SUMMARY

The technique of resection and anastomosis for cancer of the colon used at the Cincinnati General Hospital has been described. The method preferred is resection and immediate anastomosis. With careful preoperative preparation and postoperative care this has led to four deaths in forty-five patients on whom resections were done, a mortality rate of 8.8 per cent.

REFERENCES

1. Rankin, F. W., and Graham, A. S.: Aseptic End-to-Side Ileocolostomy; Clamp Method, Ann. Surg. 99: 676-681, 1934.
2. Hoag, C. L.: New Approach to Resection of Cancer of Colonic Flexures, California and West. Med. 45: 148-153, 1936.
3. Scarff, J. E.: Aseptic End-to-End Suture of Intestine, Ann. Surg. 83: 490-495, 1926.
4. Halsted, W. S.: Circular Suture of the Intestine, W. S. Halsted Collected Papers, vol. 1, p. 185. Reprinted from Am. J. Med. Sc. 94: 436-461, 1887.

CARCINOMA OF THE COLON AND RECTUM

A Report of 503 Patients Treated at the Lahey Clinic 1938-1941, Inclusive

Richard B. Cattell, M.D., Boston, Mass.
(From the Department of Surgery, The Lahey Clinic, Boston)

THE fundamental principles underlying the surgical treatment of carcinoma of the colon and rectum remain the same, but the application of methods and of different operations have been constantly changing. The most conspicuous changes in the last few years seem to be, first, an increasing operability or resectability, and secondly, the wider application of one-stage operations.

Since 1929, an attempt has been made at the Lahey Clinic to standardize suitable operative procedures for lesions in different portions of the large intestine, and to utilize certain operations in a considerable group of cases in order to evaluate them. For example, over 250 two-stage abdominoperineal resections of the Lahey type were carried out and the operation evaluated. Likewise, a modified Mikulicz operation was applied to all colon malignancies, with rare exceptions, to give it a thorough trial. A consecutive series of these cases can properly serve as a basis for comparison with the one-stage operation applied to similar cases.

We have recently reviewed a series of 503 patients with carcinoma of the colon and of the rectum who were observed during the four-year period of 1938 to 1941, inclusive. The presentation of this experience gives a fairly accurate idea of the present-day treatment of these cases at the Lahey Clinic. Finally, separate consideration of the cases for 1941 demonstrates that the most satisfactory results in our experience are now being obtained.

INCIDENCE

The histories of 331 patients treated during 1938, 1939, and 1940 were reviewed in order to obtain detailed clinical data.

Table I shows the sex incidence, as follows: 191 males (60 per cent), and 140 females (40 per cent). In a previous series of our cases, we found carcinoma of the colon slightly more frequently in females and carcinoma of the rectum more commonly in males.

AGE

The youngest patient in this series was 21 years of age and the oldest was 89. The youngest patient whom we have operated upon for carcinoma of the rectum was 13 years of age. Table II, which lists the

Read before the New England Cancer Society, Boston, May 7, 1943.
Received for publication, July 6, 1943.

TABLE I

SEX INCIDENCE, 331 PATIENTS

SEX	NUMBER	PERCENTAGE
Male	191	60
Female	140	40
Total	331	100

TABLE II

AGE, 331 PATIENTS

AGE (YEARS)	NUMBER	PERCENTAGE
Below 20	0	
21-30	6	10
31-40	25	
41-50	51	
51-60	113	70
61-70	105	
71-80	30	10
89	1	
Total	331	

ages of the 331 patients in this series, shows that 10 per cent of the patients were between 21 and 40 years of age, and that a similar percentage were betweeen 71 and 80 years of age. Carcinoma of the rectum is not uncommon in young adults. In one of our series of patients, 16 per cent were found to be 39 years of age or younger.

LOCATION

There were 335 malignant lesions in these 331 patients. Thus, 4 of the group had 2 carcinomas in widely separated segments, both of which were removed at the same operation. This does not include multiple malignancies encountered in a single rectal or colonic segment where malignant degeneration was present in more than one polyp.

Arbitrary divisions are usually made of the large intestine and are by no means comparable in different reports. Two hundred and eight of the lesions (62.1 per cent) were in the rectum and rectosigmoid, while 127 (37.9 per cent) were in the colon including the sigmoidal flexure (Table III).

TABLE III

335 LESIONS, 331 PATIENTS

LOCATION OF LESION	NUMBER	PERCENTAGE
Carcinoma of rectum including rectosigmoid	208	62.1
Carcinoma of colon including sigmoid	127	37.9
Total	335	100.0

Table IV gives more detailed information concerning the distribution of the lesions throughout the colon. A consideration of the frequency of malignancy in different portions of the colon is important from the standpoint of diagnostic methods. Nearly two-thirds of all lesions encountered can be directly visualized by the sigmoidoscope or can be felt

TABLE IV

335 LESIONS, 331 PATIENTS

LOCATION OF LESION	NUMBER	PERCENTAGE
Anus	1	
Rectum	135	62.1
Rectosigmoid	72	
Sigmoid	45	
Descending colon	12	20.0
Splenic flexure	10	
Transverse colon	17	5.1
Hepatic flexure	10	
Ascending colon	12	12.8
Cecum (appendix 2)	21	
Total	335	100.0

by digital examination. The remainder can be indirectly visualized by means of a barium enema.

DURATION OF SYMPTOMS

A malignant lesion in the large intestine may be present for some time before symptoms result. Certainly a polyp or polypoid lesion may be present for many months or years without symptoms or with intermittent symptoms. The duration of symptoms in this group of patients is shown in Table V. Many of the patients having symptoms over 2 years may have had symptoms previous to malignant degeneration of the polyp. It is encouraging to find that 60.7 per cent of the patients had symptoms of less than 1 year's duration, and approximately 40 per cent of less than 6 months' duration. This is a considerable improvement, since in previous series of our cases the average duration of rectal lesions was 9 months and of colonic lesions 11 months.

TABLE V

DURATION OF SYMPTOMS, 331 PATIENTS

DURATION	NUMBER	PERCENTAGE	
Under 1 mo.	17		
1-3 mo.	49	38.4	
3-6 mo.	61		60.7
6-12 mo.	74		
1-2 yr.	60		36.3
Over 2 yr.	60		
Not certain	10		3.0
Total	331		100.0

EXTENT OF LESION

During the years 1938 to 1940, inclusive, 280 resections of the large intestine were performed in the 331 patients observed (Table VI). The extent of the lesion was determined by observation at the time of operation and by the pathologist's report of the gross and microscopic appearance. In 103 patients (36.8 per cent) the carcinoma showed no evidence of spread, remaining in situ at its point of origin. Thus, ap-

TABLE VI

280 RESECTIONS, 331 PATIENTS

EXTENT OF LESION	NUMBER	PERCENTAGE
Primary site in bowel only	103	36.8
Involvement of lymph glands	112	40.0*
Blood vessel invasion	89	31.8*
Invasion of other organs	62	22.2*
Liver metastasis present upon resection	27	9.6

*Many duplications.

proximately one-third of the patients fell into a most favorable group for possible cure. Invasion of other structures, such as the small intestine, parietes, and pelvic organs, was observed in 62 (22.2 per cent). Liver metastasis was present at the time of resection in 27 (9.6 per cent). Blood vessel invasion observed upon examination of microscopic slides was found in 89 (31.8 per cent). Involvement of regional lymph nodes determined by microscopic examination occurred in 112 (40 per cent). Obviously, more than one type of involvement sometimes was present, as blood vessel invasion usually was observed in those patients with liver metastasis and in a few of those with regional lymph node involvement.

OPERABILITY

As mentioned earlier in this communication, one of the striking changes in the management of carcinoma of the colon and rectum has been an increasing operability or resectability. For comparison of different series of cases, it is important to know the proportion of patients with these lesions who are submitted to resection. If only favorable cases are accepted for radical surgery, the result will be much more satisfactory than otherwise. The benefits of radical surgery for favorable lesions are generally acknowledged. The results of resection for unfavorable and extensive lesions are less well known; however, from our experience at the clinic, we believe that many patients, although they do not have a chance for cure, receive sufficient benefit to justify the procedure. The operability in any series of cases depends upon the extent of the lesion and the presence of local or distant spread. The condition of the patient may be such that resection is not justified and quite properly the experience of the surgeon in a large measure will determine his operability. If the surgeon's experience with favorable cases is satisfactory, then he is justified in accepting less favorable cases with a reasonable prospect of performing the resection with at least temporary success.

During the 4-year period, 1938 to 1941 inclusive, 503 patients with carcinoma of the colon and rectum were observed (Table VII). No patients were excluded from this series because of poor condition or obvious generalized metastasis on examination. Four hundred and twenty had some type of resection, making an operability or resectability rate

TABLE IV

335 LESIONS, 331 PATIENTS

LOCATION OF LESION	NUMBER	PERCENTAGE
Anus	1	
Rectum	135	62.1
Rectosigmoid	72	
Sigmoid	45	
Descending colon	12	20.0
Splenic flexure	10	
Transverse colon	17	5.1
Hepatic flexure	10	
Ascending colon	12	12.8
Cecum (appendix 2)	21	
Total	335	100.0

by digital examination. The remainder can be indirectly visualized by means of a barium enema.

DURATION OF SYMPTOMS

A malignant lesion in the large intestine may be present for some time before symptoms result. Certainly a polyp or polypoid lesion may be present for many months or years without symptoms or with intermittent symptoms. The duration of symptoms in this group of patients is shown in Table V. Many of the patients having symptoms over 2 years may have had symptoms previous to malignant degeneration of the polyp. It is encouraging to find that 60.7 per cent of the patients had symptoms of less than 1 year's duration, and approximately 40 per cent of less than 6 months' duration. This is a considerable improvement, since in previous series of our cases the average duration of rectal lesions was 9 months and of colonic lesions 11 months.

TABLE V

DURATION OF SYMPTOMS, 331 PATIENTS

DURATION	NUMBER		PERCENTAGE
Under 1 mo.	17		
1-3 mo.	49	38.4	
3-6 mo.	61		60.7
6-12 mo.	74		
1-2 yr.	60		36.3
Over 2 yr.	60		
Not certain	10		3.0
Total	331		100.0

EXTENT OF LESION

During the years 1938 to 1940, inclusive, 280 resections of the large intestine were performed in the 331 patients observed (Table VI). The extent of the lesion was determined by observation at the time of operation and by the pathologist's report of the gross and microscopic appearance. In 103 patients (36.8 per cent) the carcinoma showed no evidence of spread, remaining in situ at its point of origin. Thus, ap-

TABLE VIII

TYPE OF OPERATION, 420 RESECTIONS

	NUMBER	PERCENTAGE	
Rectal:			
One-stage operation:			
Abdominoperineal resection (Miles)	168	58.5	
Anterior or abdominal resection	17	5.9	
	185	64.4	
Two-stage operation:			
Abdominoperineal resection (Lahey)	87	30.3	
Colostomy and perineal resection	15	5.3	
	102	35.6	
Total			287 (100%)
Colonic:			
Mikulicz resection	133		
Total			420

PREPARATION FOR OPERATION

A short period of preoperative preparation was the rule. If no obstruction was present on admission, a single dose of 1.5 to 2 ounces of 50 per cent solution of magnesium sulfate was given, followed by colonic irrigation morning and evening until operation. No irrigation was given the morning of operation, and the saline purge was not repeated except in exceptional cases. Less than 5 per cent of patients had a preliminary cecostomy. Only a few patients in this series were prepared by the use of sulfaguanidine, and the administration of the sulfonamide drug was not continued. Patients were kept on a high caloric, low residue diet during the preoperative period, and received blood transfusions as indicated. Routinely, a one-stage abdominoperineal resection for carcinoma of the rectum was performed three days after admission to the hospital if no obstruction was present. A modified Mikulicz operation was carried out after a similar interval.

ANESTHESIA

All patients in this series, irrespective of age or general condition, were operated upon under spinal anesthesia. The routine spinal anesthetic agent was pontocaine weighted with 10 per cent glucose solution, utilizing 14 to 20 mg. of the drug. In a few patients, nupercaine in 1:1,500 dilution was used. Some of the patients with lesions complicated by extension were operated upon under fractional or continuous spinal anesthesia. Spinal anesthesia was supplemented at times by avertin, pentothal sodium, or cyclopropane anesthesia. We feel sure that spinal anesthesia administered by an experienced anesthetist offers the best possible operating conditions and is particularly valuable in the more complicated cases.

TABLE VII

OPERABILITY, 503 PATIENTS

YEAR	RESECTION	NO RESECTION*	TOTAL
1938	88	22	110
1939	117	16	133
1940	75	13	88
1941	140	32	172
1938-1941	420 (83.5%)	83 (16.5%)	503 (100%)

*Includes palliative operations and unoperated cases.

of 83.5 per cent. Eighty-three patients did not have resection, but had either some form of palliative operation, such as colostomy or intestinal anastomosis around the lesion, or had no operation.

SELECTION OF OPERATION

Four different operations of the resection type were performed for carcinoma of the rectum and rectosigmoid. A one-stage abdominoperineal resection (Miles) was considered the operation of choice for all these lesions, and was performed in good-risk patients of any age. During the 4-year period, 58.5 per cent of patients were operated upon by this method, whereas in the final year of this period (1941) the percentage was 76.7.

A one-stage anterior or abdominal resection was performed in 5.9 per cent. This operation is similar to the Miles resection except that a small rectal stump is left in place. In my opinion, this operation is rarely indicated, since these patients can be submitted to the one-stage abdominoperineal resection. In the few cases in which it was utilized, the lesion was in the high rectosigmoid.

The two-stage abdominal resection (Lahey) was employed in 30.4 per cent, being used for poor-risk patients, some with moderate obstruction, and for all patients who had perforated lesions with abscess. This procedure was also used for doubtfully operable patients, particularly those with marked adherence, in whom it was impossible to tell whether the cause was inflammation or extension of malignancy.

A two-stage resection consisting of a loop colostomy and subsequent perineal excision was employed in 5.2 per cent. This was used for low rectal lesions in poor-risk patients, particularly those who were unusually obese or who had complicating conditions of cardiorenal or pulmonary origin.

A two-stage modified Mikulicz resection was performed in all carcinomas of the colon during this 4-year period.

The number and percentage of these five different operative procedures are shown in Table VIII. There were 287 rectal resections, 64.4 per cent of which were done in one stage, and 35.6 per cent in two stages.

OPERATIVE MORTALITY

The operative mortality following the different types of operation is shown in Table IX. Without selection of cases, 420 resections were carried out, with 45 operative deaths, a total percentage mortality of 10.7. One hundred and sixty-eight patients had a one-stage abdominoperineal resection, with 11 deaths (6.5 per cent). The mortality was double this figure following the two-stage abdominoperineal resection of the Lahey type, this group of patients having more extensive and complicated lesions and consequently a higher operative risk. In 87 patients, 12 deaths occurred. A high mortality also followed perineal resection in a small, poor-risk group of patients, 3 deaths occurring in 15 operations (20 per cent). There were 133 Mikulicz resections with 15 deaths, a mortality of 11.3 per cent. Nineteen deaths followed palliative procedures. Not all the 83 patients listed were operated upon, so the mortality after palliative procedures was more than double that for the group having resection.

There was no selection of cases in determining operative mortality after the 420 resections. Approximately 10 per cent of these patients had liver metastasis at the time of resection. Likewise, 22 per cent including those having liver metastasis had definite invasion of other structures. If one separates the curable cases from the incurable, the operative mortality is materially improved; however, the only fair way to present one's experience with rescection is to include all cases in which resection was performed.

The causes of the 45 deaths in 420 patients having resection are shown in Table X. Twenty were due to infection, 8 having peritonitis as a cause of death. Sulfanilamide was used in 5 to 10 Gm. amounts in the peritoneal cavity when gross soiling occurred. When no gross soiling occurred in the peritoneal cavity but did occur in the dissection of the rectum posteriorly, sulfanilamide was put in the presacral space. Except for a small series of cases, no sulfonamide drugs were used in preoperative preparation, and none in the peritoneal cavity in clean cases. The other causes of death, such as pulmonary embolism, cardiac failure, and obstruction, are what one would expect in any large group of serious abdominal procedures.

END RESULTS

I have attempted to evaluate the results following resection for carcinoma of the colon and rectum. Obviously, the series of 503 cases during the years 1938 to 1941, inclusive, cannot be used. Consequently, a previous series of 162 consecutive resections performed during the years 1932 to 1936, inclusive, was reviewed (Table XI). Seventy-five of the entire group of patients submitted to resection survived between 5 and 9 years, a survival rate of 46.3 per cent. Twenty-two patients died postoperatively, and 65 died subsequently of recurrence

TABLE IX

OPERATIVE MORTALITY, 503 PATIENTS

TYPE OF OPERATION	CASES	DEATHS	PERCENTAGE
Miles resection	168	11	6.5
Lahey resection	87	12	13.8
Perineal resection	15	3	20.0
Anterior resection	17	4	23.5
Mikulicz resection	133	15	11.3
Total resections	420	45	10.7
Palliative operations	83	19	22.9
Total all operations	503	64	12.7

TABLE X

45 DEATHS, 420 RESECTIONS

CAUSES OF DEATH	NUMBER	
Peritonitis	8	Infection
Gas bacillus	2	Infection
Wound separation	4	Infection
Pneumonia	6	Infection
Pulmonary embolus	5	
Myocardial failure	3	
Intestinal obstruction	4	
Mesenteric thrombosis	3	
Uremia	4	
Cerebral thrombosis	2	
Surgical shock	1	
Agranulocytosis	1	
Not determined	2	
Total	45	

TABLE XI

END RESULTS, 162 RESECTIONS*

(1932-1936, Inclusive)

NO. PATIENTS	PERCENTAGE	
75 survived 5 years plus	46.3	
22 died post-operatively	13.5	53.7
65 died of recurrence	40.2	53.7
140 survived operation, 5-year cure	53.6	

*All patients were followed for 5 to 10 years.

TABLE XII

PRESENT-DAY MANAGEMENT, 172 PATIENTS (1941)

TYPE OF RESECTION	CASES	PERCENTAGE	DEATHS	PERCENTAGE
Miles	79	76.7	3	3.8
Anterior	5	4.8	1	20.0
Lahey	15	14.5	1	6.7
Perineal	4	3.9	1	25.0
Mikulicz	37		1	2.7
Total resections	140	81.4	7	5.0
Palliative operations	32	18.6	3	9.4

THE MANAGEMENT OF POLYPS OCCURRING IN THE RECTUM AND COLON

VERNON C. DAVID, M.D., CHICAGO, ILL.

IT HAS fallen to my lot to examine and care for more than one hundred patients having polyps of the colon and rectum and this article will indicate some reactions to the problems involved.

Areas of hyperplasia, pedunculated adenomas, and sessile papillomas are common tumors in the colon. Feyrter found 1,100 such lesions in 1,800 consecutive autopsies. Fifty per cent of carcinomas of the colon and rectum studied were found to have flat, raised areas of hyperplasia in close proximity to them. Twenty-five per cent of carcinomas of the colon and rectum have been found to have adenomas accompanying them. The earliest carcinomas of the large bowel I have seen are those occurring on the periphery of pedunculated adenomas where, as a rule, the most bizarre arrangement of epithelium is seen. Multiple polyposis of the colon where hundreds of adenomas, small papillomas, and areas of hyperplasia are seen is frequently the seat of multiple carcinoma. Prolonged ulcerative colitis where inflammatory mucous polyps are often seen is complicated by carcinoma in about 5 per cent of the cases.

For these reasons it is obvious that all hyperplastic areas, adenomas, or papillomas should be removed or completely destroyed whenever possible because they constitute a definite precancerous lesion. The transition from hyperplasia to adenoma or papilloma formation to carcinoma is difficult to define or to recognize.

From a clinical viewpoint, hyperplasia of the bowel mucosa gives no symptoms and is found in the course of proctoscopic examinations, in examination of surgically removed segments of bowel, or at autopsy. Adenomas, which vary from the size of a BB shot to a walnut, make their presence known by bleeding, protrusion from the rectum if they are low in the bowel, and cramplike pains due to attempts of the bowel to push them along, and occasionally by becoming an apex of an intussusception.

The bleeding may be slight and may be bright or dark depending on the location of the adenoma, the blood obviously being brighter the lower the growth is in the bowel. The bleeding may occur without a bowel movement, and in some instances has been as much as a pint of blood.

The symptoms of villous tumors or papillomas, which may be small or as large as an apple, are much the same as adenomas except that they are usually associated with the passage of a large amount of mucus due

Received for publication, Feb. 10, 1943.

of the carcinoma. Thus, 53.7 per cent had an unsatisfactory result. Presumably a certain proportion of those who did not survive operation had favorable lesions. Of the 140 patients who survived the operation, 53.6 per cent showed no evidence of recurrence for the 5- to 10-year period during which they were observed.

PRESENT-DAY MANAGEMENT

A review of our experience during 1941 gives a clear picture of our present practice in the treatment of carcinoma of the colon and rectum. During the year 1941, 172 patients were seen in consultation (Table XII). One hundred and forty (81.4 per cent) were submitted to resection, with 7 operative deaths, a mortality of 5 per cent. This again was an unselected group of cases, including all patients in whom the diagnosis of carcinoma was made, irrespective of the condition of the patient or extent of the lesion. Seventy-nine one-stage abdominoperineal resections were performed, with 3 deaths, a mortality of 3.8 per cent. Thirty-seven consecutive Mikulicz resections were performed, with 1 death, a mortality of 2.7 per cent. In summary of the year 1941, an operability rate of 81.4 per cent was maintained. A one-stage abdominoperineal resection was performed in 76.7 per cent of the rectal carcinomas, with a mortality of 3.8 per cent, and the modified Mikulicz resection, which at the Lahey Clinic is considered the operation of choice for carcinoma of the colon, was performed with a mortality of 2.7 per cent.

Pedunculated adenomas which prolapse or can be prolapsed through the anus are removed by ligation of the pedicle well away from the adenoma.

Pedunculated adenomas which can be seen through the proctoscope can be removed safely by thorough fulguration of the pedicle through a proctoscope using a long fulguration wire enclosed in a ureteral catheter. Areas of hyperplasia can be similarly removed by fulguration.

Flat adenomas of the rectum below the peritoneal reflection can be fulgurated and carbonized with safety.

Careful inspection of adenomas should be the rule to be certain there is no evidence of ulceration of the tumor and no induration which can be determined by palpation or by manipulation of the polyp by the end of the proctoscope. Either ulceration or induration makes one suspicious of malignancy and several small areas should be removed for biopsy. I am personally a firm believer in the most radical operation for all carcinomas no matter what the size because of the impossibility of estimating with accuracy the tendency to metastases in any individual tumor.

In large pedunculated or flat adenomas above the peritoneal reflection there is an indication to prepare the patient carefully by complete emptying of the large bowel and examination of the tumor through a laparotomy incision. If no signs of malignancy such as induration or dimpling of the bowel at the site of the tumor attachment is present, the tumor can be removed as polyps are removed in any part of the colon. If the polyp is movable and therefore pedunculated, the tumor is grasped between the thumb and index finger in an area where the polyp has the greatest mobility within the bowel, small stomach clamps are applied on the bowel above and below the polyp, and after the field is surrounded with moist pads, the polyp is held firmly as indicated and a small incision made through the longitudinal muscle band opposite the mesenteric attachment, and the polyp is extruded (Fig. 1). The pedicle is ligated well away from the polyp and the bowel wall is closed with three layers of fine silk, the outer layer attaching an appendix epiploica over the suture line (Fig. 2). Gloves and instruments are changed for abdominal closure.

If the polyp is a sizable sessile attached adenoma or papilloma, a bowel resection is the operation of choice. Because of its safety I favor the Rankin obstruction type of resection, leaving the Payr clamps on for twenty-four hours, applying a spur crusher when they are removed, and closing the colostomy under local anesthesia in two to three months. Mortality with this type of operation has been nil in over twenty patients.

Another problem in removal of these tumors is presented when large sessile papillomas not suitable for fulguration occur in the ampulla of the rectum. They are difficult to approach from above or below un-

to the presence of many goblet cells in waving branches of the tumor. As much as a pint of mucus may be passed in a day. They may also reach a size that produces obstruction of the bowel.

Multiple polyposis of the colon is frequently associated with severe loss of blood inducing profound anemia, diarrhea, and malnutrition. Carcinoma, frequently multiple, developing in the colon at the site of various polyps, can alter the symptoms by producing obstruction and metastases.

Inflammatory polyps, which accompany long-standing amoebic dysentery or ulcerative colitis, may be the result of massive hyperplasia of islands of mucosa between areas of ulceration, or they may be very difficult to distinguish from true adenomatous tumor formation. The transition of these benign polyps to carcinoma is by no means a rarity.

Many of these various polypoid changes in the membrane of the large bowel are found by proctoscopic examinations in a search for the cause of bleeding or change of bowel habits. In children, the protrusion of a pedunculated adenoma on defecation is not uncommon. Where the search for the cause of bleeding from the large bowel results in normal proctoscopic findings and a negative fluoroscopy of the colon, an adenoma or papilloma must be suspected. Many such lesions can be demonstrated by the double contrast enema, using barium and air injection, and making stereoscopic films. It is necessary to repeat this examination to be sure that the defect found in the first examination is present in subsequent examinations. The site of the defect of an adenoma may vary six to eight inches because of the long pedicle of normal mucosa that many of the adenomas develop. Continued bleeding from a colostomy following resection of the large bowel for carcinoma should excite suspicion of the presence of an adenoma in the remaining bowel, frequently. Double contrast enemas will demonstrate them.

There are many patients with persistent bleeding of red blood where polypoid tumors of the large bowel are suspected but cannot be found despite repeated careful examinations. As a general rule, exploratory operations in such patients are not justified as it is extremely difficult to find adenomas of the bowel by palpation unless they are fairly large or a definite part of the bowel is under suspicion. Dixon has used transillumination at the time of operation to demonstrate such intraintestinal lesions. Other lesions presenting much the same type of bleeding are Meckel's diverticulum containing gastric mucosa, adenomas of the small bowel, malignancies of the small bowel, or localized granulomatous ulceration of the colon.

In the treatment of these polypoid lesions of the large bowel, thorough removal by the safest and simplest method is the underlying principle.

suscepting the bowel mucosa. The normal, healthy mucosa surrounding the tumor is picked up by Allis forceps, to prevent retraction of the mucosa, and the tumor is completely removed by the cutting cautery going through the submucosa. Bleeding points are ligated and a running stitch of catgut approximates the mucosa on both sides of the defect. In a few instances a complete circumferential cuff of mucosa was removed with end-to-end suture without seriously narrowing the lumen of the bowel which is normally wide in this region

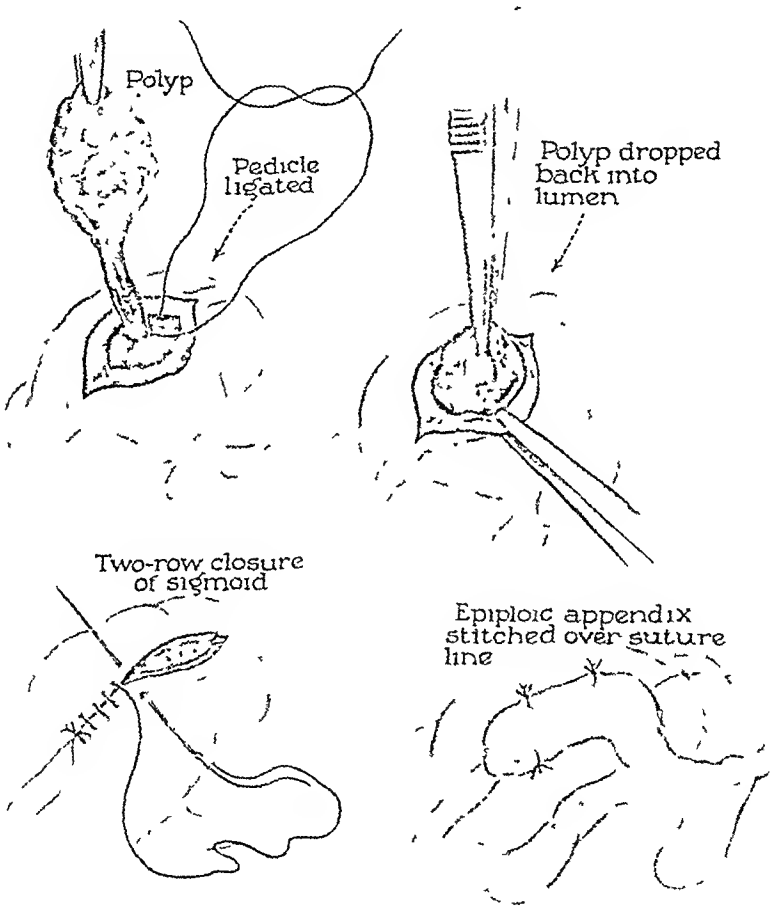

Fig 2—Ligation of the pedicle of the polyp closure of the bowel wall in layers with fine catgut

The completely incised bowel wall is then closed with fine catgut, taking care not to place sutures through the mucosa which would serve as avenues of infection from the lumen of the bowel (Fig 4). The stitches are placed in the submucosa, which tends to invert the mucosa

less one decides to remove the rectum, which in my opinion is not necessary in the tumors which are benign There again induration or ulceration as well as biopsy makes the decision as to their benignancy. In fifteen cases the operation depicted in the illustration by Shepard was carried out. The rectum is split open up to the coccyx (Fig. 3). The tumor is grasped by Allis forceps and gently pulled downward, intus-

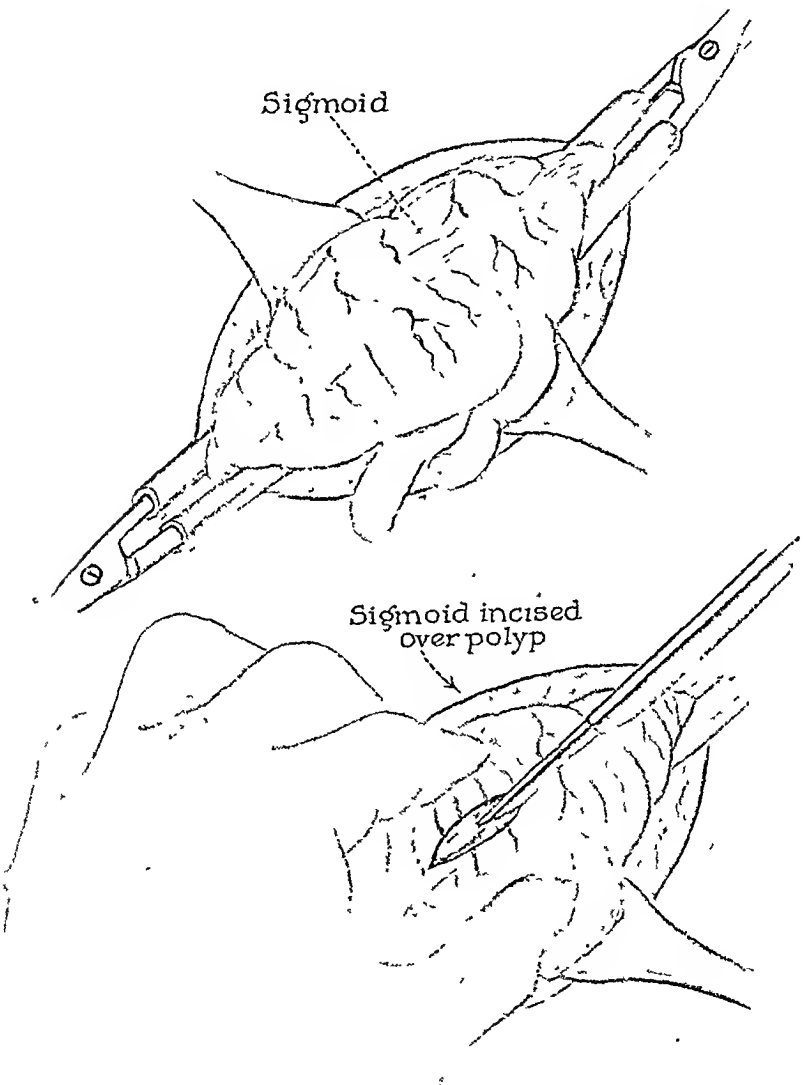

Fig. 1—Sigmoid containing the polyp held with the bowel in the grasp of stomach clamps; bowel is opened over the polyp

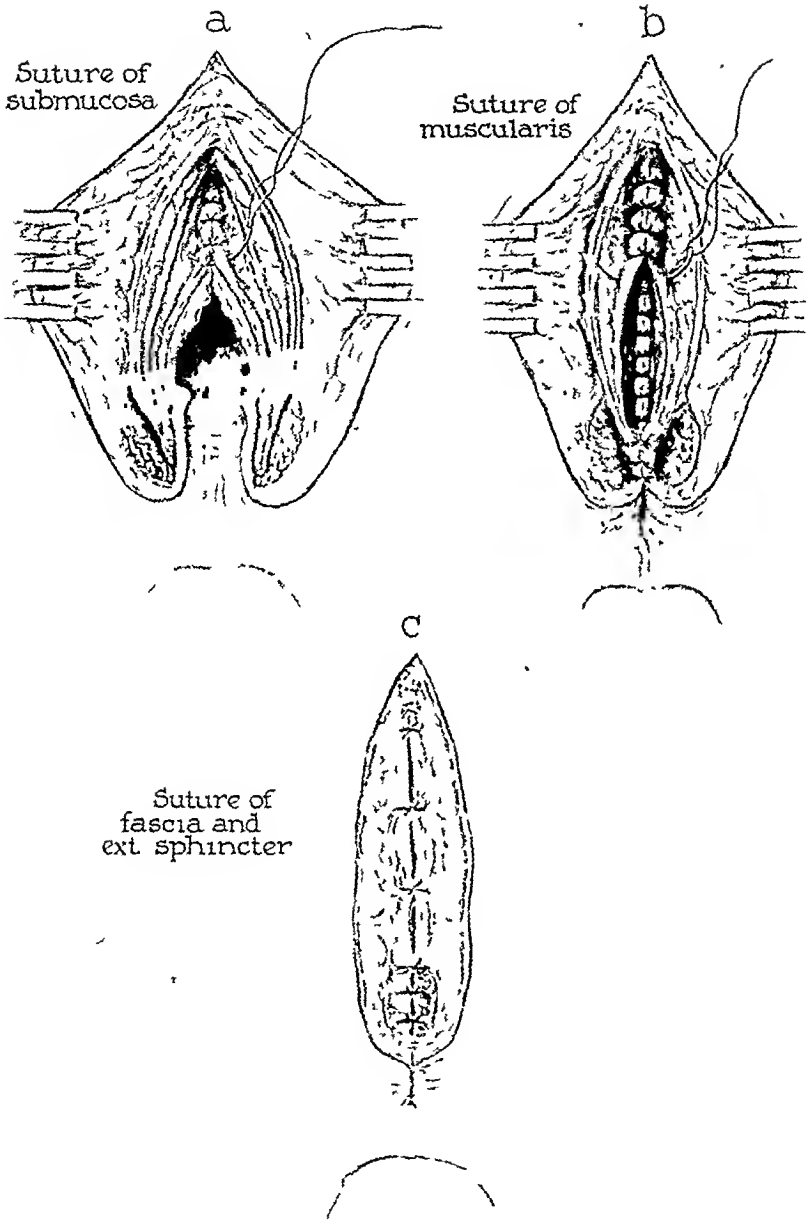

FIG 4.—(a) Suture of the bowel by interrupted catgut stitch going through the submucosa (b) suture of the muscularis of the bowel (c) suture of the sphincter and interrupted sutures through the extension of the sphincter muscle to the coccyx

into the lumen of the bowel. The muscularis is then sutured with interrupted catgut and a third row of stitches is placed through the areolar tissue over the bowel, which includes the extensions of the external sphincter muscle to the coccyx. The external sphincter muscle is united

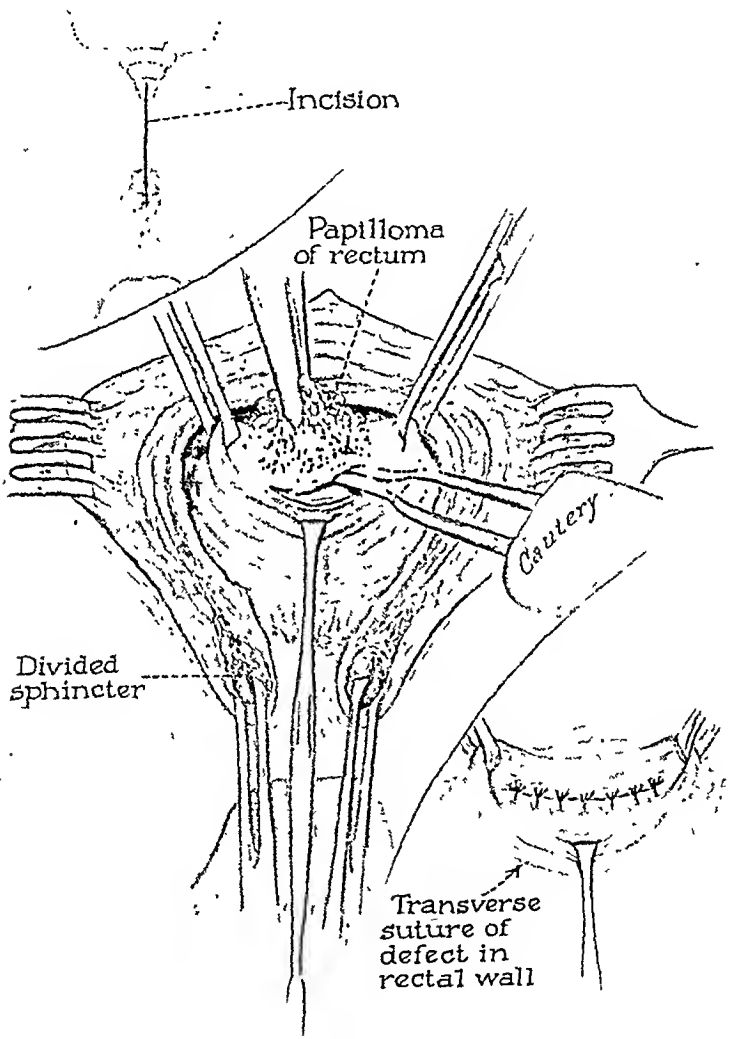

Fig. 3.—Operation for removal of sizable benign lesions in the ampulla of the rectum showing the incision, removal of the growth, and suture of the mucosa.

separately by two interrupted mattress stitches of catgut. The remaining wound is sprinkled with sulfanilamide crystals, and a vaselined piece of gauze is applied to cover the wound. The bowels are moved on

A NEW PRACTICAL SIGMOIDOSCOPE

CECIL P. G. WAKELEY,* C.B., D.Sc., F.R.C.S., F.A.C.S., HANTS, ENG.

FOR more than a year I have been using a coldlite sigmoidoscope which has some very definite practical advantages over all other forms of instruments. Coldlite solves the problem of introducing cold-light inside the body without danger, glare, or electric shock and is especially useful in illuminating cavities.

Hitherto made in solid form only as retractors, specula, or tongue depressors, tubular instruments such as sigmoidoscopes and proctoscopes have now been produced.†

The main features of the sigmoidoscopes (Fig. 1) are that the source of light is placed outside the tube, allowing an unobstructed view, freedom of operation, and safe use of diathermy instruments as the material is a perfect nonconductor of heat and electricity. The cold light travels along the wall of the instrument and escapes at the distal end showing the object under examination in a plastic form and natural coloring.

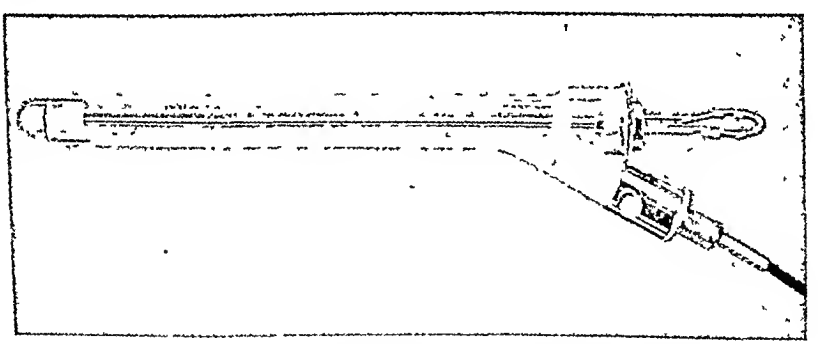

Fig. 1.—Coldlite examination and operating sigmoidoscope with airtight window for inflation and light attachment. (Brit. Pat. Appl. No. 5257/42.)

I have had made a stainless steel inspection mirror with a graduated stem (Fig. 2) for use inside the sigmoidoscope. Ulcers, polypi, fissures, and carcinomas can be detected at an early stage with the aid of the mirror, as they can be easily seen through the walls of the sigmoidoscope, greatly facilitating an early and accurate diagnosis.

*Senior Surgeon, King's College Hospital. Consulting Surgeon to the Royal Navy and the Ministry of Health.

†The instrument is made in two sizes, 13/16" and 15/16" external diameter by Messrs. Vann Bros., 63 Weymouth Street, London, W. 1, England.

Received for publication, March 13, 1943.

the third or fourth day by an oil and water enema. There is some leakage along the suture line about the sixth day but in all of the patients healing has taken place without a fistula, with continence of the sphincter muscles, and to date no patient has developed carcinoma at the removal site of the papilloma. One patient had a small local recurrence of the papilloma which was cured by fulguration. He has been well and without recurrence for over five years.

Multiple polyposis of the colon is a distressing lesion and because of the frequency of the development of malignancy should be treated by a graded removal of the colon. If the rectum is the site of but a few polyps, they may be fulgurated and destroyed and eventually an ileosigmoidostomy performed.

Multiple inflammatory polyps occurring in ulcerative colitis are an indication for ileostomy and colectomy due to the danger of malignancy developing in them. If one or two polyps develop following amoebic dysentery or ulcerative colitis, they may be treated as outlined for polyps of noninflammatory origin.

In summary, it should be emphasized that polyps of the colon and rectum should be radically destroyed or removed due to their tendency to malignant degeneration. Many can be handled well by fulguration and local removal but where necessary more radical surgery is indicated and should be done.

ANTERIOR RESECTION OF THE RECTOSIGMOID AND UPPER RECTUM WITH RE-ESTABLISHMENT OF CONTINUITY

LAURENCE SIDNEY FALLIS, M.D., F.R.C.S.

(From the Department of General Surgery, Henry Ford Hospital)

RESTORATION of continuity of the intestinal tract after removal of carcinoma of the rectum has long attracted the attention of surgeons. Many of the earlier perineal procedures for excising rectal carcinoma such as the operations of Hochenegg, Kocher, Allingham, and others aimed at reuniting the bowel and preserving the sphincteric apparatus.

This period in the development of the surgery of rectal cancer ended with Miles' convincing demonstration of the undeniable superiority of his radical combined abdominoperineal operation. Vastly improved end results, and freedom from complications and annoying sequelae eventually led to the almost complete abandonment of other measures for the eradication of rectal and rectosigmoid malignancies. Miles based his operation on the concept that carcinoma of the rectum spread in all directions, upward, downward, and laterally. However, the more recent studies of regional glandular metastases in carcinoma of the rectum by Coller and co-workers,[1] and Gilchrist and David[2] indicate that glandular metastasis is upward in the great majority of instances. This observation raises the point that the combined operation may be unnecessarily radical in low sigmoid and rectosigmoid carcinomas and has led to a limited revival of operations in which the low rectum levatores and muscles and the sphincteric apparatus are not sacrificed. Horsley,[3] Devine,[4] Pratt,[5] Dunphy,[6] and Dixon[7] and others have all made contributions to this effect.

The one-stage combined abdominoperineal operation of Miles still remains the operation of choice for most cancers of the rectum and rectosigmoid. Under certain circumstances which more or less may be defined, departure from this universally adopted procedure is permissible. Anterior resection of the rectum with or without restoration of continuity is an alternative method of dealing with tumors of that ill-defined region, the rectosigmoid. The great difficulty in having anything to do with operations for rectal carcinoma which do not require permanent colostomy is that the surgeon will be tempted to extend the scope of selection of cases to include those patients that should be subjected to more radical procedures. The temptation to make re-establishment of continuity the sole objective of the operation is one that must constantly be guarded against if the surgeon is to avoid that most grievous of surgical sins, namely, fitting the patient to the operation rather than the operation to the patient.

Received for publication, June 5, 1943.

A further advantage is that once the instrument is introduced the complete examination can be carried out by moving the mirror inside the tube, thus eliminating discomfort to the patient.



Fig. 2.—Stainless steel inspection mirror, graduated stem.

For all practical purposes unbreakable, sterilizable by boiling, this instrument has proved a valuable addition to the surgeon's examination equipment.

tion in carrying out what is admittedly a less radical procedure which might be curative rather than condemning the patient to a certain fate.

PREOPERATIVE PREPARATION

Under local anesthesia a transverse incision is made cutting across the right rectus muscle midway between the umbilicus and the costal margin and separating the fibers of the posterior rectus sheath in the line of the incision. A loop of underlying colon is delivered into the wound and held in position by a glass rod thrust through its mesentery. Since the operation requires only a few minutes, there is minimal disturbance, and the patient becomes ambulatory in two or three days. Transection of the bowel produces complete defunctionalization.

Daily irrigations of the distal segment with antiseptic solutions including suspensions of zinc peroxide over a two-week period reduce the bacterial count of the colon and the inflammatory elements of the tumor. At the same time the general condition of the patient is built up with a high protein diet, vitamin C administration, and blood transfusion when indicated.

ANESTHESIA

Unless contraindicated, spinal anesthesia with dilute nupercaine solution 1:1500 is the anesthetic of choice, although a combination of general and local anesthesia will be satisfactory if the transverse incision is used.

INCISION

One of the chief difficulties of the operation is the depth in the pelvis at which the anastomosis must be carried out. The use of a modified transverse incision recently described by Cherney[8] is of inestimable value. This curved incision runs across the lower abdomen in the pubic hairline from a fingerbreadth below one anterior superior spine line to the same point in the opposite side. The anterior sheath of both rectus muscles and some of the aponeurosis of the external oblique muscles are cut in the line of the incision. The lower flap of rectus sheath is then turned down to the pubic spine where the rectus and pyramidalis on both sides are detached from the pubic crest and turned upward. The peritoneum and transversalis fascia are cut in the line of the incision. The exposure is perfect and the wound is easily closed. The abdominal wall heals soundly.

OPERATIVE TECHNIQUE

With the abdomen opened, the patient in the Trendelenburg position, and the small intestines packed away, the operation proceeds along conventional lines with regard to mobilization of the portion of bowel containing tumor with the exception that ligation of the inferior mesenteric artery is delayed until mobilization is complete. The rectum is separated from the base of the bladder, prostate, and seminal vesicles anteriorly, and together with the mesorectum it is shelled out from the

INDICATIONS FOR ANTERIOR RESECTION

1. Operation of choice in tumors of the low sigmoid
2. As a matter of expediency in certain poor-risk patients
3. As a substitution for the classical abdominoperineal operation in cases of borderline operability
4. When permanent colostomy is refused

Tumors of the Low Sigmoid.—Tumors involving the sigmoid just proximal to the peritoneal reflection always present problems in management. Exteriorization, often impossible because of obesity, shortened mesentery, etc., does not permit the removal of enough mesentery to satisfy the requirements of a radical operation because the inferior mesenteric and superior hemorrhoidal vessels must be left intact in order to preserve nutrition of the distal loop. The sigmoid arteries with the adjacent mesentery can usually be removed, but since the lymphatic radicles from this area drain into the lymphatic chain running with the superior hemorrhoidal and inferior mesenteric arteries, it is imperative to remove these vessels if a radical resection is to be performed. It is true that the combined abdominoperineal operation fulfills this requirement, but in many instances it is unnecessarily radical, for the lymphatic drainage in this region is largely upward rather than downward or lateral. The operation of anterior resection of the rectum is ideal in this location since it permits removal of the portion of bowel containing the tumor together with adequate removal of mesosigmoid and mesorectum with their contained blood and lymphatic vessels.

Poor-Risk Patients.—Anterior resection of the rectum may be utilized as a matter of expediency in certain poor-risk patients who in spite of careful preparation and adequate support are standing operation poorly. When it is evident that it is not prudent to continue with a proposed abdominoperineal resection the operation can be terminated at once by sectioning and closing the rectum below the tumor and exteriorizing the upper loop and the tumor.

Palliative Operations.—Palliative resection of the rectum for lesions involving the rectosigmoid or upper rectum in the presence of local extension of the disease, enlarged lymph nodes along the aorta, or a single demonstrable liver metastasis is now recognized as a justifiable procedure. Many lives have been prolonged for months in relative comfort by adopting the attitude of removing all resectable tumors even in the presence of known metastases. Life may be made still more tenable for those unfortunates if the surgeon chooses to restore continuity of the intestinal tract by adopting the operation of anterior resection.

When Colostomy Is Refused.—It has been claimed that when a patient refuses colostomy it is because of poor presentation by the surgeon or medical adviser. Nevertheless, there is a small group of patients who will flatly refuse any operative procedure which will necessitate a permanent colostomy. With them it is a question of either no colostomy or no operation. The surgeon faced with this problem has some justifica-

tion in carrying out what is admittedly a less radical procedure which might be curative rather than condemning the patient to a certain fate.

PREOPERATIVE PREPARATION

Under local anesthesia a transverse incision is made cutting across the right rectus muscle midway between the umbilicus and the costal margin and separating the fibers of the posterior rectus sheath in the line of the incision. A loop of underlying colon is delivered into the wound and held in position by a glass rod thrust through its mesentery. Since the operation requires only a few minutes, there is minimal disturbance, and the patient becomes ambulatory in two or three days. Transection of the bowel produces complete defunctionalization.

Daily irrigations of the distal segment with antiseptic solutions including suspensions of zinc peroxide over a two-week period reduce the bacterial count of the colon and the inflammatory elements of the tumor. At the same time the general condition of the patient is built up with a high protein diet, vitamin C administration, and blood transfusion when indicated.

ANESTHESIA

Unless contraindicated, spinal anesthesia with dilute nupercaine solution 1:1500 is the anesthetic of choice, although a combination of general and local anesthesia will be satisfactory if the transverse incision is used.

INCISION

One of the chief difficulties of the operation is the depth in the pelvis at which the anastomosis must be carried out. The use of a modified transverse incision recently described by Cherney[8] is of inestimable value. This curved incision runs across the lower abdomen in the pubic hairline from a fingerbreadth below one anterior superior spine line to the same point in the opposite side. The anterior sheath of both rectus muscles and some of the aponeurosis of the external oblique muscles are cut in the line of the incision. The lower flap of rectus sheath is then turned down to the pubic spine where the rectus and pyramidalis on both sides are detached from the pubic crest and turned upward. The peritoneum and transversalis fascia are cut in the line of the incision. The exposure is perfect and the wound is easily closed. The abdominal wall heals soundly.

OPERATIVE TECHNIQUE

With the abdomen opened, the patient in the Trendelenburg position, and the small intestines packed away, the operation proceeds along conventional lines with regard to mobilization of the portion of bowel containing tumor with the exception that ligation of the inferior mesenteric artery is delayed until mobilization is complete. The rectum is separated from the base of the bladder, prostate, and seminal vesicles anteriorly, and together with the mesorectum it is shelled out from the

hollow of the sacrum. The middle hemorrhoidal vessels are sacrificed only if the rectal stump is to be very short, such as occurs in palliative resections of the rectosigmoid and upper rectum. Mobilization is complete when the rectum can be pulled well up into the wound and there is a generous margin of healthy tissue below the tumor. Attention is now directed to the blood vessel pattern of the sigmoid and descending colon, for on this depends the success of the operation. The blood supply of the sigmoid is in the form of a vascular loop which is much shorter than the loop of bowel itself. The vascular bundle at the base of the mesentery must be sectioned for two reasons. First, in order to permit removal of tissues possibly invaded by extension of the growth, and second, to allow unfolding and elongation of the sigmoid loop. The point of section of the inferior mesenteric artery is extremely important, for after dividing this vessel the vitality of the sigmoid depends on the vessels supplying the marginal artery. If the upper and lower sigmoid arteries arise separately the ideal site for section is between them, for then the blood will enter the upper sigmoid artery, pass into the marginal artery, and thence back into the lower sigmoid artery, and so on to the distal extremity of the loop. A problem presents itself when the sigmoid arteries arise from a common trunk, for if the inferior mesenteric artery is divided below the sigmoid trunk, it is often impossible to elongate the sigmoid loop, and if the artery is sectioned above the sigmoid trunk the left colic artery may be too slender to maintain an adequate blood supply through the marginal artery. However, the quandary is not too great because in any event one has to depend to a certain extent on what happens to the color of the bowel after ligation. If after division of the inferior mesenteric vessels there is any question about the viability of the bowel as evidenced by its dusky color, attempts at restoration of continuity must be abandoned. The choice then remains of continuing with anterior resection by closing the rectal stump and forming an abdominal artificial anus or by proceeding with the classical abdominoperineal resection.

The surgeon, having satisfied himself that the circulation in the sigmoid is unimpaired by section of the inferior mesenteric artery as evidenced by maintenance of its healthy pink color, cuts the mesorectum at as low a level as is consistent with the introduction of the anastomotic sutures and frees the anterior wall of the rectum from adherent fat tags. Low suturing of the rectum makes possible subsequent digital examination of the anastomotic site and reduces the amount of tissue dependent on the inferior hemorrhoidal vessels. The rectum is then double clamped and cut across with the actual cautery. The McClure modification of the Furniss clamp[9] is ideal for the rectal stump since the bowel can be controlled by the needle introduced through the clamp after the latter is removed. The sigmoid is likewise dealt with, being certain to leave enough bowel to allow for anastomosis without tension. The tumor, adjacent bowel, inferior mesenteric vessels, and portions of

both the mesosigmoid and mesorectum are thus removed to satisfy the requirements of a radical operation. If a Furniss clamp has been used to close the sigmoid colon it is now removed, the bowel controlled by the needle or pin, and a closed anastomosis is carried out. After the first row of interrupted silk sutures are put in, the needles are removed, the septum is broken down, and a second row of silk Lembert sutures is inserted. A rectal tube is now inserted through the anus up past the anastomosis to splint the bowel and carry off intestinal secretions. An open anastomosis is just as readily carried out and perhaps permits more accurate suturing. Five grams of sulfanilamide powder are dusted into the pelvis and the pelvic floor is re-formed about a Penrose drain. As the abdominal incision is being closed, an additional 5 Gm. of sulfanilamide are put in the various layers and a small rubber tube is used to drain the space of Retzius. The operation requires about the same time as the combined abdominoperineal resection. There is a good deal less shock.

AFTERCARE

The functioning colostomy allows early resumption of alimentary feeding and so hastens convalescence and healing. The pelvic drain and rectal tube are left in place for at least five days, so that the integrity of the anastomotic site may be investigated by injecting methylene blue into the distal loop of the colostomy. Some leakage usually occurs for the rectum, having no peritoneal covering, heals slowly. Crushing of the colostomy spur should be delayed until the anastomosis has healed and final closure of the colostomy is best deferred for at least a month. Patients become ambulatory in twelve to fourteen days and usually are able to leave the hospital in two and one-half weeks. The total hospitalization period is between four and five weeks.

COMPLICATIONS

Primary healing of the anastomotic site is the exception rather than the rule, owing to the lack of peritoneal covering of the rectal stump. Failure of the marginal artery to provide adequate blood supply to the end of the sigmoid must be a factor in some instances. Contrary to what might be expected, the blood supply of the remaining portions of the rectum is satisfactory even when the rectal stalks have been sacrificed. The inferior hemorrhoidal vessels alone apparently are capable of nourishing the lower rectum.

Delayed healing of the anastomosis, whether from actual loss of bowel tissue or failure of the sutures to hold, means that the union is effected by granulation tissue. Contraction of this scar tissue invariably results in narrowing of the anastomotic site, sometimes to the point of actual stricture. Repeated dilatation may keep the opening patent in some patients while in others the difficulty is so great that inguinal colostomy is necessary.

RESULTS

The foregoing opinions are based on a small personal experience of thirty-one operations performed during a three-year period, 1940 to 1942, inclusive. The series is necessarily limited because combined abdominoperineal resection is routinely performed for carcinoma of the rectum and anterior resection is reserved for the small group in which the indications for the operation appear to be clearly defined. There were two operative deaths, one on the fifth postoperative day from liver necrosis considered due to sulfonamide and the other on the eighteenth postoperative day from paralytic ileus. The mortality rate of 6.5 per cent compares favorably with that of the combined operation. Seven of the operations (22.3 per cent) were for tumors of the low sigmoid. There were eight patients (25.8 per cent) on whom the operation was only palliative because of liver metastases or local extension of the disease. One patient with liver metastases was able to work for one year before he finally succumbed. Stricture of the anastomotic site has occurred in three patients. One has required permanent colostomy, but the other two have been kept patent by repeated dilatations. Two patients have persistent fecal fistulas. Although insufficient time (six months to three years) has elapsed to discuss survival rates, the fate of the patients to date is approximately the same as for a similar group following the combined operation. Of the twenty-one patients who survived operation and whose operation might be classed as curative, two (9.5 per cent) have died and an additional two (9.5 per cent) show evidence of recurrence.

SUMMARY

1. The rationale and technique of the anterior approach for excision of carcinoma of the rectosigmoid and upper rectum are presented.

2. The use of the operation is suggested as an alternative not as a substitute, for combined abdominoperineal resection in selected cases.

3. The advantage and complications are discussed.

REFERENCES

1. Coller, F. A., Kay, E. B., and MacIntyre, R. S.: Regional Lymphatic Metastases of Carcinoma of the Colon, Ann. Surg. 114: 56-67, 1941.
2. Gilchrist, R. K., and David, V. C.: Lymphatic Spread of Carcinoma of Rectum, Ann. Surg. 108: 621-642, 1938.
3. Horsley, J. S.: Resection of the Rectosigmoid and Upper Rectum for Cancer, With End-to-End Union, Surg., Gynec. & Obst. 64: 313-323, 1937.
4. Devine, Hugh: Excision of the Rectum, Brit. J. Surg. 25: 351-381, 1937.
5. Pratt, J. P.: One-Stage Operation for Resection of Recto-Sigmoid and Rectum for Carcinoma (With or Without Hysterectomy); Combined Anterior and Posterior Resection; Combined Abdomino-Perineal Resection, Am. J. Obst. & Gynec. 36: 209-218, 1938.
6. Dunphy, J. E.: Anterior Resection for Cancer of the Rectosigmoid, Arch. Surg. 43: 1076-1085, 1941.
7. Dixon, C. F.: Surgical Removal of Lesions Occurring in the Sigmoid and Rectosigmoid, Am. J. Surg. 46: 12-17, 1939.
8. Cherney, L. S.: A Modified Transverse Incision for Low Abdominal Operations, Surg., Gynec. & Obst. 72: 92-95, 1941.
9. McClure, R. D.: A Clamp for Closure of the Duodenal Stump in Gastric Resections, Ann. Surg. 109: 1034-35, 1939.

PRIMARY RESECTION (CLOSED ANASTOMOSIS) OF THE COLON AND RECTOSIGMOID

Including Description of Abdomino-Anal Methods for Restoration of Continuity Accompanying Excision of Carcinoma of the Rectal Ampulla*

Owen H. Wangensteen, M.D., Minneapolis, Minn.

(From the Department of Surgery, University of Minnesota)

PROCEDURES UNDER DISCUSSION

CURRENT practice in the University of Minnesota Surgical Clinic is to try to resect all unobstructed lesions of the colon in one stage, establishing intestinal continuity by oblique end-to-end closed (aseptic) anastomosis, without antecedent or complemental colostomy or decompressive vents, other than an indwelling tube. Lesions in the rectosigmoid, whose lower limits are within 10 to 13 cm. from the anal opening, as determined by proctoscopic examination, are treated similarly. In addition, for suitable carcinomas of the rectal ampulla between 5 and 10 cm. from the pectinate line, I am endeavoring to do a one-stage abdomino-anal proctectomy with preservation of the sphincters, establishing continuity by variants of methods described by others previously. The attainment of good to excellent continence, in the majority of the few patients who have been operated upon, suggests that a restudy of the Kraske and Hochenegg sacroperineal methods (or variants of them), with special attention to an abdomino-anal method of dissection and restoration of intestinal continuity with preservation of the sphincters, is in order. Furthermore, the emphasis which has been given to the *upward* spread of cancer of the rectum by the studies of Westhues (1930), Wood and Wilkie (1933), Gilchrist and David (1938), and Coller, Kay and MacIntyre (1940) suggests definitely that operations of this type are legitimate procedures, as long as one does not compromise on the extent of the removal, or invoke the procedure in instances in which proximal lymph node blockage may have permitted retrograde or downward migration of metastases. Obviously, in lesions in juxtaposition to the sphincters, and in ampullary lesions with local extension beyond the bowel wall, the orthodox abdominoperineal operation, in which a liberal portion of the levator ani muscle and the sphincter muscle are sacrificed, is to be preferred to the abdomino-anal operation described herein.

*The researches presented here were supported by grants of the Augustus L. Searle Fund for Experimental Surgical Research, the Citizens' Aid Society, and the Graduate School of the University of Minnesota.

Received for publication, May 11, 1943.

The colonic resections reported herein have been done by five surgeons; the larger number, however, were done by two surgical residents and me. The rectosigmoid resections and the abdomino-anal operations for ampullary carcinoma were done by me.

THE RISE AND DECLINE OF THE EXTERIORIZATION OPERATION

The adoption of the exteriorization operation for carcinoma of the colon by Mikulicz (1903) was, in its time, a definite forward step in the surgical management of colonic cancer. Bryant (1882), Bloch (1892), and Paul (1895, 1912) had previously reported instances in which the exteriorization principle had permitted extirpation of colonic lesions at lesser risks. It was the advocacy of the procedure by Mikulicz and his report of a favorable experience with its use, in a large series of cases, that gave this method of dealing with colonic malignancy an important impetus. Prior thereto, the method in general use for lesions in both the right and left colon was primary resection employing the open anastomosis. In his initial report, Mikulicz (1903) reported a group of twenty-four cases, in which exteriorization, accompanied by immediate removal of the lesion in some of them, was done, followed by secondary closure of the colonic stoma with a mortality of 16.6 per cent. Mikulicz favored a one- or two-stage resection for lesions of the right half of the colon and reserved the exteriorization procedure for lesions of the left colon. Up until quite recently, the precepts of Mikulicz, with reference to choice of procedure in dealing with colonic malignancy, have been followed quite generally. Lahey (1932) extended the exteriorization plan to lesions of the right colon, a suggestion which has not met with wide adoption or favor.

It was the prevalent high mortality from peritonitis that persuaded the surgeons of a generation and more ago to abandon primary colonic resection in favor of the exteriorization principle. Surgery of that time was not ready for primary resection. Oblique section of the bowel, with re-establishment of intestinal continuity by the closed method of anastomosis, has changed all this. Surgeons, who have schooled themselves in the precepts of Halsted with reference to intestinal suture technique, find that a satisfactory one-stage, oblique, end-to-end anastomosis can be made anywhere in the intestinal canal.

Schoemaker (1921, 1927), Wilkie (1939), Campbell (1940), and Whipple (1940) have been ardent advocates of the one-stage closed anastomosis. Wilkie and Whipple favor an auxiliary cecostomy or other external drainage vent for lesions of the left colon. Campbell felt no necessity for establishment of an external safety vent. Schoemaker (1927) advised a preliminary cecostomy for obstructive lesions in the descending colon. In the cases herein reported, a complemental decompressive vent was employed only three times, all in resections of the pelvic colon. Appendicostomy was done twice and in the one pa-

tient in this series of resections in which an open anastomosis was made, a complemental colostomy was done. In one of the appendicostomies, infection of the wound occurred. Therewith, external decompressive vents, as an accompaniment of colectomy, were given up altogether. Cheever (1931) was able to report a series of thirty-five cases of primary resection in the colon for malignancy in which anastomoses were made by the open method with a mortality of only 8.5 per cent. Cheever felt the employment of an external decompressive vent important; when it was omitted, the mortality increased considerably (24 per cent). The routine employment of suction applied to an indwelling duodenal tube probably has rendered unnecessary the use of such external drainage vents. Stone and McLanahan (1942) report a mortality of 10.6 per cent employing the closed anastomosis in colonic resections, whereas when the open anastomosis was employed the mortality was 20.6 per cent.

An important advantage of primary closed resection over the exteriorization operation is in the amount of mesentery constituting the lymphatic drainage area which can be sacrificed. Rarely, if ever, need the surgeon compromise on the extent of excision of mesentery in primary resection; whereas, obviously, in the exteriorization operation, there are practical limits to the amount of mesentery that can be excised without risking the viability of the bowel brought through the abdominal wall.

THE OPERATION

The material embraced in this report covers a two-year period (April 1, 1941, to April 1, 1943) during which time sixty primary resections were done for carcinoma of the colon and rectosigmoid. The closed or aseptic method has been in use in this clinic for a longer period of time. Only within the period of the study, however, has the policy been followed consistently of attacking adherent growths by removing the tissue in juxtaposition to it. In other words, studied attempts have been made to avoid contamination during operative procedures occasioned by coming unexpectedly upon a perforated lesion. In instances, in which preliminary dissection disclosed probable perforation of the lesion against the abdominal wall, mesentery, ureter, uterus, or bladder, a part of that structure would be sacrificed rather than accept the risk of spillage and bacterial contamination. The hope lent that sulfonamides, such as sulfaguanidine and succinyl sulfathiazole, would sterilize the intestinal content of the colon and render spillage through contamination of perforated lesions innocuous has not been borne out in the experience of this clinic. The only reliable safeguard against the contingency of opening such perforated lesions is to adopt the arbitrary policy of sacrificing even such important structures as a ureter or an additional loop of bowel. This principle of operation envisages the performance of more radical procedures but with a greater economy of life. Economy of the surgeon's

time becomes a relatively unimportant consideration when weighing the element of hazard to the patient presented by two alternative schemes of procedure. Also, only during the two-year period under consideration have the surgeons in this clinic become familiar enough with the nutritional needs of the debilitated patient to eliminate largely the losses sustained on this score in earlier years. The item of preparing patients satisfactorily for operation, who have lost considerable weight, and the problem of meeting caloric and nitrogen requirements of such patients are matters of major importance in dealing with poor-risk patients who frequently require formidable operative procedures. Acute colonic obstructions are excluded from this study, save in so far as such patients came up for consideration of resection after relief of the obstruction. There were six patients in this group who had antecedent colostomy for acute obstruction.

MEETING CALORIC AND NITROGEN REQUIREMENTS

Patients, who have been supported by their own fat stores for fairly long periods and whose existence might be described as having been autocannibalistic, frequently, at operation, are found to have fatty livers. And patients with fatty livers tolerate strenuous operative procedures very poorly. A systematic and careful inquiry into the character of food ingestion and the extent of weight loss is, therefore, extraordinarily important. The greater the percentile loss in body weight, the longer must be the period of preoperative preparation. Weight losses in excess of 25 per cent of the initial body weight demand a long period of preoperative feeding of a high protein, high carbohydrate, low fat diet. Patients with acute obstruction, obviously, must have an antecedent decompressive operation. Patients with mild obstruction, who exhibit large weight losses and who require a long period of preoperative feeding, also should have an antecedent colostomy; occasionally, however, if the weight loss is not large, intravenous feeding of a 20 per cent glucose solution, amino acids, and plasma will suffice and make a temporary colostomy unnecessary in patients with mild obstructive symptoms. The precepts of Madden and Whipple (1940), Ravdin (1940), and their associates have guided us in meeting the caloric and nitrogen requirement of patients who have sustained large weight losses. My associate, R. L. Varco (1942), has compounded two diets which in our experience have met the requirements of preparing hospital patients, who have lost considerable weight, for operation. In gastric cases with obstruction, the problem is even more difficult in patients who have lost 30 to 35 per cent of their body weight, a minimum of three weeks usually has been employed in replacing depleted body stores with a high protein and carbohydrate and low fat diet. Successful gastric resection has been carried out latterly on two patients exhibiting recent weight losses, constituting 35 to 37 per cent, respectively, of the body weight.

IMPROVING THE OPERATIVE MORTALITY SCORE

Reduction of operative mortality is essentially the same problem as stopping the leaks in an expense account. No surgeon probably will learn to keep all the leaks sealed. However, it is very reassuring to note, as competence in a clinic improves in one item after another in the many problems involved in the care of surgical patients, how those increments of gain are reflected directly in an improved mortality. The best surgeons of the past generation were content with a mortality of 10 per cent in formidable operations for malignancy in the gastrointestinal canal. However, small gains in knowledge here and there, such as improved anesthesia, effectual schemes of preventing intestinal distention, and a better understanding of the importance and the technique of preparing patients for operation and caring for them after, should begin to be apparent. Avoidance of deaths, from pneumonia and peritonitis, attending operations of election is almost within the surgeon's grasp, if he will only be alert and responsive to the available means of thwarting these disasters, which have pursued the surgeon stealthily and too effectively since the very beginnings of abdominal surgery. Yet, when one contemplates the infirmities of age as well as the debility frequently attending gastrointestinal neoplasms, the goal of a low mortality appears difficult for consistent achievement. As the surgeon's confidence increases in methods of preparing poor-risk patients for operation, he is persuaded to accept risks of a strictly borderline character. With advantages of management unknown to our surgical predecessors of a generation ago, we should be able to improve upon their record of accomplishment and still extend the benefits of operation to a larger group of patients. A greater salvage of life is to be achieved obviously through urging patients with symptoms suggestive of a colonic malignancy to report for painstaking examinations at an early date. Yet, the surgeon's responsibility is to deal with the problem as he finds it. Perhaps in no malignant neoplasm in the body are determined efforts, directed at excising widely an adherent growth, more commendable than in the colon. As contrasted with the stomach, the number of long survivals or apparent cures attending the grubbing out of difficult adherent neoplasms in colonic malignancies is large, as the experience of many surgeons attests. Long periods of palliation attending resection, in the presence of hepatic metastases, in my experience are not unusual. Survival beyond six months, when gastric resection is carried out in the presence of hepatic metastases, appears to be distinctly unusual. Survival beyond one year, under similar circumstances when the primary lesion is colonic, is not unusual, in my experience.

I. COLON

Plan of Operation.—Preoperative preparation of the colon: We have tried most of the expedients which have been suggested for preparing

the colon for operation. None are wholly satisfactory. In this series of cases, there has been a fairly large number in which the preparation was poor—usually in patients with low-grade obstruction, frequently unrecognized preoperatively. Yet, employing a closed or aseptic mode of suture, the surgeon need not change his plan of operation because feces are present in the bowel. In several patients in this series, primary colonic resection was done despite the presence of feces proximal to a somewhat stenotic lesion. It is my impression that the preoperative administration of a liberal amount of mineral oil by mouth and the giving of colon flushes just prior to operation are the best schemes of insuring an empty colon. Sulfaguanidine and succinyl sulfathiazole have been employed and each has been given up in favor of the preoperative administration of enemas. No sulfonamide is given prior to operation.

Indwelling tube: Over a period of more than twelve years in this clinic, patients having abdominal operations of election have gone to the operating room with an indwelling duodenal tube in place. To this practice, patients with colonic or rectal malignancy are no exception. Suction is employed prior to, during, and after operation. After gastric resection, the duodenal tube is left in place three full days after operation; after partial colectomy, the tube is allowed to remain for five days. Whipple (1940) has come to put considerable reliance on the Miller-Abbott tube in colonic surgery. In this clinic, too, we have learned to appreciate many of the advantages of the Miller-Abbott tube; however, as a prophylaxis of intestinal distention, the ordinary nine-hole indwelling duodenal tube meets the situation admirably in most patients. Moreover, if the Miller-Abbott tube, placed well down in the reaches of the small intestine, is used as a prophylaxis against postoperative distention often it is found necessary to put an additional tube down through the patient's other nostril into his stomach, a circumstance which is trying to the patient, his relatives, and his surgeon.

Anesthesia: Cyclopropane has been the basal anesthetic agent for abdominal surgery in this clinic for years. During the past year, a combination of cyclopropane and spinal anesthesia has been employed. The anesthetist's technique of reducing the patient's respiratory movements to a minimum by artificial inflation of the lungs is a scheme particularly acceptable to the surgeon, for it insures a quiet abdomen. Improved anesthetic methods have been a great boon to the surgeon, permitting him to be more deliberate and painstaking in his operative procedures.

Incisions: The vertical incision has been used largely; in right hemicolectomies, however, an oblique incision beginning beneath the left costal margin and coursing downward and to the right above the umbilicus is employed frequently. It affords good exposure and gives ready access to the midtransverse colon, where the anastomosis will be made. This incision is not a physiologic one with respect to innervation and blood supply as is the Hoag incision which courses obliquely downward

in the other direction, paralleling nerve and blood supply. The oblique incision herein described, however, is superior to the Hoag incision in affording exposure where it is needed most, a consideration which outweighs any other. Surgeons have come to have far more trust in the transverse or the oblique, as contrasted with the vertical incision, in that evisceration with the latter is more likely to occur. Unfortunately, for low lesions in the left colon, only the vertical incision affords optimal exposure, and good exposure is so important that it becomes a dominant consideration.

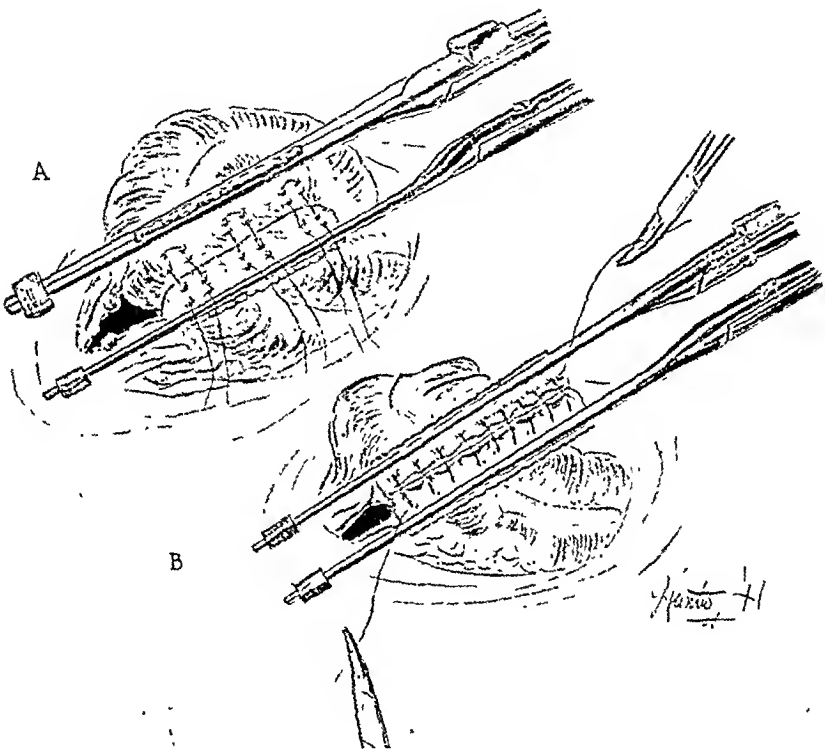

A and *B*.

Fig. 1.—Aseptic (closed) oblique end-to-end anastomosis after excision of pelvic colon. *A*, [illegible] row of sutures. Three or four Halsted mattress sutures of [illegible] two-pound test) are placed with a fine curved-eye needle (An[illegible] Then similar, additional, interrupted sutures are placed betw[illegible] row of sutures, should not lie more than 7.5 mm., away from the clamp. If only 5 mm. of the bowel wall are employed in the suture, the resultant lumen will be larger.

B. The inner posterior row is made with a running suture of 000 catgut. The ferrules are knocked off the clamps before they are rotated for placement of the anterior row of sutures.

C. The double ferrule has been placed over the tips of both blades and the locking device fastened over the mid-portion. A running suture of catgut is placed near the clamps anteriorly. It is to be noted that straight mosquito forceps are employed to identify the posterior catgut sutures, while curved mosquito clamps are used for the same purpose anteriorly.

D. The clamps have been withdrawn, the anterior and posterior catgut sutures at each end have been tied together, and placement of a row of [illegible] Halsted mattress sutures [illegible] to portion of [illegible] employed to secure closure [illegible] resection clam[illegible] V. C. Mueller Co., Chi[illegible] Intestinal [illegible] of Charles C Thomas, Publisher).

The anastomosis: An end-to-end oblique closed (aseptic) anastomosis has been employed to the exclusion of all other methods of anastomosis in this clinic, save in subtotal colectomy in which an anastomosis is effected between the terminal end of the pelvic colon and the side of the cecum. For multiple lesions of the colon, leaving the cecum and the ascending colon free, I have become very partial to this scheme of anastomosis (Fig. 1). For idiopathic dilatation of the colon, so-called Hirschsprung's disease, it is, I believe, a quite satisfactory operative procedure.

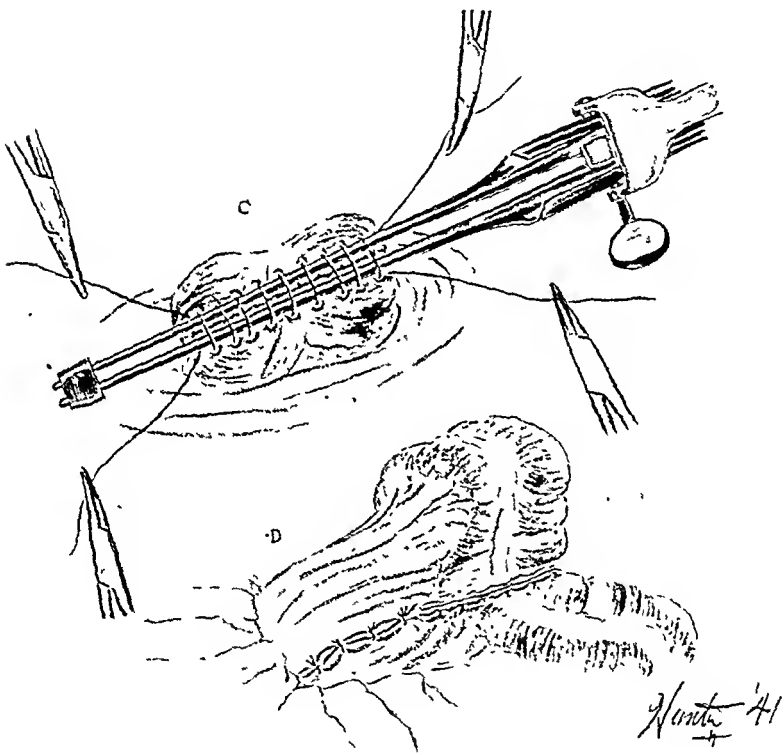

Fig. 1, *C* and *D*.—For legend see page 409.)

The Italian surgeon Parlavecchio (1898, 1900), the innovator of the closed method of making intestinal anastomoses, noted the importance of making an oblique section of the bowel, leaving the mesenteric edge longer. On consulting the original writings of Parlavecchio during the past year, I was struck with the great similarity between the clamps employed by Parlavecchio and those made for me in 1938 by Mr. John A. Phelan of the Scientific Apparatus Shop on the University campus. Parlavecchio described the use of an instrument with well-tempered, flexible, and thin blades with biting grooves. Parlavecchio employed a locking device over the shank of the handles not unlike that in my in-

strument. The only things missing in the older instrument are the single and double ferrules which prevent spread or separation of the thin blades of the clamp as it is closed on the bowel. Interestingly enough, Parlavecchio incorporated in his anastomosis clamp a refinement which Mr, Phelan and I discussed but decided to omit, viz., a curve in the handles to permit easier rotation of the instrument for the anterior suture, after completion of the two posterior rows of suture. Experience has shown that the straight-handled clamp, which is easier to manipulate, meets the requirements of the situation very satisfactorily.

The mesenteric angle in end-to-end anastomoses and the problem of the inturn: The problem of the mesenteric angle in oblique end-to-end anastomoses throughout the intestinal canal undoubtedly has occasioned many surgeons to adopt the less physiologic procedure of side-to-side anastomosis. I have solved this problem for myself in the manner illustrated in Fig. 2. The mesentery is not to be relied upon to close

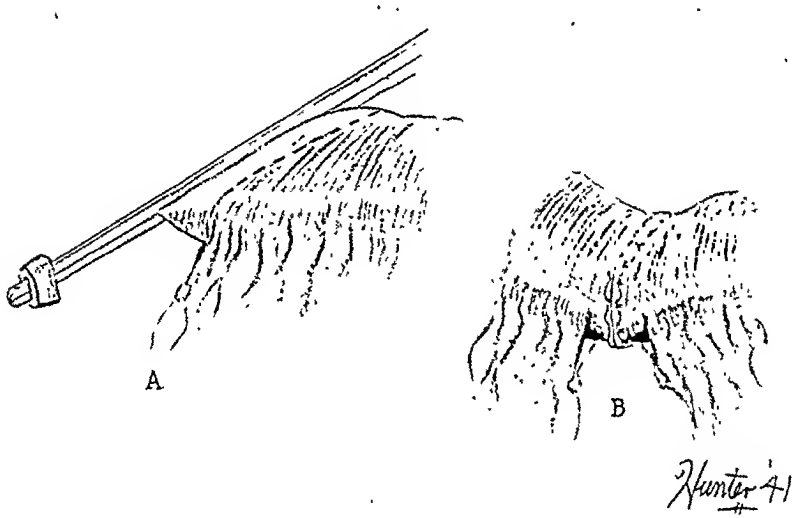

Fig. 2.—Solution of the difficulty of the mesenteric angle. *A*, Placement of the clamp upon the bowel wall at an acute angle (about 45 degrees). The external row of sutures will come within the confines of the dotted line, that is, the first posterior row and the last anterior row will not be more than .75 cm. (preferably .5 cm.) away from the clamp.

B, Detachment of the mesentery to a point .75 cm. beyond the site of application of the clamp in an oblique end-to-end anastomosis permits placement of every suture in the bowel wall. The mesentery is not employed in the anastomosis. The manner of dealing with mesenteric angle, shown here, concerns the small intestine; the same technique is employed in resections of the colon. The preparation of the colon for the anastomosis is a little more difficult. (From Wangensteen: Intestinal Obstructions, courtesy of Charles C Thomas, Publisher.)

the mesenteric border of the bowel; nor should the mesenteric border present any special problem if the scheme is followed of denuding the bowel of its mesentery 7.5 mm. beyond the site selected for section of the bowel. Furthermore, every stitch is to be placed in the gut wall. Two rows of sutures, in which the extent of the inverted bowel does not exceed 7.5 mm., constitute a satisfactory inturn. No matter where

in the intestinal canal the anastomosis is made, the surgeon should set himself the task of employing only 5 to 7.5 mm. of the adjacent walls of the tubular viscera to be approximated.

The epiploic appendages: Despite the apparent importance of the epiploic appendages in the blood supply of the colon, in the interests of placing each and every stitch in the bowel wall, I have sacrificed these appendages as indicated in Fig. 3. Grasping a fatty epiploic appendage, overlying the bowel wall in a suture, is not an acceptable substitute for careful placement of the stitches into the submucous coat of the bowel.

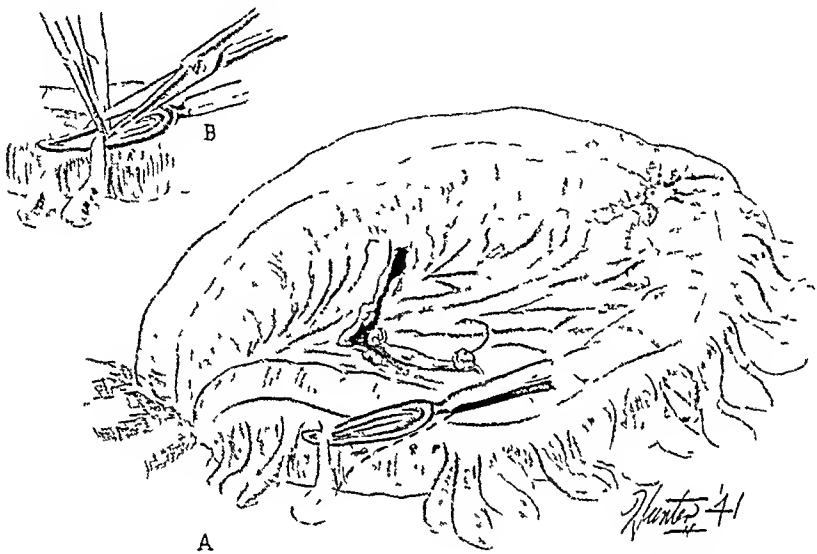

Fig 3—Mode of preparing the colon at operation for an oblique end-to-end anastomosis *A*, The dotted line indicates the proposed site for application of the clamp

B, The fatty tags are underrun with a dissector Each fatty tag is divided and tied as indicated, to obviate hematoma formation The bowel wall is to be cleared for a distance of ¾ cm beyond the proposed site of section This maneuver permits the surgeon to place each suture directly in the bowel wall (From Wangensteen Intestinal Obstructions, courtesy of Charles C Thomas, Publisher.)

Antecedent or complemental colostomy unnecessary: If each and every stitch grasps the submucous coat of the bowel, the sutures are otherwise well placed, and the blood supply of the anastomosed segments is preserved, there does not appear to be any necessity for a preliminary colostomy or little if any justification for the so-called "defunctioning colostomy" of Devine (1938) A well-made anastomosis will not leak. Only in the presence of obstruction is an antecedent decompressive vent necessary. For acute obstructions of the pelvic colon with great distention, it has long been the practice of this clinic to establish a transverse colostomy, a procedure which can be accomplished with little hazard.

Implantation of sulfathiazole: On completion of the anastomosis, a small amount of sulfathiazole is implanted about the anastomosis In-

asmuch as most anastomoses in colonic resections remain in contact with the small intestine, it is undesirable to leave a large quantity of sulfathiazole in the peritoneal cavity because of the known adhesive stimulating quality of the drug. When the anastomosis can be extraperitonealized completely, as in resections of the rectosigmoid, a larger implantation of sulfathiazole can be made with no misgivings on the score of adhesion formation. Our usual plan is to implant not more than a total of 3 Gm. in the ordinary adult patient, the larger fraction being implanted in the abdominal wall. No sulfonamide is given prior to operation; no additional sulfonamide is given after operation, until after the elapse of forty-eight hours, when a total of 1 to 2 Gm. of sulfadiazine is given subcutaneously in divided doses for two or three days if an indwelling urethral catheter still remains in place.

Intraperitoneal vaccination: We have never employed preoperative intraperitoneal schemes of vaccination in this clinic. On theoretical grounds alone the plan does not appear to have real merit. Why subject the patient to this ordeal? It would appear that the neoplasm and operation are tribulations enough for the patient. Why provoke fever and make the patient ill unnecessarily just prior to the trials of operation?

Division of Cases.—The location of the lesions appears in the tables. The majority of the operations were undertaken for carcinoma (see Table I). In the cecal group of resections, there were four instances

TABLE I

NATURE OF LESIONS

	NUMBER OF CASES	HOSPITAL DEATHS	MORTALITY (PER CENT)
Carcinoma	46	1	2.1
Regional ileitis and colitis	4	0	
Ulcerative colitis	2	0	
Diverticulitis	4*	0	
Hirschsprung's disease	3	0	
Tuberculosis	1	0	
Multiple intestinal fistulas	1	0	
Total	61	1	1.6

*One patient also had regional ileitis (see text).

of regional ileitis or ileocecitis, necessitating removal of the terminal segments of the ileum and the right half of the colon. Among the 18 patients with lesions in the pelvic colon, one had tuberculosis, and 4 had diverticulitis. One of these also had a regional enteritis involving the terminal ileum and cecum, necessitating a simultaneous ileocolic resection and a resection of the pelvic colon. The patient was dismissed from the hospital ten days later with the wound healed. The patient with tuberculosis of the pelvic colon also had two simultaneous colon resections, one in the right half of the colon and the other in the pelvic colon. As indicated in the footnote to Table II, of the 7 patients for whom a

in the intestinal canal the anastomosis is made, the surgeon should set himself the task of employing only 5 to 7.5 mm. of the adjacent walls of the tubular viscera to be approximated.

The epiploic appendages: Despite the apparent importance of the epiploic appendages in the blood supply of the colon, in the interests of placing each and every stitch in the bowel wall, I have sacrificed these appendages as indicated in Fig. 3. Grasping a fatty epiploic appendage, overlying the bowel wall in a suture, is not an acceptable substitute for careful placement of the stitches into the submucous coat of the bowel.

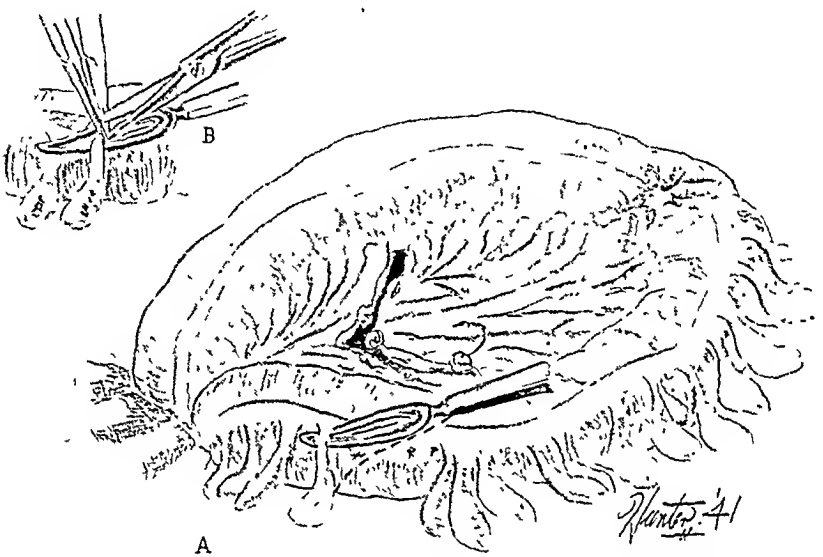

Fig. 3.—Mode of preparing the colon at operation for an oblique end-to-end anastomosis. *A*, The dotted line indicates the proposed site for application of the clamp.
B, The fatty tags are underrun with a dissector. Each fatty tag is divided and tied as indicated, to obviate hematoma formation. The bowel wall is to be cleared for a distance of ¾ cm. beyond the proposed site of section. This maneuver permits the surgeon to place each suture directly in the bowel wall. (From Wangensteen: Intestinal Obstructions, courtesy of Charles C Thomas, Publisher.)

Antecedent or complemental colostomy unnecessary: If each and every stitch grasps the submucous coat of the bowel, the sutures are otherwise well placed, and the blood supply of the anastomosed segments is preserved, there does not appear to be any necessity for a preliminary colostomy or little if any justification for the so-called "defunctioning colostomy" of Devine (1938). A well-made anastomosis will not leak. Only in the presence of obstruction is an antecedent decompressive vent necessary. For acute obstructions of the pelvic colon with great distention, it has long been the practice of this clinic to establish a transverse colostomy, a procedure which can be accomplished with little hazard.

Implantation of sulfathiazole: On completion of the anastomosis, a small amount of sulfathiazole is implanted about the anastomosis. In-

In one of these patients, Mr. F. G., aged 49 years (Univ. Hosp. No. 709574), it became necessary also to remove a strip of the inferior vena cava in addition to the kidney and ureter and finally, to my great embarrassment, to remove a section of the retroperitoneal duodenum. In the appraisal of the operability of the lesion, it was believed that a resection of the anterior face of the duodenum would suffice. The presence of an unrecognized duodenocolic fistula made it mandatory to sacrifice a fairly long segment of the duodenum ligating the pancreatic ducts. I was not certain whether the ampullary termination of the common bile duct was removed with the duodenum, consequently, I estab-



Fig. 4.—Subtotal colectomy for multiple lesions in the colon with end-to-side anastomosis between pelvic colon and side of cecum. This type of operation as a single stage procedure has been done for multiple carcinomas (pelvic colon and hepatic flexure) and for polyposis and chronic ulcerative colitis without involvement of the rectum or cecum.

A, Use of a Petz suturing apparatus in the division of the ascending colon.

B, Inversion of the divided colon with interrupted Halsted mattress suture.

C, The completed oblique anastomosis between side of cecum and end of pelvic colon. Closure of cecum is accomplished with surprising ease after subtotal colectomy. (From Charles C. Thomas, Publisher, Intestinal Obstructions, courtesy of Charles C. Thomas, Publisher.)

one-stage subtotal colectomy was done, 6 had noncancerous lesions. Of the 60 patients for whom colonic resection was done, 15 had lesions other than malignancy. There were no deaths in this group.

TABLE II

LOCATION OF LESIONS

	NUMBER OF CASES	HOSPITAL DEATHS
Cecum	14	0
Ascending colon	4	1
Hepatic flexure	3	
Descending colon	5	0
Pelvic colon (exclusive of rectosigmoid)	18	0
Multiple lesions necessitating subtotal colectomy (1 stage) anastomosing terminal ileum or cecum to terminal pelvic colon*	7*	0
Rectosigmoid	10	0
Total	61	1 (1.6% mortality)

*This group includes one patient with polyposis and multiple carcinomas, one patient with diffuse diverticulitis and diverticulosis, two patients with ulcerative colitis, three patients with Hirschsprung's disease. In three of the seven, an end-to-side anastomosis was made as shown in Fig. 4; in the other four, the terminal ileum was anastomosed to the colon pelvinum end-to-end.

Mortality and Resectability.—The total hospital mortality for resections of the colon and rectosigmoid during this two-year period was 1.6 per cent. Of the 61 operations, a closed primary anastomosis was done in 57 patients (Table III). In 60 of the 61 patients, excision of the lesion was effected by one method or another.

Among the 61 patients, 46 had malignant lesions in the colon; 45 were carcinoma. There was one lymphosarcoma of the cecum. Of the 46 patients with colonic malignancy, 42 had a primary closed resection. Entero-anastomosis alone was done in 1 patient, a two-stage resection in 1, an open anastomosis in 1, and a three-stage exteriorization was done once (Table III). A primary resection of some type was done in 43 of the 46 patients with malignancy (93.4 per cent). In all but 1 of the 46 patients, however, removal of the growth actually was accomplished (97.8 per cent). This is probably a higher resection rate than can be justified by more experience. Five of these patients had hepatic metastases; in 2 of them the hepatic metastases were extensive, but the lesions in the colon were stenotic enough to necessitate either resection or its only alternative, colostomy. Simultaneous cholecystectomy or appendectomy has been done several times as an incident to primary colonic resection. Coincidental total hysterectomy was performed once because of intimate adherence to a rectosigmoidal lesion. Removal of a portion of parietal peritoneum overlying an adherent lesion is not an unusual circumstance and must be done if entry into a perforated lesion is to be avoided. Partial excision of the urinary bladder was undertaken twice. The right kidney was removed twice for adherent, perforated lesions of the ascending colon and hepatic flexure.

one postoperative hospital day was 4 dismissals on the tenth, fifteenth, and seventeenth postoperative days. Three patients were dismissed on each of the following postoperative days: the thirteenth, fourteenth, fifteenth, and eighteenth. The other dismissals were dispersed over a wide interval. The longest postoperative stay was 35 days, occasioned by a postoperative adhesive obstruction which remained refractory to suction

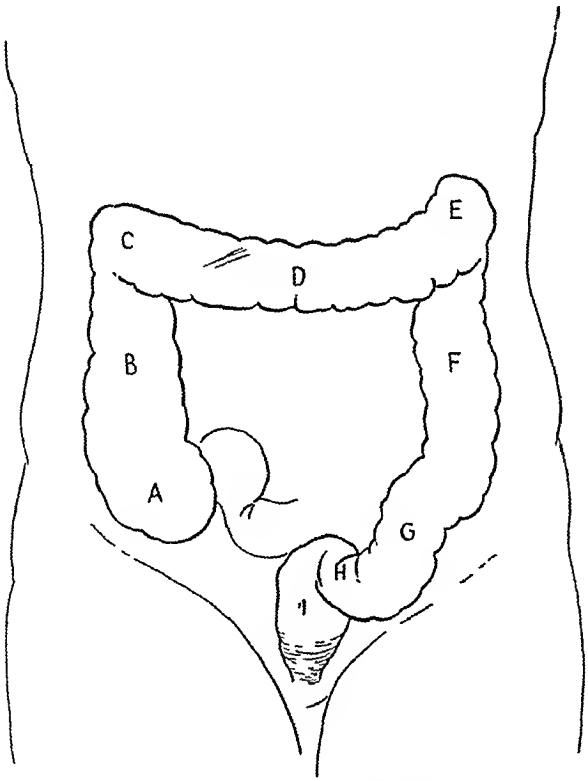

Fig 5—Location of lesions with reference to type of resection. *A*, Cecum Right hemicolectomy with removal of terminal segments of ileum, and lymphatic drainage area, re-establishing continuity by oblique end-to-end anastomosis between ileum and transverse colon No more ileum should be removed than necessary lest persistent diarrhea be provoked by simultaneous sacrifice of right colon and water-absorbing segments of the ileum

B, Ascending colon Same operation as for *A*.

C, Hepatic flexure Same operation as for *A*. If mesenteric lymph node involvement is not great, and right colic artery and vein can be preserved to the cecum, and end-to-end anastomosis can be effected between ascending and transverse colon; in the main, the operation described under *A* is preferable.

D, Transverse colon For a small lesion the avascular suspension ligaments of the hepatic and splenic flexures may be divided, permitting end-to-end union between the proximal and distal ends of the transverse colon. For large lesions in which the tension factor persists after mobilization, the ascending colon may be anastomosed to the distal end of the transverse colon, or the type of operation shown in Fig. 4 may be employed

E, Splenic flexure. Usually end-to-end anastomosis between the pelvic and the transverse colon constitutes the best choice of procedure

F, Descending colon For small lesions, local segmental resection, more frequently the type of operation described under *E* becomes necessary

G, Pelvic colon. Local segmental resection The flexure of the colon makes this procedure almost uniformly feasible

H, Rectosigmoid Segmental resection with end-to-end anastomosis between pelvic colon and rectum. See Fig 6

I, Ampulla of rectum For lesions less than 10 and more than 5 cm., from the pectinate line, ampullary resection may be done in suitable cases

lished external tube drainage of the gall bladder. Later, when the duodenal specimen was studied carefully by the pathologist, it was observed that the ampulla of the common bile duct was on the specimen. This patient died from massive hemorrhage from an actively bleeding artery in the wall of the antrum of the stomach sixteen days after operation. In other words, a Mann-Williamson operation had been done on the patient. At autopsy, both intestinal anastomoses were intact. Transplantation of the bile duct into the stomach or duodenum might have averted this disaster. In his monograph on *The Surgery of Pancreatic Tumors,* Brunschwig (1942) gives no indication that this complication has been observed in the Whipple operation for carcinoma of the ampulla or carcinoma of the head of the pancreas. It would appear, therefore, that return of bile to the intestinal canal is mandatory when the pancreatic ducts are to be ligated.

TABLE III

TYPES OF OPERATIVE PROCEDURES

	NO. OF CASES	HOSPITAL DEATHS	TALITY MOR- (%)	RESEARCHES
Exploratory only	0	0	0	
Colostomy only	0	0	0	
Enteroanastomosis only	1	0	0	Perforated lesion with abscess and metastases
Two-stage resection (preliminary enteroanastomosis)	1	0	0	Perforated lesion with abscess
Exteriorization (3 stages)	1	0	0	Severe cirrhosis
Open anastomosis	1	0	0	Closed anastomosis in ileum and open anastomosis between rectum and pelvic colon with resection of bladder for multiple intestinal fistulas (Donnis), also complemental colostomy
Primary resection	57	1	1.7	Antecedent transverse colostomy for acute obstruction 6; complemental appendicostomy 2; complemental colostomy 1
Total	61	1	1.6	

Postoperative Hospital Stay.—Complications: The mean postoperative hospital stay following resection for the 60 of the 61 patients who recovered from operation was 12 days; the average length of hospital stay was 14.3 days. Within 14 days of operation, 36 patients were dismissed. More patients were dismissed on the eleventh postoperative day than on any other, viz., 15 patients. Ten patients were dismissed on the twelfth postoperative day; the largest number dismissed on any other

principles of good cancer surgery with restitution of intestinal continuity. To Dixon, in particular, great credit is due for indicating that this procedure can be accomplished with a reasonable risk. Dixon performed the operation usually in three stages, performing first colostomy, then excising the lesion, establishing continuity by an open anastomosis. The final procedure was closure of the colostomy. Arnold (1939) and Arnold and Shea (1940) have employed an abdomino-sacral three-stage procedure for carcinoma at the rectosigmoid, an operation not unlike the sacral exteriorization of Küttner (1910).

My interest in trying to restore continuity by primary resection for lesions in the terminal pelvic colon and at the rectosigmoidal juncture was provoked by a patient for whom a colostomy had been established elsewhere for an ulcerative lesion in the pelvic colon. This patient was determined to have intestinal continuity restored. He had twice previously been subjected to exploration, at his own persistent insistence, in vain attempts to accomplish restoration of continuity. No vestige of a colon had been found in the peritoneal cavity beneath the level of an inguinal colostomy when Dr. Charles E. Rea of this clinic performed the last exploration. Proctoscopic examination disclosed a rectum patulous to the proctoscope to 12 cm. It was my intention to dissect beneath the pelvic peritoneum for the blind rectal pouch, to remove the colostomy, and to establish continuity by end-to-end suture between the rectum and the pelvic colon. The colon was so full of impacted fecal material, from cecum to the colostomy outlet, that an anastomosis with the colon did not appear feasible. The contracted colostomy outlet apparently precluded ready evacuation of the colonic content despite preoperative administration of enemas. Recourse was had, therefore, to the expedient described by Stone (1927), in which a loop of ileum was interposed, an end-to-end anastomosis being effected between the rectal ampulla resurrected from the sacral concavity and the ileum. Because of the extraordinary fecal impaction of the entire colon, the proximal end of the ileum was led out to the exterior. During convalescence, the colostomy opening was enlarged and vigorous catharsis readily remedied the disquieting colonic impaction noted at operation. At a subsequent procedure, end-to-end union was effected between the transverse colon and the ileum, the colostomy and the intervening colon being excised.

As an aside, it may be interesting to record the character of the fluid drained out through the temporary ileal fistula. This was the first time in this clinic that an anastomosis had been made at so low a level. At that time (June 9, 1941), the operation seemed technically very difficult. Apparently a few sutures engaged the opposite bowel wall, causing a temporary obstruction, an occurrence which permitted us to collect daily from the 20 cm. ileal segment, through a catheter in its proximal end, an opalescent, white, somewhat milky fluid. The fluid looked not unlike a rich admixture of mucus with fluid from anywhere in the

and the use of the Miller-Abbott tube, secondary operation being necessary for the relief of the obstruction. In the main, the chief causes for lengthening of the postoperative hospital stay beyond the conventional 11 or 12 days were the infirmities of age and the debilitated status of a poorly nourished patient. The one patient for whom the exteriorization operation was done had a total postoperative hospital stay of 33 days—13 days following the initial exteriorization and excision, 10 days after cutting the spur, and again 10 days following closure of the colostomy. The one-stage closed aseptic anastomosis is the operative procedure of choice from the standpoint of the patient's economy of time and hospital expense. A convalescence without complication assures prompt wound healing, minimal mortality, and early recovery.

The Occurrence of Diarrhea After Right Hemicolectomy.—Transient diarrhea after excision of the right colon together with 2 or 3 feet of the terminal ileum has not been an unusual circumstance. Perhaps this is as it should be, for water absorption is largely a function of the ileum; in addition, a further drying process of the intestinal content takes place normally in the right half of the colon. Whenever sacrifice of this segment of the colon is accompanied by loss of 2 or 3 feet of the terminal ileum, as becomes necessary to remove adequately the lymphatic drainage area for a cecal carcinoma, temporary diarrhea may follow. I have never observed diarrhea following sacrifice of a good portion of the left colon; nor have I seen it in the cases of subtotal colectomy in which the cecum is anastomosed to the colon pelvinum or rectum. As a matter of fact, there are 2 patients in the present group for whom right hemicolectomy with sacrifice of a short segment of the ileum was done more than a year ago, who continue to have, without other apparent cause, four to five stools a day—a diarrhea which has remained refractory to all the usual measures of dealing with such situations.

II. PRIMARY CLOSED RESECTION FOR LESIONS AT THE RECTOSIGMOIDAL JUNCTURE

As early as 1910, Balfour had reported excising lesions in the pelvic colon as a one-stage procedure, establishing intestinal continuity over a rubber tube. In 1920, Balfour made a second report upon the utility of this procedure. In 1908, Lockhart-Mummery described excision of a lesion in the pelvic colon through a perineal incision, making the anastomosis over a glass tube. In the main, however, it appears that most surgeons have settled upon a one-stage abdominoperineal operation as the only operative procedure which meets satisfactorily the problem presented by lesions of the lower pelvic colon or upper rectum. There have been only a few dissenting voices. Horsley (1937), Dixon (1939, 1940), and Dunphy (1940) have each reaffirmed their belief in the thesis that lesions in the rectosigmoid can be excised in accordance with the

Arbitrary Surgical Definition of the Lower Proctoscopic Limits of Lesions of the Rectosigmoid.—The rectum begins where the colon ceases to have a mesentery. Prior to the BNA reclassification of the constituent parts of the pelvic colon and rectum, the colon pelvinum was counted

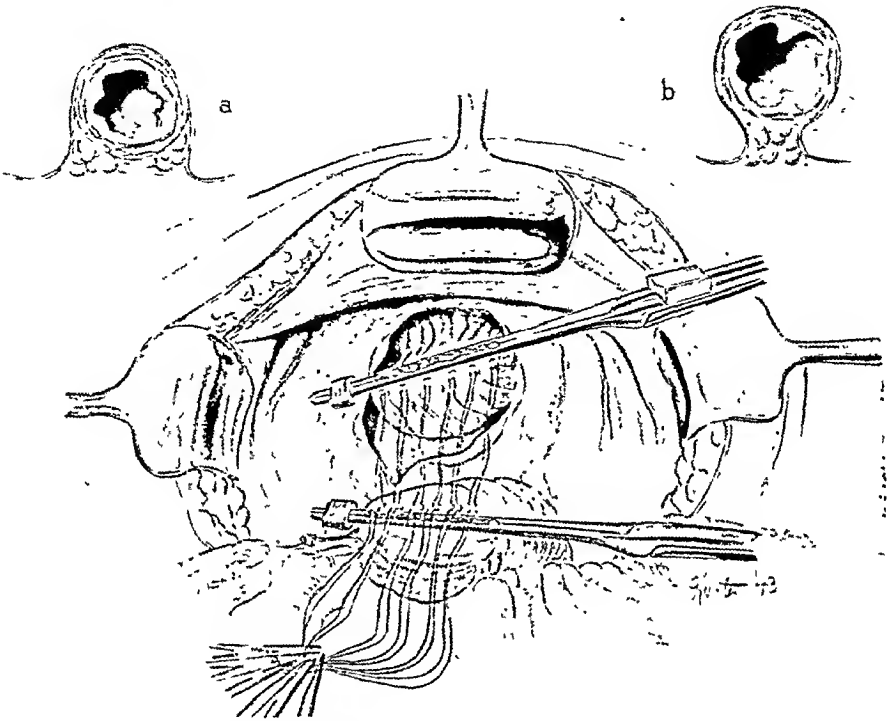

Fig. 6.—The type of anastomosis is essentially that shown in Fig. 1. However, because of the depth at which the anastomosis must be made in the pelvis, the scheme illustrated here facilitates the procedure. In the ordinary anastomosis a 13 to 16 inch (32 to 40 cm.) silk suture is employed. Here a 20 inch (50 cm.) suture is used. All the sutures are placed and the segments to be approximated, the rectum and pelvic colon, are allowed to remain at some distance from one another until the last suture is placed. Then the anastomosis is completed as is indicated in *B*, *C*, and *D* of Fig. 1.
The width of the usual mesenteric attachment of the colon pelvinum and rectum is shown in *A* (3 to 9 o'clock); the usual nature of the mesenteric attachment is shown in *B* (5 to 7 o'clock). The broader mesentery of the rectum makes it feasible to place the clamp on the lower segment, in rectosigmoidal anastomoses, directly transverse to the long axis of the bowel—an enormous advantage in a low difficult anastomosis. The only consideration which prompts an oblique placement of the clamp on the rectal segment is the matter of gaining added width for a broader lumen.

as a portion of the rectum (Fig. 7). In designating lesions of the rectosigmoid, I have employed rather arbitrary distinctions, including only those lesions whose lower extent, as observed through the proctoscope, is not less than 10 nor more than 13 cm. from the pectinate line. The rectum is not straight as its name would imply; it has a deep anteroposterior curve and lesser lateral curves. Lesions, whose lower proctoscopic limit is more than 13 cm. from the anal opening, in the main, can be resected easily without mobilizing the rectum. Even for lesions within the arbitrary limits described, there is some variation, in the ease or difficulty with which the operation is done, depending on the depth of the

intestinal canal. The surprising thing, however, was the odor of this innocent-looking fluid. Quite uniformly a startled look lighted the faces of all who sampled the aroma of the bottle. It was a pungent, unpleasant odor, which permeated the patient's room. Presumably, this is the normal ileal secretion. No such odor was perceptible on the patient's breath at this time, *initially on admission to hospital*, or after complete restoration of intestinal continuity.

This patient, Mr. R. P., aged 46 years (Univ. Hosp. No. 667947), has been very pleased with the re-establishment of intestinal continuity, and the operation of the new channel apparently has duplicated normal colonic behavior in every way.

This procedure suggested the feasibility of excising carcinomatous lesions at the rectosigmoidal juncture, with primary re-establishment of intestinal continuity. During the period covered by this study, primary resection has been done for rectosigmoidal lesion in a group of ten cases (Table II). The same technique of establishing intestinal continuity is employed as has been found practical in aseptic or closed resections of the stomach and the small intestine or colon. The clamps employed are the same. The only difference in the technique is depicted in Fig. 6. The broad attachment of the mesentery to the rectum obviates the necessity of making an oblique section of the rectum, as is mandatory in primary anastomoses in the colon. In consequence, a transverse section on the lower rectal segment can be made with salvage of rectal wall for the anastomosis, an item which makes the operation easier. Apparently, the middle and lower hemorrhoidal arteries are quite adequate to support a normal blood flow to the residual rectum, for in each such operation, obviously, it becomes necessary to sacrifice the superior hemorrhoidal artery.

Antecedent colostomy, save in the presence of acute obstruction, appears to be unnecessary; similarly, a complemental external decompressive vent appears unnecessary. As in the colonic anastomoses, each and every suture is placed in the gut wall, great care being observed to secure satisfactory approximation with an inturn, not exceeding 7.5 mm. Moreover, it is surprisingly easy to extraperitonealize the entire anastomosis.* It is also a simple procedure to push a rectal tube beyond the anastomosis after completion of the suture. I employ a No. 22 tube and have an assistant push it up from below, threading the tube about 10 cm. above the anastomosis. Every third day the tube is withdrawn 2 to 3 cm. to preclude tension effects of the tip of the tube upon the pelvic colon. No intestinal fistulas occurred in the group. Four of the ten patients in the series were dismissed from the hospital with a healed wound in eleven days and two on the twelfth postoperative day. One patient remained twenty-four days; the others left the hospital on the seventeenth postoperative day, with healed wounds.

*In primary resections of the rectosigmoid, the surgeon has no justification in being too proud to have recourse to this effective therapeutic expedient of affording his patient added protection.

place to sound a note of warning over enthusiasm for primary resection with restoration of intestinal continuity in a patient presenting a carcinoma on the basis of a polyp, exhibiting at the same time polyps in the rectum which appear benign on proctoscopic examination. Recently in this clinic, a patient from the present series, Mr. W. D., aged 60 years (Univ. Hosp. No. 619643), was submitted to abdominoperineal excision approximately 16 months after segmental resection had been done in the pelvic colon. It was believed that the polyps in the rectum could be kept in check by fulguration. Despite repeated fulguration carcinoma developed. In another patient, Mrs. M. L., aged 49 years (Univ. Hosp. No. 648542), two lesions were observed proctoscopically, one was a carcinoma at 12 cm. from the anal opening, the other was described as a benign polyp at a distance of 10 cm. from the anus. Microscopic study of the resected segment showed that the polyp was malignant, even though there was yet no demonstrable invasion of the circular muscle. To trust to fulguration for control of rectal polyps, when a similar polyp at the rectosigmoidal juncture or in the pelvic colon already has become malignant, does not appear to be a wise course.

Preservation of normal sexual function: That impotence is a frequent accompaniment of the abdominoperineal operation of removal of the pelvic colon and rectum is the common experience of surgeons. Jones (1942) indicates that the incidence of impotence following the operation in male patients is approximately 95 per cent. In rectosigmoidal resection, with immediate restoration of intestinal continuity, this unfortunate side effect of the abdominoperineal operation is avoided.

III. ABDOMINO-ANAL METHODS FOR EXCISION OF CARCINOMA OF THE RECTAL AMPULLA WITH RESTORATION OF CONTINUITY AND PRESERVATION OF THE RECTAL SPHINCTERS

The Kraske and Hochenegg methods of perineal or sacral resection of the rectum with preservation of the rectal sphincters are well known. Kraske (1885) described excision of a segment of the sacrum with resection of the rectum only, restoring continuity by circular suture. Hochenegg (1888) described two methods, known respectively as the "pull-through" and the "invagination" methods. The former has enjoyed the widest use in the hands of Hochenegg and his pupils as well as by others. The Küttner (1910) plan of sacral exteriorization already has been alluded to in the section on primary resection for rectosigmoidal lesions.

A rather general and increasing enthusiasm for the abdominoperineal method of operation for carcinoma of the rectum, together with pathologic studies, which suggests definitely a centripetal spread of lymphogenous metastases from rectal cancer, sometimes at a rather great distance from the local lesion—these factors have led to a general abandonment of the perineal or sacral methods of excision of cancer of the rec-

peritoneal cul-de-sac, and the adiposity of the patient. In lean patients with a deep peritoneal cul-de-sac and a large pelvis, resection for lesions at the rectosigmoid juncture may be easy and necessitate little mobilization of the rectum as contrasted with the adipose patient, especially if the peritoneal cul-de-sac is not deep. Interestingly enough, when patients who have had resections at this level are submitted to proctoscopy after operation, the suture line often is described as being at about the same distance from the anal opening as was the lower extent of the lesion initially, despite the excision of 2 to 3 cm., of normal appearing bowel below the lesion. Obviously, this seeming paradox can be explained only by *the surgeon's mobilization of the rectum at operation.**

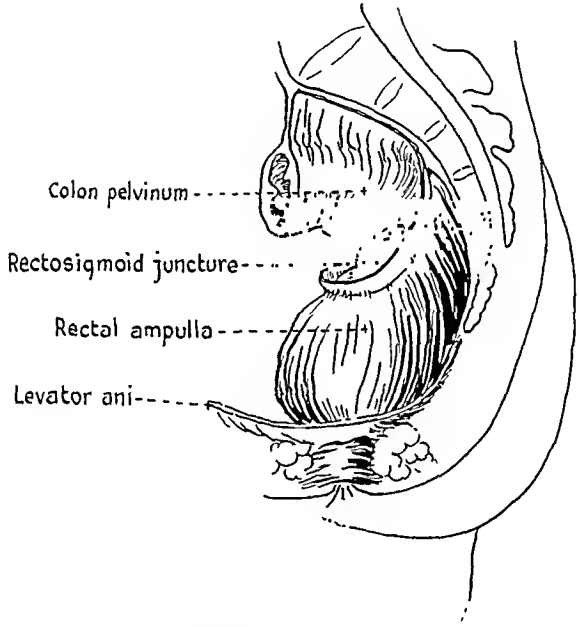

Fig. 7.—The rectum and colon pelvinum. The latter, once recognized as a part of the rectum, now is accepted generally as constituting a part of the pelvic colon. (Redrawn from Corning's Anatomy.)

It is unlikely that the resection rate will be as high for rectosigmoidal lesions as in the colon proper. I have not hesitated to perform partial colectomy in both the right and left colon in the presence of rather extensive hepatic metastases. In a similar circumstance, the lesion being at the rectosigmoidal juncture, the surgeon readily could justify to himself performance of the easier alternative operation of colostomy.

Concomitant Presence of Rectal Polyps With Lesion in Pelvic Colon or Rectosigmoid Contraindicates Resection.—It is perhaps not out of

*My colleague, Dr. William C. Bernstein, of the Division of Proctology, kindly checked the inferior limits of all lesions within the range of the proctoscope before operation and the site of the suture line after operation. This information is very helpful to the surgeon and affords him an opportunity of becoming better oriented in the anatomicosurgical aspects of the problem.

employment of the Hochenegg "pull-through" method; recovery of complete continence was observed in 36 per cent. Employing the Kraske suture method, Körbl states that primary healing occurred in 39 per cent (total of 34 cases) and eventual complete continence occurred in 66 per cent. Wilensky (1942) recently reported preservation of the sphincters in the abdominoperineal operation, a suggestion made several years ago by Kraske (1905) and practiced by Perthes (1927). Pannett (1943) records employing the same method.

The Abdomino-Anal Scheme of Operation Employing the Pull-Through or Suture Methods.—My own thought on the matter was to combine the advantages of the abdominal removal of the lymphatic

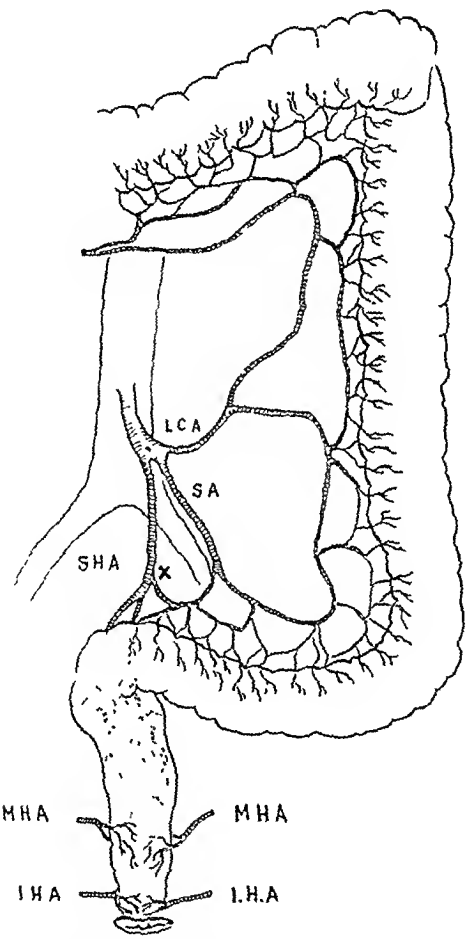

Fig. 9.—The blood supply of the left colon. In segmental resections of the pelvic colon and for lesions at the rectosigmoid Sudeck's critical point has no particular import. In such anastomoses, the residual portion of the rectum is nourished through the middle and inferior hemorrhoidal arteries (*M.H.A.* and *I.H.A.*). The superior hemorrhoidal artery (*S.H.A.*) is to be ligated above the point designated "X" (Sudeck's critical point). A high ligation and division of the superior hemorrhoidal artery permits mobilization of the colon and blood may reach the most distal end of the pelvic colon through the left colic (*L.C.A.*) and the sigmoid (*S.A.*) arteries.

tum, save on special indication. Even though the one-stage abdominoperineal operation appears to be a more formidable operation than colostomy followed by posterior excision, in practiced hands, the hazards of these procedures in standard-risk patients should be approximately the same. The gain in more complete excision of the lymph drainage area in the abdominoperineal operation definitely suggests it to be the better procedure.

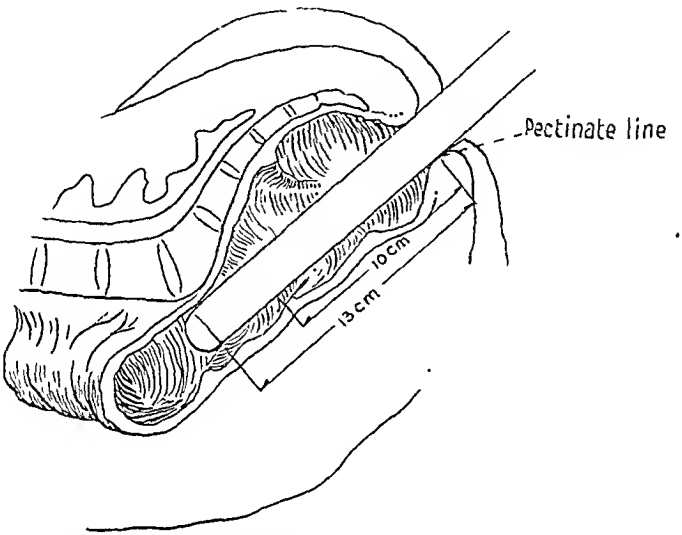

Fig. 8.—Arbitrary surgical definition of the region involved in rectosigmoidal resection. Ordinarily lesions seen throu[illegible] [illegible] [illegible] more than 13 cm. above the pectinate line can be resected with f[illegible] [illegible] lesions shown within the limits designated here. Lesions at less [illegible] [illegible] anus may be dealt with by methods described under *ampullary resection.*

Limitations of Resection Methods.—In addition to the shortcomings of the perineal or sacral methods of amputation of the rectum just described, when the rectum is resected by either of these routes with *preservation of the sphincters, the incidence of fistula formation is high,* no matter whether the methods of Hochenegg or Kraske are employed (see Fig. 11). A perusal of the papers of Körbl (1913) and Goldschmied (1914) and other pertinent literature suggests that the incidence of primary wound healing is not high by any of these methods. Rotter (1912) has devised a pedicled skin-flap procedure to deal with the item of fistula formation, following the Kraske circular suture method of rectal resection. Furthermore, even with preservation of the sphincters, the recovery of complete continence by either method has not been too promising. Mandl (1940), a pupil of Hochenegg and an ardent advocate of the pull-through method of Hochenegg, *states that* satisfactory ultimate continence is obtained in 50 per cent of instances by the Kraske circular suture method, and in 60 to 65 per cent by the Hochenegg method. Körbl (1913) of the Eiselsberg Clinic stated that primary healing occurred in only 20 per cent (total of 27 cases) with

Zealand, described a method very similar to that employed by me. Maunsell intended his operation for lesions of the rectal ampulla and lower pelvic colon. Through an abdominal incision, he divided the rectum below the lesion and pulled the upper segment with tumor attached through the lower rectal segment after excision of the lesion; anastomosis was effected between the segments. He remarked that "a tailor always pulls a sleeve inside out to sew it." In 1901, Weir described an almost identical procedure, with this difference, that the rectal segment containing the neoplasm was removed through the abdominal incision before the pelvic colon was pulled through the lower rectal segment. As in Maunsell's method, the anastomosis was described as being effected in the "cold outside." Weir reported 3 cases in which this type of operation was performed for carcinoma located in each instance at 4, 3½, and 2½ inches from the anus. Bergeret and Livory (1940) describe an abdomino-anal procedure for lesions of the rectosigmoid, employing the principle of the Hochenegg invagination scheme on the lower rectal segment.

The Experience of This Clinic With the Abdomino-Anal Method.—During the past year, seven abdomino-anal operations for carcinoma of the rectal ampulla have been done in this clinic.* There have been essentially two plans of operation. In both, the patient is placed on the operating table as shown in Fig. 8. Whereas, this position handicaps the surgeon a little in the abdominal dissection, it possesses this advantage, that the patient's position need not be changed for the final stages of the operation. My first plan was to dilate the rectal sphincter and to dissect up the normal rectal mucosa, just above the pectinate line, much in the manner of the Whitehead operation for hemorrhoids. This short mobilized tube of mucosa is then closed by suture and a gauze pack impregnated with 2 Gm. of sulfanilamide is left in the supra-anal muscular cylinder. Following a change of gown and gloves, excision of the carcinoma of the rectum is completed by the usual abdominal method. The preliminary Whitehead maneuver from below facilitates the abdominal dissection. Whereas, in primary resection for carcinoma of the rectosigmoid, Sudeck's (1907) critical point apparently has no great significance for the surgeon (Fig. 8) in this procedure, on the contrary, in which the pelvic colon is to be pulled down to or through the anal canal, the maintenance of viability to the very tip of the pelvic colon becomes a problem of real concern to the surgeon. Four patients have been operated upon by the abdomino-anal pull-through method. One of these, Mr. N. F., aged 45 years (Univ. Hosp. No. 723502), a large muscular man, died of pyelonephritis and oliguria 12 days after operation. The day following operation, the patient's external sphincter was di-

*It is a pleasant task to acknowledge here the enthusiastic help and encouragement I have received from my associate, Dr. Richard L. Varco, in carrying out the latter type of operative procedure.

drainage area, and eliminate the troublesome problem of perineal fistula by either (1) pulling the pelvic colon through the anal opening or (2) by suturing the pelvic colon to the rectal wall, at the lower level of resection.

A recent search of the literature discloses that these methods too have had their advocates. As long ago as 1892, Maunsell, a surgeon in New

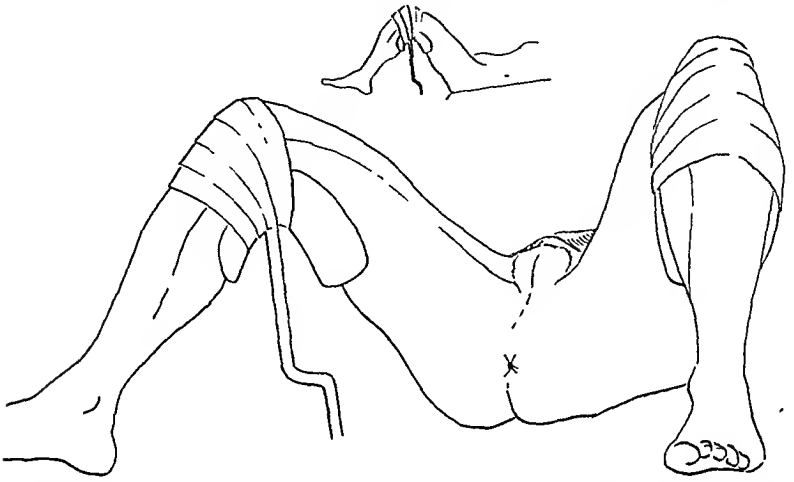

Fig. 10.—Position of the patient on the operating table; this position permits performance of the abdomino-anal operation of rectal resection for ampullary lesions without change of position. The elevated position of the knees handicaps the surgeon a little. It is possible that employment of sterile "pants" and adjustable stirrups with reference to height of elevation may facilitate the abdominal dissection.

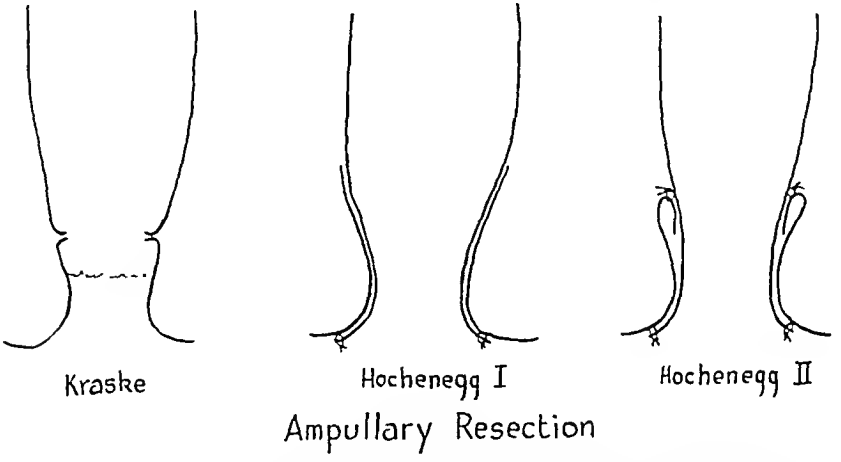

Fig. 11.—The ampullary resection methods of Kraske (1885) and Hochenegg (1888). These were carried out as sacroperineal one-stage resections. In the Kraske method, a circular suture was made. The Hochenegg I is [illegible] method, the procedure which has been used most widely. In the [illegible] the distal rectal wall is invaginated somewhat and the bowel [illegible] with placement of sutures.

One of the important shortcomings of all these operations lay in the complication of a perineal fistula. The same general methods of procedure have been carried out with the abdomino-anal methods described herein, omitting the sacroperineal dissection.

Zealand, described a method very similar to that employed by me. Maunsell intended his operation for lesions of the rectal ampulla and lower pelvic colon. Through an abdominal incision, he divided the rectum below the lesion and pulled the upper segment with tumor attached through the lower rectal segment after excision of the lesion; anastomosis was effected between the segments. He remarked that "a tailor always pulls a sleeve inside out to sew it." In 1901, Weir described an almost identical procedure, with this difference, that the rectal segment containing the neoplasm was removed through the abdominal incision before the pelvic colon was pulled through the lower rectal segment. As in Maunsell's method, the anastomosis was described as being effected in the "cold outside." Weir reported 3 cases in which this type of operation was performed for carcinoma located in each instance at 4, 3½, and 2½ inches from the anus. Bergeret and Livory (1940) describe an abdomino-anal procedure for lesions of the rectosigmoid, employing the principle of the Hochenegg invagination scheme on the lower rectal segment.

The Experience of This Clinic With the Abdomino-Anal Method.—During the past year, seven abdomino-anal operations for carcinoma of the rectal ampulla have been done in this clinic.* There have been essentially two plans of operation. In both, the patient is placed on the operating table as shown in Fig. 8. Whereas, this position handicaps the surgeon a little in the abdominal dissection, it possesses this advantage, that the patient's position need not be changed for the final stages of the operation. My first plan was to dilate the rectal sphincter and to dissect up the normal rectal mucosa, just above the pectinate line, much in the manner of the Whitehead operation for hemorrhoids. This short mobilized tube of mucosa is then closed by suture and a gauze pack impregnated with 2 Gm. of sulfanilamide is left in the supra-anal muscular cylinder. Following a change of gown and gloves, excision of the carcinoma of the rectum is completed by the usual abdominal method. The preliminary Whitehead maneuver from below facilitates the abdominal dissection. Whereas, in primary resection for carcinoma of the rectosigmoid, Sudeck's (1907) critical point apparently has no great significance for the surgeon (Fig. 8) in this procedure, on the contrary, in which the pelvic colon is to be pulled down to or through the anal canal, the maintenance of viability to the very tip of the pelvic colon becomes a problem of real concern to the surgeon. Four patients have been operated upon by the abdomino-anal pull-through method. One of these, Mr. N. F., aged 45 years (Univ. Hosp. No. 723502), a large muscular man, died of pyelonephritis and oliguria 12 days after operation. The day following operation, the patient's external sphincter was di-

*It is a pleasant task to acknowledge here the enthusiastic help and encouragement I have received from my associate, Dr. Richard L. Varco, in carrying out the latter type of operative procedure.

vided posteriorly because of gangrene of the segment protruding through the external sphincter.

The remaining three patients having the abdomino-anal procedure were operated upon in the following manner: in one, the preliminary Whitehead dissection was carried out, but following the abdominal dissection, excision of the neoplasm and mobilization of the pelvic colon, the operation was completed by suturing the pelvic colon to the remnants of the rectal wall just above the pectinate line. In the other two, the preliminary Whitehead maneuver was omitted, the removal of the carcinoma being effected from within the abdomen. In one of these, the operation was completed by the abdomino-anal pull-through maneuver; in the other, my associate, Clarence Dennis, sutured the pelvic colon to the lower level of rectal resection through a large Fansler proctoscope, while I completed the operation from within the abdomen.

I did a one-stage proctectomy and colectomy, pulling the ileum through the anal canal, for a patient of 16 years, Mr. C. E. (Univ. Hosp. No. 684951), with chronic ulcerative colitis involving the rectum. It was necessary to elongate the ileocolic artery, much in the manner with which one deals with the inferior mesenteric artery in the abdomino-anal pull-through maneuver for carcinoma of the rectal ampulla. The procedure was not a complete technical success, and a few weeks later the boy was readmitted, at which time ileostomy was performed. A well-functioning ileostomy or colostomy, obviously, is preferable to a perineal anus in which the sphincteric function is poor. Babcock (1932) is one of the few American surgeons who recommends a sacral anus to his patients in preference to a colostomy. I have had the privilege of talking with surgeons who have had personal experience with an abdominal colostomy and count it no great handicap in the ordinary activities of life.

Dissatisfaction With These Methods.—Primary healing did not occur in a single instance. It may prove that a preliminary colostomy should be done in these procedures to divert the fecal stream during the healing phase. Nevertheless, the ultimate recovery of something approximating normal continence in the majority of the patients operated upon suggests that efforts directed at preserving the rectal sphincters have some merit. I have been somewhat reluctant to perform complemental diversion of the fecal stream by colostomy, feeling that the continued maintenance of the normal channel for evacuation of the stool serves as a good prophylaxis against stricture formation. I have the impression that the suture method is superior to the pull-through maneuver; further, preservation of the entire thickness of the rectal wall in the lower segment is desirable. In other words, whereas, the preliminary Whitehead maneuver facilitates the abdominal dissection, this step in the procedure should be eliminated in the interest of preserving the lower rectal segment intact. In the Whitehead dissection, the submucosa apparently

is removed with the mucosa; there is also real hazard of inflicting injury upon the internal sphincter muscle.

All these factors suggest that the abdomino-anal suture method is the most effective way of dealing with carcinoma of the rectal ampulla, if one is to attempt preservation of the sphincters. The experience of this clinic with these methods has not been extensive enough to warrant any conclusions. These preliminary skirmishes with the problem are recorded here only to suggest that these initial trials indicate that a satisfactory technique of dealing with certain cases of ampullary carcinoma with full restoration of sphincteric function probably can be worked out.

Importance of internal sphincter: Whereas, this experience has been inadequate to enable formulation of the best plan of procedure in the preservation of normal continence, it has demonstrated to me the great importance of the internal sphincter in the maintenance of perfect control of gas and feces. One thinks ordinarily of the external sphincter as a strong muscle. It is, however, a voluntary muscle and subject to the fatigue of ordinary voluntary muscle. The internal sphincter, on the contrary, is a less dense sheet of muscle fibers, but being an involuntary muscle, it is not subject to the action of the will, nor does it exhibit the fatigue of voluntary muscle. A patient having had the Whitehead dissection, probably with trauma to the internal sphincter as a preliminary to one of the abdomino-anal operations described above, may find, when he attempts to walk from his bed to the toilet, early in convalescence, that his external sphincter tires, permitting the escape of gas or feces. This circumstance was particularly noticeable in the boy with ulcerative colitis, in whom the ileum was pulled through the external sphincter following proctectomy and colectomy.

Hospital stay: Two patients in this group left the hospital at 17 and 18 days after operation respectively. The average hospital stay for the 6 patients who survived operation was 26.3 days. Furthermore, whereas the patients with colonic and rectosigmoidal resections left the hospital with wounds healed and, usually, with complete restoration of normal intestinal function, the patients in whom the abdomino-anal resection was done for ampullary carcinoma had to endure a long healing period of several weeks beyond the long hospital stay. Nevertheless, it has been very reassuring to note the enthusiasm of these patients with reference to the item of salvage of the rectal sphincters and preservation of normal function. Further, it would appear that these patients also retain a normal sexual function as contrasted with patients having the usual abdominoperineal operation for carcinoma of the rectal ampulla.

SUMMARY

The experience of this clinic suggests that primary resection, employing the closed anastomosis, can be made with relative safety for car-

cinoma and other lesions anywhere in the colon as well as for rectosigmoidal carcinoma. Antecedent colostomy is necessary only in the presence of obstruction; complemental external decompressive vents are unnecessary. Among 60 resections performed for lesions of the colon and rectosigmoid juncture over a two-year period, there was one death, a mortality of 1.6 per cent. A high resection rate is compatible with a low mortality in colonic resections. A short hospital stay and healing period attend primary resection for lesions in the colon and rectosigmoid quite regularly. A convalescence without complication assures a low operative mortality and permits early dismissal from the hospital.

In addition, a preliminary report is made of the experience of this clinic with abdomino-anal methods of dealing with carcinoma of the rectal ampulla, preserving the rectal sphincters. Whereas, the healing period has been long in these patients, the ultimate return of function, approaching the normal, suggests that efforts directed at preserving the rectal sphincters are worth-while.

REFERENCES

I. Colon

1. Bloch, O.: Om extra-abdominal Behandling of cancer intestinalis (rectum derfra untaget) med en Fremstilling af de for denne sygdom foretagne operationer og deres Resultater, Nord. med. Ark. 2: 1, 1892.
2. Brunschwig, A.: The Surgery of Pancreatic Tumors, St. Louis, 1942, C. V. Mosby Company.
3. Bryant, T.: A Case of Excision of a Stricture of the Descending Colon Through an Incision Made for a Left Lumbar Colostomy: With Remarks, Proc. Roy. Soc. Med. 9: 149, 1882.
4. Campbell, O. J.: Surgery of the Carcinoma of the Colon, Minnesota Med. 23: 215, 1940.
5. Cheever, D.: The Choice of Operation in Carcinoma of the Colon, Ann. Surg. 94: 705, 1931.
6. Devine, H.: Operation on a Defunctioned Distal Colon, SURGERY 3: 165, 1938
7. Gibbon, J. H., Jr., and Hodge, C. C.: Aseptic Immediate Anastomosis Following Resection of the Colon for Carcinoma, SURGERY 59: 395, 1941.
8. Lahey, F. H.: Resection of the Right Colon and Anastomosis of the Ileum to the Transverse Colon After the Plan of Mikulicz, Surg., Gynec. & Obst. 54: 923, 1932.
9. Madden, S. C., and Whipple, G. H.: Plasma Proteins; Their Source, Production and Utilization, Physiol. Rev. 20: 191, 1940.
10. Parlavecchio, G.: Nuovo metodo per le enteroanastomosi nell' asse e laterali e per le gastro-e le colecisto enterostomi, Policlinico (sez., chir.) 5: 376 393, 429-437, 1898.
11. Parlavecchio, G.: Di Una utile Modificaszione all 'enterostomo, Clin. Chir. 8: 193, 1900.
12. Paul, F. T.: Colectomy, Brit. M. J. 1: 1139, 1895.
13. Paul, F. T.: Personal Experiences in the Surgery of the Large Bowel, Brit. M. J. 2: 172, 1912.
14. Raydin, I. S.: Hypoproteinemia and Its Relation to Surgical Problems, Ann. Surg. 112: 576, 1940.
15. Schoemaker, J.: Some Technical Points in Abdominal Surgery, Surg., Gynec. & Obst. 33: 591, 1921.
16. Schoemaker, J.: Operative Treatment of Obstruction Due to a Growth in the Descending Colon, Surg., Gynec. & Obst. 45: 359, 1927.
17. Stone, H. B., and McLanahan, S.: Resection and Immediate Anastomosis for Carcinoma of the Colon, J. A. M. A. 120: 1362, 1942
18. Sudeck, P.: Über die Gefässversorgung des Mastdarmes, in Hinsicht auf die Operative Gangran, München. med. Wchnschr. 54: 1311, 1907.

19. Varco, R. L.: Unpublished data, 1942.
20. Wangensteen, O. H.: Some of the Advantages of Closed Anastomosis in Gastro-Intestinal Resections, Proc. Inters. Postgrad. M. A. North America, Oct., 1941.
21. Wangensteen, O. H.: Intestinal Obstructions, Springfield, Ill., 1942, Charles C. Thomas, Publisher.
22. Wangensteen, O. H.: The Controlled Administration of Fluid to Surgical Patients; Including Description of Gravimetric Methods of Determining Status of Hydration and Blood Loss During Operation, Minnesota Med. 25: 783, 1942.
23. Wangensteen, O. H.: The Surgical Problem in Gastric Cancer; With Special Reference to (1) the Closed Method of Gastric Resection (2) Coincidental Hepatic Resection and (3) Pre and Postoperative Treatment, Arch. Surg. 46: 879, 1943.
24. Whipple, A. O.: The Use of the Miller Abbott Tube in the Surgery of the Large Bowel, SURGERY 8: 289, 1940.
25. Wilkie, D. P. D.: Surgery of Malignant Disease of the Colon, Edinburgh M. J. 46: 1, 1939.

II. Rectosigmoid

1. Arnold, H. R.: Resections of the Carcinomatous Rectosigmoid Juncture, With Establishment of Intestinal Continuity; Preliminary Report, Arch. Surg. 38: 1004, 1939.
2. Arnold, H. R., and Shea, J. F.: Resection of the Carcinomatous Rectosigmoid Juncture With Re establishment of Intestinal Continuity: Subsequent Report, Arch. Surg. 41: 110, 1940.
3. Balfour, D. C.: A Method of Anastomosis Between Sigmoid and Rectum, Ann. Surg 51: 239, 1910.
4. Balfour, D. C.: The Utility of the Rubber Tube in Intestinal Surgery, Surg., Gynec. & Obst. 31: 184, 1920.
5. Dixon, C. F.: Surgical Removal of Lesions Occurring in Sigmoid and Rectosigmoid, Am J. Surg. 46: 12, 1939.
6. Dixon, C. F.: Resection Without Permanent Colostomy for Carcinoma of the Rectosigmoid and Lower Portion of the Pelvic Colon, Treatment of Cancer and Allied Diseases, Vol. II, Edited by G. I. Pack and E. M. Livingston, New York, 1940, Paul B. Hoeber, Inc., p. 1414.
7. Dunphy, J. E.: Anterior Resection for Cancer of the Rectosigmoid, Arch. Surg. 43: 1076, 1940
8. Horsley, J. S.: Resection of the Rectosigmoid and Upper Rectum for Cancer With End to End Union, Surg., Gynec. & Obst. 64: 313, 1937.
9. Jones, T. E.: Complications of One Stage Abdominoperineal Resection of the Rectum, J. A. M. A. 120: 104, 1942
10. Lockhart Mummery, J. P.: A New Method of Restoring the Continuity of the Bowel in Cases of Excision of a Growth Low Down in the Sigmoid Flexure, Lancet 1: 1402, 1512, 1908.
11. Stone, H. B.: The Interposition of Small Bowel Segments Between Divided Ends of the Colon, Ann Surg. 86: 401, 1927
12. Stone, H. B.: Interposition of a Loop of Ileum to Repair Defects in the Colon, Ann. Surg. 88: 593, 1928.

III. Resection of Rectal Ampulla

1. Babcock, W. W.: The Operative Treatment of Carcinoma of the Rectosigmoid With Methods for the Elimination of Colostomy, Surg., Gynec. & Obst 55: 627, 1932
2. Bergeret, and Lavory: La resection rectosigmoidienne avec intubation colo rectale, J. de chir. 56: 209, 1940
3. Coller, F. A., Kay, E. B., and MacIntyre, R. S.: Regional Lymphatic Metastases of Carcinoma of the Rectum, SURGERY 8: 294, 1940.
4. Gilchrist, R. K., and David, V. C.: Lymphatic Spread of Carcinoma of the Rectum, Ann. Surg. 108: 621, 1938
5. Goldschmied, K.: Resultate der Radikalen Operationen des Mastdarmkrebsen bezuglich der Erhaltung der Kontinenz, Wien. klin. Wchnschr. 27: 412, 1914.
6. Hochenegg, J.: Die Sakrale Methode des Exstirpation von Darmkrebsen nach Prof. Kraske, Wien. klin Wchnschr. 1: 251, 1888 (article continued through weekly installments 11 to 16 inclusive).

cinoma and other lesions anywhere in the colon as well as for rectosigmoidal carcinoma. Antecedent colostomy is necessary only in the presence of obstruction; complemental external decompressive vents are unnecessary. Among 60 resections performed for lesions of the colon and rectosigmoid juncture over a two-year period, there was one death, a mortality of 1.6 per cent. A high resection rate is compatible with a low mortality in colonic resections. A short hospital stay and healing period attend primary resection for lesions in the colon and rectosigmoid quite regularly. A convalescence without complication assures a low operative mortality and permits early dismissal from the hospital.

In addition, a preliminary report is made of the experience of this clinic with abdomino-anal methods of dealing with carcinoma of the rectal ampulla, preserving the rectal sphincters. Whereas, the healing period has been long in these patients, the ultimate return of function, approaching the normal, suggests that efforts directed at preserving the rectal sphincters are worth-while.

REFERENCES

I. Colon

1. Bloch, O.: Om extra-abdominal Behandling of cancer intestinalis (rectum derfra untaget) med en Fremstilling af de for denne sygdom foretagne operationer og deres Resultater, Nord. med. Ark. 2: 1, 1892.
2. Brunschwig, A.: The Surgery of Pancreatic Tumors, St. Louis, 1942, C. V. Mosby Company.
3. Bryant, T.: A Case of Excision of a Stricture of the Descending Colon Through an Incision Made for a Left Lumbar Colostomy: With Remarks, Proc. Roy. Soc. Med. 9: 149, 1882.
4. Campbell, O. J.: Surgery of the Carcinoma of the Colon, Minnesota Med. 23: 215, 1940.
5. Cheever, D.: The Choice of Operation in Carcinoma of the Colon, Ann. Surg. 94: 705, 1931.
6. Devine, H.: Operation on a Defunctioned Distal Colon, SURGERY 3: 165, 1938
7. Gibbon, J. H., Jr., and Hodge, C. C.: Aseptic Immediate Anastomosis Following Resection of the Colon for Carcinoma, SURGERY 59: 395, 1941.
8. Lahey, F. H.: Resection of the Right Colon and Anastomosis of the Ileum to the Transverse Colon After the Plan of Mikulicz, Surg., Gynec. & Obst. 54: 923, 1932.
9. Madden, S. C., and Whipple, G. H.: Plasma Proteins; Their Source, Production and Utilization, Physiol. Rev. 20: 194, 1940.
10. Parlavecchio, G.: Nuovo metodo per le enteroanastomosi nell' asse e laterali e per le gastro-e le colecisto-enterostomi, Policlinico (sez., chir.) 5: 376-393, 429-437, 1898.
11. Parlavecchio, G.: Di Una utile Modificazione all 'enterostomo, Clin. Chir. 8: 193, 1900.
12. Paul, F. T.: Colectomy, Brit. M. J. 1: 1139, 1895.
13. Paul, F. T.: Personal Experiences in the Surgery of the Large Bowel, Brit. M. J. 2: 172, 1912.
14. Raydin, I. S.: Hypoproteinemia and Its Relation to Surgical Problems, Ann. Surg. 112: 576, 1940.
15. Schoemaker, J.: Some Technical Points in Abdominal Surgery, Surg., Gynec. & Obst. 33: 591, 1921.
16. Schoemaker, J.: Operative Treatment of Obstruction Due to a Growth in the Descending Colon, Surg., Gynec. & Obst. 45: 359, 1927.
17. Stone, H. B., and McLanahan, S.: Resection and Immediate Anastomosis for Carcinoma of the Colon, J. A. M. A. 120: 1362, 1942.
18. Sudeck, P.: Über die Gefässversorgung des Mastdarmes, in Hinsicht auf die Operative Gangran, München. med. Wchnschr. 51: 1314, 1907.

Editorial

Cancer of the Colon

ALTHOUGH great advances have been made in the treatment of disease generally, there are probably few conditions in which more has been accomplished regarding an increase in the operability and decrease in the mortality and morbidity than in lesions of the colon. This marked improvement is due to many factors, and no one technique can be credited with the results obtained today as contrasted with those obtained a decade ago, although one is likely to believe that the improvement in results which he has had is due to a particular form of therapy. Unquestionably, any one of the many factors which have been employed generally in the past decade would have resulted in an increase in the operability and a decrease in the mortality, but the combination of all of these factors is probably responsible for the results which are obtained at the present time.

Until relatively recently little attention was paid to a patient's preoperative nutrition. The importance of the maintenance of the protein balance was not appreciated until the detrimental effect of hypoproteinemia on the healing of wounds was demonstrated. Also, little was known about the essential role played by vitamin C in the healing of wounds. In ulcerative lesions of the colon as elsewhere, a vitamin C deficiency is likely to be present and unless corrected preoperatively and postoperatively, interference with the deposition of collagen results. The disregard of the frequently present hypoproteinemia and vitamin C deficiency in patients with colonic lesions was undoubtedly responsible for the relatively high incidence of leakage of the anastomotic site with resulting peritonitis which so frequently ended fatally following resection and anastomosis of the bowel. Adequate preparation of the patient generally and the preparation of the bowel locally has done a great deal to decrease the mortality rate in bowel surgery. Whereas those less familiar with the results obtained in bowel surgery are likely to credit the introduction of the sulfonamides with the improvement which has been obtained, it is undoubtedly the consensus of those with considerable experience in treating these cases that, although sulfonamides have been of value in decreasing morbidity and mortality, they are responsible for a relatively small part of the improvement of results. One cannot deny the beneficial effects of sulfonamides, and one should not decry their use. On the other hand, the results as reported by Wangensteen, who does not use sulfonamides either before

7. Hochenegg, J.: Beiträge zur Chirurgie des Rectum und der Beckenorgane, Wien. klin. Wchnschr. 2: 515, 1889 (continued article Numbers 26-30 inclusive).
8. Hochenegg, J.: Zur Therapie des Rectum Carcinoms, Wien. klin. Wchnschr. 10: 729, 1897.
9. Körbl, H.: Die Continenz Verhältnisse nach dem radicalen Operationen des Mastdarmkrebses, Arch. f. klin. Chir. 101: 499, 1913.
10. Kraske, P.: Zur Exstirpation hochsitzenden Mastdarmkrebse, Verhandl. d. deutsch. Gesellsch. f. Chir. 14: 464, 1885.
11. Kraske, P.: Erfahrungen über den Mastdarmkrebs, Samml. klin. Vortr. 1897. Chirurgie Numbers 52 and 53, page 771.
12. Kraske, P.: Die Erhaltung des Schlieszmuskels bei der Exstirpation des Mastdarmkrebse und seine spätere Funktion, Deutsche med. Wchnschr. 31: 1098, 1905.
13. Kraske, P.: Über die weitere Entwickelung der Operation Hochsitzende Mastdarmkrebse, Arch. f. klin. Chir. 80: 634, 1906.
14. Küttner, H.: Die Sakrale Vorlagerungsmethode beim Hochsitzenden Rectum Carcinom, Deutsche med. Wchnschr. 36: 606, 1910.
15. Küttner, H.: Zur Technik meinen sakralen Vorlagerungsmethode beim hochsitzenden Rektum Carzinom, Zentralbl. f. Chir. 43: 905, 1916.
16. Küttner, H.: Bericht über 800 Rektum Carzinome, München. med. Wchnschr. 67: 799, 1920.
17. Mandl, F.: Maintenance of Continence in Operations for Carcinoma of the Rectum, J. Internat. Coll. Surgeons 3: 11, 1940.
18. Maunsell, H. W.: A New Method of Excising the Two Upper Portions of the Rectum and the Lower Segment of the Sigmoid Flexure of the Colon, Lancet 2: 473, 1892.
18a. Pennett, C. A.: Carcinoma of the Rectum (Excision With Preservation of the Sphincters), M. Press 209: 244, 1943.
19. Perthes, G.: Abdominosakrale Operation hochsitzenden Rektumcarzinome mit Erhaltung des Schlieszmuskels, Arch. f. klin. Chir. 148: 605, 1927.
20. Rotter, J.: Die Wiedherstellung der Continenz nach der Excisio recti carzinomatosi, Arch. f. klin. Chir. 98: 38, 1912.
21. Weir, R. F.: An Improved Method of Treating High-Seated Cancers of the Rectum, J. A. M. A. 37: 801, 1901.
22. Westhues, H.: Über die Entstehung und Vermeidung des lokalen Rectum-Carcinom-Residiv, Arch. f. klin. Chir. 161: 582, 1930.
23. Westhues, H.: Im Kampfe um die Prophylaxe des Rectum Carcinoms, Arch. f. klin. Chir. 178: 408, 1934.
24. Wood, W. Q., and Wilkie, D. P. D.: Carcinoma of the Rectum. An Anatomico-Pathological Study, Edinburgh M. J. 40: 321, 1933.
25. Wilensky, A. O.: Retention of the Sphincter in the Radical Operation for Carcinoma of the Rectum and Rectosigmoid, New York State J. Med. 42: 1151, 1942.

Coller and their associates, in which it was shown that although glandular metastases from rectosigmoidal carcinomas are extensive, they are generally in the upward direction. This permits the use of resection of the low-lying sigmoidal lesion with the re-establishment of the continuity of the bowel and the presentation of the normal sphincteric apparatus. It is in this type of procedure that a proximal defunctionating colostomy or a carefully performed aseptic anastomosis is imperative. It will be of interest to observe these cases for longer periods of time to see if there is any evidence of recurrence in the distal segment. The investigations of Coller and David suggest that these will not occur.

Although defunctionating colostomies are being done less frequently and undoubtedly with considerable justification in the larger clinics in which considerable experience has been gained, undoubtedly in the hands of men doing an occasional colonic resection they are valuable procedures. A large adherent mass in the sigmoid which appears inoperable becomes movable and much smaller following the production of a defunctionating colostomy as described by Devine. In such an instance, wide resection of the colonic mass together with the adjacent adherent parietes, with an end-to-end anastomosis, permits a cure which would otherwise be impossible. Even though resection has been so extensive that tension of the anastomotic line might result, one need not fear the results because if an insufficiency of the suture line occurs, the re-establishment of the continuity of the bowel by crushing the spur at the colostomy can be delayed until the suture has healed completely. This may take weeks or months, but the delay is of no importance aside from the fact that the patient has the inconvenience of a colostomy.

In a consideration of surgery of the colon, one must not forget the valuable procedure of obstructive resection, originally suggested by Rankin. In many lesions this is undoubtedly the best procedure available in that it eliminates adequately the malignant process and does so in a safe and efficient manner Convalescence is not prolonged, and the end results are good.

Undoubtedly the use of the Miller-Abbott tube has done a great deal to obviate the necessity of a proximal enterostomy or colostomy. Certainly it is undesirable in a given case for tension to be applied to a recently anastomotic suture line, particularly if there has been any history of obstruction before. It is imperative, obviously, to relieve the obstruction in some way, either by preliminary use of the Miller-Abbott tube or a preliminary decompressive procedure on the bowel. With few exceptions, patients prefer the former procedure. On the other hand, there are some patients who cannot tolerate prolonged use of the tube which is necessary during the early postoperative period.

—*Alton Ochsner, M.D.*
New Orleans, La.

or after operation, only implanting a small amount of sulfathiazole about the anastomosis, it is obvious that good results can be obtained without the use of the "sulfa cure-alls." Also, it must be stressed, as repeatedly emphasized by Allen, that "although we believe that the proper use of sulfa drugs will prove helpful in dealing with colon surgery, we cannot overemphasize the caution that is to be looked upon only as an aid and is not to permit the slightest breakdown in the proven surgical principles heretofore established." Never will the use of sulfonamides supplant clean surgery.

Unquestionably, the use of aseptic methods of anastomosis has done much to improve the results and to decrease the morbidity. With the decreased incidence of contamination, the incidence of localized and generalized peritonitis becomes obviously lessened. These procedures alone undoubtedly have made possible the discontinuation of stage operations in many clinics. An aseptic anastomosis is technically more difficult to perform than open anastomosis and will be used more frequently by the more experienced surgeons than by the occasional operators. Probably this is another reason why better results are obtained with this type of anastomosis than with the open anastomosis, because, as has been emphasized by Allen, the segregation of these cases in clinics where techniques can be developed to handle them properly from every angle will undoubtedly result in a decrease in mortality and morbidity. Therefore, credit which has been given the aseptic anastomoses for lowering the mortality rate is probably due in part to the other measures which are used in these cases and not due entirely to absence of contamination.

The controversy concerning the use of one-stage and multiple-stage procedures still exists. One cannot be dogmatic in conclusions concerning which type of procedure should be used in a given case. Unquestionably, by improving the patient's condition preoperatively and by the use of aseptic anastomosis, it is possible to perform safely one-stage procedures which were not feasible before. The obvious advantage of the one-stage procedure is that the patient is subjected to a single procedure, and the convalescence is greatly shortened. On the other hand, one cannot help but be convinced by the experience at the Massachusetts General Hospital, where all of the previously mentioned measures are employed and where surgery is at its best, that there are many cases in which two-stage procedures are indicated and desirable. Obviously, in a given institution, as emphasized by Jones, the procedure to be used should be that which has been found most satisfactory in that particular clinic, but in the hands of the novice or occasional operator, unquestionably multiple-stage procedures are safer and will give better results than a single-stage procedure.

The increasing interest in more conservative procedures in the treatment of low sigmoidal lesions is of importance. The fact that these procedures are justified is based upon the investigations of David and

developing gonad by migrating cranially along the dorsal mesentery (Politzer, 1928). But this method of formation has been denied by Stieve (1927), who maintains that the germ cells are derived exclusively from the mesothelium.*

Primary sex cords are formed either by invagination of the mesothelium (Simkins, 1928) or by differentiation from the gonadal blastema (Gruenwald, 1942).

Upon observing the gonads of young embryos, males may be identified by the presence of the developing tunica albuginea. By the 20-mm. stage (seven weeks), the primary sex cords begin to become separated from the overlying mesothelium due to the formation of a tunica albuginea. Separation is complete in 25-mm. embryos. Surprisingly, and rather frequently, secondary sex cords may be observed between the mesothelium and the tunica albuginea (Gruenwald, 1934, 1942); in this respect, the development of the testis simulates slightly that of the ovary. Possibly this formation of secondary sex cords is related to the occurrence of ovotestes in some cases of hermaphroditism.

Seminiferous tubules develop from the solid primary sex cords and acquire inconspicuous lumina (pseudolumina) in 90- to 358-mm. fetuses (Wilson, 1926).

The interstitial cells of the testis have been identified in a 43-mm. embryo (Kitahara, 1923). Apparently they develop "from the original gonad blastema either by way of gonadic cords or from the mesenchymal stroma of the organ" (Gruenwald, 1942). Stieve (1927) reports that they arise from mesenchyme.

Rete cords, considered originally to have developed from the epithelium of mesonephric corpuscles (Winiwarter, 1910), have, more recently, been derived from undifferentiated cells of mesothelial origin (Wilson, 1926; Gruenwald, 1942). These primordia of the rete testis have been recognized in a 15.2-mm. embryo. By the 90-mm. stage, the cords exhibit small lumina.

Developmental union of the seminiferous tubules with the vasa efferentia, according to Wilson, is accomplished before birth, in some cases as early as the fourth prenatal month.

2. *Prenatal Positions of the Testis.*—The maximum extent of the germinal ridge, the primordium of the testis (and ovary), is from the sixth thoracic (cranially, fifth week) to the second sacral segments (caudally, third month) (Felix, 1912). Even by the end of the second month, the gonad is an elongated body which extends from the diaphragm to the site of the future abdominal inguinal ring (Fig. 1). Its cranial portion partially covers the suprarenal gland and its caudal pole is attached indirectly by means of the gubernaculum to the abdominal wall. It lies in front of the metanephros.

*Many authors including Stieve employ the term "germinal epithelium," but in view of the facts given it has seemed preferable to use Minot's general term, mesothelium.

Recent Advances in Surgery

CONDUCTED BY ALFRED BLALOCK, M.D.

DESCENT OF THE TESTIS: ANATOMICAL AND HORMONAL CONSIDERATIONS*

L. J. WELLS, PH.D., MINNEAPOLIS, MINN.
(From the Department of Anatomy, University of Minnesota)

DESCENT of the testis into the scrotum occurs either during the prenatal period or near the time of puberty. Although the general aspects of the process are well known, the forces of descent have not been adequately explained.

Numerous developmental factors have been suggested. Several of these, discussed by Eberth (1904), are the following: (1) pressure upon the testicle by such developing viscera as the liver and the intestine, (2) shortening of the gubernaculum by contraction of its smooth muscle and by retrogressive shrinkage, (3) contraction of skeletal muscle of the inguinal cone, (4) accumulation of meconium in the large bowel (see Fig. 7), (5) caudal shifting of the gubernaculum due to changes in the developing bony pelvis, and (6) upward growth of the body over the testis.

Two hormonal factors have been proposed. One involves prenatal action of chorionic gonadotropin (Engle, 1932b). The other concerns scrotal stimulation by estrogen during pregnancy (Wislocki, 1933).

The purpose of this communication is to consider the main features of testicular descent and to interpret them in the light of recent observations.

ANATOMICAL CONSIDERATIONS

1. *Early Development of the Testis.*—The testis develops from mesothelium (celomic epithelium) which is situated medial to the mesonephros. The primordium of the testis, a thickening of the mesothelium, is apparent for the first time in 5- to 7-mm. embryos (Willier, 1939). Soon, thereafter, it loses its basal membrane and contributes cells to the gonadal blastema (Gruenwald, 1942). This subepithelial layer is apparently identical with the so-called "epithelial nucleus" derived by Felix (1912) from previously existing mesenchyme. Following studies on lower vertebrates, it was said that the primordial germ cells originate in the wall of the yolk sac (Fuss, 1912) and that they invade the

*Aided by funds from the Graduate School of the University of Minnesota.

developing gonad by migrating cranially along the dorsal mesentery (Politzer, 1928). But this method of formation has been denied by Stieve (1927), who maintains that the germ cells are derived exclusively from the mesothelium.*

Primary sex cords are formed either by invagination of the mesothelium (Simkins, 1928) or by differentiation from the gonadal blastema (Gruenwald, 1942).

Upon observing the gonads of young embryos, males may be identified by the presence of the developing tunica albuginea. By the 20-mm. stage (seven weeks), the primary sex cords begin to become separated from the overlying mesothelium due to the formation of a tunica albuginea. Separation is complete in 25-mm. embryos. Surprisingly, and rather frequently, secondary sex cords may be observed between the mesothelium and the tunica albuginea (Gruenwald, 1934, 1942); in this respect, the development of the testis simulates slightly that of the ovary. Possibly this formation of secondary sex cords is related to the occurrence of ovotestes in some cases of hermaphroditism.

Seminiferous tubules develop from the solid primary sex cords and acquire inconspicuous lumina (pseudolumina) in 90- to 358-mm. fetuses (Wilson, 1926).

The interstitial cells of the testis have been identified in a 43-mm. embryo (Kitahara, 1923). Apparently they develop "from the original gonad blastema either by way of gonadic cords or from the mesenchymal stroma of the organ" (Gruenwald, 1942). Stieve (1927) reports that they arise from mesenchyme.

Rete cords, considered originally to have developed from the epithelium of mesonephric corpuscles (Winiwarter, 1910), have, more recently, been derived from undifferentiated cells of mesothelial origin (Wilson, 1926; Gruenwald, 1942). These primordia of the rete testis have been recognized in a 15.2-mm. embryo. By the 90-mm. stage, the cords exhibit small lumina.

Developmental union of the seminiferous tubules with the vasa efferentia, according to Wilson, is accomplished before birth, in some cases as early as the fourth prenatal month.

2. *Prenatal Positions of the Testis.*—The maximum extent of the germinal ridge, the primordium of the testis (and ovary), is from the sixth thoracic (cranially, fifth week) to the second sacral segments (caudally, third month) (Felix, 1912). Even by the end of the second month, the gonad is an elongated body which extends from the diaphragm to the site of the future abdominal inguinal ring (Fig. 1). Its cranial portion partially covers the suprarenal gland and its caudal pole is attached indirectly by means of the gubernaculum to the abdominal wall. It lies in front of the metanephros.

*Many authors including Stieve employ the term "germinal epithelium," but in view of the facts given it has seemed preferable to use Minot's general term, mesothelium.

In the second month, a relative decrease in the length of the testis is observable. This is accompanied by relative and absolute increases in transverse dimensions. By the third month the change in proportions is striking (Fig. 2). One even receives the impression that the testis has descended (see Figs. 1 and 2). But this is an apparent rather than a real descent, since Felix (1912) has pointed out that the cranial portion of the testis undergoes developmental involution.

Fig. 1.—Dissection of a human embryo approximately 8 weeks of age (crown-rump, 22.5 mm.). Anterior abdominal wa[illegible] loop of intestine removed. *1*, Gonad [illegible] (precursor of ligamentum teres uter[illegible] [illegible] 3), *3*, Wolffian duct; *4*, Müllerian duc[illegible] sory ligament (primordium of suspensory ligament of [illegible] *7*, pleural cavity; *8*, suprarenal gland; *9*, stomach; *10*, duodenum, *11*, vitelline vein; *12*, cranial limb of primary intestinal loop (jejunal portion); *13*, caudal limb of intestinal loop (colic portion); *14*, colon; *15*, bladder, *16*, phallus. (×9.)

From the fourth to the seventh month, the testis lies in the iliac fossa at or near the internal ring (Fig. 3). In fresh fetuses (Fig. 4) it is very mobile and it enters the ring in response to slight manual pressure. Perhaps this mobility explains the different testicular levels encountered in preserved specimens of similar age (varying degrees of shrinkage during preservation influencing the level) and such questionable observations as those of Klaatsch (1890), namely that during

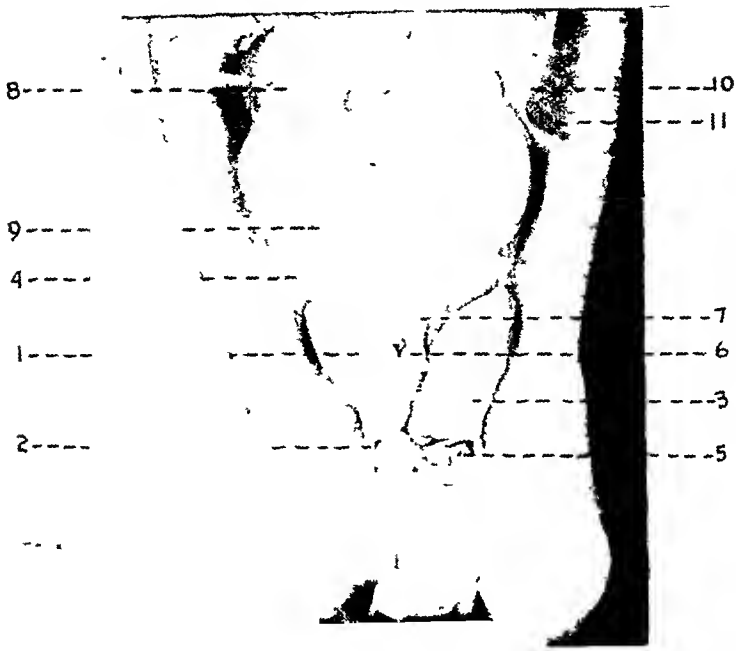

Fig 2—Dissection of a human embryo approximately 11 weeks of age (crown-rump 43 mm) Anterior abdominal wall liver, and most of the gut have been removed, while the peritoneum covering the remaining organs is intact *1*, Testis, *2*, gubernaculum *3* Wolffian duct (primordium of the epididymis and ductus deferens) situated in the ephros the Mullerian duct is not visible *4*, diaphragmatic (homologue of the suspensory ligament of the ovary) *5* to the bladder, most of which has been removed *6* severed stump of colon *7*, mesocolon *8*, suprarenal gland *9*, kidney (metanephros) *10* diaphragm *11*, pleural cavity (×6 3)

Fig 3—Dissection of a human fetus almost four lunar months of age (crown-rump 107 mm) *1*, Testes *2* epididymis *3*, peritoneum *4*, urachus (bladder above umbilical arteries on each side) *5* rectus abdominis muscle (inferior epigastric vessels above) *6*, ureter *7* sigmoid colon (×3)

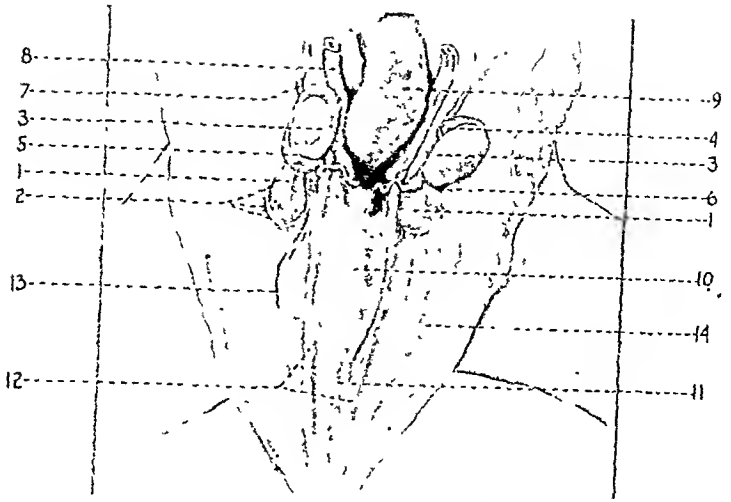

Fig. 4.—A drawing illustrating the relation of the gubernaculum to the vaginal process and to the testis in a fresh human fetus five lunar months of age (crown-rump, 167 mm., crown-heel, 242 mm.). All layers of the abdominal wall were cut beginning at the umbilicus and ending at levels near the right and left inguinal ligaments. The flap thus produced was pulled downward, thereby exposing the peritoneum. *1*, Right and left gubernacula; *2*, shallow vaginal process; *3*, testes (right testis rotated to expose epididymis); *4*, left epididymis (head); *5*, right epididymis (tail); *6*, ductus deferens; *7*, internal spermatic vessels; *8*, ureter; *9*, rectum; *10*, bladder, *11*, urachus; *12*, umbilical arteries; *13*, inferior epigastric vessels; *14*, peritoneum. (×1.4) (Drawn by Mr. Herbert Hunter from a photograph of the fresh specimen).



Fig. 5.—Dissection of a human fetus, seven lunar months of age (crown-rump, 26 cm., crown-heel, 36 cm.) Body sectioned at upper lumbar level. Much of anterior abdominal wall removed. *1*, Left testis at abdominal inguinal ring; *2*, epididymis (head); *3*, right abdominal inguinal ring (normally open); *4*, ductus deferens; *5*, bladder (part of fundus removed; umbilical arteries on its sides); *6*, sigmoid colon; *7*, ascending colon; *8*, inferior vena cava; *9*, kidney; *10*, ureter. Note that in this specimen the right testis has descended before the left (the reverse of the usual order.) (×1.26.)

the fourth month there occurs a temporary recession of the testis to a higher level and an invagination of the inguinal cone.

The lingering of the testis near the abdominal inguinal ring is a conspicuous, impressive phenomenon. Undoubtedly, the passage of the testis through this ring is relatively rapid.

Actual descent into the inguinal bursa (Figs. 5, 6, and 7) begins approximately at the seventh month (Bramann, 1884). The testis usually reaches its final position in the scrotum during the eighth prenatal month.

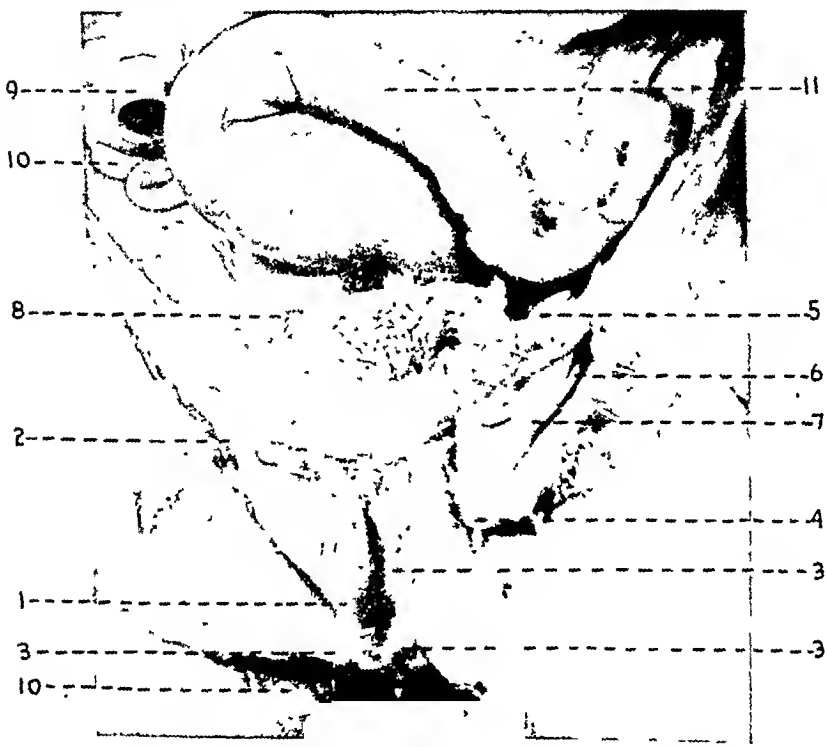

Fig 6—Same specimen as that in Fig. 5, with skin of anterior abdominal wall and scrotum reflected in order to expose the two inguinal bursae. *1*, Right inguinal bursa (wall incised and sutured), observe bursa's distinct inferior margin; *2*, developing subcutaneous inguinal ring, *3*, dartos tunic, *4*, left inguinal bursa (opened by single incision which was extended upward through subcutaneous inguinal ring and all layers of abdominal wall, medial flap of bursa and abdominal wall anchored by sutures through bladder, lateral flap to skin of thigh); *5*, left testis *6*, epididymis (tail) *7* gubernaculum, *8*, umbilical artery lateral to bladder, *9*, ileum (severed near ileo-cecal junction), *10*, vermiform process, *11*, sigmoid colon (×1 03)

3. *The Gubernaculum Testis* (gemito-inguinal ligament).—Discovery of the human gubernaculum has been attributed by Eberth (1904) to Albrecht von Haller (1749), the great anatomist and physiologist. He called it a "vagina cylindrica"* and described it as coursing from the embryonic testis down through the abdominal wall to the inguinal region.

*Upon examining Haller's *Icones anatomicae* (1743-1749), the term "vagina cylindrica" was not found A few pages are missing from the original volume belonging to the University of Minnesota Dr Shirley P Miller, my colleague in the Department of Anatomy, has generously assisted in the search by examining his personal volume He likewise failed to find this term

John Hunter (1786) applied to the structure its familiar name and described it in part as follows (see also Figs. 8 and 9):

> At this time of life the testis is connected in a very peculiar manner with the parieties of the abdomen, at that place where in adult bodies the spermatic vessels pass out, and likewise with the scrotum. This connection is by means of a substance which runs down from the lower end of

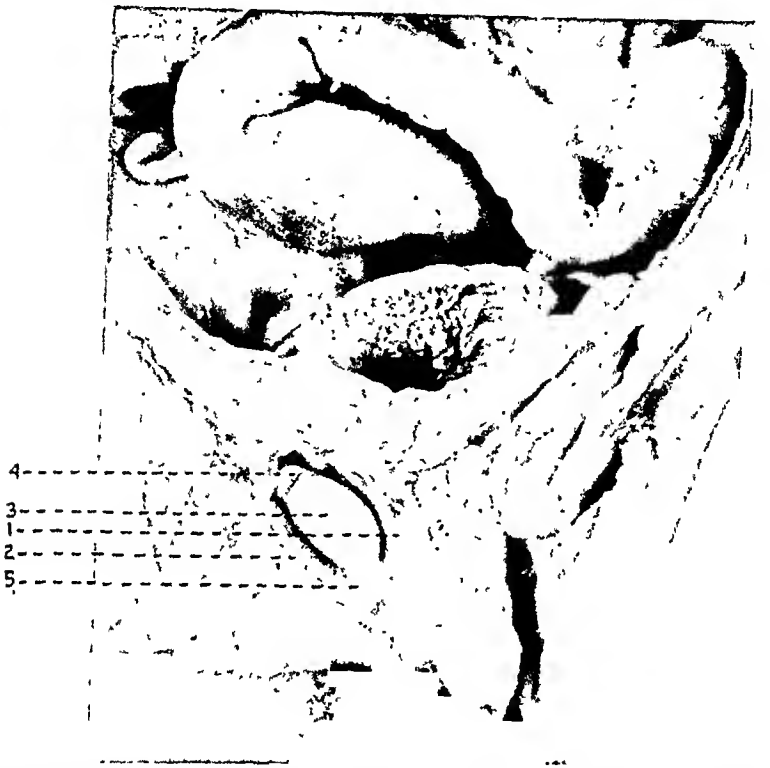

Fig. 7.—Same specimen as that in Figs. 5 and 6. The interior of the right inguinal bursa has been exposed by excising the anterior wall of the bursa. *1*, Bursa, medial wall, *2*, bursa, lateral wall, *3*, testis; *4*, epididymis, head (body and tail lie behind the testis); *5*, gubernaculum (×1.15.)

the testis to the scrotum, and which at present I shall call the ligament, or gubernaculum testis, because it connects the testis with the scrotum, and directs its course in its descent. It is of a pyramidal form; its large bulbous head is upwards and fixed to the lower end of the testis and epididymis, and its lower and slender extremity is lost in the cellular membrane of the scrotum. The upper part of this ligament is within the abdomen, before the psoas, reaching from the testis to the groin, or to where the spermatic vessels begin to pass through the muscles. Here the ligament runs down into the scrotum precicely in the same manner as the spermatic vessels pass down in adult bodies, and is there lost. The lower part of the round ligament of the uterus in a foetus very much resembles this ligament of the testis; and may be plainly traced down into the labium, where it is imperceptibly lost. That part of the ligamentum testis, which is within the abdomen, is covered by the peritonaeum all round, except at its posterior part, which is contiguous to the psoas, and

connected with it by the reflected peritonaeum, and by the cellular membrane. It is hard to say what the structure or composition of this ligament may be. It is certainly vascular and fibrous, and the fibers run in the direction of the ligament itself. It is covered by the fibers of the cremaster or musculus testis which is placed immediately behind the peritonaeum; this is not easily ascertained in the human subject, but it is very evident in other animals, more especially in those whose testicles remain in the cavity of the abdomen after the animal is full grown.

Fig. 8.—A photograph of one of John Hunter's original plates. (See Fig. 9.)

Early development: According to Moszkowicz (1935) the gubernaculum may be detected first in a 13.5-mm. embryo. He describes it as a ridge or fold which connects the Wolffian duct portion of the mesonephros with the abdominal wall and which lies directly in front of the umbilical artery. He considers it to be composed of moderately condensed mesenchyme that is covered with peritoneum. His observations caused him to deny the existence of two components, the "inguinal fold" and the "inguinal crest," which were said by Felix

(1912) to fuse end to end. He maintains that the cord is a single structure from the time of its first appearance.

In older specimens, the gubernaculum shifts to a position lateral to the umbilical artery and resembles a cord (Fig. 2). Since it is present before the abdominal muscles originate, the latter develop around it but in such a way that the transverse and the internal oblique layers

Fig. 9.—John Hunter's outline sketch accompanying his plate (see Fig. 8). *A*, "The upper part of the object, covered with a cloth". *B*, thighs. *C*, penis. *D*, scrotum. *E*, 'The flap of the integuments, abdominal muscles and peritonaeum, turned back over the right os ilium to bring the testis into view'. *F*, skin and tela subcutanea. *G*, 'The flap of the abdominal muscles and of the peritonaeum of the left side turned back over the spine of the os ilium. The lower part of this flap is cut away, in order to shew the ligament of the testis passing down through the ring into the scrotum". *H*, kidneys. *I*, "—projection formed by the lower vertebrae lumborum—". *K*, 'The rectum filled with meconium—'. *L*, inferior mesenteric artery. *M*, superior hemorrhoidal artery. *N*, bladder. *O*, umbilical arteries. *P*, ureters. *Q*, internal spermatic arteries. *R*, testes. *S*, vasa deferentia. *T*, 'What I have called the gubernacula or ligaments of the testes in a fetus. On the left side this ligament is entire so that it is seen going down from the lower end of the testis through the ring of the muscle, into the scrotum but on the right side its upper and forepart is cut away, and the continuity of the epididymis and the vas deferens may be seen, and no more of the ligament is exhibited than what is situated within the cavity of the abdomen."

of the abdominal wall are interrupted by the gubernaculum, while the external oblique layer is not (Bramann, 1884). (See Figs. 13 and 14.)

Microscopic structure: Smooth muscle and connective tissue are said to be present in the gubernaculum (Frankl, 1900). However, Forssner (1928) finds no muscle and observes progressive transformation of the

gubernaculum into mucoid tissue; he says, "The usual description of descensus, that a central core of connective tissue and unstriped muscle, chorda gubernaculi, is formed in the inguinal ligament, growing down to the bottom of the scrotum and by contractions pulling the testicle down, is not founded on facts and ought to be regarded as a pure invention." It should be pointed out that Forssner's histological material was stained either by van Gieson's method, one which should assist in identifying smooth muscle and connective tissue, or with hematoxylin and eosin. Likewise, Moszkowicz (1935) notes a "loosening" of the tissue in that portion of the gubernaculum which lies at the level of the abdominal muscles (pars intermuscularis).

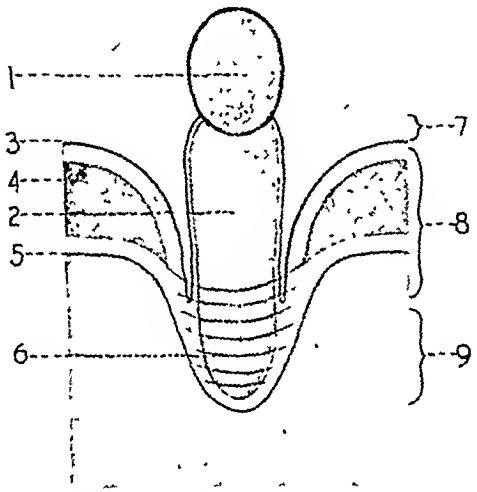

Fig. 10.—Diagram illustrating the relation of the testis to the gubernaculum and to the vaginal process previous to testicular descent. *1*, testis, *2*, gubernaculum; *3*, peritoneum, *4*, transverse and internal oblique layer [illegible] wall; *5*, external oblique layer, *6*, cremasteric layer, *7*, pars [illegible] gubernaculum, *8*, pars vaginalis, *9*, pars infravaginalis (see te[illegible] after Frankl.)

Parts: Frankl (1900) has listed three parts of the gubernaculum which are useful for dealing with anatomical aspects of testicular descent (Figs. 10, 11, and 12). Pars abdominalis extends from the cranial insertion of the gubernaculum on the epididymis to the abdominal opening of the vaginal process. Pars vaginalis stops caudally at the inferior end of the vaginal process. Pars infravaginalis terminates inferiorly between the internal oblique and the external oblique layers of the abdominal wall.

The second and third parts mentioned above have been considered as a single part and called either pars intermuscularis (Felix, 1912) or pars interstitialis (Moszkowicz, 1935).

The mesorchium and the "pars serotalis of the chorda gubernaculi" will be considered in the following paragraphs.

(1912) to fuse end to end. He maintains that the cord is a single structure from the time of its first appearance.

In older specimens, the gubernaculum shifts to a position lateral to the umbilical artery and resembles a cord (Fig. 2). Since it is present before the abdominal muscles originate, the latter develop around it but in such a way that the transverse and the internal oblique layers

Fig. 9.—John Hunter's outline sketch accompanying his plate (see Fig. 8). *A*, "The upper part of the object, covered with a cloth"; *B*, thighs; *C*, penis; *D*, scrotum; *E*, "The flap of the integuments, abdominal muscles and peritonaeum, turned back over the right os ilium to bring the testis into view"; *F*, skin and tela subcutanea; *G*, "The flap of the abdominal muscles and of the peritonaeum of the left side turned back over the spine of the os ilium. The lower part of this flap is cut away, in order to shew the ligament of the testis passing down through the ring into the scrotum"; *H*, kidneys; *I*, "—projection formed by the lower vertebrae lumborum—"; *K*, "The rectum filled with meconium—"; *L*, inferior mesenteric artery; *M*, superior hemorrhoidal artery; *N*, bladder; *O*, umbilical arteries; *P*, ureters; *Q*, internal spermatic arteries; *R*, testes; *S*, vasa deferentia; *T*, "What I have called the gubernacula or ligaments of the testes in a fetus. On the left side this ligament is entire, so that it is seen going down from the lower end of the testis, through the ring of the muscle, into the scrotum but on the right side its upper and forepart is cut away, and the continuity of the epididymis and the vas deferens may be seen; and no more of the ligament is exhibited than what is situated within the cavity of the abdomen."

of the abdominal wall are interrupted by the gubernaculum, while the external oblique layer is not (Bramann, 1884). (See Figs. 13 and 14.)

Microscopic structure: Smooth muscle and connective tissue are said to be present in the gubernaculum (Frankl, 1900). However, Forssner (1928) finds no muscle and observes progressive transformation of the

Extent: There is general agreement that in the fetus the gubernaculum extends at least from the epididymis to the external oblique layer of the abdominal wall, i.e., to that portion of this layer which becomes definitely the external spermatic fascia. Also, it is agreed that the testis is attached indirectly to the gubernaculum by means of the mesorchium. The latter, frequently called the ligamentum testis, is a structure affording direct connection between the testis and the epididymis.

However, extension of the gubernaculum into the scrotum, as advocated by Hunter, is questionable. In dissections of fresh and of preserved fetuses, it has not been possible to identify gubernacular tissue inferior to the distal end of the external spermatic fascia in which respect the present observations confirm those of Bramann (1884), Klaatsch (1890), Frankl (1900), and Forssner (1928). Yet, perhaps, its existence should not be denied until more detailed investigations have been made.

Favoring the presence of a pars scrotalis of the gubernaculum are such investigators as Lockwood (1888), Moszkowicz (1935) and Felix (1912). The former maintains that distinct bands of "muscular fibers of the gubernaculum" are attached as follows: (1) to the pubis, (2) to the scrotum, (3) to the root of the penis, (4) to the perineum, and (5) to Scarpa's triangle. Although his evidence fails to convince one of the existence of muscular bands, he believed that such bands are related to various ectopic positions of the testis. The second investigator describes a "pars subcutanea" of the gubernaculum. This structure apparently represents subcutaneous connective tissue and perhaps should be considered as such rather than as part of the gubernaculum, since in fetuses larger than 43 mm. inadequate evidence is presented for the occurrence of an aperture in the external oblique layer through which the so-called "pars subcutanea" is continuous with the gubernaculum. The third investigator diagrams a "pars scrotalis" in a 26.5-mm. embryo which he considers to be the caudal segment of a "chorda gubernaculi."

In young embryos of the Minnesota collection a cellular condensation inferior to the external oblique layer can be demonstrated in serially sectioned specimens. But it remains questionable whether in older fetuses this condensation becomes a recognizable part of the gubernaculum.

Eventually, if it can be established definitely that the gubernaculum terminates superior to the external oblique layer instead of in the scrotum, it may be desirable to replace Hunter's term, "gubernaculum," with Waldeyer's term (1899), "genito-inguinal ligament."

Variations in size: While no extensive series of measurements of the gubernaculum have come to the writer's attention, gross inspection would lead one to infer that all dimensions of the gubernaculum in-

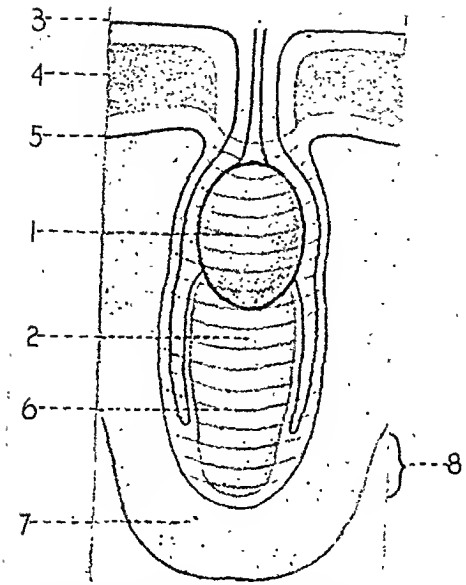

Fig. 11.—Diagram showing relations after testis enters the inguinal bursa (8-month fetus). Deeper vaginal process and shorter gubernaculum, *1*, testis; *2*, gubernaculum; *3*, peritoneum; *4*, transverse and internal oblique layers; *5*, external oblique layer; *6*, cremasteric layer; *7*, scrotum; *8*, pars infravaginalis. (From Eberth, after Frankl.)

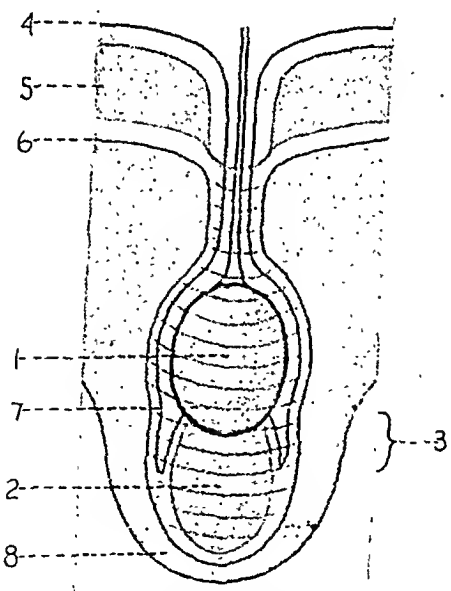

Fig. 12.—Diagram of a later stage than that shown in Fig. 11. Note the *shorter* pars vaginal and the *funicular* shape of the inguinal bursa. *1*, testis; *2*, [illegible] vaginalis; *3*, peritoneum; *5*, transverse and internal oblique layers; *6*, external oblique layer; *7*, *cremasteric layer*; *8*, *scrotum*. (From Eberth, after Frankl.)

the bursa: the external spermatic fascia (intercolumnar fascia), the middle spermatic fascia (cremasteric muscle and fascia), the internal spermatic fascia (infundibuliform fascia or tunica vaginalis communis), and the peritoneum (tunica vaginalis proprius).

Origin of the vaginal process: This evolution of the peritoneum, discovered by Camper (according to Effler, 1935), originates at a time when there are no external manifestations of a bursa (Fig. 13). It represents an inferolateral portion of the coelom which appears grossly to have been pushed out by the gubernaculum testis.

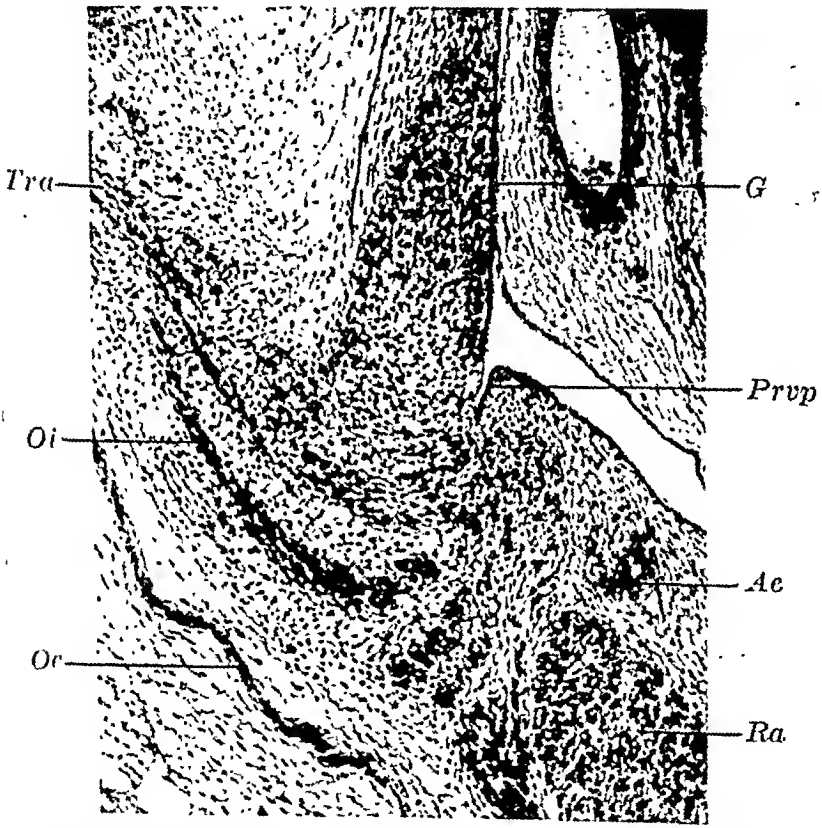

Fig. 13.—Transverse section through the abdominal wall of a 36.3-mm. human embryo, to illustrate the origin of the processus vaginalis peritonei (*Prvp*) and its relation to the gubernaculum (*G*) and the layers of the abdominal wall. The large vessel (upper right) is the umbilical artery. *Ae*, inferior epigastric artery; *Oe*, external oblique layer, *Oi*, internal oblique layer; *Ra*, rectus abdominis muscle; *Tra*, transverse abdominal layer. (×89.) (From Moszkowicz, 1935.)

The factors involved in its formation have not been adequately determined. Among several interpretations two are chosen to illustrate the complexity of the problem. Felix (1912) maintains that the shifting of the umbilical artery from a horizontal to a vertical plane is the chief factor. After this shifting, which results from growth of the anterior abdominal wall, the artery and its peritoneal covering provide

crease progressively until the seventh month (Figs. 2, 4, and 6).* Immediately preceding descent of the testis, i.e., at the beginning of the seventh month (Klaatsch, 1890), the diameter of the gubernaculum equals or exceeds the combined diameters of the testis and the epididymis (Forssner, 1928; Moszkowicz, 1935).

During the process of testicular descent, the gubernaculum becomes shorter and shorter but not wider (see Figs. 10, 11, and 12). According to Eberth (1904), respective lengths and diameters at various prenatal ages are as follows: second month, 1.0 by 0.5 mm.; beginning of seventh month, 12.0 by 3.0 to 8.0 mm.; end of seventh month, 6.0 by 2.0 mm.; after seventh month (when descent is almost completed), 3.5 by 2.0 mm. In the preserved specimens shown in Figs. 2, 4, and 6, the measurements were, respectively, 0.4 by 0.2 mm. (left) and 0.3 by 0.2 mm. (right); 5.1 by 2.3 mm. (left) and 5.0 by 2.5 mm. (right); 16.6 by 4.8 mm. (left) and 2.9 by 5.1 mm. (right).

Generally at birth the gubernaculum is small and inconspicuous; in adult subjects vestiges of it, if recognizable, are indistinct.

4. *Origin of the Scrotum.*—There is disagreement concerning this. As reported by Felix (1912), the scrotum is derived from an unpaired scrotal area which is situated between the anus and the base of the penis; and the labioscrotal swellings (paired genital swellings) disappear by contributing to the skin and its underlying layers at the base of the penis. This is contrary to an older view which maintains that the scrotum originates from the paired labioscrotal swellings. This older view has received new support from such recent investigators as Spaulding (1921) and Saunders, Rusk, Lowenstein, and Silverberg (1942). The former states that these swellings become distinguishable at the 19-mm. stage, that at first they lie lateral to the developing phallus, then migrate caudally and finally fuse to produce right and left halves of the scrotum. According to the latter investigators and to Moszkowicz (1935), the primordia of the scrotum lie originally in front of the penis.

Anomalous dislocations of the phallus (Francis, 1940; Meyer, 1941; Saunders, Rusk, Lowenstein, and Silverberg, 1942) support the view that the scrotum originates rostrally to the penis.

5. *Development and Fate of the Inguinal Bursa.*—The name for this fetal sac was introduced by Klaatsch (1890). In males the proximal portion of the sac becomes the spermatic cord of the adult and the distal portion, the part in which the peritoneum is retained, the spermatic sac.† Precursors of the following definitive layers compose the wall of

*See addendum.

†This is a term coined by Dr. Edward A. Boyden in his teaching of medical students to designate that part of the bursa which contains the testis. It is used for two purposes: (1) as a con[illegible] cord" and (2) to emphasize the fact that as outpocke[illegible] the spermatic sacs are to be considered in a different [illegible] and embryologically) from the scrotal sacs which are [illegible] d tela subcutanea. In fact, the two sacs can be easily [illegible] on, being only loosely connected by areolar tissue.

(1890) describes and illustrates the cone as a prominent structure which, in human fetuses as in rodents, first pushes upward and then is retracted downward. But this is not confirmed by Frankl (1900), who reports the cone to be rudimentary in man (Fig. 14).

Evagination of the abdominal wall: Previous to testicular descent, the abdominal wall becomes evaginated to produce the inguinal bursa. The general features of this process are illustrated admirably in a paper by Bramann (1890).



Fig. 13. [illegible] of a section of a 41-mm. human embryo, showing the [illegible] al process in transverse section. Note that dorsally (up [illegible] is not surrounded by peritoneum of the vaginal process. [illegible] tery and vein; *G*, gubernaculum; *Oc*, external oblique layer; *Oi*, internal oblique layer; *Prvp*, processus vaginalis peritonei; *Ra*, rectus abdominis muscle; *Tra*, transverse abdominal layer. (×89.) (Moszkowicz, 1935.)

It is said that even by the fourth month the external oblique layer is slightly evaginated and that by the fifth month the apex of this layer reaches the upper part of the scrotum (Frankl, 1900). However, in the specimens available to the writer, no evagination was observed before the sixth lunar month.

In the formation of a bursa, the gubernaculum and the vaginal process become longer with the result that their caudal ends lie nearer the scrotum. They carry with them the fibromuscular layers of the abdominal wall, since these layers are fused to the rudimentary inguinal cone. Some anatomists think that the gubernaculum and the vaginal process pass through an aperture which already exists in the abdominal wall. But, if the external oblique layer lacks an aperture (Bramann, 1890; Frankl, 1900), it must be everted either by the pars infravaginalis of the gubernaculum or, perhaps more precisely, by the

an incomplete partition between the vaginal process and the embryonic pelvis. Moszkowicz (1935), on the other hand, believes that the vaginal process originates in response to an active muscular contraction within the inguinal cone, this contraction stretching the peritoneum via the gubernaculum. His interpretation is a modification of one previously published by Klaatsch (1890).

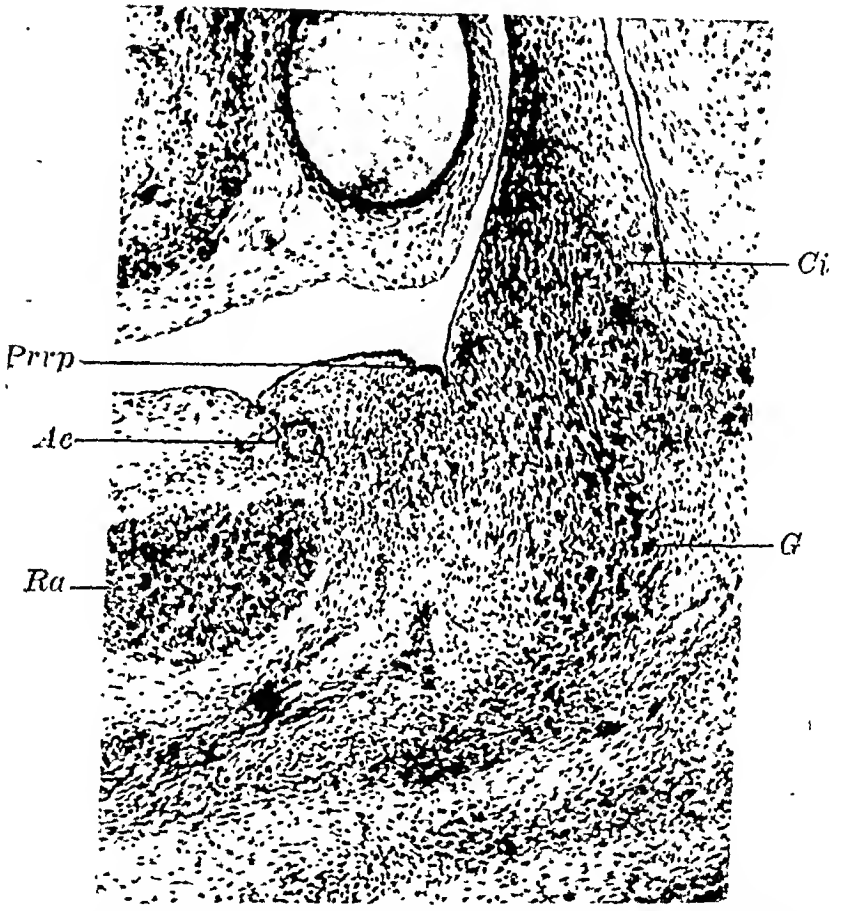

Fig. 14.—Transverse section through the abdominal wall of a 43-mm. human embryo. On the right (below legend *Ci*), the transverse and the internal oblique layers blend with the gubernaculum to form the inguinal cone. *Ac*, Inferior epigastric artery; *Ci*, inguinal cone, *G*, gubernaculum, *Ra*, rectus abdominis muscle. (×89.) (Moszkowicz, 1935.)

Until the fifth fetal month, the vaginal process is a small structure, being approximately 1 mm. in length (Frankl, 1900). Except dorsally, it surrounds the pars vaginalis of the gubernaculum (Figs. 4, 10, 13, and 15).

The inguinal cone: This cone is formed when the gubernaculum is invaded by skeletal muscle from the transverse and internal oblique layers of the abdominal wall (Frankl, 1900; Moszkowicz, 1935). Klaatsch

porary postnatal recession in the size of the testis. A definite answer cannot be given; yet the available data (Table I, last vertical column)* suggest that the weight of the testes decreases slightly during the first three postnatal months. Reasons for refraining from an affirmative

TABLE I

SUMMARY OF DATA ON THE WEIGHT OF THE TESTES IN THE PRENATAL AND POSTNATAL PERIODS*

DATA OF CASTALDI AND VANNUCCI (1926) TOTAL N = CA. 100†			DATA OF ROESSLE AND ROULET (1932) TOTAL N = 775			COLLATED DATA TOTAL N = 1734‡		
AGE INTERVAL	N	TESTES WEIGHT (GM.)	AGE INTERVAL	N	TESTES WEIGHT (GM.)	AGE INTERVAL (LUNAR MONTHS)	N	TESTES WEIGHT (GM.)
The Prenatal Period								
----------	---	----	----------	---	----	3 to 4	3	0.01
----------	---	----	----------	---	----	4 to 5	7	0.10
----------	---	----	----------	---	----	5 to 6	5	0.10
----------	---	----	----------	---	----	6 to 7	16	0.16
----------	---	----	----------	---	----	7 to 8	7	0.28
----------	---	----	----------	---	----	8 to 9	19	0.37
----------	---	----	----------	---	----	9 to 10	18	0.53
----------	---	----	----------	---	----	Postmature	15	0.79
The Postnatal Period								
Birth	---	0.30	Birth	15	1.41	Birth	122	0.91
Birth to 5 mo.§	---	0.71	Birth to 6 mo.§	21	1.56	Birth to 3 mo.§	6	0.74
3 to 6 mo.	---	1.21	6 mo. to 1.5 yr.	19	1.95	3 to 6 mo.	15	1.01
						6 to 12 mo.	11	1.19
1 to 2 yr.	---	1.93	1.5 to 2.5 yr.	4	1.98	1 to 2 yr.	16	1.30
2 to 5 yr.	---	1.53	2.5 to 6.5 yr.	12	2.86	2 to 4 yr.	33	2.29
						4 to 6 yr.	7	2.33
5 to 10 yr.	---	1.82	6.5 to 12 yr.	12	2.90	6 to 8 yr.	23	3.24
						8 to 10 yr.	23	1.65
10 to 15 yr.	---	7.17	12 to 18 yr.	15	20.55	10 to 12 yr.	13	2.00
			18 to 19 yr.	15	27.70	12 to 15 yr.	18	6.89
15 to 20 yr.	---	28.38	19 to 20 yr.	35	30.70	15 to 20 yr.	66	27.61
20 to 30 yr.	---	28.28	20 to 30 yr.	314	33.28	20 to 30 yr.	859	34.18
30 to 40 yr.	---	27.17	30 to 40 yr.	169	37.70	30 to 40 yr.	198	36.25
40 to 50 yr.	---	27.05	40 to 50 yr.	113	36.56	40 to 50 yr.	129	25.25
----------	---	----	50 to 60 yr.	36	33.84	50 to 60 yr.	44	32.50
----------	---	----	20 to 60 yr.	632	35.08	20 to 60 yr.	1280	34.53
----------	---	----	60 yr. and over	14	35.43	60 yr. and over	18	34.52

*Collated from 16 sets of data published by other observers [4, 6, 7, 13, 37, 57, 65, 73, 82, 96, 103, 105, 128, 131, 132, 135], and from unpublished observations of H. Mackeen, D. C. Mebane, and R. E. Scammon. Observations from printed sources included only after critical examination of the original publications. Total N = ca. 1900.

Postmature is defined as stillborn newborn infants, or infants dying in the first 48 hours after birth, having a body length CH of 52 cm. or over and/or a (dead) body weight of 3600 Gm. or over. *Birth* is defined as stillborn newborn infants, or infants dying in the first 48 hours after birth, having a body length CH of 48 to 52 cm. and/or a (dead) body weight of 2500 to 3600 Gm. *Age* in the prenatal period is calculated from empirical formula[3] of Scammon and Calkins (1923).

†No N's indicated in the publication of Castaldi and Vannucci (1926), but internal evidence indicates that there were over 100 observations in this series.

‡The N's and means of the several sets of collated data for birth and from 18 years forward include the values given by Roessle and Roulet (1932).

§Calendar months.

*I wish to express my indebtedness to Dr. Richard E. Scammon for the privilege of using four tables from his forthcoming book, *Human Growth and Structural Development*, Vol. III, The Commonwealth Fund, New York.

rudimentary inguinal cone (Figs. 10 and 14). In any event, the external oblique layer is the fetal precursor of the external spermatic fascia.

The orifice of the bursa: In order for the testis to descend, the orifice of the inguinal bursa must be large enough to admit the testis and its associated structures. As though "anticipating" testicular descent, the orifice becomes sufficiently large. Some authors state that this is caused in part by an increase in the diameter of the gubernaculum (Forssner, 1928; Moszkowicz, 1935) rather than by an expansion of the inguinal cone (Klaatsch, 1890). Frankl (1900), even while maintaining that the cone is rudimentary, believes that it increases the diameter of the vaginal process.

Fate of the bursa: After the testis descends, the bursa's superior part becomes funicular and later forms the spermatic cord. Its inferior part persists as the spermatic sac.

The funicular portion of the vaginal process becomes obliterated after birth, nearly always during the first postnatal year; thus, the communication is lost between the vaginal process and the peritoneal cavity. From the data of other investigators (Sachs, 1887; Engel, 1857), Scammon (1923) has concluded that more than 80 per cent of the cases between the tenth and twentieth postnatal days show partial or complete obliteration. Usually the obliterative changes are completed earliest on the left side of the body. The regression is said to begin at two points, namely, near the abdominal inguinal ring and near the superior margin of the testis (Lockwood, 1888). However, in a larger number of specimens (Engel, 1857; Sachs, 1887; Frankl, 1895) it has been observed to begin in the middle third of the funicular portion and to advance rapidly upward and downward from this level. Final disappearance of the funicular portion is accomplished by the formation of granulation tissue (Pellacani, 1884).

6. *Growth of the Testis.*—The ponderal growth of the testis in the fetal period is similar to that of the body as a whole (Wald and Scammon, 1932). But the relative weight of the testis, in comparison with body weight, becomes reduced during this interval from 0.143 per cent at the third lunar month to 0.023 per cent at birth. Since the experimental induction of testicular descent is associated with an increase in the size of the testes (see Hormonal Considerations), it is reasonable to suppose that in man normal prenatal descent is influenced by rapid testicular growth, especially during the seventh lunar month. However, concerning this point, the data are insufficient to warrant a positive conclusion; at the end of the seventh month and in fetuses having similar body weights, the weights of the testes range from less than 0.2 to approximately 0.6 Gm. (Wald and Scammon, Fig. 1).

The question should be raised as to whether the interruption of the supply of placental and/or maternal hormones at birth causes a tem-

period, even including the years of senility. This correlates with the absence of distinct climacteric manifestations in most senile men.

From birth to maturity, the increase in the weight of the testes (about thirty-seven fold) is relatively almost twice as great as that of the body (about twenty fold) and most of its parts. Apparently this style of growth is limited to the reproductive organs and their auxiliary structures (Scammon, 1930).

7. *Histologic Considerations.*—

The testis: Seminiferous tubules, at birth, measure 60 to 80 micra in diameter (Table IV); they exhibit many undifferentiated cells and few spermatogonia (Spangaro, 1902; Mita, 1914). Until the time of approaching puberty, they lack real lumina (Cooper, 1929). The tubules contain no spermatocytes during the tenth year, several spermatocytes during the eleventh year, spermatids by the thirteenth year, and spermatozoa as early as the fourteenth year (Mott, 1919; Cooper, 1929). Frequently spermatozoa are present after the seventh decade of life (Engle, 1939). Large numbers of spermatozoa have been reported in a man 94 years of age (Seymour, Duffy, and Koerner, 1935).

TABLE IV

DIAMETER OF THE CONTORTED (SEMINIFEROUS) TUBULES AT SEVERAL AGE PERIODS*

AGE PERIOD	DIAMETER (μ)
Shortly after birth	60 to 80
Before puberty	110 to 120
At the close of puberty	140 to 170
During maturity	180 to 220
At senility	200 to 260

*Data of Spangaro, 1902.

The interstitial cells of the testis are numerous during the fourth and fifth fetal months. A decline in the amount of interstitial tissue has been reported to occur between the fifth month and birth (Felix, 1912); but Mita (1914) maintains that this is apparent, rather than actual, because tubular tissue is acquiring greater quantitative predominance. In a child 4 months of age, the interstitial cells are said to be fewer and smaller than at the time of birth (Mott, 1919).

Rasmussen (1932) has written an extensive account of the interstitial cells. They present an epithelioid appearance and a polygonal shape. They occur singly or in irregular groups. Their cytoplasm contains near its periphery such lipids as phospholipin, glycolypin, cholesterol and its esters, and probably neutral fats. Centrally the cytoplasm exhibits secretion-like granules. These are most conspicuous in normal hypertrophic cells.

The scrotum: The wall of this structure consists of skin, cutaneous appendages, smooth muscle, and connective tissue. Fat is scarce or absent, while sweat glands are abundant. The epidermis is thin.

answer include the following: (1) there are relatively few observations during these months, (2) the average weight of the testes during this period (0.74 Gm.), although less than at birth (0.91 Gm.), is almost identical with that of "postmature" newborn infants (0.79 Gm.) and (3) it is uncertain whether in this period some of the data involve premature infants.

During postnatal life, three phases of testicular growth have been recognized (Scammon, 1930). In the first phase, extending through infancy, the testis shows a distinct increase in size. In the second phase, extending approximately from the latter part of the first to the end of the tenth years, the testis grows relatively little. The third phase extends into the third decade. During all except the latter part of this phase, the testis exhibits rapid growth (Tables I to III). Testicular growth during the circumpuberal period is stimulated undoubtedly by hypophysial gonadotropic hormones. It is an interesting fact that the weight of the testis is rather uniform during the adult

TABLE II

DIMENSIONS OF THE TESTES IN THE POSTNATAL PERIOD*

AGE INTERVAL	N	DIMENSIONS (MEANS OF RIGHT AND LEFT TESTES)		
		LENGTH (MM.)	BREADTH (MM.)	THICKNESS (MM.)
Birth	19	11.0	6.6	5.5
Birth to 3 mo.	23	12.9	7.3	5.6
3 to 6 mo.	15	14.5	8.0	6.0
6 to 12 mo.	9	14.9	8.9	7.2
1 to 2 yr.	11	15.2	9.1	8.2
2 to 5 yr.	14	15.6	7.9	7.3
5 to 10 yr.	20	16.0	9.7	9.0
10 to 12 yr.	10	18.0	11.2	9.2
12 to 15 yr.	12	27.7	16.1	14.6
15 to 20 yr.	13	39.0	31.5	20.0
Maturity (20 to 60 yr.)	40	42.0	38.0	25.0

*Based on the data of Sappey, 1876, Vvedenski, 1900, and Mita, 1911. Observations included only after critical examination of the original publication. Total N = 186.

TABLE III

DIMENSIONS OF THE TESTES IN THE LIVING IN THE POSTNATAL PERIOD*

AGE INTERVAL	N	RIGHT TESTIS		LEFT TESTIS	
		LENGTH (MM.)	BREADTH (MM.)	LENGTH (MM.)	BREADTH (MM.)
Birth to 3 mo.	24	16	8	16	8
3 to 6 mo.	17	17	8	16	8
6 to 12 mo.	30	16	8	16	8
1 to 5 yr.	56	16	8	17	8
5 to 10 yr.	52	17	9	17	8
10 to 11 yr.	11	17	9	17	9
11 to 12 yr.	8	19	9	20	10
12 to 13 yr.	7	23	12	23	12
13 to 14 yr.	6	28	14	28	14
14 to 15 yr.	6	28	14	29	15
15 to 16 yr.	4	35	20	36	20

*From the data of Reich, 1924. Total N = 221.

2. *The Effects of Injecting Gonadotropins.*—

Descent of the testis: This has been induced in prepuberal monkeys* by injecting either hypophyseal or chorionic gonadotropin (Engle, 1932b; Aberle and Jenkins, 1934), and in adult hypophysectomized monkeys by injecting the latter hormone (Smith, 1938).

Many investigators have observed the effects of gonadotropins on the testes of immature rats. Generally they have not mentioned whether precocious descent occurred. This is readily understandable because in normal immature rats the position of the testes is so variable that the identification of precocious descent is difficult; upon handling normal immature rats, the testes move freely upward and downward. But it has been noted frequently that in animals receiving gonadotropins, the scrota are larger than those of controls.

Descent has been obtained in ground squirrels by injecting either hypophyseal, urinary hypophyseal, or chorionic ganodatropin (see beyond). These wild rodents are favorable animals for such observations because in them complete descent does not occur normally until eight or more months after birth.

There is bountiful literature concerning the clinical induction of descent by means of gonadotropins. Since this literature has been reviewed in December, 1942 (Pullen, Wilson, Hamblen and Cuyler), only brief comments seem to be desirable. From the earlier papers, Engle (1936) noted that chorionic gonadotropin had been reported to cause the descent of "undescended testes" in 119 of 172 cases. Undoubtedly, this high percentage (69.1 per cent) is due to many inaccurate diagnoses previous to therapy.† Thompson and Heckel (1939a), excluding from their data the patients with "migratory"‡ testes, reported fewer positive responses (about 20 per cent). Orchidopexies were performed on eleven patients whose testes failed to descend. In each of these patients, anatomical barriers to descent were observed during the operation. Thompson and Heckel believe that perhaps gonadotropins cause descent only in those individuals whose testes would descend, without treatment, near the time of puberty.

Testis as a whole: The testes of experimental animals respond to gonadotropins by growing. Although variable in different animals receiving identical amounts of hormone, testicular growth tends to vary directly with the quantity of hormone which is given. Thus, in monkeys receiving hypophyseal or chorionic gonadotropin, weights of the testes were doubled (Engle, 1932a). In rats injected with chorionic gonadotropin (Moore, 1936) and in ground squirrels injected with urinary hypophyseal gonadotropin (Wells and Overholser, 1938),

*According to Engle, normal closure of the abdominal inguinal ring had occurred before injections were begun. Subsequently, however, Wislocki (1933) reported that in juvenile monkeys this ring frequently is open.

†Methods for making better diagnoses are outlined by Thompson and Heckel (1939a) and by Hamilton (1941).

‡"Migratory" testes are defined by these investigators as those "which move back and forth readily from the canal to the scrotum."

According to Eberth (1904), two layers of smooth muscle are pres The outer layer, consisting of circular fibers and belonging to the derm is the thinner. It extends across the raphe. The inner layer contai longitudinal and oblique fibers; it constitutes the greater part of t subcutaneous layer and is known as the dartos tunic; from right an left sides, some of its fibers are reflected to form the scrotal septu which separates the scrotum into paired scrotal sacs. The dartos tunic is attached to the spermatic sacs by means of loose connective tissue which is called the intermediate stratum and which represents the non-dartos portion of the subcutaneous tissue.

HORMONAL CONSIDERATIONS

1. *Gonadotropins.*—The gonadotropins are hormones which stimulate the testes (and the ovaries). Those occurring in the anterior hypophysis are called hypophyseal* gonadotropins. Pioneer investigations concerning them were made by Smith (1927) and by Smith and Engle (1927).

The gonadotropic hormones (gonadotropins) are thought to be produced by the hypophysis: the gametogenic hormone (thylakentrin or follicle-stimulating hormone) and the interstitial cell-stimulating hormone (metakentrin or luteinizing hormone). Reviews of this subject have been written by Fevold (1939) and by Engle and Levin (1941). The latter authors point out the reasons why the existence of two hypophyseal gonadotropins is difficult to prove. The gametogenic hormone is reported to stimulate the seminiferous tubules and to have no effect upon the interstitial cells (Greep, Fevold and Hisaw, 1936; Greep, van Dyke and Chow, 1942). But the interstitial cell-stimulating hormone stimulates not only interstitial cells but also seminiferous tubules as well (Greep and Fevold, 1937; Greep, van Dyke and Chow, 1942; Simpson, Li and Evans, 1942). A tentative explanation for the action of the latter hormone on the tubules is that endogenous androgen, released by interstitial cells in response to the hormone, stimulates the tubules.

Other gonadotropins are present in the body fluids of pregnant animals. Apparently they are produced by the chorion rather than by the hypophysis, hence they are called chorionic gonadotropins. Still other gonadotropins, appearing in the urine of normal men and women and of menopausal subjects, are designated as urinary hypophyseal gonadotropins. Chorionic and urinary hypophyseal gonadotropins are believed to contain both gametogenic and interstitial cell-stimulating hormones; but the indications are that the former gonadotropin contains mostly interstitial cell-stimulating hormone and that the latter consists chiefly of gametogenic hormone.

Gonaodtropins act directly on the testes. By causing the testes to secrete androgen, they stimulate indirectly such accessory reproductive organs as the scrotum and the ductus deferens.

*Corner (1943) has written a note concerning the spelling of this adjectiv

2. *The Effects of Injecting Gonadotropins.*—

Descent of the testis: This has been induced in prepuberal monkeys* by injecting either hypophyseal or chorionic gonadotropin (Engle, 1932b; Aberle and Jenkins, 1934), and in adult hypophysectomized monkeys by injecting the latter hormone (Smith, 1938).

Many investigators have observed the effects of gonadotropins on the testes of immature rats. Generally they have not mentioned whether precocious descent occurred. This is readily understandable because in normal immature rats the position of the testes is so variable that the identification of precocious descent is difficult; upon handling normal immature rats, the testes move freely upward and downward. But it has been noted frequently that in animals receiving gonadotropins, the scrota are larger than those of controls.

Descent has been obtained in ground squirrels by injecting either hypophyseal, urinary hypophyseal, or chorionic ganodatropin (see beyond). These wild rodents are favorable animals for such observations because in them complete descent does not occur normally until eight or more months after birth.

There is bountiful literature concerning the clinical induction of descent by means of gonadotropins. Since this literature has been reviewed in December, 1942 (Pullen, Wilson, Hamblen and Cuyler), only brief comments seem to be desirable. From the earlier papers, Engle (1936) noted that chorionic gonadotropin had been reported to cause the descent of "undescended testes" in 119 of 172 cases. Undoubtedly, this high percentage (69.1 per cent) is due to many inaccurate diagnoses previous to therapy.† Thompson and Heckel (1939a), excluding from their data the patients with "migratory"‡ testes, reported fewer positive responses (about 20 per cent). Orchidopexies were performed on eleven patients whose testes failed to descend. In each of these patients, anatomical barriers to descent were observed during the operation. Thompson and Heckel believe that perhaps gonadotropins cause descent only in those individuals whose testes would descend, without treatment, near the time of puberty.

Testis as a whole: The testes of experimental animals respond to gonadotropins by growing. Although variable in different animals receiving identical amounts of hormone, testicular growth tends to vary directly with the quantity of hormone which is given. Thus, in monkeys receiving hypophyseal or chorionic gonadotropin, weights of the testes were doubled (Engle, 1932a). In rats injected with chorionic gonadotropin (Moore, 1936) and in ground squirrels injected with urinary hypophyseal gonadotropin (Wells and Overholser, 1938),

*According to Engle, normal closure of the abdominal inguinal ring had occurred before injections were begun. Subsequently, however, Wislocki (1933) reported that in juvenile monkeys this ring frequently is open.

†Methods for making better diagnoses are outlined by Thompson and Heckel (1939a) and by Hamilton (1941).

‡"Migratory" testes are defined by these investigators as those "which move back and forth readily from the canal to the scrotum."

weight of the testes of some animals increased more than 400 per cent. The growth is due to hypertrophy of the seminiferous tubules, of the interstitial tissue, or of both.

Seminiferous tubules: Growth of the tubules has been reported consistently in animals receiving gonadotropins. The growth undoubtedly causes an increase in the size of the testis and it may occur even in the absence of spermatogenetic acceleration. As might be expected, however, the greatest tubular growth is to be observed in animals which respond to gonadotropins by producing spermatozoa.

As may be inferred from the above remarks, the gametogenic response to gonadotropins is variable in different species. Clinical observations on the subject deal largely with the quantity and quality of spermatozoa in patients receiving various gonadotropins.* The majority of these observations may be interpreted as evidence that in man injections of gonadotropins cause gametogenic responses.

Among mammals, the precocious production of spermatozoa in response to gonadotropins has been observed only in one species—the ground squirrel. It has been induced by adequate treatments with the following materials which contain hypophyseal, urinary hypophyseal, of chorionic gonadotropins: fresh hypophyses (Wells, 1935a; Wells and Gomez, 1937a), urine of pregnant women, antuitrin S (Wells, 1935a), blood serum from pregnant mares (Wells and Moore, 1936; Wells, 1935b, 1937) and prospermin (Wells and Overholser, 1938). But in animals such as the monkey (Engle, 1932a) and the rat, provided a reliable criterion for judgment is used (Moore, 1936; Zondek, Brzezinski, and Sulman, 1941), gonadotropins fail to induce the precocious formation of spermatozoa.

It seems reasonable that differences in age may explain in part the differing responses elicited in prepuberal ground squirrels and rats, the former animals being older than the latter. Indeed, other investigators have reported observations which support this idea. Smith and Leonard (1933) demonstrated that chorionic gonadotropin will maintain spermatogenesis in adult hypophysectomized rats or repair the damage caused by hypophysectomy, thus showing that rats may respond to gonadotropin when they have reached an appropriate age or when their tissues have become sufficiently differentiated. Leathem and Webster (1942) reported similar results in adult guinea pigs. Also, it has been noted that urinary hypophyseal gonadotropin can induce complete spermatogenesis in rats which are hypophysectomized near the time of puberty, allowed to go without treatment for several days, injected for several weeks, and killed at the approximate age of 60 to 70 days (Leathem, 1940; Leathem, and Mills, 1942). It may be pointed out that with aging the immature ovary is known to gain responsiveness to gonadotropins (Smith and Engle, 1927). In addition

*Eighteen clinical papers concerning this topic are available in the bibliography prepared by Pullen, Wilson, Hamblen, and Cuyler, 1942.

to age, the duration of treatment may help to explain the different responses, several weeks being required for the production of spermatozoa. Length of the prepuberal period permits this duration to be longer in immature ground squirrels than in immature rats.

The situation in prepuberal monkeys is less clearly understood. But there is evidence that the age of the animals and the duration of treatment are not the only factors responsible for the lack of response in monkeys. For Smith (1938) has shown that in an immature hypophysectomized monkey weighing 4040 Gm., twenty-nine daily injections of chorionic gonadotropin fail to stimulate spermatogenesis. In adult hypophysectomized monkeys. this gonadotropin provides imperfect restoration of spermatogenesis in testes which have undergone involution; although when injected immediately after hypophysectomy, the gonadotropin maintains spermatogenesis for twenty days but not for longer periods of time (Smith, 1942). It is not known, therefore, why this species is refractory to gonadotropins but the possibility exists that antigonadotropins may be involved.*

Interstitial tissue:† Certain gonadotropins cause conspicuous increases in this tissue (Steinach and Kun, 1928; Engle, 1929; Moore, 1936) and, consequently, growth of the testes.

The responses of the interstitial tissue to various gonadotropins have been reviewed by Engle and Levin (1941). Two criteria are useful for identifying positive stimulation by gonadotropins. The first is an anatomical criterion which may be either a hypertrophy of the interstitial cells or an unquestionably significant increase in the amount of interstitial tissue.‡ The second criterion, an indirect one, consists of an increase in the size of accessory reproductive organs such as the seminal vesicles and the prostate. It is based upon the generally accepted view§ that the interstitial cells produce androgen which is known to stimulate the accessory reproductive organs of males. Through the use of these criteria, the observations indicate that the interstitial tissue may be stimulated by all gonadotropic preparations except those containing predominately the gametogenic hormone (follicle-stimulating hormone or thylakentrin).‖

Scrotum and ductus deferens: These accessory reproductive structures also grow in response to gonadotropins. However, as mentioned previously, they respond indirectly to gonadotropins, the androgen produced by the testes being the stimulating agent.

*Many observations suggest that antigonadotropins are immune bodies which originate in response to foreign proteins, while other observations do not support such an interpretation. Discussions of this subject have been published recently (Thompson, Collip, and Selye, 1941, Zondek and Sulman, 1941).

†The interstitial tissue of the testis decreases after hypophysectomy (Smith, 1932), i. e., when the hypophyseal interstitial cell-stimulating hormone is not available.

‡There exists no satisfactory method for determining quantitatively the changes in the number of interstitial cells or in the amount of interstitial tissue. Intricate methods have been devised and abondoned (Sand and Okkels, 1936).

§Recent histochemical evidence supports this view (Pollock, 1942).

‖Sparrows, normally having no Leydig cells in their testes, exhibit typical Leydig cells after injections of equine gonadotropin (Pfeiffer and Kirschbaum, 1943).

Preceding descent of the testes, experimentally induced, Engle (1932b) reported a significant growth of the scrotum and an increased testicular mobility; it seems reasonable to believe that part of this mobility was due to growth of the ductus deferens. In prepuberal and hypophysectomized ground squirrels under the experimental influence of gonadotropic hormones, the scrotum acquires the size and anatomical features characteristically occurring in breeding males and the ductus deferens increases remarkably in length (Wells, unpublished observations).

Summary: Descent of the testis has been induced by administering the following gonadotropic agents: fresh hypophysis tissue, aqueous hypophyseal extract, urine of pregnant women, extracts of pregnancy urine, blood serum from pregnant mares, extracts of pregnant mare serum, and extracts of urine from normal men. The gonadotropins cause the testes to grow and to secrete androgen, the latter hormone causing growth of the scrotum and the ductus deferens.

3. *The Effects of Injecting Androgens.*—

Descent of the testis: In the following, the testes have been observed to descend in response to injections: patients exhibiting cryptorchidism (Hamilton and Hubert, 1938; McCullagh and McGurl, 1939),* monkeys (Hamilton, 1938), rats (Steinach and Kun, 1940), and ground squirrels (Wells, 1935a, 1942a; Wells and Overholser, 1939; Wells and Moore, 1936).

Growth of the testis: While there is abundant evidence that injections of androgen suppress the hypophysis and thereby injure the testis (Moore and Price, 1932; Moore, 1941), it is also clear that under certain circumstances androgen stimulates the testis, although the route by which it exerts its stimulating action is questionable (Wells, 1942a; Moore and Morgan, 1942). As discussed previously in considerable detail (Wells and Moore, 1936), the testes of different species exhibit different responses to androgen.

These differences are illustrated vividly by the effects of androgen on testicular growth. Thus, in intact prepuberal ground squirrels, a fourfold increase in the weight of the testes can be secured; in most respects, these testes resemble those of rutting adults. Conversely, the testes of immature injected rats usually are smaller than those of untreated littermates.

There is little information concerning the effect of androgen on the size of the human testis. Testicular enlargement has been reported by Webster (1938).

Testicular growth, when it occurs, is due mostly to hypertrophy of the seminiferous tubules. It is not due to the interstitial tissue because, as generally agreed, the interstitial cells are not stimulated

*As a therapeutic measure for cryptorchidism, androgen seems to be effective in only a small percentage of patients (Thompson and Heckel, 1939b; Hamilton, 1941).

by androgen (Cutuly, McCullagh and Cutuly, 1937; Greep, 1939; Selye and Friedman, 1941; Shay, Gershon-Cohen, Paschkis and Fels, 1941; Moore and Morgan, 1942; Wells, 1942a, 1942b, 1943).

Seminiferous tubules: Our knowledge about the response of human tubules to androgen has been secured indirectly by observing the semen of patients. I know of only two papers which report an increased number of spermatozoa in response to androgen (Vest and Howard, 1938; Rubenstein and Kurland, 1939). At least six other clinical papers report decreased numbers of spermatozoa (for this literature, see Pullen and associates, 1942b). Obviously it is desirable to study this question by observing the tubules secured at biopsies: this method of investigation is being used (Charny and Meranze, 1942).

There are numerous investigations concerning the action of androgen on the seminiferous tubules of animals. These investigations have been reviewed recently by Moore and Morgan (1942) who state that "the effects of androgens upon the testis remain an open question." In several species, an inhibition of the tubules has been observed; but in one species and in other species especially after hypophysectomy, stimulation of the tubules has been noted. The precocious formation of spermatozoa has been induced by androgen only in the ground squirrel (Wells, 1935a, 1942a; Wells and Moore, 1936; Wells and Gomez, 1937b; Wells and Overholser, 1939). But the production of spermatozoa after puberty has been obtained by injecting hypophysectomized rats with androgen (Cutuly, 1941a; Nelson, 1941).

The inguinal bursa: In at least two species of rodents, the size of this paired structure depends upon androgenic stimulation and upon mechanical distention by the testis (Wells, 1937b; Wells and Overholser, 1937).* The original evidence for this statement was secured by observing the bursae of animals which had been unilaterally or bilaterally castrated. Additional observations have been made; in animals receiving androgen, the bursae exhibit significant growth (Wells, unpublished data). In monkeys, Hamilton (1938) has reported that injections of androgen cause the cremaster muscle to grow.

Scrotum: It is generally agreed that during the postnatal period the scrotum grows in response to injections of androgen. Such growth has been observed in monkeys (Hamilton, 1938). The scrotum became bilobed, dependent, and rugose, while the scrotal raphe became red and prominent. After injections, the scrota of rats increase in size (Hamilton, 1936; Martins, 1938). In the ground squirrel, unpublished observations show that injections of androgen cause the scrotum to grow and become pendulous, to acquire a black color, and to exhibit coarser and less abundant hair.

In the rat, scrotal growth is due to androgenic stimulation and to the distending action of the testes (Selye, 1943). In this species,

*Owing to the fact that in 1937 we were not familiar with the paper by Klaatsch (1890), we referred to the inguinal bursae as the "fibro-muscular scrotal sacs."

scrotal contractility is regulated by androgen (Andrews, 1940; Tyrrell, Andrews and Zelle, 1942).

The human scrotum is stimulated by androgenic treatments (Hamilton and Hubert, 1938; Vest and Howard, 1938; Webster, 1938).

Ductus deferens: This organ also is governed by a male hormone (Vatna, 1930). Several investigators have stated that injections of androgen cause the ductus to become longer. I have some unpublished data showing that in rodents androgen may cause almost a twofold increase in the length of the ductus, average lengths being the following: in seven controls, 28.5 mm. and in twenty-one injected animals, 47.2 mm.

4. *Effects of Injecting Estrogen:* Greene, Burrill, and Ivy (1940) have obtained intersexual rats by injecting their mothers during pregnancy. Among the intersexes, representing modified males, they observed the failure of testicular descent and the absence of scrota. At birth, the testis exhibited an atypical position near the inferior pole of the kidney.

In male mice, injections of estrogen cause the testes not to descend (Burrows, 1936). In adult rodents receiving estrogen, scrotal testes return to an abdominal position (Wells, 1935a).

PRESENT STATUS OF THE PROBLEM

The question immediately arises as to what causes the gubernaculum to evert the abdominal wall, thus producing the inguinal bursa. The size of the gubernaculum in fetal freemartins (Bissonnette, 1924) suggests that androgen may be the stimulating agent; apparently there is no literature concerning the effect of hormones on the gubernaculum.* I am investigating this problem (Wells, unpublished data).

Two stages of descent should be recognized. The first involves the passage of the testes into the inguinal bursae. During the second stage, bursae and testes extend downward and enter the scrotum.

Both stages occur prenatally in such forms as man, monkeys, and domesticated ungulates (horses, cattle, pigs, sheep, and goats†), and postnatally in the opossum (which has a "prepenial" scrotum). Several species, illustrated by rodents, exhibit the second stage during the puberal period. In such species, there is inadequate information concerning the time when the first stage occurs. I have found that in newborn mice, rats, rabbits, and guinea pigs, the bursae of preserved specimens usually contain the caudal epididymides and sometimes the inferior extremities of the testes (unpublished observations).

Since most of the recent observations concern postnatal rather than prenatal descent, the former will receive first attention.

*One paper (Abrahamson, 1942) deals with a response of the "gubernaculum" to hormones. From the illustrations in the paper, it seems that the author was mistaken in his identification of the gubernaculum.

†Personal communication from Dr. W. L. Boyd, Department of Animal Husbandry, University of Minnesota.

Puberal descent: During puberal descent, it is probable that the gubernaculum functions chiefly, as its name implies (governor), as a guiding agent for the testis. But there is experimental evidence that this structure is not absolutely necessary; in a small percentage of rodents in which the gubernaculum was severed unilaterally during the prepuberal period, the testes subsequently descended into the scrotum (unpublished data). At autopsy, such testes lacked adhesions. In weight and in quantities of spermatozoa, these resembled contralateral, normal testes.

Hypophyseal gonadotropins provide stimuli essential for descent of the testis since the testes of prepuberally hypophysectomized animals, after failing to descend at the expected time, can be induced to descend by making intermuscular implants of hypophyseal tissue or by injecting gonadotropic hormones. The ground squirrel affords additional information which supports this thesis; in this species after annual rut, the testes normally return from the scrotum to the abdomen. The information was secured by assaying the quantities of gonadotropic hormones in the hypophyses of different animals. The quantities were found to be minimal in animals with abdominal testes (prepuberal or adult), greater in those with partially descended testes and still greater in those with scrotal testes (Wells, 1938). It may be mentioned that low environmental temperature favors high levels of gonadotropins in the ground squirrel with the striking consequence that, through the experimental provision of a cold environment, the testes may be caused to remain in the scrotum for more than twelve months (Wells and Zalesky, 1940). In this species, descent normally occurs during the period of hibernation.

Greater responsiveness of the testes to gonadotropins is a characteristic of puberty. The testes respond to hypophyseal gonadotropins by growing and by producing androgen.*

Testicular growth is undoubtedly related to descent. It causes ponderal enlargement of the inguinal bursae; the evidence for this is that in unilateral castrates, the weight of the bursa is less on the operated side (Wells, 1937b; Wells and Overholser, 1937). Obviously, the bursae must enlarge in order to reach the scrotum. However, there are two reasons for believing that testicular growth is not a major factor in descent. First, human testes descend before the onset of puberal testicular growth. Second, if a paraffin pellet is placed inside the tunica albuginea, after removing the contents of the latter, injections of androgen cause the pellet to descend (Martins, 1938); the pellet simulates a testis but differs from one by being unable to grow.

The chief hormonal factor in descent probably is the growth-stimulating action of androgen on accessory reproductive organs (in-

*They also exhibit a gametogenic response which results, after they reach the scrotum, in the production of spermatozoa.

guinal bursa, including cremasteric muscle; ductus deferens; scrotum) and their associated structures (spermatic vessels). Near the time of puberty, these organs probably have acquired a greater capacity to respond to androgen. Concerning this, we have presumptive evidence; the evidence is that as rats become older, their seminal vesicles respond more readily to certain androgens (Hooker, 1942; Selye and Albert, 1942).* From the available data (limited to one species, namely, the bull), it seems that the puberal increment of testicular androgen is gradual rather than rapid (Hooker, 1937).

Some of the androgen may be derived from extragonadal sources such as the juvenile adrenal cortex. In some species (rodents) the evidence for this is convincing (Price, 1936, 1939, 1941, 1942; Davidson and Moon, 1936; Howard, 1937, 1938, 1939; Burrill and Greene, 1939, 1940; Wintersteiner, 1941).

Spontaneous, puberal descent of the human ("undescended") testis deserves careful study.† Desirable observations are those on the patient exhibiting unilateral cryptorchidism because they may assist in answering the following questions: (1) How can prenatal hormones, equally distributed to both sides of the body, exert unequal influences on the two testes? (2) Why, in the case of one and the same testis, should antenatal hormones be ineffective and puberal hormones effective?

Prenatal descent: Hormones probably are involved. This view receives support from the following observations: (1) in several species, postnatal descent has been induced by injecting hormones, (2) the hormones in question are present during pregnancy, (3) after parturition, the testes of rhesus monkeys ascend from the scrotum (Wislocki, 1933).

The involvement of chorionic gonadotropin has been postulated (Engle, 1932b). If this hormone is a factor, it would be expected to exert its action by stimulating the testis. But the fetal testis may not be able to respond; in pouch-young opossums the reproductive organs of which exhibit fetal characteristics, the testis fails to respond (until 63 to 70 days after birth) to injections of gonadotropin (Moore, 1940; Moore and Morgan, 1943). Furthermore, as a manifestation of testicular stimulation by the hormone, one would expect conspicuously rapid growth of the testis. The available data for man (Table I) fail to reveal exceedingly rapid growth during the critical period under discussion (previous to the seventh lunar month) and, as pointed out earlier, they also fail to indicate that the testis regresses in size immediately after birth (i.e., when chorionic gonadotropin is no longer available). If the hormone does not stimulate the fetal testis, could it influence descent by stimulating some fetal organ other than the

*Similarly, with ascending age during the interval between birth and puberty, certain female reproductive organs become more responsive to estrogen. Recent literature on this subject is available in a paper by Wilson and Young (1941).

†Apparently "migratory" testes are the ones which "descend" at puberty (Thompson and Heckel, 1939a).

testis? At present it is impossible to answer the question, but one is tempted to speculate that this hormone might cause the production of androgen by the provisional cortex ("fetal cortex") of the suprarenal gland. In such speculation the main considerations are the following: (1) injections of equine gonadotropin stimulate the suprarenal cortex of hypophysectomized rodents (Zalesky, Wells, Overholser and Gomez;* (2) in juvenile rodents, the suprarenal gland probably secretes androgen; (3) postnatal descent of the testis can be induced by injecting androgen. Finally, in order for chorionic gonadotropin to be a factor in descent, an adequate quantity would have to be present just preceding or during descent. Actually, the quantity of this hormone is greatly diminished during the last two trimesters of pregnancy (Evans, Kohls, and Wonder, 1937).

In view of what has been said concerning the relation of androgen to puberal descent, is it likely that androgen influences prenatal descent? If so, androgen must be available during pregnancy and the fetal organs must depend upon it during their normal development. The secretion of androgen by the fetal testis has been postulated by Lillie (1917). This hormone has been extracted from fetal testes (Womack and Koch, 1932; Hooker, 1937), but this does not prove necessarily that it originated in them. That androgen is present in pregnant animals (rat) has been reported by Burrill and Greene (1942). If one assumes that androgenic hormones influence descent, progesterone needs to be considered in this problem because it has been found to have androgenic properties (Lamar, 1937, 1940; Greene, Burrill and Thompson, 1940). The possible production of androgenic hormones by the fetal adrenal glands should not be overlooked. However, in the fetus, there is no evidence indicating that accessory reproductive organs (inguinal bursa, ductus deferens, and scrotum) depend upon androgen. The prostates of pouch-young opossums, exemplifying accessory reproductive organs, continue their normal development for several weeks after castration (Moore, 1941b). Further study is desirable.

Concerning estrogen, Wislocki (1933) postulated that this hormone might promote descent by acting upon the scrotum; yet subsequent observations by other investigators make this appear to be very unlikely.

We may now consider certain nonhormonal factors. Moszkowicz (1934) calls attention to an embryological phenomenon which makes descent a possibility but which sheds no light on the forces of descent. He suggests that in males the regression of the Müllerian ducts favors descent by providing greater testicular mobility, and that retention of them frequently causes cryptorchidism; in three human subjects,

*However, the corticotropic factor in mare serum, unlike the gonadotropic, is said not to be destroyed by heating (Golla and Reiss, 1912).

he observed the simultaneous occurrence of hermaphroditism (including the presence of the "broad ligament") and cryptorchidism. But cryptorchidism is not always associated with hermaphroditism. Indeed, in the most extreme case of hermaphroditism recorded among mammals (Wells, 1937a), the mesometrium (infraprimate homologue of the broad ligament) failed to prevent the experimental induction of descent by injections of chorionic gonadotropin; it is of general interest that in response to these injections, the ovotestes of one and the same animal produced ova, corpora lutea, and spermatozoa.

The (theoretical) contraction of skeletal muscle in the inguinal cone has limited application. This is because the cone, although a prominent structure in rodents, is not well developed in human fetuses.

It becomes increasingly evident that the gubernaculum does not pull the testis into the scrotum. It may be recalled that Forssner (1928) vehemently denies the presence of smooth muscle in the gubernaculum. The view that retrogressive shrinkage of the gubernaculum pulls the testis downward is open to a serious criticism—the gubernaculum is *not attached distally to an immovable structure.*

CONCLUSIONS

1. Some observations suggest that in man hormones (chorionic gonadotropin and androgenic substances) are related to normal, prenatal descent of the testis. However, the capacity of fetal organs to respond to available hormones deserves additional investigation.

2. In certain species, hypophyseal gonadotropins and androgen influence normal, puberal descent.

3. It appears that estrogen does not favor normal descent.

4. If, in man, "unilaterally undescended testes" descend spontaneously several years after birth, the question arises as to how hormones (equally distributed to both sides of the body) could influence the prenatal descent of one testis and not of the other.

5. It is unlikely that the gubernaculum pulls the testis into the scrotum.

6. It is questionable whether the gubernaculum penetrates the external spermatic fascia and attaches to the scrotum.

7. The inguinal cone probably has little or no influence upon descent of the human testis.

8. Factors causing the formation of the inguinal bursae (Klaatsch) are unknown.

ADDENDUM.—After submitting the manuscript for publication, N. R. Wyndham's article concerning the morphologic aspects of descent has been published (J. Anat. 77: 179-188, 1943). There is presented a series of twenty-three gubernacular measurements. From observations in preparations stained with hematoxylin and eosin, it is reported that the gubernaculum contains striated and unstriated muscle fibers. In specimens measuring 6 to 12 cm. (crown-rump), it is said that the gubernaculum could be traced to the scrotum. Yet Wyndham does not refute directly the statement of other investigators that in the newborn infant the

gubernaculum lies exclusively within the inguinal bursa (as illustrated in R. H. Hunter's Fig. 65; Brit. J. Surg. 14: 125-130, 1926).

Concerning hormonal phases of the problem, newborn infants exhibiting female pseudohermaphroditism are of interest. This is because of the evidence which they may furnish as to whether human fetal organs can respond to androgenic hormones (regardless of their source) and whether in man the fetal cortex of the adrenal produces such hormones. A recent discussion of these questions is available in an article by T. E. Bratrud ("Congenital Hyperplasia of the Adrenals," Thesis, University of Minnesota Library, May, 1943).

REFERENCES

1. Aberle, S. G., and Jenkins, R. H.: Undescended Testes in Man and Rhesus Monkeys, J. A. M. A. 103: 314-318, 1934.
2. Abrahamson, R. H.: Combined Surgical and Physiologic Treatment of Cryptorchidism, Arch. Surg. 44: 170-186, 1942.
3. Andrews, F. N.: Thermo-Regulatory Function of Rat Scrotum. I. Normal Development and Effect of Castration, Proc. Soc. Exper. Biol. & Med. 45: 867-869, 1940.
4. Bischoff, E.: Einige Gewichts- und Trockenbestimmungen der Organe des menschlichen Körpers, Ztschr. f. rat. Med., Ser. 3, 20: 75-118, 1863.
5. Bissonnette, T. H.: The Development of the Reproductive Ducts and Canals in the Free-Martin With Comparison of the Normal, Am. J. Anat. 33: 267-345, 1924.
6. Boening, H.: Studien zur Körperverfasserung der Langlebigen, Ztschr. f. Konstitutionsl. 8: 459-506, 1922.
7. Borovansky, L.: Contribution to the Study of Fetal Growth, Bull. Internat. d. Acad. d. Sc. de Boheme, 15 pages, 1930.
8. Bramann, F.: Beitrag zur Lehre von dem Descensus testiculorum und dem Gubernaculum Hunteri des Menschen, Arch. f. Anat. u. Entwcklngsgesch., pp. 310-340, 1884.
9. Burrill, M. W., and Greene, R. R.: Androgenic Function of Adrenals in Immature Male Castrate Rat, Proc. Soc. Exper. Biol. & Med. 40: 327-330, 1939.
10. Idem: Further Studies on the Andromimetic Function of the Immature Male Rat Adrenal, Endocrinology 26: 645-650, 1940.
11. Idem: Androgen Production During Pregnancy and Lactation in the Rat, Anat. Rec. 83: 209-227, 1942.
12. Burrows, H.: The Influence of Oestrogenic Compounds in Causing Hernia and Descent of the Testis in Mice, Brit. J. Surg. 23: 658-664, 1936.
13. Castaldi, L., and Vannucci, D.: Le misure antropometriche esterne e i pesi viscerali più importanti considerati in funzione del sesso età, statura e costituzione, Scritti biol. 2: 1-151, 1927.
14. Charny, C. W., and Meranze, D. R.: Testicular Biopsy: Further Studies in Male Infertility, Surg., Gynec. & Obst. 74: 836-842, 1942.
15. Cooper, E. R. A.: The Histology of the Retained Testis in the Human Subject at Different Ages, and Its Comparison With the Scrotal Testis, J. Anat. 64: 5-27, 1929.
16. Corner, G. W.: Spelling of the Adjective "Hypophyseal," Science 97: 67-68, 1943.
17. Cruickshank, J. N., and Malcolm, J. M.: The Weight of Fetal Organs. A Study of the Relations Between Organ Weight and Body Weight in the Latter Months of Development, Based Upon an Examination of 470 Normal Fetuses Out of a Series of 1,000 Fetuses and Newborn Infants in Glasgow, Privy Council, Medical Research Council, Special Report Series No. 86, pages 33-87, 1924.
18. Cutuly, E.: Androgens and Spermatogenesis in Rats, Anat. Rec. (sup. 2) 79: 16, 1941.
19. Cutuly, E., McCullagh, D. R., and Cutuly, E. C.: Effects of Androgenic Substances in Hypophysectomized Rats, Am. J. Physiol. 119: 121-126, 1937.
20. Davidson, C. S., and Moon, H. D.: Effect of Adrenocorticotropic Extracts on Accessory Reproductive Organs of Castrate Rats, Proc. Soc. Exper. Biol. & Med. 35: 281-282, 1936.
21. Eberth, C. J.: Die männlichen Geschlechtsorgane, in Karl von Bardeleben's Handb. d. Anat. d. Mensch. Jena 7: 1-310, 1904.
22. Eller, L. R.: The Eponyms of Anatomy, Toledo, Ohio, 1935, McManus-Troup, 382 pages.

he observed the simultaneous occurrence of hermaphroditism (including the presence of the "broad ligament") and cryptorchidism. But cryptorchidism is not always associated with hermaphroditism. Indeed, in the most extreme case of hermaphroditism recorded among mammals (Wells, 1937a), the mesometrium (infraprimate homologue of the broad ligament) failed to prevent the experimental induction of descent by injections of chorionic gonadotropin; it is of general interest that in response to these injections, the ovotestes of one and the same animal produced ova, corpora lutea, and spermatozoa.

The (theoretical) contraction of skeletal muscle in the inguinal cone has limited application. This is because the cone, although a prominent structure in rodents, is not well developed in human fetuses.

It becomes increasingly evident that the gubernaculum does not pull the testis into the scrotum. It may be recalled that Forssner (1928) vehemently denies the presence of smooth muscle in the gubernaculum. The view that retrogressive shrinkage of the gubernaculum pulls the testis downward is open to a serious criticism—the gubernaculum is not attached distally to an immovable structure.

CONCLUSIONS

1. Some observations suggest that in man hormones (chorionic gonadotropin and androgenic substances) are related to normal, prenatal descent of the testis. However, the capacity of fetal organs to respond to available hormones deserves additional investigation.

2. In certain species, hypophyseal gonadotropins and androgen influence normal, puberal descent.

3. It appears that estrogen does not favor normal descent.

4. If, in man, "unilaterally undescended testes" descend spontaneously several years after birth, the question arises as to how hormones (equally distributed to both sides of the body) could influence the prenatal descent of one testis and not of the other.

5. It is unlikely that the gubernaculum pulls the testis into the scrotum.

6. It is questionable whether the gubernaculum penetrates the external spermatic fascia and attaches to the scrotum.

7. The inguinal cone probably has little or no influence upon descent of the human testis.

8. Factors causing the formation of the inguinal bursae (Klaatsch) are unknown.

ADDENDUM.—After submitting the manuscript for publication, N. R. Wyndham's article concerning the morphologic aspects of descent has been published (J. Anat. 77: 179-188, 1943). There is presented a series of twenty-three gubernacular measurements. From observations in preparations stained with hematoxylin and eosin, it is reported that the gubernaculum contains striated and unstriated muscle fibers. In specimens measuring 6 to 12 cm. (crown-rump), it is said that the gubernaculum could be traced to the scrotum. Yet Wyndham does not refute directly the statement of other investigators that in the newborn infant the

50. Hamilton, J. B., and Hubert, G.: Effect of Synthetic Male Hormone Substance on Descent of Testicles in Human Cryptorchidism, Proc. Soc. Exper. Biol. & Med. 39: 4-5, 1938.
51. Hooker, C. W.: Testis Hormone in Relation to Age, Endocrinology 21: 655-658, 1937.
52. Idem: Pubertal Increase in Responsiveness to Androgen in the Male Rat, Endocrinology 30: 77-84, 1942.
53. Howard, E.: Is the X Zone Andromimetic? Am. J. Physiol. 119: 339-340, 1937.
54. Idem: The Representation of Adrenal X Zone in Rats, in Light of Observations on X Zone Variability in Mice, Am. J. Anat. 62: 351-373, 1938.
55. Idem: Effects of Castration on the Seminal Vesicles as Influenced by Age, Considered in Relation to the Degree of Development of the Adrenal X Zone, Am. J. Anat. 65: 105 149, 1939.
56. Hunter, J.: Observations on Certain Parts of the Animal Economy. A Description of the Situation of the Testis in the Foetus, With Its Descent Into the Scrotum, London, 1786, pp. 1 26.
57. Jackson, C. M.: On the Prenatal Growth of the Human Body and the Relative Growth of the Various Organs and Parts, Am. J. Anat. 9: 119 165, 1909.
58. Kitahara, Y.: Ueber die Entstehung der Zwischenzellen der Keimdrüsen des Menschen und der Saugetiere und uber deren physiologische Bedeutung, Arch. f. Entwecklingsmechn. d. Organ. 52: 550 615, 1923.
59. Klaatsch, H.: Ueber den Descensus testiculorum, Morphol. Jahrb. 16: 587 646, 1890.
60. Lamar, J. K.: Some Effects of Progestin Containing Extracts and Progesterone on Young Male Albino Rats, Anat. Rec. (sup.) 70: 45 46, 1937.
61. Idem: Some Effects of Corpus Luteum Extracts and of Synthetic Progesterone on Young Male Albino Rats, Physiol. Zool. 13: 251 266, 1940.
62. Leathem, J. H.: Effect of "Prospermin" on Immature and Mature Hypophysectomized and Normal Male Rats, Proc. Soc. Exper. Biol. & Med. 45: 497-499, 1940.
63. Leathem, J. H., and Mills, E. J.: Influence of Normal Male Urine Gonadotropin on Spermatogenesis in Hypophysectomized Mature and Immature Rats, Endocrinology 31: 318-322, 1942.
64. Leathem, J. H., and Webster, E. C.: Response of Hypophysectomized Male Guinea Pigs to Pregnant Mare Serum, Anat. Rec. (sup. 3) 82: 37, 1942.
65. Leupold, E.: Die Bedeutung des Thymus fur die Entwicklung der menschlichen Keimdrusen, Beitr. z. path. Anat. u. z. allg. Path. 69: 473-491, 1920.
66. Lillie, F. R.: The Freemartin; a Study of the Action of Sex Hormones in the Foetal Life of Cattle, J. Exper. Zool. 23: 371 452, 1917.
67. Lockwood, C. B.: Development and Transition of the Testis, Normal and Abnormal, J. Anat. & Physiol. 22: 38 77, 461 478, 505 541, 1888.
68. McCullagh, E. P., and McGurl, F. J.: The Clinical Use of Testosterone Propionate, J. Urol. 42: 1265 1273, 1939.
69. Martins, T.: La testostèrone peut provoquer la descente de testicules artificiels de paraffine, Compt. rend. Soc. de Biol. 131: 299 302, 1938.
70. Meyer, R.: Dislocation of the Phallus, Penis and Clitoris Following Pelvic Malformations in the Human Fetus, Anat. Rec. 79: 231 241, 1941.
71. Mita, G.: Physiologische und pathologische Veranderungen der menschlichen Keimdruse von der fotalen bis zur Pubertatszeit, mit besonderer Berücksichtigung der Entwicklung, Beitr. z. path. Anat. u. z. allg. Path. 58: 554 641, 1914.
72. Moore, C. R.: Responses of Immature Rat Testes to Gonadotropic Agents, Am. J. Anat. 59: 63 88, 1936
73. Idem: On the Role of Sex Hormones in Sex Differentiation in the Opossum (Didelphys virginiana), Physiol. Zool. 14: 1 45, 1940.
74. Idem: Physiology of the Testis, J. A. M. A. 116: 1638 1644, 1941a.
75. Idem: Embryonic Differentiation of Opossum Prostate Following Castration and Responses of the Juvenile Gland to Hormones, Anat. Rec. 80: 315 327, 1941b.
76. Moore, C. R., and Morgan, C. F. Responses of the Testis to Androgenic Treatments, Endocrinology 30: 990 999, 1942.
77. Idem: First Response of Developing Opossum Gonads to Equine Gonadotropic Treatment, Endocrinology 32: 17 26, 1943.
78. Moore, C. R., and Price, D.: Gonad Hormone Functions and the Reciprocal Influence Between Gonads and Hypophysis With Its Bearing on the Problem of Sex-Hormone Antagonism, Am. J. Anat. 50: 13-71, 1932.
79. Moszkowicz, L.: Die Entstehung des Kryptorchismus, Arch. f. klin. Chir. 179: 445 462, 1934.

23. Engel: Einige Bemerkungen über Lageverhältnisse der Baucheingeweide im gesunden Zustande, Wien. med. Wchnschr. 7: 705-708, 1857.
24. Engle, E. T.: The Response of the Male Genital System to Treatment With Urine From Pregnant Women and From Men, Anat. Rec. 43: 187-195, 1929.
25. Idem: The Action of Extracts of Anterior Pituitary and of Pregnancy Urine on the Testes of Immature Rats and Monkeys, Endocrinology 16: 506-512, 1932a.
26. Idem: Experimentally Induced Descent of the Testis in the Macacus Monkey by Hormones From the Anterior Pituitary and Pregnancy Urine, Endocrinology 16: 513-520, 1932b.
27. Idem: The Relation of the Anterior Pituitary Gland to Problems of Puberty and of Menstruation, Proc. A. Research in Nerv. & Ment. Dis. 17: 298-320, 1936.
28. Idem: In Problems of Ageing: Biological and Medical Aspects, edited by E. V. Cowdry, Baltimore, 1939, Williams & Wilkins Company, pp. 434-458, chap. 15.
29. Engle, E. T., and Levin, L.: Gonadotropins of the Anterior Lobe of the Pituitary and of Chorionic Tissue, J. A. M. A. 116: 47-52, 1941.
30. Evans, H. M., Kohls, C. L., and Wonder, D. H.: Gonadotropic Hormone in Blood and Urine of Early Pregnancy; Normal Occurrence of Transient Extremely High Levels, J. A. M. A. 108: 287-289, 1937.
31. Felix, W.: In F. Keibel and F. P. Mall's Manual of Human Embryology, Philadelphia, 1912, J. B. Lippincott Company, pp. 752-979, chap. 19.
32. Fevold, H. L.: The Follicle Stimulating and Luteinizing Hormones of the Anterior Pituitary in Sex and Internal Secretions, ed. 2, edited by E. Allen, C. H. Danforth, and E. A. Doisy, Baltimore, 1939, Williams & Wilkins Company, chap. 17.
33. Forssner, H.: Ueber den Deszensus der Geschlechtsdrüsen beim Menschen, Acta obst. et gynec. Scandinav. 7: 379-406, 1928.
34. Francis, C. C.: A Case of Prepenial Scrotum (Marsupial Type of Genitalia) Associated With Absence of Urinary System, Anat. Rec. 76: 303-308, 1940.
35. Frankl, O.: Einiges über die Involution des Scheidenfortsatzes und die Hüllen des Hodens, Arch. f. Anat. u. Entwecklngsgesch., pp. 339-360, 1895.
36. Idem: Beiträge zur Lehre vom Descensus testiculorum, Sitzungsb. d. Akad. d. Wissensch. Math.-naturw. Cl. III. 109: 107-264, 1900.
37. Fuss, A.: Ueber die Geschlechtzellen des Menschen und der Säugtiere, Arch. f. mikr. Anat. 81: 1-23, 1912.
38. Golla, Y. M. L., and Reiss, M.: Corticotropic Activity in Pregnant Mares' Serum, J. Endocrinol. 3: 5-9, 1942.
39. Greene, R. R., Burrill, M. W., and Ivy, A. C.: Experimental Intersexuality; the Effects of Estrogens on the Antenatal Sexual Development of the Rat, Am. J. Anat. 67: 305-345, 1940.
40. Greene, R. R., Burrill, M. W., and Thompson, D. M.: Further Studies on the Androgenicity of Progesterone, Endocrinology 27: 469-472, 1940.
41. Greep, R. O.: Some Effects of Androgens and Gonadotropic Preparations on the Reproductive System of Hypophysectomized Adult Male Rats and Rabbits, Anat. Rec. (sup. 2) 73: 23, 1939.
42. Greep, R. O., and Fevold, H. L.: The Spermatogenetic and Secretory Function of the Gonads of Hypophysectomized Adult Rats Treated With Pituitary FSH and LH, Endocrinology 21: 611-618, 1937.
43. Greep, R. O., Fevold, H. L., and Hisaw, F. L.: Effects of Two Hypophyseal Gonadotropic Hormones on the Reproductive System of the Male Rat. Anat. Rec. 65: 261-271, 1936.
44. Greep, R. O., van Dyke, H. B., and Chow, B. F.: Gonadotropins of the Swine Pituitary. I. Various Biological Effects of Purified Thylakentrin (FSH) and Pure Metakentrin (ICSH), Endocrinology 30: 635-649, 1942.
45. Gruenwald, P.: Ueber Form und Verlauf der Keimstränge bei Embryonen der Säugetiere und des Menschen. III. Ueber sekundäre Keimstränge in Hoden menschlicher Embryonen, Ztschr. f. Anat. u. Entwecklngsgesch. 103: 278-289, 1934.
46. Idem: The Development of the Sex Cords in the Gonads of Man and Mammals, Am. J. Anat. 70: 359-397, 1942.
47. Hamilton, J. B.: Endocrine Control of the Scrotum and a "Sexual Skin" in the Male Rat, Proc. Soc. Exper. Biol. & Med. 35: 386-387, 1936.
48. Idem: The Effect of Male Hormone Upon the Descent of the Testes, Anat. Rec. 70: 533-541, 1938.
49. Idem: Therapeutics of Testicular Dysfunction, J. A. M. A. 116: 1903-1908, 1941.

50. Hamilton, J. B., and Hubert, G.: Effect of Synthetic Male Hormone Substance on Descent of Testicles in Human Cryptorchidism, Proc. Soc. Exper. Biol. & Med. 39: 4-5, 1938.
51. Hooker, C. W.: Testis Hormone in Relation to Age, Endocrinology 21: 655-658, 1937.
52. Idem: Pubertal Increase in Responsiveness to Androgen in the Male Rat, Endocrinology 30: 77-84, 1942.
53. Howard, E.: Is the X Zone Andromimetic? Am. J. Physiol. 119: 339-340, 1937.
54. Idem: The Representation of Adrenal X Zone in Rats, in Light of Observations on X Zone Variability in Mice, Am. J. Anat. 62: 351-373, 1938.
55. Idem: Effects of Castration on the Seminal Vesicles as Influenced by Age, Considered in Relation to the Degree of Development of the Adrenal X Zone, Am. J. Anat. 65: 105-149, 1939.
56. Hunter, J.: Observations on Certain Parts of the Animal Economy. A Description of the Situation of the Testis in the Foetus, With Its Descent Into the Scrotum, London, 1786, pp. 1-26.
57. Jackson, C. M.: On the Prenatal Growth of the Human Body and the Relative Growth of the Various Organs and Parts, Am. J. Anat. 9: 119-165, 1909.
58. Kitahara, Y.: Ueber die Entstehung der Zwischenzellen der Keimdrüsen des Menschen und der Säugetiere und über deren physiologische Bedeutung, Arch. f. Entwcklngsmechn. d. Organ. 52: 550-615, 1923.
59. Klaatsch, H.: Ueber den Descensus testicülorum, Morphol. Jahrb. 16: 587-646, 1890.
60. Lamar, J. K.: Some Effects of Progestin-Containing Extracts and Progesterone on Young Male Albino Rats, Anat. Rec. (sup.) 70: 45-46, 1937.
61. Idem: Some Effects of Corpus Luteum Extracts and of Synthetic Progesterone on Young Male Albino Rats, Physiol. Zool. 13: 251-266, 1940.
62. Leathem, J. H.: Effect of "Prospermin" on Immature and Mature Hypophysectomized and Normal Male Rats, Proc. Soc. Exper. Biol. & Med. 45: 497-499, 1940.
63. Leathem, J. H., and Mills, E. J.: Influence of Normal Male Urine Gonadotropin on Spermatogenesis in Hypophysectomized Mature and Immature Rats, Endocrinology 31: 318-322, 1942.
64. Leathem, J. H., and Webster, E. C.: Response of Hypophysectomized Male Guinea Pigs to Pregnant Mare Serum, Anat. Rec. (sup. 3) 82: 37, 1942.
65. Leupold, E.: Die Bedeutung des Thymus für die Entwicklung der menschlichen Keimdrüsen, Beitr. z. path. Anat. u. z. allg. Path. 69: 473-491, 1920.
66. Lillie, F. R.: The Freemartin; a Study of the Action of Sex Hormones in the Foetal Life of Cattle, J. Exper. Zoöl. 23: 371-452, 1917.
67. Lockwood, C. B.: Development and Transition of the Testis, Normal and Abnormal, J. Anat. & Physiol. 22: 38-77, 461-478, 505-541, 1888.
68. McCullagh, E. P., and McGurl, F. J.: The Clinical Use of Testosterone Propionate, J. Urol. 42: 1265-1273, 1939.
69. Martins, T.: La testostérone peut provoquer la descente de testicules artificiels de paraffine, Compt. rend. Soc. de Biol. 131: 299-302, 1938.
70. Meyer, R.: Dislocation of the Phallus, Penis and Clitoris Following Pelvic Malformations in the Human Fetus, Anat. Rec. 79: 231-241, 1941.
71. Mitu, G.: Physiologische und pathologische Veränderungen der menschlichen Keimdrüse von der fötalen bis zur Pubertätszeit, mit besonderer Berücksichtigung der Entwicklung, Beitr. z. path. Anat. u. z. allg. Path. 58: 554-641, 1914.
72. Moore, C. R.: Responses of Immature Rat Testes to Gonadotropic Agents, Am. J. Anat. 59: 63-88, 1936.
73. Idem: On the Role of Sex Hormones in Sex Differentiation in the Opossum (Didelphys virginiana), Physiol. Zool. 14: 1-45, 1940.
74. Idem: Physiology of the Testis, J. A. M. A. 116: 1638-1644, 1941a.
75. Idem: Embryonic Differentiation of Opossum Prostate Following Castration and Responses of the Juvenile Gland to Hormones, Anat. Rec. 80: 315-327, 1941b.
76. Moore, C. R., and Morgan, C. F.: Responses of the Testis to Androgenic Treatments, Endocrinology 30: 990-999, 1942.
77. Idem: First Response of Developing Opossum Gonads to Equine Gonadotropic Treatment, Endocrinology 32: 17-26, 1943.
78. Moore, C. R., and Price, D.: Gonad Hormone Functions and the Reciprocal Influence Between Gonads and Hypophysis With Its Bearing on the Problem of Sex-Hormone Antagonism, Am. J. Anat. 50: 13-71, 1932.
79. Moszkowicz, L.: Die Entstehung des Kryptorchismus, Arch. f. klin. Chir. 179: 445-462, 1934.

80. Idem: Das Gubernaculum Hunteri und seine Bedeutung für den Descensus testiculorum beim Menschen, Ztschr. f. Anat. u. Entwcklngsgesch. 105: 37-71, 1935.
81. Mott, F. W.: Normal and Morbid Conditions of the Testes From Birth to Old Age in One Hundred Asylum and Hospital Cases, Brit. M. J. 2: 655-659, 698-700, 737-742, 1919.
82. Mühlmann, M.: Ueber die Ursache des Alters, Weisbaden, 1900, J. F. Bergmann, 195 pages.
83. Nelson, W. O.: Renewal of Sperm Formation in Hypophysectomized rats, Anat. Rec. (sup. 2) 79: 48, 1941.
84. Pellacani, P.: Der Bau des menschlichen Samenstranges, Arch. f. mikr. Anat. 23: 305-335, 1884.
85. Pfeiffer, C. A., and Kirschbaum, A.: Relation of Interstitial Cell Hyperplasia to Secretion of Male Hormone in the Sparrow, Anat. Rec. 86: 211-227, 1943.
86. Politzer, G.: Ueber Zahl, Lage und Beschaffenheit der "Urkeimzellen" eines menschlichen Embryo mit 26-27 Ursegmentpaaren, Ztschr. f. Anat. u. Entwcklngsgesch. 87: 766-780, 1928.
87. Pollock, W. F.: Histochemical Studies of the Interstitial Cells of the Testis, Anat. Rec. 84: 23-29, 1942.
88. Price, D.: Normal Development of the Prostate and Seminal Vesicles of the Rat With a Study of Experimental Post-Natal Modifications, Am. J. Anat. 60: 79-127, 1936.
89. Idem: Normal Development and Regression of the Prostate Gland of the Female Rat, Proc. Soc. Exper. Biol. & Med. 41: 580-583, 1939.
90. Idem: Rat Prostate and Seminal Vesicle Grafts in Relation to Age and Sex of the Host, Physiol. Zool. 14: 145-162, 1941.
91. Idem: A Comparison of the Reactions of Male and Female Rat Prostate Transplants, Anat. Rec. 82: 93-113, 1942.
92. Pullen, R. L., Wilson, J. A., Hamblen, E. C., and Cuyler, W. K.: Clinical Reviews in Andrologic Endocrinology. III. Treatment of Seminal Failure, J. Clin. Endocrinol. 2: 730-736, 1942a.
93. Idem: II. Treatment of Androgenic Failure, J. Clin. Endocrinol. 2: 655-663, 1942b.
94. Rasmussen, A. T.: Special Cytology, vol. 3, edited by E. V. Cowdry, New York, 1932, Paul B. Hoeber, pp. 1675-1725, chap. 42.
95. Reich, H.: Klinische Testikelmessungen bei Kindern, Jahrb. f. Kinderh. 105: 290-300, 1924.
96. Roessle, R., and Roulet, F.: Mass und Zahl in der Pathologie, Berlin and Wien, 1932, Julius Springer, 1,445 pages.
97. Rubinstein, H. S., and Kurland, A. A.: The Effect of Testosterone Propionate on Spermatogenesis in the Human, South. M. J. 32: 499-503, 1939.
98. Sachs, H.: Untersuchungen über den Processus vaginalis peritonei als prädisponirendes Moment für die äussere Leistenhernie, Arch. f. klin. Chir. 35: 321-372, 1887.
99. Sand, K., and Okkels, H.: Histopathologie du Testicule et Sexualitè anormale. Rapport quantitatif entre les divers Composants du Testicule, Compt. rend. Soc. de Biol. 123: 187-193, 1936.
100. Sappey, P. C.: Traité d'Anatomie descriptive (3 me éd revue et ameliaree), vol. 4, Paris, 1879, V. Adrien Delahaye et Cie, pp. 615-616.
101. Saunders, J. B. D., Rusk, G. Y., Lowenstein, B., and Silverberg, M. H.: Observations on the Development of the Genito-Urinary Tract; Illustracted by a Case of Peno-Scrotal Transposition With Absence of the Trigonum Vesicae and Other Anomalies, Medico-Surgical Tributes to Harold Brunn, Berkeley, 1942, University of California Press, pp. 473-501.
102. Scammon, R. E.: In Abt's Pediatrics, vol. 1, Philadelphia, 1923, W. B. Saunders Company, pp. 257-444, chap. 3.
103. Idem: The Growth of the Human Reproductive System, Proc. Second Internat. Cong. for Sex Research, London, 1930, Oliver & Boyd, Ltd., pp. 118-123.
104. Scammon, R. E., and Calkins, L. A.: Simple Empirical Formulae for Expressing the Lineal Growth of the Human Fetus, Proc. Soc. Exper. Biol. & Med. 20: 353-356, 1923.
105. Schwann, T.: Measures des organes internes du corps humain, Acad. Roy. d. Sc., d. Lettr. et-d. Beaux-Artes de Belgique, Nouveau Mém. 16 (235): 51-52, 1843.
106. Selye, H.: Factors Influencing Scrotum Development, Anat. Rec. 85: 377-385, 1943.

107. Selye, H., and Albert, S.: Pubertal Increase of Accessory Sex Organs to Steroid Hormones, Proc. Soc. Exper. Biol. and Med. 49: 361-363, 1942.
108. Selye, H., and Friedman, S.: The Action of Various Steroid Hormones on the Testis, Endocrinology 28: 129-140, 1941.
109. Seymour, F. I., Duffy, C. D., and Koerner, A.: A Case of Authenticated Fertility in a Man, Aged 94, J. A. M. A. 105: 1423-1424, 1935.
110. Shay, H., Gershon-Cohen, J., Paschkis, K. E., and Fels, S. S.: Inhibition and Stimulation of Testes in Rats Treated With Testosterone Propionate, Endocrinology 28: 485-494, 1941.
111. Simkins, C. S.: Origin of Sex Cells in Man, Am. J. Anat. 41: 249-293, 1928.
112. Simpson, M. E., Li, C. H., and Evans, H. M.: Biological Properties of Pituitary Interstitial-Cell-Stimulating Hormone (ICSH), Endocrinology 30: 969-976, 1942.
113. Smith, P. E.: The Disabilities Caused by Hypophysectomy and Their Repair, J. A. M. A. 88: 158-161, 1927.
114. Idem: In Sex and Internal Secretions, edited by E. Allen, Baltimore, 1932, Williams & Wilkins Company, pp. 734-764, chap. 15.
115. Idem: In L. Brouha, Les hormones sexuelles, Paris, 1938, Hermann and Cie, pp. 201-216, pt. III.
116. Idem: Effect of Equine Gonadotropin on Testes of Hypophysectomized Monkeys, Endocrinology 31: 1-12, 1942.
117. Smith, P. E., and Engle, E. T.: Experimental Evidence Regarding the Role of the Anterior Pituitary in the Development and Regulation of the Genital System, Am. J. Anat. 40: 159-217, 1927.
118. Smith, P. E., and Leonard, S. L.: Responses of the Reproductive System of Hypophysectomized and Normal Rats to Injections of Pregnancy-Urine Extracts. I. The Male, Anat. Rec. 58: 145-174, 1933.
119. Spangaro, S.: Ueber die histologischen Veränderungen des Hodens, Nebenhodens und Samenleiters von Geburt an bis zum Greisenalter, mit besonderer Berücksichtigung der Hoden-Atrophie, des elastischen Gewebes und des Vorkommens von Krystallen im Hoden, Anat. Hefte 18: 593-768, 1902.
120. Spaulding, M. H.: The Development of the External Genitalia in the Human Embryo, Carnegie Institution of Washington, Contrib. to Embryol. 13: 67-88, 1921.
121. Steinach, E., and Kun, H.: Die entwicklungsmechanische Bedeutung der Hypophysis als Aktivator der Keimdrüseninkretion, Med. Klin. 24: 524-529, 1928.
122. Idem: Hyperaemia as a Test of Male Sex Hormone, Lancet 238: 688-689, 1940.
123. Stieve, H.: Die Entwicklung der Keimzellen und der Zwischenzellen in der Hodenanlage des Menschen, Ztschr. f. mikr.-anat. Forsch. 10: 223-285, 1927.
124. Thompson, D. L., Collip, J. B., and Selye, H.: The Antihormones, J. A. M. A. 116: 132-136, 1941.
125. Thompson, W. O., and Heckel, N. J.: Undescended Testes; Present Status of Glandular Treatment, J. A. M. A. 112: 397-403, 1939a.
126. Idem: Male Sex Hormone; Clinical Application, J. A. M. A. 113: 2124-2127, 1939b.
127. Tyrrell, W. P., Andrews, F. N., and Zelle, M. R.: Effect of Post-Pubertal Castration on Thermo-Regulatory Function of Rat Scrotum, Endocrinology 31: 379-383, 1942.
128. Vultorta, F.: Ricerche sullo sviluppo dei visceri del feto. La individualità nel neonato. Ann. di. ostet. e ginec. 31: 673-713, 1909.
129. Vatna, S.: Rat Vas Deferens Cytology as a Testis Hormone Indicator and the Prevention of Castration Changes by Testis Extract Injections, Biol. Bull. 58: 322-335, 1930.
130. Vest, S. A., and Howard, J. E.: Clinical Experiments With the Use of Male Sex Hormones. I. Use of Testosterone Propionate in Hypogonadism, J. Urol. 40: 154-183, 1938.
131. Vvedenski, V. M.: The Testes and the Seminal Vesicles in Children (Russian Thesis), St. Petersburg, 1900, 113 pp.
132. Wald, H., and Scammon, R. E.: Prenatal Growth of the Testes and Ovaries, Proc. Soc. Exper. Biol. & Med. 29: 416-420, 1932.
133. Waldeyer, W.: Das Becken, Cohen, Bonn, 690 pp., 1899.
134. Webster, B.: The Treatment of Hypogonadism in the Adolescent Male, J. Pediat. 13: 847-858, 1938.

135. Welcker, H., and Brandt, A.: Gewichtswerthe der Körperorgane bei dem Menschen und den Thieren, Arch. f. Anthrop. 28: 1-89, 1903.
136. Wells, L. J.: Seasonal Sexual Rhythm and Its Experimental Modification in the Male of the Thirteen-Lined Ground Squirrel (Citellus tridecemlineatus), Anat. Rec. 62: 409-447, 1935a.
137. Idem: Stimulation of the Reproductive System of Male Ground Squirrels by Injections of Blood Serum From Pregnant Mares, Anat. Rec. (sup.) 61: 49, 1935b.
138. Idem: Reproductive Organs of Two Mammalian Hermaphrodites and Their Response to Injections of Pregnant Mare Serum, Anat. Rec. 67: 233-251, 1937a.
139. Idem: The Fibro-Muscular Scrotal Sac Under Normal and Experimental Conditions in an Annual Breeder (Citellus), Proc. Soc. Exper. Biol. & Med. 36: 625-629, 1937b.
140. Idem: Gonadotropic Potency of the Hypophysis in a Wild Male Rodent With Annual Rut, Endocrinology 22: 588-594, 1938.
141. Idem: The Response of the Testis to Androgens Following Hypophysectomy, Anat. Rec. 82: 565-585, 1942a.
142. Idem: The Reaction of the Testis to Synthetic Androgens, Anat. Rec. (sup.) 82: 479, 1942b.
143. Idem: The Effects of Large Doses of Androgens on the Testis in the Ground Squirrel, Endocrinology 32: 455-462, 1943.
144. Wells, L. J., and Gomez, E. T.: Hypophysectomy and Its Effects on Male Reproductive Organs in a Wild Mammal With Annual Rut (Citellus), Anat. Rec. 69: 213-227, 1937a.
145. Idem: Some Effects of Crystalline Androgenic Materials on Spermatogenesis in Normal and Hypophysectomized Male Ground Squirrels, Anat. Rec. (sup. 3) 67: 52-53, 1937b.
146. Wells, L. J., and Moore, C. R.: Hormonal Stimulation of Spermatogenesis in the Testis of the Ground Squirrel, Anat. Rec. 66: 181-200, 1936.
147. Wells, L. J., and Overholser, M. D.: Effects of Testis Removal on the Fibromuscular Scrotal Sac in the Albino Rat, Anat. Rec. (sup. 1) 70: 119-120, 1937.
148. Idem: Sperm Formation and Growth of Accessory Reproductive Organs in Hypophysectomized Ground Squirrels in Response to Substances From Blood and Human Urine, Anat. Rec. 72: 231-247, 1938.
149. Idem: Sperm Formation Induced by Androgens Following Anterior Pituitary Removal, Anat. Rec. (sup. 2) 73: 56, 1939.
150. Wells, L. J., and Zalesky, M.: Effects of Low Environmental Temperature on the Reproductive Organs of Male Mammals With Annual Aspermia, Am. J. Anat. 66: 429-447, 1940.
151. Willier, B. H.: In Sex and Internal Secretions, chap. 3, Edited by E. Allen, C. H. Danforth, and E. A. Doisy, ed. 2, Baltimore, 1939, Williams & Wilkins Company, pp. 64-144.
152. Wilson, J. G., and Young, W. C.: Sensitivity to Estrogen Studied by Means of Experimentally Induced Mating Responses in the Female Guinea Pig and Rat, Endocrinology 29: 779-783, 1941.
153. Wilson, K. M.: Origin and Development of the Rete Ovarii and the Rete Testis in the Human Embryo, Carnegie Institution of Washington, Contrib. to Embryol. 17: 69-88, 1926.
154. Winiwarter, H. von: La constitution et l'involution du corps de Wolff et le development du canal de Müller dans l'espèce humaine, Arch. de. biol. 25: 169-267, 1910.
155. Wintersteiner, O.: Adrenogenital Syndrome, J. A. M. A. 116: 2679-2683, 1941.
156. Wislocki, G. B.: Observations on the Descent of the Testes in the Macaque and in the Chimpanzee, Anat. Rec. 57: 133-148, 1933.
157. Wolnack, E. B., and Koch, F. C.: Studies on the Extraction of the Testicular Hormone From Tissues and on Its Quantitative Distribution Therein, Endocrinology 16: 267-272, 1932.
158. Zalesky, M., Wells, L. J., Overholser, M. D., and Gomez, E. T.: Effects of Hypophysectomy and Replacement Therapy on the Thyroid and Adrenal Glands of the Male Ground Squirrel, Endocrinology 28: 521-530, 1941.
159. Zondek, B., Brzezinski, A., and Sulman, F.: Does a Stimulation of the Germinative Epithelium on Immature Male Rats Occur After Treatment With Gonadotropic Hormones, Augmentative Substance, Androgens and Vitamin E? Endocrinology 30: 25-31, 1941.
160. Zondek, B., and Sulman, F.: The Antigonadotropic Factor With Consideration of the Antihormone Problem, Baltimore, 1941, Williams & Wilkins Company, pp. 193.

Review of Recent Meetings

REPORT OF THE ANNUAL MEETING OF THE AMERICAN SURGICAL ASSOCIATION, MAY 13 AND 14, 1943, CINCINNATI, OHIO

J. Dewey Bisgard, M.D., Omaha, Neb.

PRESIDENTIAL address, **Vernon C. David**, Chicago.—From a historical review of the influence of wars on medical education there was evolved a discussion of the influences of the current war and the problems imposed by it upon medical education, both present and future. The accelerated program, the reduction of faculty personnel, and the curtailment of postgraduate training and of research is likely to result in some qualitative reducation of medical education.

It is imparative to formulate a comprehensive plan to provide postgraduate training for those who entered the service before completion of such training.

Closer cooperation and more overlapping of the clinical and fundamental departments in medical education should be encouraged. The present high standard of qualification for a degree in medicine and especially for certification by specialty boards should be maintained.

Experimental and Clinical Studies on the Effects of Pedicle Grafts of Jejunum in the Wall of the Stomach on Gastric Secretion, William DeW. Andrus, Jere W. Lord, Jr. (by invitation), and **Paul Stefko**, New York.—In animals, small (4 by 6 cm.) segments of jejunum with circulation intact implanted in the wall of the stomach caused a reversal of the normal reaction to histamine as reflected both in the gastric analysis and in direct measurements of the pH of the gastric mucosa. This inhibitory effect was also evident when alcohol was used as the secretory stimulus. A study of the effects of grafts from different portions of the intestinal tract indicated that the substance respousible was confined to the jejunum and duodenum where it could be demonstrated in washings of isolated loops.

Such grafts were efficacious in preventing and curing experimental ulcers in animals.

This operation has been done in four refractory cases of peptic ulcer with alterations of gastric secretions as in the animals and with symptomatic relief in three.

Gastric and Duodenal Ulcers in the Naval Personnel, Waltman Walters, Captain, M.C., U.S.N.R., and **Hugh R. Butt** (by invitation), Lieutenant, M.C., U.S.N.R.—Medical management for patients with ulcer on active duty aboard ship is difficult and frequently impossible.

Hypersecretion and hyperperistalsis are a part of seasickness, hence Naval personnel with chronic duodenal ulcers who desire to remain in the service are best operated upon, the operation of choice being partial gastrectomy. Ninety per cent of patients with peptic ulcers have had these ulcers before entering the service and 50 per cent of these become invalided in the service. The interesting problem arises, can a man be returned to active duty after a resection of the stomach.

In a series of thirteen cases in which gastric resection was done, eleven of the patients have been returned to active duty and all are getting along without symptoms. Eighty-five per cent of the operations performed for peptic ulcer in the naval service have been resections of the Polya type.

In the discussion **L. R. Dragstedt, Chicago,** stated that most experimental and clinical evidence indicated that hyperacidity is the principal cause of ulcer and that some hormone as histamine may be the exciting factor. He referred to his experiments in which ulcers developed in pedicle grafts of jejunum in the wall of the stomach of dogs and was unable to rationalize his results with those reported just previously. **J. S. Horsley, Richmond, Va.,** saw little cause for difference in the physiologic response to the pedical graft of jejunum and the established gastrojejunostomy.

Physiological Problems in Surgery of the Pancreas, Lester R. Dragstedt, Chicago.—It is probable that both man and the lower animals may survive and maintain a good nutritive state following total duodenectomy provided the free flow of pancreatic juice and bile into the upper intestine is not prevented. Complete removal of the pancreas produces a permanent impairment but one which can be fairly adequately controlled with insulin and lipocaic. The necessity for insulin and lipocaic following ligation of the pancreatic ducts depends upon the degree to which the atrophy of the pancreas affects the islet tissue. The digestive disturbance produced by the absence of pancreatic juice from the intestine can be only partially corrected by replacement therapy.

Depancreatized dogs survive for long periods of time with insulin only if supplemented by feedings of pancreatic tissue. Fifty per cent of the dogs in which the pancreatic ducts have been ligated develop fatty livers, probably from the deficiency of lipocaic. There is evidence that lipocaic is a hormone derived from the alpha cells of the islets.

A. O. Whipple, New York, during the discussion, stressed the desirability of preserving the external secretion of the pancreas in delivering the secretions into the proximal small bowel. This he has accomplished in his last seven cases of pancreatoduodenectomy. In two cases the pancreatic fistula was subsequently transplanted to the jejunum and in three the exposed pancreatic duct in the cut surface of the pancreas was anastomosed to the side of the jejunum. Some patients deprived of pancreatic juice show reduction of fat tolerance.

In two cases, eighteen months and three years after resection of the duodenum and partial resection of the pancreas with ligation of the pancreatic duct, the liver showed no abnormal deposition of fat.

A. Brunschwig, Chicago, reported one case in which almost the entire pancreas was removed with a benign tumor and no diabetes developed. Necropsy examination of two cases five and five and one-half months after pancreatoduodenectomy with ligation of the pancreatic duct showed survival of much of the acinous tissue as well as islet tissue.

R. B. Cattell, Boston, reported seven cases of resection in which the pancreatic duct was anastomosed to the jejunum with a necrosing suture as used by Coffee in ureterocolic anastomosis.

The Recognition and Management of Acute Trauma to the Pancreas With Particular Reference to the Use of the Serum Amylase Test, Howard A. Naffziger, and H. J. McCorkle (by invitation), San Francisco.—When the abdomen is injured, occasionally the pancreas may be wounded. Injury to the pancreas also may occur during operations on the stomach, duodenum, pancreas, or spleen. The use of the serum amylase test in such cases has made possible a more accurate diagnosis of pancreatic injury. Serial determinations of the serum amylase also

give some indication that the enzyme is continuing to leak from the wounded pancreas. This test for serum amylase has been useful in the recognition and in the management of acute injuries to the pancreas.

Studies in seven cases of traumatic injury of the pancreas were reported showing the early rise in serum amylase. In two cases of partial resection of the pancreas there was also early rise and a prompt fall with cessation of fistulous drainage.

Skin Removal in the Radical Breast Amputation, J. Stewart Rodman, Philadelphia.—Recent papers from large clinics admit 25 per cent or more local or skin recurrences. It is believed that such a high percentage of local recurrences are unnecessary and indicate insufficient skin removal.

Reported were 132 personal cases in which the Rodman operation was used; there were 61 per cent of five-year cures. Only 2.2 per cent developed local recurrences. Primary closure of the wound without skin grafting was possible in all cases.

In the discussion, **D. Guthrie,** Sayre, Pa., stated that local recurrences in the skin occurred often without remote matastases and for this reason should be excised.

S. Harrington, Rochester, Minn., stated that the type of incision should depend upon the location of the tumor in the breast. A tumor in the superior lateral quadrant is adequately skirted by a very different incision than one in the upper mesial quadrant. **G. J. Heuer,** New York, presented evidence in support of the wide excision of skin in the Halsted operation and the use of grafts to close defects when necessary. **W. C. White,** New York, stated that the frequency of local recurrences depends upon the type of cases included in one's report. Local recurrences are much more frequent in advanced cases encountered in charity institutions than in earlier cases as seen in private practice.

Amputations in War, Norman T. Kirk, Brigadier General, M.C., U. S. Army.—The guillotine or flapless type amputation is the amputation of choice, the simplest, quickest, and easiest method of amputation on a badly shocked or critically ill patient, for the removal of a hopelessly destroyed extremity and as a life-saving measure when amputation is indicated in the presence of infection such as gas gangrene, a septic joint, or an uncontrolled osteomyelitis.

Skin traction following amputation either by the use of zinc oxide adhesive plaster or stockinet with Ace Adherent is essential after surgery. Healing, if infection has not been too severe in this type stump, will be almost complete at the end of six weeks.

Primary closure of war wounds is a dangerous procedure. Experience in World War II has shown that where primary suture of wounds is attempted or where wounds are tightly packed, they soon became grossly infected.

A guillotine amputation is a two-stage amputation. The repair of the guillotine stump may be classified as a plastic closure, plastic resection when bone shortening is necessary, or reamputation when the stump is too long or too short.

Surgical Principles Opposed to Rule-of-Thumb in the Treatment of Compound Fractures, Clay Ray Murray, New York.—There is a great deal of investigative work being carried out at the present time on the treatment of compound fractures. Many of the conclusions voiced are obtained by punch-card analyses of the effects of single factors in the treatment of the case groups. This is productive of actuarial statistics which may determine accurately the percentage chance a patient has under the routine use of a given procedure, but which run the risk of being of doubtful value as criteria for the treatment of any individual case. Moreover, their adoption as a basis for a routine procedure may lead to violation of known and accepted surgical principles in the individual case.

In a series of thirteen cases in which gastric resection was done, eleven of the patients have been returned to active duty and all are getting along without symptoms. Eighty-five per cent of the operations performed for peptic ulcer in the naval service have been resections of the Polya type.

In the discussion **L. R. Dragstedt**, Chicago, stated that most experimental and clinical evidence indicated that hyperacidity is the principal cause of ulcer and that some hormone as histamine may be the exciting factor. He referred to his experiments in which ulcers developed in pedicle grafts of jejunum in the wall of the stomach of dogs and was unable to rationalize his results with those reported just previously. **J. S. Horsley**, Richmond, Va., saw little cause for difference in the physiologic response to the pedical graft of jejunum and the established gastrojejunostomy.

Physiological Problems in Surgery of the Pancreas, Lester R. Dragstedt, Chicago.—It is probable that both man and the lower animals may survive and maintain a good nutritive state following total duodenectomy provided the free flow of pancreatic juice and bile into the upper intestine is not prevented. Complete removal of the pancreas produces a permanent impairment but one which can be fairly adequately controlled with insulin and lipocaic. The necessity for insulin and lipocaic following ligation of the pancreatic ducts depends upon the degree to which the atrophy of the pancreas affects the islet tissue. The digestive disturbance produced by the absence of pancreatic juice from the intestine can be only partially corrected by replacement therapy.

Depancreatized dogs survive for long periods of time with insulin only if supplemented by feedings of pancreatic tissue. Fifty per cent of the dogs in which the pancreatic ducts have been ligated develop fatty livers, probably from the deficiency of lipocaic. There is evidence that lipocaic is a hormone derived from the alpha cells of the islets.

A. O. Whipple, New York, during the discussion, stressed the desirability of preserving the external secretion of the pancreas in delivering the secretions into the proximal small bowel. This he has accomplished in his last seven cases of pancreatoduodenectomy. In two cases the pancreatic fistula was subsequently transplanted to the jejunum and in three the exposed pancreatic duct in the cut surface of the pancreas was anastomosed to the side of the jejunum. Some patients deprived of pancreatic juice show reduction of fat tolerance.

In two cases, eighteen months and three years after resection of the duodenum and partial resection of the pancreas with ligation of the pancreatic duct, the liver showed no abnormal deposition of fat.

A. Brunschwig, Chicago, reported one case in which almost the entire pancreas was removed with a benign tumor and no diabetes developed. Necropsy examination of two cases five and five and one-half months after pancreatoduodenectomy with ligation of the pancreatic duct showed survival of much of the acinous tissue as well as islet tissue.

R. B. Cattell, Boston, reported seven cases of resection in which the pancreatic duct was anastomosed to the jejunum with a necrosing suture as used by Coffee in ureterocolic anastomosis.

The Recognition and Management of Acute Trauma to the Pancreas With Particular Reference to the Use of the Serum Amylase Test, Howard A. Naffziger, and **H. J. McCorkle** (by invitation), San Francisco.—When the abdomen is injured, occasionally the pancreas may be wounded. Injury to the pancreas also may occur during operations on the stomach, duodenum, pancreas, or spleen. The use of the serum amylase test in such cases has made possible a more accurate diagnosis of pancreatic injury. Serial determinations of the serum amylase also

emphasized the necessity of removing necrotic tissue to permit intimate contact of the peroxide to the tissues.

The Parenteral Administration of Fluids During the Operation and the Immediate Postoperative Period in the Light of Additional Knowledge of the Effects of Surgical Anesthesia (Ether, Cyclopropane, and Avertin), Upon Renal Function in Man, Frederick A. Coller, Carl A. Moyer (by invitation), Kenneth N. Campbell (by invitation), and Vincent L. Rees (by invitation), Ann Arbor, Mich.—With ether anesthesia renal blood flow increases or remains relatively unchanged provided that blood pressure does not fall significantly either as a result of blood loss or deep anesthesia.

The rate of glomerular filtration (inulin clearance) decreases under ether anesthesia excepting when renal blood flow is increased.

Cyclopropane anesthesia is attended by a significant decrease in the rate of glomerular filtration although renal blood flow and blood pressure may be greatly increased. The association of a loss of blood sufficient to induce a fall in blood pressure with cyclopropane anesthesia may be associated with "total renal failure."

The duration of the renal impairment as indicated by the decreased glomerular filtration rate and total urinary volume varies from a few hours to a week; it seems to depend somewhat upon the relative amount of blood lost and in patients losing little blood, upon the severity of the blood pressure fall.

Therefore, the maintenance of extracellular fluid volume and acid-base equilibrium during the operative and immediate postoperative period cannot be safely effected with the simple repair solutions, or saline or Ringer's solution, because their physiologic effectiveness depends upon selective excretion by the kidney of the excess chloride ion.

The parenteral administration of these fluids even in relatively small amounts during the period of renal impairment has been found to induce a fulminating and even fatal acidosis in some individuals.

During the discussion, **F. A. Coller**, Ann Arbor, Mich., reported two patients who developed oliguria and chloride intoxication with retention of water and marked distention and prostration with an impending fatal outcome as a result of the excessive administration of sodium chloride following operation. These were cured by the administration of sodium lactate, withholding the fluids, and in one case an ileostomy. He recommends that no sodium chloride be given in the fluids for the first two days following operation unless there has been an appreciable loss of chlorides in vomitus, aspirated stomach content, or other means. The retention of chlorides resulting from failure of filtration through the kidney following anesthesia in operations may result in a dangerous chloride intoxication.

A. Blalock, Baltimore, in the discussion, stated that this was a timely warning because there was a dangerous prevailing idea that salt solution could be administered with impunity.

Pilonidal Cysts and Sinuses, John C. Burch, Lt. Col., M.C., U. S. A., **Max Levine**, Major, S.N.C. (by invitation), **Thomas E. Smith**, Captain, M.C. (by invitation), and **Frank C. Shute, Jr.**, Captain, M.C.—Since Jan. 1, 1942, there have been 114 cases of pilonidal cysts in the Brooke General Hospital. Eighty-five per cent of the patients are completely healed and on duty. In cases of pilonidal cysts and sinuses the problem of treatment has revolved around the question of closing the wound to obtain primary healing or leaving it open to granulate in. Of fifty-nine cases in which the wounds were closed, forty-eight were healed in eight days and remained healed without recurrence. Eleven were completely healed in twenty-four days. This was accomplished by preoperative treatment for the sterilization of the sinus in so far as possible, attention to adequate sharp dissection, meticulous hemostasis, and the use of nonabsorbable sutures and postoperative pressure

The soft tissue wound and fracture should be considered as parts of the same problem and every effort made to prevent infection and the damage resulting from infection. This is accomplished by removal of as much contamination of the wound as possible, removal of dead and devitalized tissue, obliteration of dead spaces, the closure of the wound without tension, and rest of the part. In addition, the fracture must be reduced and maintained in reduction. Since there is no evidence that sulfonamide drugs cause harm in the wound and since there is evidence that they may limit if not prevent infection it is advisable to use them.

F. L. Meleney, New York, in the discussion, stated that an evaluation of methods of treating wounds and compound fractures could be attained only by analyzing a large group of cases under controlled conditions, and that some standardization of treatment is necessary in a military surgery.

The Medical Treatment of Acute Infectious Osteomyelitis, D. E. Robertson, Toronto.—Twenty-five cases of acute infectious osteomyelitis in children treated by sulfonamides and without the assistance of either splinting or surgical operation during the acute phase were compared with those treated by sulfonamides plus early operation upon the lesion or abscess produced by the lesion.

The results obtained in patients treated by sulfonamides without early operation are very much better than those treated by other means.

In the former group there was a mortality of 4 per cent as compared to a mortality of 20 per cent in those treated before the advent of the sulfonamides. These children were given 8 to 10 Gm. of sulfathiazole daily.

The fact that the disease in the first instance arises from an infection of a superficial tissue and becomes a septicemia and later again becomes a bone lesion, makes it rational to attack it early with a bacteriostatic drug that will prevent its wide dissemination via the blood stream, and its local invasion to form local lesions in bone. During the administration of sulfonamides it can be demonstrated that the individual's protective reaction to the organism and its toxin is not interfered with but carries on with increasing power in response to the antigen of the toxin.

Some of the bone abscesses and subperiosteal abscesses disappeared spontaneously. Others were aspirated, and some left alone discharged spontaneously. It is felt that the pathologic appearance of the involved bone had changed, that sequestra were rarely formed, involucrum was much smaller in extent, and that destruction of bone was much limited.

K. Speed, Chicago, in the discussion, agreed that operative interference should be delayed and the reliance placed in the sulfonamide drugs during the acute stage. He felt that there was an opportune time for the institution of drainage. Penicillin may prove even more effective than the sulfonamide drugs.

J. A. Key, St. Louis, expressed the belief that early drainage was often necessary and desirable in conjunction with the sulfonamide therapy. **D. E. Robertson**, Toronto, in closing, stated that he was now using sulfadiazine in these cases.

Peroxide Ointments, Mont R. Reid, and William A. Altemeier (by invitation), Cincinnati.—The value of peroxide therapy in certain types of infections is well established, but previous methods of application were not entirely satisfactory. Various peroxides can be incorporated in a carbo-wax guaiacol base and applied to the wounds as an ointment very satisfactorily. These ointments have been prepared by the authors with the aid of Merrill and Company.

Zinc peroxide has proved the best one to incorporate in an ointment for most purposes. It liberates oxygen in contact with a wound over a period of five or more days, as a single dressing. Urea peroxide liberates oxygen rapidly and is more irritating, but is very effective in early treatment of Lewisite burns.

In the discussion, **F. L. Meleney**, New York, stated that he had developed a similar ointment of zinc peroxide and had found it stable and satisfactory. He

unanesthetized dog. Death occurred after an average of about 40 c.c. per kilogram had been removed. The removed amount of blood in a single bleeding was less often fatal.

Immediate replacement of the volume of lost blood by a 10 per cent solution of glucose did not alter the results. However, if the solution contained 5 per cent of glucose and 5 per cent of the amino-acids of hydrolyzed casein or beef serum, the amount of blood which could be removed before death was increased to an average of 55 c.c. and the survival time was prolonged by 40 per cent. A comparative study of the effect of immediate replacement with pure amino-acid solutions, serum, citrated plasma, and heparinized plasma, proved that the first three were no better than the hydrolyzate. The heparinized plasma was the best of all, permitting removal of an average of 67 c.c. per kilogram before death and an increase in the survival time of 60 per cent.

Microscopic observations of biopsy specimens of the liver indicated that the beneficial effect of the injections of hydrolyzed protein were probably due to the replenishment of hepatic protein, thus enabling the animal to withstand further loss of blood more effectively.

There is much evidence that the citrate used in citrated plasma has a very toxic and deleterious effect; this explains the superior results obtained from heparinized plasma.

In the discussion, L. R. Dragstedt, Chicago, questioned the statement that amino acids merely replace tissue proteins and that they could be converted to plasma. C. C. Lund, Boston, stressed the desirability of a substitute for plasma in situations in which sufficient plasma is not available or in which the cost makes its adequate use almost prohibitive.

The Role of the Nervous System in the Production of Shock, Dallas B. Phemister, Chicago.—To lower the blood pressure to shock levels by as purely a neurogenic mechanism as possible, the cardio-aortic nerves of the rabbit and the carotid sinus nerves of the dog were stimulated electrically under anesthesia. Maintenance of the blood pressure at or below the threshold shock level of 70 mm. of mercury by continuous stimulation resulted in death of the animals in six to nine hours in a state of shock during the terminal period. In control experiments with only the nerve stimulus deleted, the animals lived up to twenty hours in the case of rabbits and to thirty-five hours in the case of dogs. However, it was possible by continuous stimulation to maintain blood pressure at low shock levels for three to five hours with remarkably little impairment of the circulation. Release of the stimulus in the course of this period was followed promptly by restoration of pressure to the initial level, bleeding was also well tolerated, and blood changes were very slight.

When the animal was first bled repeatedly until an impending or actual state of shock was reached, stimulation started then would cause a further drop in blood pressure and continuation of it would hasten death. However, loss of quantities of blood up to 15 per cent of the total blood volume made little difference.

Exposure of somatic nerves and stimulation by cutting, pinching, or stretching as might occur in accidental and war wounds, or stimulation by an electric current, yielded varying results on blood pressure, from a slight rise to a slight fall under varying experimental conditions. However, under no circumstances was a marked and prolonged fall in blood pressure produced in any way simulating shock.

Aseptic section of the spinal cord of the dog at the seventh cervical vertebra under evipal anesthesia lasting about three fourths of an hour interrupted all vasomotor impulses from higher centers and lowered blood pressure to 70 mm. or below, where it remained for two to four days without the appearance of the picture of severe traumatic shock. Subsequently, the blood pressure gradually rose.

dressings. In many of these cases the dead space was obliterated by an operative technique described by the author. This involved an incision through the gluteal fascia and muscle lateral to the sacrum, approximation of the mesial edges of each side rolling the flaps in over the sacrum and coccyx, and the approximation of the lateral flaps to each other in the midline. The skin was approximated over this.

In the discussion, **H. B. Stone**, Baltimore, emphasized the essential principals of cleaning up the infection preoperatively, of complete removal of the sinus, of closing the wound to obliterate the dead space and without tension.

H. F. Graham, Brooklyn, suggested that the sinus be sterilized by electrocoagulation as a first step in excision. **J. M. Mason**, Birmingham, stressed the point that such cases were seen infrequently in civilian practice.

Prevention of Infection in Accidental Wounds and Burns, Frank L. Meleney, New York.—Under the auspices of the national research council there has been carried out during the past year an extensive study on the prophylaxis of wound infection, in civilian accidental wounds, compound fractures, and burns. These observations have been made in nine different medical centers in this country.

The bacteriologic aspects of the problem were carefully considered, including the primary and secondary contamination. The course of the wound healing was carefully observed. The data from the records were transferred to punch cards and statistically analyzed. Various forms of treatment have been used in order to determine, if possible, the role of the newer chemotherapeutic agents in the prevention and treatment of infection and the role of other factors.

There were collected 682 cases with major injuries of the soft tissues, 471 compound fractures, and 347 burns. There was a slightly larger number of infections in cases in which the wounds were irrigated with salt solution and in those which were debrided. Also there was a slightly less incidence of infection in the compound fractures which were closed.

The mortality from infection in these cases was extremely low. While the sulfonamides as they were used in this series almost certainly minimized septicemia and the generalized spread of infection, they did not lower the incidence of local infections.

There was a slightly higher incidence of infection in those cases in which the sulfonamide drugs were used in the wounds. In burns the best results were obtained from the use of vaseline gauze and pressure dressings. The addition of sulfonamide drugs administered by mouth and by topical application caused a slight reduction in the incidence of infection.

E. Graham, St. Louis, discussed this project of the National Research Council stating that the precipitation of war at Pearl Harbor and observations made in respect to the use of sulfonamide drugs in the wounds following this attack augmented and accelerated the project.

J. S. Lockwood, Philadelphia, stated that the use of the sulfonamide drugs was justified upon the evidence that they prevented widespread infection and lowered mortality, irrespective of evidence of failure to minimize local infection. He spoke of the favorable early reports upon the use of penicillin.

J. A. Key, St. Louis, believed that this study did not give a true picture of the bacteriostatic value of the sulfonamide drugs. His clinical observations had given a much more favorable picture.

An Experimental Study on the Use of Serum, Plasma and Amino-Acids in the Replacement Therapy of Fatal Shock Due to Repeated Hemorrhage, Robert Elman, and Carl E. Lischer (by invitation), St. Louis.—Fatal surgical shock was produced experimentally by rapidly bleeding 10 c.c. per kilogram every hour in the

encourages infection, the ingrowth of fibroblasts, the necrosis of tissue, and retards epithelization and healing.

Drinker produced thermal burns of both paws of cats simultaneously and immediately applied a pressure dressing to one of them. There resulted no edema, no tissue necrosis, and a much more rapid healing than in the control paw which received no pressure dressing. The evidence at present favors the use of pressure dressings in the local treatment following aseptic means of handling the burned surfaces, the use of sulfonamide drugs in an effort to prevent infection, and the use of plasma in the liberal, indicated quantities to prevent and control burn shock.

Early grafting of surfaces is indicated, grafting suitable parts of the areas between other areas in which necrotic tissue is still present. Dressings should be infrequent and always carried out with the aseptic surgical technique used in the operating room.

Bovine Bone Gelatin as a Plasma Substitute in Hemorrhage and Burn-Shock, John S. Lockwood, W. M. Parkins (by invitation), C. E. Koop (by invitation), C. Riegel (by invitation), and H. M. Vars (by invitation), Philadelphia.—A solution of 6 per cent gelatin in saline solution, with a colloid osmotic pressure higher than plasma, was investigated as a plasma substitute.

Normal dogs tolerate repeated weekly infusions of amounts of gelatin-saline equivalent to 60 per cent of the circulating plasma volume without evidence of toxic reactions specific to the gelatin. Unfavorable reactions that do occur are reversible, and are produced by infusion of comparable amounts of saline or plasma.

About 50 per cent of the gelatin is excreted in the urine within forty-eight hours and most of the remainder may be utilized as a form of available protein.

Because of its capacity to maintain colloid osmotic pressure and blood volume, gelatin is superior to saline in compensating for blood loss in severe hemorrhage.

Gelatin produces pseudoagglutination and more hemodilution than plasma. In experimental burns in animals it was much less effective in controlling burn shock than plasma.

L. S. McKittrick, Boston, briefly reviewed the observations made in the treatment of burned patients received at the Massachusetts General Hospital following the Cocoanut Grove disaster. Factors contributing most to the success were strict isolation, strict surgical aseptic dressings, boric acid ointment pressure dressings of the burned surfaces, infrequent dressings, and sulfadiazine and penicillin administered orally or parentally. Many patients had severe injuries to the trachea as a result of irritating gases. Five required tracheotomy. It was the impression that possible errors in the treatment consisted of the administration of too much salt solution and morphine.

S. L. Koch, Chicago, reviewed his principles of the handling of burns, stressing the necessity of strict surgical asepsis. **R. Elman, St. Louis,** stressed the necessity of maintaining nitrogen balance and the importance of the state of nutrition in the success of grafting. Grafts are less likely to take if the general nutrition is impaired.

M. D. Morrow, M.C., U.S.N., described a method of taking grafts in which the full thickness of skin is excised and the edges which remain are brought together and sutured for primary healing. The excised segment is then entirely freed of fat, and cut into from 100 to 200 small bits of skin which are placed on the granulating surface as pinch grafts.

Improved Diagnosis and Treatment of Ruptured Intervertebral Disks, Walter E. Dandy, Baltimore.—Ruptured lumbar intervertebral disks can always be diagnosed without spinal injections of air or lipiodol or even without lumbar punc-

The results of these experiments indicate that in the absence of blood and plasma loss, the blood pressure may be lowered to shock levels for many hours by reflex nervous inhibition before a state of shock is created. Such lowering could be produced only by stimulation of special depressor nerves, and somatic nerves involved in ordinary wounds did not in consequence convey afferent impulses which resulted in marked and prolonged lowering of blood pressure. Psychic influences created by pain and disturbing special sense impulses occasioned by a wound may cause reflex lowering of blood pressure and syncopy; when these are superimposed on shock produced by blood or plasma loss, it may be thereby aggravated. Primary shock produced exclusively through the nervous system would appear to be a very improbable occurrence.

A Study of Traumatic Shock by the Use of Radioactive Plasma Proteins, Jacob J. Fine, Boston.—Plasma proteins containing radioactive sulfur, bromine, and iodine were synthesized for the determination of the degree to which capillary permeability is altered in traumatic shock. Hemorrhagic, burn, and tourniquet shock were studied. The evidence clearly contradicts the theory of a generalized increase in capillary permeability and widespread extravascular loss of plasma. Except in burn and tourniquet shock a local loss of plasma, as such is usually insignificant. While plasma loss is the most significant initiating cause of shock, the irreversibility of the shock state is not due to a progressive decline in plasma volume, but rather, to a progressive deterioration of the peripheral circulatory mechanism, characterized by decreased volume flow and velocity flow through capillaries. The most important factor is the stagnation or trapping of blood in the capillaries. The evidence suggests that this deterioration arises from a chemical or hormonal disturbance induced by damage to tissue function arising from the initial but uncorrected crucial loss of plasma volume and possibly from toxic agents elaborated in traumatized tissues. Treatment designed to move the trapped blood out of the capillaries into the normal moving volume of blood would contribute much to shock therapy.

During the discussion, **A. Blalock,** Baltimore, stated that shock results from a combination of regional loss of blood and plasma, neurogenic influences, and metabolic or toxic factors. The latter factor is a fruitful source in the search of further means of therapy.

Nitrogen Metabolism in Severe Burns, Charles C. Lund, F. H. L. Taylor (by invitation), **Stanley H. Levenson** (by invitation), and **Charles S. Davidson** (by invitation), Boston.—On or before the fifth day of a severe burn, a period of severe anemia and hypoproteinemia begins. There is an excessive, measurable loss of nitrogen in the urine as well as losses of unknown amounts from the surface. The loss of nitrogenous substances is so great that intravenous plasma, albumin, and blood cannot possibly cope with it. Very high protein diets are indicated. Anorexia may interfere with the success of these. In some cases intravenous or oral administration of amino-acids is of vital importance. In one severe case with third degree burn of 50 per cent body area, nitrogen balance studies were made over a period of several weeks. There was a progressive rapid loss with a negative balance resulting in extreme emaciation. Nitrogen balance was reached on an intake of 300 Gm. of protein (or equivalent) per day. Rapid improvement of condition followed, raising this intake to 500 Gm. This is equivalent to ten pounds of meat per day.

Factors Determining the Rational Treatment of Thermal Burns, Allan O. Whipple, New York.—There is a delay in the liberation of thromboplastic substance in burned areas and there is liberated a vasoconstrictor substance with the increase in the permeability of the capillaries in the immediately surrounding areas and an increased flow of lymph. The edema of the tissues in the burned area

topical application of sulfonamides. He stated that these patients were more likely to develop an encephalitis from an infection involving the ventricle than meningitis.

Cerebral Concussion-Alterations in Cerebral Volume, Blood Content, and Histological Changes After Experimental Injury by Acceleration of the Head, James C. White, John R. Brooks (by invitation), Joel C. Goldthwait (by invitation), and Raymond D. Adams (by invitation), Boston.—Determinations were made of brain volume, vascular congestion, and microscopic changes in cats after varying degrees of concussion. Concussion was produced by striking the cat in the occiput with a heavy steel pendulum. At a striking speed of 34 feet per second, concussion (judged by changes in reflexes, respiration, and cardiac rate) was minimal, whereas at a speed of 48 feet per second occasional linear fractures and death without recovery of respiration might take place. Even in these fatalities there has been no evidence of laceration or gross contusion of the brain, although basilar hemorrhages have been present in a few of these cats. Whereas after decapitation and exsanguination the brain of the normal cat was from 10 to 12 per cent smaller than its surrounding calvarium (differential index of brain volume), in the concussed animal this index might be reduced to between 8 and 5 per cent. Although the actual degree of increase in volume of the exsanguinated brain amounted to a maximum of only 5 per cent, swelling has been uniformly present after concussion, and has varied directly with the observed severity of the concussion in a series of twenty cats. In animals sacrificed at varying periods after concussion the swelling began within fifteen minutes of the blow, reached its maximum at the end of twenty-four hours, and disappeared after seventy-two hours. Microscopic examination revealed many of the changes which have been regarded as indicative of cerebral edema, such as increase in size of pericellular and perivascular spaces, swelling of oligodendroglia, and formation of vacuolar spaces in the white matter. These histologic changes correlated fairly well with the degree of cerebral edema as determined by increased brain volume.

It was their feeling that certain other factors, such as anoxia and hypercapnoia secondary to respiratory obstruction or failure, or extensive contusion of brain substance, are required to explain the elevated intracranial pressure which is often present in cases of severe cerebral injuries in man.

In the discussion, **F. Grant, Philadelphia,** stated that the sudden arrest of the head in motion was likely to cause greater damage to the brain. He sited the above work as evidence against the advisability of routine use of spinal puncture drainage in head injuries.

The Thyrocardiac—A Review of Six Hundred and Thirty Cases, Frank H. Lahey, and Lewis M. Hurxthal (by invitation), Boston.—Reviewed were the observations made on six hundred and thirty patients with thyrocardia. The prophylactic removal of toxic adenomas before severe cardiac damage has been produced was emphasized. If the pulse rate and basal metabolic rate remain balanced, cardiac decompensation does not occur. Decompensation occurs in those cases in which pulse rate does not increase proportionately with the basal metabolic rate or in which the pulse rate is excessive in relation to it. Cyclopropane anesthesia has induced ventricular fibrillation. The best anesthesia appears to be induction with ethylene followed by ether in these cases. Quinidine is unnecessary in the treatment of fibrillation. The mortality in this group has shown a progressive decline with the years.

R. S. Dinsmore, Cleveland, in the discussion, expressed his preference for avertin foundation anesthesia supplemented with gas or local infiltration. He also stated that in cases with fibrillation it was desirable to administer digitalis preoperatively and that quinidine should be given if fibrillation continued beyond

tures. Almost all are at either the fourth or fifth lumbar nise. Ninety-five per cent of patients with low back pain and sciatica have herniated dises; 2 per cent are due to spondylolisthesis, 1 per cent to tumors and 2 per cent to congenital deformities of the vertebrae. Anteroposterior and lateral films of the lumbar spine are necessary to rule out these lesions. Reported were the results of operations for herniated discs in 506 cases with only 14 recurrences of symptoms. In 300 cases during the last two years there was no failure to obtain relief and no recurrences.

There are protruding dises and very small (concealed) dises. Both give precisely the same symptoms. The latter will not show in spinal injections of lipiodol and they are one-half the total number.

Localization can usually be made at operation by the increased mobility of the joint determined by pushing the spinous processes.

The entire disc is removed by curettement in order to prevent recurrence.

Spinal fusions are unnecessary and undesirable. Opening and curetting the joint between the articular surfaces promotes fusion.

During the discussion, G. Horrax, Boston, stated his opinion that pneumospinal mylography was indicated in doubtful cases and that the examination of the spinal fluid was more or less routinely indicated.

J. A. Key, St. Louis, stated that many cases with a disc syndrome were relieved by nonoperative management and that operation should not be done until the patient asks for it. He questioned that fusion ever resulted from a laminectomy and believed that spinal fusion was frequently indicated as a supplementary procedure.

War Wounds of the Central Nervous System, W. M. Craig, Captain, M.C., U.S.N.R.—The recognition and treatment of shock, the use of the sulfonamides, the improved transportation of the wounded have almost revolutionized the treatment of wounds of the central nervous system. Transfusions of blood, plasma, and albumin administered in sufficient quantities to combat shock have made possible the transportation of patients over long distances. The emergency treatment of open head wounds consisting of shaving the scalp, arrest of hemorrhage, and local application of sulfanilamide has allowed for an interval before reparative surgery is imperative of from thirty-six to forty-eight hours. These two factors have not only lowered the mortality and reduced the incidence of infection but have changed the plan for the care of these cases.

Wounds of the spinal cord still produce marked disability depending upon the severity of the lesion but the factor of infection has been moderated. Spinal shock caused by wounds of the contiguous structures have been noted and under proper treatment have shown a tendency to recovery in a large percentage of cases.

The local application of sulfanilamide to wounds has made possible the earlier repair of injured nerves and does not interfere with nerve regeneration. While at the present time an end-to-end anastomosis is the operation of choice, use of nonabsorbable sutures, fibrin glue, and nerve grafts are being investigated.

Peripheral vasoneuropathy, or the so-called immersion foot, has been recognized as a disabling affection of the extremities occurring to men who have been adrift at sea. Degeneration of the peripheral nerves has been demonstrated in amputated feet and legs associated with pathologic changes in the veins and arteries.

A. W. Adson, Rochester, Minn., in the discussion, emphasized the value of oxygen, plasma and whole blood transfusion, and chemotherapy in the treatment of these cases.

Goeffrey, Jefferson, London, Eng., discussed penetrating wounds of the brain; the use of suction to remove foreign material and damaged tissue, followed by the

topical application of sulfonamides. He stated that these patients were more likely to develop an encephalitis from an infection involving the ventricle than meningitis.

Cerebral Concussion-Alterations in Cerebral Volume, Blood Content, and Histological Changes After Experimental Injury by Acceleration of the Head, James C. White, John R. Brooks (by invitation), Joel C. Goldthwait (by invitation), and Raymond D. Adams (by invitation), Boston.—Determinations were made of brain volume, vascular congestion, and microscopic changes in cats after varying degrees of concussion. Concussion was produced by striking the cat in the occiput with a heavy steel pendulum. At a striking speed of 34 feet per second, concussion (judged by changes in reflexes, respiration, and cardiac rate) was minimal, whereas at a speed of 48 feet per second occasional linear fractures and death without recovery of respiration might take place. Even in these fatalities there has been no evidence of laceration or gross contusion of the brain, although basilar hemorrhages have been present in a few of these cats. Whereas after decapitation and exsanguination the brain of the normal cat was from 10 to 12 per cent smaller than its surrounding calvarium (differential index of brain volume), in the concussed animal this index might be reduced to between 8 and 5 per cent. Although the actual degree of increase in volume of the exsanguinated brain amounted to a maximum of only 5 per cent, swelling has been uniformly present after concussion, and has varied directly with the observed severity of the concussion in a series of twenty cats. In animals sacrificed at varying periods after concussion the swelling began within fifteen minutes of the blow, reached its maximum at the end of twenty-four hours, and disappeared after seventy-two hours. Microscopic examination revealed many of the changes which have been regarded as indicative of cerebral edema, such as increase in size of pericellular and perivascular spaces, swelling of oligodendroglia, and formation of vacuolar spaces in the white matter. These histologic changes correlated fairly well with the degree of cerebral edema as determined by increased brain volume.

It was their feeling that certain other factors, such as anoxia and hypercapnoia secondary to respiratory obstruction or failure, or extensive contusion of brain substance, are required to explain the elevated intracranial pressure which is often present in cases of severe cerebral injuries in man.

In the discussion, **F. Grant**, Philadelphia, stated that the sudden arrest of the head in motion was likely to cause greater damage to the brain. He sited the above work as evidence against the advisability of routine use of spinal puncture drainage in head injuries.

The Thyrocardiac—A Review of Six Hundred and Thirty Cases, Frank H. Lahey, and Lewis M. Hurxthal (by invitation), Boston.—Reviewed were the observations made on six hundred and thirty patients with thyrocardia. The prophylactic removal of toxic adenomas before severe cardiac damage has been produced was emphasized. If the pulse rate and basal metabolic rate remain balanced, cardiac decompensation does not occur. Decompensation occurs in those cases in which pulse rate does not increase proportionately with the basal metabolic rate or in which the pulse rate is excessive in relation to it. Cyclopropane anesthesia has induced ventricular fibrillation. The best anesthesia appears to be induction with ethylene followed by ether in these cases. Quinidine is unnecessary in the treatment of fibrillation. The mortality in this group has shown a progressive decline with the years.

R. S. Dinsmore, Cleveland, in the discussion, expressed his preference for avertin foundation anesthesia supplemented with gas or local infiltration. He also stated that in cases with fibrillation it was desirable to administer digitalis preoperatively and that quinidine should be given if fibrillation continued beyond

the seventh postoperative day. He also stated that about 20 per cent of the toxic cases had at some time fibrillated and that on admission to the clinic 4 per cent were decompensated and 5 per cent fibrillated.

Experiences of a Surgical Consultant to a Service Command, Bradley L. Coley, Col., M.C., U. S. Army.—The activities of a surgical consultant to a service command were reviewed.

The high order of surgery found in most of these hospitals is due to the provision of highly trained personnel, excellent equipment, well-developed surgical teamwork and supervision by well-qualified chiefs of surgical service.

The need for a form of educational program, i.e., postgraduate medical education adapted to Army conditions is recognized and some of the measures taken to fill this need were discussed.

Grover C. Penberthy, Detroit, during the discussion, stated that no previous army had ever received as high quality of medical service and care as the present armed forces. He summarized the numerous ways in which efforts were being made constantly to improve the service.

Note regarding the article entitled "The Therapy of Shock in Experimental Animals With Serum Protein Solutions. II. Fate in the Body of Concentrated and Dilute Serum and Saline Solutions" by E. E. Muirhead, M.D., C. T. Ashworth, M.D., L. A. Kregel, M.D., and J. M. Hill, M.D., Dallas, Texas. Since this paper was submitted for publication, the effects of concentrated plasma on the plasma volume of dogs in the state of severe freezing shock has been once more tested. In this new group of ten dogs the plasma volume determinations for the control period, shock period, and post-therapeutic period were conducted in accordance with the technique recently presented by Longmire and Price (Price, P. B., Longmire, W. P.: Use of T-1824 in Plasma Volume Determinations, Bull. Johns Hopkins Hosp. 71: 51-83, 1942) i.e., the dye solution was weighed, all injections were made under vision, all samples were corrected for hemoglobin staining using the 540 mm. and 620 mm. filters, and the disappearance curves were established on semilogarithmic paper. The reinjection dye level was established by subtracting the preinjection level rather than resetting the colorimeter at 100. In all of these experiments the plasma volume increment was far greater than the volume of solution injected, indicating a shift of fluids into the blood stream. The amount of plasma protein increment accounted for 86.7 per cent of the total amount of protein injected, indicating a post-therapeutic loss of 13.3 per cent of the injected protein. This feature was not unexpected in view of the over two times greater area of local capillary damage (frozen site) as compared to the extent of capillary damage in the present experiments.

Book Reviews

Orthopedic Subjects (Military surgical manual IV) Prepared and edited by the Subcommittee on Orthopedic Surgery of the Committee on Surgery of the Division of Medical Sciences of the National Research Council, George E Bennett, Chairman Philadelphia, 1942, W B Saunders Company $3

This volume covers four sections titled as follows Ununited Fractures, Injuries to the Spinal Column, Compound Fractures, and Osteomyelitis

It is apparent that the book is not a pocket manual to be used for front line work It deals with more highly specialized phases of orthopedic treatment and was probably meant to be used by the surgeon who wants to familiarize himself in regard to these phases of orthopedic care

The sections are on the whole well done The section on ununited fractures presents a rather limited view of the subject and leaves much to be desired in the way of handling of this important problem in military practice Incidentally, it is doubtful that ununited fractures of the femoral neck deserve ten pages in a volume on military orthopedics

Much of the chapter on osteomyelitis is devoted to that problem as it relates to children The author of the chapter states definitely that it was written for publication elsewhere and that he "retained the extensive consideration of acute hematogenous osteomyelitis, which might almost be classed as a disease of childhood and is rarely seen among adults, because this is the foundation on which knowledge of pyogenic infections in bone rests" It covers the subject well, but the problem of osteomyelitis of children is not one to concern military surgeons generally

Numerous other conditons are not mentioned The volume seems to lack much that would be of help to a military surgeon

The book is well printed and the form seems excellent The illustrations are good, although again it seems that a much more completely illustrated volume would be more valuable as a military manual

---

Principles and Practice of War Surgery. By J Trueta Pp 441, with 144 illustrations St Louis, 1943, The C V Mosby Company $6 50

Trueta's surgical experience in combat zones has fully qualified him to write on the principles of war surgery In this book he explains in detail his method of treatment, sometimes called the "closed plaster treatment of compound injuries," and discusses the pathologic, bacteriologic, and physiologic fundamentals upon which this method is based The book is divided into two parts Pathology of War Wounds and General Care of the Wounded, and Essentials of War Surgery Wounds of the extremities, fractures, and burns are discussed, but injuries of the head, thorax, and abdomen are not included Following an introductory chapter on the biological principles of treatment there is an interesting section devoted to the evolution of war surgery from the time of Hippocrates

The remaining chapters in Part I include a discussion of fundamentals such as infection, the passage of bacteria and their toxins through the body, pyogenic infections of war wounds, gas gangrene, tetanus, shock, traumatic vascular spasm, blood

transfusion, and anesthesia in war time. The author has carefully reviewed the present concept of these subjects and has cautiously selected the parts applicable to war surgery as it must be practiced today. The author's viewpoint is both practical and basically sound. For students and surgeons entering upon war surgery as a new field this is a review of well-chosen principles which they might do well to memorize.

The opening chapter of Part II, The Essentials of Treatment and Organization, is particularly valuable to physicians and surgeons on the home front as well as in combat areas. A veteran surgeon of the Spanish Civil War and of the air raids over England, Trueta advises a radical departure from the "static system of assistance with a distant emergency hospital—the casualty clearing station" as developed during World War I, to the "Three-Point Forward System" based, not upon distances in miles, but upon the time factor. He states, "The main basis of success is to have the wounded patient on the operating table at the earliest possible moment. This is the only factor that counts, and is the objective at which the whole organization should aim." Brief plans of organization for the care of air raid victims and front line casualties are included.

The chapter on antiseptics gives a rational and conservative evaluation of their usefulness and concludes with an interesting discussion on the value of soap as an antiseptic as well as a detergent. In his discussion on chemotherapy, Trueta emphasizes the limitations of the sulfonamides when used locally or systemically. Local implantation of these drugs in selected wounds is grudgingly approved.

A lucid description of the technique of excision of wounds is given and accompanied by informative illustrations. The general conception of drainage is discussed; in addition, the author explains the employment of the plaster splint in contact with the gauze dressing in the wound to absorb and draw out the wound secretions.

Trueta advises the reduction and fixation of fractures by means of traction, applied simultaneously with the plaster. In cases of oblique or comminuted fractures which may not be well retained by this method, he advocates transfixion of the fragments above and below with Kirschner wires or Steinmann pins and incorporation of these in plaster to maintain traction.

Of special interest are the chapters on immobilization and the application of plaster, in which the author explains the advantages and reasons for complete immobilization in plaster and describes the technique of making and applying both bandages and patterns of plaster. The latter is very well illustrated.

Primary and secondary sutures, skin grafting of war wounds, articular wounds and amputations are reviewed briefly. Under the heading of regional surgery, seventy-seven pages are devoted to the details of the author's method for the care of fractures of the extremities, which is graphically illustrated.

The chapter on burns (fourteen pages long) is an unfortunate anticlimax to an otherwise excellent contribution to the treatment of war injuries. It lacks the thoroughness and careful detail with which all other subjects are treated. The author presents a modification of the tannic acid method of treatment which, in the opinion of most surgeons, has been superseded by better methods. The discussion is almost entirely limited to burns of the hands. Although he properly emphasizes the importance of splinting the hand throughout treatment in the best functional position, he fails to make clear the methods of dressing and redressing in such cases.

Trueta's book, like his work, is a real contribution to surgery and that part of the war effort devoted to conserving the lives and limbs of its victims. Students and surgeons concerned with treatment of compound fractures will find it both interesting and helpful and will be grateful for the numerous practical and valuable procedures presented.

SURGERY

VOL. 14 OCTOBER, 1943 No. 4

Original Communications

A CONSIDERATION OF THE PRESENT STATUS OF THE SHOCK PROBLEM

"PROBLEMS ON SHOCKS"

ALFRED BLALOCK, M.D., BALTIMORE, MD.

(From the Department of Surgery of the Johns Hopkins University and Hospital)

A RENEWED interest in shock is always manifested in time of war. It was during the Civil War that Mitchell, Morehouse, and Keen made observations which resulted in the publication of a paper which formed the basis for the vasomotor exhaustion theory of shock, the first of a number of theories in which the role of the nervous system was stressed. It was during the World War I that the first vigorous attacks on the pathogenesis of shock were made. Most of this work led to the formulation of the toxemia theory of shock, and the observations of Cannon, Bayliss, and Keith were outstanding. All of the work did not point in the same direction, as evidenced by the demonstration by Mann that traumatic shock cannot be produced by traumatization alone without opening of the abdomen, without the inducing of hemorrhage, or without injury to the medullary centers. It was during the first World War that the use of stored whole blood was suggested and employed on a small scale by Robertson, and that the use of blood plasma was suggested by Gordon P. Ward. A few cases of crush injuries and blast injuries were reported at this time, but the significance of these was not appreciated. It was shortly after this war that Hooker made his experimental observations on blast injuries and that Cannon wrote his book on *Traumatic Shock* which, though somewhat out of date, remains probably the best monograph on the subject.

The theory of traumatic toxemia remained essentially unchallenged for a number of years after the war, and it was then that several

*The E. Starr Judd Lecture in Surgery, delivered at the University of Minnesota, March 10, 1943.

Received for publication, May 10, 1943.

observers,[1, 2] using modifications of methods which had been employed previously, pointed out the important influence that the regional loss of fluid from the blood stream may exert in the causation of traumatic shock. These observations, which removed some of the obscurities regarding shock, encouraged surgeons to administer larger quantities of blood in the treatment of the injured. Blood banks were established in many hospitals. The use of blood plasma on a modest scale was introduced in a number of places. It was then that Elliott, Bond and Wright, Mahoney, Strumia, Levinson and others made their contributions, and the employment of plasma or serum on a larger scale resulted. Improvements in methods for processing plasma were being developed concurrently.

The theory which stressed the regional loss of blood and plasma as an important agent in the causation of traumatic shock gained many supporters during the five years preceding the present war, but has never been accorded the almost universal approval which the toxemia theory received after the last war. Credit is due Virgil Moon and John Scudder for continued interest in, and support and advancement of, the toxemia theory. At the same time, O'Shaugnessy and Slome and others reassessed the part played by the nervous system in traumatic shock and stated that it was an important one. Disagreements as to the pathogenesis of shock were lively but good-humored. In our enthusiasm for a particular method, few seemed to realize that the pathogenesis of all types of shock may not be the same.

This was, in brief, the state of affairs at the beginning of the present war, since which time vigorous attacks on the problems have been initiated by many investigators. The studies may be divided roughly into two groups: those on pathogenesis and those on therapy. Important advances have already been made, and it is likely that even more significant contributions will be forthcoming. From the viewpoint of the immediate war effort, the greatest accomplishment has been the collection and distribution of large quantities of blood substitutes.

No effort will be made to list the numerous contributions of those working in this field. An attempt will be made to indicate the general trend of the work both before and since the onset of war, and suggestions as to future problems will be offered.

THEORIES

Many theories regarding the cause or causes of shock have been advanced. If the term shock referred only to the traumatic type or types the situation would be complicated enough, but it becomes utterly confused when shock is used to designate a variety of conditions, many of which have no relation to one another. As Frank Mann and others have emphasized so often, *it is not a problem of shock but rather problems of shocks.* One of the most encouraging features of the work of the past

two years has been a growing appreciation by investigators of the fact that there are many causes of shock and that the mechanism of the production of all types of shock is not the same. A descriptive phrase should always accompany the use of the word shock, such as shock due to hemorrhage, shock due to burns, shock due to crush injuries, shock due to blast, shock accompanying infectious diseases, shock due to peritonitis, and so on. If the use of the term shock is restricted to failure of the circulation which accompanies trauma, there will still be confusion. For example, the mechanism of failure of the circulation following blast injury to the lungs is probably widely different from the mechanism of failure which results from a burn of a large surface of the body or from gross trauma to the extremities.

Speaking only of traumatic shock and admitting that there are exceptions, we may state that it is rather generally agreed that traumatic shock is usually due to either (1) regional loss of fluid, (2) toxemia, (3) nerve impulses, or (4) various combinations of these. These causes are placed in what I consider to be their order of importance, not in a case chosen at random but in the majority of cases. Furthermore, some instances of shock are due to other causes. For example, fat embolism is undoubtedly responsible for an occasional case of shock which follows trauma.

EXPERIMENTAL METHODS FOR PRODUCING SHOCK*

It would seem obvious that one should attempt to reproduce in the experimental animal a condition which is as closely analogous as possible to that which is encountered in an injured person. It is surprising, however, to note how often the experimental method has no apparent relation to traumatic shock as seen in man. Until recently, one could state that there is no proved relation between traumatic shock as observed in the human being and in animals. The brilliantly conceived and executed clinical studies of Cournand[3] and his co-workers at Bellevue and Presbyterian Hospitals have demonstrated that the circulatory system of man responds to trauma in a manner similar to that of the dog. This work allows one to speak with greater assurance regarding the value of experimental observations on this subject.

A constructive step in experimental studies would result from the placing of most of the emphasis on a few techniques for producing shock, in each of which an effort is made to cause a state of shock which can be reproduced with predictable morbidity and mortality. It might appear that this would be easy to accomplish, but such is not the case. There is wide individual variation in the tolerance of animals of the same species, even more pronounced in different species, to trauma as well as to hemorrhage. A recent personal experience has impressed upon

*I am indebted to Philip Bard, Robert Loeb, and Joseph Wearn for some of the ideas expressed in this section.

observers,[1, 2] using modifications of methods which had been employed previously, pointed out the important influence that the regional loss of fluid from the blood stream may exert in the causation of traumatic shock. These observations, which removed some of the obscurities regarding shock, encouraged surgeons to administer larger quantities of blood in the treatment of the injured. Blood banks were established in many hospitals. The use of blood plasma on a modest scale was introduced in a number of places. It was then that Elliott, Bond and Wright, Mahoney, Strumia, Levinson and others made their contributions, and the employment of plasma or serum on a larger scale resulted. Improvements in methods for processing plasma were being developed concurrently.

The theory which stressed the regional loss of blood and plasma as an important agent in the causation of traumatic shock gained many supporters during the five years preceding the present war, but has never been accorded the almost universal approval which the toxemia theory received after the last war. Credit is due Virgil Moon and John Scudder for continued interest in, and support and advancement of, the toxemia theory. At the same time, O'Shaugnessy and Slome and others reassessed the part played by the nervous system in traumatic shock and stated that it was an important one. Disagreements as to the pathogenesis of shock were lively but good-humored. In our enthusiasm for a particular method, few seemed to realize that the pathogenesis of all types of shock may not be the same.

This was, in brief, the state of affairs at the beginning of the present war, since which time vigorous attacks on the problems have been initiated by many investigators. The studies may be divided roughly into two groups: those on pathogenesis and those on therapy. Important advances have already been made, and it is likely that even more significant contributions will be forthcoming. From the viewpoint of the immediate war effort, the greatest accomplishment has been the collection and distribution of large quantities of blood substitutes.

No effort will be made to list the numerous contributions of those working in this field. An attempt will be made to indicate the general trend of the work both before and since the onset of war, and suggestions as to future problems will be offered.

THEORIES

Many theories regarding the cause or causes of shock have been advanced. If the term shock referred only to the traumatic type or types the situation would be complicated enough, but it becomes utterly confused when shock is used to designate a variety of conditions, many of which have no relation to one another. As Frank Mann and others have emphasized so often, *it is not a problem of shock but rather problems of shocks.* One of the most encouraging features of the work of the past

previously normal animal restrained on its back will usually result in death in several days.

Of the methods of producing shock now being systematically employed, the following seem to reproduce most closely the conditions encountered by the Armed Forces: (1) hemorrhage uncomplicated by gross trauma; (2) burns; (3) trauma to large masses of muscle; and (4) the re-establishment of circulation in a damaged ischemic area. Past and present work has indicated that at least three factors should be considered in any study of experimental shock. The first of these is a reduction in volume of effective circulating blood, usually due to regional loss of whole blood or plasma. The second is the elaboration of hypothetical toxic substances or the development of a metabolic derangement, local or general, which produces deleterious effects on the organism as a whole. The third is the role of the nervous system. Every experimental study of shock demands not only an awareness of these three factors but, as far as possible, a determination of their quantitative characteristics.

In shock produced by any of the four methods enumerated, the initial phases are certainly associated with and probably dependent upon a reduction in the volume of effective circulating blood. In any study of shock a failure to take this fact into consideration is bound to invalidate the significance of the results obtained. In studies which are undertaken to determine the value of therapeutic agents and in which the survival or mortality rates are equivocal, determinations of blood volume or cardiac output or both are imperative.

Investigations have indicated that at some time in the development of irreversible shock there appear effects which may be ascribed either to toxic substances elaborated in areas of tissue damage or to a derangement of metabolism produced by circulation which, either locally or generally, has been compromised over a long time. Although the evidence so far adduced bearing on this aspect of the subject has been vague, it is worthy of serious and intensive study. Such study requires the efforts of persons adequately trained in the principles of enzyme chemistry and tissue metabolism who will work in collaboration with investigators skilled in the techniques of producing shock experimentally and knowing the methods of evaluating its cause and severity.

Regarding the role of the nervous system, previous work has shown that the central respiratory and cardiovascular mechanisms tend to retain their functional integrity until the irreversible stage of shock develops. On the other hand, apathy and other signs of failure of certain higher nervous functions are commonly encountered in patients and unanesthetized animals before the irreversible stage develops. The theory that overactivity of the sympathetic system, especially the vasoconstrictor components, is an essential factor in bringing on shock has not received confirmation. There remains the hypothesis that afferent

me again the difficulties of this work. George Duncan and I had performed a large number of experiments in which a mechanical crusher was applied to a posterior extremity for five hours. Anesthesia was maintained by the use of nembutal and morphine. The control as well as the experimental animals in which various forms of therapy were tried were kept in place on the table for approximately five hours after removal of the crusher. There were about forty control experiments and only one animal in this series survived. Recently, what appeared to be a slight alteration was made in the procedure because we were interested in following a therapeutic lead which was discovered elsewhere. The alterations in procedure consisted of using nembutal alone instead of nembutal and morphine, and in removing the animal from the table as soon as the crusher was taken off. A large proportion of these animals survived, and I believe it was due, in the main, to the fact that they drank water sooner and in larger quantities than was the case in the earlier studies.

In this same connection, Stafford Warren and his group in Rochester recently had an interesting experience. Using a crusher technique similar to that mentioned in the last paragraph, they had a mortality rate greater than 90 per cent. It became necessary for them to move to other quarters, and it was found there that most of the animals survived. It was noted that the room temperature in the new quarters was 10 to 15 degrees lower than it was in the original location. The temperature of the room was then elevated and the mortality rate rose to the original level. It is Warren's impression that this difference in mortality rates is explainable on the basis of variation in environmental temperature.

These experiences are mentioned in order to emphasize the difficulties of this type of experimental work. Whether the injured anesthetized animal lives or dies may be dependent upon some minor variation in the procedure. Studies on mechanism present difficulties, but it is especially hazardous to attempt to evaluate therapeutic procedures, the benefits of which are at best not very striking.

There are many other points regarding experimental methods which might be mentioned. Brief reference will be made to only a few of them. Anesthesia should be no deeper than is nesessary for the prevention of pain. If the blood pressure is obtained by cannulation of an artery and the employment of a mercury manometer, sodium citrate should not be used in the system. When the blood pressure falls, some of the citrate enters the blood vessels of the animal and death may result. Chlorazol fast pink is preferable unless studies involving dye determinations are being carried out. Animals should not be restrained on their backs on tables any longer than is necessary. This is a very abnormal position for a four-legged animal, and profound anesthetization of a

No attempt will be made to enumerate and describe all of the recent interesting observations. Some of these will be mentioned in a consideration of individual types of injuries such as occur in connection with so-called blast or crush. Since there has been a great deal of interest recently in the effects of ischemia, the experimental work of Root and Mann[5] will be described. Interpretation of their findings may be open to question, but it may be observed that attempts were made to determine the respective roles of (1) toxic effects, (2) sensory impulses, and (3) local loss of fluid. They state:

"The causation of the rubber band type of trauma was studied from three viewpoints: namely, as being due to (a) early toxic effects on the capillaries, (b) bombardment of sensory impulses from the traumatized region, or (c) local loss of fluid into the damaged region.

"a. Since large doses of histamine were necessary to cause death of the animal and also since histamine is removed rapidly from the blood stream of the rat, it would seem that histamine was not the causative factor in this type of shock.

"No immediate capillary dilatation was seen to occur in the mesentery or hepatic capillaries when the rubber bands were released. When the loss of fluid was minimized by wrapping the legs tightly, the capillary bed did not differ from that of the normal control animal over a six-hour period of observation following the cutting of the bands. Thus, there was no positive evidence for the liberation of a toxic substance causing immediate capillary damage in this type of shock.

"b. Section of the lumbar portion of the spinal cord with needling of the distal segment of the cord did not prolong the lives of the animals in the rubber band type of trauma and, therefore, the bombardment of sensory impulses from the traumatized region would seem to play a minor role in the causation of the type of shock.

"c. Wrapping the hind legs tightly with adhesive tape just before the rubber bands were cut, minimizing the local loss of fluid, did prevent the onset of shock as was confirmed by the normal respiratory rate, the normal capillary circulation, the general condition of the animal, and the normal results of hematocrit and red blood cell studies.

"Temporary wrapping of the legs for one hour after the bands were cut was not of any benefit."

The results of these experiments support the thesis that there is not a general increase in capillary permeability in shock. The observations are not in accord with those of a number of investigators who have presented evidence of the liberation of toxic products from an ischemic area or who attach great significance to the effects exerted by sensory impulses, such as Swingle.

A great deal of work on the relative importance of regional loss of fluid and of nervous impulses in the genesis of traumatic shock has been done by D. B. Phemister. His views on the subject appear to me to be

impulses from traumatized tissue somehow produce shock or facilitate its development. No one has ever produced a prolonged state of shock simply by stimulation of afferent nerves. Although it cannot be denied that afferent impulses may be a factor in the genesis of shock, it does not seem likely that they are of major importance. Experiences with the use of spinal anesthesia in the treatment of injuries of the lower extremities of man have not been encouraging.

RECENT EXPERIMENTAL WORK ON PATHOGENESIS

It is my impression, and it is only an impression, that opposing schools of thought on the pathogenesis of shock are more nearly agreed at the present time than they were several years ago. Most of those who maintain that toxemia is the most important agent in the causation of traumatic shock admit that there may be other factors, and the same statement holds true for those who have stressed the importance of regional loss of fluid. This admission is a very hopeful sign.

The most remarkable shift of opinion has occurred in relation to the question of the permeability of the capillaries in shock. Previously, it was rather generally believed that the permeability of the capillaries throughout the body is increased in the terminal stages of traumatic shock, and many maintained that general capillary permeability is increased over normal in the early stages. The observations of a number of investigators, including Gregersen and Root, Fine, Gibson and Evans, E. I. Evans, Chambers, and others, indicate that there is not a general increase in permeability even in the fairly advanced stages. The following quotation is from a recent paper by Fine and Seligman[4]: "While the integrity of the capillaries may be impaired in the late shock phase, there is no evidence of a significant loss of plasma into tissues in untreated fatal shock following hemorrhage. Hence, an increase in capillary permeability is not a factor in the fatal issue. The phenomena which are set in motion by the initial critical loss in circulating plasma volume and which lead to death do not require that a progressive decline in plasma volume take place. Plasma loss into tissues therefore is not a crucial factor in hemorrhagic shock." Gibson and Evans, Fine and others, using radioactive substances, have obtained evidence that there is trapping of the red blood cells in shock. Even though I have been among those who have stressed the importance of a local increase in capillary permeability as contrasted with a general increase, it is difficult to accept without reservations the finding that there is not a general increase in capillary permeability in the late stages of shock.* It is to be hoped that the recent observations are correct for they make for a more hopeful outlook in therapy.

*Even if it be granted that there is no general increase in capillary permeability in untreated shock, it seems quite likely that general leakage may occur in the late stages if the capillary pressure is raised by the intravenous administration of fluids.

on the respiration of living tissue. Their preliminary observations indicate that sodium succinate is helpful in the treatment of experimental shock. Further studies of this nature are in order. An attack on the metabolic disturbances in shock would appear to be particularly hopeful and important.

PRODROMAL SIGNS OF SHOCK

It is well known by those who are interested in this subject that the the blood volume and cardiac output are usually diminished in traumatic shock before the arterial blood pressure declines significantly. Vasoconstriction can maintain an essentially normal arterial pressure for a fairly prolonged period when there is only a moderate decrease in the blood volume. When the arterial pressure declines in traumatic shock to the so-called critical level (approximately 75 mm. of Hg), it is a sign of advanced rather than incipient shock. It is much easier to prevent shock than it is to treat successfully the fully developed condition, and hence it would be highly desirable to have an early invariable criterion of shock which can be easily detected. It is unlikely that this hope will be realized, for there are few disorders in medicine in which a uniform early sign which is diagnostic is found. Nevertheless, work on prodromal signs is being continued.

In the present state of our information on the subject, the best plan is to treat or to prevent shock according to the nature and severity of the injury and the blood loss rather than to delay treatment until there is a decline in arterial blood pressure. This is the opinion of Whitby and associates,[9] of Grant and Reeve,[10] and of others who have examined a large number of wounded men in the present war. A rising pulse rate is often a useful indication of developing shock, but peripheral circulatory failure may exist when the pulse rate is 80 or less. A falling blood pressure is the best single index of progressing shock, but, as stated previously, it is not an early sign of traumatic shock. In injuries such as burns, where the loss of fluid is restricted in the main to plasma, an increase in the concentration of the red blood cells may serve as a helpful early sign. With the exception of patients with burns and crush and blast injuries, early hemoconcentration has not been the usual finding in the present war. Frequent but not unvarying signs include cold extremities, sweating, thirst, pale mucous membranes, and diminished pulse volume.

A number of factors influence the response of the body to injuries. Inadequate food and water, chilling or excessive heat, physical and emotional exhaustion decrease the tolerance to trauma. Under such circumstances it is particularly important to institute early treatment.

CLINICAL OBSERVATIONS

During the present war there have been numerous obstacles to the making of clinical observations on a large scale. The nature of mobile

sound, and with his permission the following personal communication is quoted:

"From both clinical and experimental studies I believe that shock is rarely if ever produced primarily through the nervous system. However, if blood or blood and plasma loss as a result of trauma bring about a state of circulatory embarrassment, then a neurogenic lowering of blood pressure occurring simultaneously or afterward may still further lower blood pressure and be a secondary factor in importance in the production of shock. Psychic influences produced by pain or by the sight of a severe accident may cause fainting with a low blood pressure. But the reaction never lasts long enough to produce shock. The same is true of the fall in blood pressure in an abdominal operation in which there is no blood loss or obstruction of the return venous circulation, such as portal vein or inferior vena cava obstruction.

"Also marked lowering of blood pressure produced by the purely neurogenic procedure of stimulation of the carotid sinus or cardio-aortic nerves may be maintained for three or four hours without creating a state of shock. Release of the stimulus is followed by a return of pressure to the previous level and the animal usually lives on as if there had been no stimulation. Also traumatic stimulation of large wounds on the extremities by manipulation and pinching does not cause a reflex fall in blood pressure. It is only as the extremity swells from local blood and plasma accumulation that the blood pressure may be lowered. Stimulation of a cardio-aortic or carotid sinus nerve, maintaining a very low pressure for six to eight hours does create a state of shock which results fatally. However, it is so improbable that these special vasodepressor nerves would ever be stimulated in an accidental wound that the idea is scarcely worthy of consideration."

Recent observations on metabolic changes in shock are of particular interest. Govier and Greer[6] noted an elevation of pyruvate in dogs after hemorrhage. Significant changes in amino acid and carbohydrate metabolism have been found by Engel, Winton, and Long[7] in shock due to hemorrhage. It is suggested that the changes are due, "on the one hand to a decrease in hepatic function resulting from early anoxia of the liver, and on the other to the effects of anoxia on the peripheral tissues, causing an enhanced rate of protein breakdown and glucose utilization. In addition, the deficient oxygen supply results in an accumulation of lactate and pyruvate in the blood and tissues." The elevation of the amino acid nitrogen of the blood occurs only after the pressure has fallen to between 85 and 90 mm. of Hg, and hence this alteration cannot serve as an early index of shock. From the viewpoint of therapy, the experiments of Mylon, Winternitz, and de Suto Nagy[8] are at least suggestive. After having found that albumin is inferior to plasma as a blood substitute, they injected sodium succinate, in combination with other agents, because of the recognized influence it exerts

These reports and some others which will not be mentioned present clinical evidence of the important part which regional loss of blood and fluid may play in the development of shock. A question will be raised here which could probably be considered more appropriately under burns. Do severe injuries usually cause a serious interference with the blood supply to the part (ischemia), and if so, does the ischemia result in damaging effects to the general circulatory system? Further information on these points is needed. Severe injuries such as burns cause death of some tissues; structures well beneath a burned area probably have an entirely adequate flow of blood. Further information is needed regarding the state of the circulation of the zone between the devitalized area and the essentially normal one. It is likely that the flow of blood is considerably reduced and this may result in the passage into the circulation of toxic products.

Burns.—There is little difference of opinion regarding the general treatment of patients with burns. It is agreed that enormous quantities of plasma may be lost from the circulation and that treatment should include the intravenous administration of large amounts of plasma. Furthermore, the extent of the surface that is burned, the increase in the concentration of the red blood cells, and other definite measurements serve as good indices of the quantity of blood substitute that is needed. Elkinton, Wolff, and Lee[11] have observed in patients that the loss of injected plasma is more rapid during the early stages after the burn than it is subsequently. If the available supply of plasma is limited, an appreciable proportion of the total should be saved for the period of beginning twenty-four hours after the burn when the local leakage will have diminished.

Rhoads and Lee and others have found in patients that the use of tanning agents causes a reduction in loss of fluid from a burned area. It is likely that the same effect can be brought about by the employment of pressure dressings. One of the most interesting alterations in viewpoint in the present war has been the trend away from the use of tanning agents in the local treatment of burns.

The two important problems in the treatment of burns are the restoration and maintenance of an adequate blood volume and the prevention of infection. It should be remembered that the volume of the blood substitute as well as its protein content is important. If concentrated albumin is used in treatment in the early period after a burn, preferably it should be diluted with or administered simultaneously with normal salt solution. A vigorous effort should be made to maintain adequate urinary output. It is very helpful if the patient can retain fluids which are taken by mouth. In any case hemoconcentration is usually replaced by anemia and hypoproteinemia four to six days after a severe burn, and the injection of whole blood is then indicated.

warfare is such that one cannot predict with any degree of certainty the localities in which injuries will be encountered. Distances are great and the transportation of apparatus presents difficulties.

A number of obstacles also have been encountered in the study of shock in the civilian population in this country. Preventive measures such as the use of whole blood and plasma have reduced greatly the incidence of shock in association with accidents and operations. Because of restrictions on the use of the automobile and a lowering of the speed limit, the number of accidents has decreased very decidedly. Studies on the injured in defense industries have not appeared advisable because they might result in a little delay in carrying out therapeutic procedures. A reduction in the personnel of the professional staffs of most institutions has increased routine duties for those who remain and there is little time for such investigations.

Despite these obstacles, some progress has been made, and an outstanding example is the work of the group at the Bellevue and Presbyterian Hospitals in New York. Reference[3] has been made to their careful studies on the circulatory system of the injured man.

No attempt will be made to discuss all types of injuries. Some of the important observations on multiple wounds of soft parts, burns, and crush and blast injuries will be discussed briefly.

Multiple Wounds of Soft Parts.—Kekwick, Marriott, Maycock, and Whitby[9] made a careful study of twenty-four patients who were severely injured. They stated that the decrease in the blood volume in these patients could be accounted for by external loss and by extravasation into the injured area, and that there was no evidence to suggest loss of plasma in regions remote from a seat of injury. There are two important facts that emerge from this study as well as from the careful clinical report of Grant and Reeve.[10] These facts were known already but they needed to be emphasized. The first of these is that a decline in blood pressure is a late rather than an early sign of traumatic shock. All of these investigators noted further that the cardinal symptoms of shock may be present without much hemoconcentration or hemodilution and that the pulse rate is an unreliable indicator. It is emphasized that patients should be treated according to the nature and severity of injury and blood loss and that one should not wait for alterations in measurable functions of the circulation. The second point of importance is that enormous quantities of whole blood or plasma may be required for the successful treatment of those with severe injuries. Blood pressure determinations are of value in estimating the response to treatment. Whitby and his associates state that, as a rule, a rise of 10 to 20 mm. of mercury can be anticipated for every 540 c.c. transfused, if bleeding has ceased and no other causes of loss of circulating plasma are operating.

quantity by intravenous injection. If tetany is induced, calcium gluconate should be given intramuscularly. Potassium salts must not be used. Sodium sulphate (2 per cent) may also be injected intravenously in combination with the above measures to maintain urinary output.

"2. With the kidneys thus protected, it is safe to restore the circulation by combating shock, if this is present. Plasma or serum should be given, or, if there has been much hemorrhage, blood. A large quantity may have to be administered: So long as the arterial blood pressure remains low no harm need be feared. Saline is of no value. Overheating the patient is dangerous."

This point of view is a very interesting one, and it would certainly seem that Bywaters is correct in his contention that diuresis should be stimulated. On the other hand, it would appear that impending shock should be treated concurrently by the intravenous administration of blood plasma.

Blast Injuries.—No attempt will be made to enumerate separately the findings of Hooker, of Zuckerman, of Denny-Brown, and of others, but the recent paper by Williams[13] will be reviewed in moderate detail. The pressure exerted by an exploding bomb may be tremendous. There are three components in the blast wave in *air:* (1) positive pressure wave acting directly on the chest and indirectly on the lungs through the diaphragm; (2) negative air suction wave; and (3) the mass movement of air or gas (windage factor). The mechanism of action of blast in *water* is somewhat different in that, generally speaking, only the primary positive pressure wave is of importance. Blast at an equal distance is more dangerous in water than in air because the rate of fall in pressure is much more rapid in air. This statement has to be modified somewhat if air blast occurs in the vicinity of rigid objects such as the walls of a building which will cause the pressure to be built up by reflection. Other parts of the body (abdominal contents, tympanic membranes, etc.) as well as the lungs may be injured by blast. Williams made the following statements concerning the mechanism of blast in water. "Now consider the human body, which has roughly the same density as water. When the pressure wave impinges on the body there will be no reflection, but the pulse will be transmitted through the tissues without displacement, just as if the body were so much water. However, when the transmitted pulse encounters an air cavity in the body, e.g., the lungs, the same phenomenon will occur as has been described above; that is, the static wave of pressure will change into a wave of kinetic energy in the layers of tissue lining that cavity and a disruptive effect will occur. Hence it can be understood that the lungs and other gas-filled cavities in the body are particularly susceptible to damage from the pressure wave, even though the body itself may not be deeply immersed."

Crush Injuries.—A few instances of crush injuries were observed in World War I, but the condition seems to have escaped further attention until the beginning of the present conflict. As a matter of fact, it may very well be that the importance of the condition has been overemphasized since only about seventy-five cases have been described. The usual story which is given is that a person is pinned by falling debris. On discovery several hours after, the patient appears to be in very good condition, if only an extremity is pinned, and is released. Swelling of the extremity ensues and the patient may present evidences of shock. This condition usually responds promptly to adequate intravenous therapy. The patient may be thought to be on the road to recovery when several days later oligemia, uremia, and death ensue. Death is believed to be due to renal failure.

A proper understanding of this condition has been retarded by the inability of investigators to reproduce the delayed renal failure experimentally. It would appear that the renal damage in man is due to some cause as yet unascertained, such as associated disease or infection, or that man and dog differ in their response to ischemia superimposed on trauma. In my opinion the main value in the reports lies in the attention which has been focused on the effects of ischemia, and particularly that which accompanies gross trauma. It would seem that it is in such conditions that one is most apt to be able to demonstrate toxic products. Furthermore, a renewed interest in renal function in shock has been stimulated.

Many suggestions have been made regarding the treatment of patients with crush injuries. Recent recommendations by Bywaters[12] are as follows:

"The natural tendency under emergency conditions is to treat shock first, then the local limb condition, and lastly the renal failure on or about the third or fourth day, when signs of renal damage are obvious. Since it is possible that the renal damage occurs soon after the reestablishment of an adequate blood supply to the damaged limb, these three aspects should be considered in the reverse order.

"1. Ample alkaline fluid (3 liters daily), by mouth preferably, or by rectum, intramuscularly or intravenously, must be given rapidly at the earliest possible moment, to produce an alkaline diuresis. If possible, this should be done while the patient is still trapped under the wreckage. We favour for ingestion an alkaline fluid flavoured with citrus juice or peppermint and glucose, containing sodium citrate and sodium bicarbonate, 2 g. of each to the ounce. Coffee or tea is also useful, and morphine should be given if required. For intravenous injection, isotonic sodium citrate (3.8 per cent) or sodium lactate (M/6) should be used. Enough alkali should be given to make the urine alkaline: This will mean probably 30 to 40 grams daily or more by mouth, or a lesser

quantity by intravenous injection. If tetany is induced, calcium gluconate should be given intramuscularly. Potassium salts must not be used. Sodium sulphate (2 per cent) may also be injected intravenously in combination with the above measures to maintain urinary output.

"2. With the kidneys thus protected, it is safe to restore the circulation by combating shock, if this is present. Plasma or serum should be given, or, if there has been much hemorrhage, blood. A large quantity may have to be administered: So long as the arterial blood pressure remains low no harm need be feared. Saline is of no value. Overheating the patient is dangerous."

This point of view is a very interesting one, and it would certainly seem that Bywaters is correct in his contention that diuresis should be stimulated. On the other hand, it would appear that impending shock should be treated concurrently by the intravenous administration of blood plasma.

Blast Injuries.—No attempt will be made to enumerate separately the findings of Hooker, of Zuckerman, of Denny-Brown, and of others, but the recent paper by Williams[13] will be reviewed in moderate detail. The pressure exerted by an exploding bomb may be tremendous. There are three components in the blast wave in *air:* (1) positive pressure wave acting directly on the chest and indirectly on the lungs through the diaphragm; (2) negative air suction wave; and (3) the mass movement of air or gas (windage factor). The mechanism of action of blast in *water* is somewhat different in that, generally speaking, only the primary positive pressure wave is of importance. Blast at an equal distance is more dangerous in water than in air because the rate of fall in pressure is much more rapid in air. This statement has to be modified somewhat if air blast occurs in the vicinity of rigid objects such as the walls of a building which will cause the pressure to be built up by reflection. Other parts of the body (abdominal contents, tympanic membranes, etc.) as well as the lungs may be injured by blast. Williams made the following statements concerning the mechanism of blast in water. "Now consider the human body, which has roughly the same density as water. When the pressure wave impinges on the body there will be no reflection, but the pulse will be transmitted through the tissues without displacement, just as if the body were so much water. However, when the transmitted pulse encounters an air cavity in the body, e.g., the lungs, the same phenomenon will occur as has been described above; that is, the static wave of pressure will change into a wave of kinetic energy in the layers of tissue lining that cavity and a disruptive effect will occur. Hence it can be understood that the lungs and other gas-filled cavities in the body are particularly susceptible to damage from the pressure wave, even though the body itself may not be deeply immersed."

An excellent dissertation on clinical immersion blast was presented in the issue of the United States Naval Medical Bulletin for January, 1943. In confirmation of previous observations, it was found that the severity of symptoms depended on the distance of the men from the source of the explosion and on their position in the water, whether horizontal or perpendicular, whether facing the blast or with their backs turned. On physical examination abnormal chest signs were more often absent than present, but roentgenograms revealed in all but one case out of a total of thirty-five slight to moderate areas of increased density at one or both bases. Severe intraabdominal lesions were present in a number of cases. The Naval observers conclude that the principal seat of trauma in atmospheric blast is in the thoracic cavity, whereas the predominating injuries in immersion blast are abdominal.

There is wide variation in the early signs and symptoms which may follow blast injuries as illustrated by the following example given by Williams. "Seven men on board of one of H.M. ships were in the vicinity of a magazine hatch when the ship blew up. These men managed to reach shore, but one of them felt so ill that he was unable to stand and had to be carried by his comrades to shelter in a school, where the party turned in for the night. The sick man was horrified to wake the next morning and see the remaining six men lying with rather blue faces and to be informed that they were all dead." Zuckerman found that some animals were able to run about for some time after exposure to blast.

In only four of 1,500 casualties mentioned by Williams were there internal blast injuries without external marks of violence. Patients with blast injury of the lungs usually have pain in the chest, difficulty in breathing, and a grunting cough. The cough is at first unproductive but later there is bloodstained sputum. Moderate cyanosis is usually observed. Although the clinical picture of "blast abdomen" varies greatly, there is usually abdominal pain, tenderness, and rigidity.

Aluminum suits lined with rubber have been shown to be effective in protecting against moderately severe pressure waves. They are, however, too expensive and cumbersome for general purposes. An inflated rubber jacket affords some protection. It is important to protect the abdomen as well as the chest. As stated previously, men swimming on their backs at the time of a blast are less apt to be injured severely than are those in the opposite position.

If shock results from the injury, it may be necessary to administer plasma, but this should be avoided if possible because pulmonary edema, if present, may be increased. Blast injuries of the lungs should be treated by rest, sedatives, the inhalation of high concentrations of oxygen, and respiratory isolation. Most patients who are suspected of having blast injuries of the abdomen recover without surgical intervention.

but all such patients should be followed closely for evidence of perforation of hollow organs or continued bleeding.

PREVENTION AND TREATMENT

Although much remains to be learned about the pathogenesis and treatment of shock, the available information about most types is not meager. A good job has been done in disseminating information but the efforts need to be increased. Civilian as well as military authorities on the subject should visit the various Army and Navy stations and should discuss the problems. There should be even more practice in the use of blood substitutes as contained in the Army and Navy packages. All medical officers should be thoroughly familiar with methods for grouping and matching blood.

Crystallization of opinion regarding the effectiveness or noneffectiveness of several agents has resulted from recent work. The value of adrenal cortical extract has been investigated very thoroughly, and it is agreed by most of the workers that it is not effective in the treatment of shock. The possibility remains that cortical extract may be helpful several days after injury when "adrenal exhaustion" may have occurred. If the observations to the effect that capillary permeability in traumatic shock is not increased are correct, then the theoretical reasons for the use of cortical extract are removed.

Regarding the value of the inhalation of high concentrations of oxygen there is some difference of opinion, but most of the observers are agreed that the benefit is slight. The oxygen saturation of the arterial blood is normal in most instances of shock. Difficulties of transporting containers of oxygen militate against the wide use of this agent of doubtful value.

In the absence of intracranial injuries, pain should be mitigated by morphine. Patients who are in shock rarely complain of pain, and the administration of large doses of morphine is a mistake. It is my opinion that one should not give as much as ½ gr. in a single dose even to the patient who is having pain. Morphine may cause nausea and vomiting which will further deplete the body of fluids. Moreover, the respirations may be unduly depressed. It is probably better to give ¼ gr. of morphine and to repeat this dose if necessary.

The head-down (shock) position is advisable for most patients with falling or low blood pressure. This position is not indicated for those with chest injuries, pulmonary edema, and head injuries.

It is fortunate that there is a growing appreciation of the dangers of the indiscriminate use of heat in the treatment of shock.[14] Too much heat is dangerous because it causes loss of fluid through sweating and inhibits the normal vasoconstrictive defenses of the body. The reduced blood volume in traumatic shock may be adequate to meet temporarily the requirements of the more vital structures such as the heart, the

brain, and the adrenals, but may be entirely inadequate if vasoconstriction in the extremities is replaced by vasodilatation as a result of the application of heat. An effort should be made to conserve body heat in the injured person who has been exposed to cold, but such a person should be covered with blankets rather than treated by surrounding him with hot-water bottles. When the patient has been placed in warm surroundings and when the deficit in blood volume has been repaired by appropriate therapy, the temperature of the extremities will usually return gradually to normal.

Since the major single cause of shock seems to be a decrease in the volume of the circulating blood, treatment is based on checking such loss and replacing body fluids by the best means at hand. Measures which may be effective in the early stages may not result in sustained improvement at a later time.

Hemorrhage should be controlled as quickly as possible, preferably either by ligating a bleeding vessel or by pressure. The use of a tourniquet on an injured extremity should be avoided whenever possible. If it is unavoidable, several points should be borne in mind. The tourniquet should be placed as low as possible on the limb. If a means for cooling the part distal to the tourniquet is available, this should be done in order to reduce the nutritional requirements and the production of metabolic end products. The temperature should not be lowered below 50° F. or 10° C. If a limb is hopelessly mangled, a tourniquet should be applied just below the site of election for amputation and should be left in place until the extremity has been removed.

Fluid administration, including the use of blood and blood substitues, is the single most effective means of treatment. Water should be given by mouth if not contraindicated and if tolerated. If water is not retained, hot tea or coffee should be tried.

While salt and glucose solutions are excellent for the correction of dehydration, their use does not usually result in sustained improvement in the treatment of shock. The intravenous injection of large quantities of solutions of crystalloids in the presence of gross capillary damage may result in harmful[15] rather than beneficial effects.

The main reliance in preventing and treating shock is the use of adequate quantities of whole blood, plasma, or albumin. Unless pulmonary edema is suspected, blood or a substitute may be given as rapidly as one pint of isotonic fluid in ten minutes. If the desired effect is not obtained in fifteen minutes, the dose should be repeated. Whole blood is preferable to a substitute if there has been massive hemorrhage, but plasma should be given in the meantime if delay is entailed in the use of whole blood.

The initial injection of a blood substitute may be two units of reconstituted plasma or its equivalent, one unit (25 Gm.) of concentrated

albumin. Since a significant elevation in the blood pressure usually accompanies the administration of a relatively small volume of concentrated albumin, an effort should be made to attain as adequate hemostasis as possible before the albumin is given. Since the concentrated albumin draws fluid from the tissue spaces into the blood stream, dehydrated patients should be given additional water and salt. When normal salt solution is available, the concentrated albumin may be diluted in the ratio of two units (50 Gm.) to a liter of the salt solution. It seems advisable not to give more than ten units of albumin in a forty-eight-hour period.

Simple dehydration collapse in the absence of injuries is treated by cooling the patient and by giving salt solution by mouth. The fluid should be given intravenously if it cannot be taken by mouth. As soon as sweating stops, one should proceed cautiously in efforts to reduce an elevated temperature.

It would appear to be desirable to make some of these recommendations more specific. Such a procedure is difficult, however, in view of the great variation in conditions of all kinds to which the fighting forces are exposed.

UNSOLVED PROBLEMS

It is the opinion of some that little is known about shock and that the major problems are unsolved. Such persons must find it difficult to explain why traumatic and postoperative shock are encountered so infrequently today in the civilian practice of surgery. As stated previously, it is my contention that a great deal of useful information is available at present. At the same time, there are many unsolved problems, and a few of them will be mentioned and discussed briefly.

Pathogenesis.—1. There is need for further search for and identification of a toxic factor or factors. It follows that there should be efforts to find an antidepressor substance or substances. It is my opinion that this is the number one problem since the results of regional loss of fluid can be combated fairly effectively by the use of blood and blood substitutes. All such studies should take into account this loss of fluid. It should be emphasized that the important point is to identify the depressor substance or substances rather than simply to perform experiments the results of which suggest that toxic products are present. Recent work seems to show that the so-called toxic substance may be simply a disturbance in tissue metabolism.

2. There should be additional studies on the nervous factors in various types of shock. It would seem that the therapeutic implications which might emanate from such studies would not be so great as those which might result from work on depressor and antidepressor substances. The results which have attended the blocking of the nerve supply of an injured area have not been very encouraging.

3. The recent observations to the effect that there is not a general increase in capillary permeability even in advanced shock should be confirmed or denied. If it is true that red blood corpuscles are trapped, it should be determined where they are trapped. If chiefly red corpuscles are trapped, where is the plasma? A particular effort should be made to determine whether the capacity of the venous system is greatly increased.

4. The role of ischemia in the causation of shock should be further elucidated. Ischemia of various organs as well as of skeletal muscle should be studied.

5. There is suggestive evidence that in some types of shock there is loss of ability to restore plasma volume by withdrawal of fluid from the tissues. Further work on this subject should be undertaken.

6. It is rather generally agreed that the heart usually is not at fault in the genesis of early shock. The work of Wiggers and others suggests that its function may be impaired in later stages. More work should be done.

7. Much remains to be learned about renal function in various types of shock. The cause of renal failure in some instances of crush injuries and burns should be determined. Fortunately, a number of competent investigators are working on this subject.

8. The terms reversible and irreversible are often used in designating the stages of shock. What occurs that changes the reversible to the irreversible stage and what signs, if any, indicate this alteration? Some information on this subject is available but more is needed.

9. Further studies on the effects of alterations in body temperature, local and general, in the pathogenesis of traumatic shock should be made. The effects of lowering the general body temperature in the presence of fever resulting from infection should be investigated.

10. Very little is known about the influence which infection, superimposed on injuries, exerts in the pathogenesis of shock. This is a difficult problem to approach but information is urgently needed.

11. There seems to be little doubt that fat embolism is responsible for an occasional case of shock. Further clinical observations should supply additional information on this subject.

PREVENTION AND TREATMENT

The following are a few of the many subjects on which additional information is needed:

1. If blood is trapped, can a means be found for restoring the trapped or segregated blood to active circulation? If there is an excess of blood in the veins, is there a mechanical means by which its return to the heart can be facilitated?

2. Do substances such as hypertensin exert a beneficial effect in the treatment of shock? The preliminary observations of Ogden, Collins,

Dexter, Braun-Menendez, and others on hypertensin in this connection are interesting.

3. Although it is agreed that adrenal cortical extract is not effective in the prevention or treatment of shock, except in adrenal insufficiency, does the use of adrenal extract accomplish good several days or longer after injuries when adrenal "exhaustion" may have occurred?

4. Should injured areas (burns, etc.) be cooled? If so, what degree of cold is optimal? A simple method for cooling an injured extremity, particularly one to which a tourniquet has been applied, is needed. This problem might appear to be an easy one, but actually under most conditions of warfare it is very difficult to cool a part by artificial means.

5. What quantity of blood or blood substitute is needed and at what rate should the fluid be administered? It is obvious that the answers vary from case to case, depending upon the nature and severity of the injury. The quantity required in the treatment of burns is relatively easy to determine, for it may be estimated from the extent of the burn or the increase in the concentration of the red blood corpuscles or hemoglobin content. The problem is not so simple in those injuries in which there is a loss of red blood cells as well as plasma. A rapid uncomplicated method for determining the blood volume or the state of hemoconcentration or hemodilution on the battlefield would be very helpful.

6. Concentrated human albumin presents the advantages over liquid blood plasma of easier preservability and transportability, but is albumin as effective as plasma in the prevention and treatment of shock? Clinical experiences with albumin have been very gratifying, but some of the experimental work indicates that it is inferior to blood plasma. Further investigation of the subject is needed.

7. How much blood or plasma in which sodium citrate is used as the anticoagulant may be given with safety in a short period of time? The recent work of Ivy and his associates[16] shows that there is a limit beyond which the citrate produces marked disturbances.

8. Is it possible to obtain a fraction of animal plasma which is nonantigenic for man? Much work is being carried out on this subject.

9. Can the quantity of plasma that is necessary in the treatment of shock be reduced by the use of amino acid mixtures? A number of investigators, including, Elman, Brunschwig, and Whipple, are advancing our knowledge on this and other questions.

10. The widespread use of plasma has resulted in the discarding of enormous quantities of red blood corpuscles. Is there some need for which these corpuscles or fractions of them could be utilized?

11. Are there substitutes not of animal origin which are as effective or almost as effective as plasma in the treatment of shock? None has been found as yet, but an intensive search continues by various groups.

12. Are thiamine and vitamin C, in the absence of vitamin deficiencies, helpful in the prevention and treatment of shock? Is it possible to sup-

ply substrates which will aid in the correction of disorders in metabolic processes? If the hypothetical toxic substances are simply the results of disorders in tissue metabolism, can a method be found to correct the abnormalities? The enzyme systems in shock should be carefully investigated.

13. The question frequently has been asked whether it is possible to "precondition" men in dangerous military zones in order to lessen the chances of the development of shock if injury should occur. Is it possible to have a reserve storage of fluid in the body tissues? In particularly dangerous times, is the oral administration of normal salt solution or glucose indicated? The answers to these questions have not been supplied.

14. Is there some way to prevent the nausea and vomiting which are usually part of the shock picture? If we assume that a significant part of the fluid taken by mouth would be absorbed, the abolition of nausea and vomiting would be a great advance in therapy. It is much more desirable to give nonprotein-containing fluids by the oral route, unless contraindicated, than by the intravenous one.

15. In the treatment of crush injuries should one attempt to cause an increase in urinary output by the administration of fluid by various routes before one treats the impending shock by the injection of blood plasma? Should a tourniquet be applied and amputation performed as soon as possible in those instances in which an extremity has been pinned longer than several hours? Much remains to be learned about crush injuries.

16. In regard to "position" in shock, how much should the head be lowered and how long should this position be maintained? It is agreed that the head-down position is indicated for most patients in shock except for those with brain and pulmonary injuries.

17. What is the best anesthetic to employ in the treatment of the severely wounded? Local infiltration is safest but frequently is inadequate. Most observers agree that anesthetic doses of intravenous barbiturates and of agents injected into the spinal canal are dangerous for these patients. Cyclopropane and ethylene are usually not available. Nitrous oxide should not be used except for very brief procedures. As emphasized by Bartlett and Evans, intercostal nerve block lessens the dose of the general anesthetic agent that is required for abdominal operations. Ether, though presenting some disadvantages, remains among the safest of the agents for inhalation. Possibly the dangers in the use of chloroform have been overemphasized. The probable ill effects of this agent should be reinvestigated. The situation regarding the choice of anesthetic agents for the treatment of shock needs clarification.

18. How much morphine should be given to an injured person? Should not a distinction be made in dosage according to whether or not

the patient is in shock? Patients in shock rarely complain of severe pain. Is morphine responsible for some of the nausea and vomiting that often accompanies shock? It is my impression that, except in unusual circumstances, it is unwise to administer as much as ½ gr. of morphine in a single dose.

19. Is it not possible to provide more adequate protection against injuries in the military forces? Is it possible to devise a more effective means for cushioning the pressure wave of water blast? Should protective chest and abdominal armor plates be used more extensively? Can the hazards of burns on ships be lessened by alterations in the type of clothing that is worn? The value of adequate covering of the skin has been demonstrated in the case of flash burns.

20. With the knowledge that the ideal treatment of penetrating abdominal wounds is immediate operation, but that this is impossible in some of the forward areas, is there some nonoperative means which will result in a greater saving of lives than at present? This is one of the most important problems confronting military surgeons.

21. A number of miscellaneous questions might be asked. Is the available information on the pathogenesis, prevention, and treatment of shock being conveyed effectively to the men, usually battalion medical officers, who will actually treat the injured? Should there be teams composed of military and civilian surgeons who could instruct the physicians and their assistants in the various camps? If so, there should be demonstrations of the use of blood substitutes as contained in the Army-Navy packages. Should there be a number of men in the services who specialize in intravenous therapy, including blood grouping and matching? In the short time available, are our students and house officers getting adequate instruction in the treatment of the various types of injuries that are encountered in warfare? Could a more adequate description of the medical problems which are met in the various fighting zones be sent to designated centers in this country in order that instructors and investigators could carry out their duties more intelligently? One realizes, of course, that total mobile warfare presents many impediments to the adoption of routine methods of therapy and to the wide dissemination of information.

CONCLUSIONS

There are many types of shock, and we are dealing with "problems of shocks rather than the shock problem." The most commonly encountered etiologic agent in the genesis of traumatic shock is the regional loss of plasma or whole blood from the blood stream. There are many unsolved problems, some of which have been considered, but the available information is such that the majority of instances of traumatic shock can be prevented or treated successfully if advantage is taken of existing knowledge.

REFERENCES

1. Blalock, A.: Experimental Shock. The Cause of Low Blood Pressure Produced by Muscle Injury, Arch. Surg. 20: 959, 1930.
2. Parsons, E., and Phemister, D. B.: Hemorrhage and "Shock" in Traumatized Limbs, Surg., Gynec. & Obst. 51: 196, 1930.
3. Cournand, A., Riley, R. L., Bradley, S. E., Breed, E. S., Noble, R. P., Lanson, H. D., Gregersen, M. I., and Richards, D. W.: Studies of Circulation in Clinical Shock, SURGERY 13: 964, 1943.
4. Fine, Jacob, and Seligman, A. M.: Traumatic Shock. IV. A Study of the Problem of the "Lost Plasma" in Hemorrhagic Shock by the Use of Radioactive Plasma Protein, J. Clin. Investigation 22: 285, 1943.
5. Root, G. T., and Mann, F. C.: An Experimental Study of Shock With Special Reference to Its Effect on the Capillary Bed, SURGERY 12: 861, 1942.
6. Govier, W. M., and Greer, C. M.: Studies on Shock Induced by Hemorrhage. I. Effect of Thiamin on Survival Time, J. Pharmacol. & Exper. Therap. 72: 317, 1941.
7. Engel, Winton, and Long: 1943. (In press.)
8. Mylon, E., Winternitz, M. C., and de Suto Nagy, G. J.: Studies on Therapy in Traumatic Shock, Am. J. Physiol. 139: 313, 1943.
9. Kekwick, A., Marriott, H. L., Maycock, W. d'A, and Whitby, L. E. H.: Diagnosis and Treatment of Secondary Shock, Lancet 1: 99, 1941.
10. Grant, R. T., and Reeve, E. B.: Clinical Observations on Air-Raid Casualties, Brit. M. J. 2: 293, 1941.
11. Elkinton, J. R., Wolff, W. A., and Lee, W. E.: Plasma Transfusions in the Treatment of the Fluid Shift in Severe Burns, Ann. Surg. 112: 150, 1940.
12. Bywaters, E. G. L.: Crushing Injury, Brit. M. J. 2: 643, 1942.
13. Williams, E. R. P.: Blast Effects in Warfare, Brit. J. Surg. 30: 38, 1942.
14. Blalock, A., and Mason, M. F.: A Comparison of the Effects of Heat and Those of Cold in the Prevention and Treatment of Shock, Arch. Surg. 42: 1054, 1941.
15. Beard, J. W., Blalock, A., and others: Intravenous Injections, J. Clin. Investigation 11: 249-325, 1932.
16. Ivy, A. C., Greengard, H., Stein, I. F., Grodins, F. S., and Dutton, D. F.: The Effect of Various Blood Substitutes in Resuscitation After an Otherwise Fatal Hemorrhage, Surg., Gynec. & Obst. 76: 85, 1943.

THE EFFECT OF INFUSIONS OF BOVINE SERUM ALBUMIN IN EXPERIMENTAL SHOCK*

J. E. DUNPHY, M.D.,† AND JOHN G. GIBSON, II, BOSTON, MASS.

(From the Laboratory of Surgical Research, Harvard Medical School, and the Medical and Surgical Service of the Peter Bent Brigham Hospital, Boston)

THE search for an adequate and readily available substitute for blood in the treatment of traumatic shock has led to the preparation of purified fractions of plasma proteins of both human and animal origin.[1,8] Such preparations appear to have certain advantages over blood or plasma in that they are more readily preserved or transported and, with respect to animal fractions, are unlimited in source. This study was undertaken to determine the efficacy of bovine serum albumin in experimental shock. Particularly severe thermal trauma, involving one-third or more of the total body area in dogs, was selected as a means of producing shock because extensive observations on the effects of treatment in this type of injury in human beings are difficult to obtain.

The course of the changes in hematocrit, plasma volume, plasma protein concentration, pulse rate, and blood pressure following thermal trauma in dogs has been described previously.[5,9] Although there is some variation in individual animals, in general the course of this type of shock is sufficiently uniform to permit an evaluation of therapeutic procedures. The characteristic changes in untreated dogs are depicted in Fig. 1. There is a rapid reduction of plasma volume with marked hemoconcentration, followed by a continued but more gradual change in the same direction The concentration of plasma proteins at first increases slightly, then falls moderately, but from the onset there is a marked reduction of total circulating protein. An initial fall of mean arterial blood pressure followed by a rise, sometimes above the preexisting level, which is maintained until just before exitus, is the rule. The pulse rate rises early and shows a progressive upward trend, being above 200 toward the end of the experiment. Pathologic examination of the animals sacrificed early in the experimental period discloses very little variation from the normal, but in animals which die or are sacrificed late, that is after seven to fifteen hours, microscopic changes similar to those described by Moon[10] are consistently present.[5]

The effects of various forms of replacement therapy on the plasma volume, circulatory changes, and pathologic findings under the conditions of these experiments have been described before.[4] It is sufficient

*The work described in this paper was done in part under a contract recommended by the Committee on Medical Research, between the Office of Scientific Research and Development and the Peter Bent Brigham Hospital.

†Major, Medical Corps, U. S. Army, Fifth General Hospital.

Received for publication, April 26, 1943

to state here that when a continuous infusion of normal or slightly diluted plasma is given in amounts of 75 to 100 c.c. an hour, depending on the size of the animal, the plasma volume and peripheral circulation are well maintained and there is a striking amelioration of the usual tissue changes of advanced shock. The points which seemed desirable to determine in this study were:

1. Is bovine serum albumin toxic to dogs when injected after an injury which involves extensive tissue damage?

2. Does bovine serum albumin remain in the circulation sufficiently long to maintain plasma volume?

3. How effectively, in comparison with plasma, will bovine serum albumin limit the circulatory and pathologic changes which follow severe burns?

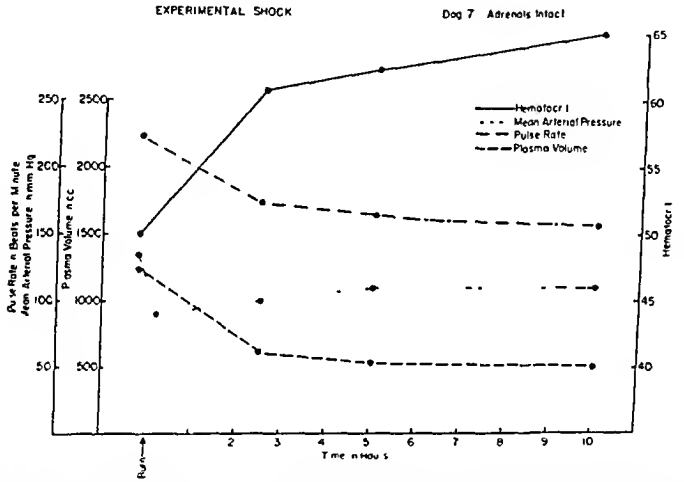

Fig. 1.—Changes in plasma volume, hematocrit, pulse rate, and mean arterial pressure in shock due to burns, untreated. Animal sacrificed at ten hours.

EXPERIMENTAL PROCEDURE

Mongrel dogs were used in all the experiments. A splenectomy was performed several weeks prior to the crucial experiment because previous observations in dogs indicated that otherwise the activity of the spleen caused wide fluctuations in the hematocrit with little relation to changes in red cell volume. The animals were given water liberally but no food for twenty-four hours before the experiment. Anesthesia was induced with sodium pentobarbital in doses of 32 mg. per kilogram of body weight and maintained throughout the experiment by small supplementary injections as needed. The possible disadvantages of this agent as an anesthetic have been discussed previously and the effects of the drug in control animals described.[5]

The mean arterial blood pressure was recorded by means of a mercury manometer connected by a cannula with the right femoral artery. At

frequent intervals, the pulse rate was counted at the apex of the heart by means of a stethoscope, as well as being recorded on the kymograph. The respiratory rate was also taken frequently. The plasma volume was determined by the direct method of Gibson and Evans,[6] a reinjection of dye being made for each determination. The plasma proteins were determined by the micro Kjeldahl method. The prothrombin time was determined by the method of Quick.[12]

All samples of blood were taken from the jugular veins which were exposed for this purpose but protected by sponges moistened in saline solution. All infusions were given through the left femoral vein which was cannulated for that purpose.

The fractions of plasma proteins employed in these investigations were prepared by E. J. Cohn, W. L. Hughes, Jr., L. E. Strong, and their colleagues in the Harvard Plasma Fractionation Laboratory in collaboration with J. D. Porsche and his colleagues in the Armour Laboratories. As this study progressed, increasingly pure preparations of bovine serum albumin were made available. In the later experiments a solution of crystallized bovine serum albumin was used. This proved so much more efficacious that certain opinions based on the earlier studies had to be revised. However, all the experiments are included in this report.

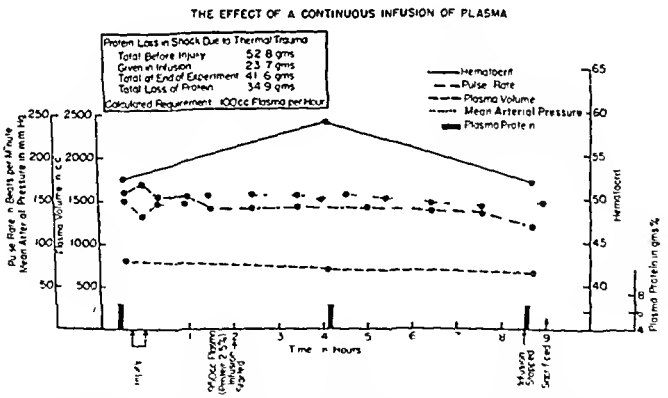

Fig. 2.—Continuous infusion of plasma in amounts equal to the stipulated requirement maintained plasma volume and mean arterial pressure satisfactorily.

The results are given in Table I. In the early experiments in which comparatively crude preparations were used, the results although by no means comparable to the effects of plasma, were encouraging in that they demonstrated that a heterologous albumin fraction remained in the circulation sufficiently long to maintain plasma volume for several hours and did so apparently without a notable toxic reaction. This was especially impressive when the experiment was of short duration as in Nos. 1, 3, and 4. In the longer experiments, Nos. 2 and 5, the results

TABLE I

EXPERIMENT NO.	DATE	WGT. (KG.)	TYPE OF THERAPY	TIME	PULSE RATE PER MIN.	MEAN ARTERIAL PRESSURE (MM. HG)	RESPIRATORY RATE PER MIN.	HEMATOCRIT (VOL. %)	PLASMA VOLUME (C.C.)	TOTAL PROTEIN (GM. %)
1	4/14/41	15.3	Amorphous bovine serum albumin, 350 c.c. by continuous intravenous infusion at 50 c.c. per hr. for 6 hr. started ¼ hr after injury	Before injury	200	145	10	50.0	840	6.3
				¼ hr. after injury	220	140	--	53.1	---	7.0
				4 hr. after injury	156	144	14	50.8	---	6.3
				5¼ hr. after injury	130	150	20	48.6	---	6.8
				6¼ hr. after injury	130	145	16	47.8	670	6.0
2	4/24/41	18.6	Amorphous bovine serum albumin, 500 c.c. (25 Gm.) in 4 hr. Started 10 min. after injury	Before injury	175	130	7	47.7	926	6.5
				10 min. after injury	170	60	24	53.0	---	--
				4 hr after injury	250	140	28	42.6	770	6.4
				8 hr. after injury	250	110	36	41.0	800	6.0
			500 c.c. (25 Gm.) in 3 hr. Started 5 hr. after injury							
3	5/22/41	20.0	Amorphous bovine serum albumin, 460 c.c. (20.4 Gm.) in 5½ hr. Started 10 min. after injury	Before injury	135	136	4	47.0	1140	7.1
				10 min. after injury	138	125	3	56.5	----	7.2
				2 hr. after injury	120	140	6	51.5	----	6.7
				6 hr. after injury	100	135	3	47.5	1140	6.9
4	5/27/41	15.4	Amorphous bovine serum albumin, lot 10 11, 350 c.c. (11.0 Gm.) in 5 hr. Started 20 min. after injury	Before injury	160	110	6	47.4	637	5.8
				10 min. after injury	172	118	3	53.5	---	7.0
				3 hr. after injury	170	130	20	46.0	---	--
				5 hr. after injury	190	120	24	39.2	500	5.9
5	6/12/41	19.3	Amorphous bovine serum albumin, lot 16, 750 c.c. (37 Gm.) in 8 hr. Started 30 min. after injury	Before injury	180	115	6	43.1	1120	6.0
				15 min. after injury	167	110	10	49.0	----	6.8
				4½ hr. after injury	170	105	18	37.4	965	5.3
				8¼ hr. after injury	190	100	40	31.0	1265	5.2

6	7/ 1/41	23.5	Amorphous bovine serum albumin, lot 17, 360 c.c. (17.6 Gm.) in 3 hr. Started 30 min. after injury	Before injury	116	125	4	41.8	1290	5.8
				15 min. after injury	110	95	15	48.3	----	6.1
				4 hr. after injury	114	145	14	48.3	1025	5.9
				7 hr. after injury	180	165	10	44.1	1130	6.0
			250 c.c. of dog plasma (15 Gm.) in 2 hr. Started 4½ hr. after injury							
7	7/15/41	21.6	Dog plasma, 340 c.c. (27.2 Gm.) in 4 hr. Started 30 min. after injury	Before injury	146	130	8	53.7	1080	6.5
				20 min. after injury	160	140	10	59.0	---	--
				4¼ hr. after injury	180	160	10	57.2	960	6.6
				8½ hr. after injury	180	160	10	52.2	880	6.1
			Bovine serum albumin, lot 17, 280 c.c. (18.5 Gm.) in 2 hr. Started 4½ hr. after injury							
8	3/25/42	25.7	Crystallized bovine serum albumin CB_a, 800 c.c. (48.8 Gm.) in 8 hr. Started 15 min. after injury	Before injury	150	120	6	47.0	1415	5.6
				10 min. after injury	150	100	12	52.0	----	5.8
				2 hr. after injury	140	115	34	50.5	----	5.4
				5 hr. after injury	160	115	20	48.4	----	5.5
				8 hr. after injury	200	136	18	47.5	1175	5.6
9	3/10/42	13.6	Crystallized bovine serum albumin CB_a, 100 c.c. (30 Gm.) in 7 min. Beginning 6 min. after injury	Before injury	144	118	8	50.4	630	5.5
				30 min. after injury	136	130	7	45.6	---	7.4
				1 hr. after injury	136	120	6	45.8	---	6.2
				4 hr. after injury	160	110	6	50.0	460	5.5
10	3/17/42	18.2	Crystallized bovine serum albumin, 110 c.c. (33 Gm.) in 7 min. Started 18 min. after injury	After injury	110	120	18	45.7	1100	6.2
				15 min. after injury	104	100	24	46.7	----	7.3
				45 min. after injury	110	115	24	39.6	----	6.3
				2½ hr. after injury	116	124	12	46.2	----	6.6
			Crystallized bovine serum albumin, 80 c.c. (24 Gm.) in 5 min. Started 6 hr. after injury	5¼ hr. after injury	124	124	16	51.1	1060	6.7
				8½ hr. after injury	130	120	16	42.8	940	7.7

were less impressive. In no instance was the effect of the replacement entirely comparable to that seen with continuous infusions of dog plasma. The effects of a prolonged plasma infusion are compared with albumin in Figs. 2 and 3. Note that when plasma was given there was

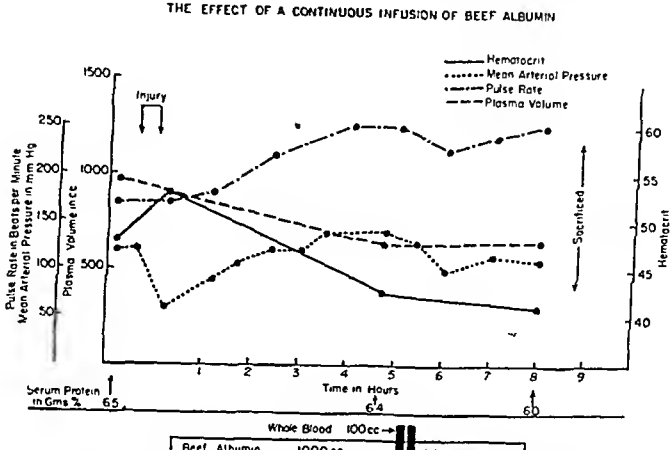

Fig. 3.—Continuous infusion of amorphous beef serum albumin prevented excessive loss of plasma and was effective in maintaining the mean arterial pressure.

little change in the pulse rate and a gradual fall in the plasma volume, no gross abnormalities were found and microscopically there was a striking amelioration of the usual late tissue changes.[4] Following continuous prolonged infusion of albumin, however, free fluid in quantities of 20 to 100 c.c. was found in the pleural and peritoneal cavities and the microscopic changes in the viscera were fairly marked although, in general, much less severe than that seen in untreated animals.

One finding which is not entirely explained was the marked reduction of the hematocrit out of all proportion to the changes in plasma volume, seen in experiment Nos. 2, 4, and 5. There was little gross loss of blood in most of these experiments, although in Nos. 2 and 5 there was quite marked oozing of blood from the wounds where vessels were exposed for sampling of blood. It is well established that saline solution infused into the blood stream in shock leaks out of the circulation not as saline but as dilute plasma.[2] It seemed possible that albumin, when given in continuous infusion, leaked out not as albumin but as dilute plasma and thereby carried with it other protein elements such as prothrombin. The possibility of an acute hypoprothrombinemia was investigated but low levels by the Quick method were found in only one, No. 2, of the five experiments, Nos. 1, 2, 3, 4, and 5, in which it was determined. Since the protein concentration remained essentialy normal, it is not likely that the decrease in hematocrit was due to changes in individual cell volume. The exact cause of the severe reduction of the hematocrit observed in these experiments is not yet explained. It is

worthy of note that similar reductions were not observed with prolonged plasma infusions.[4]

Since an infusion of amorphous albumin seemed capable of maintaining the circulation and plasma volume for short periods of time only, the possibility of using albumin as an adjunct to plasma was investigated in experiment Nos. 6 and 7. In each instance, plasma appeared to be the somewhat more effective replacement fluid (Figs. 4 and 5). However, it is quite significant that the net result in each experiment was quite comparable to that seen with plasma alone (Fig. 2). Moreover, pathologic study of the viscera of these animals disclosed the same amelioration of the pathologic changes of advanced shock that is seen following continuous infusions of plasma.

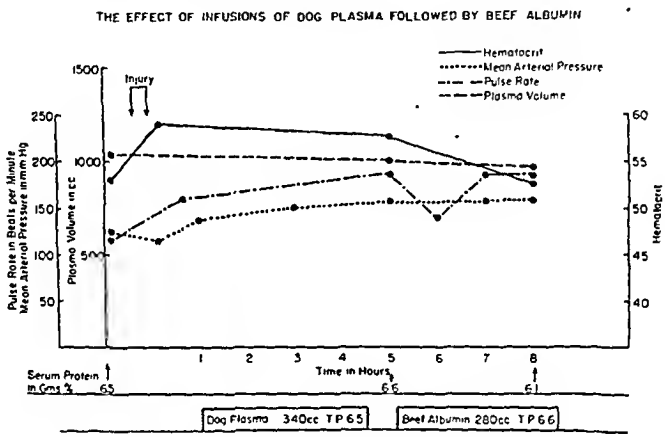

Fig. 4.—Both dog plasma and bovine serum albumin maintain plasma volume and mean arterial pressure satisfactorily.

At this point in the study, a preparation of crystallized albumin of great purity was made available to us. This was used in experiment Nos. 8, 9, and 10, in the first as a dilute solution (6 per cent concentration) and in the last two as a concentrated solution. The results of the continuous infusion of the crystallized albumin in experiment No. 8 were much more impressive than that seen following the use of amorphous albumin in experiment No. 2. However, since only one of the elements of plasma is replaced by an infusion of albumin, it is not possible to consider it a complete and adequate replacement for plasma if the losses are large and continuous. This was borne out by the fact that in the later stages of this experiment there was some oozing of blood, a rise in pulse rate, a moderate fall in plasma volume, and, on pathologic examination, moderate tissue changes especially in the kidneys, lungs, and adrenals were found.

The effects of infusions of concentrated albumin, 25 to 30 per cent, were studied in the last two experiments. The results merit considerable attention. It is evident that the plasma volume was maintained at close

to normal levels by a quantity of replacement fluid considerably less than that usually required (Fig. 6). When continuous infusions of dilute plasma or albumin are given, amounts up to 75 to 100 c.c. per hour for a 20 kg. dog are necessary to maintain the plasma volume and protein concentration. In these later two experiments, amounts of 100

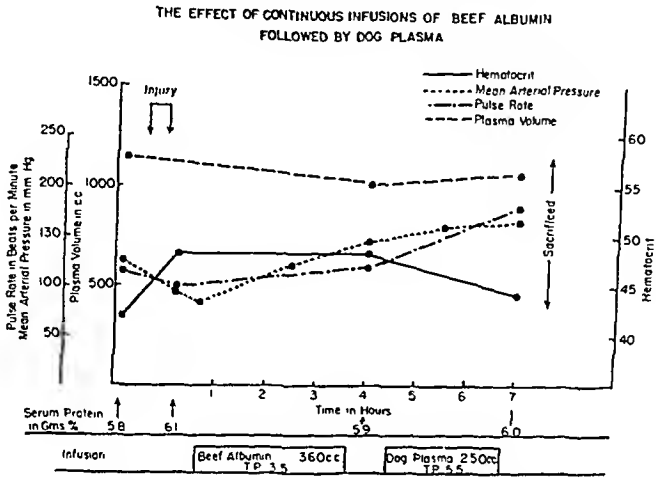

Fig. 5.—The bovine serum albumin was satisfactory in maintaining volume and pressure but not as effective as dog plasma.

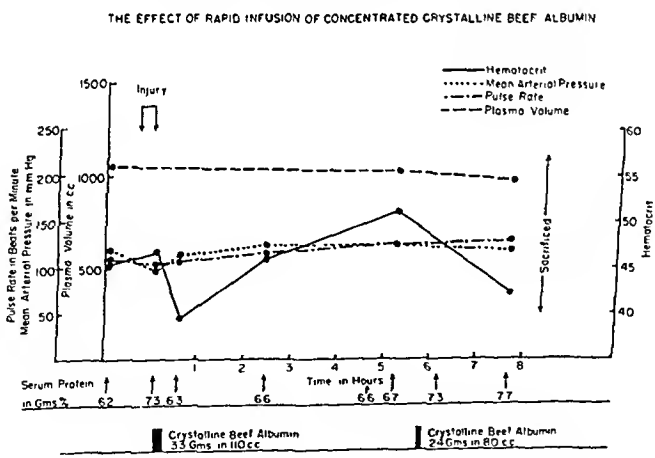

Fig. 6.—Rapid infusions of concentrated crystallized bovine serum albumin maintain plasma volume and pressure for five hours without the addition of further fluids. A second injection was as effective as the first.

and 200 c.c. seemed to accomplish the same effect for five and eight hours respectively. Whether this was accomplished by absorption of available tissue fluids into the blood stream by the concentrated protein or by the prevention of fluids being lost into the burned area is not entirely clear. There seemed to be less edema and loss of fluids into the burned area in the experiments in which the concentrated solution was

used, but no actual determination of the comparative amounts of fluid in the injured areas was attempted.

On the other hand, the pathologic changes found on post-mortem examination in experiment Nos. 9 and 10 were quite advanced for the respective duration of the experiments. The changes involved principally the lungs, kidneys, and gastrointestinal tract. The degree of congestion and edema was similar in character but not degree to that seen in untreated animals. The liver showed very little congestion but there were scattered areas of necrosis characterized by altered staining reaction of the cells and a light infiltration of polymorphonuclear leucocytes. Although these changes were fairly advanced, it is important to emphasize that there was nothing in the histologic appearance of these lesions to indicate that they were irreversible. Nevertheless, the extent of the changes is a reason for accepting the apparently excellent response of the circulation and plasma volume to therapy with concentrated plasma proteins with a certain amount of caution.

The optimum concentration of plasma or protein solutions for use in traumatic shock has not been determined. Despite enthusiastic reports[3, 11] on the use of concentrated plasma, the issue cannot be regarded as definitely settled. While it is true that in the well-hydrated individual interstitial fluid provides a large reservoir which apparently can be utilized to a great extent without danger, in the dehydrated subject or after especially severe losses, as in extensive burns, there is at least a hypothetical hazard of mobilizing extracellular fluids to a harmful degree. The excellent results of experiment No. 10, in which a concentrated solution of albumin maintained the plasma volume at close to a normal level for eight hours after an especially severe injury, indicates that the dangers are not as great as might be supposed. That there is a limit to which a concentrated solution can compensate for fluid losses is obvious and the accentuation of the visceral pathologic changes in experiment Nos. 9 and 10 suggest that the replacement was not ideal.

A determination of the optimum concentration for plasma protein when used in shock is not within the scope of this communication. It is a pressing problem which requires further study. Until further evidence is available, a reliable guide would seem to be the principle advocated by Blalock[3] of "replacing the lost fluids in the form in which they are lost" with the additional proviso that in the early stages of shock, before dehydration is established, a concentrated solution may be of value in providing an immediate excess of protein, maintaining plasma volume by utilizing available interstitial fluids, and possibly in limiting total fluid losses. The fact that concentrated plasma proteins are readily stored and transported in compact form make them extremely valuable for this purpose in the early treatment of shock in wartime.

SUMMARY

Infusions of bovine serum albumin were given to dogs after severe thermal trauma without evident toxic reaction. Continuous infusions of normal or slightly dilute solutions adequately maintained plasma volume and circulatory tone for considerable periods of time. When protein and fluid losses were large and continuous, such preparations were not quite as efficacious as plasma. When normal or slightly dilute solutions were used as an adjunct to plasma, the results were quite comparable to complete plasma replacement.

Small infusions of concentrated bovine serum albumin, 25 to 30 per cent, maintained plasma volume and circulatory tone as effectively as large infusions of normal or dilute solutions. The indications for and possible dangers of using concentrated solutions are discussed.

REFERENCES

1. Cohn, E. J., McMeekin, T. L., Oncley, J. L., Newell, J. M., and Hughes, W. L.: Size and Charge of Proteins Separating Upon Equilibration Across Membranes With Ammonium Sulfate Solutions of Controlled pH, Ionic Strength, and Temperature, J. Am. Chem. Soc. 63: 3386, 1940.
   Cohn, E. J., Luetscher, J. A., Jr., Oncley, J. L., Armstrong, S. H., Jr., and Davis, B. D.: Size and Charge of Proteins Separating Upon Equilibration Across Membranes With Ethanol-Water Mixture of Controlled pH, Ionic Strength, and Temperature, J. Am. Chem. Soc. 63: 3396, 1940.
   Cohn, E. J.: The Properties and Functions of the Plasma Proteins, With a Consideration of the Methods for Their Separation and Purification, Chem. Rev. 28: 395, 417, 1941.
2. Beard, J. W., and Blalock, A.: Arch. Surg. 22: 617-625, 1931.
3. Blalock, A.: St. Louis, 1940, C. V. Mosby Co.
4. Dunphy, J. E., and Gibson, J. G., II: SURGERY 10: 708, 1941.
5. Dunphy, J. E., Gibson, J. G., II, and Keeley, Jr.: Surg., Gynec. & Obst. 72: 823-833, 1941.
6. Gibson, J. G., II, and Evans, W. H., Jr.: J. Clin. Investigation 16: 301, 1937.
7. Hill, J., Muirhead, E. E., Ashworth, C. T., and Tigertt, W. D.: J. A. M. A. 116: 395, 1940.
8. Janeway, C. A., and Beeson, P. B.: J. Clin. Investigation 20: 435, 1941.
9. Keeley, J. L., Gibson, J. G., II, and Pijoan, M.: SURGERY 5: 872, 1939.
10. Moon, V. H.: New York, 1938, Oxford University Press.
11. Muirhead, E. E., and Hill, J. M.: Ann. Int. Med. 16: 286, 1942.
12. Quick, A. J.: J. A. M. A. 110: 1658, 1938.

VENOUS PRESSURES IN PATIENTS WITH VARICOSE VEINS*

H. S. Mayerson, Ph.D., Carroll H. Long, M.D., and E. J. Giles, M.D.
New Orleans, La.

(From the Departments of Physiology and Surgery, School of Medicine, Tulane University of Louisiana, New Orleans)

IN CONNECTION with a general investigation of the effects of posture on the cardiovascular system, it seemed of interest to determine the venous pressures in patients with varicosities of the saphenous veins. The frequent occurrence of varicosities in individuals whose occupations involve considerable standing has led to the belief that conditions imposed by the upright position, such as the high venous pressures in the extremities, are important factors in the development of varicosities.[1, 2] It, thus, has often been assumed that the venous pressure in incompetent, varicosed veins is abnormally high,[3] although a reasonably thorough search of the literature reveals but few studies in which the pressures have been directly measured,[1, 4-8] and only two instances[6, 8] in which parallel control determinations have been made on nonvaricosed "normal" veins. The latter study showed that when patients with varicosed veins are in the standing position, the saphenous pressures correspond closely with the hydrostatic pressure, irrespective of whether the vein is varicosed or not. We have been unable to find any reference to the levels of venous pressure in other veins of patients with saphenous varicosities.

We have studied fifty unselected patients, twenty-two males and twenty-eight females, who were referred to the vascular clinic of Charity Hospital for treatment. Twenty-five of these suffered from unilateral and twenty-five from bilateral varicosities. Four patients of the former and ten of the latter group also had hypertension (systolic pressure above 150 mm. Hg and/or diastolic pressure above 90 mm. Hg). The ages of the patients varied from 22 to 75 years, the majority being between 40 and 65 years old. Approximately two-thirds were white, the remainder colored patients. The degree and duration of their varicosities varied considerably as did their previous treatment. Some of the varices were of recent development and untreated; in other cases, the condition had been present for as long as twenty-five years and had been treated, at various times, by injections, ligations, and so forth. An additional control group of twenty individuals with no varicosities, four of whom were hypertensive, were also studied.

The general plan of the experiments was to determine the venous pressures of the saphenous veins of both extremities and of one of the

*Aided by a grant to one of us (H.S.M.) from the John and Mary Markle Foundation.

Received for publication, May 1, 1943.

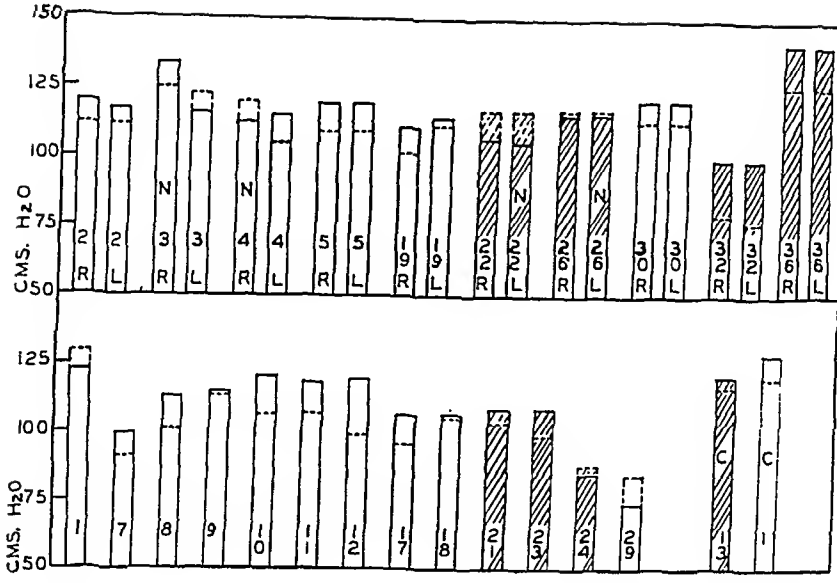

Fig. 1.—Saphenous venous pressures of patients standing. Cross-hatched bars, hypertensive patients; *N*, no involvement; *C*, control subjects, no varicosities. Hydrostatic level (distance from puncture site to fourth interspace) shown by dotted line across each bar. Numbers in each bar refer to patient's number.

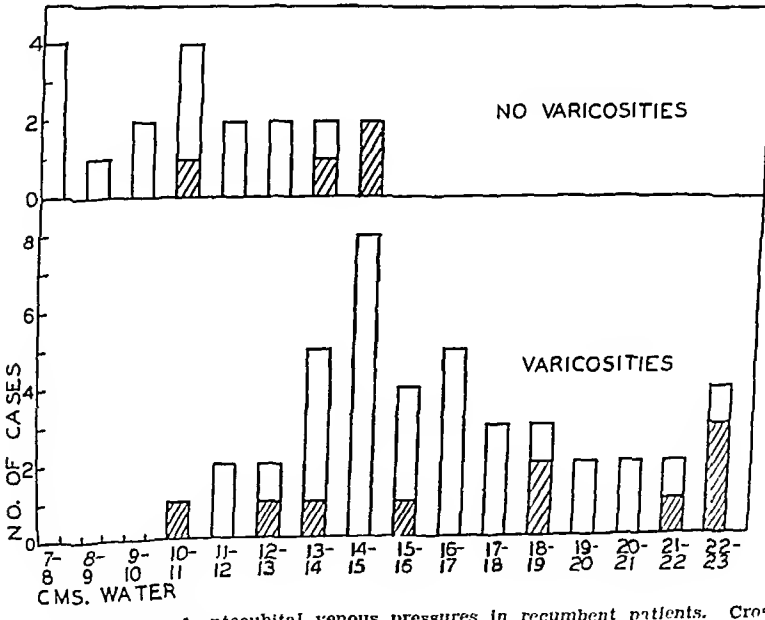

Fig. 2.—Distribution of anteeubital venous pressures in recumbent patients. Cross-hatched areas indicate hypertensive cases.

antecubital veins with the patients in the standing and then in the recumbent position. The direct method of Burch and Sodeman[9] was used throughout. In the standing position, the levels of puncture depended upon the position and prominence of the varicosity. In the cases of bilateral involvement it was usually possible to determine the pressures slightly below the mid-calf region. Where the varicosities were unilateral, the punctures were made at the most accessible point of the "normal" saphenous vein and at the corresponding point of the opposite varicosed vein. Heart level was assumed to be at the fourth interspace[10] and the hydrostatic pressure was calculated as the distance between it and the site of puncture. The antecubital readings were always made with the arm at heart level. In the early experiments the measurements were made with the patient standing, then the needles were removed and the patient placed in the recumbent position on an examining table. The needles were then reinserted at approximately the same points and the measurements repeated. The relatively large number of punctures necessitated by this procedure frequently made it impractical to obtain all of the observations on the same day. The use of a tilting table in the later part of the investigation made it possible to leave all of the needles in place while the patient was passively shifted from one to the other position. This procedure also minimized muscular movements and resulted in more uniform readings. Heart level was assumed to be 10 cm. above the height of the table for the horizontal position[11] and the arm was usually placed at an angle of 45 degrees from the trunk for the antecubital determinations.

The venous pressures, as measured in the saphenous veins of patients in the quiet standing position, are shown in Fig. 1. Representative control values are also given. The results leave no question but that pressures measured under these conditions primarily reflect the hydrostatic component. The inability of many of the patients to stand quietly during the course of the observations may account for the slight variations in the hemodynamic components (pressure above hydrostatic level) as well as for the failure of the pressures to reach the hydrostatic level in seven of the experiments.[12] The use of the fourth interspace as a common reference point for heart level also introduced some error in the determinations.[12] The values which were obtained, however, are of the same order of magnitude and exhibit the same variations as do measurements of standing venous pressures of "normal" veins.[10] This is well illustrated in the cases of unilateral varicosities, where there were no significant differences between the pressures of the "normal" and the involved vein. The presence of hypertension did not seem to influence the height of the venous pressure except where some decompensation was present (Patient 32).

Fig. 2 shows the distribution of the antecubital venous pressure values in the control and varicose vein groups when the patients were placed

in the supine position. The pressures in the saphenous veins in both groups under these conditions were either the same or several centimeters higher.[13, 14] The control values were distributed in the usual fashion and ranged from 7 to 15 cm. H_2O.[15] The majority of the readings were below 11 cm., and only two patients had a pressure of over 14 cm. H_2O which is commonly regarded as the upper limit for "normal" values.[14] These two patients exhibited a hypertension and some cardiac decompensation. On the other hand, the majority of the patients in the varicose vein group had venous pressures higher than this level and their distribution curve showed a pronounced shift to the right. In many cases, the values were of the same order as found in severe cardiac decompensation, but manifestations of cardiovascular involvement were evident in only eight of the twenty cases with abnormally high venous pressure values.

Our results thus indicate that the saphenous venous pressures of patients with varicose veins are within the normal range when the individuals are in the standing position but become elevated and abnormally high when the recumbent position is assumed. Chapman and Asmussen[16] likewise found that the cardiac indices of individuals with varicose veins were within the normal range when the patients were tilted to the upright position but were considerably higher when the individuals were placed in the recumbent position. These patients also showed elevated blood volumes when they were recumbent.

These findings suggest that patients with varicosities have become adapted to higher levels of cardiovascular function which enable them to withstand the strain of the upright position without too much discomfort. When an individual shifts from the recumbent to the standing position, there is a surge of blood downward from the head, arms, and upper trunk to the subcardiac tissues. Blood which previously flowed easily and quickly back to the heart along horizontal venous channels must now climb more slowly over vertical distances of as much as a meter or more. This column of blood exerts a hydrostatic pressure almost equivalent to the force developed by the left ventricle at the peak of its systole and causes a dilatation of the veins and a local accumulation of blood. Asmussen, Christensen, and Nielsen[17] have estimated that 500 c.c. or more of blood may pool in the legs of "normal" persons standing quietly. The amount of pooling in patients with large bilateral varicosities must be considerably in excess of this amount. This loss in circulating blood volume results in a diminished venous return and stroke output and a temporary drop in blood pressure which is partly or entirely compensated for by an increased pulse rate and a generalized vasoconstriction. The latter mechanism serves the dual purpose of preventing further flooding of the subcardiac capillary reservoirs and of shifting a large volume of blood to the dilated veins. Unless muscle tone is low, the average "normal" individual is able to

stand for relatively long periods with no cardiovascular embarrassment,[18] although it is questionable whether compensation is ever complete. The presence of large varicosities renders compensation more difficult. Chapman and Asmussen[16] found that 47 (18 per cent) of 250 patients with large varicosities complained of undue shortness of breath that was relieved in the recumbent position; 19 of these 47 also suffered mild precordial pain and palpitation, and three were women who experienced attacks of sudden dyspnea, dizziness, and precordial pain simply on standing. The patients were without gross signs of the known types of heart disease, although in some the blood pressure was slightly elevated.

While vasoconstriction probably represents an important mechanism by which blood is rapidly shifted to the dilated veins, it is improbable that this vasoconstriction is maintained over long periods of time or that the circulatory system is so regulated that any enlargement of one set of vessels is exactly balanced by an equal reduction in the size of other vessels. When, as in the development of varicosities, the vascular bed enlarges, there must be a concomitant increase in blood volume in a manner similar to that which occurs in hyperthyroidism,[19] cardiac disease,[20] and arteriovenous fistulas.[21] This increase in volume serves to fill the vascular bed, which is particularly enlarged when the patient is in the standing position, and compensates for the abnormal amount of pooling in the veins. Once the distended saphenous veins are filled, their pressures will reflect the gravity effect of the column of blood below the right side of the heart. Venous pressure will rise considerably above the hydrostatic pressure only if the intra-abdominal pressure is raised to a level which compresses the iliac vessels and vena cava and hinders the normal overflow of blood into the right heart.[8] On the other hand, when the patient assumes the recumbent position, there is less distention of the veins and the amount of blood is now greater than needed to fill the vascular bed. In other words, while compensated for the upright position, the cardiovascular system is overcompensated for the recumbent position. These patients, therefore, have high blood volumes and consequent high venous pressures when reclining.

Various explanations have been proposed for the development of varicose veins. Adams[8] believes that the erect posture has developed activity stresses which markedly increase intra-abdominal pressure and indirectly raise the saphenous pressure to abnormally high levels and that this, combined with a vulnerability in certain individuals, probably is sufficient to produce varicose veins. Irrespective of the etiologic factors which cause the stretching, the following hypothesis seems logical. Once the stretching has occurred there is a compensatory increase in blood volume in order to maintain the elastic vascular system in its usual overfilled condition and to maintain an adequate cardiac output. This results in a high pressure on the venous side of the circulation

in the supine position. The pressures in the saphenous veins in both groups under these conditions were either the same or several centimeters higher.[13, 14] The control values were distributed in the usual fashion and ranged from 7 to 15 cm. H_2O.[15] The majority of the readings were below 11 cm., and only two patients had a pressure of over 14 cm. H_2O which is commonly regarded as the upper limit for "normal" values.[14] These two patients exhibited a hypertension and some cardiac decompensation. On the other hand, the majority of the patients in the varicose vein group had venous pressures higher than this level and their distribution curve showed a pronounced shift to the right. In many cases, the values were of the same order as found in severe cardiac decompensation, but manifestations of cardiovascular involvement were evident in only eight of the twenty cases with abnormally high venous pressure values.

Our results thus indicate that the saphenous venous pressures of patients *with varicose veins are within the normal range when the individuals* are in the standing position but become elevated and abnormally high when the recumbent position is assumed. Chapman and Asmussen[16] likewise found that the cardiac indices of individuals with varicose veins were within the normal range when the patients were tilted to the upright position but were considerably higher when the individuals were placed in the recumbent position. These patients also showed elevated blood volumes when they were recumbent.

These findings suggest that patients with varicosities have become adapted to higher levels of cardiovascular function which enable them to withstand the strain of the upright position without too much discomfort. When an individual shifts from the recumbent to the standing position, there is a surge of blood downward from the head, arms, and upper trunk to the subcardiac tissues. Blood which previously flowed easily and quickly back to the heart along horizontal venous channels must now climb more slowly over vertical distances of as much as a meter or more. This column of blood exerts a hydrostatic pressure almost equivalent to the force developed by the left ventricle at the peak of its systole and causes a dilatation of the veins and a local accumulation of blood. Asmussen, Christensen, and Nielsen[17] have estimated that 500 c.c. or more of blood may pool in the legs of "normal" persons standing quietly. The amount of pooling in patients with large bilateral varicosities must be considerably in excess of this amount. This loss in circulating blood volume results in a diminished venous return and stroke output and a temporary drop in blood pressure which is partly or entirely compensated for by an increased pulse rate and a generalized vasoconstriction. The latter mechanism serves the dual purpose of preventing further flooding of the subcardiac capillary reservoirs and of shifting a large volume of blood to the dilated veins. Unless muscle tone is low, the average "normal" individual is able to

5. Seiro, V.: Blood Pressure and Circulation in Veins of Lower Extremities, Acta chir. Scandinav. 80: 41, 1937.
6. Beecher, H. K.: Adjustment of the Flow of Tissue Fluid in the Presence of Localized, Sustained High Venous Pressure as Found With Varices of the Great Saphenous System During Walking, J. Clin. Investigation 16: 733, 1937.
7. DeTakats, G., Quint, H., and Tillotson, B. I.: The Impairment of Circulation in the Varicose Extremity, Arch. Surg. 18: 671, 1929.
8. Adams, J. C.: Etiological Factors in Varicose Veins of the Lower Extremities, Surg., Gynec. & Obst. 69: 717, 1939.
9. Burch, G. E., and Sodeman, W. A.. A Direct Method for the Determination of Venous Pressure; Relationship of Tissue Pressure to Venous Pressure, J. Clin. Investigation 18: 31, 1939.
10. Doupe, J. A., Krynauw, R. A., and Snodgrass, S. R.: Some Factors Influencing Venous Pressure in Man, J. Physiol. 92: 383, 1938.
11. Lyons, R. H., Kennedy, J. A., and Burwell, C. S.: The Measurement of Venous Pressure by the Direct Method, Am. Heart J. 16: 675, 1938.
12. Carrier, E. B., and Rehberg, P. B.: Capillary and Venous Pressure in Man, Skandinav. Arch. f. Physiol. 44: 20, 1923.
13. McIntire, J. M., and Turner, A. H.: Venous Pressure and Posture in Normal Young Women, J. Clin. Investigation 14: 16, 1935.
14. Griffith, G. C., Chamberlain, C. I., and Kitchell, J. R.: Observations on the Practical Significance of Venous Pressure in Health and Disease, with a Review of the Literature, Am. J. M. Sc. 187: 642, 1934.
15. Bedford, D. E., and Wright, S.: Observations on the Venous Pressure in Normal Individuals, Lancet 2: 106, 1924.
16. Chapman, E. M., and Asmussen, E.: On the Occurrence of Dyspnea, Dizziness and Precordial Distress Occasioned by the Pooling of Blood in Varicose Veins, J. Clin. Investigation 21: 393, 1942.
17. Asmussen, E., Christensen, E. H., and Nielsen, M.: The Regulation of Circulation in Different Postures, SURGERY 8: 604, 1940.
18. Mayerson, H. S., and Burch, G. E.: Relationships of Tissue (Subcutaneous and Intramuscular) and Venous Pressures to Syncope Induced in Man by Gravity, Am. J. Physiol. 128: 258, 1940.
19. Gibson, J. B., II, and Harris, A. W.: Clinical Studies on Blood Volume; Hyperthyroidism and Myxedema, J. Clin. Investigation 18: 59, 1938.
20. Gibson, J. B., II, and Evans, W. A.: Clinical Studies on Blood Volume; Changes in Blood Volume, Venous Pressure and Blood Velocity Rate in Chronic Congestive Heart Failure, J. Clin. Investigation 16: 851, 1937.
21. McGuire, J., Havensteiu, V., Stevens, C. D., and Sharretts, K. C.: Effects of Arterio-venous Fistulae on the Heart and Circulation, Blood, Heart and Circulation, Am. Ass. Adv. of Sc., publication No. 13, Washington, D. C., 1940, Science Press, p. 213.

when the patient is in the recumbent position. When the individual with varicosities assumes the standing position, there is a considerable amount of pooling in the stretched veins, and the circulating blood volume and the cardiac output diminish. Because of the initial high levels, however, the values finally achieved usually are still within the "normal" range. The venous pressure, therefore, is also at the "normal" level and reflects the gravitationally induced hydrostatic pressure.

If the above hypothesis is correct, the presence of varicosities imposes a continuous strain on the cardiovascular system, even when the patient is in the recumbent position. The heart is called upon to handle a relatively large venous return and thus do more work. The increase in blood volume may be of sufficient magnitude to induce arterial hypertension. Ligation of the veins, by removing the peripheral blood reservoirs, should have a tendency to restore "normal" hemodynamic conditions. Thus, Chapman and Amussen[16] found that the cardiac outputs and systolic pressures were definitely decreased after ligation and that there was a decided improvement in the compensation of the patients to tilting. Adams[8] found that raised intra-abdominal pressures had much less influence on the venous pressure after the veins were ligated. We have also found, in preliminary experiments, that the venous pressure may decrease and remain low after saphenous ligation.

SUMMARY

No differences were observed in the height of the venous pressure in "normal" and in varicosed saphenous veins of standing patients. In both types of veins the pressures were usually only slightly higher than the hydrostatic pressure.

The antecubital and saphenous venous pressures of patients with varicose veins were found to be significantly higher than "normal" when the patients were in the recumbent position.

These high recumbent venous pressures are believed to be due to an increase in blood volume which enables the individual to compensate for the effects of gravity while standing, but results in an overcompensated state when the recumbent position is assumed.

We are grateful to Alton Ochsner for his interest in the problem and for his permission and that of O. P. Daly to use the facilities of the vascular clinic. Thanks are also due W. D. Davis, Jr., and W. J. Trautman, Jr., for assistance in the later part of the study.

REFERENCES

1. Delbet, P.: Pathogenesis and Prophylaxis of Varicose Veins, Internat. Clin. 4: 50, 1902.
2. Lake, M., Pratt, G. H., and Wright, I. S.: Arteriosclerosis and Varicose Veins: Occupational Activities and Other Factors, J. A. M. A. 119: 696, 1942.
3. Heller, R. E.: The Pathological Physiology of Varicose Veins, Surg., Gynec. & Obst. 71: 566, 1940.
4. McPheeters, H. O., Merkert, C. E., and Lundblad, R. A.: The Mechanics of the Reverse Flow of Blood in Varicose Veins as Proved by Blood Pressure Readings, Surg., Gynec. & Obst. 55: 298, 1932.

of the fluid. Unfortunately, three other important factors could not be studied because of lack of sufficient information to make them of statistical value. These other factors are the bacteriology of the peritoneal fluid, the time interval between the last intake of food and the perforation, and the size of the perforation.

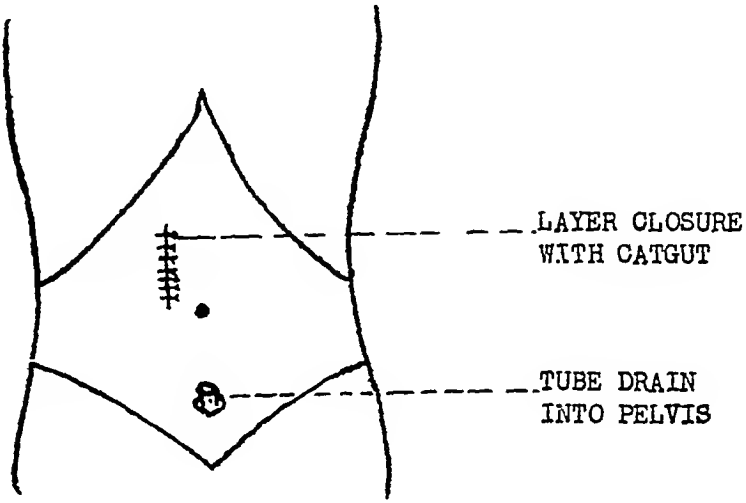

Fig. 1.

The relationship between the duration of the perforation and the character of the wound healing was not consistent. Of those perforations closed within six hours of their occurrence, 79 per cent healed without evidence of infection, and yet, in those operated upon between twelve and eighteen hours after perforation, 83 per cent healed without evidence of infection (Table II).

When the amount of fluid found at operation is considered, there is seen to be some apparent correlation between the amount of fluid and the healing of the operative wound. The less the amount of fluid the better the chance for the wound to heal without evidence of infection (Table III).

Between the character of the fluid and the healing of the wound there also seems to be a definite relationship. Clear fluid was associated with primary wound healing in 82 per cent of the 51 cases. When gastric

TABLE I

WOUND HEALING*

Primary	67 or 74.4%
Infected	23 or 25.6%
Total number	90 100 %

*Acute free perforations of gastric and duodenal ulcers, Episcopal Hospital, Jan. 1, 1912, to Jan. 1, 1936, surviving patients having primary closure of operative wound combined with suprapubic drainage of pelvis

A STUDY OF THE HEALING OF ABDOMINAL OPERATIVE WOUNDS FOLLOWING CLOSURE OF PERFORATED ULCERS OF THE STOMACH AND DUODENUM*

RICHARD H. MEADE, JR., M.D.,† PHILADELPHIA, PA.

(From the Surgical Services of the Hospital of the Protestant Episcopal Church in Philadelphia)

THE question of the drainage of the peritoneal cavity following operation for acute perforation of a peptic ulcer of the stomach or duodenum was, until relatively recently, a hotly debated one. This was particularly true in Philadelphia in the early 1930's and it was then that this study was started. For a period of many years at the Episcopal Hospital, a definite routine for the management of perforated ulcers was strictly followed. In every case, regardless of the duration of the perforation, the operation was carried out through an upper right rectus incision with splitting of the muscle or with lateral retraction of it. The readily available fluid, especially if showing gastric contents, was evacuated and the perforation closed. During the first twenty years of this series a gastroenterostomy was added in thirty-six of the fifty cases, but in only one of the forty cases in the next four years. After establishing pelvic peritoneal drainage through a suprapubic stab wound, the operative wound was closed in layers with catgut, except for the skin, and without drainage. Thus, there was established an excellent setup for the study of wound healing in the presence of contamination, for which the surgeon had established drainage of the peritoneal cavity.

During the period between Jan. 1, 1912, and Jan. 1, 1936, ninety patients, who had been treated for their perforated ulcers as outlined above, recovered and were followed a sufficient length of time to study their wound healing. In sixty-seven, or 74.4 per cent, of these there was no evidence of infection (Fig. 1 and Table I). In only four of the wounds was there evidence of enough infection to classify them as seriously infected, and three of these were associated with disruption. In the light of recent studies about wound healing it seems likely that the disruption more probably was due to nutritional disturbances than to infection, but there is insufficient data in these cases to reach such a conclusion.

The factors available for study in this series were the duration of the perforation, the quantity of the peritoneal fluid and the characteristics

Received for publication, April 10, 1943.

*Presented at a meeting of the Philadelphia Academy of Surgery, Nov. 4, 1940.

†Major, Medical Corps, Army of the United States.

wounds do not become infected if the perforation can be closed before there has been any great leakage of gastric or duodenal contents or accumulation of much peritoneal fluid. Now, with the addition of the sulfonamide drugs, it would seem that one should hesitate to establish peritoneal drainage unless the perforation cannot be closed adequately or there is a localized collection of pus.

As a matter of giving the background for this series of ninety cases, certain other data should be presented. During the twenty-four years in which these cases occurred there were 730 patients with ulcer of the stomach and duodenum admitted to the Episcopal Hospital, 232 of whom had acute perforations. During the first twenty years 164 patients were admitted and 57, or 34.75 per cent, of them died. In the next four years 68 were admitted and 13 of these died, giving a mortality rate of 19.11 per cent. During the entire period of twenty-four years only 13 patients were operated upon without establishing peritoneal drainage. Only one of these died, and that was due to pneumonia developing after a secondary operation for the establishment of peritoneal drainage in a patient whose abdomen had been closed without drainage and whose peritoneum showed no evidence of inflammation at the second operation. Four of the wounds showed some evidence of infection, but in no case was there a suggestion of peritoneal involvement.

SUMMARY

1. At the Episcopal Hospital in Philadelphia, between 1912 and 1936, acute perforations of gastric and duodenal ulcers were treated by closure of the perforation with or without gastroenterostomy. The operative wound was closed in layers with catgut after establishing suprapubic peritoneal drainage

2. Ninety of these patients recovered and were followed sufficiently long to observe the nature of their wound healing.

3. Sixty-seven, or 74.4 per cent, of the wounds healed by primary intention. Twenty-three, or 25.6 per cent, of the wounds showed some evidence of infection.

4. There was no apparent correlation between the duration of the perforation and the wound healing. Of those under six hours, 79 per cent healed without infection, whereas 83 per cent of those between twelve and eighteen hours healed without evidence of infection.

5. There seemed to be some correlation between the amount of fluid and the nature of the wound healing. Of the six cases in which there was no fluid, all of the wounds healed by primary intention. In twenty-eight with small amounts of fluid 85 per cent healed without infection. Of thirty-six with moderate amounts of fluid, 69.44 per cent healed without infection. Of twenty with large amounts of fluid, 65 per cent healed without evidence of infection

TABLE II

DURATION OF PERFORATION IN RELATION TO WOUND HEALING INFECTION

DURATION	NONE	SLIGHT	MODERATE	SEVERE
Less than 6 hr. (38)	30 (79%)	1	6	1 (Disruption)
6 to 12 hr. (39)	27 (69%)	6	4	2 (1 Disruption)
12 to 18 hr. (6)	5 (83%)	1	0	0
18 to 24 hr. (4)	2 (50%)	0	1	1 (Disruption)
24 to 48 hr. (3)	3 (100%)	0	0	0

TABLE III

RELATIONSHIP BETWEEN AMOUNT OF FLUID AND WOUND HEALING

AMOUNT OF FREE FLUID	DEGREE OF INFECTION OF WOUND			
	NONE	SLIGHT	MODERATE	SEVERE
None (6)	6 (100 %)	0	0	0
Small (28)	23 (85.7%)	1	4	0
Moderate (36)	25 (69.4%)	5	4	2 (Disruptions)
Large (20)	13 (65 %)	2	3	2 (1 Disruption)

TABLE IV

RELATIONSHIP BETWEEN CHARACTER OF FLUID AND WOUND HEALING

CHARACTER OF FLUID	DEGREE OF INFECTION OF WOUND			
	NONE	SLIGHT	MODERATE	SEVERE
Clear or not specified (51)	42 (82.3%)	1	7	1 (Disruption)
Gastric contents (19)	12 (63.1%)	3	3	1 (Disruption)
Pus (14)	7 (50 %)	4	1	2 (1 Disruption)

contents were noted in the fluid, 63 per cent of the wounds healed without evidence of infection, and when there was frank pus, only one-half of the wounds healed by primary intention (Table IV).

The operative wounds in these cases were not washed out before closure, nor were the wound edges protected in any way from the contaminating fluid. Layer closure was done with No. 1 or 2 catgut for everything except the skin, which was closed with metal clips or nonabsorbable sutures. No antiseptics were used and this was before the sulfonamide era. Notwithstanding, it has been shown that the large majority of these soft tissue wounds healed without evidence of infection. As it has been repeatedly demonstrated that the soft tissues are less resistant to infection than the peritoneum, it would seem reasonable to conclude that in this series of cases peritoneal drainage was rarely, if ever, needed. Furthermore, it seems that even the soft tissue

SULFATHIAZOLE IN CHRONIC OSTEOMYELITIS

JAMES W. TOUMEY,* M.D., BOSTON, MASS.

(From the Department of Bone and Joint Surgery, Lahey Clinic, Boston)

THE introduction of chemotherapy has been a far-reaching advance in the treatment of osteomyelitis. Much of the chronic suffering caused by this disease can be relieved with the help of the sulfonamides. In the past the therapy of osteomyelitis has been a sorrowful succession of "cures" which did not materialize as was hoped. One method after another became popular and then fell into disrepute. The surgeon demonstrated his dissatisfaction by trying one mode of therapy after another.

At one period acute osteomyelitis was considered a surgical emergency, and the cortex of the bone was drilled in search of pus, even before the roentgenologic changes had made themselves manifest. In the later stages of the disease, meticulous saucerization and sequestrectomy were carried out with great care and completeness, but even so, chronic suppuration with sinuses continued, often for years. Various bactericidal agents have been used. Dakin's solution was used widely in World War I. Then bacteriophage became popular and later there was a revival of the maggot treatment. Most surgeons agree that a definite step forward was made in the adoption of the Orr treatment (postoperative plaster immobilization of the lesion, including the joint above and below, and infrequent changes of plaster for dressings). As a rule, the wounds so treated were cleaner and healed more rapidly than those which were frequently dressed.

Modern chemotherapy was applied early to the problems of bone infection. Dickson, and associates,[1] Dively and Harrington,[2] Hoyt and associates,[3] and Key and associates[4] have been especially interested in the effect of the sulfonamides on bone infections.

This series of cases is presented with the belief that our experiences at the Lahey Clinic with chemotherapy in bone infection will aid in the clarification of present treatment. The majority of our patients have had either old chronic osteomyelitis with sinus formation, or an acute reactivation of previous osteomyelitis, flaring up after a quiescent period of a number of years.

TREATMENT

The general plan of treatment, a combination of several forms, may be divided into three stages:

*Lt. Commander, U. S. Naval Hospital, St. Albans, Long Island, N. Y.
Received for publication, March 26, 1943

6. The character of the fluid appeared to be related to the wound healing. In fifty-one cases the fluid was clear, and 82.3 per cent of these wounds healed by primary intention. In nineteen cases gastric contents were seen in the peritoneal fluid. Of these wounds, 63.15 per cent healed without evidence of infection. In fourteen cases in which there was frank pus, 50 per cent of the wounds healed by primary intention.

CONCLUSIONS

The healing of the contaminated, undrained operative wounds in these ninety cases of acute perforations of gastric and duodenal ulcers indicates that in this group of cases peritoneal drainage was rarely, if ever, needed. It should then follow that peritoneal drainage is not needed in any case when the perforation can be satisfactorily closed and there is no walled off pus. With the addition of sulfonamide therapy this conclusion seems justified.

SULFATHIAZOLE IN CHRONIC OSTEOMYELITIS

JAMES W. TOUMEY,* M.D., BOSTON, MASS.

(From the Department of Bone and Joint Surgery, Lahey Clinic, Boston)

THE introduction of chemotherapy has been a far-reaching advance in the treatment of osteomyelitis. Much of the chronic suffering caused by this disease can be relieved with the help of the sulfonamides. In the past the therapy of osteomyelitis has been a sorrowful succession of "cures" which did not materialize as was hoped. One method after another became popular and then fell into disrepute. The surgeon demonstrated his dissatisfaction by trying one mode of therapy after another.

At one period acute osteomyelitis was considered a surgical emergency, and the cortex of the bone was drilled in search of pus, even before the roentgenologic changes had made themselves manifest. In the later stages of the disease, meticulous saucerization and sequestrectomy were carried out with great care and completeness, but even so, chronic suppuration with sinuses continued, often for years. Various bactericidal agents have been used. Dakin's solution was used widely in World War I. Then bacteriophage became popular and later there was a revival of the maggot treatment. Most surgeons agree that a definite step forward was made in the adoption of the Orr treatment (postoperative plaster immobilization of the lesion, including the joint above and below, and infrequent changes of plaster for dressings). As a rule, the wounds so treated were cleaner and healed more rapidly than those which were frequently dressed.

Modern chemotherapy was applied early to the problems of bone infection. Dickson, and associates,[1] Dively and Harrington,[2] Hoyt and associates,[3] and Key and associates[4] have been especially interested in the effect of the sulfonamides on bone infections.

This series of cases is presented with the belief that our experiences at the Lahey Clinic with chemotherapy in bone infection will aid in the clarification of present treatment. The majority of our patients have had either old chronic osteomyelitis with sinus formation, or an acute reactivation of previous osteomyelitis, flaring up after a quiescent period of a number of years.

TREATMENT

The general plan of treatment, a combination of several forms, may be divided into three stages:

*Lt. Commander, U. S. Naval Hospital, St. Albans, Long Island, N. Y.
Received for publication, March 26, 1943.

1. *Preoperative.*—The patient with osteomyelitis has at least one week of bed rest in the hospital before operation. During this period a course of sulfathiazole is given, the routine dose being 15 gr. every four hours or 90 gr. in a twenty-four-hour period. The blood level of the drug, red and white blood counts, and urinalysis are determined at frequent intervals. Sulfathiazole blood levels of 3.5 to 11 mg. are reached, the more usual levels being in the lower brackets. When sulfathiazole has to be discontinued because of a reaction, the chemotherapy is continued with sulfadiazine, after the reaction has subsided. Sulfadiazine is less toxic and higher blood levels are easy to maintain. We have had insufficient experience with sulfadiazine to compare its efficacy in staphylococcal osteomyelitis with that of sulfathiazole. It is our present plan to change to sulfadiazine in any case in which we have difficulty with sulfathiazole.

After a week of preparation, the patient is ready for surgery. Usually there has been a diminution of pain, heat, swelling, tenderness, fever, leucocytosis, and sedimentation rate, due, I believe, to the combined effects of sulfatherapy and rest. In one instance (Case 2), the patient had such dramatic relief that he insisted on going home without operation. However, three weeks later the osteomyelitis again became acute, and operation was performed after another week of chemotherapy.

2. *Operative.*—The routine procedure is a wide, careful saucerization of the infected area of bone. If a sinus tract is present, before making the incision methylene blue is injected into it to aid in the dissection of the sinus tract and to help in locating the entrance of the tract into the bone. If more complete study of the sinus tract is indicated in planning the operation, lipiodol is injected and roentgenograms are taken preoperatively.

In these operations a tourniquet is used as a regular course, without evidence of spreading the infection. The dry field which a tourniquet provides is of the greatest aid in the removal of diseased soft tissue as well as bone. The extremity is first elevated, then an Esmarch rubber bandage is applied tightly from the toes or fingers in a spiral, upward; then the tourniquet, which consists of a flat rubber band around the upper thigh and a blood pressure cuff on the upper arm, is applied.

An elliptical incision is made about a previous operative scar or sinus, if present. The dissection is carried down to the bone removing the infected scar, granulation tissue, and sinus tract, brightly stained with methylene blue. As much of the scar tissue as possible is excised, bearing in mind the necessity for adequate closure of the wound by covering the bone with soft tissue. The cavity in the bone is opened freely with gouge and chisel, wherever possible creating outwardly sloping walls with no overhang or re-entrant angles. A motor burr may be helpful in thus saucerizing the bone. Sequestra, if present, are removed. The wound is washed carefully with saline solution to remove all bone particles and before closure the tourniquet is removed and hemostasis

established. Sulfathiazole powder is then placed in the wound. We have used 5 to 15 Gm. (75 to 225 gr.), depending on the condition and size of the wound. Primary closure is then effected without a drain and after each layer is closed, additional powder is dusted into the wound. For a time sulfathiazole sodium was used in preference to sulfathiazole, because it was more soluble. Then the use of sulfathiazole sodium was discontinued because of its high alkalinity, although we had no difficulties which we could ascribe to it. The deep layers of the wound are closed with catgut and the skin with silk, all interrupted sutures. A dry dressing and a circular plaster cast extended to immobilize the joint above and below the involved bone are applied. For example, in femoral osteomyelitis a single hip spica bandage is applied, while for osteomyelitis of the tibia, the knee and ankle joints are immobilized.

3. *Postoperative.*—The sulfathiazole routine is kept up for at least two weeks unless some contraindication develops. The plaster is not removed, nor is the wound inspected.

Two weeks after operation the plaster is changed and the wound sutures are removed. We are guided in the length of time the plaster is left on by the appearance of the wound. This period varies from four to eight weeks, and weight bearing is begun in lower extremity cases in from four to eight weeks after operation. Postoperative sulfathiazole administration has not been kept up longer than six weeks even when the wound has persisted in discharging.

REPORT OF CASES

The major details of treatment and results are recorded herewith in all cases of osteomyelitis treated at the Lahey Clinic from January, 1941, to June, 1942.

CASE 1.—A 25-year-old man had had osteomyelitis of the right femur which was drained surgically ten years before. For the last three years he had had an actively draining sinus in the old incision with increasing pain. Sulfathiazole was started only twenty-four hours before operation and was continued to five days after operation, at which time it was discontinued because of nausea. The average sulfathiazole blood level was 3.6 mg. The sinus, which was found to lead into a large cavity behind the femoral shaft, was excised. No aperture into the marrow cavity was found, and the bone was not saucerized. Fifteen grams of sulfathiazole sodium plus 5 Gm. of sulfathiazole were placed in the wound, which was closed primarily, and a circular plaster cast from the toes to the groin was applied. Nonhemolytic *Staphylococcus albus* was cultured from the abscess cavity. In five weeks the wound was completely healed and dry. At thirteen months after operation the wound had remained healed, dry, and painless and there was no roentgenologic evidence of activity.

Comment.—Primary closure occurred, with rapid healing of a large, soft tissue abscess which had drained for three years. The good result, in spite of the short course of sulfathiazole, was probably due to the absence of bone involvement.

CASE 2.—A 25-year-old man had had osteomyelitis of the right femur a purative arthritis of the right hip at the age of 3 years. At the age of 1 a flare-up of the osteomyelitis with drainage occurred, and two weeks bef mission to the clinic there was a sudden reactivation with pain, heat, ten swelling, fever, and a sedimentation rate of 70. On admission there was no ation and the roentgenograms showed no cavitation or sequestration. For days he was treated with bed rest and 90 gr. of sulfathiazole daily. After t eleven days an abscess localized in the right groin and was incised and d The cavity was of such shape that it could not be closed primarily. Five gr sulfathiazole were placed in the wound and the superficial portion was packed abscess cultured *Staph. aureus*. The average sulfathiazole blood level was 4 and the patient tolerated the drug well. Since the hip had become ankylosed before, a cast was not applied. The abscess healed in five weeks, and has re so after nine months.

Comment.—This patient had an adequate course of chemotherapy did well.

CASE 3.—A 36-year-old man had had an operation performed five years viously for acute osteomyelitis of the right tibia. Five months previously he to have pain at the former site of bone infection. On admission, pain, re swelling, and tenderness were present over the upper tibia, and roentgeno revealed two large cavities in the upper tibia (Fig. 1). He received 90 gr. of s thiazole daily for twelve days, maintaining an average blood level of 3.5 mg. pain, redness, swelling, and tenderness were relieved and he left the hospital ag advice.

He returned three weeks later because the process again had become acute. A nine days more of oral sulfathiazole, saucerization was carried out and two neeting abscess cavities filled with thick pus were found in the upper tibia. T cultured *Staph. aureus*. Five grams of sulfathiazole sodium were placed in wound, which was closed without drainage, and the leg was placed in a circular from toes to groin. After operation he received 60 gr. of sulfathiazole daily five weeks, with an average blood level of 6.7 mg. At discharge, five weeks a operation, the cast was removed; the wound had remained healed and weight-b ing was begun. At six months after operation he is free from symptoms and wound is healed.

Comment.—A good result was obtained in spite of extensive bone volvement. He had adequate sulfonamide therapy. A course of sul thiazole without surgery failed.

CASE 4.—A 25-year-old man had been operated upon elsewhere ten years p viously for acute osteomyelitis in the right lower tibia. For the last seven mont he had had pain in the lower tibia of increasing severity with swelling and tend ness, so that he became unable to work. Roentgenologic examination of the anl showed a cavity, 12 cm. in length, in the lower tibia, extending nearly to the joi (Fig. 2). Sixty grains of sulfathiazole were given daily for four days, and th saucerization and primary closure were carried out (Fig. 3). At operation 5 Gr of sulfathiazole were placed in the wound, which cultured *Staph. aureus*. A long le cast was applied from toes to groin. Because of nausea and progressive anemia, t sulfathiazole had to be stopped eight days after operation, though the averag blood level was 2.7 mg. Two weeks postoperatively there was slight discharge fro the wound. Six weeks postoperatively, when the plaster was left off, the woun was healed, and one year later there was no pain or evidence of activity.

Comment.—A good result was obtained in a patient with a large bone abscess though he had a rather small amount of chemotherapy after operation.

FIG. 2.—Before operation, showing osteomyelitis of the lower tibia. Extensive pus-filled cavity present.



FIG. 1.—Osteomyelitis of the upper tibia treated by sequestrectomy, sulfathiazole orally and locally, primary closure, and plaster immobilization.

CASE 5.—A 15 year old schoolboy entered the hospital because of pain and swelling just above the left wrist of two months' duration. Roentgenograms were consistent with either a Brodie's abscess with marked bone thickening or with a Ewing's endothelioma involving the lower radial shaft (Fig. 1). Because of the possibility of malignancy, a biopsy specimen was taken, and "chronic inflammation" was the pathologic finding. Therefore, sequestrectomy was done, and 5 Gm. of sulfathiazole were placed in the wound. No oral chemotherapy was given either before or

after operation. The final microscopic sections were consistent with osteomyelitis. A culture showed no growth.

Five months after the first saucerization a second operation became necessary, as pain, swelling, tenderness, and heat had returned soon after the first procedure. Ninety grains of sulfathiazole were given for three days before operation and for eight days afterward, the average blood level being 4 mg. During operation 5 gr. of sulfathiazole were implanted. Thereafter the pain subsided and four months later he was free of symptoms.

Comment.—This Brodie's abscess of the radius with extensive sclerosis failed to yield to saucerization and local chemotherapy. A second operation with preoperative and postoperative chemotherapy was successful.

CASE 6.—A 35 year old man had had acute osteomyelitis of the left lower femur twenty-four years before admission. For the last seventeen years he had had an actively draining sinus which led from a large cavity in the lower femoral shaft to a large, depressed, old incisional scar with turned in edges. Sulfathiazole was begun, 60 gr. a day for the first two days and then 90 gr. a day for four more days, at the end of which time the blood level was 5.8 mg. Saucerization and primary closure were performed, leaving 15 Gm. of sulfathiazole sodium in the wound, and applying a cast from toes to groin. The next day he had a sulfathiazole reaction with large, red, raised blotches on the skin. Several days later when the drug was begun again the reaction reappeared, so he received virtually no postoperative sulfathiazole therapy. The reaction increased about the wound, and three sinuses developed though the leg was kept in plaster for four months.

Because of the persisting sinuses he was hospitalized six months later, and another attempt was made to give sulfathiazole. The second day his temperature rose to 103° F., and the drug was discontinued. The next day he had a convulsive seizure. No definite cause for this was found, and it was possibly a drug reaction. However, sulfadiazine was tried without incident. He received 90 gr. daily for ten days before operation and for three weeks afterward, with an average blood level of 6.5 mg. At operation the sinus tracts were excised, and a thin sequestrum 1.5 inches long was removed. Five grams of sulfathiazole were placed in the wound, and primary closure was tried again. At three months after operation a small sinus persisted in the wound.

Comment.—Attempted primary closure in osteomyelitis of the femur with a chronic sinus failed. The patient could not tolerate sulfathiazole, and this is the probable cause of failure. It is too early to evaluate the result of the second procedure with a course of sulfadiazine, but it was more successful than the first procedure, at which time chemotherapy could not be used.

CASE 7.—A 14 year old man had had osteomyelitis of the left lower femur with a draining sinus ever since the primary operation in 1917, twenty-four years before. He was given 60 gr. of sulfathiazole a day for one week preoperatively and for two weeks postoperatively. The sinuses, one medial and one lateral over the lower femur, were injected with methylene blue and were dissected out. No bone focus was found. A culture showed beta hemolytic streptococcus, hemolytic and non hemolytic *Staph. aureus* and *Staph. albus*. Five grams of sulfathiazole were placed in the wounds. A primary suture was done, and a cast applied from toes to groin. The average sulfathiazole blood level was 4.2 mg. The wounds healed uneventfully, and at six months after operation he was free of symptoms.

Comment.—There was secondary still primary closure of a sinus following osteomyelitis of the femur which had drained for twenty-four years. The patient tolerated sulfathiazole well.

Case 9.—A [illegible] year old [illegible] was admitted to hospital desperately ill, toxic, dehydrated, [illegible] osteomyelitis involving the entire [illegible] upper femur. He was treated with five transfusions, [illegible] He [illegible] condition rapidly improved. He [illegible] hospital stay of ninety five days [illegible] with no untoward effects except for [illegible] to be due to the drug. There [illegible] Diagnosis separation cul [illegible]

Comment.—It is too early to know the end results in this case, but the acute process subsided without any surgical procedure.

Case 9.—A [illegible] year old [illegible] was admitted to hospital with pain in the right knee region of eight weeks' duration. There was no previous history of osteomyelitis. Roentgenograms showed an area of destruction in the lower femoral shaft, consistent with a bone abscess. However, at operation a bone abscess cavity, centrally located, was found and curetted. Eight grams of sulfathiazole were placed in the wound which was closed by primary suture, and a cast was applied from the toes to the groin. The culture from the abscess was *Staph aureus*. The patient then received 90 gr. of sulfathiazole a day for eighteen days, which produced an average blood level of 5.6 mg., and also an anemia which required two transfusions. Eighteen days after operation, slight drainage occurred, and he was discharged walking with crutches.

Eight months after the first operation he was readmitted and the persistent sinus tract was excised. Sulfathiazole was placed in the wound, which was subsequently closed and has remained so for the last fifteen months.

Comment.—A bone abscess of the femur was treated in a routine manner. A second operation on the persisting sinus resulted in healing. The patient tolerated sulfathiazole well.

Case 10.—A 41 year old man had had acute recurrent osteomyelitis of the lower right femur for the last twenty two years. Pain, heat, swelling, and tenderness had been present over the right lower femur for the last six months. Ninety grams of sulfadiazine were given daily for eight days before operation and for eighteen days afterward, maintaining an average blood level of 8 mg. without reaction. Sauceterization was carried out and an extensive cystic area containing pus was found. Five grams of sulfathiazole were placed in the wound before primary closure. The cast was left on for five weeks after operation, at which time there was still slight drainage from the wound. The culture at operation showed *Staph aureus*. At eight weeks after operation sinus drainage was still present, but we have been unable to follow this case.

Comment.—Sauceterization was carried out on an extensive, old, femoral osteomyelitis with sinuses persisting at eight weeks. The delayed healing may be due to the fact that sulfadiazine was used.

Case 11.—A 30 year old woman entered the hospital with a third flare up of osteomyelitis of the left lower tibia, acutely painful for three days. The original on

set of the osteomyelitis was twenty-three years before. The roentgenograms showed bone thickening with a central area of rarefaction in the lower tibial shaft. There was a large, wide, depressed scar over the tibia with poor quality skin adherent to the bone. At operation the old scar was excised and the tibia saucerized. To effect primary closure a relaxing incision was made medially. Five grams of sulfathiazole were placed in the tibial wound, and a long leg plaster was applied. Three days after operation the sulfathiazole was stopped because of nausea. Three weeks later the operative wound was not healed and was resutured; the defect left by the relaxing incision was grafted. Ninety grains of sulfadiazine were given for eleven days, with an average blood level of 7 mg. The wound healed in two weeks, and had remained so when last seen six months later.

Comment.—The good result clinically was due in part to sulfadiazine by mouth rather than sulfathiazole, which the patient could not tolerate.

CASE 12.—A 26-year-old man had had a right femoral osteomyelitis which had been increasingly painful for the last six months. The original attack occurred fourteen years before. Roentgenograms showed bone thickening, irregularity, and a large cystic area in the shaft. Before operation was undertaken, sulfathiazole, sulfadiazine, and sulfanilamide were tried successively, but he was sensitive to them all. At operation the wound was saucerized and packed with vaseline gauze. Ten grams of sulfathiazole were placed in the depths of the wound. A spica bandage was applied. Three months later the wound was closing gradually.

Comment.—This case shows the difficulties of treatment when sulfatherapy cannot be used.

CASE 13.—A 26-year-old man had been having progressive pain and tenderness above the left lower femoral region for the last six months. The original attack occurred twelve years before, and three drainages were done within two years. Exploration was performed before we began using oral chemotherapy, but 40 gr. of sulfanilamide were placed in the wound which cultured hemolytic *Staph. aureus*. A vaseline pack was left in the wound, and despite this healing was conspicuously rapid, requiring but three weeks. Three years later the wound had remained healed, the patient was free of symptoms.

Comment.—The healing was rapid without oral chemotherapy, probably because we were dealing with a soft tissue abscess rather than a bone focus.

SUMMARY

1. Thirteen cases are presented to demonstrate the details of treatment of osteomyelitis with chemotherapy. Healing took place promptly in ten of the thirteen cases, and in two of the three remaining cases chemotherapy could not be given because of reaction to the drug.

2. The recommended treatment of chronic osteomyelitis consists of:

a. A course of chemotherapy and bed rest in the hospital for one week before operation. Ninety grains of sulfathiazole are given in twenty-four hours.

b. The operative procedure consists of saucerization; local sulfathiazole in the wound, 2 to 15 Gm., according to the size of the wound;

Comment. There was successful primary closure of a sinus following osteomyelitis of the femur which had drained for twenty-four years The patient tolerated sulfathiazole well

CASE 8.—A 29 year old man entered the hospital desperately ill, toxic, dehydrated, severely anemic, and in great pain with an acute osteomyelitis involving the entire right femur, except for the upper fourth He was treated with five transfusions, fluids, a hip spica, and sulfathiazole His general condition rapidly improved, he became comfortable, and began to gain weight In his hospital stay of ninety five days he was given sulfathiazole on sixty days with no untoward effects except for several temperature elevations which were thought to be due to the drug There was no abscess formation, and no incision were made. Diagnostic aspiration cultured *Staph aureus*

Comment.—It is too early to know the end results in this case, but the acute process subsided without any surgical procedure

CASE 9.—A 11 year old man entered the hospital with pain in the right knee region of eight weeks' duration. There was no previous history of osteomyelitis *Roentgenograms showed an area of dense sclerosis in the lower femoral shaft*, consistent with a sclerosing osteitis of Garre However, at operation a bone abscess cavity, centrally located, was found and saucerized Eight grams of sulfathiazole were placed in the wound which was closed by primary suture, and a cast was applied from the toes to the groin The culture from the abscess was *Staph aureus* The patient then received 90 gr. of sulfathiazole a day for eighteen days, which produced an average blood level of 5 6 mg., and also an anemia which required two transfusions Eighteen days after operation, slight drainage occurred, and he was discharged walking with crutches

Eight months after the first operation he was readmitted and the persistent sinus tract was excised. Sulfathiazole was placed in the wound, which was subsequently closed and has remained so for the last fifteen months

Comment—A bone abscess of the femur was treated in a routine manner. A second operation on the persisting sinus resulted in healing The patient tolerated sulfathiazole well

CASE 10—A 41 year old man had had acute recurrent osteomyelitis of the lower right femur for the last twenty two years Pain, heat, swelling, and tenderness had been present over the right lower femur for the last six months Ninety grams of sulfadiazine were given daily for eight days before operation and for eighteen days afterward, maintaining an average blood level of 8 mg. without reaction Saucerization was carried out and an extensive cystic area containing pus was found Five grams of sulfathiazole were placed in the wound before primary closure The cast was left on for five weeks after operation, at which time there was still slight drainage from the wound. The culture at operation showed *Staph aureus* At eight weeks after operation sinus drainage was still present, but we have been unable to follow this case

Comment—Saucerization was carried out on an extensive, old, femoral osteomyelitis with sinuses persisting at eight weeks The delayed healing may be due to the fact that sulfadiazine was used

CASE 11—A 30 year old woman entered the hospital with a third flare up of osteomyelitis of the left lower tibia, acutely painful for three days The original on

set of the osteomyelitis was twenty-three years before. The roentgenograms showed bone thickening with a central area of rarefaction in the lower tibial shaft. There was a large, wide, depressed scar over the tibia with poor quality skin adherent to the bone. At operation the old scar was excised and the tibia saucerized. To effect primary closure a relaxing incision was made medially. Five grams of sulfathiazole were placed in the tibial wound, and a long leg plaster was applied. Three days after operation the sulfathiazole was stopped because of nausea. Three weeks later the operative wound was not healed and was resutured; the defect left by the relaxing incision was grafted. Ninety grains of sulfadiazine were given for eleven days, with an average blood level of 7 mg. The wound healed in two weeks, and had remained so when last seen six months later.

Comment.—The good result clinically was due in part to sulfadiazine by mouth rather than sulfathiazole, which the patient could not tolerate.

CASE 12.—A 26-year-old man had had a right femoral osteomyelitis which had been increasingly painful for the last six months. The original attack occurred fourteen years before. Roentgenograms showed bone thickening, irregularity, and a large cystic area in the shaft. Before operation was undertaken, sulfathiazole, sulfadiazine, and sulfanilamide were tried successively, but he was sensitive to them all. At operation the wound was saucerized and packed with vaseline gauze. Ten grams of sulfathiazole were placed in the depths of the wound. A spica bandage was applied. Three months later the wound was closing gradually.

Comment.—This case shows the difficulties of treatment when sulfatherapy cannot be used.

CASE 13.—A 26-year-old man had been having progressive pain and tenderness above the left lower femoral region for the last six months. The original attack occurred twelve years before, and three drainages were done within two years. Exploration was performed before we began using oral chemotherapy, but 40 gr. of sulfanilamide were placed in the wound which cultured hemolytic *Staph. aureus.* A vaseline pack was left in the wound, and despite this healing was conspicuously rapid, requiring but three weeks. Three years later the wound had remained healed, the patient was free of symptoms.

Comment.—The healing was rapid without oral chemotherapy, probably because we were dealing with a soft tissue abscess rather than a bone focus.

SUMMARY

1. Thirteen cases are presented to demonstrate the details of treatment of osteomyelitis with chemotherapy. Healing took place promptly in ten of the thirteen cases, and in two of the three remaining cases chemotherapy could not be given because of reaction to the drug.

2. The recommended treatment of chronic osteomyelitis consists of:

a. A course of chemotherapy and bed rest in the hospital for one week before operation. Ninety grains of sulfathiazole are given in twenty-four hours.

b. The operative procedure consists of saucerization; local sulfathiazole in the wound, 2 to 15 Gm., according to the size of the wound;

Comment.—There was successful primary closure of a sinus following osteomyelitis of the femur which had drained for twenty-four years The patient tolerated sulfathiazole well

CASE 8—A 29 year old man entered the hospital desperately ill, toxic, dehydrated, severely anemic, and in great pain with an acute osteomyelitis involving the entire right femur, except for the upper fourth He was treated with five transfusions fluids, a hip spica, and sulfathiazole His general condition rapidly improved, he became comfortable, and began to gain weight In his hospital stay of ninety five days he was given sulfathiazole on sixty days with no untoward effects except for several temperature elevations which were thought to be due to the drug There was no abscess formation, and no incision were made Diagnostic aspiration cultured *Staph aureus*

Comment.—It is too early to know the end results in this case, but the acute process subsided without any surgical procedure

CASE 9—A 11 year old man entered the hospital with pain in the right knee region of eight weeks' duration There was no previous history of osteomyelitis Roentgenograms showed an area of dense sclerosis in the lower femoral shaft, consistent with a sclerosing osteitis of Garré However, at operation a bone abscess cavity, centrally located, was found and saucerized Eight grams of sulfathiazole were placed in the wound which was closed by primary suture, and a cast was applied from the toes to the groin The culture from the abscess was *Staph aureus* The patient then received 90 gr. of sulfathiazole a day for eighteen days, which produced an average blood level of 5 6 mg, and also an anemia which required two transfusions Eighteen days after operation, slight drainage occurred, and he was discharged walking with crutches

Eight months after the first operation he was readmitted and the persistent sinus tract was excised Sulfathiazole was placed in the wound, which was subsequently closed and has remained so for the last fifteen months

Comment—A bone abscess of the femur was treated in a routine manner A second operation on the persisting sinus resulted in healing The patient tolerated sulfathiazole well

CASE 10—A 41 year old man had had acute recurrent osteomyelitis of the lower right femur for the last twenty two years Pain, heat, swelling, and tenderness had been present over the right lower femur for the last six months Ninety grams of sulfadiazine were given daily for eight days before operation and for eighteen days afterward, maintaining an average blood level of 8 mg without reaction Saucerization was carried out and an extensive cystic area containing pus was found Five grams of sulfathiazole were placed in the wound before primary closure The cast was left on for five weeks after operation, at which time there was still slight drainage from the wound The culture at operation showed *Staph aureus* At eight weeks after operation sinus drainage was still present, but we have been unable to follow this case

Comment—Saucerization was carried out on an extensive, old, femoral osteomyelitis with sinuses persisting at eight weeks The delayed healing may be due to the fact that sulfadiazine was used

CASE 11—A 30 year old woman entered the hospital with a third flare up of osteomyelitis of the left lower tibia, acutely painful for three days The original on

SOLITARY ECCENTRIC (CORTICAL) ABSCESS IN BONE

R. C. Brown, M.D.,* Green Bay, Wis., and Ralph K. Ghormley, M.D.†
Rochester, Minn.

THE apparently occult nature of solitary eccentric (cortical) abscess in bone as seen clinically and the lack of complete agreement between our experiences and those of others have prompted a review of the records of all cases in which patients suffering from cortical abscess of bone were seen at the Mayo Clinic over a period of ten years, including 1941. Besides the cases of cortical abscess on which data are given here, we reviewed the records of the cases of tuberculosis of long bones, osteitis of Garré,[1] acute and chronic osteomyelitis, Brodie's abscess,[2] osteoma, and osteochondroma. This was done for the reason that confusion with those categories not only is possible, but does occur. Limitation to single lesions was self-imposed and not because they are believed to occur only in this manner. They were seen with other lesions concomitantly, as chronic osteomyelitis.

We are concerned with single, uncomplicated lesions, which give rise to a rather definite syndrome, pursue a regular benign course, and are susceptible to complete surgical eradication. They occur in both the long and the short bones, being characteristically placed, lying within, subjacent to, or superposed on, the cortex, occasionally in the neighborhood of an articulating surface. The exciting center of the lesion itself is minute, not exceeding a few millimeters in diameter as seen both at operation and in the roentgenogram. It elicits a variable mass of reaction, dependent seemingly upon the location with respect to the cortex and little affected by the age of the lesion.

STATISTICAL STUDY

Twenty-four patients were found to fall in this group. Their ages varied from 3 to 55 years. Twenty-one of the total were distributed nearly equally among the first three decades of life, the variation not being significant. Six were from 1 to 10 years of age, eight were from 11 to 20, and seven were from 21 to 30. The remaining three were in the fourth and fifth decades. There were ten female and fourteen male patients. Fifteen abscesses were found on the right of the body and nine on the left.

Brodie's abscess was encountered twenty-six times in the same period, while the osteitis of Garré was found but five times. There were twenty-

Received for publication, April 6, 1943

*Formerly a Cole Fellow in Orthopedic Surgery, University of Minnesota, Minneapolis.

†Section on Orthopedic Surgery, Mayo Clinic, Rochester.

primary closure without drainage, all wound levels being dusted with sulfathiazole; and plaster immobilization, including the joint above and below the site of the lesion.

c. Postoperative chemotherapy with oral sulfathiazole for a period of at least two weeks.

3. In seven cases saucerization was done. Five healed promptly, and two did not. Both refractory cases were sensitive to sulfathiazole.

4. In five other patients saucerization was not done because of actively draining sinuses without gross evidence of bone infection. All these healed promptly with primary closure.

5. If patients cannot tolerate sulfathiazole we have tried sulfadiazine, though we have had insufficient experience with it to report on its use.

REFERENCES

1. Dickson, F. D., Dively, R. L., and Kiene, Richard: Use of Sulfathiazole in Treatment of Subacute and Chronic Osteomyelitis, J. Bone & Joint Surg. 23: 516-520, 1941.
2. Dively, R. L., and Harrington, P. R.: Chemotherapy in Infections of the Bones and Soft Tissues, J. A. M. A. 117: 1868-1870, 1941.
3. Hoyt, W. A., Davis, A. E., and Van Buren, George. Acute Hematogenous Staphylococcic Osteomyelitis: Treatment With Sulfathiazole Without Operation, J. A. M. A. 117: 2043-2049, 1941.
4. Key, J. A., Frankel, C. J., and Burford, T. H.: The Local Use of Sulfanilamide in Various Tissues, J. Bone & Joint Surg. 22: 952-958, 1940.

SOLITARY ECCENTRIC (CORTICAL) ABSCESS IN BONE

R. C. Brown, M.D.,* Green Bay, Wis., and Ralph K. Ghormley, M.D.†
Rochester, Minn.

THE apparently occult nature of solitary eccentric (cortical) abscess in bone as seen clinically and the lack of complete agreement between our experiences and those of others have prompted a review of the records of all cases in which patients suffering from cortical abscess of bone were seen at the Mayo Clinic over a period of ten years, including 1941. Besides the cases of cortical abscess on which data are given here, we reviewed the records of the cases of tuberculosis of long bones, osteitis of Garré,[1] acute and chronic osteomyelitis, Brodie's abscess,[2] osteoma, and osteochondroma. This was done for the reason that confusion with those categories not only is possible, but does occur. Limitation to single lesions was self-imposed and not because they are believed to occur only in this manner. They were seen with other lesions concomitantly, as chronic osteomyelitis.

We are concerned with single, uncomplicated lesions, which give rise to a rather definite syndrome, pursue a regular benign course, and are susceptible to complete surgical eradication. They occur in both the long and the short bones, being characteristically placed, lying within, subjacent to, or superposed on, the cortex, occasionally in the neighborhood of an articulating surface. The exciting center of the lesion itself is minute, not exceeding a few millimeters in diameter as seen both at operation and in the roentgenogram. It elicits a variable mass of reaction, dependent seemingly upon the location with respect to the cortex and little affected by the age of the lesion.

STATISTICAL STUDY

Twenty-four patients were found to fall in this group. Their ages varied from 3 to 55 years. Twenty-one of the total were distributed nearly equally among the first three decades of life, the variation not being significant. Six were from 1 to 10 years of age, eight were from 11 to 20, and seven were from 21 to 30. The remaining three were in the fourth and fifth decades. There were ten female and fourteen male patients. Fifteen abscesses were found on the right of the body and nine on the left.

Brodie's abscess was encountered twenty-six times in the same period, while the osteitis of Garré was found but five times. There were twenty-

Received for publication April 6, 1943.

*Formerly a Cole Fellow in Orthopedic Surgery, University of Minnesota, Minneapolis.

†Section on Orthopedic Surgery, Mayo Clinic, Rochester.

nine cases of periostitis definitely not in this group. Other possibly confusing diseases, such as osteitis, occurred ninety-six times including syphilitic osteitis. The tibia and the femur were the most common sites, accounting for twenty of the patients in this group. The lesion was seen also in the fibula, the radius, the os calcis, and the patella. There was no apparent predilection with respect to the site, as from proximal to distal portions of the long bones, three occurring in each of the thirds of the femur, and four in each of the superior and middle thirds of the tibia, while there were three in the lower third of that bone.

CLINICAL PICTURE

The clinical picture is of a relatively mild but troublesome condition. Pain is observed constantly, being rarely excruciating but often aching. There is a strong tendency to wax and wane. Exacerbations occurred commonly in changes of weather or when the patient stood for a long time or subjected himself to other unusual exertion.

The patient's localization of the pain is accurate to a high degree in most instances, the exceptions being in those cases in which the lesion is in the upper regions of the femur. In these cases complaint was made of pain about the lower or lateral part of the thigh or the knee, as is fairly common in other lesions about that region. Pain occurred at night and, when it did, was sharp, particularly among children, who cried out and awakened. Nocturnal pain was also more common as the disease process became older.

Swelling was the next most common symptom, occurring in seventeen of the twenty-four cases. This was more in the nature of a thickening and induration and, when marked, was accompanied by redness and increased heat. Swelling is most common in the lesions of the middle third of the tibia. Atrophy or swelling may occur in lesions of the superior regions of the femur, those about the neck chiefly giving atrophy.

A limp was present in cases of affections about the joints, as in the neck or the lower part of the femur and in the superior thirds of the tibia, and, in a few instances, in other bones, particularly in the os calcis and the patella. The apparent age of the lesion seems to have little to do with the limp, being present in one case for nine years, and in another for but two months.

The chronicity of the complaint is striking. One patient had had pain for thirty-five years, another for twenty-seven years, and a third and fourth for ten and nine years. On the other hand, one who had bumped his arm two months prior to examination noted continuous enlargement for that period. All of these displayed typical findings. Eleven of the twenty-four patients had complained for a period of one year or less; nine of these were seen before six months. Eight had complained for from one to six years, the remaining five from that time to thirty-five years.

The physical findings are not remarkable. Thickening and induration to palpation in those regions that were accessible were found in most instances. Limping was found in those in which there were lesions near a joint. Redness over the site of the induration was noted rarely. Jarring of the involved bone brought on increased pain only



Fig. 1.—Right tibia of white boy aged 13 years, who complained of occasional limping, which had been present for nine years. Four months prior to examination aching began in lower part of right leg. Pain was present night and day, or when at rest. A small bone in the right foot had been fractured eleven years previously. There were 1 inch (2.5 cm.) atrophy of right thigh and 1½ inches (4 cm.) atrophy of right calf. There was pain on pressure over the right tibia.

inconstantly. Fever was found in only one case; the oral temperature was 99.6° F.

ROENTGENOGRAPHIC FINDINGS

The roentgenologic examination was the greatest aid, the picture being definite. The minute exciting lesion is characteristically seen, radiolucent, located within or beneath the cortex, but most commonly in the

FIG. 2—[illegible]

osteoplastic reactive portion of the periosteum (Fig. 1). Here a word may be said about the interpretation of the roentgenogram. The appearance of the dark central portion as in Fig. 2 apparently locates it as lying in the cortex, while in Fig. 3 it is apparently superposed on the cortex. It must be evident that the projection of the shadows may account for the variation of the appearance to a certain extent. How-

Fig. 3.—Right femur of white woman, aged 55 years, who complained of pain and swelling in the right thigh. Thickening about the right thigh was palpable and the right thigh was slightly tender. The patient had had tonsillitis two years previously. She had injured the right thigh twenty-seven years before she was seen. The injury had necessitated rest in bed for one and one-half months. This was followed by limping for three months.

ever, we agree with others that the lesions do occur within and on either side of the cortex. Reaction with the osteosclerosis occurs about the lesions uniformly and is the pathognomonic portion of the picture,

Fig. 4.—Right tibia of white man, aged 23 years, who complained of aching at night, which was relieved by heat. There was never any limp. There was a swelling on the lateral aspect of the tibia 3 inches (8 cm.) superior to the malleolus but no tenderness or reddening. The motion of joints was normal. A year before, the patient had struck the leg against a cement step. No bruising occurred.

especially its eccentric position. Relatively enormous elevation of the periosteum is seen with heavy densification. Medullary reaction is present also, as seen in Figs. 1, 2, 3, 4, and 5. Very little medullary

disturbance seems present in every instance. Fig. 6 represents an unusual patellar lesion.

As one would expect, the organization is dependent on the time the lesion has been present. For instance, note Fig. 2 in comparison with

Fig. 5.—Left femur of white girl aged [illegible] years who had complained of limping for four months. There was pain in the left knee. The patient had an oral temperature of 99.5° F. after one month in bed. There was limitation of motion at the hip and slight spasm of the psoas muscles but no definite tenderness. Brucella agglutination was negative. The sedimentation rate was 20. The patient was given sulfathiazole, and fever abated after one month.

Fig. 3. In the latter, the lesion has been present for twenty-seven years and has undergone extensive organization, complete with the formation of an apparently secondary cortex, and with more or less restoration of the original cortex.

Fig. 6.—Right patella of white woman, aged 27 years, who complained of pain and "popping and cracking" in knee, present for ten years. Tonsillitis was graded 2. There was some thickening to palpation about the anterior portion of the knee.

In Fig. 4, an interesting problem is offered in diagnosis, not only from the roentgenologic standpoint, but from the clinical viewpoint as a whole. A question immediately arises as to the presence of a

Ewing tumor. The visibility, however, of the minute radiolucent area apparently in the center, geometrically speaking, of the reactive portion suggests the differential diagnosis. This is the annular sequestrum of some authors. In Fig. 5 is seen the typical lesion in the neck of the femur, a slight variation from normal, but none the less recognizable by the small radiolucent portion in the osteoplastic reaction.

Fig. 7.—Specimen from right tibia of white boy, aged 3 years, who had had pain and swelling in the right leg for six months. Swelling was increasing and pain decreasing when the patient was seen. He had nocturnal pain, awakened, and cried out. Swelling and reddening with tenderness were present. The specimen is characterized by chronic fibrous tissue, obliteration of vessels, and scattered giant cells (×45).

Not illustrated because it seemed impossible to reproduce was a lesion showing in the lower portion of the radius of two months' duration. Here was seen the architecture of those shown, with this difference, that the density was much less and the cortical portion itself and the medulla had undergone little change. The small shadow of decreased density was located definitely without the cortex and entirely within the area of periosteal reaction. This was interpreted as an early lesion for the same reason that the patient shown in Fig. 3 is believed to have a late lesion because of the extensive organization. In cases of early lesions overexposure of the roentgenogram may be an aid in obtaining more significant material.

PATHOLOGY

The pathologic picture is one of chronic inflammation. This is in distinct contradiction to the work of Jaffe,[1-3] whose excellent presentations must be consulted by anyone interested in these lesions. Fourteen of the twenty-four patients seen were submitted to surgical correction.

Fig. 8.—Specimen from left tibia of white girl, aged 5 years, who had complained of pain in the lower part of the left leg for three months. Ten months previously she had a "boil" on the upper outer portion of the left leg. She was said to have had a low degree of fever. A culture of *Staph. aureus* was obtained at operation. The lesion was seen surgically as 2 c.c. of purple granulation tissue, corresponding to the location in the roentgenogram. Microscopically, it was characterized by polymorphonuclear infiltration in fibrous tissue (×145).

Fig. 9.—Specimen *from right tibia of white man*, aged 29 years, who complained of pain and swelling. Redness was occasionally present. Symptoms occurred with intermissions. Hot packs afforded some relief. Varicosities were present bilaterally. The specimen was characterized by dense regions of necrotic bone in chronic fibrous tissue and scattered round cell infiltration (×75).

In ten cases the lesions were seen microscopically by the pathologist as "chronic inflammatory tissue." Review of these sections revealed the picture as seen in Fig. 7, typically chronic fibrous inflammatory tissue with a few scattered giant cells and scattered collections of round cells. Obliteration of the vessels as shown here was well marked in all of these sections. Instances, as in Fig. 8, were also observed in which there was infiltration of polymorphonuclear leucocytes in fibrous connective tissue. Fig. 9 illustrates the destructive nature of the lesion, old necrotic bone seen in a field of chronic inflammatory fibrous tissue and scattered round cell infiltration. The roentgenographic findings in these cases were typical.

TREATMENT

The treatment of these patients was not uniform. Fourteen were submitted to operation. These obtained definite relief. One was given roentgen therapy and was much improved a year later. One was advised to undertake rest in bed and was improved both clinically and as seen by roentgenogram on repeated examinations. The final results are not yet determined in this case. Surgical excision is the procedure of choice, offering the best assurance of relief. Removal of the exciting portion is sufficient, only a small region being attacked. Further proof of the necessity of surgical intervention is found in those patients seeking relief, nine, ten, twenty-seven, and thirty-five years after onset. The operation is comparatively simple, exception to this statement being taken in two circumstances, first in those in which lesions are present in the neck of the femur and such places as the patella. There are perhaps others as difficult for this reason, but not yet encountered. Second, it is by no means with unpracticed marksmanship that one approaches accurately these lesions, minute as they may be and lying in the dense armor of bony tissue overlying them. Possibly, roentgen therapy may offer some benefit. The impression is, however, that the results will not be comparable to those of surgical excision.

COMMENT

Discussion of the causation has been avoided purposely to this point. Examination at necropsy of the external portion of these lesions failed to reveal any findings conforming to the usual picture of a new growth. The results of inflammation were evident in all of the tissue reviewed. In spite of the fact that in only one of these cases was there measurable fever, it is felt that inflammation is the basis of the lesion. Despite the fact that the patient seeks the dramatic curtain raiser for the onset of his complaints, nine of the patients in this group, or approximately a third, accurately noted that a fall or a bump, or, as in one instance, a puncture wound from a nail in the heel initiated the pain. In one case a bump to the forearm caused swelling, which had never subsided during the two months' interval between the bump and the

Fig. 8.—Specimen from left tibia of white girl, aged 5 years, who had complained of pain in the lower part of the left leg for three months. Ten months previously she had a "boil" on the upper outer portion of the left leg. She was said to have had a low degree of fever. A culture of *Staph. aureus* was obtained at operation. The lesion was seen surgically as 2 c.c. of purple granulation tissue, corresponding to the location in the roentgenogram. Microscopically, it was characterized by polymorphonuclear infiltration in fibrous tissue (×145).

Fig. 9.—Specimen from right tibia of white man, aged 29 years, who complained of pain and swelling. Redness was occasionally present. Symptoms occurred with intermissions. Hot packs afforded some relief. Varicosities were present bilaterally. The specimen was characterized by dense regions of necrotic bone in chronic fibrous tissue and scattered round cell infiltration (×75).

posed to nine on the left, and there was also a slightly greater number of male patients. One has the impression of a small lesion being overwhelmed by massive defensive mechanisms apparently present in the region of the cortex.

SUMMARY

Data on twenty-four additional cases of eccentric minute lesions of bone (cortical abscesses) are presented. The following observations support the hypothesis that the condition is due to trauma or infection rather than tumor.

1. Microscopic evidence of formation of tumor was not seen in fourteen of twenty-four cases in which specimens were examined microscopically.

2. Definite destructive and inflammatory changes, not only of a fibrous nature, but also of a more acute one, were observed.

REFERENCES

1. Henderson, M. S.: Chronic Sclerosing Osteitis, J. A. M. A. 82: 945-949, 1924.
2. Brailsford, J. F.: Brodie's Abscess and Its Differential Diagnosis, Brit. M. J. 2: 119-123, 1938.
3. Jaffe, H. L.: "Osteoid-Osteoma" a Benign Osteoblastic Tumor Composed of Osteoid and Atypical Bone, Arch. Surg. 31: 709-728, 1935.
4. Jaffe, H. L.: Osteoid Osteoma, Am. J. Path. 12: 796-797, 1936.
5. Jaffe, H. L., and Lichtenstein, Louis: Osteoid-Osteoma: Further Experience With This Benign Tumor of Bone, With Special Reference to Cases Showing the Lesion in Relation to Shaft Cortices and Commonly Misclassified as Instances of Sclerosing Nonsuppurative Osteomyelitis or Cortical-Bone Abscess, J. Bone & Joint Surg. 22: 645-682, 1940.
6. Phemister, D. B.: Silent Foci of Localized Osteomyelitis, J. A. M. A. 82: 1311-1315, 1924.
7. Phemister, D. B.: Pyogenic Osteomyelitis. In Nelson's New Loose-Leaf Surgery, vol. 3, chap. 7, New York, 1941, Thos. Nelson & Sons, 695-727S.
8. Phemister, D. B.: Chronic Fibrous Osteomyelitis, Ann. Surg. 90: 756-764, 1929.

examination. It was in this instance also that the early lesion previously alluded to was seen in a roentgenogram. Eight of the patients of this report had had a previous focal infection such as chronic cervicitis, tonsillitis, a boil, typhoid fever or, as in one, a swollen painful knee (not the patellar lesion).

It is realized that both trauma and focal infection are not proved easily. However, two-thirds of all our cases may be accounted for as due to trauma or infection rather than to a neoplasm. Add to this that two of the patients had had their disease for twenty-seven and thirty-five years, and one feels that it more nearly follows the general picture of low grade inflammation than one of new growth as has been presented by Jaffe. The findings, as in Fig. 3, tend to support this view. *Staphylococcus aureus* was found in two cultures and micrococcus was found in two, all taken from the tissue at operation. Neither the age of the patient nor the duration of the disease apparently plays a part in the ability to find organisms. In the two cases in which staphylococcus was found the patients were at the ages of 5 and 22 years. The estimate of duration was ten and two and one-half months respectively. Micrococcus was found in patients aged 3 and 15 years, the duration of the symptoms being six months in the first case and five years in the second. Fig. 7 is from the former patient. Fig. 8 is from tissue of the patient aged five years with the duration of ten months.

No patient was included in this series who had a known concomitant bone lesion. That cortical abscess occurs in instances of chronic osteomyelitis is well known and has been commented on repeatedly by Phemister.[6, 7, 8] We agree with others in distinguishing this lesion from osteomyelitis of Garré, which is a symmetrical lesion in its roentgenogram. The eccentric position seen here is not present. Two roentgenologic projections should serve to distinguish the lesions.

Speculation as to the comparable frequency of Brodie's abscess seen in this review is possibly not fruitful; however, the similarity of the number of occurrences and of the pathologic pictures suggests that this may be the cortical counterpart of that lesion. Great powers for organization of defense are present in the cortical region, which is evidenced by the massive reaction as seen both roentgenographically and at operation. Further support may be gained from the fact that previous infection and previous trauma occur in approximately the same percentage of patients who have the disease.

One realizes that trauma is difficult to reconcile with lesions in such sites as the neck of the femur and those portions of the tibia opposed to the fibula. However, in no case of lesion of the femoral neck was a history of external force elicited. In those cases in which it was recorded, the lesion occurred in the tibia six times, in the radius once, in the os calcis once, and in the middle segment of the femur once, all regions accessible to direct force. Fifteen occurred on the right as op-

scopic studies which I desired, but was very kind in helping me locate someone who could do this for me. Some of the technical requirements, as will be later shown, were of considerable magnitude. Ernest W. Goodpasture, professor of pathology of Vanderbilt University, very kindly consented to aid me and made the microscopical sections, photomicrographs, and pathologic studies in this report, for which I am very grateful.

CASE 1.—A white man, J. J., a carpenter, aged 65 years, short, robust, obese, came to me Jan. 10, 1938, for repair of a ruptured supraspinatus tendon which he had received from an injury to the left shoulder when a scaffold fell with him on Dec. 7, 1937, causing the point of the shoulder to strike a board on the ground. Operation was performed May 16, 1938. The supraspinatus tendon was exposed by a straight Codman incision downward from the acromial process of the scapula. The avulsion was so great that I decided to attempt reconstruction by fascia lata sutures. An incision six inches long was made through the skin and subcutaneous fat on the lateral surface of the left thigh, and the fat brushed aside with the knife, exposing a clean surface of strong fascia lata two and one-half inches wide, the full length of the incision. Two strips of fascia each one-half inch wide and six inches long were removed. These fascia lata sutures were passed through drill holes beneath the superior facet of the humerus and anchored to the avulsed end of the supraspinatus tendon with black silk. The wound was closed in layers with 00 plain catgut for the deeper layers and fine dermal for the skin. The arm was maintained in abduction.

On the sixth day infection was apparent in the deeper parts of the wound, but not in the skin. On opening the lower angle of the wound a large amount of thick, purulent material was evacuated, and in it were some silk sutures. All of that stock of silk in the operating room was cultured and found to be contaminated with a hemolytic staphylococcus. The wound was Dakinized and the infection subsided in a few days after all the silk sutures came away. I then realized that the operation was a failure. The arm was carried in an aeroplane splint and frequent physiotherapy was given the extremity to prevent further atrophy until Jan. 10, 1939, when a second operation was done for the repair of the tendon.

I was compelled again to use fascia lata because of a greater defect than before in the musculotendinous cuff, and decided to open the same incision on the thigh for the fascia. I found that the two margins of the fascia lata had spread apart three inches in the center. Much to my surprise and amazement, connecting these two margins of full thickness fascia lata was a smooth layer of fascia which completely covered and obscured the muscles and appeared to be one-half as thick as the original fascia lata, or one-half as thick as the fascia margins. An incision was made along the lateral edge, in order to take some full thickness fascia lata for this operation, and in freeing the regenerated or new fascia lata from the old, I observed that this new fascia was a real layer with the thickness of a thin kid glove and was not more adherent to the muscles than was the normal fascia lata. I realized that it could have been used for sutures as well as normal fascia lata, had it been double or had the strips been taken twice as wide and folded one side on the other. I was so intent on the operation before me that I neglected to photograph this new fascia, or to take sections for biopsy. The following day I realized that I had found something I had not known before, and my curiosity was aroused to see if this regeneration might occur on other patients from whom I had removed fascia lata for various operative and plastic procedures. It was my pleasure within a few months to have the opportunity of exploring the second case.

FASCIA LATA REGENERATION

Preliminary Report

J. C. Foshee, M.D., F.A.C.S., Grand Rapids, Mich.
(From the Department of Surgery, Butterworth Hospital)

THE purpose of this communication is to show what happens to the fascia lata defect when a part or all of the fascia lata is removed in the performance of certain surgical operations.

I beg indulgence of the editors and the readers that I may be permitted to relate briefly the incidents which have led me to use fascia lata in many types of surgical procedures for sixteen years and the manner in which I came to discover what occurs in the defect from which the fascia lata is removed.

It was my good fortune and great pleasure to attend the clinic given by the late Dr. Scrimger of Montreal to a group of surgeons at the Royal Victoria Hospital during the meeting of the American College of Surgeons in 1926, at which time he demonstrated by operation the use of living fascia lata transplant sutures for the repair of inguinal hernia according to the technique of Gallie and Le Mesurier.[1, 2] The day of my return home I had to repair a large direct inguinal hernia in a woman. I used fascia lata for sutures, as I had seen it used by Scrimger, with special needles which I had brought from Montreal.

Since that time I have used fascia lata transplants in all recurrent inguinal hernias which I have repaired, all large inguinal hernias, direct and indirect, with wide internal oblique and transversalis aponeurosis defects, almost all incisional hernias, and all the large true ventral hernias. Earlier, I used fascia for the suturing of bones in some cases in which open operation seemed indicated to maintain the reduction of fractures, but soon gave that up. I have used it in operations for arthroplasty, ligament replacement, and tendon repair. It was in one of the latter cases that I was fortunate enough to discover what happens in the way of spontaneous replacement of the fascia lata when I had both the privilege and chagrin of being compelled to reoperate upon a patient for repair of a ruptured supraspinatus tendon, the first operation being a failure. Since that time I have had the pleasure of dissecting out and seeing for myself, as well as for my associates, that which occurs in four more instances.

Except in Case 1, I had photographs made of the regenerated fascia during and after removal at operation. W. P. L. McBride, the pathologist of our hospital, was not equipped to do some of the technical micro-

Received for publication, Jan. 30, 1943.

been joined by suture, and extensive fibrous tissue proliferation similar to a keloid formed the union (Fig. 2A). I removed a specimen from this scar. Sections were cut before I could explain to our pathologist my desire to have it sectioned transversely. I believe it was cut obliquely and it shows two thick layers with much proliferation of fibrous tissue and numerous blood vessels. The middle longitudinal layer is probably absent in this area of regeneration (Fig. 2B).

Now, having observed these two patients, I was determined to look further at the fascia lata of patients from whom I had removed living sutures and fascia grafts.

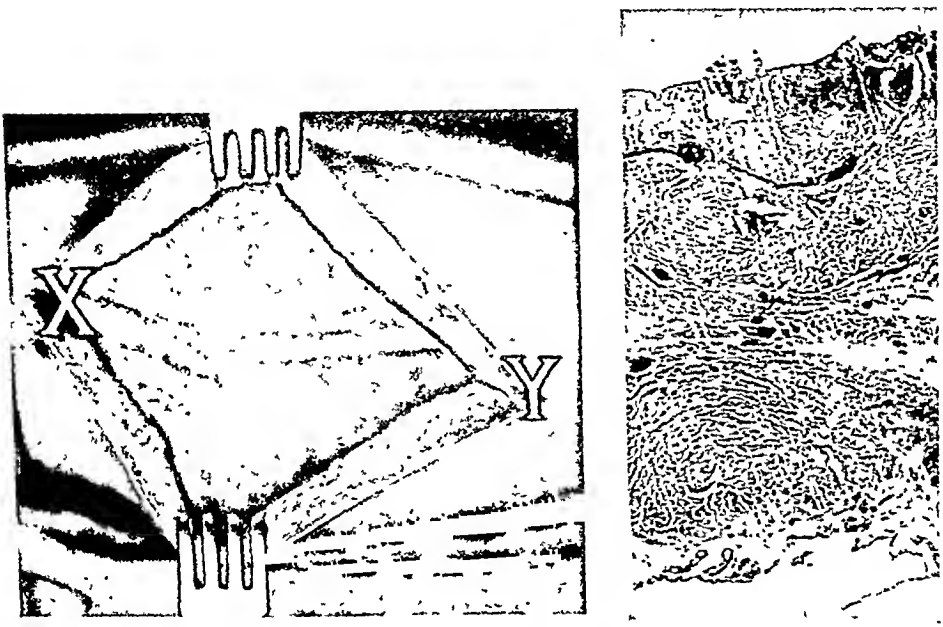

A. B.

Fig. 2.—A, Dense line of union from X to Y of fascia lata as though it had been approximated by suture. B, Two dense layers of regenerated fascia lata form the union. (×45.)

CASE 3.—A white man, C. R., aged 48 years, medium build, slender extremities, was referred to me on Jan. 26, 1939, for the repair of a ventral hernia. I performed the operation for the cure of the hernia on Jan. 28, 1939, using three living fascia sutures one half inch by seven inches which were taken from his right thigh. The patient was called to my office on June 25, 1939, and I persuaded him to let me reopen his thigh to see what had happened to the fascia lata defect. He kindly consented, and four days later I explored the defect by excising the old scar in the right thigh for a distance of six inches. When the skin and subcutaneous fat were freed from the fascia lata there was found a complete union of the margins of the fascia lata as though the two edges had been sutured together (Fig. 3A). And this ridge of union the length of the incision was twice as thick for a breadth of three quarter inch as was the fascia lata anywhere else, quite identical to Case 2. A block of fascia two inches long was secured from the middle region of this scar, taking some of the normal fascia on each side (Fig. 3B). The wound was closed

The histologic study of fascia lata is so interesting and pertinent to these cases I feel that I should make a few brief remarks here about normal fascia lata before proceeding further with the next case report. Fig. 1 shows normal fascia lata to have three distinct layers; a middle longitudinal layer which is the stronger one, and two transverse layers, the outer and inner layers which are the weaker ones. Both together equal or surpass the middle one. Further explanation is found under the heading Comments.

Fig. 1.—Normal fascia lata cut transversely to the strong middle longitudinal layer, and therefore parallel to the inner and outer transverse layers. (×100.)

CASE 2.—A white man, L. H., aged 42 years, tall and slender, reported to me on Aug. 13, 1939, with a right direct recurrent inguinal hernia which I had repaired with fascia lata sutures taken from his right thigh on Nov. 11, 1937, according to the technique of Gallie and Le Mesurier,[1, 2] using two strips of fascia lata each five-eighth inch wide and six inches long. The patient had a cleft palate and a chronic upper respiratory infection. In spite of the usual precautions following the first operation he developed an acute respiratory infection and a distressing cough the fourth day, which continued for ten days. This was probably the basis for the recurrence of the hernia. Operation was again performed on Aug. 15, 1939. On reopening the right thigh through the old incision for removal of more fascia, I found that the two margins had not retracted as in Case 1, but the two margins were reunited from one end of the incision to the other. The line of union of the two margins was so firm that it gave the appearance that the fascia margins had

Fig. 3C.—Cross-section line of union. There is a margin of normal fascia lata on the left with its three layers. All tissue to the right is made up of the inner and outer layers and represents regenerated fascia lata, the middle longitudinal layer being absent. (×45.)

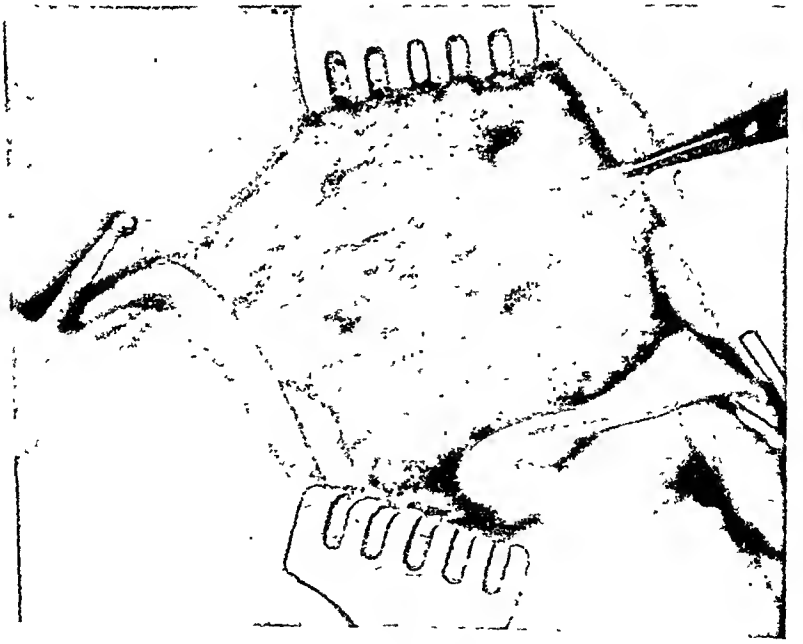

Fig. 4A.—Surface view of regenerated fascia lata.

in layers and a tight pressure bandage applied. Sections and photomicrographs made by Goodpasture show (Fig. 3C) at the extreme left a small area of normal fascia lata with its three layers. Extending across from that is a dense body of fibrous tissue which appears to be the extension and proliferation of the inner and outer transverse layers which fuse into one. The normal fascia on the other side does not show on the right since none was taken with the specimen at this level.

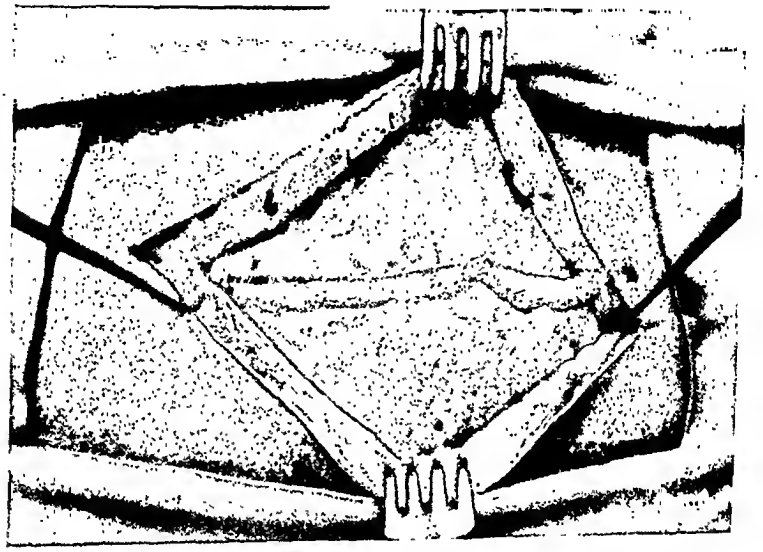

Fig. 3A.—Dense layer of fascia lata like a rope between the two skin hooks is the line of union.

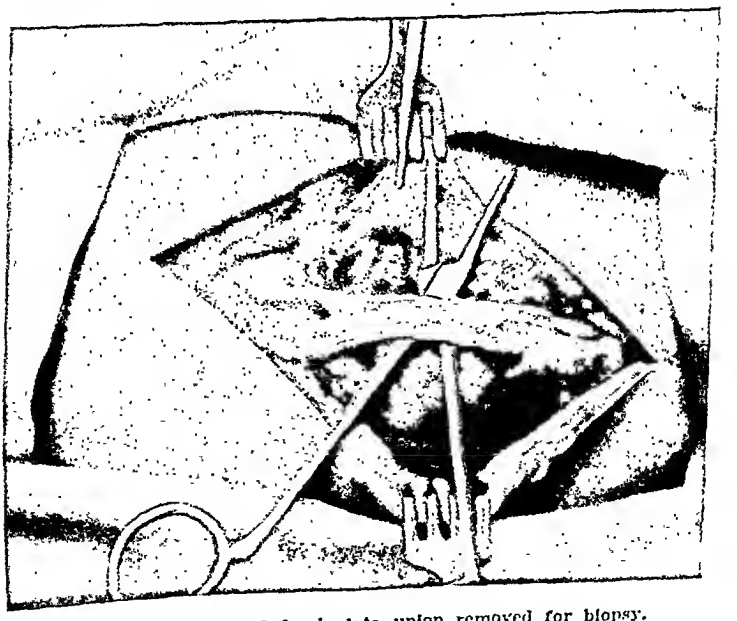

Fig. 3B.—Regenerated fascia lata union removed for biopsy.

in obtaining the sutures. This regeuerated fascia lata had the identical gross appearance of that in Case 1, not more attached to the subcutaneous fat than was the normal fascia lata, and loosely attached to the muscles by occasional fine trabeculations as is found in normal fascia lata.



Fig 4C —Smooth vastus muscle shows beneath, undisturbed.

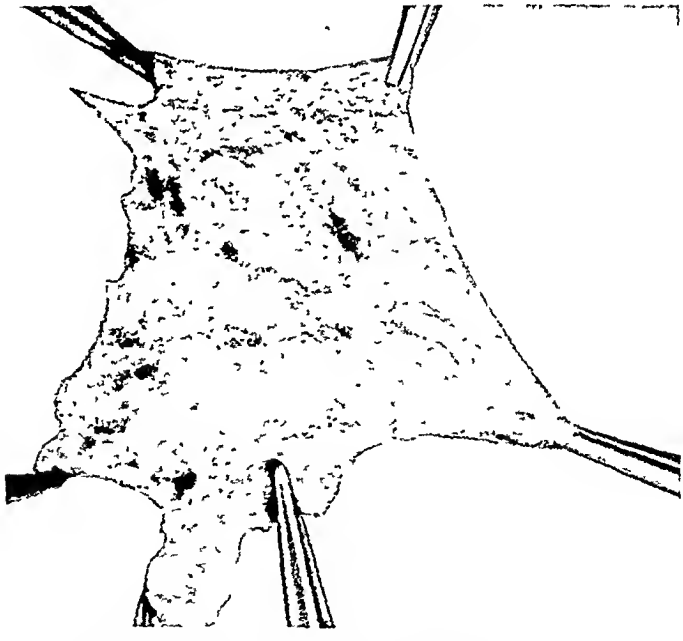

Fig 4D.—Normal fascia lata between the two hemostats at the top The remainder is regenerated fascia lata

At this stage of the investigation it was apparent that I had observed two different ways in which fascia lata regenerated In the two slender patients there was apparently no separation of the fascia edges, for they reunited together snugly; whereas in the two obese, robust, and muscular patients there was a wide separation of the fascia lata edges, but the

CASE 4.—A white woman, L. H., a housewife, aged 65 years, robust, obese, upon whom I had performed the operation for the cure of ventral hernia Aug. 18, 1940, using three strips of fascia lata five eighth inch by eight inches for sutures, reported to me at my request on May 2, 1941, at which time I explained to her why I desired to explore her thigh at the site from which I had removed the fascia lata. She readily consented, and on May 5, 1941, under local anesthesia, the old scar on the right thigh was removed by excision; the skin and subcutaneous tissue were dissected back to free widely the fascia below (Fig. 4*A*). The medial border of the fascia lata had retracted to about the midline of the thigh. The lateral border had retracted externally, enough to make an opening four inches wide in the middle.

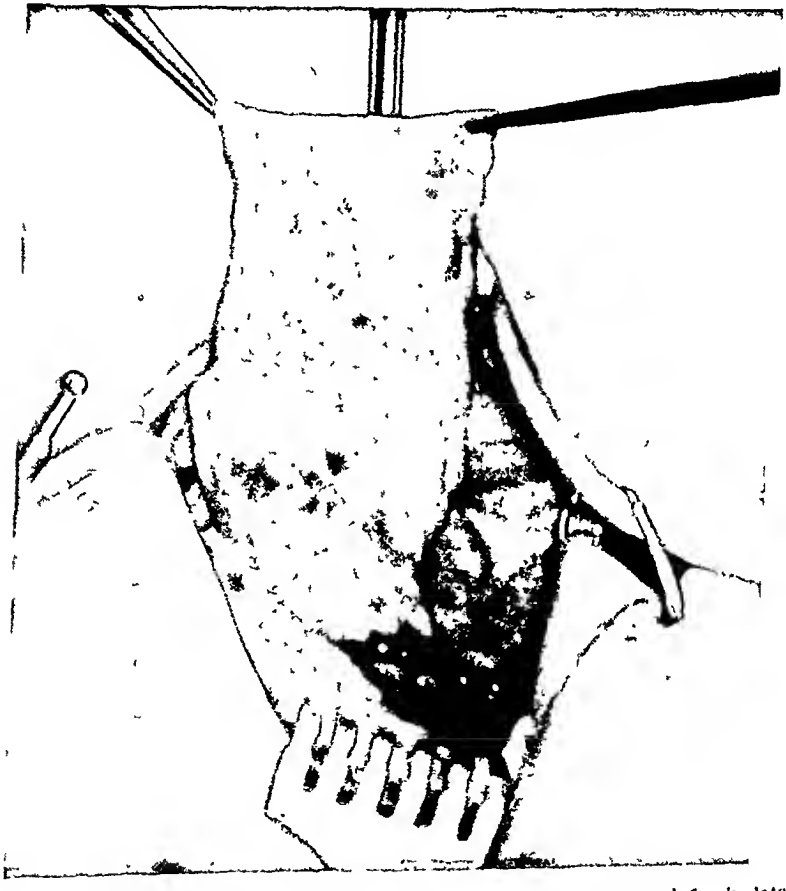

Fig. 4*B*.—Transverse flap of fascia lata dissected up with 1 cm. normal fascia lata at the top between the two hemostats

This elliptical defect throughout its entire length was completely filled in by a new layer of fascia lata, grayish white, glistening, and smooth in appearance, and it was one half the thickness of the normal fascia lata. A block three inches by five inches of this fascia lata was removed transversely across the thigh, taking one half inch of the normal fascia lata from the medial edge (Figs. 4*B*, 4*C*, and 4*D*). It was impossible to cut with this block any normal fascia lata on the lateral edge because it had been removed externally close to the border of the rectus femoris muscle

Fig. 1G.—Continuation of the two layers as in 4F. (×22.)

Fig. 1H.—Transverse section at a different level from 1E, with greater magnification (×38), shows in the left two-thirds the distinct layers of normal fascia lata with the longitudinal layer in the middle, its bundles being cut transversely. Only the inner and outer transverse layers, whose bundles are cut parallel to their fibers, extend across to form the regenerated fascia lata.

Fig. 4E.—Normal fascia lata in the left half. Regenerated fascia lata in the right half. The external layer extends across in continuity. The inner layer has been torn loose from the left half and is curled back just to the right of the middle. Note the dense fascia bundles of the middle layer in the left half. (×22.)

Fig. 4F.—Inner and outer layers of regenerated fascia lata extending across in continuity from 4E. Each layer has its own thin sheath, blood vessels, nerve supply, and intervening layer of adipose tissue. The middle longitudinal layer is absent. (×22.)

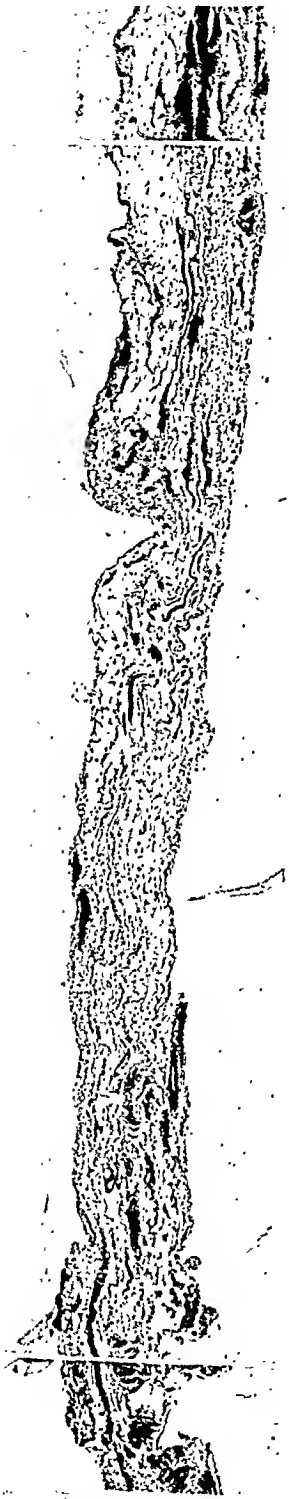

FIG. 16.—Continuation of the two layers as in 4F. (×22.)

FIG. 4H.—Transverse section at a different level from 4E, with greater magnification (×48), shows in the left two-thirds the distinct layers of normal fascia lata with the longitudinal layer in the middle, its bundles being cut transversely. Only the inner and outer transverse layers, whose bundles are cut parallel to their fibers, extend across to form the regenerated fascia lata.

intervening defect was covered by fascia lata which was thinner than normal fascia lata. Except for this, it had all the gross characteristics of normal fascia lata.

I then decided that I should have cross-section microscopic studies made in tandem of this entire specimen cut on edge. I found it very difficult to find a pathologist who would or could do this, but when I went to Dr. Goodpasture with the gross specimen and my problem, he quickly found a way to do it. The specimens and photomicrographs are a work of art (Figs. 4*E*, 4*F*, and 4*G*). They show that in all probability it is the outer and inner layers of fascia lata which regenerate and extend by continuity across the previous defect. Fig. 4*H*, made at a different level from 4*E*, shows clearly the three layers of normal fascia lata in the left two-thirds, whereas, in the right third it shows only the inner and outer layers which extend across to form the beginning of the regenerated fascia lata.

If we assume that the inner layer has by accident been torn away from the inner half of 4*E* and is shown curled back in the right half of 4*E* near the middle, then we feel certain that 4*E* would also show the three distinct layers throughout its breadth with the middle longitudinal layer extending nearly halfway across and being very dense. The external layer extends directly across from 4*E* and runs in continuity to the end of the specimen in 4*G*; the inner layer which starts from the curled-up portion in Fig. 4*E* extends straight across in continuity throughout the length of the specimen through 4*G*. There is some adipose tissue on the outside of the upper layer and each layer has its own blood vessels and much intervening collagenous fibrous tissue.

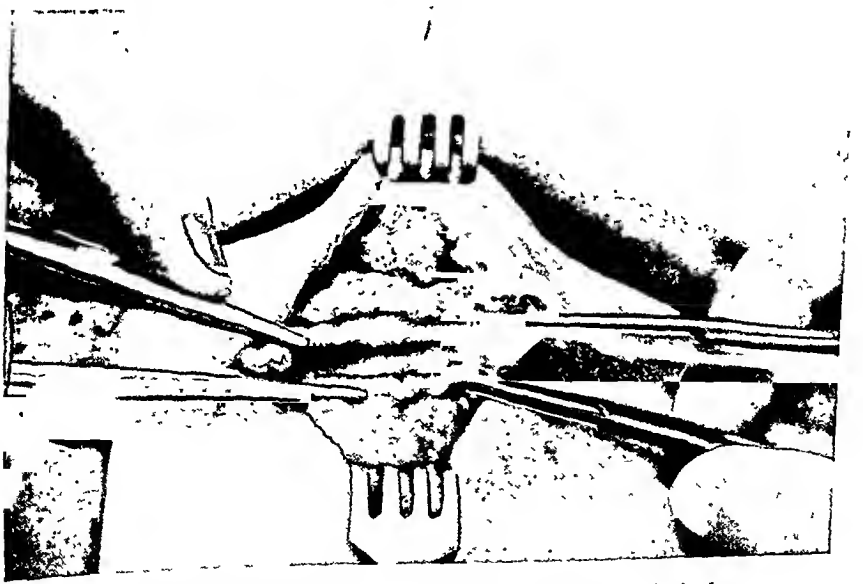

Fig. 5*A*.—Distinct layer of regenerated fascia lata incised.

CASE 5.—A white male, E. T., aged 35 years, a college professor, medium build, slightly adipose, from whom 12 years before I had removed all the fascia of the right thigh for the purpose of a knee arthroplasty on his brother of the same blood group. At the time I thought the brother had no more fascia lata of his own available, because of the two previous arthroplasties which I had performed,

Fig 5B —Regenerated fascia lata flaps dissected up showing smooth vastus muscle below

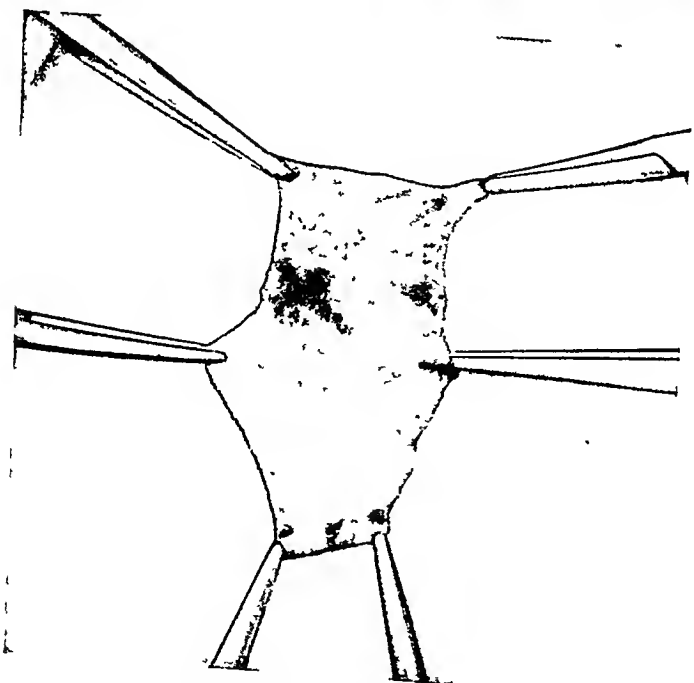

Fig 5C —Regenerated fascia lata specimen

for in so doing I had removed the fascia lata from both of his thighs. I explained my purpose in desiring to explore the thigh of the professor to determine what had occurred. He consented, and on Sept. 27, 1911, under local anesthesia, I made a three inch incision in the middle of the old twelve inch incision, and after freeing the subcutaneous fat I found a distinct, smooth, and firm fascia lata. By dissecting

Fig. 5D.—No herniation of the muscles, although all fascia lata was removed twelve years before.



Fig. 5E.—Cross section at right angles to the long axis of the thigh shows two distinct layers of fascia with collagenous fibrous tissue and adipose tissue. (E. W. Goodpasture) (×22.)

widely to either side the skin and subcutaneous fat off the fascia lata, I could visualize clearly an area of the fascia four inches by five inches. This fascia was incised longitudinally and the margins freed from the muscles in both directions (Figs. 5A and 5B). It was loosely attached to the thigh muscles as is fascia lata normally by fine trabeculations. It was three fourths as thick as a well developed layer of normal fascia lata and a sheet of this fascia doubled would have been excellent for arthroplasty, and could have been used singly in an emergency. (Fig. 5C). I have removed fascia lata for sutures in apparently normal patients in

whom the fascia lata was no thicker than the regenerated fascia lata in this case. There was no herniation of the muscles (Fig. 5*D*). Sections and photomicrographs of this specimen (Fig. 5*E*) show two distinct layers with their respective blood vessels and adipose tissue. Goodpasture notes that the stain with aniline blue shows the regenerated fascia is composed of collagenous fibrous tissue similar to, though not as dense as, that in normal fascia lata. He also makes the point that the specimen appears much more substantial grossly than microscopically.

COMMENT

Nothing can be found in the literature concerning what happens in the defect created by the removal of fascia lata. Gallie[3] makes the statement that one often wonders what the late effect may be of removing strips of fascia lata from the thigh, and admits that although he always sewed up the rent made by the removal of the living sutures, he could find no functional difference in his patients and those of his colleagues in whom the edges were not sutured together. He states that if the fascia is left open one can feel the edges widely separated, and there is a definite bulge of the vastus muscle through the opening, but there is no discomfort or noticeable loss of strength, and it does not seem to matter whether the fascia is closed or not. He makes no suggestions, however, as to the possibility of the regeneration of the fascia lata to fill the defect.

I have removed fascia lata from about 300 individuals. I have occasionally noticed a bulge of the vastus muscle for a few months, but after six months it has disappeared in every patient that I have been able to follow up.

As for the reason for this regeneration, none can be given except that of mechanical demand. Gratz[4] points out that while fibrous tissue is found in greater or lesser degree in all organs, it predominates in certain locations, and where support is the chief function, fascia develops. It would seem then that when fascia lata is removed and herniation of the muscle occurs, there is demand for more support, and the fascia lata regenerates in reply to this demand. The extent of the regeneration of fascia lata can best be determined by comparing photomicrographs of the regenerated fascia of Case 5 with normal fascia lata (Fig. 1), of J. M.

Kleinschmidt's histologic studies[5] on the free transplant of fascia lata of rabbits gives more light on what may happen in the way of fascia lata regeneration in man than anything I have read. He showed that normal fascia lata contains three distinct layers, each within its own sheath and its own blood vessels, and the three within a common denser sheath. The middle layer is the strongest and runs longitudinally. The inner and outer layers are weaker and their fibers run transversely at an angle of 90 degrees to those of the middle layer. This arrangement accounts for the fact that the greater tensile strength of fascia lata is lengthwise. Kleinschmidt also showed that if fascia lata was transplanted into a quadriceps defect with the thicker longitudinal fibers placed transversely to the long axis of the thigh muscles and the two

layers of transverse fibers were made to assume the longitudinal pull, then the two transverse layers at the end of three months grew in thickness and strength to the extent that they were like a tendon or aponeurosis, whereas the previously strong longitudinal fibers atrophied. He also showed that if a transplant of fascia lata was sutured into a quadriceps defect with the longitudinal fibers remaining lengthwise, those fibers at the end of three months became stronger resembling a tendon, whereas the transverse fibers almost disappeared. And by other experiments with rabbits he showed that if fascia lata was taken up and replaced in its normal position with the one layer of longitudinal fibers running longitudinally and the inner and outer layers transversely there would be no change at the end of three months in any of the layers.

In another treatise by Kleinschmidt[6] on the clinical application of free autoplastic fascia lata transplants in man, he utilizes to great advantage the information gained from his animal experiments in placing the fascia lata transplant so the stronger longitudinal fibers would be in proper position to take up the greater tension required of the transplant. He further stated that removal of fascia lata in the human being never left any functional defects, and besides, when any great amount was removed, as is often necessary in certain operative procedures, resuturing of its margins would be impossible. In some cases he noticed a temporary muscle bulge in the thigh which disappeared in a short while.

It will now be seen that the conclusions from Gratz's work on animals are similar to the conclusions reached by Kleinschmidt, also working on animals. And they explain in a measure the findings of the fascia lata regeneration of the cases in this report.

In Cases 2 and 3 the fascia lata margins at the time of operation were separated too much for approximation by suture, yet they approximated themselves by dense fibrous tissue formation in a fashion in order to form such a close line of union. It is my belief that the strong, longitudinal pull required of each fascia margin had a tendency in these slender muscular individuals to pull together as would the strings of a violin when made taut. We can liken it to the self-approximation which often occurs in the midline of the prethyroid muscles following partial thyroidectomy whether they are sutured together or not.

The explanation for the regeneration of fascia lata in the obese patient in which the fascia margins are further separated by the bulging vastus muscle is another story. And so it is with the fascia lata regeneration in the individual from whom all the fascia lata has been removed. This constitutes the most interesting part of the study. I believe it is the inner and outer transverse layers that regenerate. This seems reasonable in the light of the knowledge gained from Kleinschmidt's work, and from the study of the microscopic sections presented in this report. It would appear that the chief function of these two layers would be to reunite the separated fascia margins in Cases 1 and

4, but in Case 5 no explanation at this time seems feasible that would omit any layer. I hope in a future report to clear up some of these questions.

CONCLUSIONS

1. Fascia lata regenerates to fill the defect from where fascia is removed.

2. In the thin or slender well-muscled individual the fascia lata margins approximate to close the rent by rapid and thick formation of fibrous tissue which is in all probability derived from the inner and outer layers.

3. In the adipose patient the fascia margins retract further and perhaps for a short time allow a theorectical muscle herniation through the rent, but very soon the defect is filled by a new fascia lata one-half the thickness of the old fascia lata. This is thought to be the regeneration of the outer and inner layers of the true fascia lata. Further study will be made in a subsequent report.

4. When every iota of fascia lata is removed, new fascia lata of from one-half to two-thirds the thickness and tensile strength of the previous fascia lata regenerates to cover the whole area normally covered by fascia lata, and it may well be used again for fascia sutures and transplants.

5. This regenerated fascia lata serves all the purposes of true fascia lata in making a sleeve for the muscles and preventing herniation.

6. To know that fascia lata regenerates as shown here should encourage military surgeons to use fascia lata freely when needed in the great amount of reconstructive surgery that necessarily will be required for the injured men of our armed forces.

To Dr. E. W. Goodpasture I am indebted more than words allow me to express for his very valuable work in preparing these specimens. I am also deeply grateful to Dr. J. B. Wilkes of my staff who aided me in compiling information and bibliography.

REFERENCES

1. Gallie, W. E., and LeMesurier, A. B.: The Use of Living Sutures in Operative Surgery, Canad. M. A. J. 2: 505-513, 1921.
2. Gallie, W. E., and LeMesurier, A. B.: The Use of Free Transplants of Fascia as Living Sutures in the Treatment of Hernia, Arch. Surg. 9: 516-529, 1924.
3. Gallie, W. E.: Further Experiences with the Transplantation of Tendons and Fascia, Tr. West. S. A. 49, 1936.
4. Gratz, C. M.: Biomechanical Studies of Fibrous Tissues Applied to Fascial Surgery, Arch. Surg. 34: 461-495, 1937.
5. Kleinschmidt: Die freie autoplastische Faszientransplantation, Ergebn. d. Chir. u. Orthop. 8: 207-273, 1914.
6. Kleinschmidt: Experimentalle Untersuchungen über den histologischen Umbau der freie Lebensfaehigheit derselben unter Heranzienhung der vitalen Faerbung, Arch. f. klin. Chir. 104: 933-955, 1914.

layers of transverse fibers were made to assume the longitudinal pull, then the two transverse layers at the end of three months grew in thickness and strength to the extent that they were like a tendon or aponeurosis, whereas the previously strong longitudinal fibers atrophied. He also showed that if a transplant of fascia lata was sutured into a quadriceps defect with the longitudinal fibers remaining lengthwise, those fibers at the end of three months became stronger resembling a tendon, whereas the transverse fibers almost disappeared. And by other experiments with rabbits he showed that if fascia lata was taken up and replaced in its normal position with the one layer of longitudinal fibers running longitudinally and the inner and outer layers transversely there would be no change at the end of three months in any of the layers.

In another treatise by Kleinschmidt[6] on the clinical application of free autoplastic fascia lata transplants in man, he utilizes to great advantage the information gained from his animal experiments in placing the fascia lata transplant so the stronger longitudinal fibers would be in proper position to take up the greater tension required of the transplant. He further stated that removal of fascia lata in the human being never left any functional defects, and besides, when any great amount was removed, as is often necessary in certain operative procedures, resuturing of its margins would be impossible. In some cases he noticed a temporary muscle bulge in the thigh which disappeared in a short while.

It will now be seen that the conclusions from Gratz's work on animals are similar to the conclusions reached by Kleinschmidt, also working on animals. And they explain in a measure the findings of the fascia lata regeneration of the cases in this report.

In Cases 2 and 3 the fascia lata margins at the time of operation were separated too much for approximation by suture, yet they approximated themselves by dense fibrous tissue formation in a fashion in order to form such a close line of union. It is my belief that the strong, longitudinal pull required of each fascia margin had a tendency in these slender muscular individuals to pull together as would the strings of a violin when made taut. We can liken it to the self-approximation which often occurs in the midline of the prethyroid muscles following partial thyroidectomy whether they are sutured together or not.

The explanation for the regeneration of fascia lata in the obese patient in which the fascia margins are further separated by the bulging vastus muscle is another story. And so it is with the fascia lata regeneration in the individual from whom all the fascia lata has been removed. This constitutes the most interesting part of the study. I believe it is the inner and outer transverse layers that regenerate. This seems reasonable in the light of the knowledge gained from Kleinschmidt's work, and from the study of the microscopic sections presented in this report. It would appear that the chief function of these two layers would be to reunite the separated fascia margins in Cases 1 and

These reports indicate that renal failure from sulfonamides is not due necessarily to obstruction of the renal or ureteral channels by crystals but may be due to another factor which may be toxic in nature.

The measures used in the treatment of renal complications are the withdrawal of the drug, alkalinization, forcing of fluids, by mouth or parenterally, and local heat or diathermy to the kidneys. One should guard against allergy or hypersensitivity when using the drug. When these simple methods fail, the treatment has to be more drastic. It is then that ureteral catheterization is done for the purpose of washing out the concretions if present. However, when the renal complication is of the toxic type, the ureteral catheterization and washing of the kidney pelvis often does little if any good. It is in a case of this type that surgery offers the patient a chance of recovery, as it does in other cases of nephrosis which are reported.

Since the advocacy of decapsulation by Harrison, in 1896, and by Edebohls,[5] in 1898, a large number of cases in which decapsulation was performed has been reported. Many of these have been done for acute nephrosis with anuria. The causes of the nephrosis are many. The decapsulations have been unilateral and bilateral. At times a nephrotomy also has been done.

The following is a case history of a patient suffering from anuria, complicating the administration of sulfathiazole. The condition became desperate due to what appears to have been a "sulfa-nephrosis."

G. S., aged 44 years, was admitted to St. Louis City Hospital, March 1, 1943, with a chief complaint of inability to urinate. Two and one-half days previous to admission he was given sulfathiazole, 15 gr., every four hours, for an upper respiratory infection. Sixteen hours later he began to pass grossly bloody urine. He was passing only small quantities, and during the eighteen hours previous to admission he was unable to pass any urine.

The physical findings were negative essentially, except for a slight elevation of temperature, 101° F., and moderate tenderness over both kidneys. There was no muscle guard. The blood pressure was 142/90. A urethral catheter was introduced and only about 15 c.c. of grossly bloody urine obtained. It contained no crystals or organisms. The nonprotein nitrogen was 36 mg. per cent. The blood sulfathiazole concentration was 2.6 mg. per cent. X-ray diagnosis of the chest was negative. On the plain abdominal film the kidneys appeared moderately enlarged. Fluids were forced by mouth and parenterally. Alkalies were given and the patient began to vomit. March 3, 1943, his nonprotein nitrogen was 48 mg. per cent. Cystoscopy was done and ureteral catheters could not be passed. Ureteral meatotomies were done. Forcing of fluids was continued by mouth and parenterally. On March 4, 1943, carbon dioxide was 44 mg. per cent and nonprotein nitrogen 68 mg. per cent. The patient was vomiting everything and showing generalized edema. He was given a low spinal anesthetic, and attempts to catheterize the ureters again failed. They appeared to be edematous as were all other structures.

At 8:00 P.M. on March 4, 1943, a left renal decapsulation and nephrostomy were done since the illness was progressing rapidly. The tissues were markedly edematous

SULFATHIAZOLE TOXIC NEPHROSIS AND KIDNEY DECAPSULATION

CARL A. WATTENBERG, M.D., AND REESE C. COLEMAN, JR., M.D.
ST. LOUIS, MO.

(From the Department of Surgery, Urological Division, Washington University School of Medicine, and St. Louis City Hospital, St. Louis)

SINCE the extensive use of the sulfonamide drugs there have been many cases of renal complications, some of them resulting fatally. Reports of these fatal cases and also experiments carried out on rats and other animals seem to indicate that two types of renal changes occur.

In one type the renal changes are due to the drugs, causing concretions or precipitates. These crystals or concretions then produce a blocking of the renal tubules, the kidney pelvis, or the ureter. It is a common observation that a patient receiving a large dose of sulfathiazole or sulfadiazine may show no demonstrable renal complications, even when the urine shows a large deposit of crystals. It has been our experience that when blockage by crystals does occur, it usually occurs in the kidney pelvis which is of a "dysurie" type,[1] when the ureteral orifices are smaller than usual, or when some congenital or acquired malformation is present.

Various workers have failed to find crystals in kidneys removed at autopsy following death presumably due to the sulfonamides. Therefore, there must occur another renal change which produces the oliguria, anuria, and uremia complex which appears.

Prien and Frondel[2] report five autopsy cases following sulfathiazole therapy. In these, there was renal failure which could not be ascribed to the disease under treatment. Sections of the freshly removed kidneys were prepared by frozen section technique (a technique whereby there was no chance for solution and disappearance of crystals to take place). In three of these five cases, they failed to find crystals. Death in these three cases was not due to tubular obstruction by crystals, even though the patients died of uremia. The histologic changes which were present in these nephroses of kidneys not obstructed by crystals were degeneration, necrosis, and edema. These same changes also have been reported in other organs of the body following death from sulfathiazole.

Loewenburg, Sloane, and Chodoff[3] report a personal communication from H. F. Flippin to the effect that no uroliths were found in sixteen autopsies of patients receiving sulfathiazole. Long, Haviland, Edwards, and Bliss,[4] in their article on toxic manifestations of the sulfonamides, believe that anuria is due to a true toxic injury of the tubules, probably similar to that in mercury bichloride poisoning.

Received for publication, April 30, 1943.

REFERENCES

1. Rose, D. K., Hamm, W. G., Moore, S., and Wilson, H. M.: Kidney Pelves: Normal Variations in Their Shape and Flow With Possible Pathological Significance, Surg., Gynec. & Obst. 57: 1-14, 1933.
2. Prien, E. L., and Frondel, C.: Crystallography of the Urinary Sediments With Clinical and Pathological Observations in Sulfonamide Drug Therapy, J. Urol. 46: 748-758, 1941.
3. Loewenburg, S. A., Sloane, N. G., and Chodoff, P.: Urinary Calculi in the Kidneys, Ureters and Bladder, J. A. M. A. 115: 2069-2071, 1940.
4. Long, P. H., Haviland, J. W., Edwards, L. B., and Bliss, E. A.: The Toxic Manifestations of Sulfanilamide and Its Derivatives, J. A. M. A. 115: 364-368, 1940.
5. Edebohls, G. M.: Surgical Treatment of Bright's Disease, F. F. Lisiecki, New York, 1904.

and swollen in appearance. As the capsule was removed, the kidney was seen to expand in size. The kidney pelvis contained some blood. A nephrostomy tube was inserted. Within a few hours urine began to pass through the nephrostomy tube, and the dressings were saturated with urine. About twelve hours after operation the patient had passed about 500 c.c. through the nephrostomy tube and 200 c.c. through the urethral catheter. The subsequent urinary output was as follows: first 24-hour period, 1900 c.c. through the nephrostomy tube, 1750 c.c. through the urethral catheter; *second 24-hour period, 1500 c.c. through the nephrostomy tube,* 1800 c.c. through urethral catheter; third 24-hour period, 700 c.c. through the nephrostomy tube, 825 c.c. through the urethral catheter; fourth 24-hour period, 1475 c.c. through the nephrostomy tube, 1360 c.c. through the urethral catheter. The blood nonprotein nitrogen was 38 mg. per cent on March 6, 1943, 21 mg. per cent on March 8, and 22 mg. per cent on March 13.

The generalized edema subsided rapidly and had disappeared completely on the third postoperative day. The urethral catheter was removed on the fifth postoperative day and the nephrostomy tube removed on the sixth postoperative day.

An intravenous pyelogram on March 25 revealed a normal right kidney pelvis and ureter and a slight dilatation of the left kidney pelvis and calices. Each kidney appeared to have equal and good function. Intravenous pyelography was not done before surgery because of the danger of administering diodrast in an anuric patient, and because we felt it would not be excreted and thereby not add to our findings.

The patient was dismissed from the hospital on March 29, 1943, by which time the wound had healed satisfactorily.

Even though we feel convinced that the operation saved the patient's life in the preceding case, we do not mean to suggest that every patient with sulfa-nephrosis should be operated upon.

We do suggest, *however, that a patient suffering from acute sulfa-*nephrosis should not be allowed to die from anuria and uremia without renal decapsulation and nephrotomy having been tried. At least it should be tried if the patient is not relieved by ureteral catheters and forced fluids, or if ureteral catheters cannot be passed. If the decapsulation and nephrotomy are done early, before kidney damage is too marked and other tissue changes have taken place, a much better chance of recovery can be expected. Following this type of nephrosis there is a great intracapsular pressure which does decrease kidney function to a marked extent. The decapsulation relieves the pressure and edema, and then allows restoration of the cells and function to reoccur.

SUMMARY

1. A case of anuria in uremia caused by the action of sulfathiazole and relieved by unilateral decapsulation and nephrotomy is presented.

2. Anuria during sulfathiazole therapy can be due to a toxic nephrosis or due to tubular obstruction by crystals.

3. Decapsulation is indicated in those cases of sulfa-nephrosis not relieved by conservative measures.

necessary to insert a much finer needle through the bowel wall during intestinal suture to understand that this danger is almost nonexistant. We have seen no untoward effects following abdominal puncture in several hundred cases. In several patients operated upon immediately after tap, careful search has been made for bowel injury. None has been found. In many patients tapped but not operated upon there has been no suggestion of even a local peritonitis which one might expect if the bowel had been entered.

Illustrations of the importance of the information obtained without delay are from case records. The first four represent serious visceral injury without visible evidence of trauma to the abdominal wall.

C. A. (No. 42-3960), a 41-year-old woman, was driving her car when it was struck and overturned. On admission she complained of severe pain in the chest and abdomen. The systolic blood pressure was 90, the diastolic 60. Abdominal tap revealed free blood. She was operated upon immediately. A large actively bleeding rent in the liver was repaired.

In this instance there was doubt as to whether the primary injury was in the abdomen or in the thorax with referred abdominal pain. This question was readily answered.

J. P. (No. 42-4922), a 50-year-old man, was struck by an automobile. On admission he was in shock, unconscious, with bruises and abrasions over the head and extremities and a compound fracture of the right forearm. He improved but slightly after administration of plasma. Because of the sustained shock internal bleeding was suspected. Abdominal puncture was productive of frank blood. Operation revealed an extensive laceration of the mesentery.

In the absence of symptoms or signs a certain diagnosis of internal bleeding was made in an unconscious patient.

S. P. (No. 13821), a 32-year-old man, fell off a motor scooter at an amusement park. He had considerable pain in the left lower chest but his general condition was good. He showed no clinical evidence of internal hemorrhage until twelve hours later when he began to perspire and felt weak. Abdominal puncture in the left flank revealed blood, and a ruptured spleen was removed.

J. T. (No. 42-8973), a 71-year-old man, was knocked down by a truck. He was admitted complaining of severe pain in the abdomen. There was definite rigidity but no marks of trauma. A peritoneal tap was done and turbid yellow fluid was aspirated. Smears showed a few leucocytes and many bacteria. Immediate exploration disclosed a perforation of the sigmoid colon.

It is not always easy to tell whether visceral perforation or hemorrhage is present, but in the previous case the differential diagnosis was greatly simplified.

Not infrequently puzzling situations arise where there is not only a question as to the correct diagnosis but also as to the proper management. We have been able to answer some of these questions by abdominal puncture.

ABDOMINAL PUNCTURE AS A DIAGNOSTIC AID

CHARLES M. HENRY, M.D., AND C. FREMONT VALE, M.D., DETROIT, MICH.
(From the Department of Surgery, Wayne University College of Medicine and the Department of Surgery, Detroit Receiving Hospital)

THE value of abdominal puncture or paracentesis in the diagnosis and prognosis of intra-abdominal inflammatory conditions has been well described recently. Various investigators have reported it to be a reliable means of identifying the several types of peritonitis in children by the presence of bacteria in smears. Steinberg,[1] with an excellent review of these reports, advocated study of the peritoneal fluid obtained by aspiration as to cells, bacteria, and other substances. With the information obtained from a single smear he has been able to differentiate the irritative from the infectious processes of the peritoneum, and to establish the prognosis with some accuracy. Hill, O'Loughlin, and Stoner[2] demonstrated that in experimental obstruction in dogs, strangulation could be diagnosed within four hours after onset by the aspiration of characteristic reddish brown fluid from the peritoneal cavity. Our experience fully supports the importance of this procedure in the presence of peritoneal inflammation.

Neuhof and Cohen,[3] in 1926, reported the use of abdominal puncture not only for inflammatory conditions but also for the diagnosis of internal injury following trauma. Since that time a number of articles have been written on visceral damage following nonpenetrating injury to the abdomen but we have found only one reference to diagnostic puncture. Wright and Prigot[4] employed it in fifteen cases of ruptured spleen with positive findings in thirteen. They believe it is inexcusable to omit this diagnostic procedure where intra-abdominal complications are suspected. Since this is the type of patient in which it is of greatest value, abdominal tap deserves a great deal more attention in emergency cases where prompt and correct decision so often is the margin between life and death.

The technique is very simple. The site for puncture is chosen according to clinical impression. For example, if a ruptured spleen is suspected a tap is made in the upper left quadrant. Novocain infiltration is carried down to the peritoneum, and through this area an 18 gauge needle is slowly introduced into the peritoneal cavity. Fluid, if present, is aspirated by syringe. Negative findings in one area do not preclude positive results at another point.

At first thought it is natural to fear pushing the needle into the bowel. One has only to remember that force and counter pressure are

Received for publication, March 23, 1943.

procedure. We believe it should be employed in any case in which fluid of any type is suspected even if not clinically demonstrable. In known or suspected nonpenetrating abdominal trauma the examination is not considered complete without a tap. The finding of free blood has led to the removal of several ruptured spleens at an early hour, which otherwise possibly would have been recorded as delayed rupture, and with a definitely higher mortality rate.

It is particularly of value in cases where the diagnosis is in doubt and where time is a factor. Thus, if blood is obtained from the abdominal cavity, other time-consuming procedures such as hematocrit or specific gravity determinations to differentiate shock from hemorrhage may be eliminated. Furthermore, we have found that a sample of aspirated fluid may convince the patient as well as the surgeon of the necessity for immediate operation. It is so strikingly enlightening at times that one might paraphrase Deaver's aphorism about the scalpel and say "the aseptic needle dispels the mystery and reveals the truth."

SUMMARY

Diagnostic abdominal puncture is a safe, simple, and often valuable procedure, particularly for the rapid appraisal of nonpenetrating abdominal injuries as well as other acute surgical conditions within the peritoneal cavity. Several illustrative cases are cited.

REFERENCES

1. Steinberg, B.: Peritoneal Exudate, J. A. M. A. 116: 572, 1941.
2. Hill, F. C., O'Loughlin, B. J., and Stoner, M.: Peritoneal Aspiration in the Diagnosis of Strangulated Bowel, Surg., Gynec. & Obst. 74: 121, 1942.
3. Neuhof, H., and Cohen, I.: Abdominal Puncture in the Diagnosis of Acute Intraperitoneal Disease, Ann. Surg. 83: 454, 1926.
4. Wright, L. T., and Prigot, A.: Traumatic Subcutaneous Rupture of the Normal Spleen, Arch. Surg. 39: 551-576, 1939.

E. H. (No. 9148), a 39-year-old woman, was admitted with a history of abdominal pain and vomiting for one day. Because of moderate abdominal distention and intermittent bowel sounds a diagnosis of intestinal obstruction was considered. Abdominal puncture was productive of frank blood. On closer questioning a fair history was obtained for ruptured ectopic pregnancy, which was found at operation.

B. H. (No. 42-7900), an asthenic man, 36 years old, had severe abdominal pain with radiation to the left shoulder for twelve hours before admission. There had been pain in the upper abdomen after meals for two years and weight loss for several weeks. A barium study one week before admission indicated duodenal ulcer. The abdomen was rigid. On abdominal puncture, free blood was withdrawn. Operation revealed a primary carcinoma of the left lobe of the liver which had bled spontaneously.

K. D. (No. 41-12824), an obese 40-year-old woman, was admitted complaining of severe abdominal pain for about one hour. There had been intermittent pain in the right upper quadrant for a month previous. On admission she was sweating freely and had a diffusely tender abdomen. Peritoneal aspiration produced turbid brown fluid which on microscopic examination was seen to contain cholesterol crystals. A tensely swollen acutely inflamed but unruptured gall bladder was found at operation.

A. W. (No. 42-8085), a 47-year-old woman, had a history of repeated abdominal swelling for one year with attacks of pain and vomiting characteristic of biliary colic. On admission abdominal puncture was done and fluid containing bile and cholesterol crystals was withdrawn. Because of her poor condition operation was deferred. Exploration three weeks later revealed a subhepatic collection of "white" bile and a thick-walled gall bladder containing normal appearing bile but no calculi. There was no evidence that gross perforation had occurred.

W. S. (No. 42-15010), an emaciated elderly man, suffered pain in the abdomen for four days. This had become somewhat worse on the day of admission. The right side of the abdomen was rigid and there were findings suggestive of pneumonia in the right lung. Aspiration in the right lower quadrant revealed viscid pale yellow fluid typical of that seen following perforation of a peptic ulcer. A ruptured gastric ulcer was found at operation.

P. T. (No. 41-18115), a 30-year-old woman, was shot through the abdomen. At operation extensive intestinal injury was repaired. There was a retroperitoneal hematoma on the left side but exploration of this region was not thought to be justified. Five days later abdominal swelling developed to the left of the midline. Aspiration yielded blood-tinged fluid which was unmistakably urine.

DISCUSSION

These few cases are briefly reported to indicate some of the uses of this simple procedure. It should be emphasized that it is only an aid in diagnosis and should be interpreted as a part of the clinical examination. Positive data are significant but "dry" taps must usually be considered as meaningless. It is often repeated in such instances. If sufficient indications for operation are present a negative tap should be disregarded.

We have no accurate figures as to the frequency with which abdominal puncture is done but a conservative estimate would be over one hundred times a year, enough so that we consider it almost a routine

the subcutaneous region. Two weeks later the proximal end of the loop was opened so that a gastric (pyloric) fistula resulted. Owing to the direction of peristalsis in the intestinal loop, no leakage of the gastric contents occurred.

The animals were ready for observation after healing of the wound. They were fasted for twenty-four hours before each experiment. Samples of gastric contents were withdrawn by introduction of a well-lubricated rubber catheter to a marked length, so that the tip just protruded into the stomach. This insured the withdrawal of only the gastric contents as they are about to leave the stomach. This is important, since samples of gastric juice obtained from the cardiac and the pyloric regions of the stomach show a difference of acidity.[11]

Two specimens of about 5 c.c. each were withdrawn from the stomach with the animal in the fasting state. The animal was then fed a standard meal of 200 Gm. of canned meat with 250 c.c. of water. Specimens were drawn subsequently, about 5 c.c. each, every fifteen minutes for eight hours or more. On an average, thirty specimens were collected daily from each dog, for several days, so that estimations of pH were made on 400 to 500 specimens, to serve as control for each dog.

The determination of pH was made by using Northrup's potentiometer with quinhydrone oxidation-reduction potential.

Following a period of rest of two weeks or more after the control study, the duodenum was isolated by sectioning proximally at the pyloroduodenal juncture (which point was just distal to the gastric opening of the pyloric fistula) and distally about 10 cm. beyond the duodenojejunal junction. The proximal end of the duodenum was closed by inversion of the stump. The distal end of the duodenojejunal loop was anastomosed to an opening made high in the fundic region of the stomach by an end-to-side or side-to-side anastomosis (Fig. 1). The gastrointestinal continuity was maintained by a modified type of Polya anastomosis between the cut ends of the pyloris and the jejunum. Particular care was taken to prevent excision of any part of the gastrointestinal tract, in order to insure as much physiologic integrity as possible.

The studies were not begun until after complete recovery of the animal, as evidenced by its regaining a normal appetite and normal weight. The specimens were then collected, as in the control procedures, from the stomach in the fasting state and every fifteen minutes from the stomach during digestion, for eight hours or more after the feeding. As in the controls, determinations of pH were made on 400 to 500 specimens, after the duodenal contents had been drained into the stomach. (To avoid frequent repetition of a lengthy phrase, the term "duodenal drainage" is used in this communication to indicate the drainage of duodenal contents into the fundic region of the stomach.)

THE INFLUENCE OF DUODENAL CONTENTS ON INTRAGASTRIC ACIDITY

An Experimental Study*

Authi Kesavalu, M.D.,† and Frank C. Mann, M.D.‡
Rochester, Minn.

THE view that duodenal regurgitation is essential or important for the reduction of gastric acidity has been presented by Boldyreff[4, 5] and others.[1, 2, 6, 10, 20, 22, 25, 27] MacLean and Griffiths and others[3, 9, 13, 21] have opposed this view and have held that duodenal regurgitation is not an important factor in the reduction of gastric acidity.

It appears true that duodenal regurgitation is a physiologic process which occurs at variable but unpredictable intervals during the gastric cycle. There is a difference of opinion on the extent to which duodenal regurgitation normally decreases the acidity of the gastric contents. McCann[16, 17] did not find any difference of gastric acidity after draining the duodenal contents into and away from the stomach, while Wilhelmj, O'Brien, McCarthy, and Hill obtained contrary results. Wilhelmj, O'Brien, and Hill noted the reduction of acidity of whole stomach pouches when acid was introduced into them. Goldberg noted reduction of acidity of isolated stomach pouches, into which duodenal regurgitation could not occur.

The objective of the present study was to attempt to ascertain the significance of regurgitation of the duodenal contents in neutralizing intragastric acidity by drainage of the duodenal contents into the stomach.

METHOD

Two series of experiments on healthy dogs ranging in weight from 8 to 12 kg. were performed. All operative procedures were performed with the animals under ether anesthesia and aseptic technique was used. In one series, a fistula of the reverse intestinal loop type[19] was made. A loop of the distal portion of the ileum 12 cm. long with its blood supply intact was isolated, the continuity of the bowel being maintained by an end-to-end or side-to-side anastomosis. The distal end of the isolated loop was anastomosed to an opening made just proximal to the pyloric orifice and the proximal end of the loop was brought out through a stab wound to the right of the midline and anchored in

Received for publication, April 2, 1943.

*Portion of thesis submitted by Dr. Kesavalu to the Faculty of the Graduate School of the University of Minnesota in partial fulfillment of the requirement for the degree of M.S. in Experimental Surgery.

†Fellow in Experimental Surgery.
‡Division of Experimental Medicine, Mayo Foundation.

In the second series of experiments we made an isolated fundic pouch, which was drained externally by a self-retaining soft rubber catheter brought out through a left subcostal stab wound (Fig. 2).

After recovery, the secretions of the entire pouch were collected at three, six, and twenty-four hours after each meal. The dog was fasted for twenty-four hours before the standard meal was given. The quantity, pH, and free and total acidity of all the samples were determined. Free acidity was determined by titration with one-tenth normal solution of sodium hydroxide. Töpfer's reagent being used as the indicator, and the total acidity by continuing the titration with phenolphthalein as the indicator. The titration values are expressed as clinical units.

Control readings were obtained for several weeks and then the duodenum was drained into the upper part of the fundic region of the stomach, as previously described. After recovery of the animal, the studies were continued exactly similarly to those of the control series.

RESULTS

Complete studies were obtained on five dogs that had a pyloric fistula and on three dogs that had a fundic pouch. In all eight cases the internal duodenal drainage into the fundic region of the stomach was successfully performed.

A. *Internal Duodenal Drainage Into the Stomachs of Dogs That Had a Pyloric Fistula.*—We obtained several hundred determinations of pH of specimens collected every fifteen minutes, before and after duodenal drainage.

Gastric acidity in the fasting state: The control studied showed that the secretion in the resting stomach was clear and of small quantity, was often intimately mixed with abundant mucoid secretion, rarely contained any bile, and was of moderate acidity or very infrequently neutral or slightly alkaline. The presence of mucous did not appear to alter the acidity of the gastric contents materially, although when the secretion was extremely scanty and viscid, acidity was low. The acidity was not any lower than usual when bile-stained fluid was obtained, as infrequently occurred.

After duodenal drainage, the volume of the contents of the resting stomach was definitely increased. Every specimen was invariably bile-stained, which was considered as proof of the patency of the anastomosis between the duodenojejunum and the stomach. In spite of the minimal secretion of acid of the resting stomach and the presence of the alkaline duodenal contents which are being constantly secreted and evacuated into the stomach, it is noteworthy that the acidity of the fasting stomach was not reduced to any marked extent.

Gastric acidity during digestion: During the eight-hour periods of observation after feeding, a comparative study of the gastric acidity before and after drainage of the entire duodenal contents into the

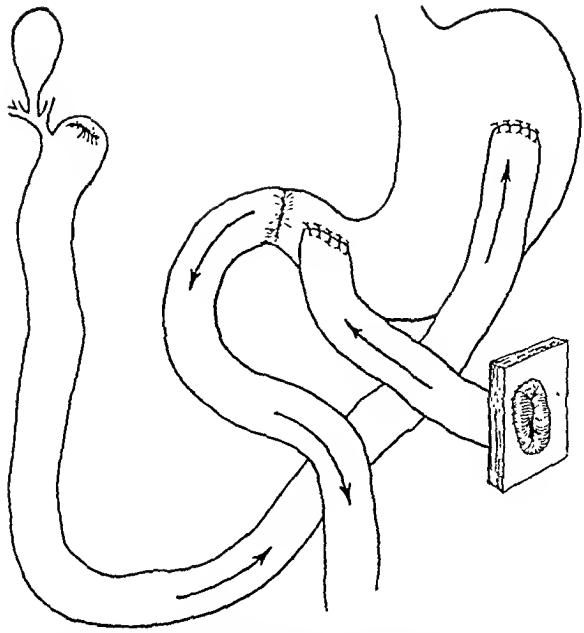

Fig. 1.—Drainage of duodenal contents into fundic region of stomach with rever intestinal loop fistula in pyloric region.

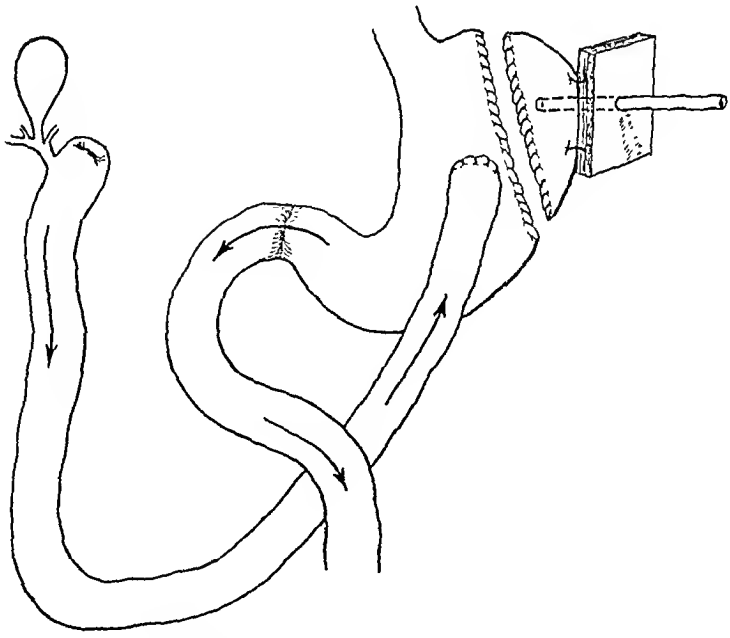

Fig. 2.—Drainage of duodenal contents into fundic region of stomach after an isolated fundic pouch has been made.

TABLE I

pH OF GASTRIC CONTENTS

TYPICAL pH VALUES BEFORE AND AFTER DUODENAL DRAINAGE, FROM FIVE DOGS THAT HAD PYLORIC FISTULAS

TIME AFTER FEEDING (HR.)	CONTROLS					AFTER DUODENAL DRAINAGE				
	DOG 1 3/7/40	DOG 2 12/13/39	DOG 3 5/24/40	DOG 4 3/23/40	DOG 5 12/19/39	DOG 1 9/16/40	DOG 2 3/21/40	DOG 3 10/23/40	DOG 4 6/14/40	DOG 5 4/24/40
Fasting	5.56	6.12	6.97	6.91	4.47	2.41	4.95	5.10	4.32	1.73
1	3.76	2.65	3.87	3.49	3.38	3.88	2.71	3.85	4.35	4.63
2	3.21	2.19	3.99	4.83	2.38	2.39	2.71	3.27	4.05	3.70
3	2.81	2.26		4.83	2.33	1.97	2.23	3.05	3.73	1.78
4	3.43	2.58	3.71	4.26	1.97	2.00	2.49	3.15	3.48	1.32
5	3.69	2.71	2.95	3.35	1.95	2.70	2.31	3.32	3.24	1.44
6	2.18	2.22	3.30	2.07	1.80	2.17	1.85	3.48	2.81	1.34
7	2.12	2.07	2.87	2.07	1.93	2.12	1.99	3.09	2.05	1.44
8	2.09	2.26	3.10	2.62	1.85	1.56	1.92	2.73	1.95	1.52

TABLE II

pH RECORD*

DOG	GASTRIC CONTENTS IN FASTING STATE				GASTRIC CONTENTS DURING EIGHT HOURS AFTER FEEDING			
	CONTROL		AFTER DUODENAL DRAINAGE		CONTROL		AFTER DUODENAL DRAINAGE	
	LOWEST PH	HIGHEST PH	LOWEST PH	HIGHEST PH	LOWEST PH	HIGHEST PH	LOWEST PH	HIGHEST PH
1	1.52	6.65	1.53	3.17	1.66	5.67	1.48	5.52
2	1.47	6.49	1.88	6.29	1.54	3.11	1.83	3.97
3	2.32	7.63	2.95	6.32	1.97	6.68	2.59	4.39
4	3.33	6.91	3.05	5.20	1.81	5.52	1.89	5.32
5	1.88	4.47	1.65	3.71	1.48	3.28	1.32	4.63

*Lowest and highest in all the dogs of this series (that had pyloric fistula) during the entire period of study, before and after duodenal drainage.

stomach showed that there was not a marked reduction of gastric acidity. In two dogs higher levels of acid were obtained after duodenal drainage than before, while in three animals the maximal level of acid after duodenal drainage was slightly lower than the control values. The minimal level of acid of the gastric contents after duodenal drainage was higher in three dogs and lower in two dogs than the control values. All the samples were intensely bile-tinged and showed the presence of bile by the usual chemical tests. There was a tendency for the stomach to evacuate more rapidly after duodenal drainage than in the controls. There was no extreme variation of acidity of the gastric contents after duodenal drainage as in the controls, moderately high acidity within narrow ranges being maintained (Fig. 3 and Tables I and II).

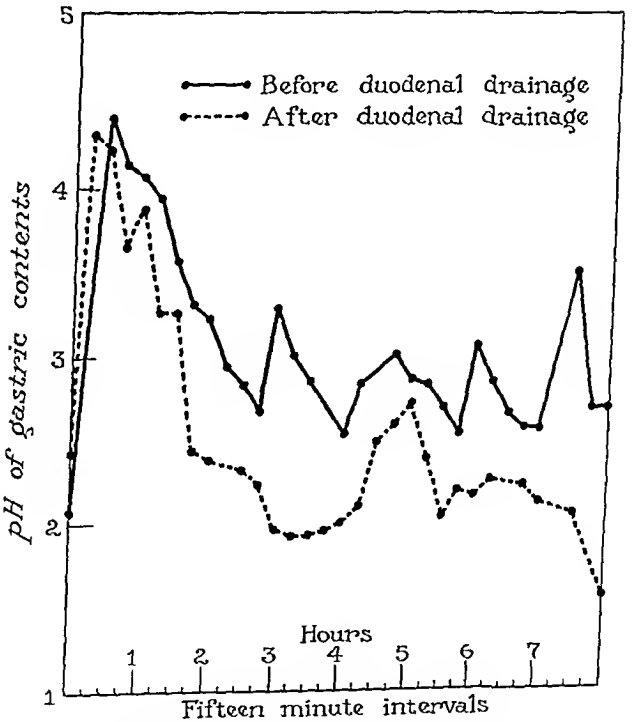

Fig. 3.—Showing pH of gastric contents before and after duodenal drainage into the stomach.

B. *Internal Duodenal Drainage Into the Stomach of Dogs That Had an Isolated Fundic Pouch.*—The quantity of secretion of three-, six-, and twenty-four-hour specimens from the fundic pouches was definitely greater in all three dogs after duodenal drainage than in the control period. In one dog the total secretion for twenty-four hours after duodenal drainage was twice, and on some days even three or four times, the secretion before duodenal drainage. In all the dogs that had iso-

lated fundic pouches the free and total acidities in three- and twenty-four-hour secretions of the pouch were definitely higher after duodenal drainage than before. The maximal acid levels, as determined by pH, were higher after duodenal drainage than those of the controls. The conspicuous feature was the qualitative (acid) and quantitative augmentation of the secretion of the pouch, which was long sustained after duodenal drainage. In the control experiments, there was a tendency of the gastric acidity to reach a very low level in the twenty-four-hour specimens, whereas after duodenal drainage, the acidity was maintained at a high level. This augmented and long-sustained gastric acidity, as measured by the miniature stomach, would appear to have been due to the presence of the duodenal contents in the stomach or the lack of them in the intestine (Fig. 4 and Table III).

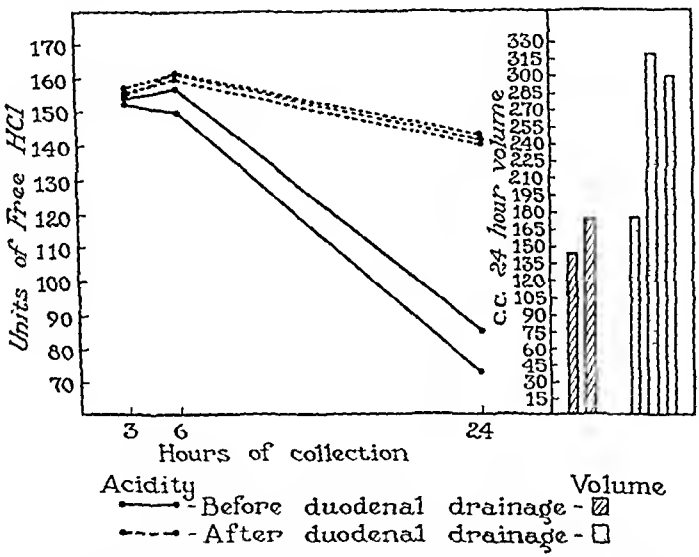

Fig. 4.—Free acidity of secretion of fundic pouch before and after duodenal drainage into the stomach. Each curve is an average for two weeks.

COMMENT AND SUMMARY

An attempt has been made to evaluate the neutralizing capacity of the duodenal contents on the acidity of the gastric contents, with a view to ascertain the role played by duodenal regurgitation in controlling gastric acidity under physiologic conditions.

Two groups of dogs were chosen for study. One group had gastric (pyloric) fistulas and the other had isolated fundic pouches. The duodenum was short-circuited into the fundic region of the stomach in both groups of dogs so that all the duodenal contents passed into the stomach. No attempt was made to determine if the quantity and quality of the duodenal contents were normal under the conditions of the experiments.

TABLE III

SECRETION OF ISOLATED FUNDIC POUCH BEFORE AND AFTER DUODENAL DRAINAGE*

AVERAGE FOR TWO WEEKS	DOG	3 HOURS			6 HOURS			24 HOURS			TOTAL QUANTITY FOR 24 HOURS (C.C.)
		QUANTITY (C.C.)	FREE ACID	TOTAL ACID	QUANTITY (C.C.)	FREE ACID	TOTAL ACID	QUANTITY (C.C.)	FREE ACID	TOTAL ACID	
Control	6	27	112	120	23	150	158	42	104	108	92
	7	26	129	136	65	156	160	98	140	146	189
	8	51	153	160	58	150	162	34	73	81	143
After duodenal drainage	6	35	152	158	28	152	160	54	119	116	117
	7	44	160	167	83	157	161	170	153	160	297
	8	71	155	165	73	161	168	174	142	151	318

*Typical average values from three dogs.

8. Boyd, T. E.: The Influence of Alkalies on the Secretion and Composition of Gastric Juice. I. The Effect of the Prolonged Administration of Sodium Bicarbonate and Calcium Carbonate. II. The Effects of Single Doses of Sodium Bicarbonate and Calcium Carbonate, Am. J. Physiol. 71: 455-471, 1925.
9. Carlson, A. J.: Contributions to the Physiology of the Stomach. XXI. The Supposed Action of the Bitter Tonics on the Secretion of Gastric Juice in Man and Dog, J. A. M. A. 64: 15-17, 1915.
10. Catheart, E. P.: Reflux From Intestine to Stomach, J. Physiol. 42: 433-438, 1911.
11. Engelbach, Friedrich, and Brown, C. L.: Variations in Volume and in the Acid Content of Gastric Secretion of Normal Individuals Following Stimulation by Histamine, Ann. Int. Med. 6: 1560-1564, 1933.
12. Goldberg, S. L.: Intrinsic Regulation of Gastric Acidity, Arch. Int. Med. 49: 816-825, 1932.
13. Hicks, C. J., Jr., and Visher, J. W.: Contribution to the Physiology of the Stomach. XXVII. The Mechanism of Regurgitation of Duodenal Contents Into the Stomach, Am. J. Physiol. 39: 1-8, 1915.
14. Kantor, J. L.: Antacid Gastric Therapy, With Special Reference to the Use of Neutral Antacids, J. A. M. A. 81: 816-818, 1923.
15. Kesavalu, Authi: Unpublished data.
16. McCann, J. C.: Studies on the Control of the Acidity of the Gastric Juice, Am. J. Physiol. 89: 483-496, 1929.
17. McCann, J. C.: Experimental Peptic Ulcer, Arch. Surg. 19: 600-659, 1929.
18. MacLean, Hugh, and Griffiths, W. J.: The Factors Influencing the Concentration of Hydrochloric Acid During Gastric Digestion, J. Physiol. 65: 63-76, 1928.
19. Mann, F. C., and Bollman, J. L.: A Method for Making a Satisfactory Fistula at Any Level of the Gastro-intestinal Tract, Ann. Surg. 93: 794-797, 1931.
20. Orndoff, B. H.: Reverse Movement in the Contents of the Duodenum and Its Probable Significance, Illinois M. J. 55: 406-408, 1929.
21. Shay, Harry, Katz, A. B., and Schloss, E. M.: Experimental Studies in Gastric Physiology; Evaluation of the Role of Duodenal Regurgitation in the Control of Gastric Acidity in Man (Boldyreff theory), Arch. Int. Med. 50: 605-620, 1932.
22. Spencer, W. H., Meyer, G. P., Rehfuss, M. E., and Hawk, P. B.: Gastro-intestinal Studies. XII. Direct Evidence of Duodenal Regurgitation and Its Influence Upon the Chemistry and Function of the Normal Human Stomach, Am. J. Physiol. 39: 459-479, 1916.
23. Wangensteen, O. H., Varco, R. L., Hay, Lyle, Walpole, Stewart, and Trach, Benedict: Gastric Acidity Before and After Operative Procedure With Special Reference to the Role of the Pylorus and the Antrum; a Preliminary Report of a Clinical and Experimental Study, Ann. Surg. 112: 626-667, 1940.
24. Wilhelmj, C. M., Henrich, L. C., and Hill, F. C.: The Influence of Duodenal Secretions on Acid Gastric Contents, Am. J. Physiol. 111: 293-304, 1935.
25. Wilhelmj, C. M., Neigus, Irwin, and Hill, F. C.: A Comparison of Intragastric and Duodenal Factors in Lowering the Acidity of Gastric Contents, Am. J. Physiol. 107: 490-507, 1934.
26. Wilhelmj, C. M., O'Brien, F. T., and Hill, F. C.: The Inhibitory Influence of the Acidity of the Gastric Contents on the Secretion of Acid by the Stomach, Am. J. Physiol. 115: 429-440, 1936.
27. Wilhelmj, C. M., O'Brien, F. T., McCarthy, H. H., and Hill, F. C.: The Role of the Duodenal Secretions in the Prevention of Experimental Jejunal Ulcer, Am. J. Physiol. 117: 79-85, 1936.

Gastric samples were collected from the first group of animals through the pyloric fistula every fifteen minutes for eight hours or more while the animals were fasting and after feeding, and the pH of the samples was determined electrometrically.

The secretion from the fundic pouch in the second group of animals was collected three, six, and twenty-four hours after feeding, the quantity was noted, and the free and total acidities were determined titrimetrically.

The results showed that duodenal regurgitation into the stomach, as determined by the presence of visible bile, occurs infrequently in the fasting state as well as during digestion. Its presence was not associated, however, with alterations of the acidity curve of the gastric contents.

After the entire duodenal contents had been diverted into the stomach, some dogs that had pyloric fistulas showed an increase of gastric acidity while others showed some reduction, although not marked. The gastric evacuation time was definitely decreased after gastrojejunostomy (modified Polya), which was a part of the operative procedure in duodenal drainage. This, in itself, might have contributed in no less degree to the reduction of gastric acidity noted in some animals (Wangensteen and co-workers). Effective neutralization or inhibition of the acid secretion never occurred.

In the dogs that had isolated fundic pouches, short-circuiting of the duodenal contents into the stomach was followed by an increase of the quantity and the acidity of the gastric secretion.[24] This result is similar to the augmented gastric secretion that occurs when alkalies are administered orally.[8, 14, 15, 24]

The results of these experiments would appear to demonstrate that the presence of even the entire duodenal contents in the stomach does not cause effective neutralization, buffering, and dilution of gastric acidity in either the fasting or the digesting state. It is questionable if the slight and infrequent duodenal regurgitation that occurs normally can be a primary and essential factor in controlling intragastric acidity.

REFERENCES

1. Apperly, F. L.: Duodenal Regurgitation and the Control of the Pylorus, Brit. J. Exper. Path. 7: 111-120, 1926.
2. Babkin, B. P.: The Physiological Factors Determining the Acidity of the Gastric Juice and of the Gastric Contents, Canad. M. A. J. 17: 36-42, 1927.
3. Baird, M. McC., Campbell, J. M. H., and Hern, J. R. B.: The Importance of Estimating Chlorides in the Fractional Test Meal Samples, and Some Experiments With the Duodenal Tube, Guy's Hosp. Rep. 74: 23-53, 1924.
4. Boldyreff, W.: Der Übertritt des natürlichen Gemisches aus Pankreassaft, Darmsaft und Galle in den Magen, Arch. f. d. ges. Physiol. 121: 13-53, 1907.
5. Boldyreff, W.: The Self-Regulation of the Acidity of the Gastric Contents and the Real Acidity of the Gastric Juice, Quart. J. Exper. Physiol. 8: 1-12, 1915.
6. Bolton, Charles, and Goodhart, G. W.: The Role of Duodenal Regurgitation in the Automatic Regulation of the Gastric Acidity, J. Physiol. 87: 360-387, 1936.
7. Bolton, Charles, and Salmond, R. W. A.: Antiperistalsis of the Duodenum and Its Relation to Pyloric Regurgitation, Lancet 1: 1230-1232, 1927.

ease has been found to have cerebellar cysts, and involvement of the cerebrum also has been reported by Rochat. Cushing and Bailey believed the intracranial growths to be true tumors or hemangioblastomas of a type that exudes plasma with the formation of cysts which at times have xanthrochromic contents. The familial tendency is common and Rochat reported the appearance of the disease in three generations.

Angiomatosis retinae is bilateral in 50 per cent, leads to degenerative changes with retinal detachment and usually a secondary glaucoma. Apparently metastasis does not occur from the retinal growths, but the exudative tendencies may lead to a choroidal retinitis, frequently with complete loss of vision. Because of their peripheral position, or other cause, the retinal growths may escape observation, as in the case mentioned by Cushing, in which at least eight observers had failed on ophthalmic examination to find an angioma. Rochat believes the disease to begin in the retina as a hypertrophy of an angiomatous capillary which is followed by hyaline degeneration of the capillary walls with development of gliomatous and connective tissue and secondary detachment of the retina. These angiocystic diseases occur most commonly in patients between the ages of 10 and 30 years and are rare after 50. A coincidental hypernephroma of the kidney or von Recklinghausen's disease has been reported. The cystic involvement of the pancreas rarely is prominent, usually gives rise to no symptoms, and is discovered as an unexpected post-mortem finding, frequently so microscopic as to be revealed only on histologic study. The lesions of Lindau's disease have been designated by various descriptive terms, such as hemangioblastic cysts, angiomatosis, hemangio-endothelioma, hemangioblastoma, angiomatosis retinae, hyperplastic capillary hemangioma, cystosarcoma of the pia mater, gliosarcoma, angiosarcoma, cystic cystoglioma, angiospindle-cell sarcoma, secondary sarcoma, cysts of the kidney, pancreas, and suprarenal gland.

Because cystic angiomatous disease of the pancreas repeatedly has been associated with the vascular cerebellar cysts of Lindau and the angiomatosis of the retina of von Hippel, we have attempted to determine whether it is different from the case to be reported. In this patient the entire pancreas finally was destroyed by the progressive development of multiple cysts and vascular caverns of large size, unassociated with retinal changes, neurologic evidences of space-taking intracranial lesion, or the histology of malignant disease. The findings in the case suggest a rare destructive lesion of the pancreas differing from the small or microscopic cysts found in the organ in Lindau's or von Hippel's disease. In size and angiocystic qualities the lesions resembled the cerebellar growths described by Lindau. The pathologic process was largely a rapid proliferation of new blood vessels lined by one or more layers of flattened or cuboidal endothelial cells, with frail walls of poorly developed fibroconnective tissue and little collagen, which evidently expanded or ruptured under the influence

DESTRUCTIVE ANGIOCYSTIC DISEASE OF THE PANCREAS

W. WAYNE BABCOCK, M.D., MACHTELD E. SANO, M.D., PHILADELPHIA, PA. AND STUART B. GIBSON, M.D., WILLIAMSPORT, PA.

(From the Surgical and Pathological Departments of Temple University, Philadelphia)

ARVID LINDAU, of Lund, Sweden, from a study of all cases of cerebellar cysts reported in the literature during the previous twenty years, together with sixteen of his personal cases, demonstrated, in 1926, the tendency for hemangiomatous cerebellar cysts to be hereditary and to be associated with the angiomatosis of the retina, described by von Hippel in 1904 (von Hippel's disease), as well as cystic disease of the medulla, spinal cord (syringomyelia, syringobulbia), pancreas, kidneys, liver, suprarenal glands, and epididymis. The cerebellar cysts contained angiomatous channels separated by sheets or strands of cells which Lindau termed pseudoxanthomatous. Of the associated abnormalities in the abdominal organs, cystic degeneration of the pancreas was the most frequent. The association of the angiomatous cerebellar tumors with a cystic pancreas had been noted previously by Berblinger, in 1922, and by his pupil Ledebur, in 1926.

In 1930, in a lecture given in London, Lindau said that "the cystic pancreas is, in adults, almost pathognomonic for the syndrome," but added, "these abdominal lesions associated with capillary angiomatoses are not *themselves* vascular, as far as I have observed." Putshar, in 1935, made a similar comment regarding the nonvascular nature of the visceral lesions. In a careful review of the literature it appears that angioma of the pancreas is a rare finding. Isolated cysts of the pancreas are by no means uncommon, but actual destructive cystic disease of the organ is definitely unusual. In a case reported by McKechnie and Priestley the possibility of Lindau's disease was suggested by the pathologist, but the authors were unable to confirm the diagnosis clinically.

Busni, in 1928, described what he believed to be the first recorded case of an angioma of the pancreas of arterial origin. This was studied carefully and the illustrations are convincing. He wrote that he had reviewed the Russian literature as well as the general foreign literature on both pathology and anatomy without finding any reference to a *similar* case. Ten years later Ranström, in 1939, reported a case of venous angioma of the pancreas and emphasized the rarity of such vascular tumors in that organ. To these cases should be added two others, those of Sajewloschin and Querneau, in which the lesions were angiomas histologically. Lymphangiomas and hemangio-endotheliomas, but without generalized cystic degeneration, also have been described. About one of four or five patients with von Hippel's dis-

Received for publication, April 5, 1943.

ease has been found to have cerebellar cysts, and involvement of the cerebrum also has been reported by Rochat. Cushing and Bailey believed the intracranial growths to be true tumors or hemangioblastomas of a type that exudes plasma with the formation of cysts which at times have xanthrochromic contents. The familial tendency is common and Rochat reported the appearance of the disease in three generations.

Angiomatosis retinae is bilateral in 50 per cent, leads to degenerative changes with retinal detachment and usually a secondary glaucoma. Apparently metastasis does not occur from the retinal growths, but the exudative tendencies may lead to a choroidal retinitis, frequently with complete loss of vision. Because of their peripheral position, or other cause, the retinal growths may escape observation, as in the case mentioned by Cushing, in which at least eight observers had failed on ophthalmic examination to find an angioma. Rochat believes the disease to begin in the retina as a hypertrophy of an angiomatous capillary which is followed by hyaline degeneration of the capillary walls with development of gliomatous and connective tissue and secondary detachment of the retina. These angiocystic diseases occur most commonly in patients between the ages of 10 and 30 years and are rare after 50. A coincidental hypernephroma of the kidney or von Recklinghausen's disease has been reported. The cystic involvement of the pancreas rarely is prominent, usually gives rise to no symptoms, and is discovered as an unexpected post-mortem finding, frequently so microscopic as to be revealed only on histologic study. The lesions of Lindau's disease have been designated by various descriptive terms, such as hemangioblastic cysts, angiomatosis, hemangio-endothelioma, hemangioblastoma, angiomatosis retinae, hyperplastic capillary hemangioma, cystosarcoma of the pia mater, gliosarcoma, angiosarcoma, cystic cystoglioma, angiospindle-cell sarcoma, secondary sarcoma, cysts of the kidney, pancreas, and suprarenal gland.

Because cystic angiomatous disease of the pancreas repeatedly has been associated with the vascular cerebellar cysts of Lindau and the angiomatosis of the retina of von Hippel, we have attempted to determine whether it is different from the case to be reported. In this patient the entire pancreas finally was destroyed by the progressive development of multiple cysts and vascular caverns of large size, unassociated with retinal changes, neurologic evidences of space-taking intracranial lesion, or the histology of malignant disease. The findings in the case suggest a rare destructive lesion of the pancreas differing from the small or microscopic cysts found in the organ in Lindau's or von Hippel's disease. In size and angiocystic qualities the lesions resembled the cerebellar growths described by Lindau. The pathologic process was largely a rapid proliferation of new blood vessels lined by one or more layers of flattened or cuboidal endothelial cells, with frail walls of poorly developed fibroconnective tissue and little collagen, which evidently expanded or ruptured under the influence

DESTRUCTIVE ANGIOCYSTIC DISEASE OF THE PANCREAS

W. WAYNE BABCOCK, M.D., MACHTELD E. SANO, M.D., PHILADELPHIA, PA. AND STUART B. GIBSON, M.D., WILLIAMSPORT, PA.

(From the Surgical and Pathological Departments of Temple University, Philadelphia)

ARVID LINDAU, of Lund, Sweden, from a study of all cases of cerebellar cysts reported in the literature during the previous twenty years, together with sixteen of his personal cases, demonstrated, in 1926, the tendency for hemangiomatous cerebellar cysts to be hereditary and to be associated with the angiomatosis of the retina, described by von Hippel in 1904 (von Hippel's disease), as well as cystic disease of the medulla, spinal cord (syringomyelia, syringobulbia), pancreas, kidneys, liver, suprarenal glands, and epididymis. The cerebellar cysts contained angiomatous channels separated by sheets or strands of cells which Lindau termed pseudoxanthomatous. Of the associated abnormalities in the abdominal organs, cystic degeneration of the pancreas was the most frequent. The association of the angiomatous cerebellar tumors with a cystic pancreas had been noted previously by Berblinger, in 1922, and by his pupil Ledebur, in 1926.

In 1930, in a lecture given in London, Lindau said that "the cystic pancreas is, in adults, almost pathognomonic for the syndrome," but added, "these abdominal lesions associated with capillary angiomatoses are not *themselves* vascular, as far as I have observed." Putshar, in 1935, made a similar comment regarding the nonvascular nature of the visceral lesions. In a careful review of the literature it appears that angioma of the pancreas is a rare finding. Isolated cysts of the pancreas are by no means uncommon, but actual destructive cystic disease of the organ is definitely unusual. In a case reported by McKechnie and Priestley the possibility of Lindau's disease was suggested by the pathologist, but the authors were unable to confirm the diagnosis clinically.

Busni, in 1928, described what he believed to be the first recorded case of an angioma of the pancreas of arterial origin. This was studied carefully and the illustrations are convincing. He wrote that he had reviewed the Russian literature as well as the general foreign literature on both pathology and anatomy without finding any reference to a similar case. Ten years later Ranström, in 1939, reported a case of venous angioma of the pancreas and emphasized the rarity of such vascular tumors in that organ. To these cases should be added two others, those of Sajewloschin and Querneau, in which the lesions were angiomas histologically. Lymphangiomas and hemangio-endotheliomas, but without generalized cystic degeneration, also have been described. About one of four or five patients with von Hippel's dis-

Received for publication, April 5, 1943.

On Nov. 10, 1939, the right kidney was exposed and found ptosed but grossly normal. A decapsulation and nephropexy were performed. The patient had an uncomplicated operative convalescence and was discharged from the hospital ten days after the operation.

The patient was re-examined March 22, 1940, when she was apparently in good physical condition. In September, 1940, a globular, firm mass was discovered, measuring 6 by 3.5 cm., below and to the right of the ensiform. This evidently was the same mass that previously had been ascribed to the kidney. The liver was not palpable. Roentgen studies showed that the mass did not arise from the colon. The patient was readmitted to Temple University Hospital, Oct. 1, 1940. In appearance she was a well-nourished, middle-aged woman, rational but obviously in a state of anxiety. Colielike abdominal pains with borborygmus had occurred recently.

The abdomen was moderately protuberant and relaxed, soft, somewhat obese, without tenderness but with hyperactive peristalsis. The tense mass could be palpated to the right of the midline in the epigastric region. The physical examination was unsatisfactory due to the mental resistance of the patient. The blood sugar value was 157 mg.; hemoglobin, 75.8 per cent; erythrocytes numbered 4,260,000, and whole blood sugar, 96. Examination of the urine gave negative results.

On Oct. 21, 1940, the nonprotein nitrogen level was 29; on Oct. 15, 109; total protein, 5.84; albumin, 361; globulin, 223; albumin-globulin ration, 1.6.

Operation was performed Oct. 3, 1940. A vertical upper right rectus incision exposed a very vascular, large, multicystic mass presenting through the gastrohepatic omentum. The omentum was incised and a second lower and deeper projecting portion of the cystic mass detected. The mass apparently arose from the head or body of the pancreas. An attempt was made to dissect the cystic mass from what was thought to be the underlying pancreas. The procedure was tedious owing to the many vessels to be divided and ligated. A thin-walled cyst ruptured, with the escape of amber-colored fluid. Needle aspiration of other cysts revealed pure blood. The application of a hemostatic forceps tore the thin wall of one of the large vascular sinuses, with profuse hemorrhage, controlled by digital pressure and additional hemostats. Further attempts to enucleate the cystic mass were followed by such massive hemorrhage from fragile, thin-walled sinuses that the pulse became nearly imperceptible, and no blood pressure was registered by the sphygmomanometer for fifteen minutes. The hemorrhage was controlled by digital pressure and gauze packing; respiratory and cardiac stimulants were given, together with glucose infusion and later 480 c.c. of citrated blood. Attempts at enucleation were abandoned. The abdomen was closed with figure-of-eight wire sutures, and one large tubular glass drain was placed over the gauze sponges to enable additional packing, should such be required.

Operative and Pathologic Findings.—A large, thin-walled, angiomatous cystic tumor of the pancreas measuring about 8 by 8 cm., containing clear amber fluid, large blood sinuses or caverns, and solid tumor masses were found, together with at least one additional cystic portion which was not explored, situated below and deep to the first mass. The specimen removed consisted of what appeared to be the wall of a small cyst measuring about 2 cm. in diameter. The fluid aspirated at operation from the hemorrhagic cyst was frankly bloody. Microscopically it contained red cells, polynuclear leucocytes, lymphocytes and monocytes in the approximate proportion found in normal blood. The outer surface was smooth, the inner surface was trabeculated, showed multiple hemorrhages, and was lined by a layer of cells which in places proliferated to form small, thin-walled blood vessels. The underlying layer consisted of thin strands of acid-staining tissue in which were few nuclei but many thin-walled vessels filled with blood. There was much interstitial hemorrhage, fibroblastic proliferation, and occasional collections

of the blood pressure into cystlike angiomatous caverns. From the extensive endothelial proliferation some of the older caverns apparently became blocked from the general blood stream and remained as cysts containing stagnant blood, clear or colored serum. Evidence is lacking of a familial tendency, of associated angioma of the retina, or of a tumor of the central nervous system. During four years of mild psychosis the patient was examined repeatedly in various institutions for the treatment of mental and nervous diseases, without finding evidence of a space-taking lesion within the skull. We cannot, however, exclude the presence of associated cerebellar cysts, since a post-mortem examination of the central nervous system was not permitted. The optic discs were examined by W. I. Lillie and were found normal on ophthalmoscopic examination. The cysts of the pancreas, although producing few subjective symptoms, progressed to large size and finally involved the entire pancreas so that residual portions of recognizable pancreatic tissue were found only on microscopic study and then in small areas.

Obviously, it is more than probable that some references have been overlooked in reviewing the literature and quite as possible that cases similar to the one reported here never were published. However, taking these possibilities into consideration, we have failed to find any case similar to the one here reported.

The patient, aged 54 years, a widow with three adult children, previously had been in good health. Mental depression developed in 1935. The patient had had the usual childhood diseases, and menses had been regular until the menopause four years before admission. In the same year, while in deep depression, temporary glycosuria was reported and treatment for diabetes was given, but evidence of diabetes since 1935 has not been found. During the first winter she was in the hypomanic phase, with unusual physical and mental activity, euphorin, and the like. Since this time she had had psychic depressions and elevations of mental activity, considered to be a true manic depressive psychosis, always with rather mild waves which recurred yearly between April and October. For these attacks she was treated temporarily in special hospitals. Physically and neurologically, at repeated examinations, she had been found to be normal although her weight gradually fell from 180 to 140 pounds. During an annual physical examination in 1939, a mass about 8 cm. in diameter was found in the upper right quadrant of the abdomen. The patient had noticed a mass in the right flank for about five months without symptoms except a tired, drawing sensation. Her weight was then stationary but she had a slight hypochromic anemia. Complete gastrointestinal roentgen examinations, including cholecystography, revealed no abnormality with the exception of a downward displacement of the hepatic flexure. The nonprotein nitrogen value was 109; the total protein, 584; albumin, 361; globulin, 2.23; albumin-globulin ratio, 1.6; hemoglobin, 75.6 per cent; erythrocytes, 5,240,000; leucocytes, 13,550; polymorphonuclear neutrophiles, 76; lymphocytes, 24; filaments, 74, and nonfilaments, 2. No abnormality was found in the urine but an intravenous pyelogram revealed mild hydronephrosis, with the right ureter sharply pushed over toward the midline just below the kidney. Thoracic roentgenologic study showed no metastatic tumor. Under the diagnosis of probable hypernephroma of the right kidney, the patient was referred to the Temple University Hospital for operation.

Pathologic Report.—The cystic growth showed great structural variation in different areas (Fig. 1). In microscopic areas pancreatic acinar tissue was observed, with some distortion due to interacinar edema and the encroachment of the angiocystic disease process, but few islands of Langerhans were found (Fig. 5).

Two major pathologic processes seemed to exist side by side, or in places to merge one with the other. The first consisted of areas of cystic dilatation (Fig. 2) which honeycombed or rather replaced the pancreatic tissue and at times seemed to involve some of the secondary ducts, although the impression was gained that the process was mostly acinar in origin. The cysts were lined for the most part by flattened cells, which had moderate-sized, ovoid nuclei parallel in position to the long axis of the cell. The nuclei contained one or two rather prominent nucleoli and a moderate amount of medium sized, deep staining metachromatic

Fig. 2.—Thin, fragile wall of an older pancreatic cyst (×50).

granules. A gradual transition from the flattened endothelial type of cell to a frankly cuboidal cell was apparent. These cuboidal cells were vacuolated for the most part and in places showed beginning papillary proliferation and some metaplastic stratification (Fig. 2). The lumina tended to be filled with finely granular, almost homogeneous eosin staining material. Beneath the lining of the cystic areas there was delicate connective tissue stroma in which occasional round cells were seen, chiefly lymphocytes (Fig. 3).

The other major pathologic feature was an angiomatous type of lesion (Fig. 4). The larger blood filled cysts had walls lined by typical hyperplastic appearing, elongated endothelial cells. In places these had proliferated to form communicating vascular channels outlined only by clumps of undifferentiated endothelial cells, which suggested a neoplastic origin. Such spaces were ill defined, sinusoidal in character, without definite intimal lining cells, as it in places, at least, due to hemorrhage. However, a definite supportive stroma of connective tissue could be identified readily in these areas when stained by Masson's trichrome stain. Running through such trabeculae, normal thin walled, capillary vessels were identified, apparently representing the original vascular supply. Similarly, occasional

of cells with round nuclei and which stained coarse granular, resembling epithelial cells that apparently filled round spaces limited by the fibrous strands of tissue. The pathologic diagnosis was angiomatoid cyst wall.

The patient left the operating room with a blood pressure of 80 mm. systolic and 60 mm. diastolic, and a barely perceptible pulse of 140. Quantities of, at first serosanguineous, and later clear, thin, slightly turbid fluid were collected from the wound by aspiration drainage; the first day 480 c.c.; the second, 600 c.c.; the third, 660 c.c.; the fourth, 720 c.c.; the fifth, 1,020 c.c.; the sixth, 960 c.c.; the seventh, 990 c.c.; the eighth, 1,200 c.c.; the ninth, 1,140 c.c.; the tenth, 900 c.c., and the eleventh 630 c.c. The drainage produced a moderate excoriation of the skin despite exposure under a bed cage and stearate of zinc dusting powder. The temperature after the second day was rarely over 99.2° F., and the pulse averaged between 90 and 100. One gauze drainage sponge was removed Oct. 9, 1940. On Oct. 10, the lamp chimney drain slipped out and that evening the last gauze sponge was removed. The patient was discharged from the hospital Nov. 3 and died Nov. 15, 1940, after a steady downward course, with drainage of foul smelling bloody fluid from the fistula the last few days.

Fig. 1.—Angiocystic tumor of the pancreas with adherent portions of duodenum, removed at autopsy, showing the absence of gross pancreatic tissue and the diffuse cystic change, with clear and hemorrhagic cysts.

At an autopsy limited to the abdomen a large multicystic tumor was found located deep in the right upper quadrant and tightly surrounded by gangrenous duodenum. No grossly recognizable pancreatic tissue could be found. The base of the pancreatic fistula consisted of necrotic tissue. There were massive adhesions everywhere, some of which seemed old. There were some small, very irregular veins in the necrotic bed which had been the body of the pancreas. When the first part of the duodenum was separated from the undersurface of the liver and turned down, a second mass, approximately 10 cm. in diameter, was found in the right upper abdomen. Tightly encircling it was the remainder of the duodenum, which was black, friable, and gangrenous. It was impossible to separate the duodenum from the tumor, so they were removed together. This tumor was apparently intact, with a large vein in its pedicle.

Although the histopathology is compatible with Lindau's disease, none of the other signs and symptoms of the syndrome were evident, such as cystic tumor of the cerebellum or von Hippel's disease of the retina. Perhaps the descriptive term of destructive angiocystic disease of the pancreas conforms best to the microscopic findings of this case. It does not seem possible, however, to exclude one of the more complex mixed tumors of true endothelial origin, the so-called hemangiolymphangio-endothelioma, in our consideration of the differential diagnosis.

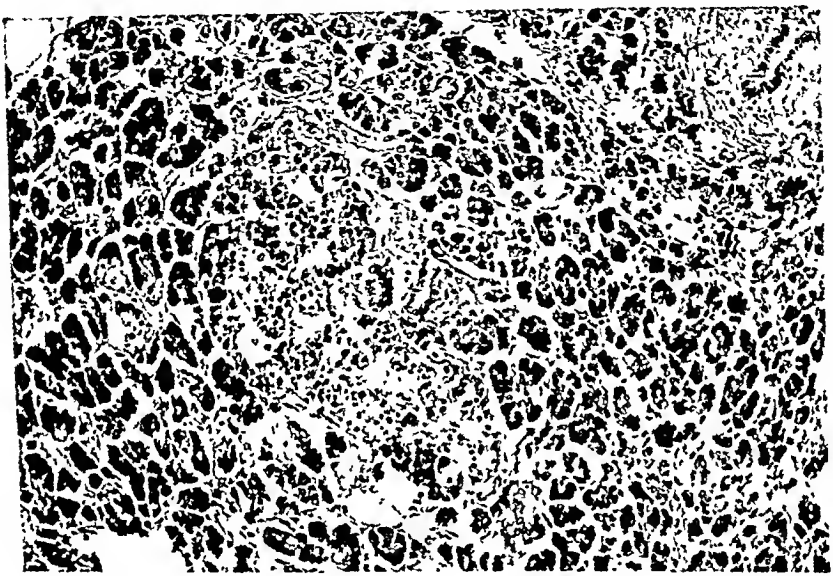

Fig. 5.—One of the few microscopic areas of persistent pancreatic tissue.

Treatment.—Our experience in this single case suggests that the chief problem in the extirpation of angiocystic disease of the pancreas is the control of hemorrhage. This may not be difficult in the early stages when the resection may be carried through the normal pancreas rather than through angiomatous tissues. Many of the cystlike cavities are great vascular caverns with very thin, fragile walls that may tear from the weight of a hemostatic forceps, with rapid loss of large quantities of blood. Additional hemostats tear larger holes in the walls, with increased hemorrhage. Even the serous cysts have walls containing innumerable vessels which on division require many fine ligatures. A coagulating current might be used for the smaller vessels but would be quite ineffective to control bleeding from the large caverns. In the early stage it would seem possible to excise the growth through the normal pancreas where blood vessels may be satisfactorily ligated and oozing controlled by sutures. For larger growths a preliminary provisional occlusion of arteries carrying blood to the pan-

vessels with an arteriolar or even arterial musculature were seen. Occasional islands of undifferentiated cells suggested either budding new vessels or possibly pancreatic acinar formation.

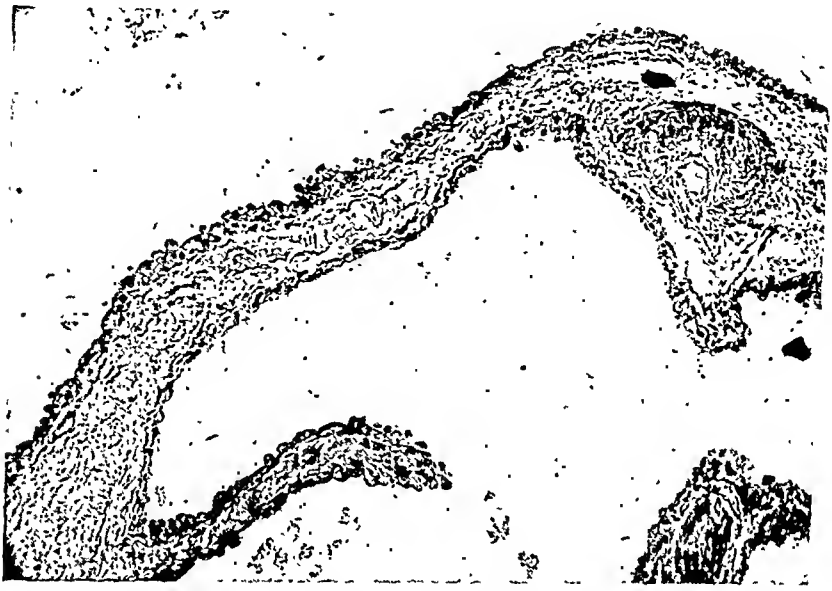

Fig. 3.—Proliferating cuboidal endothelial cells lining an older cyst (×150).



Fig. 4.—Angiomatous wall of a cyst of more recent development. (×250.)

In certain areas there was a suggestion of actual transition from the vascular pattern, with spaces filled with red cells, to the more cuboidal-like, cell-lined cyst. Even the contents of these cystic areas suggested a merging of the red cells and serouslike material.

dition apparently differs from the forms of cysts and angiomatous disease of the pancreas previously described by Lindau and others. As a nearly fatal hemorrhage followed cautious attempts to enucleate the cystic area, the desirability of early operation before the pancreas has been extensively destroyed and the use of provisional temporary occlusion of the main pancreatic arterial trunks is suggested in similar cases.

REFERENCES

Armstrong, M. V.: Angiomatosis Retinae (von Hippel's Disease Lindau's disease), Complicated by Pregnancy, Am. J. Obst. & Gynec. 34: 494, 1937.

Atkinson, W. S.: Angiomatosis Retinae With Cerebellar Cyst (Lindau's Disease), Tr. Am. Acad. of Ophth. 36: 106, 1931; Arch. Ophth. 7: 510, 1932.

Aust, O.: Von Hippel'sche Erkrankung mit Staungspapille und Hämangiom. Ztschr. f. Augenh. 50: 305, 1923.

Barrière, A. V.: Sobre las enfermedades de Lindau, von Hippel y Coats, Arch. de oftal. hispano am. 31: 425, 1931.

Beblinger, W.: Zur Auffassung von der so genannten von Hippelschen Krankheit der Netzhaut, Arch. f. Ophth. 110: 395, 1922.

Berger, L., and Vallée, A.: L'angio rétinolo xanthome de la rétine, Ann. d'anat. path. 8: 313, 1931.

Brandt, R.: Zur Frage der Angiomatosis retinae, Arch. f. Ophth. 106: 127, 1921.

Brohée, G.: Un cas de kyste hématique spontané volumineux du pancréas, Bruxelles méd. 9: 542 544, 1929.

Brown, H. H.: Excision of Large Angioma of Liver in a Diabetic, Brit. M. J. 1: 232, 1927.

Busm, N. A.: Ein Fall von Arteriolangiom des Pankreas, Odessky M. J. 3: 713 715, 1928.

Colber, W. T.: Two cases of Lindau's Disease, Brit. M. J. 2: 144, 1931.

Cordes, Friedrick G., and Hogan, Michael J.: Angiomatosis Retinae (von Hippel's disease): Report of a Case in Which Roentgen Therapy Was Used in an Early Stage, Arch. Ophth. 23: 253, 1940.

Craig, W. M., Wagener, H. P., and Kernohan, S. W.: Lindau von Hippel Disease, Tr. Am. Neurol. A. 65: 98, 1939.

Cushing, H., and Bailey, P.: Tumors Arising From the Blood Vessels of the Brain, Springfield, Ill., 1928, Charles C Thomas, Publisher.

Idem: Hemangiomas of Cerebellum and Retina (Lindau's Disease), Arch. Ophth. 57: 447, 1928; Tr. Am. Ophth. Soc. 26: 182, 1928.

Davidoff, L. M.: Hemangioblastoma of the Cerebellum, Am. J. Path. 5: 141, 1929.

Davison, C., Brock, S., and Dyke, C.: Retinal and Central Nervous Hemangioblastomatosis With Visceral Changes (von Hippel Lindau's Disease), Bull Neurol. Inst. New York 5: 72, 1936.

Delmas Marsalet, P., Lafon, Y., and Faure, Y.: Etudes sur les phakomatoses, J. de méd. de Bordeaux 116: 295, 1939.

Dixon, C. F., and Whitlock, M. E.: Hemangio Endothelioma Probably Originating in Hemangioma of the Pancreas, Case, S. Clin. North America 14: 701, 1934.

Escalona, E.: Angiomatosis de Lindau y von Hippel con adenomas sebáceous simétricos tipo Pringle, Medicina, México 20: 205, 1940.

Golubova, R. A., Lasitsa, P. M., Merkulov, I. O., and Toropova, M. N.: Von Hippel Lindau's Disease, Sovet. psikhoneyrol. 6: 30, 1933.

Hadfield, G.: Association Between Angioma of Cerebellum, Polycystic Pancreas and Renal Adenoma, Bristol Med. Chir. J. 46: 211, 1929.

Hall, G. S.: Bloodvessel Tumors of the Brain With Particular Reference to the Lindau Syndrome, J. Neurol. & Psychopath. 15: 305, 1935.

Harbitz, F.: Ein Fall von multiplen Geschwulsten: Hemangiome und ghomatose mit syringomyelie des Zentralnervensystems, sowie Zystenpankreas und andere Geschwulstender Abdominalorgane (Lindau's Krankheit), Acta path. et microbiol. Scandinav. 11: 142, 1934.

Hartmann, E., and Sourdille, G.: Aromahe vasculaire de la rétine chez une malade operée d'une tumeur cerebrale, Bull Soc. d'opht. de Paris, 187, 1930.

Idem: Un cas de maladie de Lindau "a deux": Angiome du cervelet chez la m. d'oeul 168: 881, 1931.

creas would seem desirable when the size and vascular connections of the growth are not prohibitive.

The arteries of the pancreas are derived from the lienal for the body and tail of the organ, and from the pancreaticoduodenal branch of the hepatic artery and the inferior pancreaticoduodenal branch of the superior mesenteric artery for the head of the pancreas. In certain cases it may be feasible to do a provisional occlusion of these branches or of the hepatic, lienal, and possibly the superior mesentery trunks. A convenient method is to pass a narrow tape or soft silk ligature about each artery, the ends of which are brought through a small catheter to which they are clamped under sufficient traction to produce the desired arterial occlusion. This simple method, suggested by Astley, we have used for temporary occlusion during suture of the portal vein, the external iliac, and the common carotid artery. Obviously, very large growths and highly vascular attachments may prevent access to the supplying vascular trunks, and the growth may then be found incradicable. Hemostasis is quite different from that found adequate in the removal of the usual large cysts of benign or malignant type which develop from the pancras. Although in the past these have been treated largely by marsupialization, increased experience has shown that removal by incising or resecting the pancreas is much less dangerous than formerly thought. As a rule it is preferable to remove these large cysts with a margin of adjacent pancreatic tissue. The pancreas is fairly firm and may be sutured or its vessels ligated. The escape of small quantities of pancreatic juice into the peritoneal cavity, when not activated by bile or gastrointestinal contents, apparently does little harm, especially when a continuous aspirating suction abdominal drain is used after the operation. When marsupialized the large cysts may become infected and discharge purulent material for many months or lead to a fistula, while an overlooked malignant process may progress and be recognized only when it has spread beyond the possibility of removal, causing the operator to regret that the original operation was not more radical. Before attempting to remove any very large angiocystic tumor of the pancreas, it is evident that the entire organ and its tributary vessels, including the pancreaticoduodenal branches of the hepatic, lienal, and superior mesenteric arteries, and the veins that run from the pancreas to the lienal and superior mesenteric veins should be investigated. If, as in the present case, the entire pancreas is involved, the outlook of course is not favorable, even with special diet and the continued used of insulin.

SUMMARY

A rare, markedly angiomatous and cystic disease of the pancreas is described which progressed to the macroscopic destruction of the entire organ, with few symptoms except a moderate leucocytosis, a rise in the nonprotein nitrogen, and an upper abdominal mass. The con-

dition apparently differs from the forms of cysts and angiomatous disease of the pancreas previously described by Lindau and others. As a nearly fatal hemorrhage followed cautious attempts to enucleate the cystic area, the desirability of early operation before the pancreas has been extensively destroyed and the use of provisional temporary occlusion of the main pancreatic arterial trunks is suggested in similar cases.

REFERENCES

Armstrong, M. V.: Angiomatosis Retinae (von Hippel's Disease Lindau's disease). Complicated by Pregnancy, Am. J. Obst. & Gynec. 34: 494, 1937.

Atkinson, W. S.: Angiomatosis Retinae With Cerebellar Cyst (Lindau's Disease), Tr. Am. Acad. of Ophth. 36: 106, 1931; Arch. Ophth. 7: 510, 1932.

Aust, O.: Von Hippel'sche Erkrankung mit Stauungspapille und Hamangiom. Ztschr. f. Augenh. 50: 305, 1923.

Barrière, A. V.: Sobre las enfermedades de Lindau, von Hippel y Coats, Arch. de oftal. hispano am. 31: 425, 1931.

Berblinger, W.: Zur Auffassung von der so genannten von Hippelschen Krankheit der Netzhaut, Arch. f. Ophth. 110: 395, 1922.

Berger, L., and Vallée, A.: L' angio réticulo xanthome de la rétine, Ann. d' anat. path. 8: 313, 1931.

Brandt, R.: Zur Frage der Angiomatosis retinae, Arch. f. Ophth. 106: 127, 1921.

Brohée, G.: Un cas de kyste hématique spontané volumineux du pancréas, Bruxelles méd. 9: 542 544, 1929.

Brown, H. H.: Excision of Large Angioma of Liver in a Diabetic, Brit. M. J. 1: 232, 1927.

Busin, N. A.: Ein Fall von Arteriolangiom des Pankreas, Odessky M. J. 3: 713 715, 1928.

Collier, W. T.: Two cases of Lindau's Disease, Brit. M. J. 2: 144, 1931.

Cordes, Frederick G., and Hogan, Michael J.: Angiomatosis Retinae (von Hippel's disease): Report of a Case in Which Roentgen Therapy Was Used in an Early Stage, Arch. Ophth. 23: 253, 1940.

Craig, W. M., Wagener, H. P., and Kernohan, S. W.: Lindau von Hippel Disease, Tr. Am. Neurol. A. 65: 98, 1939.

Cushing, H., and Bailey, P.: Tumors Arising From the Blood Vessels of the Brain, Springfield, Ill., 1928, Charles C Thomas, Publisher.

Idem: Hemangiomas of Cerebellum and Retina (Lindau's Disease), Arch. Ophth. 57: 447, 1928; Tr. Am. Ophth. Soc. 26: 182, 1928.

Davidoff, L. M.: Hemangioblastoma of the Cerebellum, Am. J. Path. 5: 141, 1929.

Davison, C., Brock, S., and Dyke, C.: Retinal and Central Nervous Hemangioblastomatosis With Visceral Changes (von Hippel Lindau's Disease), Bull. Neurol. Inst. New York 5: 72, 1936.

Delmas Marsalet, P., Lafon, Y., and Faure, Y.: Etudes sur les phakomatoses, J. de méd. de Bordeaux 116: 295, 1939.

Dixon, C. F., and Whitlock, M. E.: Hemangio Endothelioma Probably Originating in Hemangioma of the Pancreas; Case, S. Clin. North America 14: 701, 1934.

Escalona, E.: Angiomatosis de Lindau y von Hippel con adenomas sebáceous simétricos tipo Pringle, Medicina, México 20: 205, 1940.

Golubova, R. A., Lisitsa, F. M., Merkulov, I. O., and Toropova, M. N.: Von Hippel Lindau's Disease, Sovet. psikhonevrol. 6: 30, 1933.

Hadfield, G.: Association Between Angioma of Cerebellum, Polycystic Pancreas and Renal Adenoma, Bristol Med. Chir. J. 46: 211, 1929.

Hall, G. S.: Bloodvessel Tumors of the Brain With Particular Reference to the Lindau Syndrome, J. Neurol. & Psychopath. 15: 305, 1935.

Harbitz, F.: Ein Fall von multiplen Geschwulsten: Hemangiome und gliomatose mit syringomyelie des Zentralnervensystems, sowie Zystenpankreas und andere Geschwulstender Abdominalorgane (Lindau's Krankheit), Acta path. et microbiol. Scandinav. 11: 442, 1934.

Hartmann, E., and Sourdille, G.: Aromalie vasculaire de la rétine chez une malade opérée d' une tumeur cérébrale, Bull. Soc. d' opht. de Paris, 187, 1930.

Idem: Un cas de maladie de Lindau "a deux": Angiome du cervelet chez la mere, maladie de von Hippel chez le fils, Ann. d' ocul. 168: 881, 1931.

Heine, L.: Ueber Angioglosis retinae mir Hirntumor, Ztschr. f. Augenh. 51: 1, 1923.

Von Hippel, E.: Ueber die Beziehungen von Mikrophthalmus mit Unterbldcyste zu allgemeinen Missbildungen, besonders zum Landauschen Symptomenkomplex, Arch. f. Ophth. 132: 256, 1934.

Hughes, R. P.: A Case of Lindau's Disease, Canad. M. A. J. 31: 537, 1934.

Isnel, R.: Observation d' un cas d' angiomatose de la rétine, Bull. Soc. d' opht. de Paris, 652, 1931.

Jess, A.: Angioglomatose de la rétine et glome de la moelle (pinière, XIII ième Congrès Intern. Opht., Amsterdam, 156, 1929 Cited by Viallefont, H.

Judd, E. S., and Mattson, P.: Forty Seven Cases, Arch. Surg. 22: 838 849, 1931.

Jung, R.: Ueber die Angiome Lindau's als eine charakteristische Gruppe unter den Kleinhirntumoren, Arch. f. Psychiat. 103: 580, 1935.

Karasek, O.: Angiomatosis retinae (von Hippel Lindau), Klin. Monatsbl. f. Augenh. 95: 163, 1935.

Keller, H.: Sogenannte "hyperplastische Capillarangiome" (Lindau) und Gross hirncyste, zugleich ein Beitrag zur Tumor Cystenfrage, Virchows Arch. f. path. Anat. 289: 151, 1933.

Konig, E., und Schoen, H.: Über ausgedehnte Angiomatosis der medulla oblongata und des Rückenmarks mit Zentraler Gliose, Syringomyelie, Zystenpankreas, Nierenzystem und zystisch hypernephroiden Tumoren beider Nieren Lindauisches Syndrom), Beitr. z. klin. Chir. 170: 239, 1939.

Kufs, H.: Beitrag zur Klinik, Histopathologie und Vererbungspathologie der von Hippel Landauschen Krankheit auf Grund der Untersuchung eines neuen Falles, Ztschr. f. d. ges. Neurol. J. Psychiat. 138: 414, 1932.

Lévy, G.: L' angiomatose du système nerveux central, Presse méd. 38: 37, 1930.

Liebegott, G.: Ein Beitrag zur Klinik und Pathologie der Kleinhirnangiome Lindau's, Nervenarzt 10: 178, 1937.

Lindau, A.: Studien über Kleinhirncysten. Bau, Pathogenese und Beziehungen zur Angiomatosis Retinae, Acta path. et microbiol. Scandinav. 1: 1, 1926.

Idem: Zur Frage der Angiomatosis Retinae und ihrer Hirnkomplikationen, Acta ophth. 4: 193, 1927.

Idem: Discussion on Vascular Tumors of the Brain and Spinal Cord, Proc. Roy. Soc. Med 24: 363, 1930.

Lindau, A., Sargent, P., and Collins, E. T.. Discussion on Vascular Tumors of the Brain and Spinal Cord, Proc. Roy. Soc. Med. 24: 1, 1931.

Lotmar, F.: Zur Kenntnis der Lindauschen Krankheit, Schweiz. Arch. f. Neurol J. Psychiat. 36: 257, 1935.

MacDonald, A. E.: Lindau's Disease· Report of 6 Cases With Surgical Verification in 4 Living Cases, Arch. Ophth. 23: 564, 1940

McKechnie, R. E, Jr., and Priestley, J. T.: Multilocular Polycystic Tumor, Canad M. A. J. 36. 592, 1937.

McKechnie, R E., Jr., and Priestley, J. T · Multilocular Polycystic Tumor of the Pancreas, Canad. M. A. J. 36: 592 593, 1937.

Macnab, G. H.. Lindau's Disease, Proc. Roy. Soc. Med 34: 324, 1941.

Matsuoka, S: Brain Tumor Resembling Lindau's Disease, Tr. Jap. Path Soc 22: 903, 1932.

Mennenga, M: Zur Klinik und Pathologie der Lindauschen Erkrankung, Beitr. z. klin. Chir. 164: 633, 1936

Møller, H. U. Familiaer angiomatosis retinae et cerebelli. Lindau's Sygdom Ugesk. f. Læger. 92: 379, 1930; Acta ophth. 7: 244, 1929

Nygaard, K. K.· Polycystic Disease· Report of a Case With Partial Pancreatectomy, Ann. Surg. 106: 49 53, 1937.

Nemlin, F.. Ein Fall von Leberkavernom, Zentralb f. Chir. 58: 1575 1577, 1931.

Palm, A.: Von Hippel Lindau's Disease, Proc. Roy. Soc Med. 32: 1618, 1939.

Panà, C. Su la morfologia e la istogenesi degli angioreticulomi encefalici, Riv. di pat. nerv. 44: 1, 1934

Paton, L, Noble, and Greenfield· A case of Lindau's disease, XIIIe Congrès intern. d' Opht, Amsterdam, 294, 1929. Cited by Viallefont, H

Petchn, S. M., and Markhaer, G P.. Neuro ectodermoses (case resembling Lindau's disease), Vrach delo. 20: 53, 1938

Porta, V.: Malattia di Lindau e malformazioni encefaliche, Riv. di pat nerv. 50: 1, 1937.

Putschar, W.· Ueber Angiomatosis des Zentralnervensystems und der Netzhaut (von Hippel Lindausches Syndrom) mit besonderer Berücksichtigung der Pankreasveränderungen, München, med. Wchnschr. 82: 1084, 1935.

Querneau, J.: Kyste congénital du pancreas, Mém. Acad. de chir. 65: 777-781, 1939.
Ranström, S.: Haemangioma cavernosum pancreatis, Zentralbl. f. allg. Path. u. path. Anat. 73: 33-35, 1939.
Rocha, H., and Garcia, J.: Molestia de Lindau com naevus de face, Brasil-med. 51: 1003, 1937.
Rochat, G. F.: Angiomatosis of the Retina (von Hippel's Disease), Nederl. tijdschr. v. geneesk. 75: 437, 1931.
Rochat, G. F.: Familiäre Angiomatosis retinae und Kleinhirnangiom, Klin. Monatsbl. f. Augenh. 78: 601, 1927.
Idem: Grosshirnangiom bei der Lindauschen (v. Hippelscher) Erkrankung, Klin. Monatsbl. f. Augenh. 86: 23, 1931.
Roger, H., and Alliez, J.: Les neuroectodermomes: neurogliomatose de Recklinghausen périphérique et centrale; sclérose tubéreuse de Bourneville avec adénomes sébacés de la face; angiomatose cérébrorétinienne de Lindau, Presse méd. 43: 2113, 1935.
Roulet, F.: L' angiomatose des centres nerveux (maladie de Lindau), en particulier des kystes du cervelet, Rev. méd. de la Suisse Rom. 52: 529, 1932.
Roussy, G., and Oberling, C.: Les tumeurs angiomateuses des centres nerveux, Presse méd. 38: 5, 1930.
Sajewloschin, M. N.: Lymphangioma cavernosum hypertrophicum pancreatis, Frankfurt. Ztschr. f. Path. 35: 452-456, 1927.
Schuback, A.: Ueber die Angiomatosis des Zentralnervensystems (Lindausche Krankheit), Ztschr. f. d. ges. Neurol. u. Psychiat. 110: 359, 1927.
Shapiro, P.: Hemangioblastoma of the Cerebellum With Cyst Formation (Lindau's Disease), Arch. Path. 8: 915, 1929.
Sladden, F. A.: A Case of Lindau's Disease, Brit. J. Ophth. 14: 224, 1930.
Talkovskiy, S. I.: Nature of Hippel-Lindau's Disease, Vestnik oftal. 15: 180, 1939.
Tannenberg, J.: Ueber die Pathogenese der Syringomyelie zugleich ein Beitrag zum Vorkommen von Kapillarhämangiomen im Rückenmark, Ztschr. f. d. ges. Neurol. u. Psychiat. 92: 119, 1924.
Tedeschi, C.: Tumori vascolari encefalici e malattia de Lindau, Riv. sper. d. freniat. 56: 497, 1932.
Tourainc, A.: Idiotie et angiomatose intra-cranienne (maladie de Lindau), Bull. Soc. franç. de dermat. et syph. 43: 447, 1936.
Treacher, C. E.: Intra-ocular Growths, Tr. Ophth. Soc. U. Kingdom 14: 141, 1894.
Urechia, M.: Cinq cas de tumeur de Lindau, Rev. neurol. 2: 640, 1931.
Usher, C. H.: Angiomatosis Retinae, Tr. Ophth. Soc. U. Kingdom 50: 183, 1935.
Van Bogaert, L., and Martin, P.: Deux cas d' hémangiome du cervelet chez deux soeurs, J. belge de neurol. et de psychiat. 33: 809, 1933.
Van der Hoeve, J.: Les phakomatoses de Bourneville, de Recklinghausen et de von Hippel-Lindau, J. belge de neurol. et de Psychiat. 33: 752, 1933.
Viallefont, H.: La maladie de von Hippel. La maladie de Lindau-von Hippel, Rev. d' oto.-neurol.-ophth. 13: 416, 1935.
Viets, H. R.: Additional Case of Hemangioblastoma of Retina and Cerebellum, With Note on Lindau's Disease, J. Nerv. & Ment. Dis. 77: 457, 1933.
Vogel, P.: Was versteht man unter Lindauscher Krankheit, Ztschr. f. ärztl. Fortbild. 37: 673, 1940.
Watrin, J., Meignant, P., and Weille, R.: Sclérose tubéreuse de Bourneville et naevi fibromateux symétriques de la face, Ann. de dermat. et syph. 10: 644, 1939.
Wolf, A., and Wilens, S. L.: Multiple Hemangioblastomas of Spinal Cord With Syringomyelia, Am. J. Path. 10: 545, 1934; Arch. Path. 15: 604, 1933.
Wolff, K., and Donat, R.: Die Nierenveränderungen bei der Lindauschen Krankheit an Hand einer Beobachtung von cystisch-hypernephroiden Umwandlung beider Nieren, Ztschr. f. urol. Chir. u. Gynäk. 43: 272, 1937.
Wood, H. G.: Polycystic Disease of the Pancreas: Case, Proc. Staff Meet., Mayo Clin. 11: 449-451, 1936.

THE ASSOCIATION OF CARCINOMA IN THE BODY AND TAIL OF THE PANCREAS WITH MULTIPLE VENOUS THROMBI

WILLIAM E. KENNEY, M.D.,* ST. LOUIS, MO.

(From the Department of Pathology, Washington University School of Medicine, and the Barnes Hospital, St. Louis)

INTRODUCTION

IN 1938, Sproul[6] first pointed out the remarkably frequent association of carcinoma in the body and tail of the pancreas with multiple venous thrombi. I have had the opportunity to examine at autopsy two cases with carcinoma of the pancreas (one in the body and one in the tail), in which the presenting symptoms and signs were referable to multiple venous thrombi. A report of these two cases, together with a full analysis of the association of phlebothrombosis with disease of the pancreas, forms the basis of this communication. Inasmuch as the physical signs of multiple venous thrombosis may be the earliest clinical manifestation of the presence of a carcinoma in the body or tail of the pancreas, it is hoped that this paper may focus the attention of clinicians on the phenomenon and assist in the difficult diagnosis of these tumors.

A correct and early diagnosis of carcinoma of the body and tail of the pancreas is rarely made. The symptoms and signs—abdominal pain, loss of weight, ascites, hematemesis, enlargement of the liver and spleen, and terminal jaundice—are not sufficiently characteristic to establish the diagnosis. Thus, in the series studied by Ransom,[5] carcinoma of the body or tail of the pancreas was unsuspected before death or operation in eleven out of sixteen. In the sixteen cases investigated by Duff,[1] not a single correct diagnosis was made despite an opportunity to examine the peritoneal cavity visually at laparotomy in four cases. The most common erroneous diagnosis in both series was carcinoma of the colon.

To avoid any misconception of the term "multiple venous thrombi" as used in this paper, it may be pointed out that the veins involved are the subclavian, the great saphenous, the iliacs, the inferior vena cava, the splenic, the portal, the inferior and superior mesenteries, etc. The thrombi usually extend throughout the entire length of these veins, with no tendency to end at a junction of two veins. Hence, the process is unique in its multiplicity and in its extent.

Received for publication, April 26, 1943.

*Now at the Department of Surgery, Yale University School of Medicine and the New Haven Hospital, New Haven, Conn.

CASE REPORTS

CASE 1 (Hospital No. Medicine 89906).—A 51-year-old white man was admitted to the Barnes Hospital, on June 3, 1941, and died July 17, 1941

Illness Upon Admission.—On returning from a fishing trip in Florida in March, 1941 (3 months before admission), he noticed pain in the feet and ankles. Manipulation by an osteopath and the purchase of new shoes gave no relief. The pain came gradually to involve the entire legs, and the ankles were intermittently red and swollen. The administration of sulfathiazole was without benefit. Ten days before admission he began to have profuse night sweats and the left arm became swollen and tender. There was paresthesia in the left arm In the preceding two weeks there were four attacks of "pleurisy." For the first time, the stools were observed to be light in color two days before entry to the hospital.

Past History.—Aside from "indigestion" he had been in good condition until this illness. As a child he had had measles and whooping cough, and in 1906, and again in 1907, pneumonia and pleurisy.

Family History.—His mother died at the age of 70 of cancer of the stomach, and one brother died at the age of 61 from "intestinal trouble, gall bladder disease, and thrombophlebitis."

Physical Examination.—Temperature, 37.3° C.; pulse, 86; respirations, 20. Examination revealed a well developed and well nourished man who did not appear acutely ill. Examination of the head and neck showed nothing remarkable. Auscultation and percussion of the lungs and heart revealed no abnormal findings. The edge of the liver extended 6 cm. below the right costal margin in the mid clavicular line and was tender. There were no other palpable masses in the abdomen. Both ankles were swollen, red, and hot. Cords, presumably thrombosed veins, could be palpated in the subcutaneous tissues of the ankle and upward to the middle third of the thighs. The left arm was swollen, tender, and warm, and similar cords were palpable.

Laboratory Examination.—R.B.C., 3,620,000; hemoglobin, 68 per cent; W.B.C., 8,000; coagulation time (Howell) 33 minutes; bleeding time by the cuff method, 6 minutes; prothrombin time by bedside method, 28 seconds (normal of 23 seconds): total plasma proteins, 4.5 Gm. with albumin of 2.9 and globulin of 2.0 Gm.; blood sugar, 77 mg.; icteric index, 13.4. The Kahn test and agglutination tests for *Eberthella typhi*, *Bacillus melitensis*, and *Pasteurella tularense* were negative. Urine, 1 plus albumin and occasional white cells in the sediment. Stool, trophozoites and cysts of Endolimax nana.

Roentgenologic Examinations.—Films of the thorax were indeterminate. Films of the sinuses showed some haziness in the left maxillary sinus.

Course.—The feet and legs were elevated. Sulfathiazole, 1 Gm. every four hours for ten days, had no effect on the symptoms and signs. The temperature rose each afternoon to 38° C. On the third day pain developed in the right hemithorax and on physical examination there were a friction rub and a few fine râles in the region of the eighth and ninth ribs at the posterior axillary line. On the fourth day three additional thrombosed veins were palpable on the inner aspect of the right thigh. Cultures of the throat revealed hemolytic streptococci, pneumococci, and *Micrococcus catarrhalis*. A blood culture showed no growth.

Two weeks after admission, examination of the blood showed: R.B.C., 4,325,000; hemoglobin, 11.3 Gm.; reticulocytes, 0.6 per cent; W.B.C., 11,900; and platelets, 149,280. The bleeding time was 5½ minutes (normal, 3 to 6 minutes). Differential count: Segmented, 54; nonsegmented, 10; mononuclears, 13; eosinophiles, 9; myelocytes, 2.

During the second and third week jaundice gradually developed; by the end of the fourth week the icteric index was 44, and at the end of the fifth week it was 60. The blood nonprotein nitrogen was 42 mg. per 100 c.c.

Artificial fever therapy, three treatments on alternate days for one half, one, and one and one half hours to 101° F., and two transfusions of 500 c.c. and 250 c.c. respectively, brought some improvement of the swelling and pain in the legs. Because of severe nausea and anorexia, feeding with amigen, Karo, yeast, and minerals was attempted, but had to be abandoned as the nausea and abdominal distress became more marked.

At the end of the sixth week, 1,750 c.c. of bloody fluid were removed from the peritoneal cavity. Cultures of the fluid remained sterile and microscopic examination of the sediment revealed no tumor cells.

On July 16, forty-three days after admission, the patient became weaker and lapsed into a stuporous state. Examination of the chest revealed many moist râles over both upper lung fields. The blood pressure fell to 72/54 and he died the following day, July 17.

Clinical Impression.—Migratory thrombophlebitis of the legs, left arm, and pelvis; pylephlebitis, recent infarct of intestine; pulmonary infarct, right; bronchopneumonia, bilateral; and external hemorrhoids.

Autopsy (W. U. Autopsy No. 9413).—There were 3,000 c.c. of bloody ascitic fluid. The tail of the pancreas was expanded to twice normal size by a grayish white, glossy tissue. The remainder of the pancreas was normal. The greater part of the parenchyma of the liver was replaced by metastatic tumor. Metastases were present on the inferior surface of the diaphragm, in all lobes of the lungs, and in the peripancreatic, celiac, and abdominal periaortic lymph nodes. From a point 2 cm. above the orifices of the renal veins the inferior vena cava was filled with a thrombus which extended down through the common, internal, and external iliac veins bilaterally. In addition, the splenic vein was entirely occluded by a thrombus, as were also the portal vein and its intrahepatic radicles. Several of the branches of the pulmonary artery in the lower lobes of the lungs contained emboli. There were a few infarcts in the lower lobes. The veins of the greater omentum were dilated, tortuous, and filled with thrombi. Microscopic section of the pancreatic tumor showed an adenocarcinoma.

Case 2 (Hospital No. Medicine 89921).—A 67-year-old white night watchman was admitted to the Barnes Hospital for the first time on June 3, 1941.

Illness Upon Admission.—Eight weeks before admission he suddenly developed severe pain in the lower abdomen. There was an associated nausea and a change in bowel habits—urge to defecate immediately after each meal. A roentgenologic examination of the gastrointestinal tract at the Barnard Free Skin and Cancer Hospital was entirely negative. Since the onset he had lost thirty pounds in weight. On the day of admission he noticed that the left arm was swollen, slightly painful, and blue.

Past History.—He had been in excellent health until the onset of this illness. He had had pneumonia at the age of 60, but there was no history of other serious illness or injury.

The family history was negative.

Physical Examination.—Temperature, 37.4° C.; pulse, 78; blood pressure 114/70. The left pupil was slightly smaller than the right. The teeth were carious and dirty. The heart and lungs were normal. The abdomen was soft, nontender, and no organs or masses were palpable. The prostate was enlarged to twice normal size and was firm and tender. The entire left arm was swollen, cold, and a mottled blue-red. In the left axillary and supraclavicular region there was a soft swelling.

Laboratory Examinations.—R.B.C., 4,700,00; hemoglobin, 16 Gm.; W.B.C., 15,200, differential normal. Urine, 1 plus albumin, numerous hyaline and granular casts; and 20 to 30 white cells per high power field. Stools, no occult blood and no parasites. The Kahn test was negative and the blood nonprotein nitrogen was 29 mg. per 100 c.c.

Roentgenologic Examination.—A film of the thorax showed only lengthening of the aorta.

Course.—During the fifteen days in the hospital there was a persistent diarrhea, with as many as nine stools in a day. On rest, elevation, and external heat, the swelling and cyanosis of the left arm subsided and the patient was discharged on June 18, 1941.

Second Admission.—The patient was readmitted to the Barnes Hospital on July 7, 1941. Since discharge he had observed gradual enlargement of the abdomen and the appearance of jaundice.

Physical Examination.—In contrast with the first examination, just one month previously, the patient was now markedly emaciated, dehydrated, and jaundiced. The left hand was slightly edematous and a firm cordlike structure could be palpated in the left axillary space. The veins over the left pectoral region were dilated. Over the right lower thorax there were respiratory lag, slight impairment of the percussion note, diminished breath sounds, and many fine crackling râles. Fluid was easily demonstrable in the peritoneal cavity. The veins about the umbilicus were conspicuous. The abdomen was not tender and no masses could be palpated. There was edema over the sacrum and of the lower extremities.

Laboratory Examinations.—R.B.C., 4,200,000; hemoglobin, 75 per cent; W.B.C., 16,200, differential normal; blood nonprotein nitrogen, 45 mg. per 100 c.c.; blood amylase, 12 units per 100 c.c.; and plasma proteins, 5 Gm. with 2.3 Gm. of albumin and 2.7 Gm. of globulin. Urine, 1 plus albumin; 4 plus sugar, and 1 plus acetone; urobilinogen was present in a 1:25 dilution when tested with Ehrlich's reagent.

Course.—On the second day after admission, 4,000 c.c. of yellowish brown fluid were removed from the peritoneal cavity. Examination revealed a specific gravity of 1.007, and 3,000 red blood cells and 100 white blood cells (all lymphocytes) per cm. Histologic study of the sediment for neoplastic cells was indeterminate.

Clinical Impression.—Carcinoma, probably pancreatic; questionable cirrhosis of liver; portal obstruction, probably by metastatic tumor; probable pulmonary metastases; thrombosis of the left subclavian vein; generalized arteriosclerosis; and benign prostatic hypertrophy.

Autopsy (W. U. Autopsy No. 9295).—There were 2,500 c.c. of clear yellow fluid in the peritoneal cavity. The anterior part of the body of the pancreas was large, and the cut surface revealed a hard, white, dry tissue. Distally the pancreatic duct was distended to twice normal size, and contained a viscid, light yellow fluid. The tail of the pancreas had undergone atrophy and fibrosis. Tumor tissue had extended through the walls of the splenic and portal veins, and the lumens were filled with thrombi. The hepatic artery passed through the tumor, and the lumen was obliterated by compression and by a thrombus. There was a constriction of the lower third of the common bile duct by masses of tumor and dilatation of the common and hepatic ducts proximally. Many of the intrahepatic branches of the portal vein contained thrombi. Metastases were present in the liver, all lobes of the lungs, the adrenals bilaterally, and the mesentery of the ileum. Tumor tissue was found in the peripancreatic, celiac, pericecal, and thoracic periaortic lymph nodes extending to the wall of the esophagus. Throughout the tertiary radicles of the pulmonary artery, emboli were present. In all lobes of the lungs except the middle lobe of the right lung there were infarcts. The left subclavian vein was filled with a thrombus distal to the junction with the internal jugular vein. Microscopically the tumor in the pancreas was an adenocarcinoma.

DISCUSSION

The clinical histories and examinations in these two patients were remarkably similar. Both were men in the latter half of life (51 and 67

years) who sought medical advice because of pain and swelling of one or more extremity. The second patient also complained of pain in the lower abdomen and a change in bowel habits. At no time did the first have symptoms referable to the abdominal viscera, except nausea and abdominal discomfort during the last two weeks of life. An abdominal mass was not palpable in either. Both developed terminal jaundice. Both had ascites with the accumulation of a bloody fluid. It is of interest that a brother of the first patient died of some abdominal condition with "thrombophlebitis."

The clinical history was dominated by the signs and symptoms of multiple venous thrombi.

In order to extend the work of Sproul, a review has been made of all cases of carcinoma of the pancreas, whether of the head, body, or tail, in the 9,800 autopsies, records, and slides which are on file in the department of pathology of the Washington University School of Medicine. In the 9,800 autopsies there were thirty cases of carcinoma of the head of the pancreas. Of these not one was associated with multiple venous thrombi. In five there was a single thrombosed vein. Analysis of these five instances showed that in three the wall of the vein was invaded by tumor. In the remaining two the pulmonary arteries contained emboli, which by their shape were thought to have originated in the long veins of the extremities. One of two was associated with cardiac decompensation. Therefore it is obvious that the thrombi found with carcinoma of the head of the pancreas can readily be explained by well-recognized mechanisms.

In the same series of autopsies, twenty-one cases of carcinoma of the body or tail of the pancreas were available for study. Seven, or 33.3 per cent, showed multiple venous thrombi. Ten, or 47.6 per cent, had at least one thrombus. This compares with the figures of 31 per cent and 56 per cent respectively, reported by Sproul. These figures are in marked contrast with those obtained in cases of carcinoma in the head of the pancreas.

Before any conclusions may be drawn concerning the relation of carcinoma of the body and tail of the pancreas and multiple venous thrombi, it is well to review each of the various factors which might conceivably influence the incidence of thrombosis.

Debility.—Debility is no more characteristic of carcinoma of the *body* and *tail* of the pancreas than it is of cancer of the *head* of the same organ, or no more characteristic of this condition than of any other chronic and wasting disease. Since the multiple venous thrombi are found much more frequently in the condition under discussion, debility cannot be the basis for the phenomenon.

Cardiac Decompensation.—Naturally, cardiac decompensation with venous stasis should be considered as an explanation for the clinical picture presented by these patients. In one of the seven cases revealing

multiple thrombi there was clinical evidence of cardiac failure. Digitalization had been carried out and the patient was considered clinically as compensated. Therefore, it is highly improbable that decompensation was the fundamental factor, although it may have contributed in that one case.

Mechanical Pressure.—In the cases reviewed, none that could be explained on the basis of pressure by the primary tumor or lymph nodes containing metastases was considered to represent thrombosis as discussed in this communication. The extent and positions of the thrombi rule out direct compression as a factor.

Invasion of the Vein Wall.—If invasion of the vessels by tumor is a major factor of pathogenesis, then carcinoma of the *body* and *tail* of the pancreas must be markedly different in the invasive potentialities of the cells from carcinoma of the *head* of the pancreas, and from any other malignant tumor yet known arising in any organ. Duff[1] has pointed out the greater tendency for metastasis in carcinomas of the body and tail of the pancreas, as compared with that of the head. Yet it is extremely doubtful whether sufficiently widespread dissemination of neoplastic cells could take place to produce the bizarre and widespread thrombi which occur with this condition. Direct proof that invasion of the venous wall is not the primary cause is supplied by microscopic study, which failed to reveal malignant cells at the sites of the thrombi.

"Thrombophlebitis."—Some patients who actually had carcinoma of the body or tail of the pancreas and who manifested this by multiple and migrating venous thrombosis have been designated as suffering from "migratory thrombophlebitis." It is generally agreed that infection of a vascular wall leads to clotting. Yet in the cases under consideration no infection was noted grossly, and microscopic study of the wall of the vein revealed no inflammatory process.

Disturbed Hepatic Function.—The question may be raised as to whether the role which the liver plays in blood clotting is disturbed in carcinoma of the pancreas, either by obstruction of the hepatic ducts or by destruction of the parenchyma of the liver by metastases. Of the twenty-one cases of carcinoma of the body or tail of the pancreas, only three had no metastases in the liver. These metastases were totally unrelated to the phenomenon of multiple venous thrombosis. It is, furthermore, to be noted that jaundice in these patients, if it occurred at all (five cases only), was terminal and many times not intense. On the other hand, in malignant tumors of the head of the pancreas, obstruction of the bile duct with jaundice is among the first signs. These tumors metastasize to the liver frequently enough and thrombosis is infrequent enough so that it can be stated that neither obstruction to the bile duct nor destruction of hepatic tissue is responsible for the abnormal tendency to thrombosis.

The problem is therefore reduced to the search for a disturbance in the pancreas itself as an explanation. Atrophy and fibrosis of the body and tail of the pancreas might, by reducing pancreatic tissue, remove a normal secretion and bring about an abnormal clotting mechanism. Such a pathologic change of atrophy was observed in ten out of the thirty cases of carcinoma of the head of the pancreas, yet in these cases there was no tendency to thrombosis.

Acute hemorrhagic necrosis of the pancreas damages the organ severely. Twenty-two cases of this condition were reviewed and none showed a tendency to multiple thrombosis. It is true that the veins in the immediate area of damage contained thrombi, but these were not comparable to the generalized thrombosis seen in the cases of carcinoma.

In acute interstitial pancreatitis there are edema, congestion, and infiltration with polymorphonuclear leucocytes. Eight examples of this condition were examined, with negative results.

Increase in the interlobular and intralobular fibrous tissue of the pancreas may be the result of a previous injury, of arteriosclerosis, or it may be a part of the process of ageing. In any event the function of the organ might diminish. Thirty-five patients showing these changes were chosen at random from the same general group as the previously cited instances of carcinoma of the pancreas. None showed multiple venous thrombosis, although seven had a single thrombus. All of these seven may be readily explained: two cases were caused by embolism from a mural thrombus in the heart, two by pyemia, two by cardiac decompensation, and one occurred in an immediate area of injury.

In diabetes mellitus a disturbance of pancreatic function may be postulated, with a dysfunction of at least one type of cell. Accordingly, the protocols of autopsies in twenty-seven diabetic individuals were analyzed. Eleven of these showed hyalinization of the islands of Langerhans. Not one had more than one thrombus, and only three revealed a single thrombus, the basis for each of which was clear: mural thrombus in the heart giving rise to a pulmonary embolus (two cases), and thrombosis of the left femoral and iliac vein following an amputation of the left leg (one case). Furthermore, consideration of such relatively uncommon processes as adenoma of the pancreas (four cases), hemochromatosis of the pancreas (four cases), tuberculosis (one case), and advanced chronic passive congestion of the pancreas (four cases), shows that none of them was associated with thrombosis.

In the group of metastatic tumors destroying the pancreas, leucemic infiltrations are included. Forty-one examples were reviewed and two were found to have multiple venous thrombi without any satisfactory explanation. Both of these were instances of carcinoma of the stomach, and Sproul has pointed out that this tumor is third in the series of carcinomas associated with multiple venous thrombi. Six of this group

showed a single thrombus. Three of these were caused by direct invasion, one by compression, and two were unexplained.

It is clear that only in the case of a primary carcinoma of the pancreas located in the *body or tail* is there a consistent development of multiple venous thrombosis. It appears to be a peculiarity of these tumors that the blood clotting mechanism is disturbed in this way. Either the neoplasms secrete an excessive amount of a substance normally produced by the pancreas and involved in the clotting of blood, or they give rise to an abnormal substance which hastens clotting. Sproul has made several suggestions as to how the clotting mechanism may be disturbed.

The microscopic appearance of the tumors of the body and tail was studied and it was found that thirteen contained mucinous foci. All examples of multiple thrombi fall within this group. Sproul noted that all except one of her patients with multiple thrombi had mucinous foci. Inasmuch as some tumors contained mucin and were not associated with thrombi, Sproul felt that no causal relation could be expressed. Nevertheless, it is striking that no tumor without mucin shows the phenomenon. Of the thirteen cases showing mucin, seven had multiple thrombi. In two, autopsy permission was limited to an examination of the abdominal cavity, and no statement could be made regarding the condition of the veins. In one there is some question as to whether the tumor arose in the head or body. Under a favorable interpretation, therefore, only three out of the thirteen cases showed mucin and no thrombi. Whichever view is taken it can be said that the phenomenon of multiple thrombosis occurs exclusively within the group of mucinous carcinomas. This lends support to the idea that primary carcinomas of the *body and tail* produce an excess of a substance which enhances the clotting mechanism. Further evidence is given by the studies of Sugiura, Pack, and Stewart[7] who extracted an adenocarcinoma of the body and tail of the pancreas and compared the result with the extract of three normal pancreases. The enzymatic action of the extract on starch, casein, peptone, and esters was comparable with the normal, that is, the tumor had a physiologic resemblance to normal pancreas.

The mucinous tumors of the pancreas may arise from the ducts. Kiefer[4] states that cylindric epithelial cells are of ductal origin; Ewing[2] concurs and mentions a rare gelatinous change; Karsner[3] feels that the cylindrical cells arise from the ducts but points out the fallacy of such a morphologic comparison when dealing with malignant tumors. It is possible that the ductal epithelium, normal or neoplastic or both, elaborates and secretes a substance that is concerned with the clotting of blood.

CONCLUSIONS

Two cases of carcinoma of the pancreas, one of the body and one of the tail, are reported. In both, multiple venous thrombosis was a prominent feature of the clinical and pathological picture.

Thirty cases of carcinoma of the head, and twenty-one of the body and tail of the pancreas are reviewed. Carcinoma of the body and tail is associated with multiple venous thrombosis in a high percentage (33 per cent), whereas carcinoma of the head shows no such striking association. Considering the difficulty of performing a really complete autopsy with an adequate examination of all veins, and in view of the ease with which a past history suggestive of multiple venous thrombi may be passed over as unimportant, even such high figures may be too low.

In view of the great difficulty in making a diagnosis of carcinoma of the pancreas early enough to be of any practical aid to the patient, the value of an early diagnostic sign is obvious. It is urged, therefore, that in every patient either suspected or known to have such a tumor, all factors of the blood clotting mechanism be studied energetically. It may be that some difference not yet suspected may become apparent or a new substance be isolated. This would in turn act as a diagnostic agent in the future. Further, in any case of so-called "migratory thrombophlebitis" the possibility of the diagnosis of carcinoma of the body or tail of the pancreas must be considered.

Carcinoma of the body and tail of the pancreas is not so rare in comparison to the incidence of carcinoma of the head as one would be led to believe by many reports (twenty-one cases compared to thirty cases in a series of 9,800 autopsies).

Extrinsic factors such as debility, cardiac decompensation, mechanical pressure, invasion of the venous wall, phlebitis, and damage to the liver were considered and found to be inadequate to explain the phenomenon.

Intrinsic factors were also reviewed. These are atrophy and fibrosis of the body and tail of the pancreas, acute hemorrhagic necrosis of the pancreas, acute interstitial pancreatitis, interlobular and intralobular fibrosis, diabetes, adenoma, hemochromatosis, tuberculosis, and chronic passive congestion. None of these are any more satisfactory as an explanation than invasion of the pancreas by metastatic tumors.

It is concluded that carcinoma of the body and tail of the pancreas is unique in being associated with multiple venous thrombi, and it is suggested that these tumors may secrete an abnormal substance or an undue amount of a normal substance concerned in blood clotting. This assumption is supported by the fact that in every case showing multiple thrombi the tumor is of the mucinous type. A thorough study of all factors in the clotting mechanisms of patients with this neoplasm is urged, in the hope that a characteristic change may be discovered and used as a diagnostic method.

To members of the Department of Pathology, Washington University School of Medicine, acknowledgment is gratefully made: to Dr. R. A. Moore for critical readings and many suggestions, and to Dr. E. B. Helwig and Dr. I. I. Goodof for reviewing the microscopic sections. Thanks is due Dr. G. E. Lindskog of the Department of Surgery, Yale University School of Medicine, for corrections and help on this paper.

REFERENCES

1. Duff, G. L.: The Clinical and Pathological Features of Carcinoma of the Body and Tail of the Pancreas, Bull. Johns Hopkins Hosp. 65: 69-98, 1939.
2. Ewing, J.: Neoplastic Diseases, Ed. 4. Philadelphia, 1940, W. B. Saunders Company.
3. Karsner, H. T.: Human Pathology, Ed. 5, Philadelphia, 1931, J. B. Lippincott Company.
4. Kiefer, E. D.: Carcinoma of the Pancreas, Arch. Int. Med. 40: 1-29, 1927.
5. Ransom, H. K.: Carcinoma of the Body and Tail of the Pancreas, Arch. Surg. 30: 584-606, 1935.
6. Sproul, E. E.: Carcinoma and Venous Thrombosis: the Frequency of Association of Carcinoma in the Body or Tail of the Pancreas With Multiple Venous Thrombosis, Am. J. Cancer 34: 566-585, 1938.
7. Sugiura, K., Pack, G. T., and Stewart, F. W.: A Study of the Enzyme Content of a Parenchymatous Adenocarcinoma of Pancreas and a Comparison With the Normal Human Pancreas, Am. J. Cancer 26: 351-357, 1936.

LIGATION OF THE SUPERIOR MESENTERIC VEIN

EDWARD SCHNUG, M.D., CINCINNATI, OHIO

(From the Department of Surgery, College of Medicine of the University of Cincinnati, and the Cincinnati General Hospital)

MUCH has been written on the subject of spontaneous occlusion of the superior mesenteric vessels, but discussions on the course and treatment of injuries to these vessels have been neglected. It has been an accepted fact that the spontaneous occlusion of either the superior mesenteric artery or vein carries a nearly 100 per cent mortality rate. Isolated cases have been reported where slow occlusion of the superior mesenteric artery occurred, giving time for sufficient collateral circulation to develop and maintain the viability of the intestine. I have found no report of a patient surviving after a sudden complete occlusion of the superior mesenteric vein. We recently had a patient, the victim of a gunshot wound of the abdomen, who recovered following the ligation of the superior mesenteric vein. A report of this case follows:

E. C., a 38-year-old colored man, was admitted to the Cincinnati General Hospital about thirty minutes after receiving a gunshot wound of the abdomen.

Examination revealed a well-developed and well-nourished colored man lying flat in bed. He was quite uncooperative, which made the examination difficult. Temperature was 98° F., pulse 72, respirations 18, and blood pressure 110/70. The patient's skin was warm and he showed no external evidence of shock. His head and neck showed no remarkable findings. Examination of the chest revealed no positive findings.

In the left abdominal wall 2½ cm. above and 2½ cm. lateral to the umbilicus was found a bullet wound of entrance. The abdomen was scaphoid and showed generalized tenderness and rigidity. Peristaltic sounds were absent. Liver dullness was normal.

Palpation of the back revealed the bullet to be lying just under the skin and just to the right of the midline at about the level of the fourth lumbar vertebra. There was moderate tenderness of the lower lumbar spine, but no deformity was demonstrated.

Rectal examination revealed slight relaxation of the sphincter. No tenderness or gross blood was encountered.

A neurologic examination revealed normal cranial nerves. The reflexes and motor power in the upper extremities were normal. Motor power was present in the left leg, but the patient was unable to move the right leg. Reflexes in the lower extremities were absent bilaterally. The Babinski test produced no response. A sensory examination was impossible due to lack of cooperation from the patient.

Examination of a catheterized urine sample was negative. The white blood count was 15,800.

The diagnosis was made of a gunshot wound of the abdomen and spine with probable penetration of the stomach and cauda equina injury.

Received for publication, April 8, 1943.

X-ray pictures of the abdomen and spine revealed no free gas under the diaphragm, and the bullet was seen just to the right of the fourth lumbar vertebra. A fracture of the right lamina of the fourth lumbar vertebra was present.

An exploratory laparotomy was done through a long right rectus incision under cyclopropane anesthesia. Only a small amount of free blood was found in the peritoneal cavity. Perforations of the anterior and posterior walls of the stomach near the lesser curvature were found and were closed with interrupted silk sutures. The abdomen was thoroughly explored and no other injuries to the hollow organs, liver, kidneys, or spleen were found. However, in the region of the pancreas and third portion of the duodenum there was a large retroperitoneal hematoma. A clot which was located on the lower border of the pancreas was removed from the bullet tract in the posterior peritoneum and rapid bleeding ensued. The third portion of the duodenum was then mobilized, and no perforation in the duodenum was found. Mobilization of the lower border of the pancreas revealed the bleeding to be venous in character and arising from the region of the superior mesenteric vessels. Temporary hemostasis was obtained by compressing the superior mesenteric vein above and below the injured site. The superior mesenteric vein was then dissected out and was carefully separated from the superior mesenteric artery coursing next to it. No injury to the artery was found. Because of the patient's poor general condition, and due to the large size of the defect in the vein, it was decided that a repair of the vessel was not advisable. The vessel was divided and doubly ligated with double medium silk ligatures.

Following the ligation several interesting changes occurred. The vein distal to the ligature, of course, became markedly dilated, and the superior mesenteric artery also seemed to dilate slightly. The muscle tone of the entire small bowel became markedly increased and peristalsis became extremely active. Subserosal petechiae appeared over the surface of the small intestine and the venous radicals in the mesentery became dilated, but no definite diffuse cyanotic color appeared in the bowel.

The peritoneal cavity was dusted with 6 Gm. of sulfanilamide powder, and the abdomen was closed with through and through steel wire sutures. The patient left the operating room in fair condition. The Levin tube which had been inserted into the patient's stomach preoperatively was connected to a Wangensteen suction, and the patient was given continuous nasal oxygen. The patient had received 500 c.c. of blood and 700 c.c. of saline solution intravenously during the operation.

In accord with the advice of Dr. Louis Herrmann, heparinization was begun four hours after operation, using the continuous method and administering the drug through a continuous venoclysis inserted into the saphenous vein. The patient was given 1,000 units of heparin each hour in a normal saline solution. Determinations of the clotting time, using the capillary tube method, were made every four hours until it became maintained at between ten and fifteen minutes. After the first twenty-four hours the clotting time was nicely maintained at this level, using 1,000 units of heparin each hour. The heparinization was continued for five days after the operation, during which time no clinical evidence of bleeding either internally or externally appeared. Intravenous sulfadiazine, 4 Gm., were given daily for six days and 2 Gm. a day were given for the next three days. On the fourth postoperative day peristalsis appeared and the Wangensteen suction was discontinued. The patient received a unit of plasma on the second and third days postoperatively and after heparin therapy was discontinued, he received frequent blood transfusions. The patient's fluids were maintained with intravenous saline and glucose solutions.

On the eighth day after operation the patient began vomiting, and the Wangensteen suction was again instituted. Attempts were made to discontinue the gastric suction during the next few days, but vomiting always reappeared.

On the thirteenth day after operation an upper gastrointestinal x ray series was done, which revealed a complete obstruction of the third portion of the duodenum. This obstruction failed to respond to conservative therapy and on the sixteenth postoperative day an exploratory laparotomy was done through a right rectus incision under gas oxygen ether anesthesia. Exploration of the abdomen revealed numerous adhesions throughout the upper abdomen. These adhesions were extremely abundant in the region of the third portion of the duodenum and the adjacent border of the pancreas. They appeared to have arisen as a reaction to secretions from the injured pancreas. Examination of the small intestine revealed patchy cyanotic areas throughout its length, with many patches of organizing subserosal hematomas in the mesentery. The bowel wall seemed quite viable and healthy, normal in diameter, and peristalsis was present (Fig. 1). The veins in the mesentery of the small bowel and right colon seemed slightly distended. The superior and inferior pancreatoduodenal and gastric epiploic veins were quite markedly dilated The colon appeared quite normal except for adhesions around the mid transverse colon which were continuous with those around the pancreas.

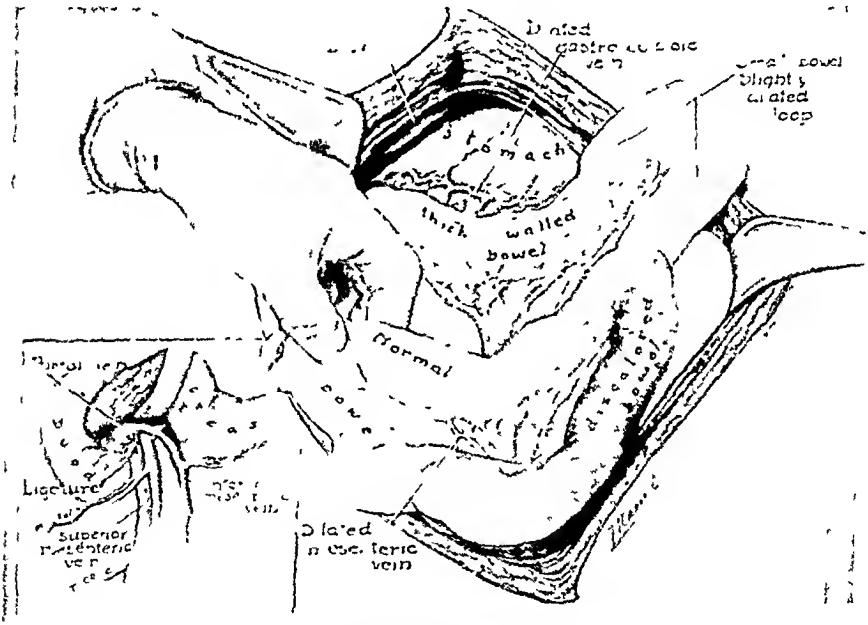

Fig 1—Appearance of the bowel, mesentery, and blood vessels at the time of the second operation.

An attempt was made to free the adhesions around the third portion of the duodenum and, if possible, to expose the superior mesenteric vessels in this region Because of the abundance and density of the adhesions it was impossible to separate the scar tissue overlying these structures. It was then decided to do an anterior gastroenterostomy, using a loop of jejunum distal to the ligament of Treitz. This procedure was then done without difficulty. Sulfanilamide was placed in the peritoneal cavity and the abdomen was closed with through and through steel wire sutures

Using continuous Wangensteen suction, intravenous sodium, sulfadiazine and parenteral fluids, plasma, and blood after operation, the patient continued on to a

complete recovery except for residual neurologic changes in the right lower extremity. He was discharged on his sixty-second hospital day.

He has been seen on several occasions since his discharge from the hospital. He is now on a general diet and gaining weight. He has no complaints referable to the abdomen but still does have quite marked weakness of the right leg. The abdominal wound is well healed.

The study of this case brings up for discussion several interesting practical points. The pathways through which an adequate collateral venous return was accomplished are immediately conjectured upon (Fig. 2). In 1868, Chiene[1] reported the findings of an autopsy which illustrated very nicely the collateral circulation between the visceral and parietal vessels of the abdomen. This necropsy was performed upon a patient with an aneurysm of the abdominal aorta which had, due to the formation of a laminated clot, caused the development of a complete obstruction to the celiac, superior, and inferior mesenteric arteries. It was definitely proved that the obstruction of these vessels was of long duration, and yet the blood supply of all the viscera seemed entirely adequate. With the blood vessels injected, a thorough dissection of abdominal and pelvic vessels was carried out. There had developed a good collateral circulation with the ileocolic artery through the last dorsal, lumbar, and ileolumbar vessels. A branch from the splenic artery supplied the splenic flexure of the colon, anastomosing with the arterial loop formed by the middle and left colic arteries. The superior hemorrhoidal artery was as large as the femoral and anastomosed with the ischiatic, lateral sacral, and middle hemorrhoidal arteries, all of which were dilated. It seems quite logical to assume that a collateral venous circulation may develop through the same collateral pathway by the venae comites of these arteries.

Additional collaterals between the systemic and portal circulation have been described in the standard textbooks of anatomy. Communicating veins are consistently found between the left renal vein and the middle colic veins. The left renal vein also communicates with the inferior pancreatoduodenal vein. There are connecting veins between the retroperitoneal branches of the inferior vena cava and the mesenteric veins of the intestine, the so-called veins of Retzius.

It was definitely noted in our patient at the time of the second operation that the superior and inferior pancreatoduodenal and gastric epiploic veins were definitely dilated. The superior mesenteric vein had been ligated above the origin of the inferior pancreatoduodenal vein, thus allowing a collateral venous return from the proximal portion of the small intestine to pass through the inferior and superior pancreatoduodenal veins to the gastroepiploic and thence to the superior mesenteric vein above the point of injury. The transverse colon was involved in a mass of adhesions so that the middle and left colic veins in that region could not be visualized, but, undoubtedly, the anastomosis be-

tween these two vessels must account for some of the venous flow from the right and transverse colon. The ileocolic vessels were not exposed, but a collateral could be developed between this vessel, the last dorsal, lumbar, and ileolumbar veins. The veins of Retzius may be added to this collateral venous system.

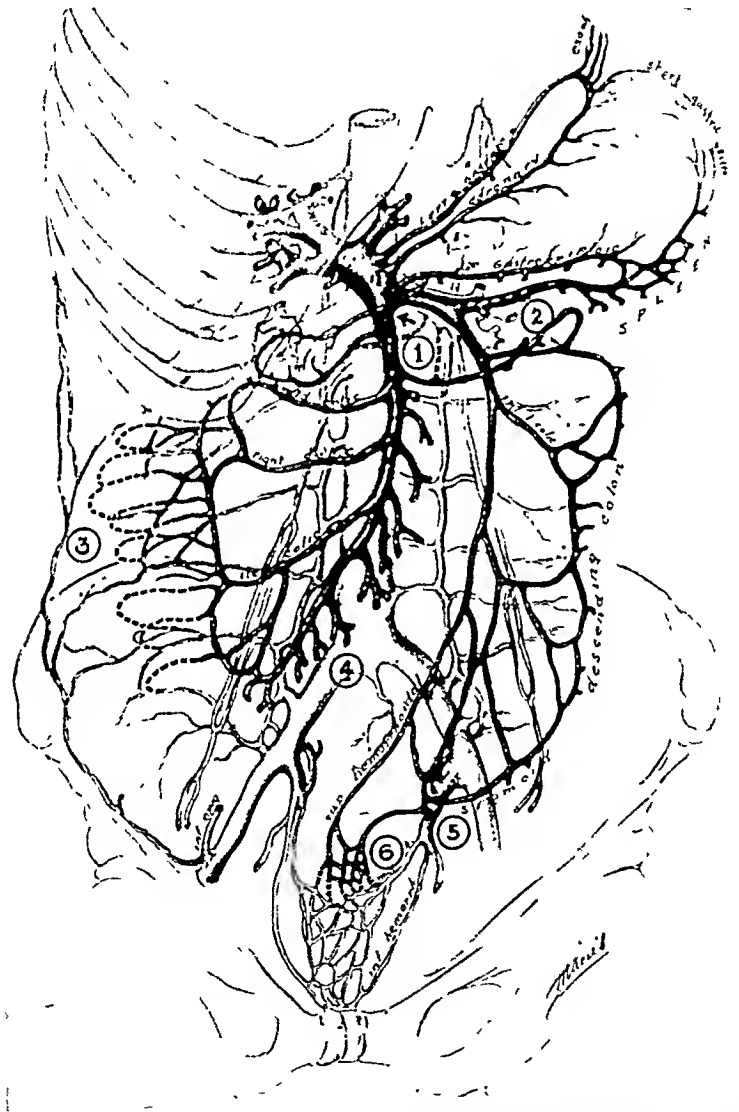

Fig. 2.—Arrow indicates point of ligation of superior mesenteric vein. *1*, Anastomoses between superior and inferior pancreatoduodenal veins, also between inferior pancreatoduodenal and left renal veins. *2*, Anastomoses between superior and inferior mesenteric veins through middle and left colic veins, also between middle colic and left renal veins. *3*, Anastomoses between ileocolic and right colic veins, and ileolumbar and last dorsal veins. *4*, Anastomoses at base of mesentery between superior mesenteric and inferior vena cava through the veins of Retzius. *5*, Anastomoses between the sigmoid and hypogastric vein. *6*, Communications between the superior and middle hemorrhoidal veins.

This patient was given continuous heparin therapy beginning four hours after operation and continuing for five days. This therapy undoubtedly played an important role in the re-establishment of the mesenteric venous circulation. Murray[2] and Laufman[3] have done experimental work in regard to the use of heparin in patients with mesenteric thrombosis. Both agree that heparinization tends to prevent the spread of the thrombotic process. Laufman believes that in cases of extensive infarction (over 5 to 10 cm.) heparin is harmful in that it promotes extravasation of blood into the wall and lumen of the bowel and thus produces shock and death. He does advise its use in conjunction with resection when only short segments of bowel are involved. We feel that in cases of extensive involvement, as well as in the less severe cases, heparinization may be of definite benefit. If given early, heparin keeps the stagnant blood in the venous channels in a fluid state, giving time for the collateral channels to dilate and develop sufficiently to take over the return venous flow. If the veins within the bowel wall and the mesentery are allowed to thrombose, then the development of collateral circulation is, of course, impossible.

In any patient with impaired circulation of a part, it is extremely important to maintain a normal blood pressure, normal blood volume, and normal oxygenation of the blood. Special attention was given to these factors in this patient's treatment. This patient's blood volume and blood pressure, in spite of severe bleeding, was maintained during and after operation by intravenous fluids, blood, and plasma. In addition, he was given continuous oropharyngeal oxygen after operation. In any patient where the development of an adequate collateral circulation is necessary to maintain the viability of a tissue, the maintenance of adequate blood pressure, blood volume, and normal oxygenation is of vital importance.

COMMENT

In studying this case, one immediately suspects that this patient may have an accessory superior mesenteric vein which took over the venous return from the small bowel. This is certainly possible, although we believe it to be quite improbable. It was noted at the operating table that, after the ligation of the superior mesenteric vein, the small intestine developed a tonicilike contraction of the muscles in the bowel wall. This I have observed in dogs following the ligation of the mesenteric vein. The mesenteric veins became dilated, and subserosal petechiae appeared almost immediately. At the second operation, residual organizing subserosal hematoma were still present and the bowel wall still retained a cyanotic color in several scattered areas. This patient had an extensive injury of the vein with much destruction of vein wall which made it impossible to repair the vessel. In cases where a repair of the vessel is possible, it is probably the procedure of choice.

CONCLUSIONS

1. A case report and discussion of a patient who survived following the ligation of the superior mesenteric vein has been recorded.

2. In patients with spontaneous occlusion of the superior mesenteric vein the mortality rate closely approaches 100 per cent.

3. The potential pathways for the development of collateral circulation incident to complete obstruction of the superior mesenteric vein were reviewed.

4. The importance of early, adequate, and continuous heparinization as an aid to the development of collateral venous channels is stressed.

5. The development of an extensive collateral circulation requires the maintenance of adequate blood pressure, blood volume, and normal oxygenization of the blood.

REFERENCES

1. Chiene, J.: Complete Obliteration of the Celiac and Mesenteric, Arteries, J. Anat. & Physiol. 3: 65, 1869.
2. Murray, G. D. W.: Heparin in the Surgical Treatment of Blood Vessels, Arch. Surg. 40: 307-325, 1940.
3. Lautman, H.: The Effect of Heparin on the Behavior of Infarction of the Intestine, Surg., Gynec. & Obst. 74: 479-482, 1942.
4. Murray, G. D. W.: Heparin in Thrombosis and Embolism, British J. Surg. 40: 567-598, 1940.

THE TREATMENT OF ACUTE EMPYEMA BY CONTINUOUS TIDAL IRRIGATION*

EDGAR J. POTH, PH.D., M.D., GALVESTON, TEXAS, AND
MARY E. MATHES, M.D., SAN FRANCISCO, CALIF.

(From the Department of Surgery, University of Texas Medical Branch, Galveston, and the Department of Surgery, Stanford University School of Medicine, and Hospital for Women and Children, San Francisco)

BECAUSE of its frequency, empyema thoracis is the most important surgical lesion of the pleura. The nature of the lesion was recognized by Hippocrates, who advocated treatment by drainage. The treatment is complicated by one's inability to put the part to rest and by the property of the lung of collapsing and creating a large cavity or dead space. To effect a cure the attendant infection must be arrested, all foreign material removed, and the dead space obliterated.

The principles underlying the mechanics of respiration should be understood by the surgeon treating this disease, and he should appreciate the possible disastrous consequences of an untimely opening of the thoracic cavity to communicate freely with the outside.

The aim of the treatment of acute empyema is twofold: preservation of the life and the prevention of the development of a chronic disease. This aim is realized by the proper application of any procedure which will give early, free, and efficient drainage to the cavity, prevent paradoxical respiratory movements of the mediastinal structures, and allow the lung to re-expand to fill the cavity and obliterate the dead space. If a dependent outlet is provided, good drainage results. Resection of the proper rib will allow effective drainage, but this procedure has some disadvantages, especially in children. A simple tube introduced between the ribs does not permit adequate drainage. A tube can be placed through the chest wall at the lowermost level of the cavity, but unfortunately the material to be removed must find an exit through an opening in the tube. This opening cannot rest in the most dependent portion of a pleural cavity and remain patent for any length of time. The pus and secretions can, however, be effectively removed through a tube if they are diluted and flushed away.

Numerous schemes[1-5] have been devised to provide continuous irrigation of empyema cavities. Hart[5] obtained good immediate and late results by employing tidal irrigation. The main difficulty with most of these procedures arises from the complicated apparatus used. A scheme for tidal drainage is presented in this communication, for which the apparatus is felt to be simple. If the principles governing

*The major portion of this work was done in the Lane Hospital of the Stanford University School of Medicine and the Hospital for Women and Children, San Francisco, Calif.

Received for publication, April 3, 1943.

the action of this device are understood, the details of its operation become self-evident.

Paradoxical respiratory movements of the mediastinal structures are prevented if tube drainage is employed, or if open operation is postponed until frank pus is present. It should be recalled, however, that chronic empyema is more frequent after delayed operation, and in massive synpneumonic purulent effusions and putrid empyema following the rupture of large pulmonary abscesses, it occasionally seems imperative to establish drainage before the mediastinum has become stabilized. These persons have extremely low respiratory reserve and must be guarded very carefully from even minor paradoxical respiratory movements. Likewise, immediate drainage may be necessary on the occasion of a spontaneous pyopneumothorax or so-called "tension pneumothorax" to relieve high intrathoracic pressure. Ordinarily pus is present under considerable pressure, and when thoracotomy is performed the mediastinal tissues will shift toward the affected side. The mere shift of the mediastinal structures following an ill-advised rib resection does not cause all the untoward symptoms solely because of the reduction of the respiratory reserve; they are also due to the superimposition of paradoxical respiratory movements preventing the noncollapsed portion of the lung from filling and emptying efficiently. The tidal air flows in and out of the lungs because of a difference in pressure between the air in alveolar spaces and the atmospheric air. In the absence of an adequate respiratory reserve a rather insignificant paradoxical movement might make it impossible for these differences to be established. Another abnormal mechanism which inhibits proper aeration results when air from the functioning portions of lungs is forced into the collapsed areas on expiration, and then on inspiration this same spent air flows back into the functioning portion. This phenomenon occurs when there is a considerable to-and-fro flow of air between a pleural cavity and the outside through a large hole in the chest wall.[6] The duration of the disease will not necessarily determine the mobility of the mediastinum. Where considerable pleural thickening occurs early, the mediastinal structures will become fixed in a relatively short time. In conditions such as exist in hemolytic streptococcal infections, however, fixation will not take place until much later.

Treatment with irrigations is an efficient method of removing layers of fibrin from the pleural surfaces, and as soon as these surfaces are clean, the lung will re-expand to obliterate the dead space and heal the empyema. Two conditions may prevent this course; first, rare instances of pulmonary fibrosis, and second, atelectasis due to a plugged bronchus. When re-expansion is unduly delayed, bronchoscopic examination may reveal a bronchus plugged with mucus which can be removed by direct aspiration.

It must be emphasized that consistently good results are obtained only by conscientious observation of and attention to the minute de-

ails of the treatment and course of the disease. This statement is true egardless of the form of treatment. Particular attention should be iven to the patient's nutrition. Many of these patients have endured prolonged debilitating illness and are in poor physical condition. However, when efficient drainage is established the fever disappears nd the appetite is restored. A high vitamin, high calorie diet will be elished. As in most diseases affecting the respiratory apparatus, food, est, and good hygienic conditions contribute much toward recovery.

Points in Diagnosis and Preliminary Studies.—The diagnosis of empyema frequently is overlooked because the condition is not suspected. So-called unresolved pneumonia is usually unrecognized empyema. The absence of physical signs should not be considered as sufficient to exclude the diagnosis of empyema, and x-rays should be taken. The presence of a scoliosis following pneumonia with the concavity toward the affected side is highly suggestive of empyema. The final positive diagnosis must rest on the aspiration of pus. This pus must be examined for tubercle bacilli when pyogenic organisms cannot be demonstrated. It must be realized that the pus of an empyema following pneumococcus pneumonia is frequently sterile when first obtained by thoracentesis.

At the time of making a diagnostic puncture one should be prepared to remove as much pus as possible. Pus under pressure should not be left in contact with a puncture wound. Meningitis, pericarditis, and other blood-borne infections are favored by such a procedure. Pus is removed until respiratory distress is relieved. Then air is injected and pus withdrawn alternately in small equal amounts until the cavity has been evacuated of purulent exudate. The use of a three-way cock and syringe makes this a simple bedside procedure and ensures accurate control over the quantities of fluid withdrawn and air injected.

This combined aspiration of pus and injection of air serves several functions: (1) It relieves pressure; (2) it decreases the surface area bathed by pus and so reduces toxic absorption; (3) it reduces the required frequency of aspiration in the event that thoracotomy is delayed, because the slowly absorbed air compensates for the reaccumulation of pus; (4) it keeps the cavity partly distended and lessens the likelihood of early pocket formation; (5) it permits accurate x-ray visualization of the extent and nature of the cavity; and (6) it occasionally results in a cure of the empyema.

If x-ray pictures are taken with the patient in various positions a complete and accurate outline of a cavity is obtained. A loculate cavity will show several fluid levels. Multiple cavities and cavities connected by narrow channels are easily demonstrated. An unsuspected, accompanying interlobar collection of fluid may become evident because of the visualization afforded by this double contrast technique. A knowledge of the extent and outline of the fluid collection will direct the plan of attack as well as be extremely helpful during the course of

therapy, especially should complications arise. As suggested by Danna,[7] a large quantity of air serves much better than a small amount.

While repetition of aspiration and air injection is seldom necessary before thoracotomy is done, it should be performed as frequently as necessary to relieve respiratory distress. This procedure combined with the administration of sulfanilamide will cure a certain percentage of the patients with streptococcal infections if they are not seen too late.

The Institution of Drainage.—When the decision has been made that drainage is necessary, when the pus has become thick and fibrinous, and when it has not been possible to demonstrate the presence of acid-fast organisms, simple tube thoracotomy is done. While this is ordinarily a bedside procedure, it must be done in a very exact manner. An accumulative experience has shown that certain precautions must be taken.

First, a No. 22 French urethral catheter (Robinson) of medium stiffness is selected and prepared. The size of this tube is not determined by the size or age of the patient, but by the character of the material to be removed. About one-third of the length of the catheter is cut off, and the end is cut on a bevel. Four to six small fenestras are cut in the distal two inches of the catheter. Not for the purpose of making the tube a better drain but with the idea of making its end more flexible and reducing the pressure it might exert against tissues pressed upon.

Second, the tube is placed as near the center of the cavity as possible. It is undesirable to place the tube at the edge of the cavity because healing occurs at the periphery and would encase the drainage tube in a heavy fibrous tract. Also, the tube must not come in contact with the diaphragm. Capps and Coleman[8] made an extensive study of pain arising from the human pleura by tactile stimulation of various locations. The visceral pleurae are insensitive. Stimulation of the parietal pleura causes sharp local pain due to the rich supply of sensory fibers from the intercostal nerves. The central portion of the diaphragmatic pleura receives its nerve supply from the phrenic nerve, and the peripheral rim of the diaphragmatic pleura for two to three inches is innervated by the seventh to the twelfth intercostal segments. Stimulation of the central portion of the diaphragm gives rise to pain referred to the neck through afferent impulses along the phrenic nerve and transmitted as efferent impulses out the third and fourth cervical segments. The region of maximum pain is most frequently along the ridge of the trapezius muscle and is characterized by a point of maximum pain and tenderness surrounded by a zone of hyperesthesia and hyperalgesia. Irritation of the peripheral rim of the diaphragm will cause pain referred to the lower thorax, abdomen, and lumbar region. Drainage tubes and packs against a mobile diaphragm are not tolerable. Few surgeons have escaped the embarrassing experience of operating on a child for appendicitis when the symptoms were due to an early pleurisy.

A location anterior to the posterior axillary line between the fifth eight ribs is the site of choice for tube thoracotomy. Thus the sca is avoided, the arm movements are not interfered with, and the pat can lie on his back without pressing on the tube.

Third, the site having been chosen, an exploratory puncture is n with a large needle, and the pressure is relieved. With the need place, the skin and subcutaneous tissues are incised parallel to th

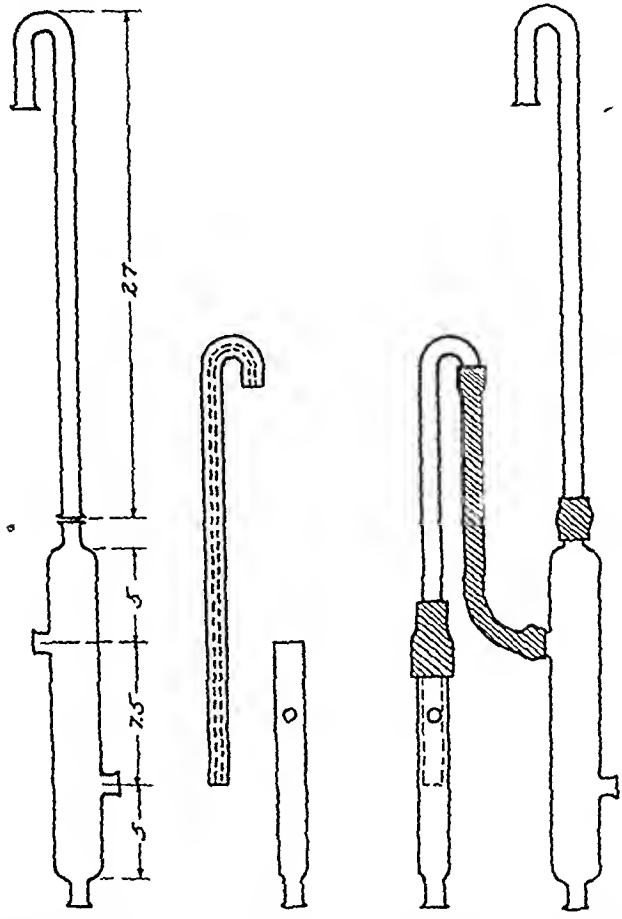

Fig. 1.—Illustrating the special glass parts of the irrigator, dimensions in meters and drawn to scale. The capillary siphon tube has an inside diame 2 mm.

Note. These dimensions should be rigidly adhered to. The "breather hole" be present in the simple glass connector tube. (These glass parts can be ob from Richter and Drube, 611 Mission Street, San Francisco, Calif.)

margin. The incision must be sufficiently long to hold the tube lo as illustrated in Fig. 4. If the skin does not fit snugly against the ber tube, any leakage around the tube will come to the surface will not dissect subcutaneously to form an abscess of the chest In this series this complication did not occur during treatment

two occasions the tube was deliberately placed through pre-existing abscesses and served to drain the lesion. The course of the exploring needle being followed, a suitable trocar is passed through the chest wall into the empyema cavity. Occasionally, it is desirable to pass obliquely through the intercostal muscles. The catheter is inserted

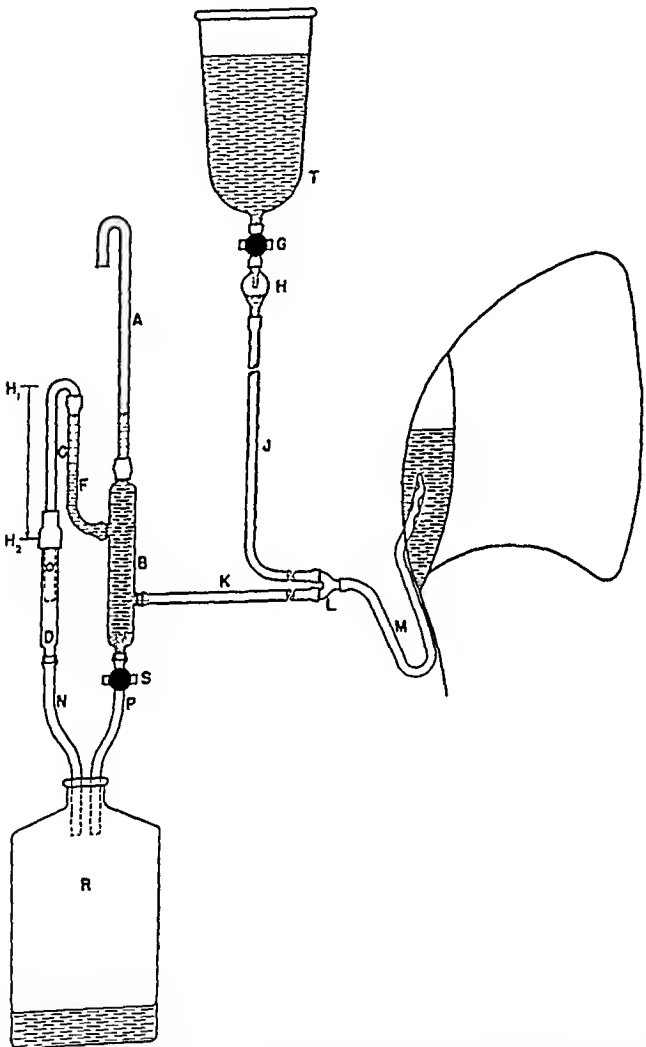

Fig. 2 - [illegible] assembly of the simplified irrigator and its attachment to t[illegible] tubes J and K should be long enough to permit the patient to [illegible] When the apparatus is attached to a small child, these tubes should be long enough to allow the child to play and to stand up in its crib. Tube K must not hang in a loop, because the formation of "airlocks" will interrupt free tidal irrigation.

into the cavity for a distance of three to four inches, but this is never done against resistance. The tube should extend well into the cavity for five to seven days to permit the wall of the tract to become fixed.

Should the end of the tube escape from the cavity and come to lie in the chest wall, it can seldom be replaced through the same opening. Once the tract has become stabilized by granulation tissue, the catheter is withdrawn until its lowest fenestra is about one inch inside the boundary of the parietal pleura. Externally the tube is fixed to the chest wall as shown in Fig. 4. This method of fixation contributes much to the success of the treatment and to the comfort of the patient.

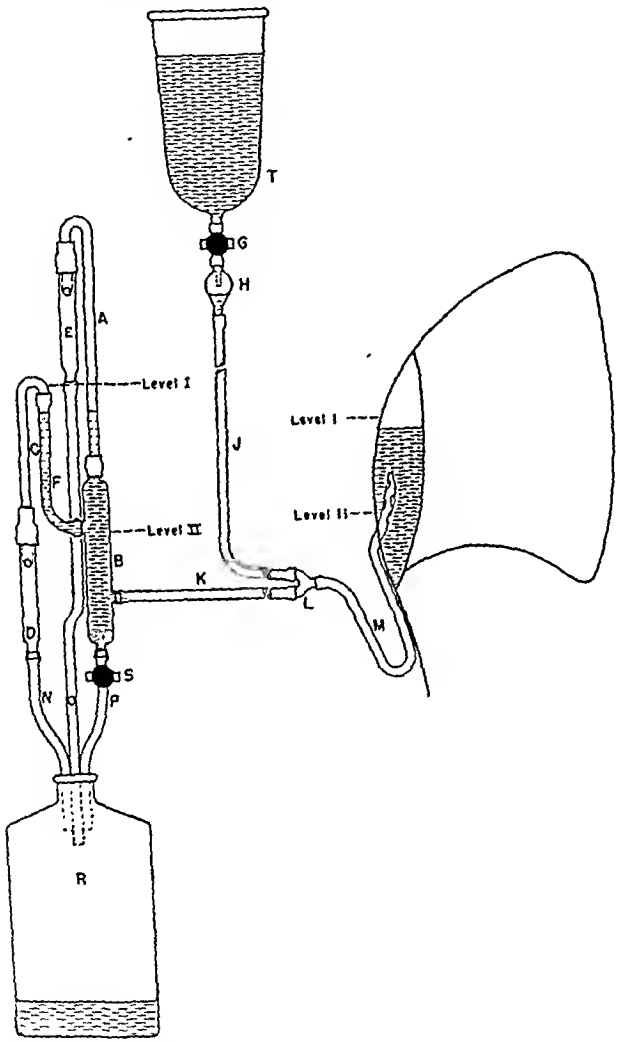

Fig. 3.—Tube *E* is added to the apparatus shown in Fig. 2. This attachment serves to carry fluid into the waste bottle *R* should the patient force fluid through *A* during a paroxysm of coughing. Stopcock *G* is adjusted to deliver 20 to 30 drops of the irrigant per minute. This fluid divides at *L* to pass into the pleural cavity or into the container *B* to change the fluid level from *Level II* to *Level I*. At *Level I* this siphon *C* overflows to drain the apparatus and the chest cavity to *Level II* and *II* respectively.

Note: The siphon must drain slowly enough to allow emptying of the chest cavity as the fluid level in the apparatus falls. The "breather-holes" in *E* and *D* must be open.

Since the patient can move about without fear of pain from slipping and dragging of the tube, there is much less restriction of movement Should the intercostal space be insufficient to receive the drainage tube without compression or without causing pain, a portion of rib should be resected.

The Technique of Treatment.—In the treatment of acute empyema a dynamic system is concerned, and the part cannot be placed at complete rest. Changes occur continuously which must be recognized and dealt with as soon as they take place. If the formation of a pocket is recognized early, simple distention of the general empyema cavity will break down the wall of the pocket

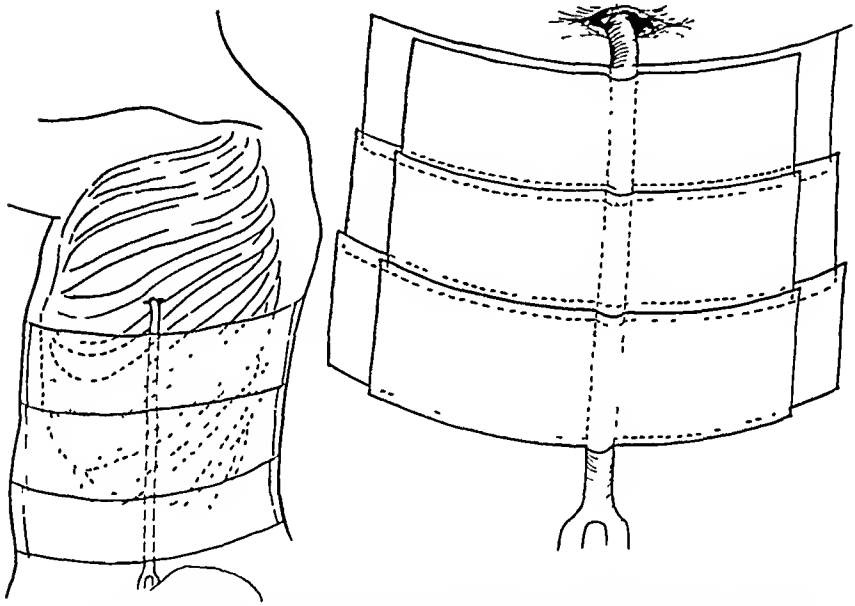

Fig 4 —Illustrating the technique of fixing the thoracotomy tube to the chest The skin must not fit snugly around the thoracotomy tube which is placed in the midaxillary line whenever possible A single sponge dressing protects the thoracotomy wound

The irrigator (Fig 3), filled with normal saline solution, is attached immediately after the introduction of the catheter The top of the siphon and the outlet tube, *F*, are placed at approximately the level of the chest, *Level II* Cock *G* is adjusted to deliver 30 to 40 drops per minute of physiologic normal salt solution continuously, which serves to wash the diluted pus out of the system beyond the catheter *M* After twelve to twenty-four hours, depending upon the condition of the patient, the siphon tube *C* is raised to a position about 15 cm above the outlet tube of chamber *B* This adjustment initiates automatic tidal irrigation with a flow and ebb into and out of the cavity to dilute and wash away the exudate Obviously, the height of the

entire apparatus determines the maximum and minimum pressures in the cavity. Continuous suction below atmospheric pressure should never be applied during the early stages of the treatment of uncomplicated acute empyema because of the likelihood of forming pockets.

The most critical period of so-called closed drainage comes within the first five days of treatment and usually during the first twenty-four hours. A "shower of fibrin" takes place due to the rather dramatic shedding of the accumulated fibrinous coat from the granulating pleural surfaces of the cavity. This material will come away in pieces much too large to pass through the drainage tube; consequently, the

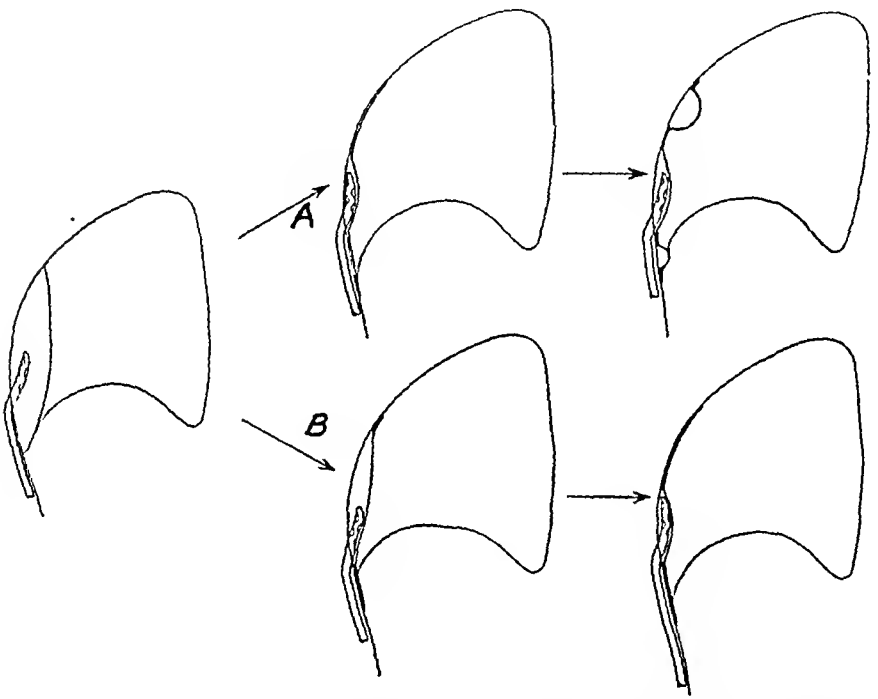

Fig. 5.—A schematic demonstration of the course of healing when: *A*, Suction is applied, the pleural surfaces are brought into contact, adhesions develop, and multiple pocket formation results. *B*, suction is not applied and healing results between the clean granulating surfaces from the periphery as the infection subsides.

tube becomes plugged. One must now patiently break up this material and slowly evacuate it. This is done by occluding tubes *J* and *K* with one hand while alternately compressing and releasing these tubes with the other hand between the point of occlusion and *L*. This procedure sets up a vigorous to-and-fro flow through the intubation catheter and will mince the particles caught in the end of the tube to a size which readily passes through the system and can be removed by washing. This operation consumes an hour or more of time, causes the patient little concern, and usually requires repetition once or twice.

Following this shower of fibrin, 500 c.c. of Dakin's solution are placed in the empty reservoir *T* twice daily. The Dakin's solution serves to dissolve and loosen fibrin and exudate if any remain; otherwise normal salt solution is used for continuous irrigation.

The use of a solution of sodium tetradecyl sulfate (1:800) and azochloramide (1:2,000) buffered to pH 7.4 as the initial irrigating agent has resulted in complete solution of the pus and the fibrinous coating of the empyema cavity in fifteen hours. The patient was a 2½-year-old Negro child with a postpneumonic empyema of three weeks' duration. The pus had the appearance of thick, split pea soup so characteristic of pneumococcal empyema. The type I pneumococcus was grown from the pus. The entire left chest was affected, with displacement of the heart and mediastinal structures completely to the right. At no time during the subsequent three weeks' period of treatment by tidal irrigation with normal saline and half-strength Dakin's solutions did pus reappear. If this experience of complete dissolution of the fibrinous deposits can be duplicated, the treatment of empyema will be greatly simplified.

The apparatus should be inspected carefully twice daily by the person in charge of the case. One will recognize at a glance, by the to-and-fro movement of fluid in the apparatus, that free communication exists between the irrigator and the cavity. After the irrigator has been emptied and washed out, the cavity is distended by pinching shut tube *K*, opening cock *G* widely, and then successively occluding and releasing tubes *J* and *K*. With tube *K* pinched shut and tube *J* open, the cavity is distended with fluid until the patient complains or coughs, until the fluid leaks out around the catheter, or until the pressure in the cavity becomes sufficient to stop the flow from the reservoir *T*. This simple procedure repeated twice daily breaks up any adhesions of unhealthy granulating surfaces and prevents pocket formation.

Leakage around the tube can be of two varieties: suction of air into the cavity and escape of fluid out of the cavity. In streptococcal infections the catheter frequently becomes loose on the fourth to the seventh day because the tissues retract and under these circumstances granulations are slow to grow out against the tube. To prevent leakage of air into the cavity the catheter is passed to fit snugly through a sheet of rubber dam which is fixed to the chest wall by adhesive ties at the four corners, or a pack impregnated with zinc oxide ointment is placed around the catheter. The outward leakage of fluid is prevented by lowering the irrigator just sufficiently to stop this flow when the apparatus is full.

In the presence of a bronchopleural fistula the irrigator, full of fluid, is lowered until coughing is no longer excited. The fistula ordinarily

heals in one or two days and the apparatus can then be raised again. Dakin's solution cannot be used in the presence of a bronchopleural fistula because it will cause coughing. This rather violent coughing is frequently the first objective sign indicating the presence of a bronchopleural fistula. In the case of infants, however, the first sign may be the vomiting of Dakin's solution which has been swallowed. If a fistula does not close spontaneously, operative procedures must be undertaken.

The volume of the cavity can be followed by measuring either the amount of fluid required to fill it or the quantity obtained when the cavity is emptied. These data, however, merely give an indication of the extent to which the lung has re-expanded but do not indicate accurately the area of involved pleura. The extent of the cavity and of the pleural thickening should be followed by weekly x-ray studies by the double contrast technique previously described.

After cultures of the fluid are negative and the exudate is scanty the irrigator may be lowered to give a so-called negative pressure in the cavity. The cavity is, however, actively distended twice daily as before. Should the patient's temperature show an evening rise, the irrigator is raised again immediately.

As the size of the cavity decreases, the catheter is shortened. When the volume of the cavity is reduced to about 30 c.c., the tidal irrigations will cease, and the apparatus is detached. Lipiodol is injected and films are taken to demonstrate the possible presence of small sinus tracts. The cavity is irrigated three times daily with Dakin's solution. The use twice weekly of a generous amount of 1 per cent silver nitrate as an irrigating solution will effect a rapid obliteration of the residual cavity and tract. The use of the silver nitrate solution is both preceded and followed by irrigation with distilled water so as to minimize the amount of silver chloride precipitated. Finally, the catheter is extruded from the healing tract, which will have become so small that the tube cannot be replaced. Following two or three days' observation the patient can be dismissed from the hospital with the tract completely healed. Should the temperature rise after removal of the tube the tract will not have healed, and a small tube can be reinserted and Dakin's irrigations continued for a few more days. If healing of the tract is unduly prolonged, it might be excised and packed. In this series such a procedure has not been necessary.

Results of Treatment.—Fifty-five consecutive cases of postpneumonic empyema were treated during a period of six years extending from 1934 to 1940 (Tables I, II, and III). No cases in which the patients were treated since 1940 are included in the discussion of end results, because after a two-year period of freedom from symptoms, with negative x-ray pictures and physical examination, recurrence is unlikely.

TABLE I

A TABULATION OF THE TYPES OF CASES OF ACUTE EMPYEMA TREATED

NO. OF CASES	CAUSTIVE ORGANISM
48	Pneumococcus*
4	Hemolytic streptococcus
2	Staphylococcus
1	Putrid (ruptured lung abscess)
Total 55	

*All types of the pneumococcus infections are grouped together since the treatment and course of the disease are essentially the same.

TABLE II

AGE DISTRIBUTION AND MORTALITY

AGE (YR.)	NO. OF CASES	DEATHS	MORTALITY (PER CENT)
Under 2	9	2*	22
2 to 10	21	0	0
11 to 20	9	0	0
21 to 30	6	0	0
31 to 40	5	0	0
41 to 50	2	0	0
51 to 60	1	0	0
Over 61	2	0	0
Total	55	2	3.64

*Both of these patients had pneumococcus infections. The cause of death is discussed in the text. One death was due to meningitis and the other to fibropurulent pericarditis.

TABLE III

COMPLICATIONS ENCOUNTERED IN 55 CONSECUTIVE CASES IN WHICH PATIENTS WERE TREATED BY TIDAL IRRIGATION

COMPLICATION	NO.
Bronchopleural fistula	8
Empyema necessitatis	2 (pneumococcal)
Pericarditis (fibrinous)	1 (fatal)
Meningitis	1 (fatal)
Diabetes	1
Otitis media	10
Lung abscess	1

Two-year follow-up studies have been obtained in fifty-four of the cases. There have been no recurrences and in no patient has a chronic empyema developed.

Two deaths occurred. One patient was 9 months of age, a 7-month, premature syphilitic infant who had fully developed signs of meningitis before thoracotomy was performed; at autopsy approximately one-third of the cerebral cortex was found to be involved. The empyema cavity was empty and free of pus. The second death was that of a Chinese infant 18 months of age. This child had signs of pericarditis before thoracotomy was performed. Death occurred suddenly two days after drainage of the chest. Postmortem examination showed the empyema cavity to be empty and free of pus. A massive fibropurulent pericarditis was present. Since both patients had a fatal disease ac-

cessory to the empyema thoracis before drainage was instituted, any treatment to cure the empyema was obviously futile.

In a consideration of the length of treatment required, the cases must be divided into two groups: (1) Those in which treatment was without terminal irrigation with silver nitrate solution, and (2) those in which treatment was with terminal silver nitrate irrigations. The number of cases are about equal in each group. Without the use of the silver nitrate irrigations, the small residual cavities around the drainage catheters healed very slowly. Nearly as much time was consumed in obliterating these small tracts as was required to secure the previous healing of the large empyema cavity. From our experience with the second group it may be stated that if silver nitrate irrigations are used as soon as the cavity has been reduced to a volume of approximately 30 c.c., the entire expected period of treatment will be three to five weeks, depending upon the extent of the original effusion.

The presence of a concurrent infection such as otitis media will prolong the period of treatment. Little healing occurs as long as an active underlying pneumonic process exists.

In this series healing has occurred regularly without the reaccumulation of pus, without the development of chronic empyema, and without permanent deformity.

DISCUSSION

In this study of fifty-five consecutive cases of acute empyema, with treatment over a period of six years, the factors of periodic variation of virulence of the causative organisms and severity of the disease tend to be eliminated. Therefore, it should be possible to take the results of this study as representative of what might be expected for any average period.

It would be incorrect to leave the impression that the good results reported in this communication were entirely due to the tidal irrigator used. The apparatus does greatly simplify the handling of an individual case of empyema; but strong emphasis must be placed on the fact that the treatment was carried out in all of its minute details by only two individuals. It is entirely possible that another form of treatment would give equally good results if conducted under the same conditions of general care and attention to details. Obviously, experience in the handling of this type of case influences the course of the disease, and this fact might become of increasing importance for the individual patient if the incidence of empyema is lessened by chemotherapy in pneumonia.

The introduction of chemotherapeutic measures employing the sulfonamides and detergents will probably result in cure in a higher percentage of cases of empyema during the early stages by simple thoracentesis. The use of these agents[9, 10] combined with the technique of

aspiration and air injection as suggested by Danna[11] and McEnery and Brennemann[12] may well reduce the number of cases of empyema requiring surgical drainage.

The replacement of pus by air is a valuable aid in completely outlining the character and extent of the cavity. The use of this double contrast x-ray technique will frequently reveal an otherwise obscure, coexisting, interlobar collection of fluid.

The early obliteration of the cavity with the aid of suction will often result in multiple pocket formation, and this sequence is probably the main factor contributing to the failure of closed drainage. Early in the treatment the apparatus should be adjusted to give, during each tidal cycle, a pressure on the fluid in the cavity alternately above and below atmospheric. This procedure, together with the daily forceful distention of the cavity, prevents multiple pocket formation and permits healing at the periphery as the pleural surfaces become healthy and the lung re-expands.

During approximately the first half of this study the period of treatment was prolonged by inability to secure prompt healing of the residual drainage tract. Subsequently, prompt healing occurred following irrigation with a solution of silver nitrate.

We do not advocate the use of any single routine treatment for empyema thoracis, because success or failure in the treatment of this condition is largely due to the attention given to the details of whatever therapeutic measures are employed.

REFERENCES

1. Beulau, G.: Fur die Heber Drainage bie Behandlung des Empyems, Ztschr. f. klin. Med. 18: 31, 1891.
2. Mozingo, A. E.: The Surgical Treatment of Empyema by a Closed Method, Am. J. M. Sc. 161: 676, 1921.
3. Hart, Deryl: Acute Empyema: Treatment by Continuous Tidal Irrigation and Drainage Dependent on Normal Respiratory Movements, Arch. Surg. 17: 102, 1928.
4. Hart, Deryl: Empyema: Treatment by Tidal Irrigation and Suction, Arch. Surg. 19: 1732, 1929.
5. Hart, Deryl: Empyema: Acute, Chronic and Tuberculous, J. A. M. A. 93: 1724, 1929.
6. Homans, J.: A Textbook of Survey, ed. 5, Baltimore, 1940, Charles C. Thomas, Publisher, p. 763.
7. Danna, J. A.: Some Principles Involved in the Pathology and Treatment of Empyema Thoracis, Surg., Gynec. & Obst. 56: 299, 1933.
8. Capps, J. A., and Coleman, G. H.: Localization of Pain Sense in Parietal and Diaphragmatic Peritoneum, Arch. Int. Med. 30: 778, 1922.
9. Petroff, S. A., and Schwartz, R.: Bacteriology of Chronic Non-Tuberculous Pulmonary Infections, Quart. Bull., Sea View Hosp. 6: 363, 1941.
10. Palitz, L., and Herman, M.: Treatment of Tuberculous and Mixed Infection Empyema With New Irrigating Solutions, Quart. Bull., Sea View Hosp. 6: 181, 1941.
11. Danna: Loc. cit., page 294.
12. McEnery, E. T., and Brennemann, J.: Aspiration in the Treatment of Empyema in Children, J. A. M. A. 44: 742, 1932.

PERFORATION OF THE CERVICAL ESOPHAGUS WITH MEDIASTINITIS

KENNETH D. GRACE,* M.D., LAGRANGE, GA., AND THOMAS M. IRWIN,* M.D., ORLANDO, FLA.

PERFORATION of the esophagus has been in the past, and still is, a major surgical catastrophy. Numerous reports are in the literature describing this accident. Its cause may be any object that can be swallowed. In the case reported here, a broken piece of acrylic, a plastic material forming a partial upper denture, was the offending agent. Plastic material in one form or another is gaining popularity in almost every field today. As more of this valuable material is used, one should expect to see and hear of industrial accidents resulting from its use. Unfortunately, it is not radiopaque, a fact which makes localization of the offending piece very difficult and often impossible. A report on this accident is not intended to condemn plastic dentures but more to inform those using such material of the potential danger accompanying its use. Broken plastic dentures, because of their location, may cause damage to the oral cavity or to the esophagus, as in the case of this patient. Likewise because of its thin sharp edge when broken, it may cause a severe laceration or penetration of soft tissue. The ever-present bacteria found in the oral cavity and esophagus find an excellent field in the injured tissue and immediately begin their destructive processes.

In discussing surgery of the esophagus, Sauerbruck and O'Shaughnessy[1] state that factors which have enabled progress in the surgery of the gastrointestinal tract are missing in surgery of the esophagus. The stomach and intestines are readily accessible and can be freely mobilized to permit extensive repair and resection. Repair is simplified by the vital reaction of their serous coat. Should postoperative infection take place, its spread may be limited by the localizing action of omentum and peritoneum.

The esophagus is difficult to reach. There is no superfluous length. Small lacerations are difficult to repair. There is no serous external coat and little natural tendency to localize postoperative infection. The infection may involve the pleura, mediastinum, or even the pericardium.

The esophagus is a musculomembranous canal, 23 to 26 cm. in length leading from the pharynx to the stomach. The inner or mucous coat is composed of stratified squamous epithelium resting on a loose sub-

Received for publication, Feb. 23, 1943.
Presented before the Clinical Conference, Station Hospital, Camp Stewart, Ga., Dec. 11, 1942.
*Major Medical Corps, U. S. Army.

aspiration and air injection as suggested by Danna[11] and McEnery and Brennemann[12] may well reduce the number of cases of empyema requiring surgical drainage.

The replacement of pus by air is a valuable aid in completely outlining the character and extent of the cavity. The use of this double contrast x-ray technique will frequently reveal an otherwise obscure, coexisting, interlobar collection of fluid.

The early obliteration of the cavity with the aid of suction will often result in multiple pocket formation, and this sequence is probably the main factor contributing to the failure of closed drainage. Early in the treatment the apparatus should be adjusted to give, during each tidal cycle, a pressure on the fluid in the cavity alternately above and below atmospheric. This procedure, together with the daily forceful distention of the cavity, prevents multiple pocket formation and permits healing at the periphery as the pleural surfaces become healthy and the lung re-expands.

During approximately the first half of this study the period of treatment was prolonged by inability to secure prompt healing of the residual drainage tract. Subsequently, prompt healing occurred following irrigation with a solution of silver nitrate.

We do not advocate the use of any single routine treatment for empyema thoracis, because success or failure in the treatment of this condition is largely due to the attention given to the details of whatever therapeutic measures are employed.

REFERENCES

1. Beulau, G.: Fur die Heber Drainage bie Behandlung des Empyems, Ztschr. f. klin. Med. 18: 31, 1891.
2. Mozingo, A. E.: The Surgical Treatment of Empyema by a Closed Method, Am. J. M. Sc. 161: 676, 1921.
3. Hart, Deryl: Acute Empyema: Treatment by Continuous Tidal Irrigation and Drainage Dependent on Normal Respiratory Movements, Arch. Surg. 17: 102, 1928.
4. Hart, Deryl: Empyema: Treatment by Tidal Irrigation and Suction, Arch. Surg. 19: 1732, 1929.
5. Hart, Deryl: Empyema: Acute, Chronic and Tuberculous, J. A. M. A. 93: 1724, 1929.
6. Homans, J.: A Textbook of Survey, ed. 5, Baltimore, 1940, Charles C. Thomas, Publisher, p. 763.
7. Danna, J. A.: Some Principles Involved in the Pathology and Treatment of Empyema Thoracis, Surg., Gynec. & Obst. 56: 299, 1933.
8. Capps, J. A., and Coleman, G. H.: Localization of Pain Sense in Parietal and Diaphragmatic Peritoneum, Arch. Int. Med. 30: 778, 1922.
9. Petroff, S. A., and Schwartz, R.: Bacteriology of Chronic Non-Tuberculous Pulmonary Infections, Quart. Bull., Sea View Hosp. 6: 363, 1941.
10. Palitz, L., and Herman, M.: Treatment of Tuberculous and Mixed Infection Empyema With New Irrigating Solutions, Quart. Bull., Sea View Hosp. 6: 181, 1941.
11. Danna: Loc. cit., page 294.
12. McEnery, E. T., and Brennemann, J.: Aspiration in the Treatment of Empyema in Children, J. A. M. A. 44: 742, 1932.

Under direct esophagoscopy, a lacerated area was seen just below the cricopharyngeal pinchcock on the left (Fig. 3). The mucosa below this point was greatly swollen and inflamed, blocking the lumen, and further instrumentation was thought inadvisable. The patient was hospitalized, and since he could swallow water, he was given 2 Gm. of sulfathiazole by mouth, crushed and suspended in water, and 1 Gm. four hours later. Temperature on admission was 99° F., pulse 70. Nine hours after admission, at 7:00 A.M., Nov. 30, 1942, the patient complained of severe pain



Fig. 1.—X-ray of plate showing that the plastic material is nonopaque.

Fig. 2.—Arrow points to area in esophagus where barium collected following barium swallow.

mucous layer. Once the epithelium is penetrated by a foreign object, it meets little resistance in the loose tissue of the submucosa. The muscular coat consists of two layers of smooth muscle, an outer longitudinal and an inner circular layer.

The distance from the upper incisor teeth to the cardiac orifice is at least 37 cm. The blood supply in the upper portion is derived from the inferior thyroid artery, in the thoracic portion from the bronchial arteries and the upper five intercostal arteries. The main blood supply for the lower portion is derived from a single branch of the aorta which divides into an ascending and descending branch. The venous return from the esophagus is by way of the inferior thyroid, azygos, and hemiazygos veins. The lymphatic drainage is by way of the deep cervical glands in the upper third, the bronchial and mediastinal glands in the middle third, and the glands along the lesser curvature of the stomach in its lower third.

The nerve supply of the esophagus is derived from the vagi and the sympathetic trunk.

The relation of the esophagus to surrounding structures is especially unfortunate in regard to spread of infection. There is no anatomic block to dependent spread of infection from perforation of any portion of the organ; in fact, the esophagus itself acts as a pathway for spread into the mediastinum. The deep cervical fascia of the neck limits external spread of infection, further encouraging drainage into looser mediastinal tissue. These facts, plus the poor tendency of the esophagus to close or limit spillage from itself following perforation, make any injury to it especially dangerous, and requires prompt action on the part of the surgeon. The most frequent portion involved in perforation is the cervical portion. This fact greatly facilitates necessary surgery because of the relative ease with which the neck and superior mediastinum can be drained. Perforation of the thoracic portion is more serious because of immediate mediastinitis and because of the much more difficult posterior approach when drainage is instituted.

CASE REPORT

The patient, C. A. K., a 25-year-old white soldier, a native of Wisconsin, was admitted to the Station Hospital, Camp Stewart, Ga., Nov. 29, 1942, at 10:00 P.M. While riding a bus six hours before admission, he had been eating hard candy and broke off a piece of the plastic portion of a partial upper denture in his mouth, swallowing it. After the denture was broken and swallowed, he felt immediate pain in his throat. He ate more candy, attempting to force the particle down. The pain increased in his throat and he was able to swallow water only with great difficulty at time of admission.

Examination of the mouth and throat revealed nothing of importance. Under fluoroscopy, without barium, nothing could be seen as the plastic material is nonopaque (Fig. 1). A swallow of barium paste was given. In the upper third of the esophagus on the left there was an area where the barium had difficulty passing (Fig. 2). Once the radiopaque fluid passed this point, it descended to the stomach with ease.

in his neck and back. On palpation, there was very slight subcutaneous emphysema noted on both sides of the neck, with moderate bilateral swelling. The temperature was then 102° F. and pulse 90. All medication by mouth was discontinued and sodium sulfathiazole, 5 Gm., was given intravenously. A flat x-ray plate of the chest and neck taken at this time revealed a marked widening of the mediastinal shadow (Fig. 4). It also revealed a tissue emphysema extending from the mediastinum upward through the fascial planes of the neck. The foreign body was not visualized. One thousand cubic centimeters of 5 per cent glucose were given intravenously. At 4:00 P.M. the temperature was 103° F., pulse 120, and the patient was almost comatose. The pressure and emphysema of the neck had grown progressively worse during the day. Drainage of the neck tissues and mediastinum was decided upon and approximately twenty-four hours from the time of the accident operation was performed.

Operative Report.—Under sodium pentothal intravenous anesthesia, a six-inch incision was made along the medial border of the left sternomastoid muscle, extending within one inch of the suprasternal notch, upward. The pretracheal muscles and sternomastoid were reflected laterally from the midline and the thyroid gland exposed. The inferior thyroid vessels were ligated and the gland reflected medially. This exposed the trachea, esophagus, and carotid sheath. The carotid sheath was then followed downward close to the esophagus, by blunt finger dissection, until pulsation of the aortic arch could be easily palpated. By further blunt dissection, all muscles and fascial planes were separated, for drainage. Only a serous exudate and much air in the loose areolar tissues were encountered on the left side. On the right side of the neck the same procedure was performed and here was found frank pus within the fascial planes of the neck and around the carotid sheath, as well as serous exudate and air. Neither the injuring agent, nor the actual esophageal rent were seen at operation. Large gauze and cigarette drains were inserted into the deep spaces on both sides of the neck, packing the wound wide open, and downward into the mediastinal spaces on each side. These were anchored loosely to the skin with black silk sutures. No attempt was made to close the incisions. Time required for the operation was fifty minutes, during which 600 c.c. of 5 per cent glucose were given. Two grams of sodium pentothal were required for anesthesia, which was followed by CO_2 and O_2 inhalation when the procedure was completed. Mouth suction was used at frequent intervals during the operation. No sulfonamide preparations were applied locally.

On returning to the ward, the patient was kept in position with head low to promote drainage. Sulfathiazole, 5 Gm., was given intravenously plus 5 per cent glucose in saline solution. There was little change in the patient's condition during the night. Sixteen hours postoperative, the sulfathiazole level had reached 3.7 mg per 100 c.c. His neck dressing was saturated with pus and serum. He was still comatose, his pulse had dropped, but his respiration and temperature continued elevated. Blood plasma was given intravenously (500 c.c.). Twenty-four hours postoperative, the temperature had risen to 104.6° F. with a rapid pulse and a lowered respiratory rate. During the day there was a marked increase in neck rigidity. His respiration had become Cheyne-Stokes in character.

In view of his surgery it was felt that the neck rigidity might be due in part to muscle spasm, but because of his generally depressed condition, meningeal irritation was suspected. A spinal puncture was done and approximately 25 c.c. of clear fluid under slight increase in pressure was removed. Thirty minutes later, 8:30 P.M., and twenty eight hours postoperative, the patient roused from his coma for the first time and talked to the attendants. This was the first evidence of any improvement he had shown since 9:00 A.M. the previous day when he became comatose. The temperature and pulse began to decline and by the following morning his general

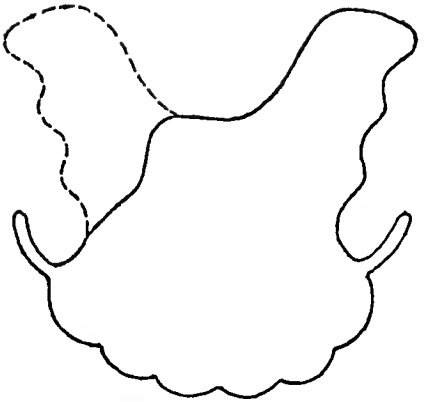

Fig. 3 —Diagram of upper denture showing broken fragment in outline



Fig 4 —Increase in the diameter of the mediastinal shadow and air in neck prior to surgery.



Fig 6—Mediastinal shadow within normal limits, twenty days postoperative



Fig 7—Final checkup with barium swallow, no evidence of esophageal obstruction.

condition was much improved. On Dec. 2, 1942, another x-ray of the neck and chest was made (Fig. 5). This showed a decrease in the amount of air in the soft tissues of the upper chest and neck. A culture taken from the wound at the time of operation was reported: Few colonies of *Staphylococcus aureus* and *albus* (nonhemolytic), and a few colonies of streptococcus, gamma, nonhemolytic. Fluids and sulfathiazole were continued intravenously throughout the day. On Dec. 3, the patient was given one ounce of water orally with no ill effects. Since this was taken with no great difficulty, sulfathiazole was given by mouth from this time on. Dressings were changed daily, as drainage was still profuse. The drains were shortened daily.



Fig. 5.—Decrease in mediastinal shadow following drainage; safety pins attached to drains in the neck.

On Dec. 4, the patient was able to take fruit juice at frequent intervals in small amounts and a supplemental intravenous injection of glucose was given to maintain his fluid level.

From this point, the progress might be considered uneventful. The fever gradually subsided and the patient regained strength. Strained soups, milk, and other nourishing liquids were added to the diet. By Dec. 9, he was given a soft diet which was well tolerated. Drainage from the wound at this time was minimal and more serous than purulent in character. On Dec. 18, the drains were removed and the wound was permitted to close (Fig. 6). The patient was encouraged to exercise in the ward. By Dec. 23, he was eating a general diet in the mess hall. On Dec. 31, he was discharged from the hospital and permission was granted for him to visit his home in Wisconsin. The broken piece of plastic which was the original offending agent was never found, though stools were searched carefully and all dressings carefully inspected. Presumably it is still somewhere in the soft tissues of the neck, or the patient unconsciously brought it up during the painful initial injury and eliminated it by mouth.

of the neck is dangerous. We believe further that most patients will be better served by bilateral incision and drainage, even though the point of perforation can be established on one or the other side of the esophagus. The tissues surrounding the esophagus lend themselves to spread of infection across the midline as well as into the mediastinum.

In our case, earlier drainage might have prevented the appearance of the meningeal symptoms, which were unquestionably due to pressure on the great vessels of the neck by the accumulated emphysema and infection within the enveloping cervical fascia.

The operative approach to drainage of the area surrounding the esophagus and the superior mediastinal tissue was essentially that described by Pearse.[2] Drainage should be wide, as complete as possible, and maintained until all infection has cleared.

This case report and discussion are presented as a reminder that an apparently trivial accident may result in a serious surgical emergency. Temporizing or treatment with conservative means will certainly end in disaster in a large percentage of cases. Prompt, adequate, radical therapy should give a great percentage of favorable results.

REFERENCES

1. Sauerbruck, Ferdinand, and O'Shaughnessy, L.: Thoracic Surgery, Baltimore, 1937, William Wood & Company.
2. Pearse, H. E., Jr.: The Operation for Perforation of the Cervical Esophagus, Surg. Gynec. & Obst. 56: 192, 1933.
3. Phillips, C. E.: Mediastinal Infection From Esophageal Perforation, J. A. M. A. 111: 998, 1938.
4. Touroff, A. S. W.: Perforation of the Cervical Esophagus With Flexible Gastroscope, Ann. Surg. 114: 369, 1941.
5. Snyder, John: Perforation of the Cervical Esophagus, South. M. J. 32: 1080, 1939.
6. Cummings, Geo. O.: Perforation of Esophagus by Foreign Bodies, J. Maine M. A. 32: 193, 1941.
7. Carp, Louis: Mediastinitis Following Esophageal Perforation by Ingested Bone, J. Mt. Sinai Hosp. 7: 322, 1940.
8. King, J. M., and Strans, G. D.: External Perforation of the Esophagus, Am. J. Surg. 58: 448, 1942.
9. Shaw, J.: Recovery From Mediastinitis Due to a Foreign Body in the Esophagus, Clin. Rep. Melbourne Hosp. 9: 104, 1928.

On Jan. 18, 1943, following his return from leave, fluoroscopy was performed and the patient was given barium paste (Fig. 7). No evidence of any esophageal obstruction was seen. Both incision scars were well healed, pliable, and not adhered (Fig. 8). The patient was fitted with a new denture and returned to full duty.

Fig. 8.—Front view of neck showing healed scars along anterior border of sternomastoid muscles.

DISCUSSION

This case illustrates the rapidity with which infection can spread from the poorly guarded esophagus through the neck and mediastinal structures. It also illustrates the importance of early, adequate drainage of the neck and mediastinum without waiting for localization or depending upon sulfonamide therapy alone.

As recently as 1933, Pearse[2] called attention to the controversy at that time regarding choice of drainage in cases of this type, endoscopic or by external incision. More recent writers, Phillips,[3] Touroff,[4] Snyder,[5] Cummings,[6] and Carp,[7] are heartily in accord with Pearse's opinion that prompt recognition of the perforation and early external drainage will prevent many cases of mediastinitis and save many patients not improved by conservative therapy. The possible exception to this is when perforation is external, from without in, as in the case recently described by King and Straus,[8] In this type of penetration, drainage is already established and often does not need to be supplemented.

We believe that a history of swallowing a sharp object, followed by marked pain on further swallowing, and subsequent emphysema of the neck tissues are positive indications for open drainage. Sulfonamides are doubtless of value, but they should be considered only as supportive measures. Delay in the hope that infection will localize in one portion

in such position that no tension is placed on it except in absorbing the recoil after the breaking of the suture being tested.

For sutures of greater tensile strength, a smaller diameter pulley is mounted with the free pulley (see *inner pulley*, Fig. 1); a separate scale indicates values when this is used. The cost of the materials for this device was forty-five cents.

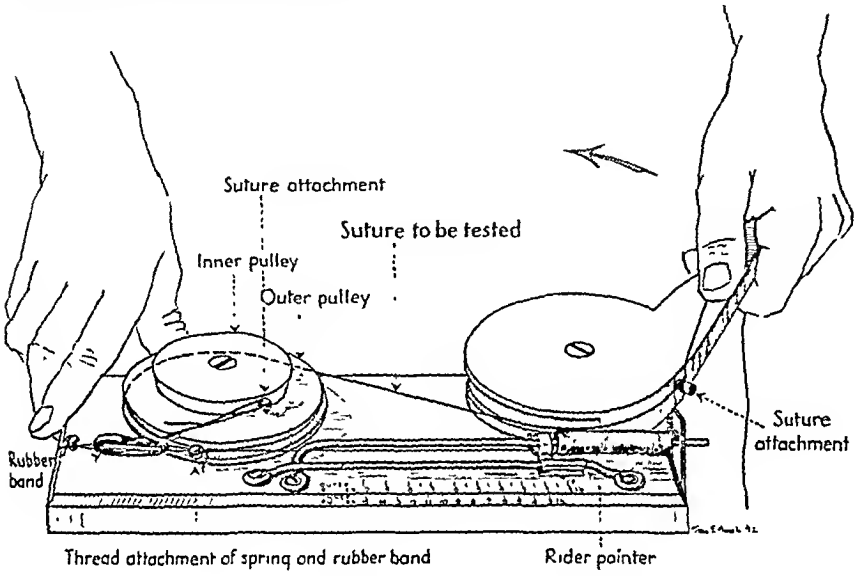

Fig. 1—Simplified suture testing apparatus.

In practice, the suture uniformly breaks at a point not in contact with either pulley. Repeated tests on successive pieces of surgical silk from the same spool have shown results consistent within four ounces on many repeated tests.

SUMMARY

Need for a simplified suture testing device exists. Such a device is described.

REFERENCES

wes, Edward L.: Factors Determining the Loss of Strength of Catgut When Embedded in tissue, J. A. M. A. 90: 530, 1928.
ard L., Sooy, J. W., and Harvey, S. C.: The Healing of Wounds as ned by Their Tensile Strength, J. A. M. A. 92: 42, 1929.
Über die Zug und Reissfestigkeit chirurgischer Nahtmaterials, Zen. Chir. 59: 147, 1932.
A Study of the Variations in the Tensile Strength of Silk Suture Ann. Surg. 86: 940, 1927.
W.: Untersuchungen über Anaphylaxiegefahr und Zugfestigkeit en Nahtmaterial "Carnofil Bost," München. med. Wchnschr. 82:
urgical Knots, Ann. Surg. 107: 158, 1938.
urgical Knots and Sutures, Surgery 5: 198, 1939.

A SIMPLIFIED SUTURE-TESTING APPARATUS

CLARENCE DENNIS, M.D., MINNEAPOLIS, MINN.

(From the Department of Surgery, University of Minnesota, Minneapolis)

IN THE past few years many excellent papers have been written on the subject of suture strength and knot strength, but few of the authors have dwelt at length on the type of suture-testing apparatus used. Taylor described a device for testing knots with intermittently applied two and one-half-pound tension. Scarff described the use of a "sensitive spring scale" which was held vertically, the ends of the suture being grasped by the gloved hand, the middle looped over the hook of the scale. Schmidt-Lange fixed the ends of his strands in cellulose and strung them vertically, testing by cautious addition of weights to the lower end. Polano used a testing machine loaned by "Nähseidenfabrik Gutermann," and Howes used a "Scott thread-testing machine." The commercial machines are designed to determine not only the breaking strength, but also the elasticity of the suture or thread, and other factors. The cost of some of these commerical machines, designed for the testing of threads entering into fabrics, etc., runs in hundreds of dollars.

The conclusion one draws is that all the methods described are either inaccurate, clumsy and time-consuming, include too large a human element, or involve investment in expensive apparatus.

For the purposes of most surgeons, simple determination of the breaking strength is adequate. A simple device for this purpose is shown in Fig. 1.

The suture to be tested is wound for half a turn around each of two pulleys, the end being anchored to the first of these by a screw and to the second by two turns about a post, the loose end being held by the hand of the operator as it grasps a handle attached to this second pulley. Turning of the second pulley by means of the attached handle thus places tension on the suture to be tested, which in turn rotates the first pulley. Rotation of the latter is checked by a heavy cord attached to a coil spring in such fashion as to stretch the spring progressively with each increment in tension of the suture to be tested. A light, free rider-pointer is pushed along two parallel bars by the spring as it is stretched. With gradually increasing tension, the suture breaks; the spring snaps back to the original length, leaving the rider-pointer at the point of greatest stretch. The breaking strength then may be read directly from the pointer of the rider. Excessive snapping back of the first pulley is prevented by attachment of a rubber binder loosely to the surface of it

Received for publication, March 22, 1943.

In 1942, his alma mater, Roanoke College, bestowed upon him the honorary degree, Doctor of Science. He was a member of many important surgical societies including the American Surgical Association, Southern Surgical Association, Society of Clinical Surgery, American College of Surgeons, Society of University Surgeons, Central Surgical Association, and others. In all of these he took an active part, contributing much to the value of their meetings, which he regularly attended. At the time of his death he was supervisor of research work, on

MONT ROGERS REID

the Study of Contaminated Wounds, under contract with the National Research Council, technical supervisor of the Red Cross Blood Procurement Program of Cincinnati; and director and member of the Committee of the Cincinnati Chapter of the American Red Cross. To all of these tasks, and to many others too numerous to mention, he brought the benefit of his loyalty, cool judgment, and wise counsel and advice. To those who knew him as a friend, as a teacher, or as an associate, his death has been a crippling blow and an irreplaceable loss.

—*M. M. Zianinger, M.D.*

In Memoriam

Mont Rogers Reid
1889-1943

Dr. Mont Rogers Reid died May 11, 1943, at the age of 54 years, after a brief illness. His death is a great loss, not only to American surgery, but also to the community in which he lived and to his many friends and associates. Reid was a great man in the true sense of the expression, a civic leader, a great teacher, and one of the nation's great surgeons. His almost infinite interest led to achievement in many fields. The training school for surgeons which he headed was one of the best known in the country, and every year he turned out young men eager to carry out his methods. He inspired all who come in contact with him, to industry and activity, at the same time gaining their devotion by his own modesty and unselfishness. His death is a great loss to Surgery, of which he was for years a member of the editorial board.

He was born April 7, 1889, at Oriskany, Va., the son of Benjamin Watson and Harriet Pendleton Reid. After receiving the A.B. degree at Roanoke College, he attended the Johns Hopkins Medical School, where he was graduated in 1912. He continued his surgical training at the Johns Hopkins Hospital, where he soon became known as one of the most gifted pupils of the great William Stewart Halsted.

In 1922, he came to Cincinnati as associate professor of surgery, and soon became identified with the life of the city. During 1925 to 1926 he served as visiting professor of surgery at the Peking (now Peiping) Union Medical College in China. In 1931, he was appointed professor and head of the department of surgery at the University of Cincinnati, which position he held at the time of his death.

Reid became interested in the surgery of great blood vessels while still at Hopkins, an interest which he retained throughout his career, and which led to his becoming pre-eminent in that field. In recognition of this fact, he was made the recipient of the first award of the Matas Medal in 1934. It is for his studies in the field of vascular surgery that he is best known among surgeons, but he had many other interests. His contributions to the study of the healing of wounds are well known, but in addition he wrote important articles on the surgery of the bile ducts, the thyroid gland, the sympathetic nervous system, the appendix, and many others. In recent years he was especially interested in cancer problems and as a member of the National Advisory Cancer Council had much influence on the work done in that field.

SURGERY

VOL. 14 NOVEMBER, 1943 No. 5

Original Communications

THE SURGICAL SERVICE OF A STATION HOSPITAL IN THE MIDDLE EAST

FRANKLIN E. WALTON, M.D.,* NEW YORK, N. Y.

THE doctor in civilian practice along with the medical officer in one of the armed forces in a home station unquestionably asks himself and others, "What are those medical officers overseas actually doing of a *professional* nature at this time?" "This time" is the spring of 1943 and the object of this communication is to acquaint this anxious and puzzled medical public with the scope and activities of the surgical service of a numbered station hospital in the Middle East. For obvious military reasons this answer must be clothed in ambiguity. The exact location of this particular medical installation, its capacity, and the number of patients cannot be disclosed. Because of the plethora of rumors and innuendos in circulation today a statement of facts should be welcomed by the medical public at large. If a careful perusal of the following statements will result in a clearer conception of the professional experiences of this installation, the thought provoking summation must bring some satisfaction to those in service at this time and perhaps stimulate the activities and imaginations of others.

The proportion of surgical cases to total admissions is shown in Fig. 1. The relative constancy of this proportion, some 43 per cent, only reflects the general character of the medical and surgical demands of this particular area of command.

Fig. 2 illustrates the proportion of elective surgical cases in comparison with the acute surgical emergencies. These elective procedures ran the gamut of possibilities from prostatectomies and rhinoplasties through various plastic procedures that had not been carried out in the United States. Though the emergency procedures obviously fluctu-

*Major, Medical Corps, U. S. Army.
Received for publication, April 12, 1943.

Book Reviews

Lymph Node Metastases. By Grantley Walder Taylor, A.B., M.D., F.A.C.S., Instructor in Surgery, Harvard Medical School; and Ira Theodore Nathanson, M.S., M.D., Instructor in Surgery, Harvard Medical School. Ed. 1. Pp. 458, with 61 illustrations and 116 tables. New York, 1942, Oxford University Press. $8.

This book is a needed addition to the sources of information for those who frequently or infrequently must make decisions regarding a plan of treatment for patients with neoplastic disease. It will be appreciated especially by the overburdened general medical practitioner who does not have the time to refer to the pathologist for knowledge of the behavior of a tumor in regard to lymph node metastasis, or to the anatomist for a description of the regional lymphatics, or to the surgical and radiological literature to complete the solution of the therapeutic problem of lymph node metastasis, not to mention the clinician and statistician for end-result studies.

The authors have achieved their purpose to assemble briefly the available information regarding the incidence of node involvement in various neoplastic diseases, the factors affecting the incidence, and the surgical management of metastases in lymph nodes.

The present volume consists of three parts. The first is a summary of the anatomy of the lymph system, and serves as a basis for the surgery of the lymphatics. Part II is a review of neoplasms of particular regions, with analysis of the incidence of node metastasis, the indication for regional dissection, and the possibility of control by surgical intervention. The role of radiation therapy of regional lymph node metastases has been briefly included, but no exhaustive effort has been made to appraise the adequacy of such treatment. Part III contains a description of standard operations, based upon orthodox procedures from the surgical literature with modifications found desirable as a result of the author's experience and studies.

This book justifies its inclusion among the eminently practical contributions to the cancer literature. It is written in simplicity of style and uniformity of presentation. In addition to an adequate subject index, frequent references to the literature are included throughout.

under adequate supervision. The inhalation anesthetics, ether, chloroform, and nitrous oxide oxygen, were administered by a medical officer or by a corps man or nurse under the supervision of a medical officer. All were surprisingly satisfactory and there were no alarming complications from a single anesthesia.

The personnel of the operating team consisted of two medical officers, one scrub nurse, one corps man scrubbed to assist the nurse, an anesthetist, one circulating nurse, and two corps men to assist this last-named nurse. Additional medical officers were added to the operating team when the need was apparent. On one particular occasion, seven such teams were functioning simultaneously.

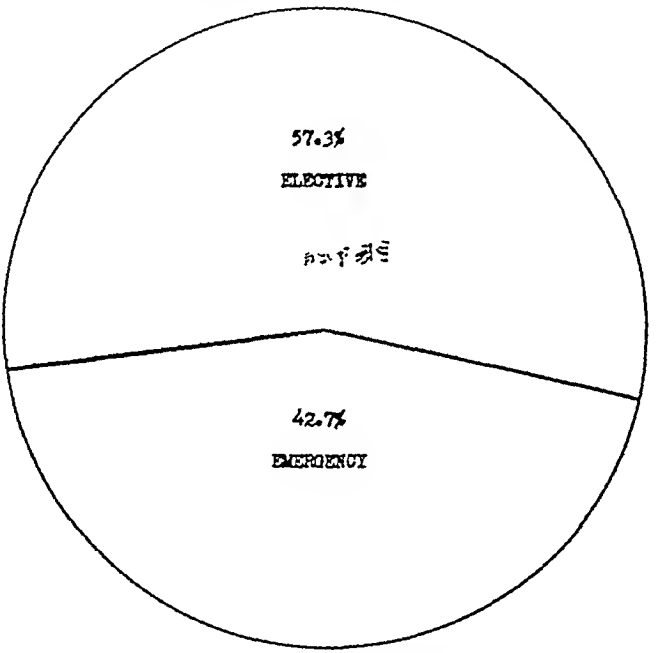

Fig. 2.—The proportion of elective surgical cases in comparison with the acute surgical emergencies.

The breakdown of surgical cases into types of operative surgical procedures shown in Fig. 4 is self-explanatory. The obstetrical group included normal deliveries and the gynecologic procedures were not abdominal but all vaginal in type.

An extensive educational program was instituted and carried out in conjunction with the normal activities of this relatively busy surgical service. The unit fortunately contained officers who, in civilian life, had carried out important roles in the educational activities of university hospitals and medical schools and this fact added considerable emphasis to such a program. It included refresher courses in subjects such as anesthesia, with didactic lectures and clinical demonstrations.

ated from time to time, these elective possibilities were always with us and were relatively constant; they depended upon the abilities of the respective surgical specialists.

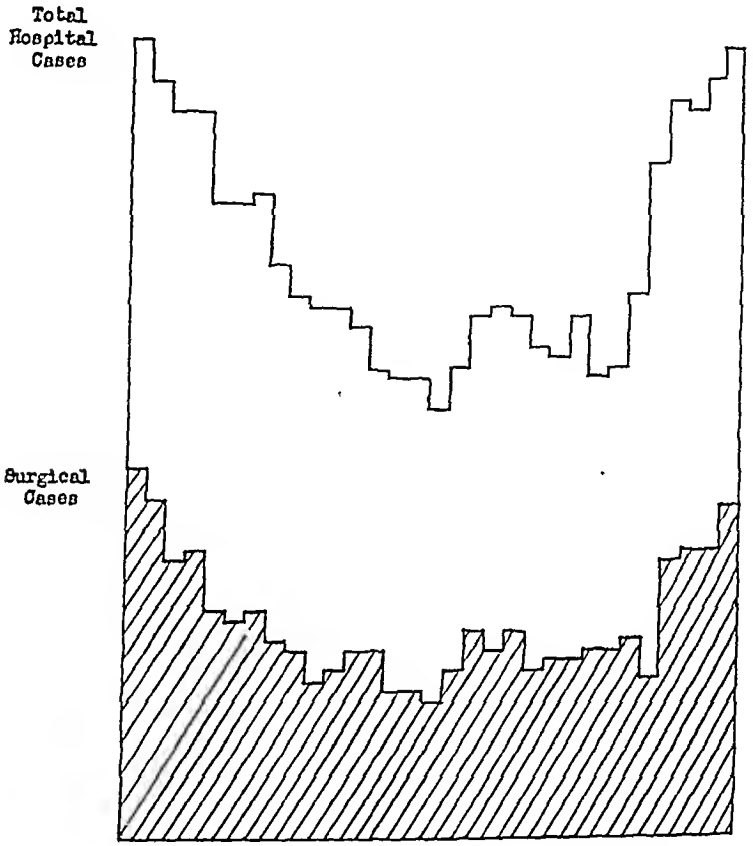

Fig. 1.—The proportion of surgical cases to total admissions.

The type of anesthesia employed is shown in Fig. 3. It will be noted that in roughly one-sixth of the operative procedures no anesthetic was used. This relatively large group included patients (many of whom had received basal drugs) with fractures without displacement, for example, and others in which, because of sound surgical reasons, anesthesia was contraindicated at the time. The group that was administered sodium pentothal is not included in the graph, although this drug was used with excellent results in those requiring surgical dressings of a painful nature, and in brief surgical procedures not requiring muscular relaxation. Brachial block was employed with much satisfaction in many surgical procedures, particularly in fractures of the upper extremities. Spinal anesthetics were administered by the surgeon in charge of the case and the remaining functions of the anesthetist assumed by a medical officer or a trained corps man

These were attended by corps men, nurses, and medical officers alike and were extremely well received. The head nurse on each of the surgical wards, with the aid of her assistant, drilled the corps men assigned to her respective ward in those nursing procedures expected of the corps men. These included assistance with surgical dressings, and handling of patients, as well as mechanical procedures such as the serving of trays, etc. The principal nurse in the operating room held daily drills in which the corps men were taught the theory and then allowed to carry out "scrub up" procedures. They were eventually allowed to scrub for operations and thus actively participated under the direction of a competent nurse. In like fashion these enlisted men received training in the duties of the circulating nurse—the position of the patient, the taking of blood pressures—and in assisting the anesthetist.

Weekly surgical pathologic conferences with presentation of cases, patients, the surgical specimens, x-rays, etc., were held for the entire professional staff and attended by the nurses who were available at that period of the day. Subjects under discussion included, in addition, such "peace time" subjects as surgical lesions of the thyroid gland, internal derangements of the knee joint, a symposium on acute appendicitis, fractures of the humerus, tumors of the anterior triangle of the neck, pneumococcal mastoiditis, infections of the hand with particular emphasis upon human bites, fractures of the pelvis with rupture of the bladder, pathologic fractures of the long bones, and acute mesenteric thrombosis.

The role of the department of radiology in the function of the surgical service cannot be underestimated. The coordination between the two departments was manifest at all times; radiology was purposely located in a section immediately adjacent to the operating room in which all orthopedic cases were cared for. Their service not only offered the routine x-ray and fluoroscopic procedures, but gastrointestinal series, cholecystographic studies, encephelograms, pyelograms, myelograms, etc.

In a similar fashion, the laboratory service carried out such tests as sulfanilamide determinations, CO_2 and O_2 tensions, total and fractional serum protein determinations, Friedmann tests, blood chlorides, Ca and P determinations, anaerobic cultures and provided twenty-four-hour rush hematoxylin-eosin paraffin sections.

Because this installation was located in the zone of combat, although upon its fringe, the "52 Series" or short type of case record was used throughout. However, adequate charts were maintained on each patient for the benefit of the ward officers and the nurses, and later discarded. The paper work in this fashion was minimized by army regulations, supplemented as described above, and proved adequate. Technical and surgical equipment was most complete and reflected thoughtful and careful planning through the services of supply.

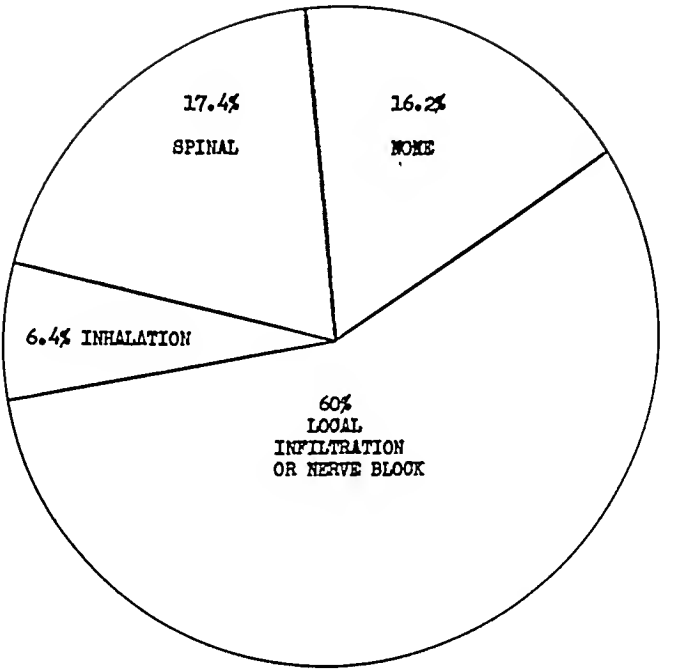

Fig. 3.—The type of anesthesia employed.

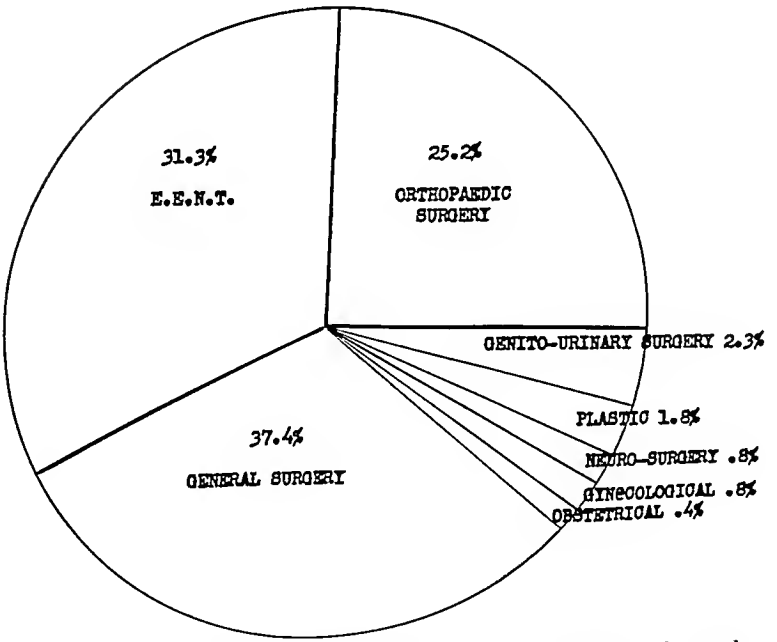

Fig. 4.—The breakdown of surgical cases into types of operative surgical procedures.

These were attended by corps men, nurses, and medical officers alike and were extremely well received. The head nurse on each of the surgical wards, with the aid of her assistant, drilled the corps men assigned to her respective ward in those nursing procedures expected of the corps men. These included assistance with surgical dressings, and handling of patients, as well as mechanical procedures such as the serving of trays, etc. The principal nurse in the operating room held daily drills in which the corps men were taught the theory and then allowed to carry out "scrub up" procedures. They were eventually allowed to scrub for operations and thus actively participated under the direction of a competent nurse. In like fashion these enlisted men received training in the duties of the circulating nurse—the position of the patient, the taking of blood pressures—and in assisting the anesthetist.

Weekly surgical pathologic conferences with presentation of cases, patients, the surgical specimens, x-rays, etc., were held for the entire professional staff and attended by the nurses who were available at that period of the day. Subjects under discussion included, in addition, such "peace time" subjects as surgical lesions of the thyroid gland, internal derangements of the knee joint, a symposium on acute appendicitis, fractures of the humerus, tumors of the anterior triangle of the neck, pneumococcal mastoiditis, infections of the hand with particular emphasis upon human bites, fractures of the pelvis with rupture of the bladder, pathologic fractures of the long bones, and acute mesenteric thrombosis.

The role of the department of radiology in the function of the surgical service cannot be underestimated. The coordination between the two departments was manifest at all times; radiology was purposely located in a section immediately adjacent to the operating room in which all orthopedic cases were cared for. Their service not only offered the routine x-ray and fluoroscopic procedures, but gastrointestinal series, cholecystographic studies, encephelograms, pyelograms, myelograms, etc.

In a similar fashion, the laboratory service carried out such tests as sulfanilamide determinations, CO_2 and O_2 tensions, total and fractional serum protein determinations, Friedmann tests, blood chlorides, Ca and P determinations, anaerobic cultures and provided twenty-four-hour rush hematoxylin-eosin paraffin sections.

Because this installation was located in the zone of combat, although upon its fringe, the "52 Series" or short type of case record was used throughout. However, adequate charts were maintained on each patient for the benefit of the ward officers and the nurses, and later discarded. The paper work in this fashion was minimized by army regulations, supplemented as described above, and proved adequate. Technical and surgical equipment was most complete and reflected thoughtful and careful planning through the services of supply.

The ultimate goal in any medical installation is the result in terms of properly handled patients. The answer may be obtained from the pertinent words of a lieutenant-general of the line who recently inspected this hospital. After visiting some of the wards he turned and said, "I know you have an excellent medical installation here. Its character is reflected in the expression on the face of every patient I see."

In conclusion, let those physicians at home, either in civilian practice or in the service, rest assured that in this numbered station hospital, the medical officers with the excellent assistance of the departments of radiology, the laboratory and physiotherapy, are practicing their respective specialties with equipment in most instances far superior to that available in the United States at the time of this communication. The satisfactory results that are being obtained reflect the excellent medical training these medical officers have had and bespeak the cooperation that holds among all the services of supply.

TRAUMATIC SURGERY

A Review of Some Bone and Joint Injuries in Wartime

A. G. Ord, F.R.C.S. (Edin.), Ralph Shackman, M.B., F.R.C.S.* (Eng.), and H. L. M. Roualle, M.D., F.R.C.S. (Eng.), London, Eng.

(From the Ministry of Pensions Hospital Service)

THIS article is concerned with the records and observations on some particular bone and joint injuries which, we believe, will be of interest to readers. It is hoped that a further communication will record our experience of the treatment of soft tissue injuries, using the Stannard irrigation envelope. The review deals almost entirely with service men injured during training, or, together with the women, while in action on the home front. The majority of the patients were men of the army and the age groups were comparable to the classes which had been called up during the period under review. A few of the civilian air raid casualties belonged to the older age groups.

On account of the record filing system actually in operation, it has not proved feasible to obtain full details on every case; in many individual instances, treatment and evaluation of results have been complicated by repeated evacuations due to the exigencies of war. It is, however, possible to submit Tables I and II, of fractures and joint injuries treated in the course of the years 1941 and 1940, together with the anatomic distribution of these injuries. The relative incidence of fractures thus demonstrated is of interest.

We draw attention to the comparative infrequency of fractures involving the head and trunk in contrast to those of the extremities; the few with which we have had to deal have been managed on orthodox lines with satisfactory results. In the main, it can be stated that the problems are comparable to those met in dealing with civilian and industrial accidents. However, certain aspects have appeared to take on more importance in view of the strict evaluation of results of treatment as interpreted by terms of rapid return to full and arduous duties. Again, ambulatory treatment not only lessens the work of the hospital and its staff but also directly raises the morale of the patients, particularly during periods of enemy air activity.

Fractures of the Upper Extremity.—The age groups into which the majority of our patients have fallen are those in which two particular fractures typically occur, namely, the head of the radius and the waist of the carpal scaphoid. In addition to this, the active life and mechanical work have produced many injuries of the wrist and the fingers.

*Formerly Assistant in Surgery, British Postgraduate Medical School.
Received for publication, April 14, 1943.

TABLE I

FRACTURES	1941	1940
Head:		
Skull	4	3
Nose	8	2
Mandible	2	3
Spine:		
Cervical	2	3
Dorsal	4	2
Lumbar	3	1
Thorax:		
Ribs	8	4
Sternum	0	1
Upper extremity:		
Clavicle	6	7
Scapula	3	5
Humerus	8	5
Forearms:		
Radial head	5	4
Shafts	5	6
Wrist	16	12
Hand:		
Scaphoid	15	6
Metacarpals	13	7
Phalanges	15	10
Lower extremity:		
Pelvis	4	2
Femur	5	10
Patella	4	3
Leg:		
Upper ends	5	9
Shafts	16	16
Ankle	28	23
Foot:		
Tarsus	4	3
Metatarsals	6	12
Phalanges	9	1
Totals	198	160

DISLOCATIONS		
Shoulder	1	3
Acromioclavicular	3	–
Sternoclavicular	1	–
Elbow	4	2
Wrist	1	–
Fingers	1	2
Hip	3	–
Totals	14	7

Fractures of the Head of the Radius.—Although the number of fractures of the head of the radius has not been large, the management has been of interest in view of the divergence of opinion on the question and timing of operation. It has, as a rule, been found at operation that the injury is more extensive than the x-rays have suggested. Of seven cases of fracture of the radial head, one was complicated by concurrent dislocation of the humero-ulnar joint; four of the remainder showed slight cracks only, without displacement, and restoration of function was rapid. In our opinion, the indication for operation is any degree of displacement likely to cause irregularity of the radial

articular surface, which would in turn lead to a progressive osteoarthritis. Where operation is decided upon, we consider that better results are obtained when it is carried out as early as possible, before any damage is done to the capitellar articular surface. The loss of power is slight, and in recent cases the ultimate range of movement obtained should be almost full. Five excisions of the radial head have been carried out, two of them for dislocation (one congenital).

Fracture of Carpal Scaphoid.—The relative number of these cases encountered has been remarkable and the incidence appears to be steadily increasing. The protracted nature of many has emphasized this, as at one time no less than eight were under treatment simultaneously. Of twenty-one cases encountered, five have been transferred elsewhere and three are still under treatment; the remaining thirteen have been returned to full duty. In four recent fractures (three waist, one tuberosity) immediate treatment, i.e., plaster of Paris immobilization for six weeks, has sufficed to ensure demonstrable union, both clinically and radiologically, and less recent fractures have required periods of fifteen weeks or more. After some weeks it appears that an untreated fracture forms a type of fibrous scar which it is difficult for the osteoblastic tissues to penetrate. It has, therefore, become our policy to operate immediately on the majority of these old, hitherto untreated, fractures, as long as necrosis is not perceptible and arthritic changes are not advanced. We have not encountered this until recently, when we saw two cases and propose to carry out arthrodesis of the wrist.

Four operations for bone grafting have been performed through a radial incision: one graft was taken from the tibia, the others from the olecranon; the operation was followed by plaster immobilization until clinical union was confirmed radiologically. In two of these patients complete union was obtained; a six-month-old fracture took three and one-half months; an eighteen-month-old fracture five months; the third patient has been transferred, and the fourth is ununited after five and one-half months.

Acromioclavicular Dislocation.—Although minor degrees of this condition have responded to strapping and physiotherapy, we have had two patients with persistent pain and impairment of function, in whom operative treatment was indicated. The main factors in maintaining the stability of the joint are the coracoclavicular (conoid and trapezoid) ligaments, and the operation performed here is directed to reinforce these rather than the acromioclavicular ligaments, which are quite secondary. Strips of fascia lata, cut with a fasciotome, are passed through the coracoid and clavicle, and secured with catgut. Both patients have made a complete recovery.

Fractures of the Lower Extremity.—The force required to fracture the pelvis or femur, or to dislocate the hip of a young adult, is usually

prodigious, and we have found that such injuries are almost invariably due either to the effects of high explosive or to motorcycle accidents.

In 1940, fractures of the shaft of the femur were treated by the method of continuous traction through a Steinmann pin over a Braun frame. The repeated air raids of the following winter emphasized the helplessness of patients undergoing this form of treatment, many of them already bomb victims, and we have since adopted a walking plaster spica treatment. By this method, the fracture is reduced under x-ray control on a table devised by one of us (A. G. O.), traction being applied both through the tibial tubercle and the calcaneus, with the hip and the knee joints flexed to 30 degrees (see Fig. 1). The position is maintained by a plaster spica extending from the axillae to the toes; the flexion of the hip and the knee preserves the extension and prevents rotation or angulation. These patients can be transported with minimal risk and are able to walk on a stirrup sometimes

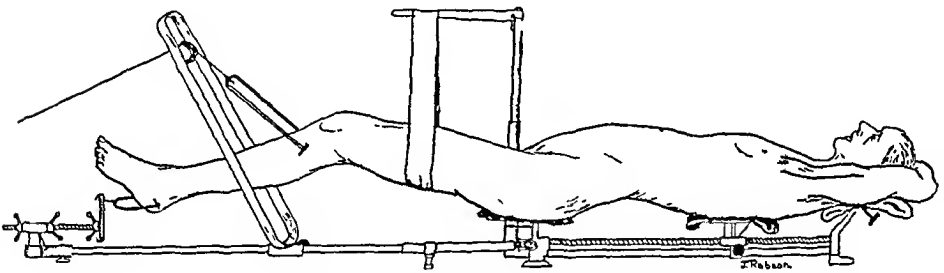

Fig. 1.—Method of maintaining reduction with double pin traction while applying plaster spica.

without crutches or even without sticks, within two or three days, if necessary. No final conclusion can be drawn from the few cases which we have treated ourselves, but two air raid casualties with fractures of the middle one-third produced callus in four to six weeks and were able to bear weight within nine weeks. The criticism that such immobilization causes stiffness of the knee was not confirmed in these men who within six weeks of the removal of the plaster had a knee flexion of more than a right angle. A third man with a compound supracondylar T-shaped fracture, with backward displacement of the lower fragments, required only eleven weeks before union occurred, and after another nine weeks of active physiotherapy had a range of 103 to 175 degrees and was steadily improving. Thus, apart from the good psychologic effect on these patients who are no longer helpless and immobilized, the functional results and duration of treatment appear to compare favorably with other more orthodox methods. Although only three cases have been quoted here, one of us (A. G. O.) has used this method of treatment in over twenty cases, which include some patients of the older age groups. Return of knee function is of course more rapid and complete in the younger patients.

This method of reduction and fixation takes us one hour or more to complete and radiologic assistance is essential. Therefore, we do not advocate carrying out this procedure while air raids are in actual progress, because not only may the x-ray apparatus be out of action as a result of electrical failure, but also because we have found it impossible to afford the necessary time when other more urgent surgical procedures may have to be undertaken. Accordingly, we have inserted a Steinmann pin through the tibial tubercle, under local anesthesia in the ward, and nursed the patient on a Braun's frame. This procedure deals with the emergency and takes only a few minutes. At our leisure on the following day the patient is transported in his bed to the theater where, under general or spinal anesthesia, a Böhler caliper is inserted into the calcaneus and the patient is transferred to the extension table. Reduction under x-ray control and plaster fixation are then carried out.

Fractures of the Tibial Shaft.—Recent observations on the prolonged disability due to this type of injury have been confirmed by us. The subcutaneous character of most of the bone means not only a restricted blood supply but also an increased tendency to compound (open) fracture, which may further delay recovery. From the point of view of management we divide such open fractures into those due to penetration by fragments of bone from within, and those due to foreign bodies penetrating from without, e.g., war injuries. Where possible, the "internal" type is treated by excision of the wound, introduction of sulfonamide, and primary suture; the leg is kept under traction by a Steinmann's pin through the calcaneus and raised over a Braun's frame until the wound is healed, when plaster is applied as in a closed fracture (to be described later). In cases of "external" penetration by foreign bodies, radical débridement is carried out, sulfonamide powder is introduced, and the wound lightly packed open with vaseline gauze, a closed plaster being then applied. If the amount of soft tissue damage is limited, e.g., as is more commonly found in the civilian type of compound fracture, primary suture is undertaken, but this is never done when there is any doubt as to the completeness of the excision, that is, after injuries due to high velocity projectiles.

For the reduction of closed fractures we have preferred vertical traction under x-ray control to the horizontal traction apparatus of Böhler, in which gravity tends to produce backward bowing, and is not used to assist the reduction. Traction is applied by Böhler's ice-tong caliper to the calcaneus or by fixing a stirrup to the retained Steinmann's pin in the case of the compound fractures. In the oblique and spiral fractures the unpadded plaster is extended well above the knee, although this does not appear to be indispensable in completely reduced transverse fractures below the middle one-third of the bone.

Although the latter have not the same tendency to slip as the former, it is our impression that callus formation is often much slower. In all cases, a minimum of ten weeks' immobilization in plaster has been required, and a troublesome complication has been stiffness of the forefoot and ankle when the plaster has been finally removed, due in part to the development of some degree of pes planus and in part to edema following the removal of the cast. In several instances recovery has been delayed for six weeks or more on this account alone. For this reason, after about eight weeks we replace the knee-to-toes plaster with another, incorporating a "slipper" (Figs. 2 and 3). These slippers consist of a leather sole covered with a layer of sorbo rubber. The posterior part of the slipper is incorporated in the plaster which stops

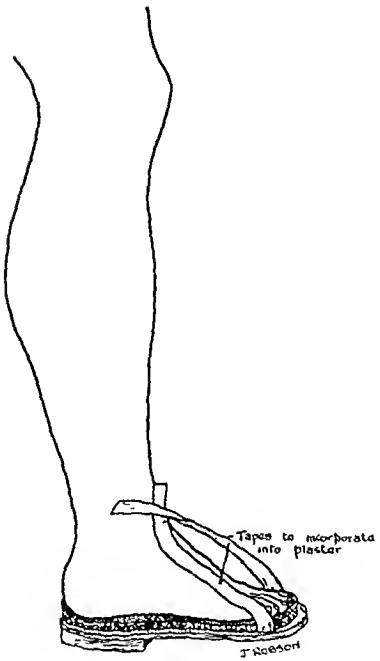

Fig. 2.

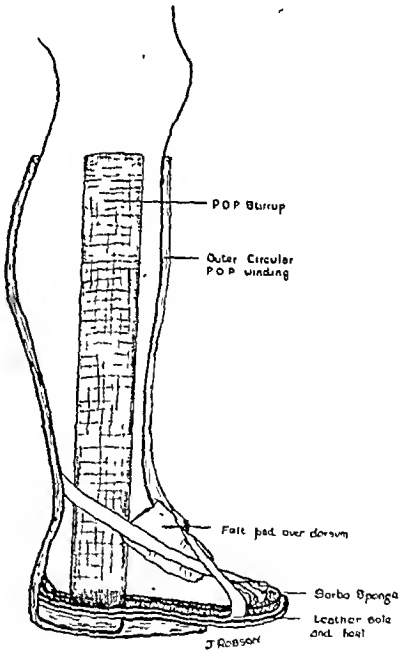

Fig. 3.

Fig. 2.—Sole to be incorporated in cast.
Fig. 3.—Sorbo and leather sole being incorporated in cast to permit active exercise of foot.

short at the midtarsal joint, allowing heel-toe walking and movement of the forefoot while immobilizing the ankle. In wet weather these can be protected by an "elephant boot." These slippers have proved to be of great value in accelerating the return of function. We have used them also in treating sprains and minor fractures of the ankle, where excessive immobilization is to be avoided. They are appreciated by patients who like to feel that they can use the foot despite the injury, and the active exercise maintains the tone of the intrinsic muscles of the foot, and assists the venous return from the limb.

Reduction of fractures has, of course, been confirmed by x-ray control, and here the Victor portable outfit has been very valuable. Fluroscopic screening is not only potentially dangerous to the operator but may be deceptive in many instances. We have found an ultrarapid developing technique an extremely useful alternative. This necessitates a small dark room immediately adjoining the theatre and, for instance, in bone grafting operations, sterile covers (e.g., small pillow slips) are used for the cassettes which can thus be handled by the surgeon without endangering the asepsis. By the use of an express developer the negative can be made ready for inspection on the viewing box alongside the surgeon within ninety seconds of the exposure—before, in fact, the surgeon has had time to rinse his hands and rearrange the towels. In grafting the scaphoid, for instance, the direction of the drill can be checked with absolute precision.

Injuries of and Around the Knee Joint.—A relatively large number of patients with injuries of and around the knee joint have been seen and treated during the period under review. This is to be expected because of the occupation and age group into which the majority of our patients fall. About one-half of the cases dated back their original injury to an accident sustained at football.

From Table II it will be seen that the majority of the injuries were other than cartilage lesions.

TABLE II

KNEE JOINT INJURIES

1. Traumatic arthritis*	
A. Direct contusion	7
B. Torsion injuries	21
2. Internal lateral ligament injuries	14
3. External lateral ligament injuries	2
4. Cruciate ligament injuries	6
5. Quadriceps insufficiency	6
6. Thickened pad of fat	2
7. Fractures	16
8. Loose bodies	3
9. "Painful knee"	1
10. Osteoarthritis	2
11. True internal cartilage injuries	16
12. Internal cartilages (operated elsewhere and with recurrent symptoms)	10
13. External cartilages	5
14. Cysts of external cartilage	8
Total	119

*The term traumatic arthritis is used in preference to the more usual term synovitis because it is visualized that the inflammatory processes of resolution following injury probably implicate other joint tissues.

The primary acute cases have presented little difficulty in diagnosis, but we have been impressed by the difficulties in making an accurate diagnosis in the patients who have suffered from previous disability in the same knee. This seems to have been emphasized by our own operative findings in cases where cartilage lesions have been suspected,

but have not been found; with every patient careful and repeated examinations have been made and a full staff discussion carried out before operation has been undertaken. Further emphasis has been laid by the ten patients who have been admitted here because of recurring symptoms after meniscectomies performed in other hospitals.

It would seem to us that the majority of difficulties in accurate diagnosis have arisen chiefly in patients with traumatic arthritis and associated quadriceps insufficiency, who have been incompletely treated at the time of the primary injury. We cannot, therefore, emphasize too strongly the importance of an accurate diagnosis in the first instance, and thoroughly adequate treatment before the patient passes from the medical officer's supervision.

We have treated the majority of patients with acute traumatic effusions into the knee joint by aspiration as soon as possible under local anesthesia. Varying amounts up to 100 c.c. of bloodstained glairy effusion have been found, and the proportion of blood, as judged by the naked eye, has varied. Generally, it has been considerable, and it appears to us that if such an effusion is left to absorb, the ligaments might stretch under the tension, and the synovial membrane may become thickened with fibrinous deposits, new blood vessels, and inflammatory cells. If this occurs, then together with the associated loss of tone of the quadriceps, a varying degree of instability of the knee joint will result and further repeated intra-articular damage is liable to follow.

After careful clinical and radiologic examination, the aspiration has been followed by application of a firm Robert-Jones bandage (preferably using crepe bandages). Physiotherapy and active exercises, especially weight lifting, have then been carried out under careful and continual observation. For the first few days the bandage is left in position and active exercises are carried out with the knee joint extended. After this, the bandage is removed only during the periods of physiotherapy, and weight lifting from the bent knee position is begun. The bandage is reapplied and remains in position for the patient to begin walking after a week. If care has been taken to treat the quadriceps muscle the bandage can usually be dispensed with after a further week. In spite of this, we have found that it is often six weeks before we have been able to assure ourselves that the man's knee is fit enough to stand up to the rigors of Army life.

We maintain that this type of knee joint injury should be treated with special care and continued observation and encouragement in order to lessen the incidence of recurrence with its increasing difficulty in diagnosis, and the dangers and bad ultimate results which may follow unnecessary operative exploration of the knee joint for doubtful cartilage injuries.

In partial injuries of the medial collateral ligament, we have been interested to note the prolonged residual tenderness, sharply localized, most frequently over its femoral attachment, which frequently lasts six weeks or longer. In addition to physiotherapy, active exercises and wedging of the inner side of the boot, we frequently have infiltrated the injured part of the ligament with novutox or planocaine. In about one-half the cases, the residual tenderness has been permanently abolished, but this procedure has not proved as completely satisfactory as we had hoped.

An unusually high incidence of cysts of the external cartilage have been seen and although the etiology of these cysts is not necessarily or exclusively traumatic, we have included them in this review because the symptoms which led the patients to seek treatment commonly followed some form of trauma, often, it is true, quite mild in nature. Of eight cysts seen, six have been excised, together with the associated cartilage, through a large curved incision laterally over the knee joint. The rapid and complete recovery made by these men has been impressive. The convalescence is shorter, and the result of the operation seems to be more satisfactory, than in other types of knee joint injury.

SUMMARY

A review is given of the anatomic distribution of fractures and joint injuries encountered during the first two years of the war. Attention is paid to injuries commonly causing protracted disability, viz: fracture of the carpal scaphoid, fracture of the head of the radius, and dislocation of the acromioclavicular joint.

The methods used to overcome these difficulties are summarized and the reasons given for

(1) Early excision of the radial head where irregularity of the articular surface may lead to a progressive arthritis.

(2) Grafting fractures through the waist of the scaphoid where they have been untreated for six months or longer.

(3) Reconstructing the coracoacromial, rather than the acromioclavicular ligaments in severe displacements of the acromioclavicular joint.

In fractures of the lower limb, emphasis is laid on the importance of ambulatory treatment, both for the psychologic benefit of the patient and to facilitate his transportation. Details are given of a method used in reducing fractures of the femoral shaft prior to the application of a plaster spica.

Distinction is made between the different types of compound fractures and their management, together with some views on the treatment of fractures of the tibial shaft.

Express x-ray developing is recommended as a valuable and accurate alternative to screening during manipulations or bone grafting operations.

An account is given of our experiences of knee joint injuries. Table II stresses the comparatively large number encountered, and the small proportion of true cartilage lesions. The majority of patients sent in with suspected cartilage lesions were cases of traumatic arthritis following a wrench of the joint. They had received inadequate treatment at the time of the original injury and had, as a result, developed insufficiency of the quadriceps. This had led to repeated trauma which prolonged the duration of disability and increased the difficulties of accurate diagnosis and proper treatment, hence, the vital importance of early accurate diagnosis and correct and adequate treatment is stressed.

The late Dr. H. Lightstone, D.G.M.S., ministry of pensions, kindly gave us permission to publish this article. We record our thanks.

THE EFFECT OF SULFUR COMPOUNDS ON BLOOD CLOTTING*

GEZA DE TAKATS, M.D., F.A.C.S., CHICAGO, ILL.

(From the Fourth Surgical Service and the Martha Borland Surgical Laboratory, St. Luke's Hospital, Chicago)

INTRODUCTION AND PREVIOUS LITERATURE

IN A previous communication,[1] a simple test of the clotting mechanism was described, which briefly consists of the study of the individual's response to a small, test dose of heparin. The coagulation time of capillary blood is determined before, ten, twenty, thirty, and forty minutes after the intravenous injection of 1 c.c. (10 mg.) of purified heparin. Dry, standard-sized capillary tubes are used for this purpose. The individuals tested readily fall into hyporeactors, normal reactors, and hyperreactors. The pattern of such a heparin curve remains surprisingly constant in the same individual as long as seventeen days.[1]

The heparin-tolerance curve permits a study of various factors which influence coagulation of blood. In this report the effect of sulfur compounds on the clotting mechanism is presented.

Heparin, itself, is a mucoitin-polysulfuric acid and its anticoagulant action is in direct proportion to its sulfur content.[2] That sulfur radicals play an important part in intracellular oxydation has been widely recognized since the isolation of glutathione from the tissues by F. G. Hopkins.[3] The active principle of glutathione, cysteine seems to be the intracellular carrier of oxygen.[4]

Both cysteine and methionine, two sulfur-containing amino-acids, have been stated to prolong coagulation and bleeding times by Sterner and Medes.[5] Carr and Foote[6] felt that the accumulation of these sulfurated amino-acids in the plasma of patients suffering from obstructive jaundice explained their tendency to bleed.

The metabolism of such sulfur compounds could be minimized by a low protein, high carbohydrate diet. Of all the thiol compounds, glutathione seemed most potent in its inhibiting action on thrombin.[7] This was only true, however, in a neutral or acid medium. Rabinowitz[8] stated that alteration of clotting time was directly dependent upon the amount of thrombin inactivated by cysteine. Curiously enough, this author advocated cysteine and methionine to control spontaneous bleeding and to restore clot retraction in hemorrhagic purpura. Putman and Hoefer,[9] after carefully conducted animal experiments, gave cysteine to patients suffering from multiple sclerosis and obtained in seventeen out of twenty-three instances a prolongation of the clotting time. When cysteine was first administered to patients at St. Luke's Hospital, we were unaware of this significant experimental and clinical study.

*Aided by a grant of Hoffmann-La Roche, Inc., in Nutley, N. J., Mr. Vincent McCue rendered all technical assistance.

Received for publication, May 28, 1943

Sodium thiosulfate has been advocated for several years in the treatment of Buerger's disease or for the prevention of phlebitis. Rabinowitz[10] and Rabinowitz and Kahn[11] suggested this drug, combined with iodine, to correct disturbance in the phospholipin metabolism, which they found to exist in thromboangiitis obliterans. Bancroft and his associates[12] have extensively investigated the use of sodium thiosulfate in thrombophlebitis and concluded that the incidence or the duration of thrombophlebitis can be materially reduced by the use of this drug combined with a diet low in fats and proteins. In a series of detailed investigations on the changes in the blood in thromboangiitis obliterans, Theis and Freeland[13] stated that inorganic sulfur compounds produce a marked increase in the oxygen capacity and content of the circulating blood. In the active stage of Buerger's disease, they found the oxyhemoglobin to be in an inactive state. The catalytic action of glutathione corrected this anomaly. Their data demonstrated that the administration of inorganic sulfur increased both the reduced and oxydized form of glutathione in the blood.

This partial survey of the previous literature supports the use of sulfur compounds to raise the level of the oxygen catalyst in the blood and tissues and thus influence the oxydation-reduction system in the blood. With the introduction of sodium tetrathionate, which has a more prolonged action and is excreted more slowly than sodium thiosulfate, Theis and Freeland[13] have described a successful correction of the disturbed chemistry in Buerger's disease. Clinically, there can be no doubt about the beneficial influence of intravenous sulfur compounds, especially in migrating phlebitis (own observations). Observations are here reported on the effect of sulfur compounds on heparin tolerance. If sulfur really prevents or inhibits the formation of thrombi, its effect on the reaction to heparin should be noticeable.

METHODS OF INVESTIGATION

Heparin tolerance curves were determined (1) before and ten to thirty minutes after a single dose of sodium thiosulfate or tetrathionate, (2) before and after a course of twelve biweekly injections of sodium tetrathionate, (3) before and after a single dose of cysteine given by mouth, (4) before and after two weeks of oral administration of cysteine. The dosage employed was: 15 gr. (1 Gm.) of sodium thiosulfate and 10 gr. (0.6 Gm.) of sodium tetrathionate given intravenously. Fifteen grains (1 Gm.) of cysteine were given by mouth. For the prolonged administration this dose was given three times a day after meals. No attempt was made to restrict or acidify the diet.

RESULTS

1. *Single injections of sodium tetrathionate:* In every single instance the injection of sodium tetrathionate has increased heparin sensitivity, whether the patient was a hypo-, hyper-, or normal reactor. Fig. 1

shows the curves of the reactions of four patients. It is interesting that in Case 2, where the reaction to heparin was normal, the greatest exaggeration of response was obtained after the injection of sulfur. The least response was obtained in Case 4. The patient in this case had multiple embolic phenomena and had demonstrated clinically his marked tendency to thrombosis. The curves of another group of three patients are shown in Fig. 2. Again, one of the patients (Case 3)

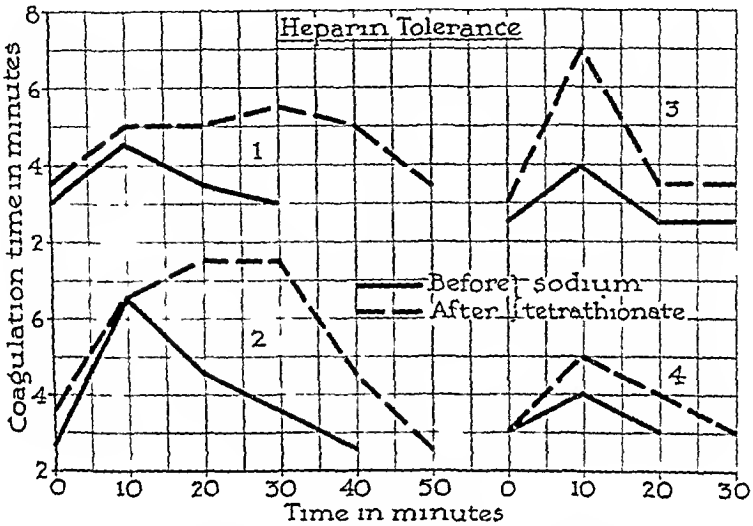

Fig. 1.—Case 1 is that of Marvin M., with migrating phlebitis as a symptom of Buerger's disease. Note the marked prolongation of the effect of heparin after the sulfur compound has been given.

Case 2 is that of Frank M., who was suffering from essential hypertension. He had a normal clotting mechanism and showed a marked response to heparin ten minutes after sodium tetrathionate had been given.

Case 3 is that of F. B., who had a chronic, recurrent type of Buerger's disease and whose heparin response was markedly improved by sodium tetrathionate.

Case 4 is that of Leroy M., who had multiple emboli following coronary thrombosis, one of them resulting in gangrene of the left lower extremity. His response to sodium tetrathionate was very small, indicating a marked clotting tendency.

showed only a small response to sodium tetrathionate. This 45-year-old man, suffering from a subacute stage of Buerger's disease, showed a diminished response in that his coagulation time returned to normal at twenty minutes after the injection of heparin. The injection of sulfur improved this response only very slightly. He had not stopped smoking. As Theis has shown, smoking and sodium tetrathionate antagonize each others action.[13]

2. Another group of patients received twelve injections of sodium tetrathionate, given twice a week. The heparin tolerance was determined before, during, and at the completion of the treatment. Note that the heparin tolerance, which has diminished at the start, improved as early as the third day of the treatment (Fig. 3). In the next graph (Fig. 4) the tolerance curves of three patients are shown who have received twelve injections of sodium tetrathionate; in the case of A.B.

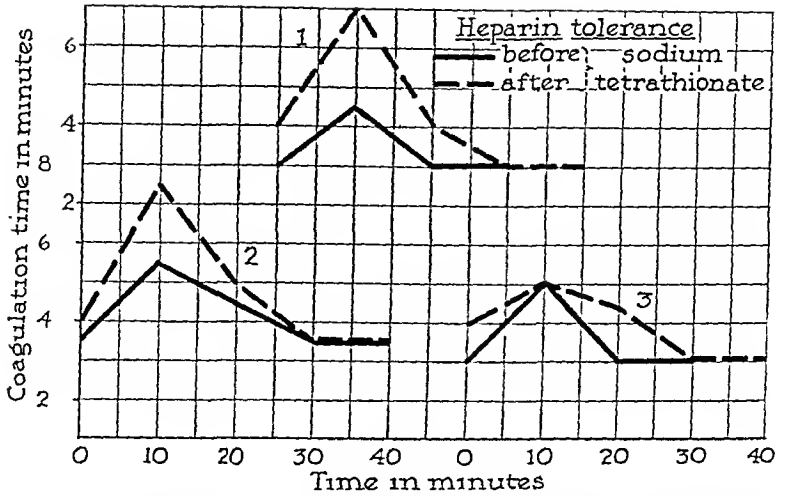

Fig. 2.—Case 1 is that of Thomas McM., 60 years old, with a coronary thrombosis occurring one year previously. The flat heparin curve improved markedly after sulfur.

Case 2 is that of Ida de G., aged 61 years, with a diabetic arteriosclerosis. A normal tolerance curve, greatly improved after sulfur.

Case 3 is that of Dempster S., 45-year-old man, suffering from a subacute stage of Buerger's disease. There was very little response to sodium tetrathionate. The patient was unable to stop smoking.

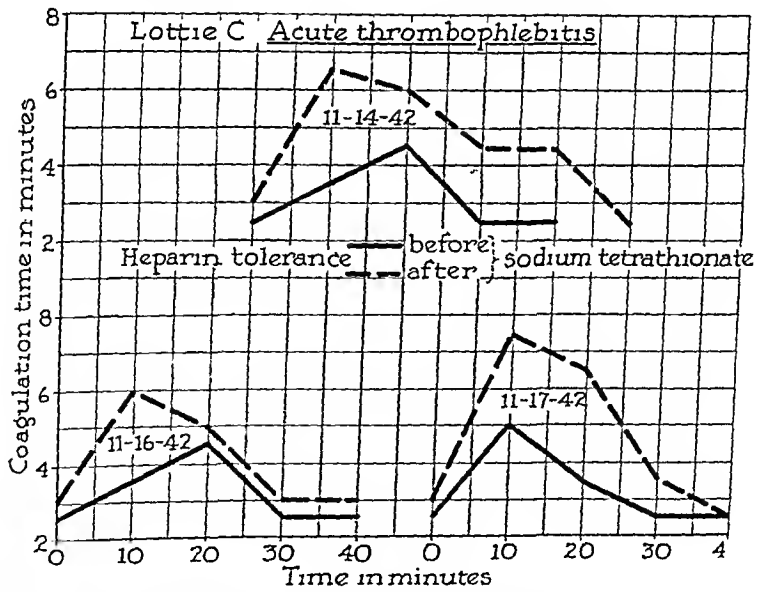

Fig. 3.—Heparin tolerance before and ten minutes after the injection of 0.6 Gm. (10 gr.) of sodium tetrathionate. The patient is Mrs. Lottie L., aged 54 years, who had an acute thrombophlebitis induration of the left lower leg. The first two heparin-tolerance tests show a flat curve, whereas the third one is within normal limits. In all of the three experiments the sulfur compound markedly increased the response to heparin. Given without heparin, sodium tetrathionate has not prolonged capillary coagulation time.

an additional determination was possible after six injections. In the case of Harold B., the sulfur compound produced a "hyperreactor" response,[1] whereas originally this patient's response was abnormally low.

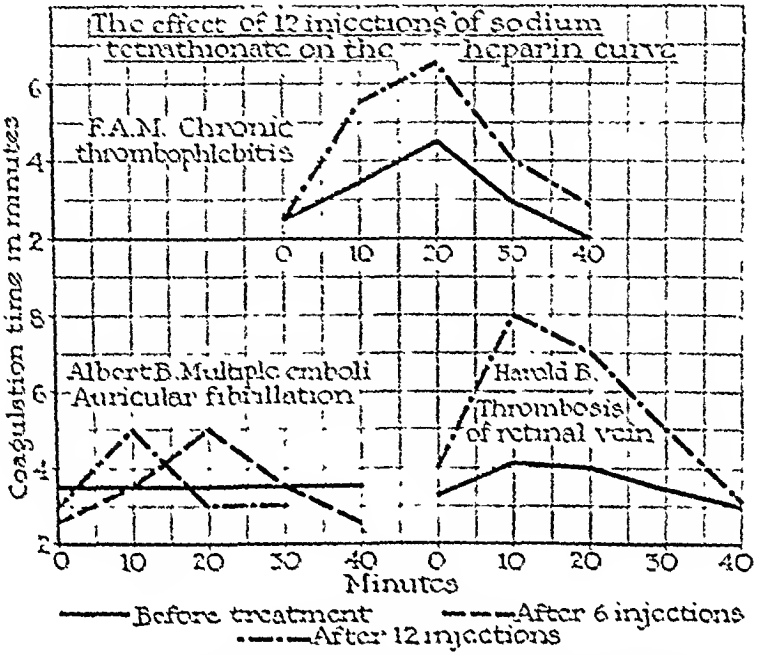

FIG. 4.—Heparin curves before and after twelve injections of sodium tetrathionate. In the case of F. A. M. a somewhat flat curve became high. In the case of A. B. the first curve was quite flat, it improved after six injections and still more after twelve injections, but never has become normal. This patient continues to have emboli from the left auricle into both lower extremities, into the left arm, and two to the brain. The most striking response was obtained in the case of Harold B., who has had several thromboses of the retinal vein. While his initial response was very low, the heparin sensitivity increased considerably and placed him in the hyperreactor group. One peripheral artery was occluded. He has had no further vascular episodes.

3. After a number of single doses of cysteine it was impossible to observe any change in the heparin curves. These determinations were made between 15 and 120 minutes from the time of the oral dose, but failed to show any effect.

4. In a group of ten patients cysteine hydrochloride was given in three daily doses of 15 gr. (1 Gm.) after meals for two weeks. It was impossible to observe any clear-cut effect on the heparin tolerance. In one patient, Anton K., suffering from Buerger's disease, who was admitted to the hospital with a flat heparin-tolerance curve, the curve was restored to normal in twenty-four hours after three doses of cysteine. However, other measures, such as increased fluid intake and abstinence from tobacco, may have been responsible for this effect. Further doses did not increase heparin sensitivity. In no other patient was any change observed. In A. K. cysteine was given, after dicoumarol had lowered the prothrombin level to 40 per cent of normal. During the

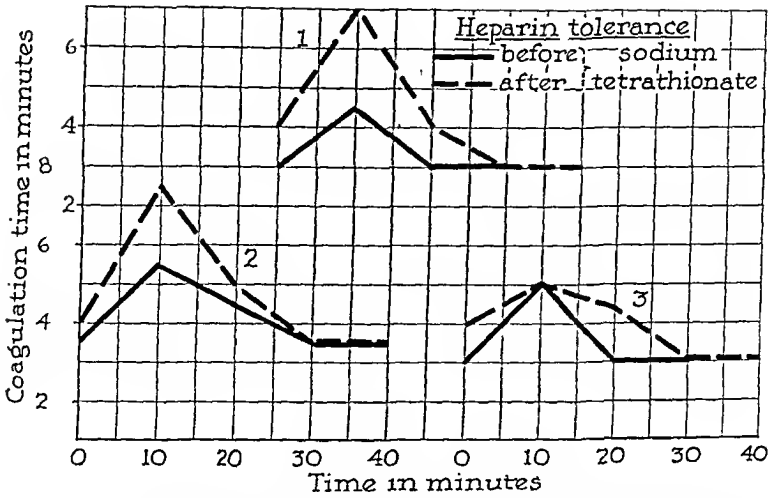

Fig. 2.—Case 1 is that of Thomas McM., 60 years old, with a coronary thrombosis occurring one year previously. The flat heparin curve improved markedly after sulfur.

Case 2 is that of Ida de G., aged 61 years, with a diabetic arteriosclerosis. A normal tolerance curve, greatly improved after sulfur.

Case 3 is that of Dempster S., 45-year-old man, suffering from a subacute stage of Buerger's disease. There was very little response to sodium tetrathionate. The patient was unable to stop smoking.

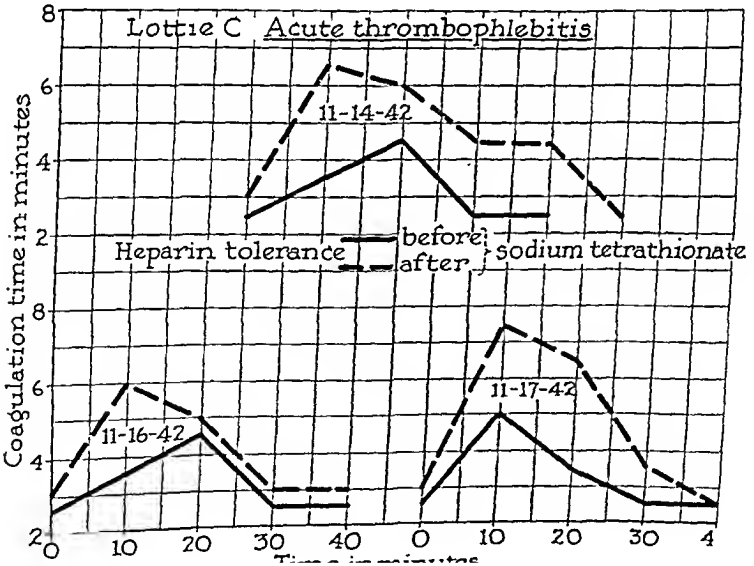

prompted us to advocate small, subreactionary doses of triple typhoid vaccine in Buerger's disease, namely, to desensitize the patient to an unknown specific sensitizing agent.[14] The work of Theis and Freeland[13] has given an entirely different explanation for the beneficial effect of

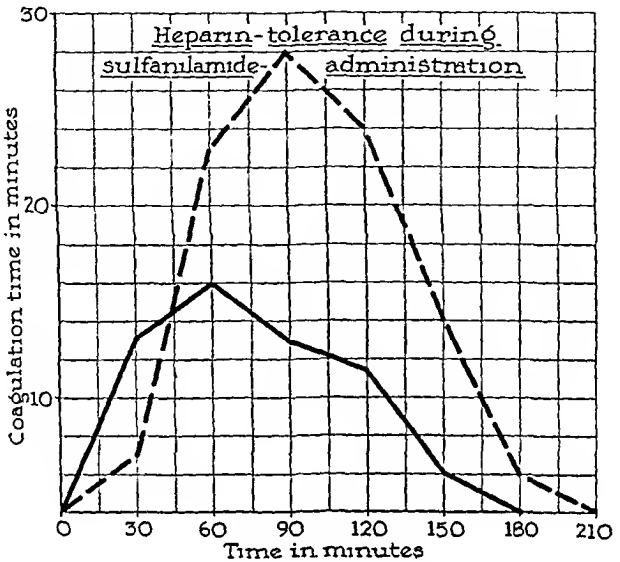

Fig. 5.—Heparin curves after the intravenous injection of 5 c.c. (50 mg.) of heparin; average curve of normal response of four patients. This is the usual therapeutic dose, which has been given to more than fifty patients. Note that the peak of the rise occurs at the first hour and does not exceed fifteen minutes. In the case of M. R., a 26-year-old man suffering from rheumatic heart disease with a superimposed bacterial endocarditis and receiving 120 gr. of sulfapyridine, a considerable increase in the reaction to heparin was obtained. At one and one-half hour after the injection of heparin, the coagulation time rose to twenty-eight minutes. This is a dangerous level, which has never been obtained with the 5 c.c. dose. Further observations are being made on the augmenting effect of sulfonamide drugs on the action of heparin. The sulfapyridine level was 4.2 mg. per 1000 c.c. of blood on the day of the test.

sulfonamide drugs. There can be no doubt that in the acute stages of Buerger's disease the intravenous use of sulfur has given surprising results. Thus, in migrating phlebitis one can observe the rapid absorption of the hot, red periphlebitic exudate in a few days. It has been our custom to give a daily injection of sodium tetrathionate to hospitalized patients for two weeks, then follow it with biweekly injections for six weeks, and a single injection once a week for another six weeks.

There is, however, an urgent need for a safe, inexpensive drug affecting the clotting mechanism, which could be given by mouth for a prolonged period, without daily control of prothrombin times, which must be done if dicoumarol is to be given safely. Cysteine, as we have given it in this group of patients, has not been effective. Sulfonamide drugs obviously should not be given for such a purpose. Whether an acid producing, low protein, low fat diet combined with cysteine can fulfill our need is next is to be tried.*

*In preliminary observations no effect was noted when the diet and ammonium chloride were added to the administration of cysteine.

administration of cysteine, which was maintained for two weeks, the prothrombin-level returned to normal at a rate which it usually does when dicoumarol is discontinued. In addition, the patient who had had multiple peripheral and one cerebral embolus previously, suffered another cerebral embolus while taking cysteine and after having taken a total of 450 gr. (30 Gm.) by mouth in ten preceding days.

COMMENT

The results indicate that sulfur compounds given intravenously definitely increase the patient's response to heparin. It is likely that both the reduced and oxydized forms of glutathione are increased by the injection of sulfur,[13] but the obvious change in the clotting mechanism is that the patient becomes sensitive to heparin.

While it is impossible to observe any change in the clotting mechanism after oral ingestion of sulfur, further trial of this type of medication is still in progress. It may be that by placing the patient on a low protein and low fat diet[6, 12] some effect could be obtained. Also, if the cysteine medication tends to accumulate glutathione in the blood, this catalyst inhibits thrombin only in an acid or neutral medium.[7] The oral administration of ammonium chloride or nitrate might prove useful.

Another group of observations might be cited. Patients receiving sulfonamide drugs have shown a remarkable response to heparin. The first patient on whom this reaction was observed had subacute endocarditis and was receiving 120 gr. (8 Gm.) of sulfapyridine daily. A heparin curve showed a marked increase over the normal pattern (Fig. 5). This finding is important since patients suffering from subacute bacterial endocarditis are sometime given heparin in the customary safe doses and hemorrhages still occur. In I. C., who had an ascending facial infection with nasal and periorbital edema, and was receiving sulfanilamide, not more than three injections of 50 mg. of heparin produced nasal hemorrhages. Certainly, caution ought to be observed in the dosage of heparin when sulfonamide drugs are given.

The action of the intravenously given sodium tetrathionate is very encouraging and we are now using an 0.6 Gm. ampule to each 1000 c.c. of intravenous fluid (dextrose or salt) given postoperatively. In the first communication on heparin tolerance it was shown that the heparin curve becomes flat after major operations for the first two to three days. My associates and I are studying different measures to change this clotting tendency. Obviously, heparin and dicoumarol will never be administered preventively to all patients, but the inexpensive and nontoxic sodium tetrathionate is now in routine use on our surgical service. It will necessarily take many hundreds of cases before a possible decrease of postoperative thrombosis can be observed.

In addition to its use for postoperative patients, sodium thiosulfate has been used for many years on my service in the acute and subacute stages of Buerger's disease. It was used with the same idea that

THE EFFECT OF HEPARIN ON EXPERIMENTALLY PRODUCED VENOUS THROMBOSIS

JACOB RABINOVITCH, M.D., C.M., AND BERNARD PINES, M.D.
BROOKLYN, N. Y.

(From the Departments of Surgery and Pathology, Jewish Hospital, Brooklyn)

THE scope of this communication is limited to the effect of heparin on experimentally produced venous thrombosis. Only a succinct discussion of the pertinent features concerning the mechanism of thrombus formation will be given here, as they have been considered extensively in numerous articles in the literature. It is a well-known fact, definitely established by experimental and clinical research, that the combination of trauma to the endothelial lining of a blood vessel and retardation of circulation in the region of injury is sufficient to effect local thrombus formation. This phenomenon is based on the principle that injury to the blood vessel sets free thromboplastin, and that the latter in turn converts prothrombin into thrombin. The free thrombin converts fibrinogen in the presence of calcium into fibrin and a clot is formed. The reason that blood does not clot intravascularly, is that no thromboplastin is available to convert the prothrombin to the active ferment thrombin. The formation of such a clot is hastened if the local circulation is retarded. On the basis of this knowledge one can produce experimentally an intravascular clot by the simultaneous injury of the endothelium and slowing of the local circulation. It was also shown by Best[1] that heparin may act both as an antithrombin and as an antiprothrombin in the prevention of clot formation, and that some as yet incompletely identified factor, or factors, present in blood serum is necessary for these actions.

In a series of experiments previously performed by one of us (J.R.)[2] it was shown that a forcible pull on a vein sufficient to injure its endothelial lining resulted in local clot formation. Furthermore, when the vein was partially constricted at the site of injury so as to retard the local flow of blood, the clot formed more promptly. Murray, Jaques, Perrett, and Best[3] utilized a somewhat similar procedure in their study of experimental thrombosis in dogs. They made no attempt, however, to retard the flow of blood at the site of injury, and this may account for a certain percentage of failures which they encountered in their experiments. The technique which these investigators employed may be summarized briefly as follows: A small piece of silk thread was passed through the lumen of a vein for a distance of about three-

Received for publication, May 14, 1943.

SUMMARY

With the help of a simple test of the clotting mechanism, namely the determination of the heparin tolerance of the patient, the effect of intravenous sulfur medication was studied. Sodium tetrathionate was found to increase definitely the patient's response to heparin after both single and repeated doses. The use of this drug for the prevention of postoperative thrombosis and for the acute stages of Buerger's disease, in which the heparin tolerance is poor, is definitely worth while. No simple, safe method of administrating sulfur by mouth for the same purpose has yet been found.

REFERENCES

1. de Takats, G.: Heparin-Tolerance, A Test of the Clotting Mechanism, Surg., Gynec. & Obst. 77: 39, 1943.
2. Jorpes, J. E.: Heparin, Its Chemistry, Physiology and Application in Medicine, London, 1939, Oxford University Press.
3. Hopkins, F. G.: On Glutathione, a Reinvestigation, J. Biol. Chem. 84: 209, 1929.
4. Kendall, E. L., McKenzie, B. L., and Mason, H. C.: A Study of Glutathione; Its Preparation in Crystalline Form and Its Identification, J. Biol. Chem. 84: 657, 1929.
5. Sterner, J. H., and Medes, G.: The Effect of Certain Sulfur-Compounds on the Coagulation of Blood, Am. J. Physiol. 117: 92, 1936.
6. Carr, J. L., and Foote, F. S.: Progressive Obstructive Jaundice, Arch. Surg. 28: 277, 1934.
   Naffziger, H. C., Carr, J. C., and Foote, F. S.: Obstructive Jaundice; The Cause and Prevention of Bleeding Dyserasia, Ann. Surg. 107: 743, 1937.
7. Kuhnau, J., and Morgenstern, V.: Glutathione, Schwermetalle and Blutgerinnung, Ztschr. f. physiol. Chem. 227: 145, 1934.
8. Rabinowitz, H. M.: Thromboangiitis Obliterans, Am. J. Surg. 51: 366, 1941.
9. Putman, T. J., and Hoefer, P. F. A.: Cysteine Hydrochloride as an Anticoagulant for Clinical Use, Am. J. M. Sc. 198: 502, 1939.
10. Rabinowitz, H. M.: Thromboangiitis Obliterans, Am. J. Surg. 21: 260, 1933.
    Idem: The Use of Sodium Iodide Thiosulphate in the Treatment of Thromboangiitis Obliterans, J. Chemotherapy 13: 1, 1936.
11. Rabinowitz, H. M., and Kahn, J.: The Relationship of Phospholipin Metabolism to Thromboangiitis Obliterans and Its Treatment, Am. J. Surg. 31: 329, 1936.
12. Bancroft, F. W., Kugelmass, I. N., and Stanley-Brown, M.: Evaluation of Blood Clotting Factors in Surgical Diseases, Ann. Surg. 90: 161, 1929.
    Bancroft, F. W., and Stanley-Brown, M.: Postoperative Thrombosis, Thrombophlebitis and Embolism, Surg., Gynec. & Obst. 54: 898, 1932.
    Bancroft, F. W., Stanley-Brown, M., and Quick, A.: Postoperative Thrombosis and Embolism, Am. J. Surg. 28: 648, 1933.
    Bancroft, F. W., Stanley-Brown, M., and Chargaff, E.: Postoperative Thrombosis and Embolism, Ann. Surg. 106: 868, 1937.
13. Theis, F. V., and Freeland, M. R.: The Blood in Thromboangiitis Obliterans, Arch. Surg. 38: 9, 1939.
    Idem: Thromboangiitis Obliterans, Treatment With Sodium Tetrathionate and Sodium Thiosulphate, Arch. Surg. 40: 190, 1940.
14. Theis, Frank, V., and Freeland, M. R.: Clinical Observations and Arterial Blood Oxygen Studies During Treatment of the Disease With Sodium Tetrathionate and Sodium Thiosulfate, SURGERY 11: 101, 1942.
15. de Takats, G.: Peripheral Vascular Disease; Its Significance for the General Practitioner, J. A. M. A. 104: 1463, 1935.

Technique of producing a venous clot by injuring the vessel wall and slowing the local circulation: Rabbits averaging 2 kg. in weight were anesthetized by inhalation of ether. Under aseptic conditions a midline incision was made through the neck and both jugular veins were exposed. In some experiments both veins were used while in others one was used as control and the other for the actual test. After the vessel was liberated for a distance of about 2 or 3 cm., it was grasped on either side between the thumb and index finger of each hand and forcibly pulled so as to injure the endothelial lining. It was then partially constricted at the site of injury by tying a loose ligature around it, care being taken that the blood continued to flow through the narrowed lumen, although less freely. This procedure was found effective in producing an intravenous clot in each experiment.

Control clot experiments: In six rabbits the jugular veins were injured according to the technique described and the lumen of the vessels narrowed. At the completion of this procedure the wound of the neck was closed by first suturing together the divided fascia over the vein, and then the skin wound was closed with interrupted silk sutures. The animal was allowed to recover from the operation and at the end of twenty-four or forty-eight hours the wound of the neck was reopened and the injured veins exposed. At this time the veins were found occluded for a distance of about ½ to 1 cm. by a loosely adherent red clot. A portion of the vein containing the clot was excised and placed in 10 per cent solution of formalin for sectioning. Microscopic examination of the vein showed it to be occluded by a thrombus composed for the most part of a marginal zone of blood platelets adherent at one point to the endothelium of the vein. The rest of the clot was made up of a fine network of fibrin enmeshing numerous red blood cells and scattered leucocytes (Fig. 1).

Experiments with liquaemin: In six experiments 1 c.c. of liquaemin diluted in 10 c.c. of saline solution was first injected into the rabbit. The jugular veins were next traumatized as previously described, the lumen constricted with a loose ligature, and the wound closed. After four days the neck wound was reopened and the veins examined. It was found that in two rabbits the traumatized veins were occluded by a thrombus seen on both gross and microscopic examination. In the other four rabbits no gross or microscopic evidence of local thrombosis was observed. The injured endothelium had regenerated and there was no break in the continuity of the lumen. (Fig. 2).

In a series of experiments liquaemin was given to the animal both preoperatively and postoperatively. Six rabbits were injected with 1 c.c. of liquaemin diluted with normal saline solution and immediately after, the neck was opened through a midline incision, both jugular veins were exposed, traumatized, and their lumina constricted. Following the operation the animals received liquaemin injections in 1 c.c.

quarters of an inch and the vein crushed against the thread between the jaws of artery forceps. In this way not only the endothelial lining was injured but all the remaining coats of the vessel were equally traumatized. In another series of experiments performed by the same workers, chemical agents such as sodium ricinoleate were used to induce local clotting. These sclerosing agents injure the endothelium to the extent that a local clot will form.

Two problems confronted us in this study. First, would the injection of heparin prevent the formation of an intravascular clot if administered prior to injury of the vessel wall, and second, is heparin effective in causing the solution or disappearance of a clot once the latter has been formed? On this basis, the following experiments were carried out.

Experimental.—Before proceeding with the experiments it was found necessary to study the effect of heparin on the coagulation time of the blood of normal animals. Rabbits weighing 2 to 3 kg. were used. The coagulation time was determined by drawing samples of blood from the ear vein into very fine capillary glass tubes which were broken at regular, short intervals of time, and observed for the appearance of a fine, fibrinous thread. According to this technique the coagulation time of the normal rabbit's blood averaged three to four minutes.

The heparin used was furnished* to us in the form of Liquaemin solution. One cubic centimeter of the solution contained the equivalent of 10 mg. of highly purified heparin. In each of the succeeding experiments with liquaemin 1 c.c. of the anticoagulant was diluted with 10 c.c. of saline solution before it was injected into the ear vein of the rabbit. It was found that the intravenous injection of this amount of anticoagulant prolonged the coagulation time of the rabbit's blood for several hours.

Control experiments: In the following series of experiments the animal was injected with 1 c.c. of liquaemin diluted with 10 c.c. of saline and samples of blood were withdrawn at regular intervals in order to determine the effect of the drug on the coagulation time. An analysis of this study disclosed the following facts. Blood withdrawn 10 minutes after the injection of liquaemin remained fluid for more than ten hours. When removed one-half hour later, clotting took place after six hours. At the end of one hour, the clotting time was shortened to four hours, and at the end of five hours the clotting time returned to normal, namely three to four minutes. These results are represented graphically in Chart 1, and were substantially the same in several animals used as controls. It would appear from the experiments recorded here that in order to keep the blood of the animal fluid, it would be necessary to reinject the anticoagulant at least once every four or five hours.

*Furnished by Roche-Organon, Inc., Roche Park, Nutley, N. J.

the vein. They found that, "in animals where only a single dose of heparin was injected before traumatizing the vein, twelve of the thirteen veins used were completely filled with thrombus and clot and the remaining one was partly occluded. To be effective, the vein had to be removed before the effect of heparin was worn off. In those experiments in which the animal was maintained under the influence of heparin for some time after injuring the vein the incidence of obstruction by thrombus formation was very small."

Fig. 2.—Animal received a preoperative injection of liquaemin; note the absence of clot in the lumen and regeneration of the endothelial lining.

The findings of Murray and his co-workers are not entirely in keeping with our data for several reasons. First, we have found it unnecessary to keep the animal continuously under the influence of the anticoagulant in order to prevent clot formation in the traumatized vein. As has been shown, a single preoperative injection of liquaemin was sufficient to prevent thrombosis in four out of six rabbits similarly treated. Second, in the series of experiments where the animals were injected with the anticoagulant both preoperatively and postoperatively, but after long intervals instead of continuously (twice daily), none had developed a local clot. In this respect, therefore, our findings are in

doses twice daily for periods ranging from two to five days. At the completion of the period of liquaemin administration, the animals were reoperated upon and the traumatized veins examined. It was then found that none of the animals showed any evidence of local clot formation both on gross and microscopic examination. It was also evident that the endothelium had regenerated at the site of the injury.

Fig. 1.—Control experiment; the lumen of the vein is occluded by a typically formed platelet thrombus.

From these observations it may be concluded that the administration of liquaemin both before and after injuring the vessel wall keeps the circulating blood fluid and prevents the formation of a local clot. At the end of four or five days the injured endothelium regenerates completely and thrombus formation does not follow. Animals receiving only a preoperative injection of liquaemin may or may not develop local thrombosis, although in the majority of instances it appears that a single injection of liquaemin is sufficient to prevent clot formation in the injured vessel. Somewhat different results were reported by Murray and his associates[3] in their experiments with heparin in dogs. These workers administered the heparin either as a single dose or in the form of a continuous infusion for seventy-two hours following the injury to

five animals under observation. Microscopically, the lumen of the control was occluded by a typical platelet thrombus. The veins of four of the animals that were injected with liquaemin showed no microscopic evidence of thrombus formation. In the remaining animal, the vein was partly occluded by a retracting clot. The endothelium of the vessel of the heparinized animal had regenerated at this time and the continuity of the lumen was re-established, (Fig. 3). It would appear then that liquaemin can cause the solution or disappearance of a thrombus if administered in the early stages of its formation.

Six rabbits were subjected to the same procedure as described here, excepting that the injection of liquaemin did not begin until the third postoperative day. In three of the animals no clot was found in the vein either on gross or microscopic examination. In one animal the vein was partly occluded by a retracted clot and in the remaining two animals the entire lumen was filled with a thrombus.

Fig. 4.—Experiment in which liquaemin was not administered until the sixth postoperative day. The clot had undergone complete organization with some recanalization; liquaemin had no effect in causing the disappearance of the thrombus.

In four rabbits the injection of liquaemin did not begin until the sixth postoperative day. At this time it was administered in 1 c.c. doses, twice daily, for a period of eight days, at the end of which time the animals were reoperated upon and the veins examined. It was then found that the veins in the entire series were occluded by an adherent thrombus. On microscopic examination the vein in each instance was occluded by a partially organized blood clot containing

contrast to the findings of Murray and his associates and may be explained perhaps on the basis that there exists a difference in potency between the anticoagulants used in the individual experiments, or that the different types of animals used may be a factor. It is conceivable that one type of animal may be more responsive to the effect of the drug than another animal.

Fig. 3.—Experiment in which the vein was traumatized and a clot allowed to form; this was followed two days later by repeated injection of liquaemin in 1 c.c. doses twice daily for a period of six days. Note the complete disappearance of the clot and regeneration of the endothelial lining.

The Effect of Liquaemin on the Formed Thrombus.—In the following series the jugular veins were first traumatized in the manner described, the lumina were constricted, and a clot was allowed to form. On the second postoperative day the wound of the neck was reopened and the injured veins examined. It was then found that both veins were occluded by loose thrombi. A portion of one of the veins bearing the clot was removed for microscopic study and served as control. The constricting ligature was removed from the other vein which was otherwise left undisturbed. The animals were then injected with liquaemin in 1 c.c. doses twice daily for a period of five to six days. At the end of this time the animals were reoperated upon and the remaining vein removed and examined. It was then noted that the clot previously found occluding the vessel had completely disappeared in four of the

thelium of a blood vessel will produce a local thrombus in a large number of instances, and that the formation of this clot is enhanced if the circulation at the site of trauma is simultaneously retarded. Also, the experimental facts cited in this communication demonstrate quite clearly that liquaemin through its prolonged effects on the coagulation of the blood will prevent the formation of such a thrombus if administered to the animal before injuring the blood vessel. It is particularly effective in preventing clot formation if administered both before and after injuring the vessel wall. Of particular interest is the fact that the injection of a single dose of the anticoagulant was sufficient to prevent the formation of a thrombus in a relatively large percentage of the traumatized veins. It will be recalled that Murray and his associates were not successful in preventing the formation of a mechanically produced thrombus in the dog when a single dose of heparin was administered to the animal before injuring the vessel. According to their experiments heparin proved effective only in cases where the solution was administered continuously for some time following the mechanical injury to the vein. An attempt was made to explain these differences in results by assuming that the liquaemin used in the present series of experiments was a more potent anticoagulant than the heparin which they have used. It was also felt that the different types of animals used in the individual series of experiments played a determining role. Such explanations are entirely hypothetical and therefore of little practical significance. While it is conceivable that such factors may exist, no sufficient evidence can be presented at the present time to prove these facts.

Of added interest is the fact that liquaemin is effective in certain instances in causing the solution or disappearance of a clot if given during the early phases of its formation, namely, the second or third day, but it is of no effect if given late after the clot has reached the stage of organization. Here again, it is very difficult to explain the mechanism involved in such a process, since it is a well-established fact that heparin has no effect on fibrin solution. This was substantiated in our in vitro experiments where the addition of liquaemin to fibrin freshly obtained from the rabbit's blood had no effect. It is debatable whether other factors come into play in vivo which are not apparent in vitro and which may explain the solution or disappearance of the clot when liquaemin is used.

The foregoing evidence has a definite clinical application and the importance of these findings is quite obvious. The most dreaded complication of surgery, particularly in the aged and debilitated individual, is the formation of a thrombus. That this picture is not overdrawn is shown by the mortality figures of all the hospitals of the country, and the measures available at the present time to counteract such a catastrophe, to our knowledge, are still inadequate. This is, therefore, a promising development and if by this means it will be possible to pre-

proliferating fibroblasts invading the thrombus. In certain instances there was evidence of recanalization of the thrombus (*Fig. 4*).

The results of the foregoing experiments are quite significant and shed valuable light on the effect of liquaemin on thrombus formation. It appears that under certain conditions liquaemin is effective in causing the solution or disappearance of a clot especially when administered during the very early stages of its formation. It is of no effect if given during the later stages of clot formation, when it is undergoing organization. It is difficult to explain the mechanism of this action, since it is a well-known physiologic fact that heparin is not a solvent of fibrin. It was, therefore, decided to carry out the following experiments in vitro. A few drops of blood were withdrawn from the ear vein of a normal rabbit, allowed to clot, and the fibrin separated. The fibrin

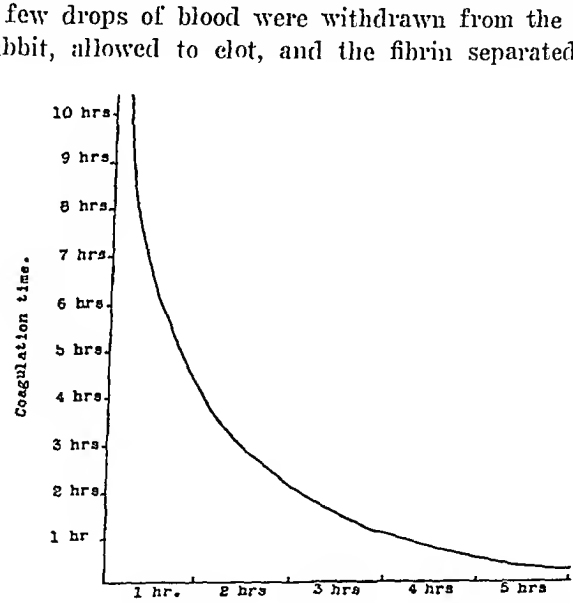

Chart 1.—Time of withdrawal of blood after the injection of liquaemin.

was then mixed thoroughly with various dilutions of liquaemin and incubated at body temperature for several hours. It was found that the fibrin remained unaffected by liquaemin even when the latter was used undiluted. The failure of liquaemin to dissolve fibrin in vitro is in contradiction to the findings noted in vivo, and we are at a loss at the present time to explain the difference in results obtained. One may speculate by saying that some other yet unexplained factor, or factors, may come into play in vivo and may not be apparent in vitro experiments, but this is as far as one can go with the present state of our knowledge concerning the mechanism of liquaemin action.

COMMENT

Conclusive experimental and clinical evidence has accumulated, especially in recent years, to demonstrate the fact that injury to the endo-

INTRAVENOUS CLOTTING AND ITS SEQUELAE

ALTON OCHSNER, M.D., AND MICHAEL DEBAKEY, M.D.
NEW ORLEANS, LA.
(From the Department of Surgery, School of Medicine, Tulane University, and the Ochsner Clinic, New Orleans)

INTRAVENOUS clotting is feared by all surgeons, not because of the venous thrombosis per se, but because of the potential sequelae. The complications of venous thrombosis vary considerably in their manifestations and in their prognosis. Nothing could be more tragic than the sudden instantaneous fatality from massive pulmonary embolism following an apparently normal convalescence from a clean operative procedure, and the persistence of postphlebitic edema following phlegmasia alba dolens is indeed disabling.

It is not within the scope of this presentation to discuss the etiologic factors in intravenous clotting. These have been covered in detail in previous publications.[1-4] It is of importance, however, in considering intravenous thrombosis to differentiate between the two types as previously emphasized by us,[1, 3, 4] not only because of difference in the mechanism of development but also because of the variation in prognosis and therapy. Whereas most postoperative and postpuerperal intravenous thromboses are the result of inflammation of the vein wall with consequent clotting of the blood, i.e., thrombophlebitis, there are many cases of venous thrombosis in which there is no associated inflammation of the vein wall, that is, phlebothrombosis. Thrombophlebitis is accompanied by definite symptoms, pain, fever, and swelling and because of this the diagnosis is easy but the diagnosis in phlebothrombosis is less evident because the symptoms are either very mild or entirely absent. As previously emphasized by us, the latter condition is not associated with an inflammation of the vein wall and for this reason the clot is not firmly attached. There is likely to be little or no pain, no swelling, and no fever. Of greatest importance is the elevation of the pulse rate out of proportion to anything else and frequently a sense of impending disaster by the patient.

The prognoses in the two types of intravenous clotting vary considerably. In thrombophlebitis, because the coagulum is the result of changes in the vascular endothelium caused by the associated inflammation, the clot is firmly attached to the vein wall, and is either a white or

Received for publication, June 5, 1943.

vent the formation of a clot, the prognosis will be materially improved. Whereas this can be determined only by further experience, the anticoagulant certainly merits a trial in all such cases where thrombus formation is prone to occur. The problem is already receiving increasing thought, as is shown by the ever growing investigations upon the subject. Murray has undoubtedly made one of the most important advances in the therapeutic consideration of heparin with the introduction of the anticoagulant in surgery of the vascular system.

It also appears from the results of the experiments cited above, that liquaemin has a definite effect on formed clot, but only when the latter is still in the early stages of its formation. Should this prove to be the fact in the human being, it will unquestionably have a wide clinical application. It will be of particular use in diseases in which there is extensive thrombus formation or expectation of it, such as in pulmonary, coronary, pelvic, and other vessels, and in which there may be great danger to life through embolism as well.

SUMMARY AND CONCLUSIONS

1. An experimental method of producing a thrombus in a vein by injuring its endothelial lining and slowing the local circulation has been presented.

2. Liquaemin has been shown to be a powerful anticoagulant of the rabbit's blood even when administered in small single doses.

3. The administration of liquaemin before injuring the vein and the formation of a thrombus will prevent the subsequent development of a local intravascular clot. It was found unnecessary to administer the anticoagulant continuously in order to obtain the desired effects of the drug.

4. In a certain number of cases, liquaemin proved effective in causing the solution or disappearance of a thrombus but only when given during the early stages of clot formation. It was of no effect when given late after the clot had already organized.

5. The clinical application of these findings has been briefly discussed.

We wish to express our indebtedness to the American Medical Association for their grant which enabled us to carry out these experiments.

REFERENCES

1. Best, C. H.: Heparin and Thrombosis, *Bull. New York Acad. Med.* 17: 796, 1941.
2. Rabinovitch, J.: Unpublished experiments.
3. Murray, D. W., Jaques, L. B., Perrett, T. S., and Best, C. H.: Heparin and the Thrombosis of Veins Following Injury, SURGERY 2: 163, 1937.

branches of the pulmonary artery. This results in infarction of the lung, which is of importance not only because of its associated pneumonitis but also because it is a warning that the patient has a focus from which emboli can originate and produce a fatal embolism. According to Zink,[7] 70 per cent of patients with fatal pulmonary embolism have had an antecedent infarction. As emphasized by Barker, Nygaard, Walters, and Priestley,[6] patients with multiple episodes of pulmonary embolism terminate in a fatality in about 60 per cent. They also found that in all cases of fatal embolism, the final attack was preceded by one or more nonfatal attacks in 36 per cent. Of great importance in nonfatal pulmonary infarction is the necessity of preventing further embolism and particularly massive pulmonary embolism. In addition to this, although of less importance, is the possibility of pneumonitis occurring in the lung as the result of the disturbance in blood supply and superimposed infection of the pulmonary parenchyma. Another possible complication of embolism which occurs relatively infrequently is pulmonary arterial fibrosis which has been emphasized by Belt.[8] He believes that this is likely to follow recurrent, nonfatal embolism resulting in subsequent pulmonary thrombosis and fibrosis.

The sequelae of thrombophlebitis must be divided into two types, those which follow the nonsuppurative variety and are by far the most common and those which follow the suppurative lesions. Those which follow the nonsuppurative type of thrombophlebitis are postphlebitic edema, postphlebitic streptococcic infection, and postphlebitic ulceration. Following the suppurative variety, embolism is the most important sequel. This may result in septic infarction with the development of pneumonitis or pulmonary abscess and even sepsis.

As mentioned previously, the treatment of intravenous thrombosis is primarily that of prophylaxis. If, however, phlebothrombosis or thrombophlebitis occur, their sequelae also can be prevented by prophylactic management, which is without doubt the best form of therapy. The prophylactic therapy for embolism in phlebothrombosis consists of the early detection of the intravenous lesion and the institution of measures to prevent the detachment of the clot with resulting embolism. As mentioned before, the clinical manifestations of phlebothrombosis are not marked, and it is for this reason that the condition is likely to be overlooked unless one considers the possibility of its existence. Too frequently a patient who has had a relatively simple operative procedure and who is apparently convalescing nicely develops a fatal pulmonary embolism upon first getting out of bed. This can usually be obviated. In any individual in whom intravenous thrombosis might occur, particularly if there has been extensive tissue trauma, and in an individual in whom circulatory retardation is likely, such as elderly persons with impaired cardiovascular activity, the possibility of phlebo-

a mixed thrombus. It is for this reason that the clot seldom becomes detached and it is not likely to develop into an embolus. The only conditions under which embolism can occur in thrombophlebitis are in those cases in which a red or coagulation thrombus proximal to the white or mixed thrombus, or in those relatively rare cases of suppurative thrombophlebitis in which liquefaction of the clot by the infection may occur with separation of infected emboli. Although patients with thrombophlebitis seldom develop emboli and therefore do not succumb to massive pulmonary embolism, they live to develop postphlebitic sequelae. On the other hand, patients with phlebothrombosis in whom there is no associated inflammation of the vein wall and in whom the intravenous clotting is the result of changes in the fluid and solid constituents of the blood together with circulatory retardation are potential fatalities because the clot which is a coagulation thrombus is not attached to the vein wall and is easily loosened, resulting in pulmonary embolism, either a massive one or a smaller one resulting in pulmonary infarction.

The treatment of most of the intravenous clottings and their sequelae consists principally in preventing the thrombosis, and although it is not the purpose of this presentation to discuss the causes of intravenous clotting it must be emphasized that any trauma, whether it is the result of an infection, an invasion by malignant disease, operative, accidental, or puerperal injury, produces changes in the constituents of the blood which predispose to clotting. If in addition to these changes there is circulatory retardation, which is likely to occur in the lower extremity, intravenous clotting is favored. By minimizing the operative trauma, the tendency toward thrombosis can be decreased. Of greatest importance, however, is the prevention of circulatory retardation in patients who have had tissue trauma with resulting blood changes. These frequently consist of avoiding vasospastic influences such as exposure to cold, and smoking; the correction of cardiovascular disorders; and the prevention of stasis within the vascular system by overcoming abdominal distention, by encouraging deep breathing, and by mobilization of the extremities.

As mentioned previously, it is not the thrombus per se which is of interest to the physician and patient but rather its potential sequelae. In phlebothrombosis, embolism and its complications are the important sequelae. Embolism may result in sudden fatality because of massive plugging of the pulmonary arteries which has been demonstrated by Gibbon[5] to occur when the lumen of the pulmonary vessel is decreased to 15 per cent or less of its original size. In most cases of pulmonary embolism the attack is not fatal, and according to Barker, Nygaard, Walters, and Priestley[6] only 24 per cent of the cases of pulmonary embolism are fatal with the first attack. In the other cases of pulmonary embolism, the clot is smaller, producing obstruction in the smaller

soft tissue detail. It is desirable to have the roentgenographic tube arranged in such a way that both the lower and upper films can be exposed at the same time. This is possible only if the tube film distance is at least six feet. If it is not possible to have the tube six feet above the table, visualization of the leg and popliteal vessels should be done first and later a similar visualization of the veins of the thigh obtained. Before attempting phlebography it is desirable that one familiarize himself with a normal phlebogram because only by contrasting the findings in a given case with those found normally can one determine whether an intravenous clot is present and accurately locate a thrombus visualized as a defect in the normal venous system.

If phlebography demonstrates the presence of an intravenous clot it is imperative that steps be taken either to remove the clot or to prevent its migration into the systemic circulation. Depending upon the location of the clot the vein should be exposed and either tied above the clot or the vein opened and the clot removed. If the thrombus is located in the superficial vein it is relatively simple to ligate the involved vein above the thrombus. If, however, the deep venous system is involved, in which case the thrombus frequently extends into the iliac, one may either expose the iliac vein and ligate above the thrombus or preferably open the femoral vein at its junction with the saphenous and remove the thrombus by means of suction. This can be done if need be in the patient's room, but is best done in the operating room. Under local analgesia, the femoral vein and its tributaries in its upper portion are exposed. Care is taken not to manipulate the veins any more than is absolutely necessary because a thrombus which frequently is difficult to detect before the vein is opened can be dislodged easily. After careful dissection a ligature is loosely placed around the profunda vein, another around the femoral below this, and another above the saphenous vein is doubly clamped close to the femoral and divided. The distal end is ligated. With the head of the patient somewhat elevated in order to increase the venous pressure, the clamp on the proximal end of the saphenous vein is removed and the edges of the open vein caught with mosquito forceps. If no bleeding occurs it is evident that there is a thrombus in the femoral vein. A suction tip is introduced into the lumen of the femoral vein and directed cephalad. By means of gentle suction the contained thrombus is removed. Complete evacuation of the clot proximal to the opening in the vein is indicated by free retrograde flow of blood from the proximal end of the vein. The ligatures which previously had been placed around the femoral are tied. By this procedure detachment of the thrombus is prevented and embolism is obviated.

Although prophylactic therapy of embolism in phlebothrombosis is the ideal method of treatment, there are many patients who are seen for the first time after embolism has occurred. The active therapy of

thrombosis must be considered. Whereas they do not present the typical picture seen in thrombophlebitis, such as swelling of and pain in the extremity, and fever, they frequently have a tachycardia which is out of proportion to all other findings. This should immediately make one suspicious of the possibility of a phlebothrombosis. This together with an associated increase in erythrocytic sedimentation rate is of diagnostic importance. Of diagnostic importance also is the detection of tenderness along the course of possibly involved veins. In elderly individuals in whom thrombosis is likely, careful routine examinations of the lower extremities are essential. Since many of the thrombi begin in the plantar veins of the soles of the feet, tenderness on compression of the foot is of diagnostic significance. Neumann[9] found that the plantar veins were involved in 71 per cent of cases of intravenous clotting and that solitary plantar vein thrombosis occurred in 12 per cent. Tenderness on forceful compression of the calf muscles and pain in the calf and popliteal space when the foot is forcefully dorsiflexed as suggested by Homans[10] is indicative of thrombosis of the deep veins of the calf. Neumann[9] found the calf veins involved in 87 per cent of cases with intravenous thrombosis and the thromboses were limited to these veins in 29 per cent. Rössle,[11] in post-mortem studies, found that 25 per cent of all patients had calf vein thromboses. One should palpate along the course of the femoral vessels also to determine the possible existence of thromboses in them. Careful measurements of the circumference of the lower extremities are of importance in the early detection of intravenous clotting, and enlargements of one or both extremities is suggestive of beginning thrombosis.

If any of these symptoms and signs are present one must suspect an intravenous clot, and phlebography is imperative. This will not only demonstrate the presence or absence of a clot but will also give its location. Phlebography was advocated by dos Santos[12] and Bauer,[13] and has been popularized in this country by Welch and his associates.[14] It is a procedure which is virtually without danger and should be employed in all suspected cases of phlebothrombosis. Phlebography as practiced in our clinic[15] is briefly as follows: With the patient in the supine position on the roentgenographic table a tourniquet is placed around the upper part of the thigh just below the fossa ovalis and applied tightly enough to compress the superficial veins. A 7 by 14 cassette is placed beneath the leg and lower part of the thigh and a 17 by 14 cassette placed in tandem above this extending up to the pelvis. The lower cassette is placed so that it extends above the knee to include the popliteal vein on this film. The extremity is rotated somewhat medially in order to separate the shadows of the tibia and fibula. Into a superficial vein of the foot are injected 25 c.c. of a 35 per cent diodrast solution at a rate of about 1 c.c. per second. Approximately 25 to 30 seconds after the completion of the injection the exposure is made in order to bring out

limited to the venous system, the symptoms are almost entirely those referable to the arteriolar system, the arteriolar contraction being the result of vasospastic impulses originating in the thrombophlebitic segment.

In addition to the vasodilatation secured by the procaine block of the regional sympathetic ganglia, it is important that the extremity is wrapped with compression bandages. This is best accomplished by the application of an Ace No. 8 bandage from the toes up to the upper limit of the swelling. Immediately after the application of the compression bandage, the extremity should be mobilized. Instead of having the patient keep his legs perfectly quiet as was previously done, he should be made to move them frequently and preferably against a resistance. Active flexion of the foot against a resistance ten to fifteen times every hour is of great value in these cases.

Unfortunately, there are many cases in which active therapy was not used during the acute thrombophlebitis so that postphlebitic edema develops. There are few lesions which are more disabling than the edema which follows an antecedent phlebitis many years previously. It is for this reason that it is desirable that something be done for these chronically disabled patients who have not been adequately treated during the period of their acute phlebitis. Whereas it was our original contention that the chronic persistent postphlebitic edema would be benefited little or none by vasodilatation because it was difficult to understand how vasospasm could play a role in such a lesion, we are now equally as convinced that most if not all chronic postphlebitic edemas can be relieved by the institution of vasodilatation. The results although less dramatic than in acute thrombophlebitis are equally as acceptable to the patient because the patient with the acute thrombophlebitis who is well within a week or ten days cannot appreciate to the same degree the results obtained as can the patient who has had a swollen painful extremity for many years and who is similarly relieved although it may take a longer period of time. It is relatively easy to determine whether or not vasoconstriction is a factor in the production of the symptoms by determining the effect of the vasodilatation on the edema. The patient is instructed to walk a given distance, usually about a mile at a normal rate of speed. Following this, careful measurements of the involved extremity are made. The circumference of the thigh at two levels, the circumference of the knee, and the circumference of the leg at two levels are determined. Procaine block of the homolateral sympathetic ganglia is done and after approximately 20 to 30 minutes have elapsed to permit the block to become complete the patient again walks the same distance at approximately the same rate of speed. Following the completion of this tour, measurements of the extremity at the same levels are made. If there is a decrease in the size of the extremity following the

a patient with pulmonary embolism depends to a large extent upon the type of embolism. If there has been a massive pulmonary embolism resulting in obliteration of a considerable portion of the pulmonary artery, energetic radical procedures are necessary. Because there is probably an associated spasm of the remaining pulmonary vessels, measures to relieve the spasm are of great importance. As emphasized by Jesser and deTakats,[16] the intravenous administration of papaverine and atropine because of their antispasmodic effect are beneficial. Novocain block of the cervicodorsal sympathetic ganglia will relieve many of these patients and save lives. Because their oxygenation is greatly impaired it is imperative that these patients receive inhalations of oxygen in high concentrations as it minimizes respiratory and cardiac efforts.

Although embolectomy as originally suggested by Trendelenburg was considered quite popular one and one-half decades ago, it is now relatively infrequently used. The number of patients who have been saved by this heroic procedure is so small that it offers relatively little in the treatment of pulmonary embolism. Certainly one is most justified in watching the patient who has had one or more nonfatal emboli until fatal embolism occurs as has been suggested by some of the continental workers. It is far better to prevent pulmonary embolism by the prophylactic measures outlined above.

In the patient who has had a nonfatal pulmonary embolism with infarction it is imperative to control the pneumonitis which may result. Fortunately, this is not much of a problem today with the use of the sulfonamides. Oxygen administration is desirable in pneumonitis for the same reason that it is valuable in massive pulmonary embolism.

In thrombophlebitis in which, as mentioned previously, there are marked clinical manifestations and in which the diagnosis is not difficult to make, prevention of sequelae is important. In the nonsuppurative variety postphlebitic edema, postphlebitic streptococcic infection, and postphlebitic ulceration are the most disabling sequelae. As we[1-4] have demonstrated repeatedly, the prophylactic treatment of postphlebitic edema consists of the production of vasodilatation during the acute phase of thrombophlebitis by repeated procaine anesthetization of the regional sympathetic ganglia. Whereas previously the convalescence in these cases was prolonged from six to eight weeks and the postphlebitic edema persisted for months or even years, these patients now can be perfectly well within a week or ten days by the use of this conservative therapy. Daily procaine injections of the sympathetic ganglia should be done as long as the patient has fever because it is our opinion that the persistence of fever is an indication of the persistence of the thrombophlebitic process which results in the spasm of the arterioles, which in turn is responsible for the edema. From a biological standpoint it is of interest that whereas in thrombophlebitis the lesion is

fibrosis resulting from the infection. This condition consists of recurrent attacks of chills and fever associated with burning, itching, pain, and redness of the extremity. These result from the flare-up of a dormant streptococcic infection of the skin of the extremity or as the result of sensitivity of the skin to an acute streptococcic infection elsewhere in the body such as the throat. There is deposited in the skin and subcutaneous tissues a considerable amount of fibrous tissue resulting in a true elephantiasis and characteristically the condition becomes worse with each attack. This is best treated prophylactically by using the same measures used for the prevention of postphlebitic edema. The active therapy of this recurrent erysipeloid condition consists first of producing vasodilatation by the same measures which are used in postphlebitic edema. In addition, compression and active mobilization of the extremity are essential and sulfonamide therapy is necessary. Whereas Ochsner, Longacre, and Murray[22] reported that sulfonamides were of little value in these cases, we have subsequently found that the administration of sulfadiazine in large doses for a week out of each month will usually control and prevent recurrences. As advocated by Trout,[23] the administration of relatively large doses of sulfanilamide not only during the attack but also at monthly intervals for a year is essential. It is the rule in our clinic that these patients receive from 60 to 90 gr. of sulfadiazine a day for a week out of each month. In this way the dormant microorganisms in the tissues or other parts of the body can be eliminated. In a case in which the condition has been present for a long time it is occasionally necessary to resort to a radical procedure such as a modified Kondoleon operation because only by such therapy can the excessive subcutaneous fibrous tissue which is responsible for the persistence of the edema be removed.

Another infrequent complication of thrombophlebitis is postphlebitic ulceration. Here also the treatment consists primarily of prophylaxis and by preventing the thrombophlebitis and the subsequent edema, postphlebitic ulcerations can be prevented. The active therapy consists of the institution of vasodilatation, the use of compression bandages, and mobilization. Sulfonamide therapy is very helpful because of the frequent presence of streptococci in the ulcer and the surrounding tissues. Because these cases also have varicosities of the superficial veins and the communicating veins between the superficial and deep systems, these must be corrected before the ulcer will heal. Generally the usually successful methods of therapy of varicosities will fail because of the presence of one or more large communicating veins in the base of the ulcer in which the valves are incompetent, permitting retrograde flow from the deep to the superficial systems. In order to accomplish a cure it is necessary to ligate these veins, and it is usually desirable to excise the ulcer and surrounding scar tissue and cover the defect with skin graft.

anesthetization it is evident that vasoconstriction plays a role in the production of the edema and it is logical that vasodilatation will have a beneficial effect. In all cases of postphlebitic edema, unless there is some definite indication for active radical therapy, conservative measures should be used. These consist of reflex vasodilatation by the application of heat to an uninvolved portion of the body as originally suggested by Lewis and Pickering,[17] and Landis, and Gibbon.[18-20] This can be accomplished either by immersing an uninvolved extremity, such as the arm, in hot water two to three times a day for about 30 minutes, or by the application of a hot-water bag or heating pad to the abdomen after retiring at night. Repeated procaine blocks of the lumbar sympathetic ganglia are of value and will frequently apparently break the vicious cycle and permit prompt resolution. It is imperative that these patients avoid vasoconstricting measures such as chilling and smoking. Patients should be instructed to avoid getting chilled at all times. They should wear bed socks during the night and should protect their extremities and the rest of their body during cool weather. It is also essential that they refrain from smoking because of the vasospastic influence that it exerts. Of great importance in the conservative treatment of thrombophlebitis is the compression of the involved extremity because it is our firm belief that no individual should be allowed to have edema. This is best accomplished by wrapping the extremity with Ace No. 8 bandages, the wrapping extending from the toes to above the area of swelling. The bandage should be applied in bed before the patient arises in the morning and removed upon retiring at night. The administration of relatively large doses of vitamin B_1 is of value apparently because it favors oxidation in the tissues, which in turn decreases the permeability of the capillary endothelium.

In the severe case and in some individuals for economic reasons, such as the laborer who is incapacitated because of his postphlebitic edema, radical procedures to produce vasodilatation are essential. In these cases resection of the regional sympathetic ganglia to produce a permanent vasodilatation is desirable. Whereas sympathetic ganglionectomy may seem at first thought a very radical procedure, it is undoubtedly the best type of therapy in the individual whose livelihood is jeopardized by disability resulting from persistent postphlebitic edema. By performing the operation through a muscle-splitting approach which we have employed for years it is possible for the patient to be out of bed within three days and be discharged from the hospital on the fifth postoperative day.[21]

Relatively rarely in patients who have had a postphlebitic edema over a long period of time, there may occur recurrent streptococcic infections which are of great importance not only because of the disability which the infection intself produces but also because of the likelihood of

The sequelae of nonsuppurative thrombophlebitis are postphlebitic edema, postphlebitic streptococcic infection, and postphlebitic ulceration. All these are best treated prophylactically, i.e., the institution of vasodilatation during the acute stage of thrombophlebitis. Vasodilatation is of great benefit even after the sequelae have developed. Postphlebitic streptococcic infections, in addition, require the administration of sulfonamides at regular intervals for a year or more.

In postphlebitic ulceration the associated varicosities of the superficial and communicating veins must be corrected.

The treatment of embolism is also that of prophylaxis. In phlebothrombosis early detection of the thrombus by phlebography and either the removal of the clot or the ligation of the vein above the clot are imperative. In suppurative thrombophlebitis, ligation of the involved vein above the thrombophlebitic segment or the extirpation of the involved vein and thrombus is necessary to prevent pneumonitis, sepsis, and death.

REFERENCES

1. Ochsner, Alton, and DeBakey, Michael. Thrombophlebitis and Phlebothrombosis, South. Surgeon 8: 269, 1939.
2. Ochsner, Alton, and DeBakey, Michael. Therapy of Phlebothrombosis and Thrombophlebitis, Arch. Surg. 40: 208, 1940.
3. Ochsner, Alton, and DeBakey, Michael. Therapeutic Considerations of Thrombophlebitis and Phlebothrombosis, New England J. Med. 225: 207, 1941.
4. Ochsner, Alton, and DeBakey, Michael. The Role of Vasospasm in Thrombophlebitis and Its Treatment by Novocain Block or the Sympathetics, Tri-State M. J. 13: 2654, 1941.
5. Gibbon, J. H.: Pulmonary Embolism. A Review of Recent Contributions, Pennsylvania Med. J. 42: 877, 1939.
6. Barker, N. W., Nygaard, K. K., Walters, Waltman, and Priestley, J. T.: A Statistical Study of Postoperative Venous Thrombosis and Pulmonary Embolism: Predisposing Factors, Proc. Staff Meet., Mayo Clin. 16: 17, 1941.
7. Zink: Cited by Aschoff, L. Ueber Thrombose und Embolie, Wien. klin. Wchnschr. 51: 1277, 1938.
8. Belt, Thomas H. Late Sequelae of Pulmonary Embolism, Lancet 2: 730, 1939.
9. Neumann, R.: Ursprungszentren und Entwicklungsformen der Bein—Thrombose, Virchows Arch. f. path. Anat. 301: 708, 1938.
10. Homans, John. Circulatory Diseases of the Extremities, New York, 1939, The Macmillan Company.
11. Rossle, R.: Ueber die Bedeutung und die Entstehung der Wadenvenenthrombosen, Virchows Arch. f. path. Anat. 300: 180, 1937.
12. dos Santos, J. C. Direct Venography, Conception, Technique, First Results, J. Internat. de Chir. 3: 625, 1938.
13. Bauer, Gunnar. A Venographic Study of Thrombo-Embolic Problems, Acta chir. Scandinav. (Suppl. 61) 84: 1, 1940.
14. Welch, C. E., Paxon, H. H., and McGahey, C. E. The Application of Phlebography to the Therapy of Thrombosis and Embolism, SURGERY 12: 163, 1942.
15. Schroeder, G. P., DeBakey, Michael, and Ochsner, Alton: Significance of Phlebography in Phlebothrombosis. (In Press.)
16. Jesser, H. H., and deTakats, Geza. The Bronchial Factor in Pulmonary Embolism, SURGERY 12: 541, 1942.
17. Lewis, T., and Pickering, G. W. Vasodilatation in the Limb in Response to Warming of the Body With Evidence for Sympathetic Vasodilator Nerves in Man, Heart 16: 33, 1931.
18. Gibbon, J. H., Jr., and Landis, E. M. Vasodilatation in the Lower Extremities in Response to Immersing the Forearm in Warm Water, J. Clin. Investigation 11: 1019, 1932.

Suppurative thrombophlebitis is frequently associated with puerperal sepsis and occasionally in other infections involving an extremity. The danger in such a case is the breaking off of infected emboli with the production of secondary septic processes at the site of lodgment of the embolus and also the possibility of a blood stream infection. Here again prophylaxis is of greatest importance. Ligation of the vein proximal to the site of the thrombus is imperative. Occasionally, excision of the involved vein is the preferable procedure as is frequently the case in thrombophlebitis involving the superficial veins of the extremity. These same procedures are used as active therapy once the condition has occurred. The site of election for the vein ligation depends upon the veins involved and the extent of the process. In many cases of pelvic infections associated with septic puerperal infections because of the widespread involvement, it is necessary to ligate the vena cava. Conrad Collins, of our department of gynecology, has ligated the vena cava in twelve cases of suppurative pelvic thrombophlebitis. This procedure has also been done on our service in three cases of suppurative thrombophlebitis originating in the pelvic veins, and it is astounding to see the dramatic results which can be obtained in these cases following the ligation of the vena cava, which mechanically prevents the dissemination of infected emboli.

Although ligation of the vena cava may seem a very radical procedure and far too extensive to be justified, our results demonstrate that not only is the operation lifesaving but also that it is attended with little risk and few if any sequelae. Nothing is more dramatic than the complete cessation of all chills and the prompt subsidence of fever in a patient who previously had recurrent chills and fever and was critically ill. The results in such a case are due to the prevention of dissemination of the infected emboli which if allowed to continue would almost invariably result in sepsis and death.

SUMMARY

Intravenous clotting per se is of little significance but its sequelae are of great importance.

In the consideration of the sequelae of intravenous thrombosis, it is necessary to differentiate between the two types of intravenous clotting, i.e., phlebothrombosis and thrombophlebitis. The thrombus in the former is loosely attached and is likely to become detached resulting in embolism. Embolism in thrombophlebitis occurs infrequently because the thrombus is firmly attached to the vein wall. Only when a coagulation thrombus, which is a red clot and not attached, forms proximal to the thrombophlebitic area, or when suppuration occurs in the thrombophlebitic processes, with liquefaction of the clot, does embolism occur in thrombophlebitis.

ONE-STAGE PERINEO-ABDOMINAL OPERATION FOR CANCER OF THE RECTUM

ALBERT O. SINGLETON, M.D., GALVESTON, TEXAS
(From the Department of Surgery, Medical Branch, University of Texas)

THE Kraske operation for cancer of the rectum, which came into use about fifty years ago, was probably the most serious procedure that surgery imposed upon a patient at that time. At least, it was one of the most tedious and difficult, if not the most hazardous of operations. This was a very courageous attempt to eradicate cancer of the rectum and the areas to which it spread, and in truth it was a far step in the satisfactory removal of cancer in this region. Properly done, the entire rectum and a large amount of the sigmoid could be removed, with the gland-bearing tissues as well. It necessitated a perineal colostomy which was more acceptable to the patient, and for a long time it seemed to be as satisfactory as an operation could be in this part of the body for this disease. Still the mortality was high, and subsequent studies of the spread of the disease showed that cancerous tissue was left which might be removed with a still more extensive operation, provided the abdomen was opened and an abdominal colostomy was resorted to.

At the present time the maximum attainment in surgical procedures for eradication of cancer of the rectum is that based upon the operation which now carries the name of Miles radical procedure, which, as is well known, contemplates the complete removal of the anus, rectum, and lower part of the sigmoid flexure with gland bearing tissue about these parts of the large bowel. This procedure has been popularized by a great many capable surgeons. Rankin, Jones, Bartlett, and others have made some modifications of the Miles procedure but generally the operation is the same, and the abdomino-perineal procedure in the sequence mentioned is used by a great majority of surgeons at this time. We practiced this operation for some time but found it technically quite difficult on any occasions, particularly in the male patient whose pelvis is very deep and narrow. Also, the difficulty was increased if there was distention of the bowel, and if the anesthetic was not perfect.

Since 1930, we have utilized the reverse sequence in the operation, that is, the perineo-abdominal sequence, almost exclusively because we have found this method so very much easier to perform and our patients are in much better condition after the operation than previously experienced. We have done the operation on forty-six consecutive patients

Received for publication, June 1, 1943.

19. Landis, E. M., and Gibbon, J. H., Jr.: Simple Method of Producing Vasodilatation in Lower Extremities With Reference to Its Usefulness in Studies of Peripheral Vascular Disease, Arch. Int. Med. 52: 785, 1933.
20. Landis, E. M.: Observations on Diagnosis and Treatment of Peripheral Vascular Disease, Ann. Int. Med. 8: 282, 1934.
21. Oehsner, Alton: Indications and Technique for the Interruption of Impulses Traversing the Lumbar Sympathetic Ganglia, S. Clin. of North America. (In Press.)
22. Oehsner, Alton, Longacre, Alfred B., and Murray, Sam D.: Progressive Lymphedema Associated With Recurrent Erysipeloid Infections, SURGERY 8: 383, 1940.
23. Trout, Hugh: Personal communication.
24. Collins, Conrad, Jones, Jack, and Nelson, Edward: Surgical Treatment of Pelvic Thrombophlebitis; Ligation of Inferior Vena Cava and Ovarian Veins, New Orleans M. & S. J. 95: 324, 1943.
Idem: Pelvic Thrombophlebitis; a Study of the Etiologic Factors From a Statistical Standpoint, New Orleans M. & S. J. 95: 375, 1943.

In women it is not necessary to disturb the coccyx. The rectum is freed in the usual way, the inferior hemorrhoidal vessel being identified and doubly ligated, and the levator muscles cut wide of the rectum (Fig. 2). The fascia propria is identified and incised (Fig. 3), and by blunt dissection with the hand within the fascia, the rectum is freed from the hollow of the sacrum.

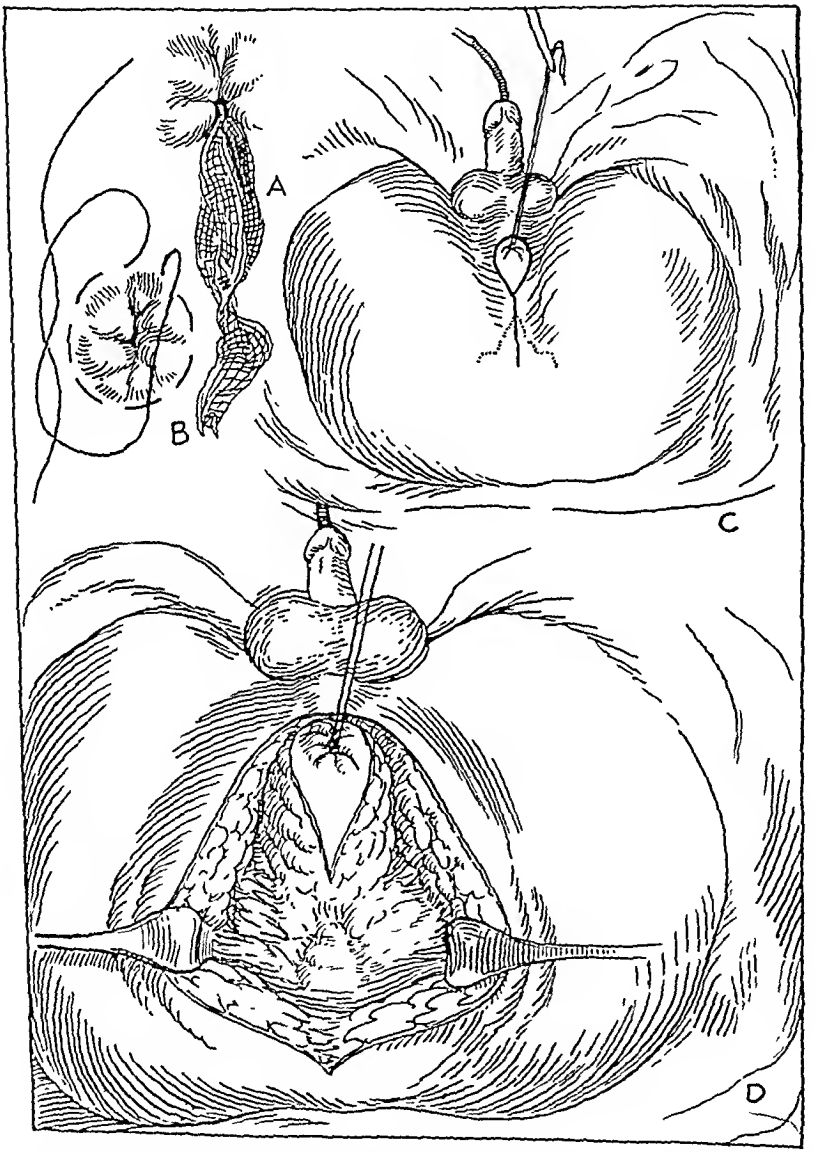

Fig. 1.—Patient in extreme lithotomy or gynecological position; catheter in bladder. (*A*) Yard strip of gauze passed into rectum (*B*). (*C*) Rectum closed with two purse-string stitches. (*D*) Incision made from just above coccyx toward the midline and forward around the anus.

for cancer of the rectum. Of these patients, two have died following operation, both early in our experience. One patient apparently died of delayed shock as autopsy revealed no cause for death although generally he was a very favorable risk. The second patient, a woman, had an intestinal obstruction due to a herniation of a loop of bowel through the perineo-peritoneal suture line, which should not have occurred, and should have been recognized early enough to prevent death. No patient other than these two was in a grave condition at any time and we have not had a death in the last thirty-nine consecutive cases. We are so impressed with the advantages of the operation that we are here giving a description of the procedure and also a discussion of the advantages and disadvantages of it.

METHOD OF PROCEDURE

1. A purgative is given forty-eight hours before operation. We do not emphasize a long preoperative preparation of the patient as is so generally stressed by many writers. If the colon is very empty we see very little reason for endeavoring to make it completely empty or clean from the standpoint of number of bacteria, by days of fasting and repeated purgation. An enema is given the night before the operation.

2. An indwelling Levin tube is passed in the stomach and gastric suction started before the anesthesia begins. This gastric suction is maintained for a period of three to four days following operation, eliminating all danger of postoperative ileus and distention.

3. The patient is placed on the operating table in an extreme lithotomy position (Fig. 1). We formerly did the perineal portion of the operation with the patient lying on his face over the table with the buttock elevated, which we thought quite satisfactory, but there was some confusion when the patient had to be turned over on his back for the abdominal portion of the operation. For some time we have used the lithotomy position and find it an advantage in that the orientation of the anatomy is more satisfactory and the confusion and trouble of turning the patient over for the second part of the operation is eliminated. An indwelling catheter is placed in the bladder and the bladder allowed to remain empty during the operation and for one week subsequently. The perineal region is scrubbed thoroughly with soap and water and a good brush, and antiseptics used for perineum, buttock, anus, and scrotum.

4. A yard strip of dry gauze is passed into the rectum (Fig. 1). This serves the purpose of identifying the rectum and facilitating dissection; also it absorbs fluid content should there be fluid in the rectum, reducing the danger of soiling if the bowel is accidently opened. Next, the anus is closed by a double row of purse-string sutures, making the anal closure very secure. The incision is made in the usual way from over the coccyx around the anus; in men the tip of the coccyx is removed.

middle hemorrhoidal with the triangular ligaments to the rectum are identified by blunt dissection, ligated, and the rectum freed on each side.

By pushing the peritoneum off the prostate, one opens the peritoneum and enters the peritoneal cavity. This opening is made entirely around

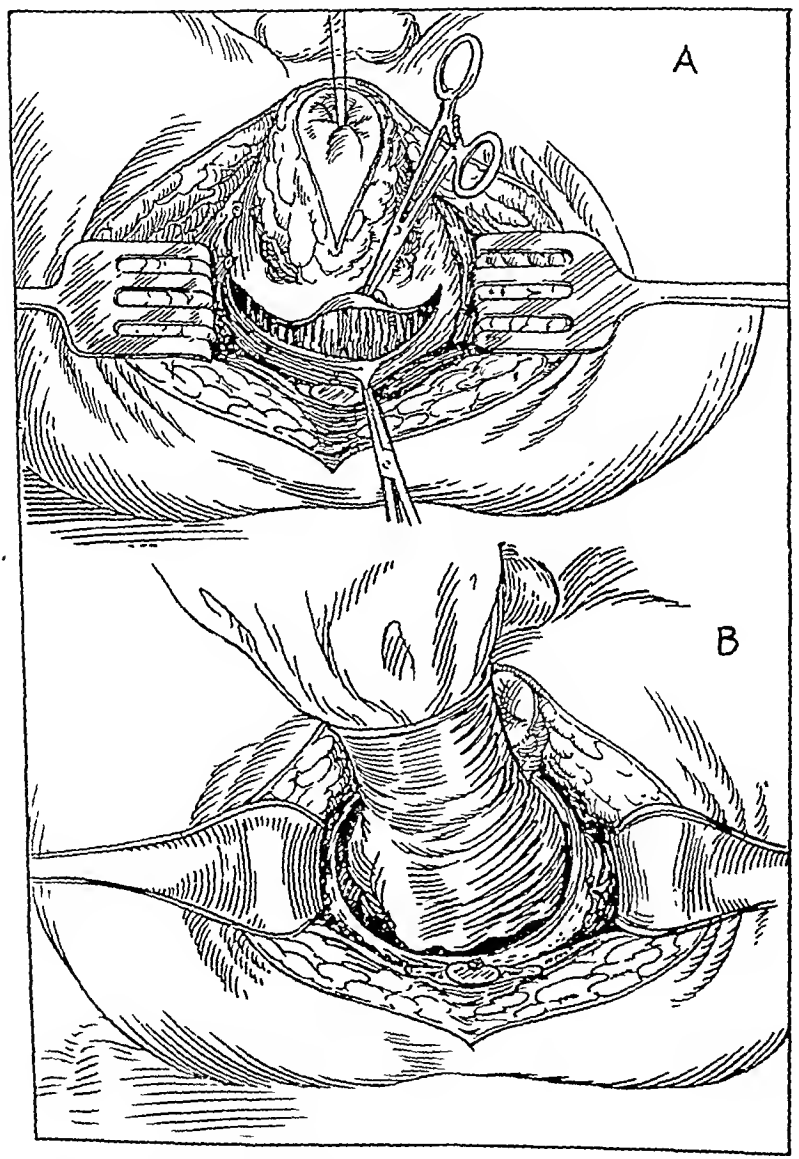

FIG. 3.—(*A*) Fascia propria incised. (*B*) The rectum freed from the hollow of the sacrum by the hand passed within the fascia propria and around the rectum.

the sides and in front of the rectum and the rectum may then be drawn down considerably and the lateral attachments of the peritoneum to the rectum incised up on to the sigmoid.

From in front, the separation is made between the urethra and prostate and the rectum in men (Fig. 4). In women the rectum may be dissected from the vagina, but much time and bleeding may be saved

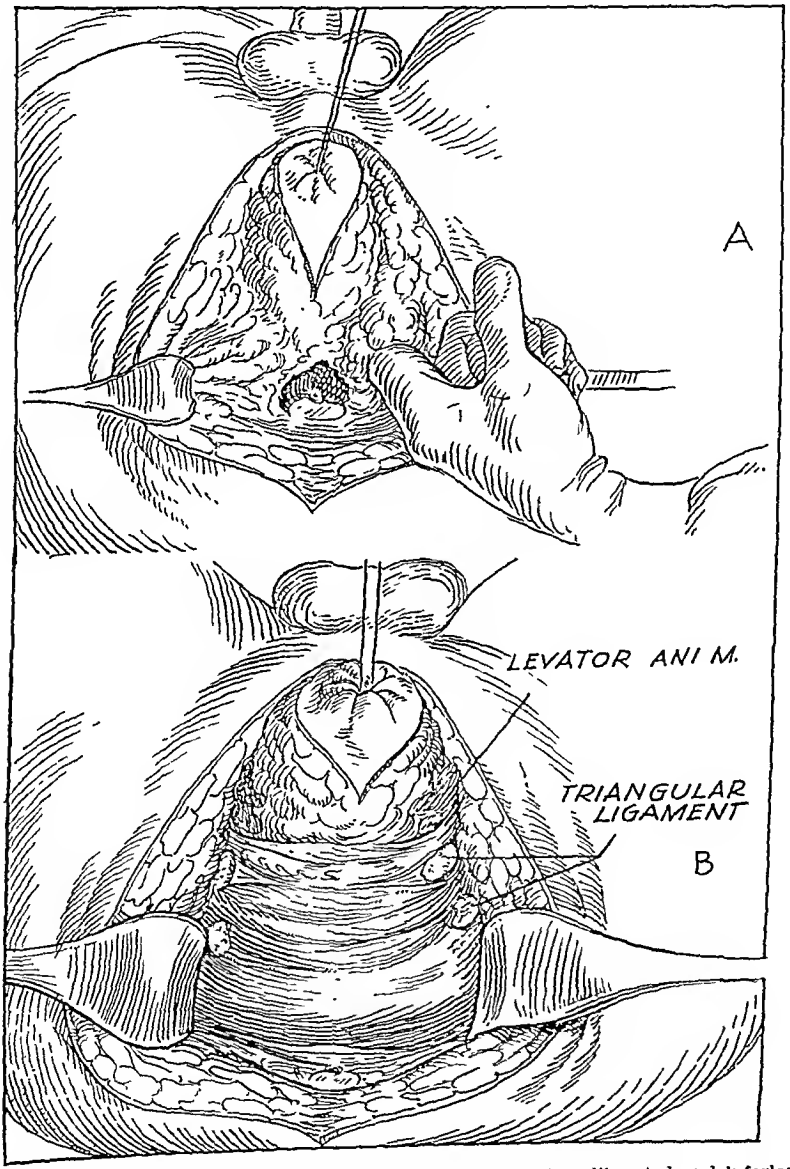

Fig. 2.—(*A*) Coccyx removed in men not in women. Rectum liberated and inferior hemorrhoidal vessels ligated. (*B*) Levator ani muscles cut widely, triangular ligaments of middle hemorrhoidal vessels cut between ligatures.

by removing the posterior wall of the vagina with the rectum. This also has the advantage of lessening the danger of entering the rectum, as well as being a more complete removal of cancer bearing tissue. The

middle hemorrhoidal with the triangular ligaments to the rectum are identified by blunt dissection, ligated, and the rectum freed on each side.

By pushing the peritoneum off the prostate, one opens the peritoneum and enters the peritoneal cavity. This opening is made entirely around

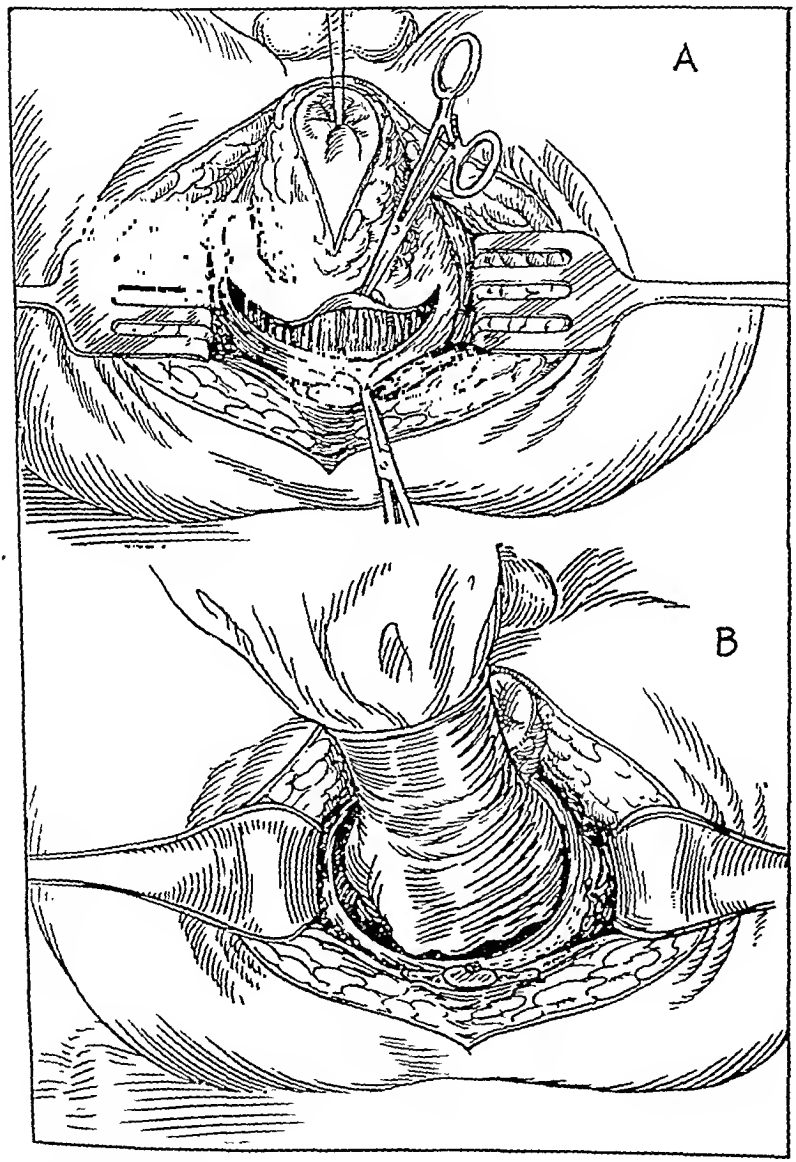

FIG. 3.—(*A*) Fascia propria incised. (*B*) The rectum freed from the hollow of the sacrum by the hand passed within the fascia propria and around the rectum.

the sides and in front of the rectum and the rectum may then be drawn down considerably and the lateral attachments of the peritoneum to the rectum incised up on to the sigmoid.

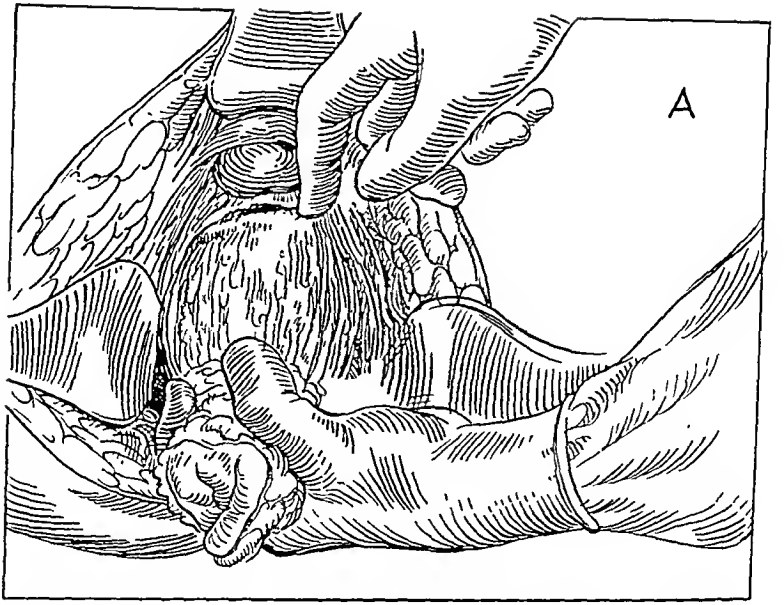

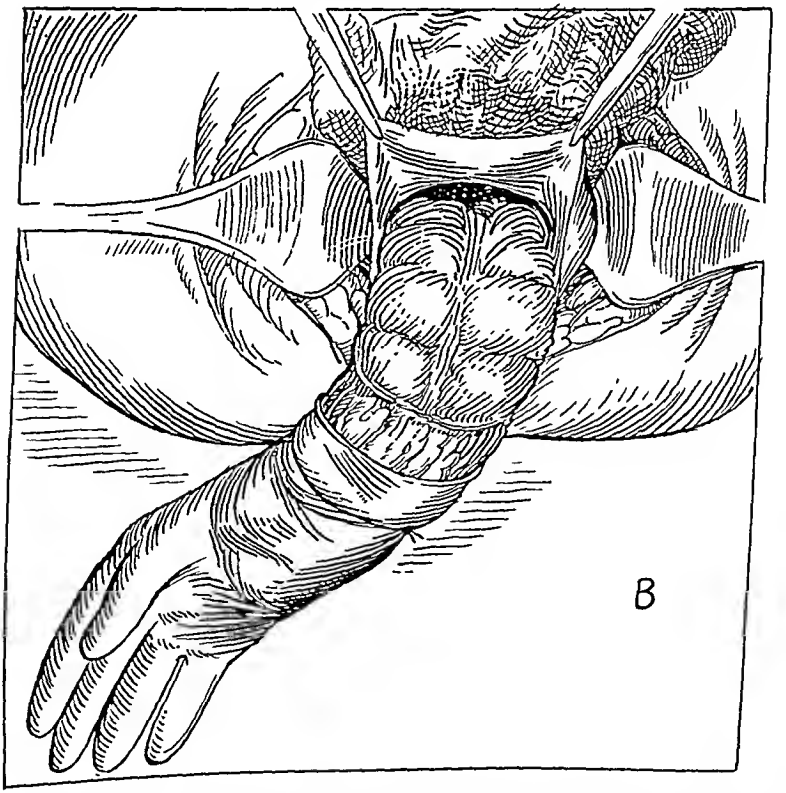

Fig. 4.—(*A*) The rectum is freed from the corpora spongiosum, urethra, and prostate in front. In women the posterior vaginal wall we[illegible] rectum. (*B*) Above the prostate the peritoneal cavity is e[illegible] incised in front and around the rectosigmoid. The perit[illegible] rectum is incised further up the sigmoid and the rectum and [illegible] A sterile glove is now placed over the rectum and tied secure[illegible]

A sterile glove (Fig. 4) is placed over the anal and rectal portion and tied securely, high up, with a strong ligature around the bowel (Fig. 5). Then this portion of the bowel covered with glove is pushed into the peritoneal cavity. The peritoneum, beginning at the bladder, is sutured with a size 0 chromic catgut doubled on a round muscle

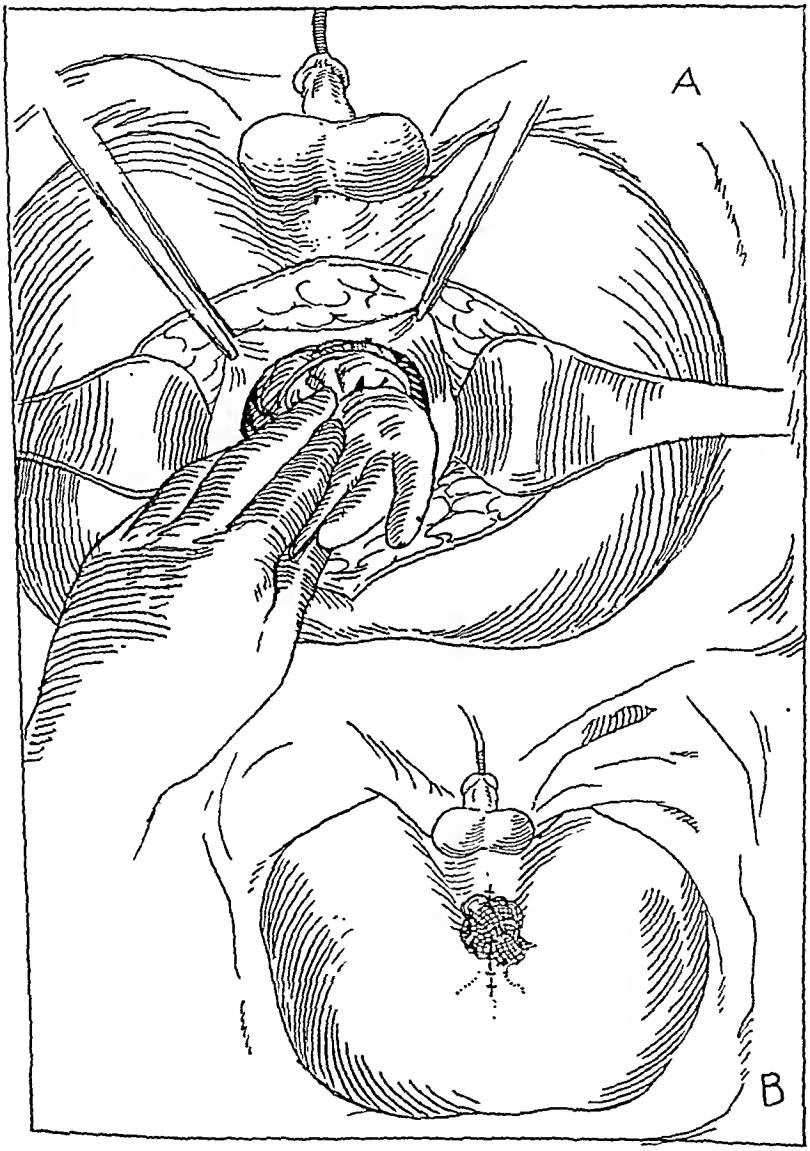

Fig. 5.—(*A*) The rectum covered with a sterile glove is now pushed into the peritoneal cavity. Suture of the peritoneum, beginning near the bladder, is begun with a continuous chromic stitch. The needle and sutures are wrapped on a piece of gauze and pushed in the abdomen. (*B*) A large rubber-covered pack of iodoform gauze is placed in the ischiorectal cavity and the perineal wound closed about it with interrupted skin stitches. Dressings are applied and the patient placed flat on the table prepared for the laparotomy.

needle. The peritoneum is brought together for a short distance and then the needle and suture is wrapped securely around a piece of gauze and pushed into the abdominal cavity. Hemostasis has been controlled as the operation proceeded. The hollow of the sacrum and perineal space from which the rectum has been removed is filled with a large pack of iodoform gauze wrapped with rubber tissue or cellophane. In-

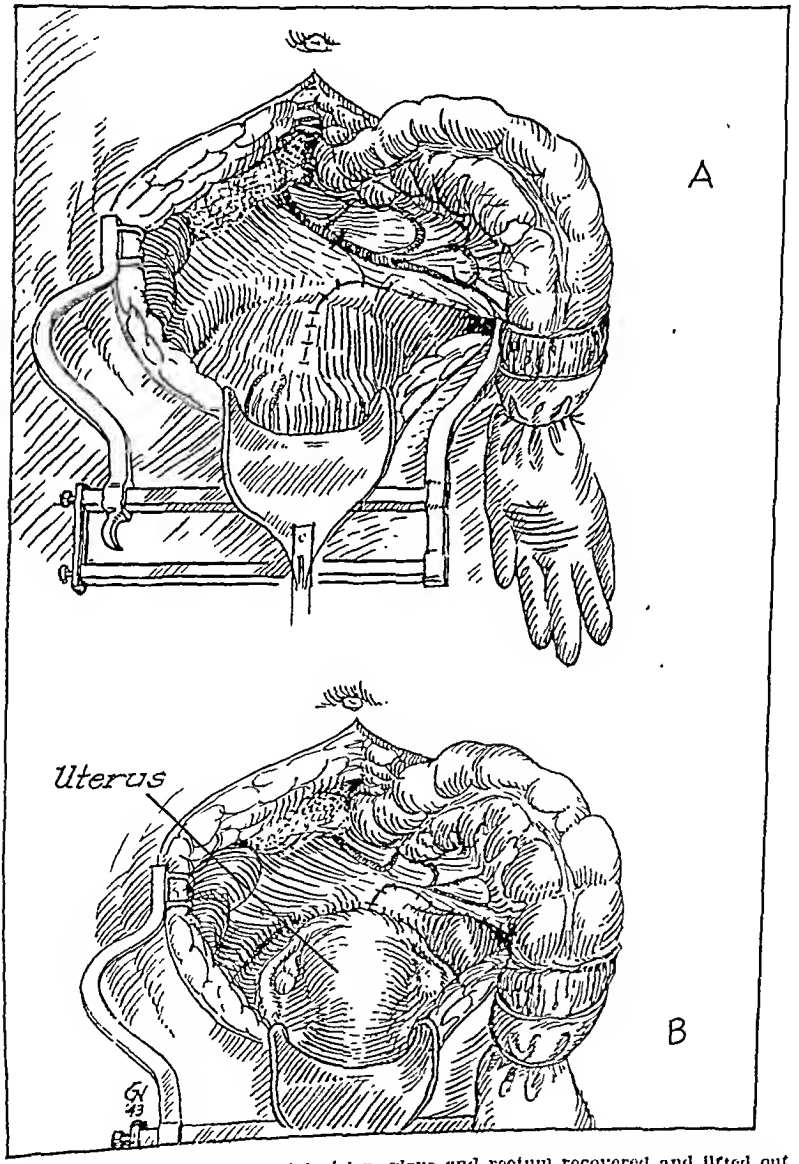

Fig. 6.—(*A*) Midline abdominal incision, glove and rectum recovered and lifted out of abdomen. Inferior hemorrhoid artery ligated and sigmoid flexure freed with gland-bearing tissue. The pelvic peritoneum suture is finished from within the abdomen. (*B*) In women the uterus is tacked back over the line of peritoneal suture.

terrupted stitches close the perineal wound, leaving the drain protruding through the center of the wound. The perineal part of the operation is finished. Dressings are applied. The patient is then placed straight upon the table in the Trendelenburg position and prepared for laparotomy.

After a change of gowns, gloves, and operative tray, a midline incision is made, the small intestines packed out of the way, and a Balfour

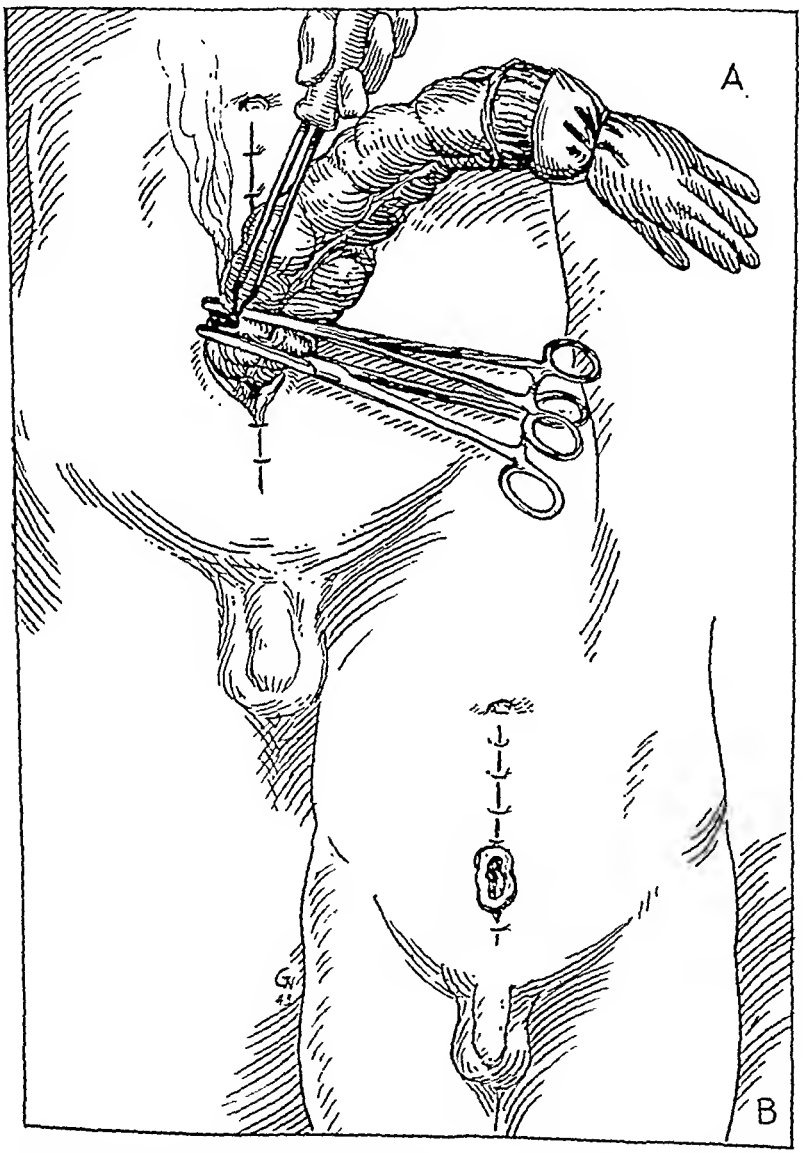

Fig. 7.—(A) Abdominal wound is closed about the colon in the middle of the midline incision. Crushing clamps are applied and the bowel is burned across with electric cautery; proximal clamp left on. (B) Midline colostomy.

needle. The peritoneum is brought together for a short distance and then the needle and suture is wrapped securely around a piece of gauze and pushed into the abdominal cavity. Hemostasis has been controlled as the operation proceeded. The hollow of the sacrum and perineal space from which the rectum has been removed is filled with a large pack of iodoform gauze wrapped with rubber tissue or cellophane. In-

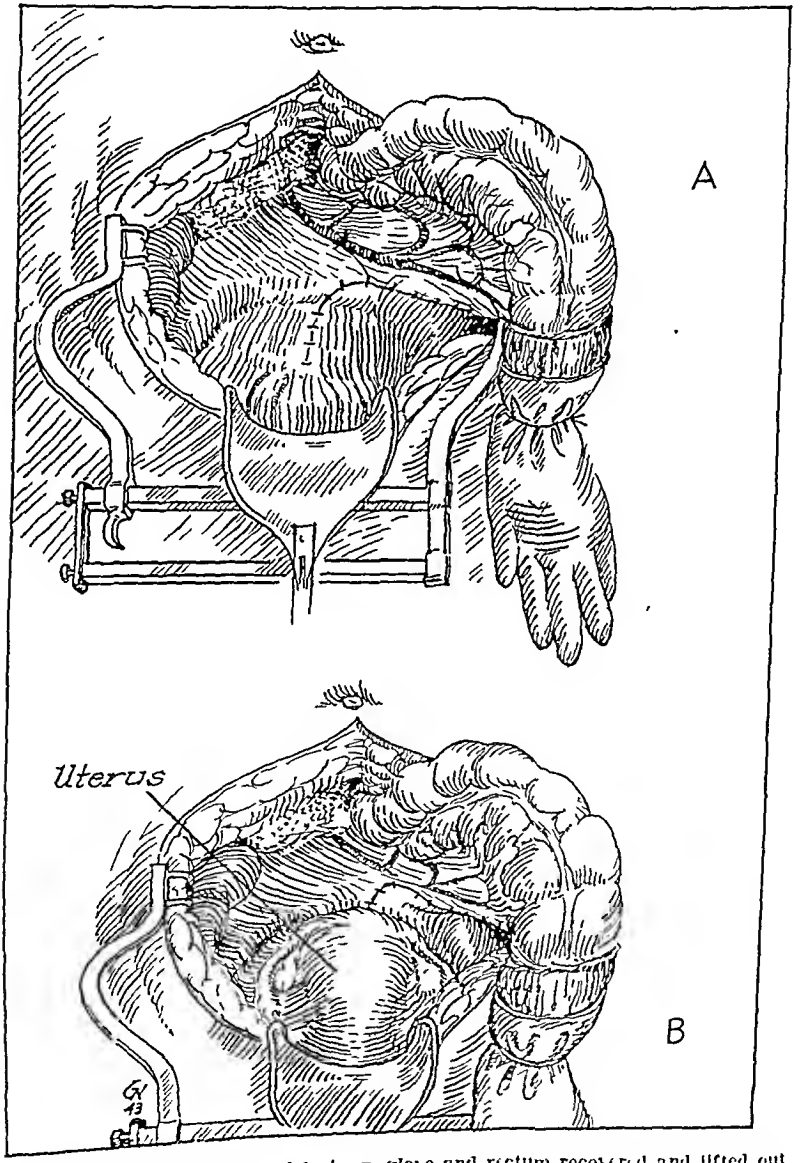

Fig. 6.—(A) Midline abdominal incision, glove and rectum recovered and lifted out of abdomen. Inferior hemorrhoid artery ligated and sigmoid flexure freed with gland-bearing tissue. The pelvic peritoneum suture is finished from within the abdomen. (B) In women the uterus is tacked back over the line of peritoneal suture.

soiling is not present and has not happened in our experience in a single case.

3. If gastric suction is used postoperatively until peristalsis is restored (three to four days), the danger of annoyance from ileus is completely eliminated. Also, the gaseous distention which ordinarily may occur and endanger the abdominal wound and the sutured pelvic peritoneal floor is prevented. Routine gastric suction has eliminated completely the above complications.

ADVANTAGES OF THE OPERATION OVER THE ABDOMINOPERINEAL PROCEDURE

1. It is technically much easier and more rapid of performance. The operation is largely completed before the abdomen is opened. This naturally means a short time in the abdomen with little handling of the intestines, which naturally results in less shock and a more rapid recovery.

2. The chances for infection are greatly reduced because the bowel is not opened until the operation is completed. We have not seen evidence of peritonitis or infection in the wounds of any patient.

3. The surgeon who is not doing a great many resections of the rectum will become more expert with the knowledge gained by a repetition of the same procedure. It is true that the surgeon should have at his command and be able to perform any of the procedures which are usually considered necessary for operations for cancer of the rectum, but we should remember that the operation will be done by many general surgeons who do not have the advantage of a long and extensive experience with rectal excision.

abdominal retractor inserted. The glove-covered rectum is now recovered and brought out of the abdomen (Fig. 6, *A*). The complete liberation of the rectum and sigmoid is completed well on to the sigmoid flexure, with ligation of the superior hemorrhoidal vessels. Then the previously started suturing of the peritoneum is completed. In women the uterus (Fig. 6, *B*) is sutured back over the peritoneal suture line. Since the accident previously mentioned, in which a loop of bowel herniated through this suture line, this precaution has been taken and we think it is worth while.

The colostomy may be made in the left side through a muscle-splitting incision, or it may be left in the center of the midline incision as advocated by Jones and others. At the present time we are inclined to believe that the midline colostomy is less likely to result in hernia. The colon is placed in the proper position for the permanent colostomy, and the abdominal incision is closed about it (Fig. 7, A). When the wound closure is completed, the bowel is doubly clamped distal to the skin and burned across with the electric cautery. Thus the bowel has not been entered at any time until the operation is completed, and then outside of the abdomen. Should a colostomy of the left side be desired, one clamp may be passed through the wound on the left side, and after careful protection with moist gauze the bowel is burned across and the clamp on the proximal end brought out through the side wound. The midline colostomy procedure naturally is less hazardous from the standpoint of infection. The clamp which is on the colon may be left on for thirty-six to forty-eight hours if the intestine is kept free of gas by gastric suction.

We are convinced that the operation is as complete as the Miles procedure.

CRITICISMS OF THE OPERATION

1. An opportunity is not afforded for examination of the liver and lymph glands for metastasis before operation is completed.

2. The cleansing of the colon before operation is difficult without a previous colostomy.

3. Troublesome ileus may occur following the operation because the colostomy has not developed proper function with a previous colostomy before the removal of a large amount of bowel.

DEFENSE OF CRITICISMS

1. In answer to the first of these criticisms it should be said that liver metastasis is not contraindicated to resection of the rectum since the patient will live longer and be more comfortable after resection, even though metastasis has occurred in the liver.

2. The perfectly dry and empty bowel is an advantage but with this procedure the bowel is not opened until the operation is finished and with ordinary care the danger of accidentally opening the bowel and

surgery. The diagnostic aspects of the condition are not emphasized. Much has been written about this aspect and on the prognosis, and an excellent article with a careful analysis of these points has recently been published by Rogers and Faxon.[1]

The 149 patients constitute a cross section of the population of the metropolitan area. They ranged in age from 5 months to 76 years, and were distributed throughout the decades as indicated in Table I.

TABLE I

DECADE	NUMBER OF CASES	DEATHS
1	23	1
2	22	1
3	33	1
4	23	1
5	19	1
6	16	1
7	10	1
8	3	0

There were seven deaths in the series, a postoperative mortality of 4.7 per cent. The causes of death were varied. Two patients died of generalized peritonitis; in one the peritonitis was present at the time of operation, in addition to the abscess, in the other there was probably a postoperative spread of the infection. Two patients died of massive pulmonary embolus seven and eight days, respectively, after operation. Two others developed mechanical intestinal obstruction and died, both after having had jejunostomies as secondary operations. There was one death from bronchopneumonia.

An analysis of these seven fatalities yields the impression that two might have been avoided had different treatment been carried out. In one of the two cases of generalized peritonitis the patient was subjected to appendectomy, despite the fact that the position and condition of the appendix made its removal difficult and time-consuming, and undoubtedly resulted in spread of the infection. It would probably have been wiser had the surgeon been content with simple drainage of the abscess. The patient with pneumonia probably would have had a better chance of survival had the sulfonamide drugs been available at the time.

It is the general policy in this clinic to subject the patient to operation as soon as the diagnosis of appendical abscess is made. Thus, the great majority of patients in this series were operated upon within six hours of their admission.

If the appendical abscess was complicated by other coexistent conditions such as diabetes, cardiac disease, or fluid imbalance, operation was delayed sufficiently long to allow such conditions to be controlled. In a few cases in which the diagnosis was obscure, several days elapsed while diagnostic studies were carried out.

APPENDICAL ABSCESS

ARTHUR I. CHENOWETH, M.D., NEW YORK, N. Y.
(From the Department of Surgery of the New York Hospital and Cornell University Medical College)

IT IS generally recognized that, conditions being favorable, the best form of operative treatment for appendical abscess is appendectomy with drainage. It is likewise well known that at times circumstances make removal of the appendix inadvisable if not impossible, and in such cases simple drainage of the abscess is employed. The decision as to whether to remove the appendix or to be content with simple drainage of the abscess must be left to the judgment of the individual surgeon. In this decision he is guided by the general condition of the patient before and during operation and by the relative ease with which the appendectomy may be accomplished. An additional factor of much importance is the subsequent course of the patient as influenced by the type of procedure performed. It is in an attempt to clarify this ultimate prognosis that the present study is undertaken.

A review has been made of all cases of appendical abscess treated at the New York Hospital over the period of ten years, from 1932 to 1942. The cases have been selected on the basis of the condition found at operation. The criteria on which the diagnosis was based were the following: (a) a localized suppurative process was found, (b) a positive culture was obtained from the pus, and (c) a perforated appendix was identified as the origin of the peritoneal infection. In a few cases the appendix itself could not be seen or felt, but in these there was sufficient evidence, on the basis of the location of the abscess and the subsequent course of the patient, to point to the appendix as the offending organ.

According to these criteria no cases were included in the series which had early perforation without evidence of a walling-off process, no case of generalized peritonitis, or of acute gangrenous appendicitis with cloudy peritoneal fluid, culture of which yielded no bacterial growth. It is felt that the pathologic condition found at operation provides a more reliable basis for the diagnosis of appendical abscess than do the preoperative findings alone. In this series of cases, for instance, there are many patients in whom there was no palpable mass either at the time of the initial examination or after induction of anesthesia.

As judged by these standards, 149 cases were selected out of a total of about 3,600 appendectomies. They were studied chiefly from the viewpoint of operative treatment and immediate and late results of

Received for publication, May 17, 1943.

mortality rate in the second group is likely to be misleading unless it is understood that, in general, the patients selected for simple drainage were those who were in the poorest condition before operation.

COMPLICATIONS

Excluding the fatal complications described above, there were forty-five complications in thirty-nine patients. The discrepancy of figures is due to the fact that six patients each had two complicating conditions. Grouped according to the type of operation there were thirty-one complications following appendectomy and fourteen after simple drainage (see Table III). The larger number of fecal fistulas in the second group of cases would be expected, since in them no attempt was made to close the opening in the bowel. All except two fistulas closed spontaneously before the patient was discharged from the hospital. One of these required closure after five months, at which time the appendix was removed; the other persisted intermittently for two years after operation, at which time the patient died of pyelonephritis. If the complication of fecal fistula is excluded, the numbers of complications are reduced to twenty-eight in the first group and six in the second. Thus, it becomes apparent that the morbidity is strikingly less following incision and drainage than after appendectomy with drainage.

TABLE III

POSTOPERATIVE COMPLICATIONS

COMPLICATION	OPERATIVE PROCEDURE	
	APPENDECTOMY WITH DRAINAGE	INCISION AND DRAINAGE
Pelvic abscess	9	0
Fecal fistula	3	8
Pulmonary infarct	5	0
Bronchopneumonia	6	0
Intestinal obstruction	1	0
Peritonitis	2	0
Parotitis	2	0
Empyema	1	0
Renal infarct	1	0
Wound abscess	1	4
Pyelonephritis	0	1
Jaundice with fever*	0	1

*Attributable to sulfanilamide.

It is to be noted that postoperative (incisional) hernias are arbitrarily omitted as postoperative complications. Although, undoubtedly, hernias are technically caused by the operative procedure, it is considered logical, from the practical standpoint, to list them separately, since in no case did they influence the early postoperative course. There were twenty-two such hernias in this series, an incidence of 15 per cent. The fact is of interest that of these only six followed appendectomy with drainage, while sixteen occurred after simple incision and drainage. All hernias were at the site of the McBurney incision.

The incision of choice was the McBurney (or gridiron) type and it was used in all cases save a few in which failure to arrive at a definite diagnosis before operation warranted exploration through a paramedian incision.

General anesthesia (ether, nitrous oxide and ether, or cyclopropane) was used in the majority of cases, although spinal or local was used in a few.

Once the abdomen was opened, the type of procedure was dictated by two factors: (1) relative ease with which the appendix could be removed, and (2) the general condition of the patient before and during operation. The procedure of choice was appendectomy with drainage. However, if it was judged that removal of the appendix would be difficult and would necessitate much manipulation and trauma with the danger of the spread of infection, the surgeon in most cases simply evacuated the pus and inserted drains. By the same token, if the condition of the patient was very poor, so that prolonged anesthesia and manipulation would have been hazardous, simple drainage was performed.

According to these indications appendectomy was carried out in eighty-nine patients (60 per cent) of the series and simple drainage in sixty (40 per cent).

In the group of patients treated by appendectomy and drainage there were three deaths, a mortality rate of 3.4 per cent. One patient died of generalized peritonitis with paralytic ileus, one of mechanical obstruction due to volvulus of a loop of ileum without gangrene, and the third of massive pulmonary embolus (see Table II).

TABLE II

POSTOPERATIVE DEATHS

HOSPITAL NUMBER	AGE IN YEARS	DURATION OF SYMPTOMS (DAYS)	OPERATIVE PROCEDURE	CAUSE OF DEATH
76805	13	3	Appendectomy with drainage	Mechanical obstruction
258728	30	4	Appendectomy with drainage	Peritonitis and ileus
288225	63	2	Appendectomy with drainage	Embolus
67195	2	10	Incision and drainage	Peritonitis and ileus
80770	52	5	Incision and drainage	Mechanical obstruction
164354	32	10	Incision and drainage	Pneumonia
301476	43	10	Incision and drainage	Embolus

Four of the sixty patients treated by drainage alone died, a mortality rate of 6.6 per cent. The causes of death were strikingly parallel to those in the former group. Peritonitis, demonstrated at autopsy to have been present at the time of drainage of the abscess, mechanical obstruction, and embolus again were the conditions leading to death. In addition, one patient died of pneumonia. The relatively higher

is impossible to predict, according to age, which patients are likely to develop recurrence. Elective appendectomy should, therefore, be performed in all patients whose condition does not contraindicate this procedure.

It is not possible to establish an arbitrary limit of time within which elective appendectomy should be performed. However, it is advisable to remove the appendix as soon as possible after recovery from the original procedure. A two or three months' interval is adequate time to allow for resolution of the inflammatory process in the peritoneal cavity. Therefore, the optimal time for elective appendectomy is three months after the incision and drainage.

USE OF SULFA DRUGS

Of the 149 cases in this series, only 26 were treated by the oral or parenteral administration of the sulfonamides, sulfanilamide having been given to 11 and sulfadiazine to 15 patients. In this group there were two deaths, a mortality rate of 7.7 per cent. The group obviously is too small to allow for fair evaluation of this adjunct of operative treatment.

SUMMARY

1. A series of 149 consecutive cases of appendical abscess is reviewed.

2. Of the total 149 cases, 60 per cent of the patients were subjected to appendectomy with drainage, 40 per cent to incision and drainage alone. There was a general mortality of 4.7 per cent.

3. Of the patients whose appendices were not removed either at the time of drainage of the abscess or at a secondary elective operation, ten, or 40 per cent, developed a recurrent abscess.

4. The number of patients given sulfonamide drugs is too small to allow a fair evaluation of their effect.

REFERENCE

1. Rogers, Horatio, and Faxon, Henry H.: A Statistical Study of 671 Cases of Appendiceal Peritonitis, New England J. Med. 226: 707, 1942.

SUBSEQUENT COURSE OF PATIENTS SUBJECTED TO INCISION AND DRAINAGE WITHOUT APPENDECTOMY

A study of the subsequent course of the patients in whom the appendix was not removed at the time the abscess was drained is of interest.

Twenty-eight of the patients were subjected to elective appendectomy at intervals varying from two months to four years after the original operation. There were no deaths in this group.

Ten patients were readmitted with a recurrence of acute appendicitis at the time intervals following the primary procedure shown in Table IV. All of these, save one who had simple acute appendicitis, were found to have perforation and recurrent abscess requiring operation. Two of the patients had two recurrent abscesses. Again there were no deaths.

TABLE IV

RECURRENCE AFTER SIMPLE DRAINAGE

AGE IN YEARS	INTERVAL AFTER ORIGINAL OPERATION	CONDITION FOUND AT SECONDARY OPERATION
12	1½ mo. and 1 mo.	Appendical abscess
57	4 mo.	Appendical abscess
35	5 mo.	Appendical abscess
22	6 mo.	Appendical abscess
63	7 mo.	Appendical abscess
55	7 mo.	Appendical abscess
50	11 mo.	Appendical abscess
56	11 mo.	Acute appendicitis
9	18 mo.	Appendical abscess
4	6 yr.	Appendical abscess

A third group of patients, fifteen in number, have not had the appendix removed at operation, either because the patient refused to enter for appendectomy or because appendectomy was thought to be contraindicated by age or associated condition. The time that has elapsed since incision and drainage varies among these fifteen patients from eight months to seven years. None of them has had symptoms suggestive of appendicitis. One other patient, who had a persistent fecal fistula, died of pyelonephritis and diabetes two years after incision and drainage. Two patients have been lost to the follow-up clinic.

According to these figures, twenty-five patients who had simple drainage of an appendical abscess and have not had elective appendectomy are known to be living. Of these twenty-five, ten (40 per cent.) have had recurrence of their disease requiring operation under unfavorable circumstances with added hazards.

It is of note that in this group of ten patients the recurrence in eight cases developed within the first year after incision and drainage. The ages of the patients having recurrences varied widely, four of them being 25 years of age or younger, and five being 50 or older. Two [illegible]

stools. This triad was found in 39 or less than one-half of the 86 cases for which an adequate history was recorded.

There was a manifestation of abdominal pain in 73.3 per cent of the cases. Ladd and Gross describe the recurrent colicky abdominal pain as an almost universal complaint. The onset is usually sudden. The pain is of an intermittent and colicky nature, coming on in paroxysms every ten to thirty minutes and lasting only several seconds. Between the paroxysms the child may be content and apparently comfortable.

Vomiting usually appears early and in many small infants was the first sign of illness. Vomiting was recorded in 89.5 per cent of the records and was noted in 21 cases when no manifestation of pain had been recognized. Gordon elicited this complaint in all infants and in 90 per cent of children and adults with intussusception.

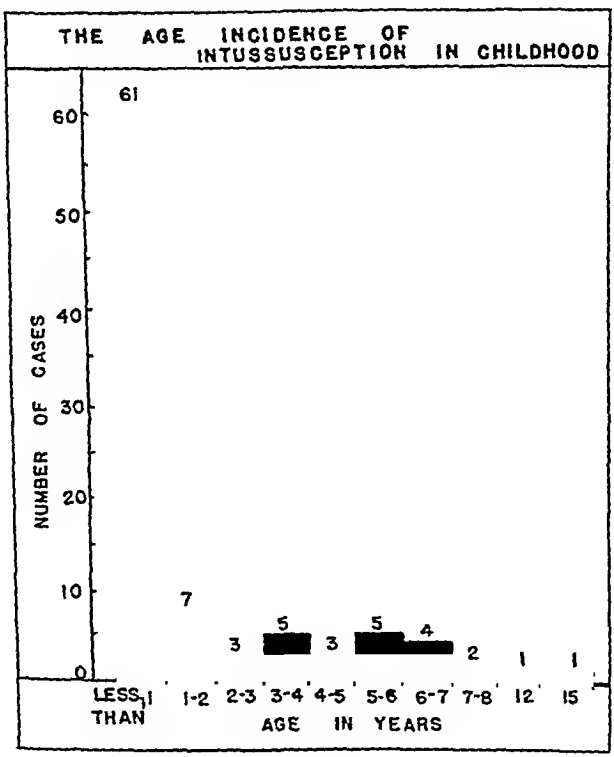

Fig. 1.

A history of blood in the stool, hematochezia, was noted in only 70.9 per cent of the cases. However, blood was noted on the examiner's finger after rectal examination in 6 additional cases. The history may be one of gross hemorrhage or only of bright red staining on the diaper. Ladd and Gross anticipate the passage of bloody stools by about 85 per cent of the patients, but warn that this symptom may be absent if the

INTUSSUSCEPTION—NINETY-TWO CASES IN INFANCY AND CHILDHOOD

EDWARD W. GIBBS, M.D., AND PAUL W. SUTTON, M.D., CINCINNATI, OHIO
(From the Department of Surgery of the College of Medicine of the University of Cincinnati, the Cincinnati General Hospital and the Children's Hospital, Cincinnati)

ACUTE intestinal intussusception is one of the most important surgical emergencies in the early years of life. An admirable discussion of the subject has been presented by Ladd and Gross in their recent text. Their remarkable improvement in mortality for this frequently fatal disease stimulates a review of additional cases from other clinics and hospitals in an effort to achieve a universal reduction in mortality.

The cases have been reviewed from two institutions which are affiliated with the University of Cincinnati and are supplied by the same rotating surgical house staff, the Children's Hospital of Cincinnati and the Cincinnati General Hospital. The records of the former include both private and ward patients under 15 years of age. Those of the latter represent only ward patients in the same age group.

The review covers a sixteen-year period from Jan. 1, 1927, to Dec. 31, 1942. During this time 59 patients with 60 intussusceptions were operated upon in the Children's Hospital and 31 patients with 32 intussusceptions were operated upon in the General Hospital, an average of 6 cases per year for the two institutions.

AGE, SEX, AND RACE INCIDENCE

Intussusception is primarily a disease of infants in the first year of life. Of the patients in this study, 62.5 per cent were between 2 and 11 months of age. The peak of the age incidence was at 5 months. The youngest child was 1 month and 28 days of age, the oldest was 15 years. All but 2 were less than 8 years old. The age incidence by months and by years is essentially comparable to that reported by others.[2, 9, 10, 12]

The sex incidence also is in accord with that found by other reporters.[3, 4, 7, 9, 10, 13] Sixty-two per cent of the patients were boys and 38 per cent were girls.

At the Children's Hospital all but 2 patients were white. At the General Hospital there were 17 white and 15 Negro.

SYMPTOMATOLOGY

The often emphasized cardinal symptoms of intussusception are: intermittent colicky abdominal pain, vomiting, and the passage of bloody

Received for publication, May 22, 1943.

shaped. Kahle wonders whether the mass is typically sausage shaped or whether this is a convenient term which has passed down from one generation of physicians to the next. The mass may vary in size from that of a walnut to that of an orange, depending upon the age of the patient. The mass was described in all quadrants of the abdomen but was most frequently found in the right upper quadrant. It was observed sometimes to become tense during a paroxysm of pain.

Rectal examination was recorded in only 68 cases and a mass was felt in only 28, or 41.2 per cent, of these. However, the importance of rectal examination must be emphasized. In 16 cases a mass was felt by rectal examination when none could be felt by abdominal palpation. This is likely to be true particularly when the abdomen has become distended. Furthermore, as was already mentioned, blood may be found on rectal examination when there is no history of bloody stools.

This series of cases is too small to evaluate the significance of fever. In 39 cases the rectal temperature on admission was less than 100° F. In 31 cases it was between 100 and 102° F. and in 14 cases it was more than 102° F.

LABORATORY STUDIES

The white blood cell count on admission was less than 10,000 in 16 cases, between 10,000 and 20,000 in 31 cases, and more than 20,000 in 8 cases. Other laboratory studies were not recorded in sufficient number to warrant their discussion.

ROENTGENOLOGIC FINDINGS

Roentgenologic studies were made in only 34 of the cases. In 29 of these only a simple film of the abdomen was made. Gas accumulation was described in 21 cases and 8 were reported as negative. Fluoroscopic examination with a barium enema was used in only 5 cases. Typical findings were reported and the diagnosis strengthened in 4 cases. The fifth case was a lesion of the ileo-ileal type in which the intussusceptum had not progressed as far as the cecum. This patient presented such characteristic symptoms and signs that operation was done in spite of the negative x-ray findings.

TREATMENT PRIOR TO ADMISSION

A history of home treatment by catharsis was obtained in 18 cases and by enemas in 22 cases. However, a definite relation to mortality rate, as can be so well shown in acute appendicitis was not demonstrable.

CONSERVATIVE TREATMENT

It has been our opinion that every case of intussusception is a surgical emergency and the patient should be operated upon as soon as the diagnosis is made. We have had no experience with nonoperative methods of reduction. However, one cannot blind himself to the excellent results obtained by Hipsley with preliminary injections of saline solution

patient is seen in the first twelve to fourteen hours of illness. In other reviews, hematochezia has been described in from 70 to 100 per cent of the cases.[2, 10, 13]

The absence of hematochezia is not necessarily a good prognostic sign, for of 19 patients without blood in the stool, 8 died. Of 67 with blood in the stool, only 17 died.

Although the classical triad of symptoms was reported in less than one-half of the cases, two of the three cardinal symptoms were noted in more than 90 per cent.

The average duration of symptoms at the time of admission to the hospital was 41.3 hours, at the time of operation 47.5 hours. The average delay between admission and operation was thus 6.2 hours. The relation of these factors to mortality will be discussed later.

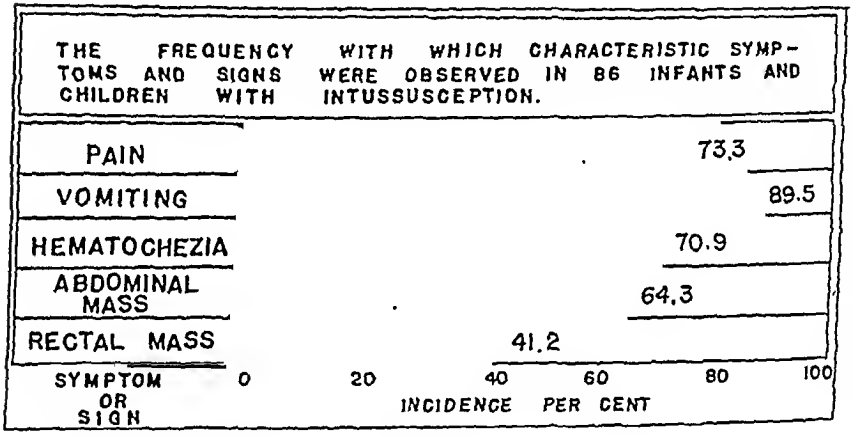

Fig. 2.

PHYSICAL FINDINGS

It is well known that intussusception is apt particularly to occur in well-nourished, healthy infants and children. This was found to be true in the majority of instances. Early in the illness the child may not appear to be very ill, especially if seen between the paroxysmal attacks. However, if intestinal obstruction remains present for many hours the child becomes obviously ill.

Five patients not included in this report were admitted to the Children's Hospital in a moribund condition too sick for operation. All died in less than three hours after admission. Three of these patients had had symptoms for only twenty-four hours, one for three days, and one for seven days.

The so-called cardinal finding on physical examination is a palpable abdominal mass. This was recorded in only 64.3 per cent of the cases. Other reporters describe a mass in from 50 to 85 per cent of the cases.[2, 10, 12, 13] It is usually described as firm and frequently as sausage

mediately, but perforation during reduction is a grave and sometimes fatal technical error, even though it is recognized and repaired.

Once reduced, the bowel may appear very dusky or angry red due to edema and hemorrhage. A few moments spent in observation after the application of warm saline pads will give evidence of viability by improvement in color and return of peristalsis.

The following operative procedures were used in the patients studied. Reduction was accomplished and was all that was done in 25 cases with a mortality rate of 40.0 per cent. In 16 other cases, in addition to reduction, some attempt was made to fix the bowel and prevent recurrence. This was done either by suturing the ileum to the cecum, or by suturing the ileum, cecum, or ascending colon to the parietal peritoneum. The mortality in this group was 25.0 per cent. In 32 cases appendectomy was done with an associated mortality of 3.1 per cent. Obviously, one cannot conclude that the mortality rate is lower with than without appendectomy. Appendectomy is more apt to be done when the lesion is mild or readily reduced and when the patient's condition is not critical. In severe cases it is done only when the appendix exhibits definite irreversible impairment of blood supply. Reduction and Meckel's diverticulectomy were done in 2 cases with one death. One fatality followed closure of a perforation made during reduction. In one case a lymph node, thought to be the cause of the intussusception, was removed without complications.

Resection and primary anastomosis was done in 7 cases with a mortality of 42.9 per cent. Five of these patients had end-to-end anastomosis, one had a side-to-side anastomosis, and in the other case the type of anastomosis was not specified. The ages of the patients who survived were 10, 10, 31, and 39 months. Those who died were 7, 30, and 33 months of age.

Resection was accomplished by a Mickuliez type of procedure or double enterostomy in 5 patients, the ages of which were 4, 5, 9, 16, and 60 months. All of these patients died.

In 2 patients, 5 months and 15 years of age, resection was done, the end of the distal bowel closed, and a proximal ileostomy made. Both patients died.

In one patient, 7½ years of age, an ileosigmoidostomy was made around the irreducible mass by side-to-side anastomosis leaving the mass in situ. This patient also died.

Thus, there were 77 cases in which reduction was accomplished without major bowel resection, with 17 deaths, a mortality rate of 22.1 per cent; and 14 cases in which some form of major resection was necessary, with 10 deaths, a mortality of 71.5 per cent. In the latter group the results with resection and primary anastomosis were better than with the establishment of an enterostomy.

per rectum prior to operation. Certainly, to apply gentle pressure on the apex of the intussusceptum from within the bowel is a rational method of attempting reduction. The chief objection to hydrostatic reduction is that the operator is uncertain whether or not reduction has been accomplished. After many years of experience Hipsley has found certain signs of reduction fairly accurate.[5] However, if there is any doubt, reduction is verified by operation, frequently through a McBurney incision. If reduction is not accomplished easily the hydrostatic method is abandoned and operation undertaken.

Most surgeons, particularly in the United States, condemn any method of reduction other than operative. Jones adopts a more liberal attitude and concedes that one should not disregard the value of an attempt at reduction with hydrostatic pressure, especially in early cases, but warns that this method may be unwise when the condition has been present for twenty-four hours.

PREOPERATIVE TREATMENT

If the child is dehydrated, toxic or acidotic, fluid and electrolyte balance are restored rapidly by the administration of intravenous or subcutaneous fluids. These and blood or plasma transfusions may be continued during operation if the child's condition warrants. Atropine or scopolamine is given by hypodermic injection in proper preanesthetic dosage.

ANESTHESIA

Open drop ether is preferred to local anesthesia unless it is specifically contraindicated. Not only does local anesthesia afford poorer relaxation and greater technical difficulty but it also renders the operation more shocking to these frequently tiny patients. Ether anesthesia is also preferred by Ladd and Gross, Mayo and Woodruff, Wyatt, and Miller and Workman. All but 7 patients in this series were operated upon under ether anesthesia.

OPERATIVE TREATMENT

All of the patients in this review were operated upon. A right rectus incision was used in 80 cases. A left rectus, a midline, and a McBurney incision were used in 3 cases. In 3 cases the type of incision was not recorded. Ladd and Gross have found the most difficult part of the operative procedure to be generally in the reduction of the last portion of the lesion in the region of the cecum. Hence, an incision which affords a good exposure of this area is preferable to one made over the palpable mass.

Reduction of the intussusception is performed by gentle pressure backward along the intussuscipiens attempting to squeeze out the intussusceptum. Traction should be used only with great care. Small tears in the serosa are not particularly serious and should be repaired im-

the General Hospital with 2 deaths, a mortality of 14.3 per cent. The combined mortality for both institutions during this period was 8.3 per cent.

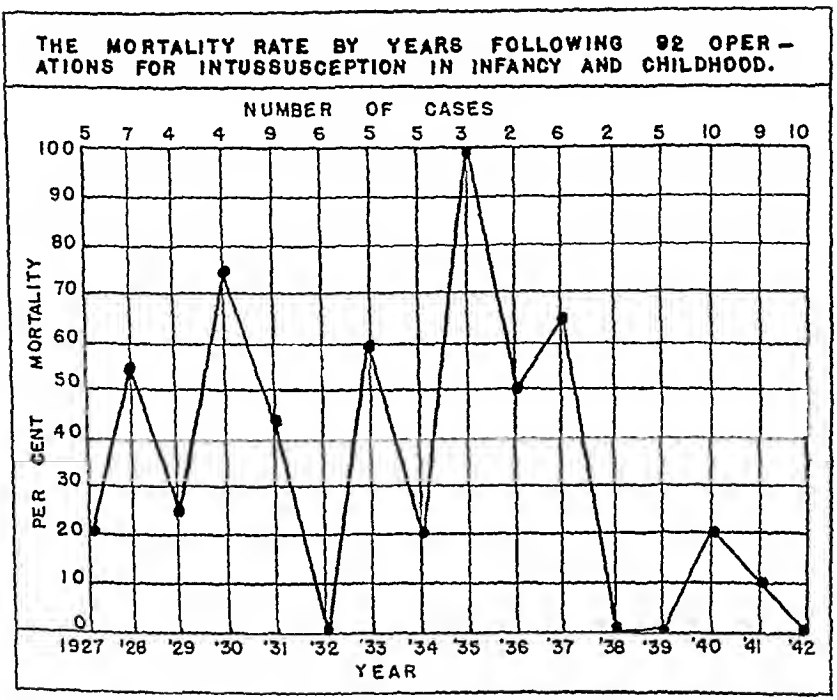

Fig. 3.

Similar improvement in recent years has been obtained by others. Gordon reported 16 consecutive cases with a 6.25 per cent mortality. Ladd and Gross reported a mortality of 14.0 per cent in 90 cases and in their text report 12 consecutive cases without a death.

FACTORS AFFECTING MORTALITY RATE

The three most important factors in the lower mortality figures for the last five-year period are probably: (1) earlier hospitalization and fewer cases of delayed operation, (2) fewer bowel resections, and (3) improved pre- and postoperative care.

This report again indicates the dangers of delayed operation for intussusception. Only 19 per cent of the patients in the last five-year period had allowed symptoms to progress for more than 48 hours before coming to operation, while 44 per cent of those seen in earlier years were operated upon after the second day of illness. Not only was the average duration of symptoms on admission less in the recent group (35.8 hours as compared with 45.3 hours for the earlier cases) but there was also less delay between admission and operation (3.9 hours as compared with 7.8 hours).

Most reporters are agreed that bowel resection should never be done unless absolutely necessary. The mortality of resection in infants is estimated at from 70 to 100 per cent.[3, 9, 14, 15] However, what type of resection should be done when it is necessary is still unsettled and our figures are too small to shed much light on the discussion. Ladd and Gross found that the proportion of successful resections, even in a collective review of the literature, is inadequate to determine whether primary anastomosis or double enterostomy is the procedure of choice. They found that the successful resections were treated, in the majority of instances, by primary anastomosis of the intestine but their own records tend to show that the Mikulicz procedure gives a little better chance of recovery.

In our opinion, the procedure to be used must be chosen for the individual case. The operator must make every effort to reduce the lesion, even though it may require one-half hour, rather than to resort to unnecessary resection. On the other hand, valuable time must not be wasted in attempting to reduce an irreducible or gangrenous lesion. If resection is necessary and the patient's condition will permit, primary anastomosis is preferred. On the other hand, the Mikulicz procedure can be more rapidly executed and its use, when the patient's condition is critical, may mean the difference between a live child with an enterostomy and a dead one with an anastomosis. However, infants and young children do not tolerate well the subsequent loss of succus entericus and every effort must be made to maintain fluid, protein, and electrolyte balance. Restoration of bowel continuity should be established as soon as feasible.

Woodhall reported two successful resections in which he made a lateral anastomosis around the lesion at the same time he did the Mikulicz procedure. In this manner continuity of the bowel was re-established immediately. We have had no experience with this procedure.

MORTALITY RATE

At the Children's Hospital 60 operations were followed by 18 deaths, a mortality of 30.0 per cent. At the General Hospital 32 operations were associated with 10 deaths, a mortality of 31.3 per cent. The average mortality for the entire series from both institutions for the sixteen-year period was 30.4 per cent.

Kahle reports a mortality rate of 52.5 per cent in infants and children. Mayo and Woodruff reported a mortality of 23.6 per cent, Gordon of 22.7 per cent, Wakely and Atkinson of 10.0 per cent. Grigsby and Kaplan of 22.0 per cent, Hipsley of 4.9 per cent, and Ladd and Gross of 31.2 per cent.

There has been a conspicuous improvement in mortality among the cases herein reported during the last five years. Since 1937, 22 patients have been operated upon at the Children's Hospital with one death, a mortality of 4.5 per cent; and 14 have been operated upon at

COMPLICATIONS

Twenty-three of the 28 deaths occurred during the first twenty-four postoperative hours and we have come to believe that if a patient survives the first twenty-four hours after operation he is apt to recover. These early deaths are generally attributed to shock and toxemia.

Complications included 14 cases of diarrhea, 8 upper respiratory infections, 8 cases of otitis media, 5 cases of pneumonia, 3 wound infections, 3 eviscerations, 2 cases of pulmonary edema, 2 cases of postoperative obstruction requiring operative release of adhesions, 2 cases of acute bronchitis, and 1 each of insulin shock, chicken pox, scarlet fever, intraenteric hemorrhage, atelectasis, fecal fistula, and intestinal obstruction of unknown cause thought to be the result of a recurrence with subsequent spontaneous resection.

Recurrence of the lesion was confirmed in 3 cases. Two of these patients were operated upon a second time, ten months and one year, respectively, after their first operation. A third patient died 5 hours after operation and was found to have a recurrent ileo-colic lesion which had extended around to the splenic flexure after being reduced from the sigmoid area at operation. This is believed to be the earliest recurrence to be reported.

TABLE III

THE TYPES OF LESION ENCOUNTERED IN 92 CASES OF INTUSSUSCEPTION AND THEIR RELATIVE MORTALITY RATES

TYPE OF INTUSSUSCEPTION	NO. OF CASES	DEATHS	PER CENT MORTALITY
Ileo-ileal	8	5	62.5
Ileo-ileo-colic	9	4	44.4
Ileo-colic	67	17	25.4
Colo-colic	8	2	25.0
Total	92	28	30.4

CONCLUSIONS

1. Ninety-two cases of intussusception with the patients operated upon in infancy and childhood have been reviewed from the Children's Hospital of Cincinnati and the Cincinnati General Hospital.

2. The classical symptom complex was described in less than one-half of the cases.

3. Of every 10 cases, pain was described in 7, vomiting in 9, and hematochezia in 7. At least two of these symptoms were noted in nearly all of the cases.

4. Of every 10 cases, a palpable abdominal mass was described in 6 and a rectal mass in 4.

5. The methods of treatment are described and the results of different methods compared.

6. Factors which have effected a recent reduction in mortality rate are discussed.

TABLE I

THE OPERATIVE PROCEDURES USED AND THE ASSOCIATED MORTALITY RATES IN 92 CASES OF INTUSSUSCEPTION

OPERATIVE PROCEDURE	NO. OF CASES	DEATHS	PER CENT MORTALITY
Reduction	77	17	22.1
Reduction only	25	10	40.0
Fixation	16	4	25.0
Appendectomy	32	1	3.1
Diverticulectomy	2	1	50.0
Closure of perforation	1	1	100.0
Removal of lymph node	1	0	0.0
Resection	14	10	71.5
Primary anastomosis	7	3	42.9
Double enterostomy	5	5	100.0
Single enterostomy	2	2	100.0
Anastomosis around mass	1	1	100.0
Total	92	28	30.4

Recently there have been more successful reductions and fewer bowel resections. Only 11 per cent of the cases seen in the last five years have required resection. This figure was 18 per cent in the earlier group.

Shock, toxemia, and dehydration are recognized as the most important complications and the most frequent cause of death in cases of intussusception. Although we cannot show it statistically, there is little doubt that improved preoperative care and postoperative care have contributed materially to the recent reduction in mortality. Both hospitals now receive the benefit of close cooperation between the surgical and pediatric services. Recently, the facilities of a fully equipped blood bank have made the more frequent use of whole blood and plasma transfusions easy. Care in re-establishing fluid and electrolyte balance before operation and maintaining it during and after operation with intravenous and subcutaneous administration of fluids, and the more frequent use of oxygen therapy have all contributed to the improved results.

TABLE II

THE RELATION BETWEEN DURATION OF SYMPTOMS AT THE TIME OF OPERATION AND THE MORTALITY RATE IN 86 CASES OF INTUSSUSCEPTION

DURATION OF SYMPTOMS	NO. OF CASES	DEATHS	PER CENT MORTALITY
Less than 24 hr.	38	4	10.5
24-48 hr.	19	3	15.8
2-3 days	6	2	33.3
3-4 days	7	3	42.9
4-5 days	5	3	60.0
5-6 days	3	2	66.7
6-7 days	4	3	75.0
More than 7 days	4	4	100.0

The ileo-ileal lesions were associated with the highest mortality (62.5 per cent) and the colo-colic lesions with the lowest (25.0 per cent). The mortality for ileo-colic lesions was 25.4 per cent, and for ileo-ileo-colic lesions, 44.4 per cent. No instances of multiple or of retrograde invagination were encountered.

COMPLICATIONS

Twenty-three of the 28 deaths occurred during the first twenty-four postoperative hours and we have come to believe that if a patient survives the first twenty-four hours after operation he is apt to recover. These early deaths are generally attributed to shock and toxemia.

Complications included 14 cases of diarrhea, 8 upper respiratory infections, 8 cases of otitis media, 5 cases of pneumonia, 3 wound infections, 3 eviscerations, 2 cases of pulmonary edema, 2 cases of postoperative obstruction requiring operative release of adhesions, 2 cases of acute bronchitis, and 1 each of insulin shock, chicken pox, scarlet fever, intraenteric hemorrhage, atelectasis, fecal fistula, and intestinal obstruction of unknown cause thought to be the result of a recurrence with subsequent spontaneous resection.

Recurrence of the lesion was confirmed in 3 cases. Two of these patients were operated upon a second time, ten months and one year, respectively, after their first operation. A third patient died 5 hours after operation and was found to have a recurrent ileo-colic lesion which had extended around to the splenic flexure after being reduced from the sigmoid area at operation. This is believed to be the earliest recurrence to be reported.

TABLE III

THE TYPES OF LESION ENCOUNTERED IN 92 CASES OF INTUSSUSCEPTION AND THEIR RELATIVE MORTALITY RATES

TYPE OF INTUSSUSCEPTION	NO. OF CASES	DEATHS	PER CENT MORTALITY
Ileo-ileal	8	5	62.5
Ileo-ileo-colic	9	4	44.4
Ileo-colic	67	17	25.4
Colo-colic	8	2	25.0
Total	92	28	30.4

CONCLUSIONS

1. Ninety-two cases of intussusception with the patients operated upon in infancy and childhood have been reviewed from the Children's Hospital of Cincinnati and the Cincinnati General Hospital.

2. The classical symptom complex was described in less than one-half of the cases.

3. Of every 10 cases, pain was described in 7, vomiting in 9, and hematochezia in 7. At least two of these symptoms were noted in nearly all of the cases.

4. Of every 10 cases, a palpable abdominal mass was described in 6 and a rectal mass in 4.

5. The methods of treatment are described and the results of different methods compared.

6. Factors which have effected a recent reduction in mortality rate are discussed.

7. A lower mortality will be obtained only when the pediatricians are constantly on the alert for cases of intussusception, by prompt hospitalization and operation, by careful and individual selection of the operative procedure, and by intelligent cooperation between the pediatricians and surgeons in the preoperative and postoperative care.

REFERENCES

1. Bell, H. G., and Olney, M. B.: Acute Insussusception in Infants, S. Clin. North America 14: 1303, 1934.
2. Gordon, E. F.: Review of 42 Cases of Intussusception From the Files of the New Haven Hospital and 2 Cases Seen in Private Practice, Arch. Pediat. 37: 585, 1940.
3. Grigsby, G. P., and Kaplan, S. E.: Intussusception in Infancy and Childhood, Kentucky M. J. 36: 318, 1938.
4. Hipsley, P. L.: Intussusception, Brit. M. J. 2: 717, 1935.
5. Hipsley, P. L.: Treatment of Intussusception by Preliminary Injections Per Rectum, SURGERY 1: 825, 1937.
6. Jones, T. E.: Acute and Chronic Intussusception, S. Clin. North America 16: 991, 1936.
7. Kahle, R. H.: An Analysis of 151 Cases of Intussusception From Charity Hospital of Louisiana at New Orleans, Am. J. Surg. 52: 215, 1941.
8. Ladd, W. E., and Gross, R. E.: Intussusception in Infancy and Childhood, Arch. Surg. 29: 365, 1934.
9. Ladd, W. E., and Gross, R. E.: Abdominal Surgery in Infancy and Childhood, Philadelphia and London, 1941, W. B. Saunders Co.
10. Mayo, C. W., and Woodruff, R.: Acute Intussusception, Arch. Surg. 43: 583, 1941.
11. Miller, G. G., and Workman, E. W.: Clinical Survey of 21 Cases of Intussusception, Canad. M. A. J. 32: 660, 1935.
12. Perrin, W. S., and Lindsay, E. C.: Intussusception: A Monograph Based on 400 Cases, Brit. J. Surg. 9: 46, 1921.
13. Wakely, C. P. G., and Atkinson, F. R. B.: Acute Intussusception in Children, Brit. J. Child. Dis. 35: 241, 1938.
14. Woodhall, B.: Modified Double Enterostomy (Mikulicz) in Radical Surgical Treatment of Intussusception in Children, Arch. Surg. 36: 989, 1938.
15. Wyatt, O. S.: Intussusception in Infants, Minnesota Med. 24: 587, 1941.

MASTITIS OBLITERANS

ROBERT L. PAYNE, M.D., ARNOLD F. STRAUSS, M.D., AND
R. D. GLASSER, M.D., NORFOLK, VA.
(From the Surgical and Pathologic Departments of St. Vincent's Hospital)

IN RECENT years low-grade inflammatory lesions of the breast simulating cancer clinically, and sometimes microscopically,[1, 6, 7, 9, 10, 17] have received much attention by pathologists and surgeons. In addition to simple and subacute mastitis and traumatic fat tissue necrosis, there has been a picture called plasma cell mastitis discussed and described at length. However, there is a less known low-grade inflammatory lesion of the breast which is characterized by an obliterating process of the milk ducts called mastitis obliterans, and this condition likewise simulates cancer in its clinical picture.

In 1909, Alexandra Ingier[13] published the first description of this picture under the name of "Mastitis Obliterans." She referred to previous studies by Langhans,[16] who as early as 1873 had called attention to the obliteration of the milk passages in tissue associated with cancer of the breast.

In 1905, Samelson-Kliwansky[20] published an article entitled "A Contribution to the Knowledge of Mammary Cyst With Butterlike Contents." The clinical data relating to his specimen were not reported. The cross section of the specimen showed a "firm, granular, whitish, semitranslucent tissue with numerous small openings from which, upon slight pressure, yellowish-green, partly calcified plugs came forth." The hollow spaces in the specimen were ducts 1 to 2 cm. long and 0.25 to 1 mm. in diameter. Microscopically, the butterlike material consisted of degenerated epithelium and its products. He reasoned that inflammatory connective tissue had led to the obliteration of the ducts and had been followed by degeneration of the epithelium which in some areas was in the stage of proliferation. Giant cells and cholesterol crystals were present in the milk passages, and these passages were surrounded by numerous areas of lymphocytic foci.

Ingier's case was as follows.

A woman 43 years of age had given birth to a child, and while nursing this baby, a mammary abscess developed in the right breast which was incised. Approximately one month after her discharge from the hospital, a nodular mass the size of a small hen egg developed in the right breast and was excised. The tissue excised was quite firm and composed of lobules slightly larger than those of the normal breast. The cut surface showed yellowish white flecks and stripes, 1 to 2

Received for publication, May 28, 1943.

mm. long and 0.5 mm. in diameter. A yellowish white secretion could be expressed from the tissue. Microscopically, many of the acini showed their lumina obliterated and the membrana propria was often destroyed. Lymphocytes were present between the proliferated epithelial cells and diffusely scattered throughout the lobules. The epithelium showed degenerative changes such as fat droplets, indistinct outline, and badly stained nuclei. There were many multinucleated giant cells. In addition to the acini being closed, the lumina of the larger ducts and their branches were occasionally obliterated, and their walls appeared to be formed by three layers as follows: A peripheral layer, highly infiltrated with lymphocytes, associated with an increase of elastic fibers; a medial layer consisting of round spindle shaped polyhedral and branched cells arranged radially with relation to the lumen; an internal one consisting of epithelial cells showing marked degenerative and proliferative changes which were limited by the medial layer and often showed loss of the membrana propria.

In 1910, Hoerz[12] discussed a case of mastitis obliterans as follows.

A woman 43 years of age had borne sixteen children and had nursed all of them from her left breast. Her right one had not given sufficient milk. One and one half years after the birth of her last child, she received a blow against the nonfunctioning right breast. Two weeks later an acute mastitis was present, associated with chills. The temperature rise cleared up in a few days, but the tenderness, redness, and swelling persisted. The nipple became retracted, and there developed a lump the size of a fist with indistinct boundaries but not fixed to the skin. One month later part of the large mass had disappeared, but there remained a diffuse hardening in the lower, inner quadrant with some attachment to the skin. She underwent a radical mastectomy because cancer was suspected. The gross and microscopic examination of the tissue removed showed the same changes as in Ingier's case but in addition, ray fungushke clusters of fatty acid crystals surrounded by foreign body granulomas were present.

During the following two decades, mastitis obliterans seems to have been forgotten. In 1923, Keynes,[15] in a publication on chronic inflammatory mastitis, described a case of acute exacerbation of chronic mastitis during pregnancy and attributed the fibrosis of the ducts and the disappearance of their epithelium to the retention of milk. Illustrations in his publication coincide with those of mastitis obliterans.

In 1933, Schultz[22] published a discussion of a case of mastitis obliterans with numerous photomicrograms and described in details the histologic picture but did not stress the clinical data. He considered complete obstruction of the ducts to be rare and emphasized the fact that the same process occurred rather commonly in chronic mastitis. In considering the relationship of the clinical picture to malignancy, Schultz stated that mastitis obliterans could begin as an acute or subacute inflammation which became chronic; however, in some cases the acute and subacute stages were not apparent and could only be developed through the history.

One of us (R.D.G.) observed the following case of mastitis obliterans.

Mastitis obliterans occurred in a colored woman 57 years old. Her family history was not contributory. She has two living children and has had three miscarriages. In 1918, hysterectomy was performed because of tumors in the uterus.

In 1930, she had a bilateral subtotal thyroidectomy performed for toxic adenoma On admission to St Vincent's Hospital, her chief complaint was enlargement of the left breast which she had been observing for two years During the two weeks prior to admission the breast had become somewhat tender and she felt shooting pains through the area involved. There was dyspnea on exertion, and standing for a long period of time produced swelling of the ankles There was a slight tremor of her hands Her temperature ranged from 98 6 to 100° F. Blood pressure was 174 systolic and 98 diastolic. She thought she had lost approximately ten pounds in weight during the past two years Her left breast was enlarged with a firm infiltrated mass under the nipple and some induration of the skin The nipple reflex was lost and in the axilla there were some enlarged lymph nodes which were tender. Radiologic examination revealed no metastases to the lungs or to the skeletal framework

Laboratory Findings on Admission—Urine was positive for sugar, a trace of albumin, and a few pus cells After four days on a diabetic diet (carbohydrate, 120; fat, 80, protein, 60), the urine became negative for sugar and the blood sugar was 108 mg The blood picture disclosed hemoglobin 78 per cent, R B C 4,116,000, W B C 11,500, polymorphonuclears 85 per cent, and lymphocytes 15 per cent The non protein nitrogen was 40 mg per 100 c c of blood and she had a positive Wassermann

The diagnosis of a subacute mastitis was confirmed from a clinical viewpoint, yet the tumor mass gave a decided suspicion of cancer At operation a simple mastectomy was performed and rapid frozen section showed no evidence of cancer The gross specimen showed an infiltrated hard tumor mass 7 cm in diameter and on section showed many areas of degeneration with thick purulent secretion The gross examination of the specimen in the pathologic laboratory was breast, 21 by 14 by 3 cm in size, areola 6 cm in diameter There was very little, if any, retraction of the nipple Under the nipple there was a hard mass with indistinct boundaries, which was adherent to the overlaying skin On cross section, there was no well defined tumor, throughout the entire mammary gland and especially throughout the mass below the nipple, pressure caused yellowish creamy material to ooze from numerous small openings The mammary tissue was white in color and decidedly more dense and firm in the subareolar region with this tissue reaction fading into the sur rounding fat Within the mass there were yellowish stripes and spots and the ducts appeared white but showed a yellow center

Microscopic Examination—Blocks of tissue examined from different areas of the mass showed lymphocytic infiltration, especially marked about the smaller and larger ducts There was very little plasma cell infiltration The terminal ducts showed budlike proliferation and revealed hyperplasia and desquamation of their epithelial cells and occasionally giant cells were present The larger ducts presented granulation tissue in their walls The fibroblasts were radially arranged forming a thick ring including the lumen of the larger ducts These lumina were filled with partly proliferated, degenerated, and desquamated cells Round cells, leucocytes, and histiocytes infiltrated the epithelial layer and the granulation tissue In the section from the periphery of the breast, there were within the fat tissue some leucocytic infiltration and abscess formation surrounded by many pseudo xanthomacells intermingled with a few foreign body giant cells

Diagnosis. Mastitis obliterans

A second case coming under our observation is as follows

A colored woman, aged 36 years had always been in good health She had had three pregnancies 18, 16, and 9 years previously, respectively She had nursed each baby from nine to twelve months There was no history of previous breast trouble at any other time Menstrual history was normal

Four weeks before coming under observation, the patient noticed a lump in the right breast about the size of a hickory nut. She had never previously noticed anything in this breast. For several days prior to observing the mass, she began experiencing some darting pains in the breast. Examination revealed a hard, irregular mass in the upper inner quadrant of the right breast about the size of a hen's egg. The mass was attached to the skin about one inch from the nipple but the breast itself was freely movable with no deep attachment of the tumor mass. A small amount of whitish yellow, milky looking fluid was expressed on palpation from the nipple. Temperature was normal, and the Wassermann blood reports were negative. Malignancy of the right breast was suspected and the breast was removed.

Pathologic Report (No. 17,912).—Clinical Diagnosis: Malignancy of right breast.

Gross Description. A hard fibrous mass about the size of a hen egg was found. The mass was infiltrated with something resembling milk pockets.

Gross Examination: The piece of breast tissue 4 by 2.5 by 2 cm. consisted of fat and whitish glandular tissue which showed, upon cross section, a number of fine ducts with yellowish walls and small yellow geographical areas within the tissue.

Microscopic Examination: The breast showed ducts lined by granulation tissue, sometimes covered by irregularly grown epithelial cells. The granulation tissue itself consisted of large fibroblasts which contained fat and showed light cytoplasm of slightly foamy appearance. There was a fair amount of neutrophilic infiltration within the granulation tissue which narrowed the lumen of the ducts. The surroundings showed marked lymphocytic infiltration and occasionally groups of plasma cells, but the latter were not the predominant feature.

The granulation tissue of the ducts contained giant cells in some places and the lumen of one duct showed desquamated cells which were vesicular, clear, and contained fat. Within the desquamated epithelial cells could be found raylike bodies which consisted of fatty acid crystals and the center of these occasionally contained cellular detritus.

DISCUSSION

Mastitis obliterans as a pathologic entity is characterized by the two inseparable features expressed by its name. First, a truly inflammatory mastitis and second, an obliteration of the milk passages. The structures involved are the acini, the ductal, periductal, and interstitial tissues.

Infiltrative, proliferative, and hyperplastic changes are part of the pathology of the ducts. Obliteration of the ducts in itself is not characteristic of the disease and may be found in other noninflammatory or inflammatory diseases of the breast. The primary, senile atrophic occlusion of the milk passages is known,[3, 4, 8, 22] although it is doubted by some authors.[2, 21] In cystic diseases of the breast "peritubular halos" of the ducts were first described with drawings illustrating the obliterating ducts by von Saar.[23] They were observed in association with carcinoma, especially scirrhous carcinoma[2, 16, 21] and mesenchymal tumors.[21] In reviewing some of our breast cases, we find occasional obliteration not only in cystic disease but also in intraductal papilloma and carcinoma. We have gained the impression that often the obliterating process seems to occur distal to a mechanical obstruction by tumor or cyst. An example of inflammatory disease which may spread intraductly is tuber-

culosis.[14] We have recently observed such a case in which the milk passages were filled with specific granulation tissue.

In obliterating mastitis the occlusion of the ducts is likewise distinctly inflammatory, but the granulation tissue prevails in a radial arrangement while noninflammatory lesions show a concentric pattern. Progressive and degenerative changes of the epithelium take part in filling out the lumina. This is exemplified by a proliferation producing giant cells or groups of cells undergoing necrobiotic changes such as fatty degeneration and desquamation. Sometimes clusters of fatty acid crystals can be found which grossly resemble sulfur bodies. The basal membrane of the duct is often destroyed by granulation tissue and this, coupled with the aforementioned changes, will frequently give a picture which

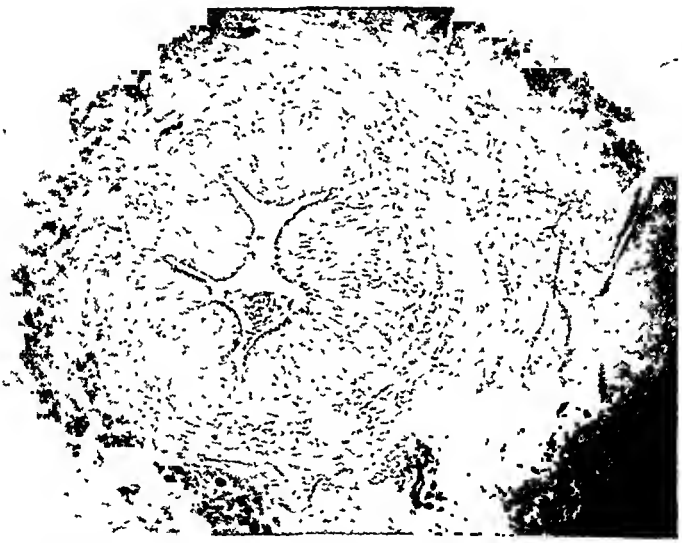

Fig 1—Shows a large duct nearly obliterated by granulation tissue. There is desquamation of epithelial cells in the center of the duct.

simulates tuberculosis or even carcinoma. Interstitial changes are often found associated with the ductal lesions Inflammation may produce neutrophilic, eosinophilic, lymphocytic, and plasmacellular infiltration. Damage to the fatty tissue leads to necrosis and there will also be present lipophagic elements, sometimes referred to as pseudoxanthoma cells, foreign body giant cells, and frequently fatty acid crystals. The great resemblance, clinically, of mastitis obliterans to carcinoma and lesions simulating cancer must be strongly emphasized in the differential diagnosis.

The recently described plasma cell mastitis deserves a more extensive discussion. Although the latter term was first used by Ewing,[9, 10] he has never claimed priority of authorship, which he attributes to Adair. Adair first published a series of cases[1, 5] under the title of plasma cell mastitis and his reports were followed by contributions from Miller[18] and Rodman and Ingelby.[19]

Four weeks before coming under observation, the patient noticed a lump in the right breast about the size of a hickory nut. She had never previously noticed anything in this breast. For several days prior to observing the mass, she began experiencing some darting pains in the breast. Examination revealed a hard, irregular mass in the upper inner quadrant of the right breast about the size of a hen's egg. The mass was attached to the skin about one inch from the nipple but the breast itself was freely movable with no deep attachment of the tumor mass. A small amount of whitish yellow, milky looking fluid was expressed on palpation from the nipple. Temperature was normal, and the Wassermann blood reports were negative. Malignancy of the right breast was suspected and the breast was removed.

Pathologic Report (No. 17,912).—Clinical Diagnosis: Malignancy of right breast.

Gross Description: A hard fibrous mass about the size of a hen egg was found The mass was infiltrated with something resembling milk pockets.

Gross Examination: The piece of breast tissue 4 by 2.5 by 2 cm. consisted of fat and whitish glandular tissue which showed, upon cross section, a number of fine ducts with yellowish walls and small yellow geographical areas within the tissue.

Microscopic Examination: The breast showed ducts lined by granulation tissue, sometimes covered by irregularly grown epithelial cells. The granulation tissue itself consisted of large fibroblasts which contained fat and showed light cytoplasm of slightly foamy appearance. There was a fair amount of neutrophilic infiltration within the granulation tissue which narrowed the lumen of the ducts. The surroundings showed marked lymphocytic infiltration and occasionally groups of plasma cells, but the latter were not the predominant feature.

The granulation tissue of the ducts contained giant cells in some places and the lumen of one duct showed desquamated cells which were vesicular, clear, and contained fat. Within the desquamated epithelial cells could be found raylike bodies which consisted of fatty acid crystals and the center of these occasionally contained cellular detritus.

DISCUSSION

Mastitis obliterans as a pathologic entity is characterized by the two inseparable features expressed by its name. First, a truly inflammatory mastitis and second, an obliteration of the milk passages. The structures involved are the acini, the ductal, periductal, and interstitial tissues.

Infiltrative, proliferative, and hyperplastic changes are part of the pathology of the ducts. Obliteration of the ducts in itself is not characteristic of the disease and may be found in other noninflammatory or inflammatory diseases of the breast. The primary, senile atrophic occlusion of the milk passages is known,[3, 4, 8, 22] although it is doubted by some authors.[2, 21] In cystic diseases of the breast "peritubular halos" of the ducts were first described with drawings illustrating the obliterating ducts by von Saar.[23] They were observed in association with carcinoma, especially scirrhous carcinoma[2, 16, 21] and mesenchymal tumors.[21] In reviewing some of our breast cases, we find occasional obliteration not only in cystic disease but also in intraductal papilloma and carcinoma. We have gained the impression that often the obliterating process seems to occur distal to a mechanical obstruction by tumor or cyst. An example of inflammatory disease which may spread intraductly is tuber-

be mainly a repetition of the features of mastitis obliterans herein described. The difference remaining between the two diseases is possibly a more pronounced occlusion of the ducts by granulation tissue in obliterating mastitis in contrast to a marked infiltration of plasma cells. This led Ewing, Adair, and Rodman to name the picture plasma cell mastitis. We would like to record the opinion here that plasma cells as a feature of the picture are not of sufficient importance to establish a new entity of mastitis. So far as we know they are not pathognomonic of any one lesion. Plasma cells are merely a cellular expression of the

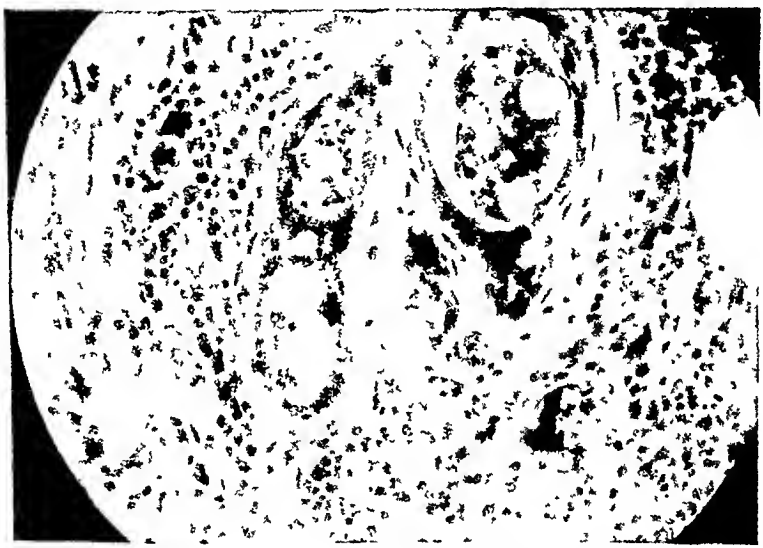

Fig 4—Shows a small duct under high power The epithelial tissue is in marked proliferation, atypical, with giant cells, and in vacuolar degeneration There is budding of the ducts The infiltration is lymphocytic with some plasma cells, and shows about the maximum of plasma cells found in any of the slides.

chronicity of an inflammation. There are a great number of other cells present in the published photomicrographs of plasma cell mastitis such as neutrophiles, eosinophiles, lymphocytes, and pseudoxanthoma cells. Generally we classify inflammatory lesions in conformity with their etiology, localization, stage, and certain complex features but not according to the predominant types of cells found We recognize obliterating inflammations, such as bronchitis and phlebitis, but to use the term plasma cell inflammation is definitely a generalization even though these cells may often predominate in certain lesions, such as are found in the Fallopian tubes or the nasal mucosa Gross cancer-simulating features have led to the adoption of the name plasma cell mastitis to define both a clinical and pathologic entity. These cancer-simulating features do not depend on the predominance of the plasma cell. The marked proliferation of the connective tissue, especially the subepithelial connec-

: cancerous appearance on clinical exam-

If one compares the description and photomicrographs of the two diseases, there will be observed a very great similarity. Clinically, the gross symptoms and findings are identical. Ewing[10] states that in plasma cell mastitis "the main gross anatomical feature is the presence of many greatly thickened ducts," but his microscopic description would



Fig. 2.—Shows a corner of a larger duct. The infiltrating cells are mostly lymphocytes, but this is one of the regions where some plasma cells are found.

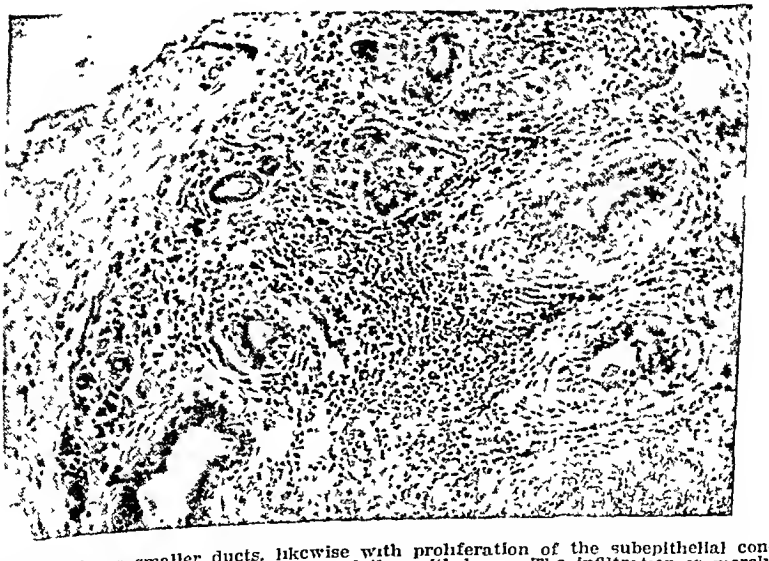

Fig. 3.—Shows smaller ducts, likewise with proliferation of the subepithelial connective tissue and marked proliferation of the epithelium. The infiltration is merely lymphocytic; plasma cells are absent.

cancer. Principally, these lesions are cystic disease of the breast, subacute and chronic mastitis, lactation mastitis, galactocele, traumatic fat tissue necrosis, tuberculosis, actinomycosis, and syphilis of the breast. The features of these diseases have all been discussed in a number of excellent and recent publications.[1, 5, 6, 7, 17, 18] Obliterating mastitis simulates cancer in many respects. Usually there is a lump generally located in the neighborhood of the areolar region. This mass is adherent to the skin and may be reddened as in inflammatory carcinoma. Often the nipple is retracted. The axillary glands may be enlarged. On the other hand, if there is a history of previous inflammation, if the mass and lymph nodes are tender and painful, if the thickened ducts can be felt in the mass, and especially if yellowish creamy material can be expressed or sucked from the nipple, one should think of mastitis obliterans.

SUMMARY

Two cases of mastitis obliterans, a lesion simulating cancer, are described and its realtion to so-called plasma cell mastitis is discussed.

REFERENCES

1. Adair, F. E.: Arch. Surg. 26: 735-749, 1933.
2. Askanazy, M.: Beitr. z. path. Anat. 87: 396, 1931.
3. Beneke, R.: Verhandl. d. deutsch. path. Gesellsch. 25: 315, 1930.
4. Berka: Frankfurt. Ztschr. f. Path. 8: 203, 1911.
5. Cheatle, G. L., and Cutler, M.: Tumors of the Breast, Philadelphia, 1931, J. B. Lippincott Co., p. 298.
6. Cohn, L. Clarence, and Bloodgood, J. G.: Am. J. Cancer 16: 487, 1932.
7. Cutler, M.: J. A. M. A. 101: 1217, 1933.
8. Deaver, J. B., and McFarland, J.: Philadelphia, 1917, P. Blakiston's Son & Co., p. 19.
9. Ewing, James: Neoplastic Diseases, Philadelphia, 1940, W. B. Saunders Co., p. 547.
10. Ewing, James: Quoted by Adair.
11. Gronwald: Zentralbl. f. Chir. 58: 663, 1910.
12. Hoerz: Beitr. z. Klin. Chir. 70: 682, 1910.
13. Ingier, Alexandra: Virchow's Arch. f. path. Anat. 198: 338, 1909.
14. Ingier, Alexandra: Virchow's Arch. f. path. Anat. 202: 217, 1910.
15. Keynes, Geoffrey: Brit. J. Surg. 11: 89, 1923.
16. Langhans, Theodor: Virchow's Arch. f. path. Anat. 58: 132, 1873.
17. Lehman, Edwin P.: Virginia M. Monthly 67: 197, 1940.
18. Miller, J. K.: Am. J. Surg. 43: 788, 1939.
19. Rodman, J. Stewart, and Ingelby, Helen: Ann. Surg. 109: 921-930, 1939.
20. Samelson-Kliwansky: Virchow's Arch. f. path. Anat. 179: 76, 1905.
21. Scholz, Wolfgang: Frankfurt. Ztschr. f. Path. 43: 102, 1932.
22. Schultz, A.: Handbuch der Speziellen Pathologie, Berlin, 1933, Julius Springer, VII. 2, p. 145.
23. von Saar, Gunther: Arch. f. klin. Chir. 84: 223, 1907.
24. Cromar, C. A. L.: Proc. Staff Meet., Mayo Clin. 16: 475, 1941.

ination. The proliferation of the subepithelial connective tissue, the obstruction of the ducts by the latter, and the irregular proliferation of the ductal epithelium are the most striking features. Plasma cells are nothing but the expression of a chronic inflammation of long duration. They are not pathognomonic of anything. Recently we have observed a massive plasma cell exudation of the periductal tissue surrounding an old sinus tract of the breast, yet none of the cancer-simulating features of so-called plasma cell mastitis were present. These

Fig. 5.—A cluster of fatty acid crystals in the midst of debris filling a duct.

cancer-simulating features are produced by the contraction of inflammatory granulation tissue and the irregular retraction mass consists of thickened ducts and inflammatory cells of all types independent of the presence of more or less plasma cells. Thus we believe that the name, plasma cell mastitis, is superfluous and that the well-known terms of subacute and chronic (inflammatory) mastitis are sufficient with their old subdivision according to the main localization, interstitial and ductal types. The microscopic picture of the ductal types may show a prevalence of neutrophiles, eosinophiles, lymphocytes, and plasma cells without any recognized change in the clinical picture or in the gross specimen. If the lesion reaches the stage of tortuous, thickened ducts, easily recognized on cut surface, the old term of obliterating mastitis seems justified. Although we deem the new name of plasma cell mastitis superfluous, we think that Adair, Rodman, and others deserve much credit for emphasizing the difficulties in distinguishing the lesion under discussion from malignancy and other inflammatory lesions.

From the standpoint of clinical differential diagnosis, obliterating mastitis belongs to the group of lesions which may be confused with

cancer. Principally, these lesions are cystic disease of the breast, subacute and chronic mastitis, lactation mastitis, galactocele, traumatic fat tissue necrosis, tuberculosis, actinomycosis, and syphilis of the breast. The features of these diseases have all been discussed in a number of excellent and recent publications.[1, 5, 6, 7, 17, 18] Obliterating mastitis simulates cancer in many respects. Usually there is a lump generally located in the neighborhood of the areolar region. This mass is adherent to the skin and may be reddened as in inflammatory carcinoma. Often the nipple is retracted. The axillary glands may be enlarged. On the other hand, if there is a history of previous inflammation, if the mass and lymph nodes are tender and painful, if the thickened ducts can be felt in the mass, and especially if yellowish creamy material can be expressed or sucked from the nipple, one should think of mastitis obliterans.

SUMMARY

Two cases of mastitis obliterans, a lesion simulating cancer, are described and its realtion to so-called plasma cell mastitis is discussed.

REFERENCES

1. Adair, F. E.: Arch. Surg. 26: 735-749, 1933.
2. Askanazy, M.: Beitr. z. path. Anat. 87: 396, 1931.
3. Beneke, R.: Verhandl. d. deutsch. path. Gesellsch. 25: 315, 1930.
4. Berka: Frankfurt. Ztschr. f. Path. 8: 203, 1911.
5. Cheatle, G. L., and Cutler, M.: Tumors of the Breast, Philadelphia, 1931, J. B. Lippincott Co., p. 298.
6. Cohn, L. Clarence, and Bloodgood, J. G.: Am. J. Cancer 16: 487, 1932.
7. Cutler, M.: J. A. M. A. 101: 1217, 1933.
8. Deaver, J. B., and McFarland, J.: Philadelphia, 1917, P. Blakiston's Son & Co., p. 19.
9. Ewing, James: Neoplastic Diseases, Philadelphia, 1940, W. B. Saunders Co., p. 547.
10. Ewing, James: Quoted by Adair.
11. Gronwald: Zentralbl. f. Chir. 58: 663, 1910.
12. Hoerz: Beitr. z. Klin. Chir. 70: 682, 1910.
13. Ingier, Alexandra: Virchow's Arch. f. path. Anat. 198: 338, 1909.
14. Ingier, Alexandra: Virchow's Arch. f. path. Anat. 202: 217, 1910.
15. Keynes, Geoffrey: Brit. J. Surg. 11: 89, 1923.
16. Langhans, Theodor: Virchow's Arch. f. path. Anat. 58: 132, 1873.
17. Lehman, Edwin P.: Virginia M. Monthly 67: 197, 1940.
18. Miller, J. K.: Am. J. Surg. 43: 788, 1939.
19. Rodman, J. Stewart, and Ingelby, Helen: Ann. Surg. 109: 921-930, 1939.
20. Samelson-Kliwansky: Virchow's Arch. f. path. Anat. 179: 76, 1905.
21. Scholz, Wolfgang: Frankfurt. Ztschr. f. Path. 43: 102, 1932.
22. Schultz, A.: Handbuch der Speziellen Pathologie, Berlin, 1933, Julius Springer, VII. 2, p. 145.
23. von Saar, Gunther: Arch. f. klin. Chir. 84: 223, 1907.
24. Cromar, C. A. L.: Proc. Staff Meet., Mayo Clin. 16: 475, 1941.

THE USE OF INTRAVENOUS AMMONIUM CHLORIDE IN THE TREATMENT OF ALKALOSIS

H. A. Zintel, M.D., J. E. Rhoads, M.D., and I. S. Raydin,* M.D.
Philadelphia, Pa.
(From The Harrison Department of Surgical Research, Schools of Medicine, University of Pennsylvania and Surgical Service B, Hospital of the University of Pennsylvania)

THE need for a more effective parenteral method of correcting alkalosis has arisen with increasing frequency during recent years. Hartman and Senn[1] pointed out the usefulness of an intravenous solution of sodium lactate for overcoming acidosis, but no parenteral preparation has been generally available for the correction of alkalosis. In a limited number of cases, intravenous ammonium chloride has proved to be highly effective in combating alkalosis.

Undoubtedly, the use of continuous suction drainage of the stomach, especially in the preoperative preparation of patients with pyloric obstruction, has been responsible for most of the cases of severe alkalosis. The use of suction drainage in patients with pyloric obstruction, as advocated by Graham,[2] is a procedure which we believe has reduced the morbidity and mortality of operative procedures on the stomach and duodenum. Graham has recommended not only that the stomach be washed out, but that it be kept clean and empty for a number of days before operation.

Patients with pyloric obstruction, when they are first hospitalized, commonly have a considerable degree of alkalosis from vomiting alone, since the vomitus contains more anions (especially chloride) than it does cations other than hydrogen. Suction drainage further accentuates the alkalosis. Some of these patients lose enormous quantities of gastric juice. The volume of gastric drainage may amount to over 6 liters per day. When such exaggerated losses occur, they tend to accelerate the development of alkalosis and increase its severity.

For some years the medical profession followed the view advanced by Gamble and Ross[3] that if the body was supplied with sufficient physiologic saline solution and if ketosis was prevented, the electrolyte pattern of the plasma would be adjusted satisfactorily by the kidneys. It is well known that infants and adults ill with pneumonia are frequently unable to dispose of surplus sodium.[4] Similar limitations of sodium excretion were found to apply to certain postoperative patients by Jones and Eaton.[5]

*Lt. Colonel, Medical Corps, U. S. Army.

Received for publication, May 10, 1943.

Gambill and Sharpe,[6] in a discussion of alkalosis and gastric tetany, dismissed the use of ammonium chloride on the findings of Gamble and Ross.[3] Gamble and Ross found that rabbits with complete pyloric obstruction lost not only chlorides but also considerable amounts of base in the form of sodium. In their animals the total base as well as the chlorides was depleted. Their experiments showed that saline solution kept the animals alive while ammonium chloride did not keep them alive although it did overcome the alkalosis.

In the patient with excessive gastric drainage, replacement of the drainage fluid by sodium chloride solutions in quantities calculated to keep the patient in positive water and electrolyte balance does not always effectively combat alkalosis. The patients reported in this series all received fluid and sodium chloride in amounts calculated to restore their plasma electrolyte patterns. In five of the instances the total serum base was determined by chemical analysis. In the remaining cases the total base was approximated from the serum protein level, CO_2 value, and serum chloride level according to the method of Elkinton, Gilmore, and Wolff.[7] The total serum base in each of the reported cases was above the lower limits of the normal accepted range of total serum base. It is in this type of patient, namely, the patient with severe alkalosis, who has been treated with ample fluid and sodium chloride, that we believe the intravenous injection of ammonium chloride is at times justified. Alkalosis not only may produce tetany and convulsions but it may produce serious renal damage, the alkalosis nephrosis described by Nicol[8] and others. It, therefore, seems wise to overcome the alkalosis and to restore electrolyte balance of the blood as promptly as possible. Intravenous ammonium chloride is not only effective but it is also prompt in its action.

Ammonium chloride has long been employed by the oral route to acidify the urine. It has been used to advantage occasionally by the same route to overcome alkalosis, but the oral route is not available in the group of patients in which the tendency to alkalosis is greatest, those who have pyloric obstruction. The rectal route in our experience proved to be of only limited value. Some reduction in serum CO_2 was obtained but the change was slow (Table I).

The results of the intravenous administration of ammonium chloride twelve times in seven patients on surgical service B at the hospital of the University of Pennsylvania, are shown in Table I. In most instances the response was quite uniform. The figures obtained indicate that for an adult of 150 pounds, 1 Gm. of intravenous ammonium chloride will reduce the serum CO_2 by an average of 1.1 volumes per cent. On the basis of this experience the dose may be calculated according to the instructions in Table II. These findings indicate a wide distribution of the solute in body water.

TABLE I

PATIENT	DIAGNOSIS	AMT. OF NH_4Cl SOL.		CO_2 VOL. %		VOL. % CO_2 DECREASE PER GM. NH_4Cl†
		(C.C.)	(%)	BEFORE	AFTER	
J. M.	Perf. gastric ulcer	200	2	72	67	1.3
J. E. M.	Perf. ca. of sigmoid with peritonitis	200 *200	2 2	75	62	1.2
A. H.	Chronic peptic ulcer with stenosis, avitaminosis	750 *500	2 2	152	112	1.1
A. H.	Chronic peptic ulcer with stenosis, avitaminosis	700	2	113	85	0.9
A. H.	Chronic peptic ulcer with stenosis, avitaminosis	250	1.7	76	-	-
A. H.	Chronic peptic ulcer with stenosis, avitaminosis	650	2	84	62	1.1
H. D.	Chronic peptic ulcer with stenosis	1,000	2	87	51	1.2
S. H.	Perf. appendix with peritonitis	1,000	2	80	65	1.1
T. B.	Bleeding peptic ulcer, hypoproteinemia	750	2	87	75	0.9
T. B.	Bleeding peptic ulcer, hypoproteinemia	500	2	77	-	-
T. B.	Bleeding peptic ulcer, hypoproteinemia	1,000	2	87	76	0.6
M. M.	Ca. of pancreas	1,000	2	117	80	1.5
	Average					1.1

*These patients received part of this NH_4Cl by rectum.
†These figures have been calculated for a body weight of 150 pounds.

TABLE II

DOSAGE OF AMMONIUM CHLORIDE

TO REDUCE THE SERUM CO_2	ALLOW
One volume per cent	16 mg. per kilogram of body weight or 7.3 mg. per pound of body weight
One milliequivalent	36 mg. per kilogram of body weight or 16 mg. per pound of body weight

Two per cent solutions of ammonium chloride were prepared by dissolving 20 Gm. of ammonium chloride in a liter of water, 0.9 per cent sodium chloride solution, or 5 per cent dextrose solution. In most instances the solution was brought to boiling just before the ammonium chloride was added and then allowed to cool slowly. It was then used as soon as it had cooled sufficiently.

We have, however, given 2 per cent ammonium chloride with 0.9 per cent sodium chloride without reaction after autoclaving at 15 pounds pressure for twenty minutes. If 5 per cent glucose is present a marked brownish color develops suggesting caramelization. Such solutions have not been used.

The rate of administration has varied with the exigencies of the case but usually it was not greater than 1000 c.c. in two hours. It is pos-

sible that slower rates of administration and more dilute solutions will prove to be of advantage except when tetany has appeared.

No serious reactions have been encountered but three transient reactions have occurred. Two of these patients complained of a sensation of lights flashing before their eyes and the third patient had a chill lasting three minutes, with a rise of temperature to 102° F. It may be of interest that the two patients who experienced the scintillating scotoma received a solution of ammonium chloride in distilled water with no other solute, whereas the patients who had no reactions received ammonium chloride in solutions of either sodium chloride or glucose.

CONCLUSIONS

Severe alkalosis may result from continuous gastric suction, especially in patients with pyloric obstruction.

Ammonium chloride solution was administered intravenously to seven patients with alkalosis without evident harm.

It was effective in rapidly lowering the serum CO_2 at the rate of approximately one volume per cent for each gram administered to adults of medium size and weight.

Sufficient evidence has not accumulated to determine the safety of this method of administration, but it appears sufficiently safe to warrant its use in severe alkalosis that cannot be corrected by the administration of salt and fluids promptly enough to avert the danger of renal changes.

REFERENCES

1. Hartman, A. F., and Senn, M. J. E.: Studies in Metabolism of Sodium lactate; Response of Human Subjects With Acidosis to Intravenous Injection of Sodium Lactate, J Clin. Investigation 11: 337, 1932.
2. Graham, R. R.: Technical Surgical Procedures for Gastric and Duodenal Ulcer, Surg., Gynec. & Obst. 66: 269 287, 1938.
3. Gamble, J. L., and Ross, S. G: The Factors in the Dehydration Following Pyloric Obstruction, J. Clin. Investigation 1: 403, 1925.
4. Wilder, T. S., and Drake, T. G H.: Metabolism of Chloride and Total Fixed Base in Pneumonia and the Retention of Salt and Water Retention, J. Clin. Investigation 7: 353, 1929
5. Jones, C. M., and Eaton, F. B: Postoperative Nutritional Edema, Arch. Surg. 27: 159, 1933.
6. Gambill, E. E., and Sharpe, W. S Gastric Tetany as a Symptom, Proc. Staff Meet. Mayo Clin. 17: 72, 1942.
7. Elkinton, J. R., Gilmore, M. T., and Wolff, W. A.: The Control of Water and Electrolyte Balance in Surgical Patients, Ann. Surg. 110: 1050, 1939.
8. Nicol, B. M: Renal Changes in Alkalosis—Related to Alkali Treatment of Peptic Ulcer, Quart. J. Med. 9: 91 105, 1940.

THE ROLE OF SURGERY IN THE TREATMENT OF MALIGNANT SKIN TUMORS

DANELY P. SLAUGHTER, M.D., CHICAGO, ILL.

(From the Department of Surgery, University of Illinois, College of Medicine, Chicago, and the Research Hospital)

CANCER of the skin is the most common malignant tumor affecting the human body, and, in most of its manifestations, the most easily curable. The average early cancer can be eradicated by any of several destructive methods, surgical excision, the selectively destructive roentgen or gamma rays, electrodesiccation, or by zinc chlorine or other pastes. Irradiation and surgery are now the most frequently used, irradiation being the more universally employed. Both surgical and radiation methods have special advantages in particular types of skin cancer, but neither is capable of being employed universally to the best advantage. The purpose of this communication is to attempt a definition of the phases of skin cancer best suited to surgical treatment. It must be realized that there are many borderline situations in which indications for either surgery or radiation may overlap, and in such a situation the therapist is justified in using either method with which he is most familiar and skillful.

PROPHYLAXIS

Prophylactic treatment of precancerous lesions is concerned mainly with the keratoses and dyskeratoses, and is principally a radiation problem. These lesions occur, as a rule, late in life and are usually found on the face, neck, and backs of the hands. However, surgery is definitely the method of choice for the following two classes of lesions.

Benign Neuronevus.—The common mole, or benign neuronevus, when in a location exposed to constant irritation, should be completely excised surgically. Probably all moles on the feet should be removed, as they are particularly prone to malignant transformation. Other dangerous locations are the belt line, the shoulders, the neck (where a collar may rub the lesion), and the neck or face in males where shaving may cause repeated slight trauma. It cannot be too strongly emphasized that, when the decision is made to remove them, these lesions should be completely excised. Tampering with them by electrodesiccation or incomplete removal is inviting serous trouble. Radiation is, of course, entirely useless.

Presented at a meeting of the Society of University Surgeons, Feb. 13, 1943.
Received for publication, May 10, 1943.

Postradiation Keratosis.—Postradiation atrophy of the skin with beginning keratosis is a precancerous lesion which should be excised and replaced by a full thickness or thick split-skin graft. The younger the patient the more important is this therapy. For obvious reasons the majority of such lesions are seen as late results of radiation dermatitis caused by accidental exposure or from x-ray therapy given to benign lesions. The majority of precancerous late radiation effects are from unfiltered or lightly filtered low-voltage x-rays. However, the much "harder" gamma rays from radium or radon may also produce this result. Radiation sclerosis of the skin from accidental exposure is usually seen today on the fingers and hands of radiologists, orthopedists, or other surgeons accustomed to setting fractures under the fluoroscope. Those lesions resulting from treatment of benign lesions are commonly seen about the face and chin of women who received epilation doses of low-voltage x-ray for hirsutism. Enthusiastic treatment of chronic dermatologic conditions with x-ray also furnishes a number of such patients (Fig. 1). In recent years older children and adolescents who were treated by radium in infancy for hemangiomas are also being seen with precancerous radiation dermatoses. These latter patients constitute an imperative indication for excision and skin graft as prophylaxis against cancer, as eventual malignant transformation of such areas is almost inevitable, due to the patient's greater life expectancy.

SURGERY IN SPECIFIC TYPES OF SKIN CANCER

Melanoma.—Malignant melanoma when still operable is an absolute indication for surgical treatment. These tumors are almost all completely resistant to radiation, and radical surgery is the only method of therapy available. These lesions should be excised widely and deeply without regard to subsequent cosmetic effect. The underlying fascia should always be included in such a removal. If, as occasionally happens, a supposedly benign nevus is excised and turns out to be melanoma, an immediate re-excision should be done if there is any doubt about the adequacy of the original surgery. Malignant melanoma usually metastasizes first to its regional nodes, except in the hopeless fulminating cases where explosive metastases seem to occur simultaneously throughout the body. In operable melanoma the regional nodes may be handled in one of three ways. If the primary lesion is close enough to the regional nodes, these may be removed with the primary as an en bloc dissection, an operation for which the term "excision and dissection, in continuity" has been coined (Fig. 2). This conforms to the ideal concept of extirpative cancer surgery, a principle which the present day radical mastectomy exemplifies. In such an operation the primary lesion, the majority of the direct lymphatic pathways, and the regional nodes are removed in one piece, with all contained tumor cells

and emboli. Such an operation is ideal whether or not the regional nodes are clinically involved. If the primary lesion is too far away for such a procedure the nodes should be removed at the same time or shortly thereafter if they obviously contain metastatic tumor. If the nodes are not clinically involved the best practice today is to wait six to eight weeks after the primary is excised and then do a radical dissection of the

Fig. 1.—Late radiation effect on skin from low-voltage x-ray administered during adolescence for Acne.

regional nodes (Fig. 3). The theoretical advantage of this maneuver is that it allows tumor cells already in the lymphatics to reach the regional node filter. That this is more than a theoretical consideration is shown by those patients who develop numerous minute skin metastases along the lymphatic pathways when uninvolved nodes have been removed separately but simultaneously with the primary lesion. In contrast to the problem of node involvement from squamous cancer

it is believed justifiable to perform prophylactic node dissections in patients with melanomas. Adequate statistics are not available to show the percentage, but it is the general opinion that metastases from

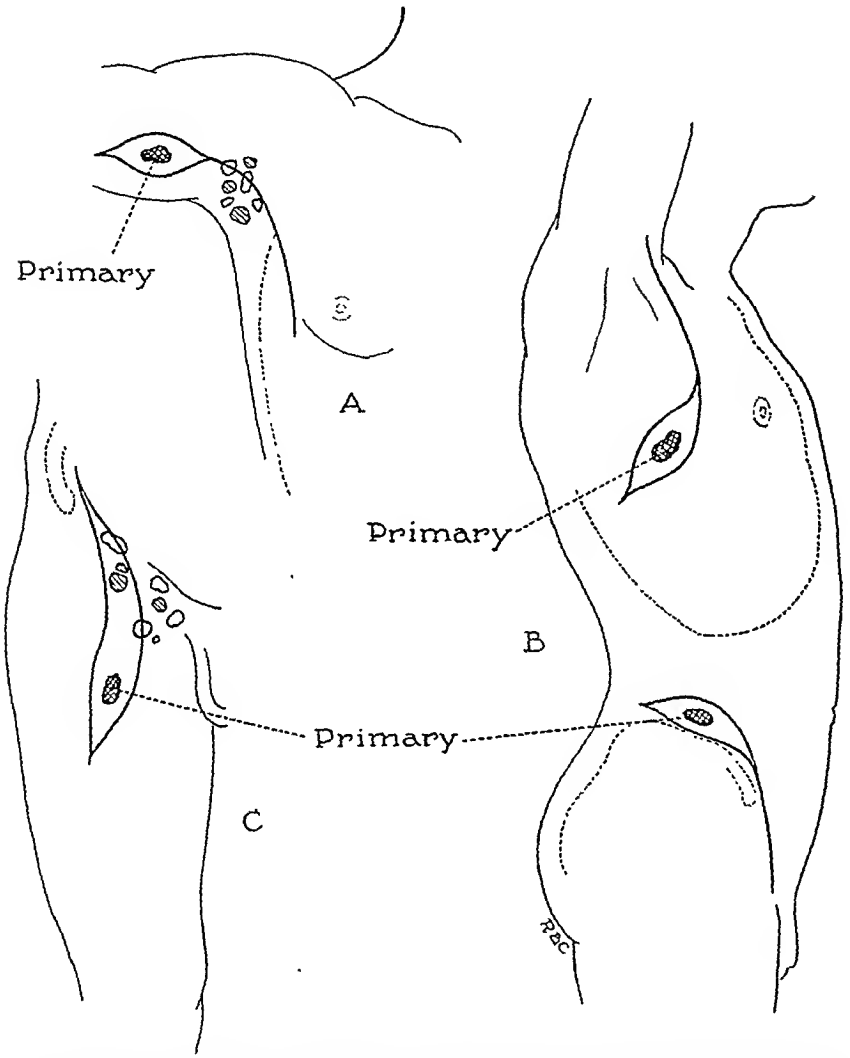

Fig. 2.—Illustrating a few possibilities of the operation of "excision and dissection in continuity." In these diagrams the primary lesion is so situated that it can be removed, along with the regional nodes and their intervening lymphatics, with one continuous incision. Such an operation may have an infinite number of anatomic variations and is suitable whether or not the regional nodes contain metastatic disease.

melanoma are found much more often when dissections for clinically uninvolved nodes are done, than is the case with squamous lesions.

Residual or Recurrent Disease.—In spite of the radiocurability of most squamous and basal-cell cancers of the skin, the occasional radiation failure presents a perplexing problem. Residual disease, that is, viable

cancer remaining in an area that has been treated to the limit of tissue tolerance, presents two alternatives, either surgical removal or further irradiation with resultant radionecrosis. This last course defeats the original indication for the use of radiation, and in most instances should not be followed (Figs. 4, 5, and 6). It should be noted that the diagnosis of residual disease must not be made for some time after treatment is finished, as continued regression of the tumor may take place for eight to twelve weeks after the acute reaction in normal tissues has occurred

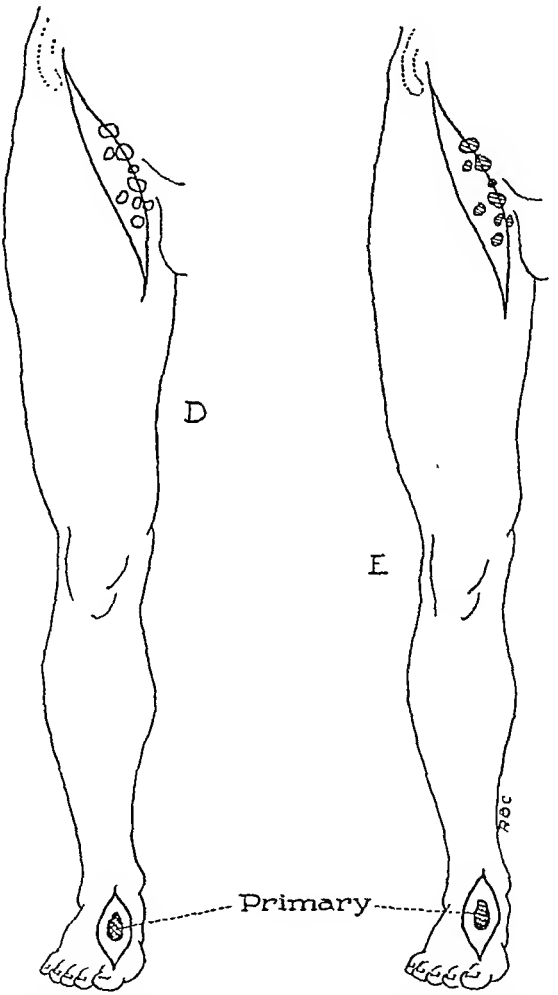

Fig. 3.—Illustrates the problem presented when the primary lesion is too far removed from its regional nodes to remove them and the intervening lymphatics through one incision. *D* illustrates the situation when the nodes are not clinically involved. Here the nodes should be removed by radical dissection six to eight weeks after the primary is excised, the time interval allowing the lymphatics to empty any tumor cells into the regional node filter. *E* illustrates the situation when the regional nodes obviously contain metastatic disease. These must be removed as soon as possible and usually simultaneously with the excision of the primary lesion. Here the patient and surgeon must sacrifice the possibility of further lymphatic metastases for the expediency of removing those already present.

and healed. Once the existence of residual disease has been established, however, recourse to surgery is usually the wisest choice. A wide excision of the entire area should be done and the defect repaired with a full thickness or a thick split-skin graft. Recurrent disease is actively growing cancer, arising, of course, in a focus of unrecognized residual disease. It is simply a further stage of the other, and should be treated in the same way and for the same reasons. The indication for the use of surgery in these conditions is a relative one, depending largely on individual circumstances. For a small focus of residual disease situated well below the skin surface, interstitial radiation in the form of gold radon seeds may often complete the tumor regression. In general, however, surgical excision with immediate or delayed grafting is preferable.

Fig. 4.—Illustrates a patient with squamous carcinoma inadequately treated by irradiation. The tissues will not now tolerate a complete cancericidal dose, which is necessarily more than that originally given, and the problem now is one of a mutilating surgical procedure along with excision of the neck metastases.

Radiation Cancer.—Carcinoma arising in skin that is atrophic and telangiectatic as a late result of radiation is almost invariably a surgical problem. In the first place, such a tumor is usually squamous carcinoma, and as such is relatively radioresistant, requiring a high dosage to kill it. In the second place, the tumor bed and surrounding tissues, already damaged by radiation, will not tolerate cancericidal doses of roentgen or gamma rays. In the third place, these lesions are frequently located on the fingers and hands, areas which tolerate radiation poorly because of the close proximity of bone. If a biopsy of a radiation cancer shows

the tumor to be a spindle-cell variant of squamous carcinoma, the indication for surgery is absolute. Martin and Stewart[1] state that spindle-cell epidermoid carcinoma is practically incurable by radiation, and such a tumor should always be attacked surgically. Spindle-cell carcinoma may be found in radiation cancer, as a metaplastic phase of radiated and recurrent squamous carcinoma, or occasionally as an ex-

Fig. 5.

Figs. 5 and 6.—Illustrate the preoperative and immediate postoperative condition of a patient who had been treated for twelve years by repeated inadequate doses of radium. The outer table of the skull and the roof of the frontal sinus had to be removed. Actively growing basal-cell carcinoma was invading the orbit.

pression of the carcinogenic effect following chronic arsenic poisoning or long-standing psoriasis. Whenever it is encountered it should be treated by surgical methods if feasible and not by radiation.

Burn Scar Cancer.—Epidermoid carcinoma rising in old burn scars presents a specific problem quite distinct from the ordinary occurrence of skin cancer. It originates on a fibrotic, relatively avascular tissue bed whose lymphatics are few in number and functionally distorted. The tumor cells themselves ordinarily are so highly differentiated that they may closely resemble normal mature squamous epithelial cells, and thus histologically would be classified as radioresistant. Burn scar cancer

usually is indolent and tends to metastasize late, but it is very stubborn in response to treatment because it tends to recur locally. Patients with these tumors frequently give a history of repeated excisions with recurrence in adjacent areas. This is thought to be a result of the disruption of lymphatic pathways in the scarred tumor bed, with a consequent atypical metastatic pattern. Such a tumor is a surgical problem because it not only requires a high dosage of radiation to sterilize it, but also because it grows in a tumor bed of avascular scar tissue that will not tolerate cancericidal doses of the order needed. When excision of such a lesion is done, it must be carried much wider than is necessary

Fig. 6.—For legend see opposite page.

for the usual skin cancer because of this tendency of burn scar lesions to recur in nearby sites. Ideally, the entire scar and tumor should be excised and the area covered by a split-skin graft. This is, of course, frequently impossible because of the size of the area involved by many burn scars. The entire thickness, at least, of the scar should be removed under the lines of incision. The extent of excision required in these lesions is another contraindication to radiation therapy, as a cancericidal dose of x-ray could not be delivered over such an area, even through normal skin.

CONSIDERATIONS OF ANATOMIC LOCATION AND EXTENT

Scalp.—Most small or medium-sized squamous and basal-cell cancers of the scalp are best treated by radiation. However, the occasional large and deeply ulcerating lesion is best treated by wide surgical excision and immediate skin graft. This is because destruction of such a tumor by radiation may expose the underlying bone which has been partially devitalized by the radiation. Severe osteomyelitis of the skull may en-

Fig 7.—Patient with sequestration of the skull following intensive irradiation of a large, ulcerating basal-cell carcinoma of the scalp The floor of the defect is the exposed dura

sue, or, at the least, osteoradionecrosis with sequestration of the irradiated area (Fig 7). Exposure by surgery of healthy, nonirradiated bone is not necessarily serious and can easily be repaired by skin grafting. If the galea or periosteum is removed an immediate thin split-skin graft may be made to grow on the exposed bone without waiting for drilling and formation of granulations It is certainly worth while attempting such a procedure as the chance of loss of such a graft is much

less of a problem to the patient than the three to six weeks required by the maneuver of drilling and waiting for granulations. If the primary graft takes, the procedure is finished. If it does not the patient has lost nothing but a few days, as the donor site of a split-skin graft restores itself very completely.

Ears.—Cancer of the skin of the auricle is as easily cured by radiation as skin cancer anywhere else, but because of the proximity of the cartilage to the surface, ulceration and nonhealing are frequent occurrences. Primary excision of these lesions, with or without a "V" removal of the cartilage, usually results in a better cosmetic effect in spite of the surgical defect. Long-continued ulceration following irradiation, or eventual sloughing, are far more trying to a patient than simple excision and primary healing of healthy tissues. Radionecrosis, furthermore, often requires more extensive surgical procedures than would have been necessary by surgical excision in the first place. The larger the lesion, or the deeper it extends, the more imperative is the indication for surgical attack. Many radiologists refuse to treat such lesions after experiences with chronic perichondritis or chondronecrosis.

Midline Lesions.—Cancer of the skin occurring in the midline of the body is better treated by surgery than radiation, the reason being that the blood supply is least in this area. Tissue recovery following irradiation is directly dependent on the blood supply to the region treated. These considerations do not apply to the face, scalp, or perineum, where the blood supply is excellent, and therefore lesions falling in this class are quite rare.

Cancer in Skin Adjacent to Bone.—Carcinoma of skin overlying a bony prominence is better treated by surgery than by irradiation for two reasons: first, the blood supply to the integument is usually less in such areas; second, bone is easily damaged by radiation, and, being close to the skin surface, receives a high tissue dosage when radiation therapy is given.[2] These conditions tend to delay healing, and lead to late radionecrosis and breakdown (Figs. 8 and 9). Such vulnerable areas of skin are found on the hands and feet, over the malleoli, and over the anterior aspects of the tibiae. It has long been known that irradiation of the fingers or the dorsum of the foot is a dangerous practice, and this is almost equally true of the metacarpal area. The disastrous late results of accidental irradiation occurring in the hands of radiologists and surgeons are effects of comparatively low doses of radiation. The full cancericidal doses required to sterilize the squamous carcinomas found in these regions are even more destructive. In many patients so treated, surgical procedures necessitated by the late results of radiation would be simpler both to the surgeon and the patient if they had been done in the first place.

Perineum.—Cancers of the skin of the anus, vulva, scrotum, or penis are more suitable to surgical treatment than irradiation, because the skin

of these regions tolerates radiation poorly. This skin is more moist than other areas in the body and maceration occurs early during radiation therapy, thus making the reactions more intense, and thereby limiting the total dose that can be given. For the same reasons the late effects of radiation are far more distressing to the patient than is usual for

Fig. 8.

Fig. 9

Figs 8 and 9.—Radionecrosis through the hand with gangrene of the fingers following irradiation of a carcinoma of the palm eight years previously. There is no tumor present in the lesion.

drier regions. Ulceration and infection occur more commonly, and a patient with radiation dermatitis about the perineum may be permanently miserable. Lesions of the vulva or scrotum lend themselves readily to surgery because of the ease of repair in redundant tissues, and because of excellent blood supply. The scrotum, furthermore, is a poor site for irradiation from the standpoint of damage to the contained testicles. Cancer of the skin about the anus deserves special consideration, because, if surgical treatment requires a permanent colostomy and posterior resection, or even rectal incontinence, the disadvantages of radiation must be balanced against these factors. Such a situation, however should not influence the physician to attempt the impossible with radiation. Cancer of the penis is almost invariably best treated by surgical measures. In this connection it should be noted that circumcision in infancy or childhood is practically 100 per cent prophylactic protection against the later development of cancer in this organ.[3]

Skin Cancer Invading Bone or Cartilage.—It is practically impossible to cure squamous or basal-cell cancer invading bone or cartilage by irradiation. Such lesions on the extremities, when very large in extent, require amputation. Pack and Livingston[4] list the indications for amputation in patients with extensive skin cancer of the extremities as follows: (1) hemorrhage caused by erosion of a large vessel; (2) when the interior of a large articulation is exposed; (3) when the cancer has invaded so deeply and become so adherent that excision is impossible; (4) when large areas of bone are exposed, resulting in necrosis; (5) when uncontrollable suppuration of the wound is complicated by fever and toxemia; (6) when the functional result, even after a presumptive local cure, would be unsatisfactory, the limb becoming an encumbrance.

CANCER COMPLICATING SPECIFIC SKIN DISEASES

Squamous and sometimes basal-cell carcinoma occurs as a complication or result of certain skin diseases, notably in xeroderma pigmentosa, acrodermatitis chronica atrophicans, and rarely as a late result of lupus vulgaris and lupus erythematosis. Patients with xeroderma pigmentosa usually present impossible therapeutic problems, and they commonly die in early adult life of multiple skin cancers. These tumors are a result of the action of actinic rays on the damaged skin, and as such are not suitable for treatment by further radiation. They therefore are surgical problems, although only in a palliative way. Cancer arising in lesions of acrodermatitis chronica atrophicans should be treated by surgical excision because the atrophic skin will not tolerate cancericidal doses of radiation. The same considerations apply to cancer arising in skin which has been the site of lupus vulgaris or erythematosis, although to a lesser extent. Decision as to treatment in this latter situation depends upon the degree of skin damage resulting from the previous disease.

of these regions tolerates radiation poorly. This skin is more moist than other areas in the body and maceration occurs early during radiation therapy, thus making the reactions more intense, and thereby limiting the total dose that can be given. For the same reasons the late effects of radiation are far more distressing to the patient than is usual for

Fig. 8.

Fig. 9.

Figs. 8 and 9.—Radionecrosis through the hand with gangrene of the fingers following irradiation of a carcinoma of the palm eight years previously. There is no tumor present in the lesion.

section of node metastases from skin cancer in general, two conditions are necessary: one, the primary lesion must be controlled, or be removed simultaneously; two, the nodes must be operable. Quixotic attempts at removal of huge masses may be useful from a palliative standpoint, but they are not curative. Bilateral metastases to the neck, groins, or axillae from midline skin lesions are not contraindications to dissection if the lesions are operable. Bilateral dissections should be done when bilateral metastases are present, because nothing else affords the patient an equal chance in such a situation.

SURGERY AS AN ADJUNCT

The use of surgery and radiation combined as complementary methods has little place in the treatment of skin cancer in general. It is no more reasonable to use "postoperative irradiation" after surgical removal of a malignant skin tumor than it would be to do a little surgery after adequate irradiation of such a lesion. Surgery may be employed to advantage, however, in the everting or polypoid lesions, as an adjunct to irradiation. Radiation may be used much more effectively in such situations if the main bulk of the tumor mass is first removed surgically, preferably by the endotherm knife or actual cautery. The tumor bed may then be exposed to a much higher tissue dose of radiation than would be possible if the same amount of radiation were filtered through one or several centimeters of overlying tumor tissue.

DISCUSSION

From this account it may seem that surgery has been advocated as the treatment of choice for most skin cancers. Careful study, however, will show that these indications are not concerned with the great majority of skin cancers, but in reality affect a relatively minor group. Melanoma, fortunately, is not a common disease, nor is burn scar cancer or xeroderma pigmentosa, and most of the other lesions listed.

In such a discussion as this the contraindications to surgical treatment should be considered. Obviously, surgical measures can be made to cure any skin cancer that radiation can cure, and also some others that cannot be controlled by radiation. However, when radiation is used by an expert, it will produce a better cosmetic result and cure the lesion more simply than will surgery, with the exceptions as discussed in this communication. In this connection it should be stated that most authors believe that early carcinoma about the eyelids should be treated by radiation, cancer in this location being considered a contraindication to surgical treatment. Again it must be emphasized that irradiation by skilled therapists is referred to, and not the casual use of radium or x-ray by someone not thoroughly familiar with this field. Serious damage to the eye, particularly the lens, may result from injudicious irradiation of this area. When a cancer of the eyelid has invaded the

REGIONAL NODE METASTASES

In one sense the treatment of metastatic nodes in patients with skin cancer is of more concern than treatment of the primary lesion. In the first place, skin cancer usually kills by its metastases rather than by the local effect of the primary lesion, differing in this respect from some other tumors, such as untreated cancer of the larynx or esophagus. In the second place, most skin cancers can be fairly easily cured at the primary site by any of several means, as stated before.

The question of the treatment of regional node metastases from squamous cancer has been repeatedly discussed from many angles. The majority of the opinions today seems agreed on the following premises: that prophylactic dissection of regional nodes is not only unnecessary, but may actually be harmful; that the treatment of operable metastatic cancer in nodes should be surgical and not by radiation. Prophylactic regional node dissection, i.e., where metastasis is not demonstrable, has been shown conclusively by Martin[5] and Duffy[6] to be a waste of time in most patients with squamous carcinoma of the lip, mouth, and pharynx. The same reasoning and conclusions are equally applicable to squamous carcinoma of the skin. That prophylactic dissection may be harmful is illustrated by those patients who develop inaccessible metastases, because of diverted lymphatic flow, sometime after node dissection. The regional lymph nodes act as a temporary filter for tumor cells loose in the tissue lymphatics, and they will hold them in check until the tumor destroys the node and breaks through the capsule. When a node becomes blocked by tumor cells, local diversion of lymphatic flow occurs, and thus successive adjacent nodes become involved, by collateral flow. This is why it is futile to do a local excision of a solitary involved node. Whenever surgical extirpation of a regional metastatic node is done, the operation must be radical, removing the entire node bearing area by an en bloc dissection.

The use of radiation in the treatment of node metastases from skin cancer either should be confined to palliative therapy for late and inoperable lesions, or should be used as a delaying action, as it were, in holding in check cancer in regional nodes while the primary lesion is either being definitively treated by radiation or prepared for excision. This latter course is only an expediency to delay growth of metastases until regional dissection can be done. Metastatic squamous cancer in nodes can be cured occasionally by roentgen or gamma radiation, but in too small a percentage of cases for this form of therapy to be seriously considered as an equal alternative to radical regional node dissection in operable cases.

The types of neck dissection for cervical metastatic cancer have been described recently by Martin,[5] and the operation of radical groin dissection has been redefined and elaborated by Pack and Rekers.[7] For dis-

Recent Advances in Surgery

CONDUCTED BY ALFRED BLALOCK, M.D.

RECENT ADVANCES IN THE TREATMENT OF PERIPHERAL ARTERIAL EMBOLISM

ROY D. MCCLURE, M.D., F.A.C.S., AND
HENRY N. HARKINS, M.D., F.A.C.S., DETROIT, MICH.
(From the Division of General Surgery, Henry Ford Hospital, Detroit)

THE treatment of arterial embolism is a subject of considerable practical importance. The condition is not rare and the results without therapy are poor indeed. Griffiths (1938) found that 87 per cent of the patients not operated upon were dead within a fortnight and all the remainder required major amputations. The treatment of this condition is not simple and if anything is to be accomplished at all it should be done promptly. In addition to several forms of therapy in use for some years, the recent introduction of several newer modes of attack upon this most serious of conditions furnished the opportunity of a reappraisal of the entire question. The following article attempts to correlate past experiences in the treatment of acute embolic arterial occlusions with the present status of the newer forms of therapy.

HISTORICAL

Severeanu (1894), professor of surgery at the University of Bucharest, is the first who recorded attempts at embolectomy. This author was apparently fully acquainted with the predilection of localization of emboli at the bifurcation of vessels and with their essentially cardiac origin. He did not use his method, however, to make a complete cure, but to preserve the vitality of amputation stumps, essentially of the lower limbs. He would amputate close to the level of gangrene in embolic cases and then insert an oiled catheter up the proximal stump of the occluded artery. In many cases a clot would come away and not only would the reopened artery bleed, but "l'hémorrhagie capillaire est devenue plus abondante et les tissus prirent une couleur plus vive." Healing by primary intention usually occurred in these cases.

The first real attempt at removal of an embolus by arteriotomy was made by Ssabanejeff (1895). This author unsuccessfully tried to remove an embolus from the femoral artery in a case of embolic threatened gangrene of one leg in a 28-year-old woman with rheumatic fever

structures of the orbit, then the contraindication to surgery is reversed, and the orbit should be exenterated.

Each problem in skin cancer should be treated on its own merits, and requires individualization in judgment and technique. Only broad generalizations can be made about any form of treatment and the specific details of each case must be considered separately in outlining a treatment plan.

SUMMARY

Both surgery and radiation have special advantages in the treatment of certain types of skin cancer. In this article the phases of malignant tumors of the skin which are best suited to surgical attack are discussed. They have been considered in the following order:

1. Prophylaxis: moles and postradiation keratosis.

2. Surgery in specific types of skin cancer: melanoma, residual or recurrent disease, radiation cancer, and burn scar cancer.

3. Considerations of anatomic location and extent: scalp, ears, midline lesions, cancer in skin adjacent to bone, perineum, and skin cancer invading bone or cartilage.

4. Skin cancer complicating specific skin diseases: xeroderma pigmentosa, acrodermatitis chronica atrophicans, and lupus vulgaris and lupus erythematosis.

5. Regional node metastases.

6. Surgery as an adjunct to radiation.

REFERENCES

1. Martin, H. E., and Stewart, F. W.: Spindle Cell Epidermoid Carcinoma, Am. J. Cancer 24: 273-298, 1935.
2. Slaughter, D. P.: Radiation Osteitis and Fractures Following Irradiation, Am. J. Roentgenol. 48: 201-212, 1942.
3. Cole, W. H., and Elman, R.: Textbook of General Surgery, ed. 3, New York, 1941, D. Appleton-Century Company, Inc., p. 1020.
4. Pack, G. T., and Livingston, E. A.: Treatment of Cancer and Allied Diseases, Vol. 3, New York, 1940, Paul B. Hoeber, Inc., p. 2066.
5. Martin, H. E.: The Treatment of Cervical Metastatic Cancer, Ann. Surg. 114: 972-986, 1941.
6. Duffy, James J.: Cervical Lymph Nodes in Intraoral Carcinoma: Surgery or Irradiation? Am. J. Roentgenol. 39: p. 767-777, 1938.
7. Pack, G. F., and Rekers, P.: The Management of Malignant Tumors in the Groin, Am. J. Surg. 56: 545-565, 1942.

(1941), Pratt (1942), and Lesser (1943). The book of Haimovici (1937) on *Les embolies artérielles des membres* which is 336 pages long is the largest work extant exclusively devoted to this subject.

DIAGNOSIS

The essential features in the diagnosis are the sudden onset of pain, usually in one of the lower extremities, with blanching, loss of sensation, and loss of local heat. Generally, except in aortic cases, the circulation to the opposite extremity is fairly competent. Bull (1921-1922) found 181 instances of parietal cardiac thrombi in a series of 6,140 necropsies, testifying to the frequency of this condition and the resultant dangers of embolism. Garvin (1941) also discussed the importance of the presence of mural thrombi in the left side of the heart in the causation of peripheral embolism. Danzis (1933) also pointed out that the origin of most of the emboli is from the heart and that the most common site for lodging is one of the femoral arteries. In Key's statistics (1921-1922), the left arm and left leg were involved more than the right. Forty-one of 46 cases of arterial embolism observed by McKechnie and Allen (1935) occurred in cases of heart disease. In the diagnosis of arterial embolism, Edwards (1941) outlined the differentiation from nonarterial disorders which simulate disease of the peripheral arteries. DeTakats (1936) pointed out that in some of his cases of peripheral arterial embolism pain was entirely absent. In the diagnosis, oscillometry and arteriography are useful in localization. Haimovici (1937) especially advised arteriography. Nordentoft pointed out that the downward thrust of the embolus itself may be confused with the arterial pulsation and that the embolus actually lies a little higher than the lowest palpable pulse. In speaking of the disappearance of the pulse (asphygmia) Haimovici (1937) stated: "l'absence du pouls, de règle dans les embolies artérielles, constitué un des meilleurs signes cliniques." This author also recognized the importance of Nordentoft's sign, pointing out that the pulse may be felt in some cases several centimeters distal to the obstruction due to a pulsation transmitted by the clot itself. Pulsation of the artery below the embolus has also been noted by Deitch (1936), Griffiths (1938), and by one of us (H. N. H.) in several personal cases. Deitch and Griffiths stated that such a pulsation preoperatively has no connection with prompt return of the distal pulse after surgery. Heanley (1939) also noted the thrusting type of impulse felt in an artery just below an embolic obstruction. In his two cases this occurred in the femoral region.

Haimovici (1937) pointed out that pain comes on as a veritable *coup de fouet*. Its sudden appearance and violent character constitute a major symptom of arterial embolism. It is probably due to reflex spasm rather than to direct irritation from the embolus.

and ulcerative endocarditis. Key (1921) stated that Ssabanejeff did not find the embolus. The patient agreed to amputation and it was done lower down and the wound in the vessel was sutured. Death occurred nineteen days later and necropsy revealed that the vessel was patent at the point of suture.

Moynihan (1907), of Leeds, removed a popliteal embolus and the patient died four days later. Handley (1907) attempted an iliac embolectomy but could not remove the clot. Stewart (1907), of Philadelphia, did a femoral embolectomy which almost was successful. An embolus at the bifurcation of the common femoral artery was removed thirty-six hours after lodging in the presence of gangrene of the foot. Pulsations reappeared down to the knee and gangrene was limited to the calf and below. Amputation at the level of the tibial tubercle was performed on the forty-second day. Lilienthal (1907) suggested the use of end-to-end arteriovenous angiorrhaphy for peripheral arterial embolism, but naturally this operation was not widely adopted. John B. Murphy (1909) did a femoral embolectomy but had to amputate the leg. Lejars (1902) removed an arterial thrombus. Twelve embolectomies were done in all before Georges Labey did the first successful one in 1911.

The first successful embolectomy was performed by Georges Labey on Nov. 16, 1911 in the Hôpital Saint-Antoine, Paris, and reported by Mosny and Dumont at a meeting of the Academy of Medicine of Paris a month later. The patient, a man aged 38 years, with mitral stenosis, was operated upon by Labey under local anesthesia six hours after the lodging of a left femoral embolus. The clot was removed directly through an incision in the artery 1 cm. long and after suturing, the vessel circulation returned. The next day, thirty-six hours after the operation, pulsations were felt distinctly in the posterior tibial artery and at the time of reporting, thirty-three days after operation, the patient was improved and the left leg was entirely well. A year later, in 1912, Einar Key of Stockholm did the first of his series of seventeen embolectomies on fifteen patients reported in 1921 to 1922. Reviews of the literature are given by Key (1921-1922), quoting thirteen successes out of forty-five cases; Jefferson (1925) quoting twenty-eight successes out of seventy-three cases; Petitpierre (1928) quoting thirty-four successes out of 118 cases; and Key (1929) quoting approximately eighty-six successes out of 216 cases. Key's article in 1921-1922 is the classic in the field of embolectomy and so great has been his influence that of the 216 cases collected to the end of 1927, 145 were done in Sweden. American and English reviewers agree on the preponderance of Swedish cases and Pemberton (1928) stated that up to 1928 only twenty cases were reported in the United States and Canada. Recent reviews include those of Lahey (1926), Reid and Andrus (1927), Andrews and Harkins (1932), Pearse (1933), Danzis (1933), Linton

was followed by continuous drip heparin administration. Some papaverine was given postoperatively, but no papaver was used.

The paravertebral injections caused no improvement in the coldness of the foot or leg, so a femoral incision was made and the femoral artery explored with the finger down into Hunter's canal without opening the artery. A good pulsation could be felt, therefore this wound was quickly closed without drainage and the patient was turned on her face.

A popliteal vertical incision was made, coming down on the popliteal artery. We found that it was distended, hard, and nonpulsating. A longitudinal incision was made, 1 cm. long. This revealed a nonadherent clot. The clot extended upward three to four inches into Hunter's canal and after cleansing out the upper end, no definite embolus could be found, merely an extension of the clot, and a good pulsatile blood stream occurred. Milking the clot from below the site of incision in the artery, we found that all three branches of the popliteal artery were full of these clots. The anterior tibial artery was cleansed to where it perforated the intermuscular septum. The posterior tibial artery was found to be very hard with evidently a thick wall and incision ½ cm. long made in it, and a definite communication made between the two incisions. The peroneal artery seemed to be better in nature than the posterior tibial, but it could only be cleansed down several inches. Thus, the whole system seemed to be riddled with these clots, which all had the same appearance. The vessel walls were sclerotic and involved, and it was decided that this was a thrombotic process rather than an embolic one. The clots which were removed are shown in Fig. 1.

Fig 1—Popliteal thrombus of H Ba., Case 1.

However, two inches below the branching of the peroneal artery, all three branches were cleansed and a pulsation of all three branches was obtained. The lower incision was sewed up with a single row of interrupted fine white silk and the upper incision was sewed with a double row of continuous fine white silk. Then, 4 c.c. of heparin were injected into the artery and definite pulsation continued. However, this did not extend down much beyond the level of the wound. The blood did not seem to be flowing through The wound was closed without drainage. The appearance of the leg afterward was not much different than at the onset. Continuous heparin injection was advised and papaverine kept in reserve.

Anesthesia for the procedure consisted of spinocaine 1.75 c.c. expanded to 4.0 c.c. The spinal anesthetic was given shortly after the paravertebral injection. The patient left the operating room in fairly good condition. The leg did not improve in

Premonitory signs of embolism are vague and are probably due to breaking off of small embolic fragments before lodging of the main clot. Movement of the main clot from a straddle position to a more obstructive one may account for some of the symptoms noted. In most cases the reflexes are weakened or abolished and sense of position is absent. Haimovici (1937) quoted Gallavardin and Contamin, Achard, Leblanc and Rouillard, Seneert, Ravault, Langeron, and others as observing that the onset is not always rapid but may be slow and progressive.

Oscillometry.—This method has been used by Haimovici (1937) and others. It essentially is a more delicate method of noting where the arterial pulse becomes weaker or disappears. Haimovici points out that there are three zones: normal pulse, diminished pulse, and absent pulse. The obliteration is often at the proximal end of the middle zone.

Another useful test is the reactive hyperemia ring test of DiPalma, Muss, and Foster (1942) which may prove of value in the differential diagnosis of peripheral arterial embolism.

Local Hypothermia.—Haimovici (1937), as well as others, has pointed out the importance of decrease in local temperature after lodging of an embolus. This is not only objective, but subjective. In advanced cases one finds a typical *froid cadavérique.* Ipsen (1931) believes that a temperature difference of 1° C. between two extremities indicates a pathologic condition and the greater the difference, the more serious the ischemic condition. Antonioli stated that there is often a hyperthermic zone at the upper level of the ischemic region and that observation of this will indicate the level of gangrene.

Nervous Changes.—Aside from those listed above, Haimovici pointed out that there is often a loss of voluntary motion. Generally the loss of sensation does not extend as high as does the discoloration and coldness. Deep sensation is occasionally exaggerated, but in general decreases in proportion to the loss of superficial sensation.

Differential Diagnosis.—In this respect, several conditions which are not benefited by operation should be particularly considered. These include especially arteriosclerosis with arterial thrombosis, as well as arterial spasm, thrombophlebitis, and Buerger's disease. An example of such a faulty diagnosis is demonstrated by Case 1.

CASE 1.—H. Ba., a widow, aged 74 years, with a history of arteriosclerosis and hypertension of several years' duration was noted to have auricular fibrillation in January, 1941. She was admitted to the hospital for several days at this time. Eight days afterward, on Feb. 9, 1941, she had sudden pain in the left leg, of acute onset with numbness. She came to the hospital two days later at which time there was coldness and duskiness of the left foot. Immediately after admission she was seen and although thrombosis on an arteriosclerotic basis was considered most likely, embolism could not be ruled out.

Exploration of the left popliteal artery was performed under spinal anesthesia by one of us (H. N. H.) after left paravertebral novocain injection, and operation

The chief means of preventing secondary thrombosis are (1) choice of early cases with normal vessel walls, and (2) the use of heparin in the vessel after closure of the arteriotomy wound.

Not only are secondary thrombi apt to occur (Schein, 1935), but other emboli are frequent. In fact, a good share of temporarily successful embolectomy patients subsequently die from other emboli.

Some years ago the senior author (R. D. McC.) analyzed two groups of cases of embolism and thrombosis. One of these groups (177 cases) was seen at the Johns Hopkins Hospital before 1916, and the other (46 cases) was observed at the Henry Ford Hospital after 1916. Of the entire group of 223 cases, 163 patients died and 60 recovered. Most of the cases were medical in nature, but some (about one-third) were surgical. The most common type of embolism was pulmonary (82 cases in the Johns Hopkins series and 15 in the Ford Hospital series). In the entire group there were 41 instances of femoral thrombosis or embolism, only 3 being called embolism. It is interesting that of 12 cases of femoral thrombosis in the Ford Hospital series, all but 2 were on the left side. There were 3 cases of aortic thrombosis and 1 of aortic embolism. Three cases each of brachial embolism and subclavian thrombosis were noted, while iliac and pelvic thrombosis (probably includes some venous cases) were noted 21 times.

The complication of pulmonary embolism occurring during an embolectomy (that of the common iliac artery) as described by Crowe (1942) is unique. It is well known that many patients with peripheral embolus later die of pulmonary emboli. Therefore, this accident occurring during operation is not so surprising as it would seem at first glance.

Concurrent Venous Thrombosis.—Haimovici (1937) made an extensive analysis of this problem, as a concurrent venous thrombosis occasionally is noted associated with arterial embolism as in our Case 2. Haimovici concluded that extension of the thrombus intravascularly in continuity is not the chief item in these cases. The important factor is, he decided, a transverse propagation by contiguity. This accentuates once more the importance of the adventitia in these cases. It not only conditions the noxious vasomotor reflexes in these cases but also increases the hazard of associated venous lesions. Our Case 2 furnishes supportive evidence for this theory of Haimovici's, as there was so much periarteritis present that separation of the popliteal artery and vein were extremely difficult.

CASE 2.—D. B., a married woman, aged 78 years, with arteriosclerotic heart disease, auricular fibrillation, and arterial hypertension was admitted with a history of sudden pain in the right foot beginning twenty-four hours before with rapidly developing signs of arterial obstruction. Despite the fact that arterial thrombosis seemed likely, the possibility of embolism caused a decision for operation to be made which was performed by one of us (H. N. H.).

appearance and the heparin was discontinued on the fourth postoperative day because of bleeding from the popliteal wound. The general condition failed and definite gangrene was evident in the left leg. Death occurred two weeks after operation.

This case demonstrates the futility of arterial thrombectomy in a patient of this age. The operation was done in the belief that an embolus might be present, but this hope was not realized.

GENERAL CONSIDERATIONS

Collateral Vessels.—Collateral vessels have an especial importance in planning the operation of embolectomy. Finch (1934) reported a case in which he removed an embolus by the retrograde method with Key's probe. Immediately both ends of the vessel showed free bleeding, indicating opening of the collaterals. He tied the artery on both sides of the incision, and divided it, recovery ensuing. A colleague of his did the same, only in a case without bleeding from the distal end with disastrous results, indicating the importance of the collateral circulation. The procedure of trying to milk an embolus down without removing it has been suggested. Without knowledge of the collateral circulation, such a procedure is apt to be dangerous because even though the embolus moves from a critical position, there is no assurance that it will go to a safer one.

Secondary Thrombosis.—Extension of the original clot into side branches of the artery was discussed by Schmorell (1933), Girdlestone (1935), and Haimovici (1937).

True secondary thrombosis, however, denotes formation of a new clot, usually at the site of arteriotomy, and in the preheparin days was the chief hazard in embolectomies. Burnett (1939) reported a case of embolism of the brachial artery in which the artery was opened three times. Each time pulsations gradually ceased after about sixty seconds and on reopening, a new clot was found. Doberauer (1907) performed an axillary embolectomy fifty-two hours after the onset of the condition, extracting a clot 3 cm. long. Because of immediate rethrombosis he did an arteriovenous anastomosis with unstated results. Bérard (1909) did a temporarily successful embolectomy on the femoral artery, but secondary thrombosis occurred immediately, taking away from this author the honor of doing the first recorded successful case. Wreden (1913) removed an aortic embolus by retrograde sounding with a catheter but the next day recurrent thrombosis necessitated amputation. This whole subject is discussed by Nyström* (1936). In one of his cases, secondary thrombosis occurred twice, but with true patience, Nyström reopened the vessel twice, removing the clot, and the second time (third arteriotomy), he injected heparin with a perfect result.

*Page 25 of Reference 154.

words, it was definitely poorer than earlier in the procedure. Because of the patient's condition, we did not feel it advisable to explore the femoral artery. It was felt that the embolus itself was palpated in the bifurcation of the femoral artery (see Fig. 2).

Because of the patient's condition and age, we decided to do an arteriectomy, which was performed 1 cm. above the incision in the artery, downward, including the two uppermost branches of the popliteal artery. We also noted at this time that there were definite clots in the popliteal vein and we decided to ligate this vein. This was done and the wound was then closed with interrupted silk for the fascia and interrupted skin silk without drainage. No local heparin was injected but the patient was to be started on continuous intravenous heparin.

At the close of the procedure, there was very little change in temperature of the leg as compared before operation, but it seemed to be definitely better than before the paravertebral sympathetic injection was done.

Despite the administration of heparin postoperatively, gangrene developed and the patient died on the eighth postoperative day. During the last few days of life, marked gangrene of the left (unoperated) leg was also present.

This case demonstrates again the futility of operation in a case of arterial thrombosis. An addition to the history, obtained from a relative after operation, showed that this patient had suffered from severe pain with icicle coldness in the right foot for eight weeks before operation.

Paradoxical Embolism.—Paradoxical embolism, through a patent foramen ovale into the heart, was discussed by Koritschoner (1936). Carling (1934) and Haimovici (1937) discussed peripheral emboli of such origin.

Multiple Emboli.—Multiple emboli have been reported by several authors, including Harkins (1934) and MacFarlane (1940).

SPECIAL EMBOLI

Emboli in certain locations require special treatment. Such individualization applies especially to the arm and to the aorta, as will be discussed. While the most common site of lodging of the embolus is the origin of the left femoral artery, other sites each have a special significance. Embolectomy of the popliteal artery apparently should be a simple procedure, but because of danger to the collateral blood supply about the knee, in actuality the procedure is fraught with more than ordinary risk to the extremity.

Arm.—The arm is one region where special indications for embolectomy exist. Lund (1937) showed that the local results following embolectomy in the arm are almost twice as likely to be successful as in the leg (86 per cent as opposed to 48 per cent respectively). The percentage of success as far as life is concerned, however, was little better in the case of the arm (43 per cent as opposed to 35 per cent). These figures are of necessity lower than the local results given above as they include the deaths as well. While patients with embolectomy in the arm were just as likely to die as those with it in the leg if not operated upon, in no case did gangrene result. Lund concluded, there-

Operation.—Examination of this patient revealed a sock-like discoloration of the foot extending up about five inches above the malleoli of the ankle. Just above the upper layer of this discoloration, there was an area of hyperesthesia and hyperalgia. The area of discoloration and sensory defect seemed to coincide. The patient could move her toes easily. Temperature curve was taken, a paravertebral injection was done on this right side, and 10 c.c. of 2 per cent novocain were injected into each of four needles placed two fingerbreadths lateral to the spine and two fingerbreadths deep to the transverse processes. A moderate temperature response occurred. The temperature of the right shin improved relatively 5° F., but the right large toe improved relatively only 2° F. The patient was then observed for about twenty minutes. In the absence of oscillometer, we took a blood pressure cuff and tested both legs. The fluctuation was rather marked in the left thigh and weakened in the right thigh. There was a moderate fluctuation at the left knee but none whatsoever at the right knee. To direct palpation the femoral pulses were both strong, whereas both popliteal pulses were not palpable. We decided to do a popliteal exploration.



Fig. 2.—Popliteal thrombi of D. B., Case 2, above; with segments of artery removed by arteriectomy, below. (Scale in inches.)

It is to be noted that, if we had followed the result of the oscillometer reading, we would have done a femoral exploration, which would have been better. The patient was explored in the popliteal region, using novocain anesthesia, through a vertical incision five inches long. Great difficulty was found in separating the popliteal artery and vein because of dense inflammation of the adventitia of the arteries and to some extent of the vein. The three branches of the artery were identified and just above them, the popliteal artery was opened by means of a vertical incision 1 cm. long. A clot was present. Palpating and milking the three branches caused some clots to pass and milking way up above in Hunter's canal by placing the finger up there caused a large amount of clot to come down followed by some blood. Exploration with the uterine probe and catheter also removed some clots, the upper portion of which was whitish and appeared somewhat like an embolus. However, we were not able to free the vessel completely and observation of the three branches indicated that there was a nest of clots in all of them. No blood came out from the peripheral end of the popliteal artery at any time. At the end of this exploration, the flow of blood from the popliteal artery was not noticeable at all. In other

with his entire series of 73 cases led Hesse to conclude that aortic emboli are commoner in men, aortic thrombi commoner in women. He favored an aortic approach for embolectomy and opposed retrograde probing. In the entire series, the mortality of the untreated cases was 92 per cent. In 52.2 per cent (also includes the thrombi cases) the patients lived a week at least, so that sudden death was rare. The aortic bifurcation was the site of the obstruction in 52.5 per cent of the cases. Hesse opposed simultaneous vena cava ligation.

TABLE I

INCIDENCE OF GANGRENE AFTER ARTERIAL LIGATURE

SITE OF LIGATURE	PERCENTAGE OF GANGRENE		
	WOLFF	HEIDRICH	MAKINS
Axillary	15.0	9.8	---
Brachial	4.0	3.1	---
Aortic	---	100.0	---
Common iliac	50.0	100.0	40.0
External iliac	11.2	13.4	16.6
Common femoral	25.0	21.8	25.9
Superficial femoral	12.7	10.4	14.1
Popliteal	14.9	37.2	32.5

Siegel and Garvin (1941) reported an unoperated case of thrombosis and embolism of the abdominal aorta with concomitant obstruction of the renal arteries and fatal issue. At the Cleveland City Hospital from 1930 to 1939, inclusive, they saw 9 such autopsied cases, in only 2 of which, however, was there renal obstruction. O'Shaughnessy (1934) also reported a case of aortic embolism, not operated upon, in which there was suppression of the urine in addition to the usual signs. Necropsy revealed the infarction had taken place at the level of the renal arteries. In Hesse's series (1921), 23.3 per cent of the patients had renal infarction.

The prognosis without operation is thus almost hopeless. Welch and Rolleston (1909) stated that three patients (reported by Gull, Chvostek, and Nunez) had survived without operation. Neuhof (1932) claimed to have seen a spontaneous cure. In all the remaining reported cases the patients have died, save two reported by Hesse (1921), who survived double amputations. In an extensive review, Hesse studied reports of 53 patients with aortic emboli, of which all but 4 died (96 per cent mortality). Mason and Warren (1931) collected 116 cases of aortic embolism, including one operative case of their own in which recovery did not take place. Griffiths (1938) collected 5 more cases from the literature and added 3 of his own, making a total of 124 cases. Of these, 28 patients were operated upon, 1 twice, with 9 successes in 28 operations. Of the 9 reported successes, 7 were operated upon during the first six hours. Patients with ligation of the abdominal aorta have lived one year (Matas, 1925) and three months (Brooks,

fore, that "no benefit is gained by such operations on the upper extremity." It is of interest that in Lund's entire series, of the 27 patients submitted to operation, 37 per cent were successful, while of 29 patients not submitted to operation, only 8 per cent were successful. Patients who did not have embolectomy nearly all died whether or not there was gangrene or amputation.

Graham (1937) reported 10 embolectomies performed at the Toronto General Hospital. Three operations done on the upper extremities were successful, but only 2 of 7 done on the legs led to improvement. Pearse (1933) also noted the much more favorable results in upper extremity cases. DeTakats (1936) agreed with Lund (1937) that embolectomy is seldom indicated in the upper extremity.

An illustrative case of upper extremity embolism is as follows.

CASE 3.—P. H., a man, aged 53 years, with known arteriosclerosis and arterial hypertension for at least two years, developed a coronary attack with auricular fibrillation. On March 7, 1943, he had a sudden pain with numbness in the left hand and arm. He was admitted to the hospital three hours later at which time pulsations could be felt in the upper but not in the lower portion of the brachial artery. The hand and forearm were markedly discolored, cold, and anesthetic. Because of the fact that the involvement was in the arm and because of the patient's desperate condition (Cheyne-Stokes respiration, râles at both lung bases, disorientation), embolectomy was decided against. Treatment included papaverine intravenously and stellate ganglion novocain block. The success of the block was attested by the development of an immediate Horner's syndrome. The gangrenous process remained constant and the patient died the next day, twenty-four hours after lodging of the embolus. At necropsy the left subclavian and brachial arteries were opened, revealing a recent embolus which extended from a point 2.5 cm. superior to the origin of the profunda brachialis downward for a distance of 11.5 cm. The embolus was essentially homogeneous throughout, there being no evidence of secondary thrombus formation. It was not adherent to the intima.

It was decided that the length of this embolus (11.5 cm.) blocked off the collateral vessels as well as the lumen of the brachial artery itself. This fact, plus the general extreme condition of the patient, contributed to the lack of improvement following conservative therapy.

Aorta.—Embolism of the aorta is one of the most serious of all types of peripheral arterial embolism. The bifurcation is involved in most instances. In Hesse's series (1921) of 42 aortic emboli in which the site was known, 25 were at the aortic bifurcation, 2 in the thoracic aorta and 12 in the abdominal aorta above the bifurcation. Of 49 unoperated cases of aortic embolism reported by Hesse (1921), 1 or possibly 2 recovered spontaneously. Hesse (1921) reported a case of aortic embolism and another of aortic thrombosis and collected 71 other such cases from the literature. Fifty-three of these cases were embolic in nature and of these, 36 were definitely of cardiac origin. A sudden onset was observed in 97.5 per cent of the embolic cases and in only 28.5 per cent of the thrombotic cases. Hesse also collected 14 cases of ligature of the aorta with 14 deaths (see Table I). Experience

11 common iliac, 6 external iliac). The cases treated by the milking method were more successful than those treated by retrograde sounding. This applied to the number of these difficult cases in which the embolus could be removed at the first attempt (10 of 13 in the milking cases, 3 of 9 in the sounding cases) and also to the frequency of secondary thrombosis (0 of 4 in the milking cases and 4 of 5 in the sounding cases). Finally, the long-term recoveries were much more frequent in the series treated by milking. It should be stated, however, that on further analysis of the series of cases, it is seen that the best results were obtained in those patients treated by milking after unsuccessful retrograde sounding.

The method of Nyström, "retroperitoneale Hinuntermelkung" or retroperitoneal milking down of the embolus, was first used by him in his clinic in Uppsala in 1923. By either cutting or freeing Poupart's ligament, the hand is introduced retroperitoneally until the embolus is felt and milked down to the femoral arteriotomy where it is removed. To prevent fragments coming down the opposite femoral vessel, it too should be opened and temporarily clamped off with a soft rubber tube. The embolus may be first crushed against the promontory of the sacrum. If embolic fragments escape into the hypogastric vessels, no harm is done. The femoral vessels, however, should be kept closed by rubber tube traction to prevent escape of embolic fragments into them. Nyström believes that retrograde probing should be used only in cases with undiseased arteries.

Nyström performed a successful embolectomy on the aortic bifurcation and nine months later, Westerborn did another embolectomy at the same site following which the patient lived five years, death resulting from uremia. Key (1936), Schmorell (1933), and Jefferson (cited by Griffiths, 1938) used the retrograde milking method of Nyström.

A collection of 19 cases of successful aortic embolectomy is shown in Table II. This table is based partly on Griffiths' (1938) collection of 9 cases, but as the case he lists by Hindmarsh and Sandberg (1936) is the same as his second case by Key (1922), his table should only include 8 cases. Nyström (1936) states that Crafoord (1933) did a successful aortic embolectomy, but we could find no other record of this case. Schmorell's patient, a 66-year-old man with a straddle embolus of the aorta following appendicitis, was cured for at least five weeks by embolectomy by Nyström's extraperitoneal milking from below. In this case the advantages of the extraperitoneal approach in the presence of peritonitis were manifest. Usadel (1932) used a long lumbaringuinal incision with a retroperitoneal approach. The similarity in shape of Bauer's (1913) and Drevermann's (1931) aortic emboli is noteworthy. Both were about 3 cm. long and consisted of a large crown or body with two roots, the crown lying in the aorta and the stubby roots in the two common iliacs. Key (1922) removed his embolus in five pieces.

1926). Experimental studies in ligation of the aorta by Brooks (1926) and by Brooks, Blalock, and Johnson (1928) revealed little, if any, change in the blood pressure in the artery proximal to the occlusion.

Griffiths (1938) collected 9 successful cases of aortic embolectomy. Haimovici (1937) found 9 such cases, including that of Gohrbandt which was not in Griffith's series. Griffith's case was included in a report of 8 cases of arterial embolism seen at the Manchester Royal Infirmary. In this article, Griffiths (1938) described the first successful British aortic embolectomy and also reported the first diagnosed case of carotid embolism. In his series of 8 cases he did 3 embolectomies with success. His single successful aortic case was, according to him, the ninth successful one on record.

Gohrbandt (1933) reported an additional successful case, as did Culmone (1938). Gohrbandt operated first on the left femoral artery, then opened the aorta. Lindgren's patient (1939) received heparin for nine days postoperatively. Murray (1941) reported two successful aortic embolectomies, heparin being used in conjunction with operation. Pratt (1942) reported an additional case of aortic embolectomy which was successful except that one leg had to be amputated at the knee. McMaster's (1939) two months' cure of aortic embolism following iliac embolectomy is too atypical to include in this series. This author reported that spinal anesthesia caused an immediate improvement in his patient. Walzel's case (reported by Kaps and Walzel, 1930-1931), was fortunate in that operation was done 40 minutes after onset. The patient was a man, aged 38 years, with endocarditis lenta. An abdominal approach was used and there was a good result with restoration of the dorsalis pedis pulse on both sides, but death occurred from the cardiac condition twenty-five days later. Necropsy revealed no local recurrence. Wikle and Cabot (1943) reported an aortic embolectomy performed four hours after the lodging of the embolus. The left leg was saved, but amputation of the right had to be performed two weeks after the original operation. Two weeks after this the patient died.

Groth (1939) concluded from a study of 46 embolectomies done at the Surgical Clinic, Uppsala, that in cases of embolism at relatively inaccessible sites (e.g., aorta, common, and external iliacs) the following rule should be adopted:

"Bei Operation von peripherer Embolie mit schwer zugänglicher Lokalisation soll in erster Linie retroperitoneale Hinuntermelkung des Embolus und Arteriotomie an leicht zugänglicher Stelle versucht werden, und erst wenn dies nicht zum Resultat führt, soll man zu versuchen mit retrograder Sondierung übergehen, evtl. danach zu direkter Embolektomie."

In the Uppsala series of 46 embolectomies, there were 5 aortic cases, 4 treated by milking and 1 by retrograde sounding without removal of the embolus. Milking was used in this series 13 times as compared to 9 times for retrograde sounding in 22 cases (5 aortic bifurcation,

Our only case of aortic embolectomy was unsuccessful mainly because of the long duration. It is noted in Table II that in 14 cases with the duration in hours recorded, all but 3 were six hours or less. There were 10 men and 6 women, and 11 of 15 were between 38 and 56 years of age. In all but two stated cases the origin of the embolus was in the heart. The transperitoneal approach was used five times, the retrograde milking method (Nyström) four times, the retrograde probing method three times, and the lumbar or abdominal retroperitoneal approach (Usadel or Murray) five times. All the patients recovered without amputation, but only 7 are known to have lived for more than one year after operation.

The best group of cases of aortic embolectomy is that of Murray (1943), who reported five successes. The circulation was restored in all five cases and the impending gangrene of both legs in each instance was immediately replaced by extremities with normal circulation and function, thus transforming the picture to that of the original healthy state. An extraperitoneal abdominal approach was used in all cases, extending from two inches above the umbilicus to the pubis as a right paramedian incision. Heparin was used at the time of operation in all instances. As it is assumed that these five cases include and are duplications of those briefly mentioned by Murray in 1941, these earlier cases are not included in Table II. It also is to be noted that Murray speaks in his 1943 article of five successes, but gives six case reports, two of the patients dying of other causes on the second day. Therefore, if these are excluded there were four successes, if not, six. It is not apparent how Murray considers he had five successes; only four are included in Table II.

The report of our case is as follows.

CASE 4.—J. L., a man aged 53 years, had diarrhea with black stools two years before the illness for which he was admitted to the hospital. For six months he had suffered from heart trouble and had lost ninety pounds in weight during this period. On Christmas day, 1940, he had diarrhea and was admitted to the hospital the next day. The first night he was in the hospital he had seven stools. At 7:30 A.M. on Dec. 29, 1940, he had a sudden onset of pain in both legs with loss of sensation, motive power, and normal warmth At first a diagnosis of a neurologic condition was made by the resident staff, but the next day the patient was seen for the first time by Dr. Grain who immediately made a diagnosis of occlusion at the bifurcation of the aorta. At this time no pulsation was felt below the epigastrium and there was marked coldness and beginning color changes in both legs.

One of us (H. N. H.) was immediately called in consultation. The patient's condition without operation seemed hopeless, but with operation appeared to be almost equally as bad because of the length of time since the lodging of the embolus (twenty nine hours). Operation was decided upon as offering the only hope for the patient's life. A preoperative diagnosis of straddle embolus of the aortic bifurcation was made. A preliminary bilateral paravertebral lumbar block of novocain was done without any demonstrable effect on the temperature of the legs. Operation was done at 1:30 P.M. on December 30, thirty hours after the probable lodging of the embolus.

TABLE II
SUCCESSFUL AORTIC EMBOLECTOMIES

NO.	AUTHOR	DURATION IN HR.	SEX	AGE	SOURCE OF EMBOLUS	OPERATIVE APPROACH	SUBSEQUENT HISTORY
1	Bauer (1913)	3	M	39	Cardiac	Transperitoneal	Death in 2½ yr.
2	Key (1922)	23	M	44	Cardiac	Retrograde	Death in 10½ yr., from heart disease
3	Usadel (1931)	½	F	44	Cardiac	Retroperitoneal	Alive at 9 mo.
4	Drevermann (1931)	6	M	41	Cardiac	Transperitoneal	Alive at 12 mo.
5	Walzel (1930-1931)	1	M	38	Cardiac	Transperitoneal	Death in 25 days from heart disease
6	Nyström (1932)	½	M	56	Cardiac	Retrograde, milking	Recurrence in 9 mo. (see No. 7)
7	Westerborn (1932)	6	M	56	Cardiac	Retrograde, milking	Death in 5 yr. from uremia, same patient as No. 6
8	Commando* (1933)	2	M	68	(Postop.)	Retrograde	Death in 3 wk.
9	Gohrbandt (1933)	5	F	39	Cardiac	Transperitoneal	Unknown
10	Schmorell (1933)	—	M	66	Appendicitis	Retrograde, milking	Alive at 5 wk.
11	Stegemann (1933)	4	M	55	?	?	Died after several mo.
12	Culmone (1938)	—	—	—	—	—	—
13	Jefferson† (1938)	6	M	25	Cardiac	Retrograde, milking	Death in 3 mo.
14	Lindgren (1939)	10 (38‡)	F	41	Cardiac	Transperitoneal	Unknown (alive at 9 days)
15	Ravdin (1941)	3	M	32	Cardiac	Retrograde	Alive at 3 yr.
16	Murray (1943)	—	—	19	Cardiac	Right paramedian extraperitoneal	Death in 2¼ yr. from pulmonary embolus
17	Murray (1943)	21	F	38	Cardiac	Right paramedian extraperitoneal	Death in 4 mo. from cerebral embolus
18	Murray (1943)	—	F	48	Cardiac	Right paramedian extraperitoneal	Death in 2 yr. from cerebral embolus
19	Murray (1943)	—	F	27	Cardiac	Right paramedian extraperitoneal	Alive after 3½ yr.

*Cited by Danzis (1933).
†Reported by Griffiths (1938).
‡Warning signs of pain in left foot (preliminary embolus ?)

After operating the patient's condition grew worse, there was no recovery of the circulation in the legs, and repeated temperature studies showed no improvement. He died at 1.20 A.M. on Dec 31, 1940, twelve hours after operation. Necropsy revealed almost complete intimal occlusion of the left iliac artery, ulceration of the abdominal aorta with periarterial inflammation and intraarterial organized thrombosis. There were also organized thrombi in the right iliac artery While this case may have had an embolus of the abdominal aorta grafted upon the older thrombotic and ulcerative process, this latter was probably the more important condition of the two It is practically certain that without operation the patient would have died

Choice of Treatment and Decision as to Operability.—Because of the urgency of the situation, early diagnosis and prompt decision are essential As in perforated peptic ulcer and many other surgical conditions, the number of hours after onset is one of the chief factors affecting the prognosis Thus, Funck-Brentano (1938) advised the following treatment of a peripheral arterial embolus depending on how long after the onset the patient is first seen.

1. Before ten hours embolectomy plus vasodilatory and spasmolytic treatment (paravertebral, sympathetic injection, papaverine, and acetylcholine).

2 After ten hours arteriectomy plus vasodilatory and spasmolytic treatment.

3 Late cases arteriectomy

In Key's (1936) series, 34 operations were performed within ten hours of the onset of symptoms, and of these patients, 19 (55 8 per cent) regained normal circulation The results in the later cases were not so good Schein (1935) also pointed out the value of early operation. Linton's results with various treatments are shown in Table III. In discussing the need for early operation, DeTakats (1936) stated, concerning his series of 15 arterial embolism cases, that in only 5 could exploration be done and only two were seen in the first 10 hours. Haimovici (1937) had the following system

A. Under 12 hours

1 Medical treatment should be tentative and should not delay further indicated therapy more than 30 to 60 minutes Medical treatment includes

(a) Lumbar block of novocain

(b) Papaverine

TABLE III

COMPARISON OF DIFFERENT METHODS OF TREATMENT OF ACUTE ARTERIAL OCCLUSION IN LINTON'S SERIES (1937)

METHOD OF TREATMENT	TOTAL NUMBER OF EXTREMITIES	EXTREMITIES SAVED		EXTREMITIES LOST		DIED TOO SOON	
		NO	%	NO	%	NO	%
Conservative	17	5	29	7	41	5	30
Embolectomy	12	4	33	7	58	1	8
Papaver	15	4	60	7	20	3	20

Operation (H. N. H.).—Through a left herniotomy incision, going through a layers, the left iliac artery was exposed above Poupart's ligament. The inferic epigastric vessels which might have been a source of collateral supply to the leg were sacrificed with this fact fully in mind to enhance the exposure in this markedl obeso patient. The cord and associated structures were pulled downward. The ar tery had no pulsation. It was opened. The wall was sclerotic and fragmented There was no definite clot present and no free blood. A No. 16 catheter coul not be introduced more than one and one-half inch upward, whereas a No. 12 catheter could only be introduced about four inches. Flushing out with saline solution and rapid withdrawal of the catheter produced no result. It is of interest that autopsy later revealed that the difficulty in putting the catheter upward was due to narrowing of the lumen rather than to thrombosis or embolism.

Following this, the abdomen was opened through a hypogastric incision, extending from a little to the left of the umbilicus to near the pubis, cutting through the edge of the rectus sheath on the left side. No free fluid was present. The intestines were slightly darkened in their contents but the walls were quite viable. A diagnosis of some free blood in the lumen of the intestine was made but this proved at autopsy to be erroneous. Through very dense fat and markedly adherent tissue, which was later shown at autopsy, probably to be secondary to ulcerations of the aorta, this vessel was exposed near the fourth lumbar vertebral body and an incision was made one-half inch away from the aorta on the common iliac artery. This artery was also markedly sclerotic. A catheter could not be inserted downward, in spite of the fact that no thrombus was present at the site of opening and autopsy later disclosed this to be due to marked decrease in size of the lumen due to thickening.

The catheter was placed upward and flushed with very little result, but later, a No. 16 catheter was pushed upward about eight inches and definite blood obtained. Finally, using the finger to massage the lower end of the aorta, several fragments of clot were obtained, with relatively free pulsatile bleeding. Following this, in order to be sure that the right iliac artery was open, a vertical incision over the femoral artery on the right side was made below Poupart's ligament, and the artery exposed. It, too, had no pulsation. It was opened. A catheter could be placed up about six inches with no free blood obtained. There was still no pulsation in the aorta except one inch above the bifurcation but finally with massaging, another large segment of clot came out from the bifurcation and a very steady pulsatile flow of blood came out through the hole in the left common iliac. A definite clot was felt in the right common iliac, but despite considerable effort, we could not displace this.

The patient's condition was becoming poor. Try as hard as we could, we could not remove this clot on the right, and because of the poorness of the patient's condition, it was decided to sew the openings in the vessels. First that in the left common iliac was sewed, then that in the left external iliac, and then it was found that there was no pulsation any more in the lower aorta or left common iliac, so that the left common iliac had to be reopened and another large clot removed, this time followed by even better bleeding from the hole in the left common iliac. This was then closed but at that time only a slight flow of bright red blood, with practically no pulsation, came out of the hole in the right femoral artery, whereas from the left external iliac, no blood flow at all occurred, in spite of every effort. All the wounds were then closed, using interrupted skin silk for the incision over the right femoral artery, continuous heavy silk for the peritoneum, interrupted silver wire for the anterior sheath of the rectus of the abdominal incision, and through and through heavy wire through all layers of the incision over the left external iliac artery, which was entirely extraperitoneal.

The patient left the operating room quite conscious but still irrational, with a moderately good blood pressure, but we held forth no hope of eventual recovery because of the serious condition of the vessels.

where between 10 and 15 degrees below the horizontal position. The use of heat is also less popular than formerly.

The chief modes of treatment, to be discussed in detail, include:

1. Sympathetic block (and lumbar sympathectomy)
2. Periarterial sympathectomy
3. Arteriectomy
4. Heparin
5. Papaverine and related drugs
6. Alternating positive and negative pressure
7. Amputation
8. Embolectomy itself

1. *Sympathetic Block and Lumbar Sympathectomy.*—The importance of sympathetic block in cases of arterial embolism should be borne in mind. Since the use of sympathetic block is based on relief of *arterial spasm*, a discussion of this condition which is a usual concomitant of embolism will now be given. Nyström (1936) pointed out that arterial spasm is the cause of the slow pulse return noted after embolectomy. The spasm caused by the internal irritation of an embolus is much like that caused by external irritation of an artery, producing "traumatic segmental arterial spasm" as reviewed by Montgomery and Ireland (1935) as well as in an editorial in the Lancet (1941), and of which several cases were reported as having been seen by Gage and Oehsner (1940). Åkesson (1937) and Duncan (1938) also believed that there was a spastic element in cases with arterial emboli. The case of Pridie's patient (1943) with gangrene of the leg following arterial contusion also demonstrated a vascular spasm. Despite the relief of the local spasm by exploratory operation, gangrene resulted.

DeBakey, Burch, and Oehsner (1939) approached this problem experimentally, stating: "It is evident that a chemical irritant placed either in the lumen of the main vein of the extremity or in the perivascular tissues of this vein produces a marked diminution of this volume (51.6 per cent) of peripheral pulsations. However, interruption of nerve pathways by local infiltration with procaine hydrochloride at the site of the chemical irritation or by resection of the lumbar sympathetic ganglia and chain abolished this effect."

In most cases sympathetic block (lumbar in the case of the lower limb; stellate ganglion in the case of the upper limb) is advised. Such injections of novocain were especially recommended by Leriche, Froment, and Vachon (1934), DeTakats (1936), Funck-Brentano (1938), Raydin and Wood (1941), and DeTakats (1942). Gage and Oehsner (1940) reported on the use of sympathetic block in four cases of embolus of the femoral artery. In one case the embolus was removed after sympathetic block, but in all four cases the results were good. Roome (1941) was also one of the early advisers of sympathetic blockade in the management of arterial embolism and thrombosis. In both

Medical treatment, if successful, continues two to three days. If it fails, use one of following:

2. Embolectomy

3. Arteriectomy (if wall is damaged, if poor condition of patient demands extreme haste, or if secondary thrombosis occurs)

4. Lumbar sympathectomy, especially as adjuvant to iliac or aortic embolectomies when done by the abdominal route

B. Over 12 hours

Again medical treatment should be tentative

1. Embolectomy rarely, but more often in aortic bifurcation cases. In such instances this should always be accompanied by a lumbar sympathectomy

2. Arteriectomy, in most cases

Haimovici concluded in this regard: "Quelle que soit la methode chirurgicale appliqué, les infiltrations [of the sympathetics] ou les injections d'eupavérine doivent toujours etre associées." He also pointed out that after unsuccessful embolectomy, about 45 per cent of the cases survive after amputation. Griffiths (1938) stated: "It is never the operation which kills these patients, but the disease which makes the operation necessary." In deciding whether or not to operate it should be borne in mind that the danger of gangrene after embolism is greater than after ligature, probably because of secondary thrombosis as well as the underlying cardiac condition. Nyström (1936) pointed out that the operation is less apt to be successful in old people or in those with diseased vessels. As to the general operability, Lund (1937) stated that he operated upon 27 out of 55 patients (25 embolectomies, 2 explorations of artery).

The indications for embolectomy have been broadened somewhat since the time of the first successful peripheral embolectomy in 1911. At that time, Mosny and Dumont set down the following rules:

"Les embolies vasculaires entrent donc maintenant dans le cadre des affections médico-chirurgicales, mais a condition qu'elles soient aseptiques, qu'elles soient opérées rapidement, que le sujet soit jeune, que ses artères soient saines, que l'embolie soit facilement abordable."

Pemberton (1928) states: "There is no established operative procedure of equal simplicity, fraught with so little risk and with such dramatic potentialities, that has been so woefully neglected as embolectomy for circulatory disturbances of the extremities."

General treatment includes conservative management with massage, heat, elevation, etc. The general care of acute arterial obstruction in the extremities was outlined by Scupham (1935). DeTakats (1936) and others have pointed out that a leg with embolic obstruction should not be elevated, but instead should be in a dependent position, some-

rather than on the obstruction itself. Schein (1935) also recognized the importance of the vasospastic element. Referring to obstructed arteries, Leriche (1927) stated: "The thrombosed arterial segment is no longer an artery, inasmuch as all arterial function has disappeared, but constitutes a sympathetic nerve in abnormal condition."

Haimovici (1937) did much experimental work on the problem of arterial occlusion. From this work he concluded that one of the chief elements in the pathologic physiology of peripheral arterial embolism is a vasoconstrictor reflex. This reflex originates from stimuli in the adventitia of the involved vessel at the point of blockage. One of the chief aims of therapy should be to suppress the vasoconstrictor reflex arc, either by acting directly on the reflexogenic zone (embolic segment) or indirectly by attacking the reflex arc at the origin of the vasoconstrictor nerves.

Other work indirectly applicable to this subject is that of Mulvihill and Harvey (1931) who found that simultaneous removal of the lumbar sympathetic ganglia would prevent the lowering of temperature (10 to 30° F.) of the affected limb which normally accompanies the ligation of the external iliac artery. Harvey and Halpert (1931) showed that the temperature-sustaining action of the sympathectomy occurs even when spinal cord section or posterior root section has been done. Furthermore, the two latter procedures have no effect in preventing limb temperature decrease after external iliac artery ligation.

All of this work also supports the rationale of the second and third forms of treatment discussed below.

2. *Periarterial Sympathectomy.*—In most cases of embolectomy, more or less of a periarterial sympathectomy is done in freeing the artery. Special emphasis has been placed on this stage of the procedure by Haimovici (1937), who pointed out that periarterial sympathectomy serves a double purpose. It removes the damaged adventitia and it prevents conduction of the spastic sympathetic reflexes. Schein (1935) and others have pointed out that the periarterial sympathectomy incidental to the exposure and stripping of the vessel serves as a temporary aid to collateral blood flow and to the removal of the embolus and adjacent thrombi. Periarterial sympathectomy has been used by Leriche for many years for a variety of arterial lesions. It relieves vasospasm, but not as completely as a cervical or lumbar sympathectomy. The latter operation is too severe, however, for use in these gravely ill patients, so the use of arteriectomy has been substituted.

3. *Arteriectomy.*—The first arteriectomy for peripheral arterial embolism was done by Tixier in 1907. In 1924, Leriche advocated the procedure as a means of preventing secondary thrombosis and of stimulating collateral circulation. This stimulated interest and numerous authors performed arteriectomies for this condition, especially in France. Haimovici (1937) collected reports of 17 arteriectomies with 12 successes (70 per cent). Success occurred most often in instances of

his cases the relief of pain was quite marked following this procedure while previous large doses of morphine were relatively ineffective. In both cases, however, amputation had to be done.

Meyer (1940) had a 46-year-old male patient with evident embolism of the left iliac artery. Paravertebral novocain injection was done in the left lumbar region and exploration was then made of the femoral, popliteal, and tibial arteries. In each instance no visible pulse was present, but palpation did reveal pulsations. An incision in the tibial artery revealed a good flow of blood. It seemed evident, therefore, that the collateral vessels were opened by the paravertebral injection as evidenced by improvement in the temperature of the foot. The patient recovered except for a slight necrosis of the skin of the foot in several places.

Alcohol injections are less popular, but have been used occasionally. Thus, DeTakats (1937) used a paravertebral alcohol injection in the treatment of one case of postembolic occlusion.

Actual sympathectomy, chiefly lumbar, has been utilized. Thus, Bedrna (1936) of Königgratz, Czechoslovakia, reported two cases of embolism of the femoral artery treated by lumbar sympathectomy with healing. The first patient, a man aged 64 years, was treated for two days with novocain infiltration of the lumbar sympathetics on the affected side with only temporary relief after each injection. At the level of the second lumbar ganglion, 20 c.c. of 0.5 per cent novocain were injected at six and fourteen hours after onset. On the third day the third and fourth lumbar ganglia on the affected side were excised with healing four months later despite a pulseless femoral artery. Bedrna's second case, a woman, aged 66 years, with cardiac decompensation, also had an embolism of the left femoral artery. Twelve hours after onset, without previous novocainization, excision of the third and fourth lumbar ganglia was done with prompt relief of pain, improvement in appearance in nine hours, and recovery of the patient and of the limb despite an absent dorsalis pedis and popliteal pulsation. It is of interest that the cardiac edema disappeared much more rapidly on the side operated upon than on the other side (e.g., twelve weeks after operation, left leg edema-free; circumference of right thigh, 44 cm.; of left thigh, 40.5 cm.; of right knee, 27.5 cm.; of left knee 26 cm.). It is of interest that Bedrna reported paresthesias in one of his patients treated by lumbar sympathectomy. Besides the two cases of lumbar sympathectomy reported by Bedrna (1936), Haimovici (1937) lists two others with beneficial results.

The vascular spasm on the basis of sympathetic dysfunction in these cases seems, therefore, to rest on a firm foundation. Funck-Brentano (1938), in summarizing French views on embolism, lays most emphasis on sympathetic reflex disturbances caused by the local obstruction,

continues to threaten despite embolectomy. Arteriectomy has been less successful in the hands of Fercy (1935); Mathieu, Gérard-Marchant, and Lance (1935); Soupault (1935), and Schein (1935). While the words of Fontaine that "a good arteriectomy is better than a bad embolectomy" may be true, those of Griffiths that "a good embolectomy is best of all" are even truer. In general, Leriche will do embolectomies in patients seen early, but if postoperatively the pulsations disappear once more as evidence of rethrombosis, he reopens the wound and excises about 10 cm. of the vessel at the site of obstruction. Leriche (cited by Pampari) stated: "L'artériectomie est toujours suivie d'une vasodilatation active, avec hyperthermie dans le segment d'aval, à condition, évidemment, que les voies périphériques superficielles et profondes soient libres."

Grégoire (1939) also advised arteriectomy in peripheral arterial embolism. He based his preference for arteriectomy over embolectomy on the experience he had with a case of what he calls "useless embolectomy." An embolectomy was done for obstruction of the right femoral artery. Twenty-one days later the patient was able to walk, but pulsations below the operative site were extremely weak. To determine the cause of this, the artery was exposed for arteriography and it was found that throughout the length of Hunter's canal, the artery was completely occluded. Thus, despite the apparent success, the embolectomy was useless. Grégoire then postulated upon how many other cases reported as successes in the literature might not similarly be useless embolectomies. Some cases where necropsy or subsequent reoperation, such as those of Key, Nyström, Westerborn, and others, proved competency of the vessel following the first operation could not be doubted. Others, however, had no such proof. Because of this, Grégoire concluded:

"L'obstruction embolique des artères principales des membres doit être traitée par l'artériectomie. Cette opération évite la thrombose artérielle secondaire et le spasme des collatérales, de qui depend le pronostic."

Other advocates of arteriectomy include Schein (1935), DeTakats (1942) and Atlas (1942).

Not all the reports on this procedure, however, are favorable. While Leriche, Fontaine and Dupertuis (1937) reported excellent results following arteriectomy in a series of 78 cases (34 thromboangiitis obliterans, 33 arteriosclerosis, 6 traumatic, 3 embolus, and 2 syphilis) with only 19 total bad results, it is to be noted that in all three of the embolus cases results were bad. Thus, this article can be quoted as favoring arteriectomy in some cases, but not in embolus. Soupault (1935) found no benefit from iliac arteriectomy in his case. Mathieu, Gérard-Marchant, and Lance (1935) also had a failure after femoral arteriectomy.

In conclusion it may be stated that the two chief conditions for arteriectomy are (1) late cases (over twenty-four hours according to

TABLE IV

ARTERIECTOMY FOR PERIPHERAL ARTERIAL EMBOLISM (FROM HAIMOVICI)

ARTERY	ARTERIECTOMIES	SUCCESSES
Brachial	4	4
Popliteal	3	2
Femoral	7	6
External iliac	2	0
Internal iliac	2	0

brachial, femoral, and popliteal embolism as shown in Table IV. After Leriche's championing of this procedure in 1924, between that date and 1934, successful cases were reported by Grégoire, Jouve, Langeron, R. Bernard, and Baillat. Gallavardin (1934) pointed out that an arteriectomy has two aims: to decrease sympathetic reflex stimuli and to prevent propagating thrombosis.

Leriche, Froment, and Vachon (1934) reported the case of a woman, aged 54 years, on whom they performed an arteriectomy for embolism of the femoral artery. This was done five hours after lodging of the embolus and was followed eighteen hours later by a novocain infiltration of the lumbar sympathetics on the same side. Ten days later the limb and its circulation were entirely normal. Ferey (1935) did an arteriectomy of the brachial artery at the same time as he performed an axillary embolectomy. The operations were performed thirty-two hours after the onset and all the clots could not be removed. Gangrene resulted and amputation was performed at the elbow.

Leriche, Froment, and Vachon (1934) listed the types of case in which they believed arteriectomy is indicated:

(1) Where, because of the condition of the patient, speed is essential.

(2) Where, on performing the embolectomy, the arterial wall is found to be damaged.

(3) In late cases seen after twenty-four hours.

(4) Where, after embolectomy and suture, there is secondary thrombosis. (It is quite possible that this last indication will seldom play a role now that heparin is utilized in most cases of embolectomy, vide infra.)

Jeanneney and Darget (1937) reported a case where embolectomy of the femoral artery was done but a new clot was found at a second operation twelve hours later. Because of this an arteriectomy was done with resultant gangrene and death. These authors point out that when arteriography reveals a paucity of collateral circulation, arteriectomy should not be done. Arteriectomy has also been advised by Leriche, Fontaine, and Dupertuis (1937) and by various pupils of Leriche.

One of these latter, Pamperi (1936) advised arteriectomy if the endothelium under the embolus appears damaged, if the operation is performed twenty-four or more hours after the embolism, or if gangrene

heparin has recently been reviewed by Ziff and Chargaff (1940). Groth (1940) was one of the first to use heparin in conjunction with embolectomy.

In the United States, the group of workers at the Henry Ford Hospital was among the first to use the newer heparin preparations clinically. The writings of McClure and Lam (1940), and Lam (1941, 1942) should be consulted as reporting the results of this group of workers. The mechanism of the action of heparin has recently been studied by Murray, Jaques, Perrett, and Best (1936), Lucia and Aggeler (1939), Fischer and Astrup (1939), Nyström (1939), and Ziff and Chargaff (1940). Heparin used clinically, is of five kinds: (1) That purified by Jorpes method and obtained from the Karolinska Institute, Stockholm, (2) "Vetren," a heparin solution marketed by Promonta Chemisches Fabrik, Hamburg, (3) heparin purified by the methods of Charles and Scott, and available from the Connaught Laboratories, Toronto, (4) heparin solution supplied by Hoffmann-LaRoche, Basle, Switzerland, and more recently (5) heparin prepared by several American firms. Heparin can be neutralized by protamine, 1 mg. of the latter neutralizing 0.3 mg. heparin in vitro or in vivo (Mason, 1939). However, this has little clinical application since protamine is toxic if administered in any form intravenously. Nyström (1936) used interrupted sutures in his embolectomy cases. He stopped any small spurting of blood with prolonged application of the gloved finger tip. Such technique is not applicable to heparinized patients and in general, in such instances, the arteriotomy wound is closed with a running silk suture. Dicumarol has little applicability to these cases since its delayed action makes it unfit for the emergency procedure of embolectomy.

Heparin has also been utilized by Bancroft (1940), Priestley, Essex, and Barker (1941), and by Lesser (1943). Bancroft and Glick (1941) reported the successful operation of embolectomy for a femoral embolus, 48 hours after onset of symptoms, by the use of a retrograde suction procedure. They further attributed the success of the operation to the combined use of heparin and pavaex treatment. Lindgren (1939) used heparin successfully in two cases, advising 0.5 per cent thionin locally in the wound to counteract the heparin effect. Ravdin and Wood (1941) used heparin in conjunction with their successful aortic embolectomy. Marshall and Vary (1942) reported the successful use of heparin in conjunction with embolectomy for removal of an embolus of the external iliac artery.

One of the chief advocates of the use of heparin in conjunction with embolectomy has been Murray of Toronto. In 1940, this author stated that the results following embolectomy with heparin were better in his experience than those following the use of the pavaex boot. Murray (1940) performed experiments on dogs to test the effects of heparin in embolectomy. Peripheral vessels in dogs were plugged with foreign

Jeanneney and Darget [1937]—possibly longer when heparin is used), and (2) damaged arterial wall. When the collaterals are known to be poor, arteriectomy is often contraindicated. Arteriectomy should usually be performed so as to remove 10 cm. of vessel from the site of the exploratory arteriotomy down to, but not past, the next collateral. The value of arteriectomy is that it causes a peripheral vasodilatation if the collateral vessels remain intact as shown by Leriche, Fontaine, Grégoire and Jouve, Bernard, Careassonne, and Jeanneney and Darget.

4. *Heparin.*—Heparin has been advised in the treatment of peripheral arterial embolism by several authors. In practically all instances such advice applies to the use of the drug in conjunction with surgical treatment rather than as a definitive mode of therapy in itself. Murray (1936) reported embolectomy performed on 17 patients in a series of 30 cases of peripheral arterial embolism seen at the Toronto General Hospital in the five-year period, 1931-1935. It is of interest that during this period there were 126 total cases of embolism distributed as follows: pulmonary, 56; cerebral, 35; central artery of retina, 3; coronary, 2; and peripheral arteries, 30. Of the 17 patients operated upon, 9, with 11 operations, were alive and well with adequate circulation to the extremity. Of the remaining 8, one was alive with amputation, while the others died. However, in all cases of death the circulation had been restored to the limb.

While Olovson (1938) did not use heparin in his cases, in discussing them in retrospect, he wondered if, as a prophylactic measure against secondary thrombus formation, heparin might not be of value. Olovson (1939) carried on experiments to test the efficacy of heparin (Jorpes) in treatment of arterial emboli. He suggested local use as well as general intravenous injection and also suggested that the suture materials be prepared with heparin. In experiments on dogs and rabbits, he found that a local hemostyptic would control local bleeding and prevent hematoma formation. In none of his experiments did a secondary thrombosis arise. Heanley (1939) administered heparin to his second patient, a man, aged 67 years, with femoral embolus due to auricular fibrillation. Ten thousand units were administered intravenously as soon as the artery had been closed and the embolectomy completed, and 45,000 units additional were given by continuous venoclysis over a period of three days. Despite this amount of heparin, gangrene occurred and amputation was performed fifteen days after embolectomy and four days before death. Fischer and Astrup (1939) showed that heparin is entirely inactive by mouth. Murray and Best (1938) reported the use of heparin in five embolectomies with four recoveries. Groth (1939) mentioned the use of heparin. Jorpes (1939) in his monograph on heparin reviewed its use in clinical and experimental instances of embolism. Mason (1939) wrote an American review of heparin at about the same time. The mechanism of action of

left retina. Two days later on Nov. 6, 1939, at 8 A.M. he developed sudden pain in the left leg below the knee with blanching and coldness. Intravenous heparin by constant drip was given both before operation and for five days postoperatively. After operation the patient was placed on the oscillating bed.

Operation.—This was done by the senior author (R. D. McC.), at 11 A.M., three hours after lodging of the embolus. Local anesthesia supported by a little open drop ether was used to make a 10 cm. vertical incision over the patient's left popliteal space. The popliteal artery was separated from the vein. Pulsation could be felt in the upper portion of the artery, but not below. All of the vessels were very sclerotic. A longitudinal incision was made in the artery and a partially organized nonadherent clot 4 cm. in length was removed. A bulldog clamp was then placed on the artery above the incision to prevent bleeding.

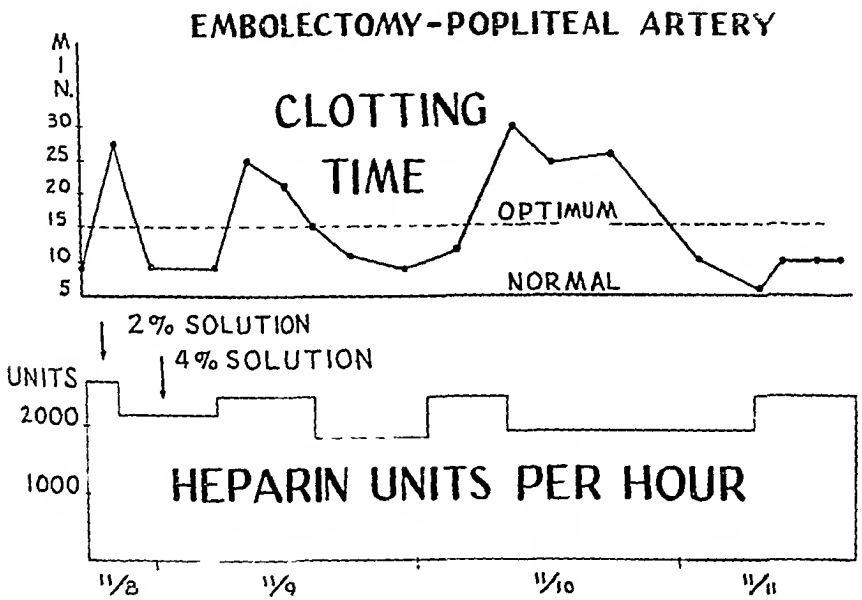

Fig. 3.—Heparin chart of G. L., Case 5. (We are indebted to Dr. C. R. Lam for preparation of this chart.)

Closure of the arteriotomy wound was effected by a continuous suture of fine silk which was reinforced with another continuous suture in the opposite direction. When this was done, the bulldog clamp was removed and the pulsation returned to the vessel throughout its length. There was practically no oozing of blood along the suture line. The superficial wound was closed. It should be noted that this operation was done with the patient under the influence of heparin. This is the only one of our cases in which heparin was used preoperatively as well as postoperatively.

The pulsations in the arteries in both feet were normal after operation and remained so. The patient developed another pulmonary infarct on the tenth postoperative day, but was able to get out of bed on Nov. 27, 1939. He was discharged from the hospital on Dec. 14, 1939, with complete restitution of circulation in the affected leg. He died of cerebral embolism on Nov. 26, 1940, a little over a year after operation. Just prior to death examination showed a normal circulation and function of both legs.

The prompt diagnosis, early treatment, and complete removal of the embolus with the help of heparin led to a good result in this case. The embolectomy gave this patient over a year additional life with entirely normal extremities (see Fig. 3).

bodies and blood clot and closed. The plugs were removed after intervals up to seventy-two hours. In the earlier hours removal was easy, but later involved scraping off from the intima, usually followed by recurrent thrombosis. Heparinization, however, prevented this secondary obstruction and specimens removed a month later showed the artery to be clear of thrombi. In twelve clinical cases the vessel remained patent in all after embolectomy with heparin and the circulation to the extremities was maintained. Two patients died at intervals after operation and necropsy showed the vessels at the site of incision to be quite patent. Since one of these two patients who died had had the embolectomy done twenty-five hours after onset, this necropsy finding is all the more remarkable.

Murray (1940), in reviewing his experience with heparin, reported twelve peripheral arterial embolectomies performed successfully with the aid of heparin. He stated, "If the lumen was completely cleared of the plug and the circulation restored, all the cases were successful when treated with heparin." He introduced the drug into the vessel at the time of operation and heparinized the patients from three to fourteen days postoperatively. One of his patients showed a residual anesthesia and loss of motion of the foot somewhat similar to that in our Case 12. Two patients died later and necropsy revealed that the arterial channels were quite patent. This patient of Murray's was treated twenty-five hours after onset of symptoms of obstruction of both common iliac arteries. Murray concluded regarding embolectomy: "From our experiences with the use of heparin in this operation, one is encouraged to believe that many more cases may be saved amputations." In Murray's last available complete report (1941) he described the use of heparin in conjunction with embolectomy in twenty-six cases.

The series of articles in the Acta Medica Scandinavica, volume 107, 1941, page 107, et seq., shoud be consulted. In the opening article of the discussion, Jorpes discussed the general aspects of the situation. Lindgren and Wilander considered the use of heparin in vascular surgery. These authors reported the results of eight embolectomies done in conjunction with heparin on seven patients. One of the patients presented a bilateral popliteal embolism of four and one-half days' duration with a successful result on one side, but failure on the other. Rosenqvist's discussion on the usefulness of heparin in combating arterial embolism and thrombotic complications discusses mainly the question of pulmonary embolism.

Several of our own cases have been reported elsewhere in this communication, but the following examples are cited at this point.

CASE 5.—G. L., a man, aged 62 years, suffered from arteriosclerotic heart disease and auricular fibrillation since 1937 or before, and myocardial failure since June, 1938. In January, 1939, he had an infarction of the right lung. He was admitted to the hospital on Oct. 23, 1939, again for observation because of myocardial failure. On November 4, he developed acute obstruction of the central artery of the

There was no improvement in the condition of the left leg and the patient's cardiac condition grew worse. On the seventh day after operation, the patient developed an embolism of the right leg and died the day after.

Lam prepared the following notes on four of our cases which received heparin and which are described in detail elsewhere in this paper.

CASE 4.—(J. L.).—Continuous heparin begun at 2:15 P.M. Initial clotting time was 3 min. 15 sec. Given 2 vials of heparin before death. Highest (longest) clotting time obtained was 5 min. at 11:00 P.M.

CASE 5 (G. L.).—Reported in detail in the article by McClure and Lam in J. A. M. A., May 25, 1940. Necessary to discontinue heparin on account of congestive failure, and aggravation of symptoms from salt solution given intravenously. However, if more heparin had been urgent, we could have given it undiluted by the intermittent method. (See Fig. 3.)

CASE 9 (E. B.).—Attempted embolectomy for embolus in left external iliac artery. This patient was heparinized immediately after the artery was sutured, by the injection of 3 c.c. of heparin, followed by continuous heparin by cannula in the right leg. Given 6 vials of Connaught heparin, 1,500 units per hour necessary to maintain the clotting time at the optimum level.

CASE 12 (G. G.).—Heparinized immediately after operation. Given 16 vials of Connaught heparin over a period of four days, about 1,500 units per hour necessary to maintain the clotting time, at the optimum level. Necessary to discontinue on account of bleeding from popliteal wound (see Fig. 7).

5. *Papaverine and Related Drugs.*—Papaverine, introduced by Pal (1914), was first used as an agent to relax arterial spasm in cases of arterial embolism by Denk (1934) of Vienna. Henschen (1935) used the drug in similar cases intravenously. Denk (1936) reported remarkable results from the intravenous injection of eupaverin (a European Merck trade name for papaverine). In a series of ten of Denk's own cases of embolism of the extremities treated with this drug, 7 patients were cured, 2 died, and 1 required amputation.

Papaverine, an alkaloid of the opium group, was first advocated as a means of relieving smooth muscle spasm by Pal of Vienna in 1914. The chief pharmacologic effects of papaverine are peripheral and it relaxes all types of smooth muscle without paralyzing them. Its analgesic effect is such that when given subcutaneously, about 40 mg. corresponds to 10 mg. of morphine. Papaverine hydrochloride in ½ gr. (0.03 Gm.) doses or sodium nitrite in 1 gr. (0.06 Gm.) doses given intravenously will affect the general blood pressure little or none at all, but will enlarge the venocapillary portion of the vascular bed. This acts as a general peripheral vasodilator. The clot itself is probably not affected, but the peripheral circulation may be. Papaverine is an agent producing a direct effect on the smooth muscles in the vascular wall and has no remote effect conveyed by the nerves. It is difficult to see how it can reach the affected vessel when the factors of the embolus itself, postembolic thrombosis, occlusion of collaterals, collapse of the

CASE 6.—H. Br., a woman, aged 68 years, had a history of arteriosclerotic heart disease, arterial hypertension, and angina pectoris. On Oct. 8, 1941, she had a sudden attack of precordial pain followed in one hour by pain in the left calf with coldness and pallor. A diagnosis of embolism of the left femoral artery was made and operation performed fourteen hours after the accident.

Operation (H. N. H.).—The patient was turned on the right side with the left side up, and opposite the second and third lumbar vertebral spine, an injection of 10 c.c. of novocaine was made two fingerbreaths lateral to the left side of the midline, and two fingerbreadths deep to the transverse processes, thus attempting to infiltrate the sympathetic chain at this site. There was a slight temperature response in the leg, indicating that the novocain went to the right place but the result was not striking. The patient was then placed again on her back and a vertical incision four inches long was made over the fossa ovalis. The femoral artery was exposed and opened. A small clot was brought out from the distal end. The wall of the artery was thickened, so as to be almost as thick as its lumen and somewhat irregular. There were, however, no ulcerations or incrustations on the lining. After removal of the small clots from the distal end, a very weak flow of blood came from it. There was no flow of blood from the proximal end and there was no pulsation in the artery except as palpated by placing the finger high up near the bifurcation of the femoral. A probe and later a catheter were inserted into the artery. Both of these brought out practically no clots, so with finger milking, placing the finger up beneath Poupart's ligament as high as we could reach, we milked out four portions of clot. These evidently came from the bifurcation of the femoral artery.

Fig. 4.—Emboli from left common femoral artery of H. Br., Case 6.

Following this, there was a free gush of pulsating blood with perfect freeing of the artery and 1 c.c. of heparin solution was injected into the distal segment of the artery. A double row of lock suture with arterial silk was then made using one suture and reversing it back on itself. Following this, there was a slight pulsation in the artery distal to the point of suture. We injected 6 c.c. total additional heparin in three doses into the artery by means of a hypodermic syringe and needle. When we compressed the vessel, about one and one-half inch below the line of suture, blood leaked out at the site of the suture more easily. Thus, although there was no definite pulsation below the line of suture, there was evidently a moderate flow, so that it was estimated that we had restored the circulation to one third its correct amount. More heparin was now injected. Further restoration was impossible because of the markedly constricted and sclerotic nature of the vessel. We had now exposed the distal one-half inch of the vessel at the lower end, to be sure that there was not a distal clot.

The wound was then closed in several layers of interrupted silk. A rather loose elastoplast bandage was applied. The patient was to be continuously heparinized. During the operation she received a total of 10 c.c. of heparin into the artery.

into the affected artery after embolectomy. No postembolic thrombosis occurred in his case.

In our own series papaverine was used in several instances, but as other treatments were used at the same time, no conclusions as to its efficacy can be drawn.

6. *Alternating Positive and Negative Pressure (Pavaex).*—The use of this method of treatment, either definitively, or in conjunction with other forms of therapy, was early popularized by Reid and Herrmann (1933). Conway (1936) reported good results in several cases of embolism of the extremities with the use of pavaex. Burnett (1939) also found the method to be efficacious. Collens and Wilensky (1937) reported favorably on the use of intermittent venous occlusion in the treatment of three cases of peripheral arterial embolism. Linton (1937) advised embolectomy followed by pavaex as the best method of treatment. Edwards (1937) presented a modified pavaex boot for management of acute arterial obstruction. Herrmann (1936) reported on 7 patients with embolic obstruction of the extremities treated by the pavaex boot with 6 good results. Graham (1937) reported improvement in 6 out of 9 patients treated with a pavaex boot. He tended to favor conservative measures, especially after ten hours. Raydin and Wood (1941) used pavaex in conjunction with embolectomy. Linton (1943) found that intermittent venous occlusion was effective in treating a case of traumatic thrombosis of the left external iliac artery. In this author's previous paper (1937) his good results with the pavaex treatment are all the more noteworthy when it is observed that in 2 cases the embolus was at the aortic bifurcation, 1 was in the common iliac and 2 in the popliteal artery, all notoriously difficult locations.

Not all articles on the subject are favorable to this form of therapy. DeTakats (1934) wrote a preliminary report on the treatment of obliterative vascular disease with alternating negative and positive pressures. However, DeTakats (1936) reported little or no improvement in a series of 4 cases of peripheral arterial embolism treated with the pavaex boot. In another article in the same year, he found that the pavaex boot was not nearly as efficacious as papaverine in the treatment of embolic obstruction of the extremities. The next year, however, DeTakats (1937) used intermittent venous hyperemia in the treatment of one case of postembolic arterial occlusion. Pickrell (1943) opposed the use of the pavaex apparatus in peripheral arterial embolism. Wilson and Roome (1936) used the pavaex boot on three patients with leg embolism with one good result. The improved patient as well as one of the two with poor results received papaverine in addition. Because of the small amount of pavaex treatment given in the successful case, these authors believed that it could not account for all the improvement. No large series of cases treated by a machine

artery because of drop in pressure, and reflex spasm all contribute to blocking off its access. Åkesson (1937) showed that intravenous eupaverin does not prevent secondary thrombosis, while Groth (1939) showed that direct intra-arterial injections were also ineffective in this regard. Groth (1939) and Lund (1939) believe that "the prospects of obtaining any kind of effect on the arteries by intravenous injections of eupaverine are thus nonexistent or in any case very small" (Groth) and the results of papaverine are "possibly not much better than the results of no treatment at all" (Lund).

DeTakats (1936) reported on the beneficial effects of intravenous papaverine in a case of pulmonary embolism, another of acute peripheral thrombosis, and three cases of peripheral arterial embolism. Geisthövel (1938) advised eupaverine in cases of arterial embolism, but only as an adjunct to operation if the circulation was not promptly restored. He advised its use not only intravenously, but locally in the involved vessel. Funck-Brentano (1938) advised 0.25 Gm. of papaverine (either intramuscularly or intravenously) and acetylcholine (0.1 Gm. intravenously or 0.4 Gm. intramuscularly) every 30 minutes for five to six hours. Funck-Brentano (1938) also believed that medical treatment of the vascular spasm doesn't take sufficient account of the action of the embolus as a starting point of thrombosis. He stated in this regard: "La thérapeutique par action à distance (chirurgicale, anesthésique ou médicale) nous paraît devoir être une action d'accompagnement et non pas une action isolée." Funck-Brentano (1938) concluded in this regard: "Le traitement médical doit demeurer, actuellement, un adjuvant de la chirurgie."

Other drugs have been used to accomplish much the same purpose. Funck-Brentano (1938) mentioned the use of yohimbine (a sympatholytic drug).

Perlow (1940) reported slight improvement in one case of embolism of the iliac artery first treated four days after lodging of the embolus with prostigmine (the dimethyl carbamic ester of m-oxyphenyltrimethylammonium methylsulfate). This same author reported improvement in another case of peripheral arterial embolism following the use of prostigmine. Villaret and Justin-Besançon (1926) first used acetylcholine in the treatment of arterial embolism, using 0.2 to 0.4 Gm. subcutaneously every thirty minutes for five or six doses. Ferey (1935) and Grégoire (1939) used acetylcholine, while Henschen (1935) used acetylcholine in the wound.

Funck-Brentano (1938) stated: "Papavérine et acétylcholine agissent de deux façons differentes et leur association réalise des effets plus puissants que ceux, qu'on peut obtenir par l'emploi isolé de l'un d'entre eux." Atropine is contraindicated because it suppresses completely the action of acetylcholine.

The route of administration may also be changed, Östling (1939) reporting a favorable result following the use of eupaverin injected

flow only slightly, but did not affect the retrograde flow at all. Probing, aspiration, and injection of saline solution with a catheter were all performed to no avail, so finally the arteriotomy wound was closed with continuous fine white Chinese silk, following which 3 c.c. of heparin were injected into the artery and the superficial wound was closed. There was no improvement in the pulse or temperature in the foot or leg after operation.

Left midthigh amputation was performed on May 19, 1942, four days after the first operation, and the patient got along well until September 26, 1942, when he died of a cerebral embolism.

8. *Embolectomy.*—This is discussed in detail after a consideration of the technique.

TECHNIQUE OF EMBOLECTOMY

Certain aspects of the technique will be considered in the individual case reports, but a general discussion of the subject will be made at this time. The importance of the collateral vessels is shown in Table V.

Henschen, of Basle (1935), has several suggestions for the technique of embolectomy: (1) For indirect retrograde embolectomy he uses a long corkscrew tipped probe, (2) for the same purpose he inserts a catheter with its opening at the end and applies suction from an electrically driven suction pump, (3) peripheral irrigation of the vessels at the end of the operation with 10 to 15 c.c. thorotrast or 20 c.c. equal parts normal salt solution and urosclectan for the combined purpose of arteriography and flushing out the vascular periphery, and (4) avoidance of all tight bandages after operation.

TABLE V

SUPERIOR LIMIT OF CIRCULATORY DISTURBANCE IN PERIPHERAL ARTERIAL EMBOLISM

SITE OF EMBOLUS	AUTHOR		
	SENCERT	KEY	BULL
Aorta	Crural arcade	Crural arcade and abdomen up to the umbilicus	Crural arcade
Common iliac	Crural arcade	Middle of the thigh or at the arcade	Crural arcade
Common femoral	Inferior third of the thigh	Inferior third of the thigh, at the knee, or just below the knee	Inferior third of the leg
Popliteal	Inferior third of the leg	Superior third or between the middle and superior thirds of the leg	Instep or inferior third of the leg

Anesthesia.—Local anesthesia is favored by most authors. Embolectomy patients are often severely ill and furthermore the operation is usually readily carried out under local anesthesia. Danzis (1933), Leriche, Froment, and Vachon (1934), Henschen (1935), Haimovici (1937), and Groth (1940) are among the many advocating this type of anesthesia. Danzis (1934) advised regional or block anesthesia. Deitch (1936) used spinal, but Fontaine opposed spinal anesthesia as the method of anesthesia in embolectomy because the resultant hypotension and local stasis impair still further the already diminished circulation.

have been presented to date in which the results will at all compare with those of surgical operation. Even where gangrene is averted, the limb in many cases is permanently impaired. Reviewing the subject of embolectomy in a recent editorial, Lund (1939) stated that he questioned the value of papaverine and thought that operation was better than the pavaex boot. In late cases, however, he believed operation to be contraindicated and the pavaex treatment the method of choice.

7. *Amputation.*—In most instances a primary amputation is not advised because in even the most serious cases a trial with medical management is advisable. In general, all definitely gangrenous cases eventually come to amputation as do those first seen after too long a period since lodging of the embolus. This period may be extended somewhat by the use of heparin, but certainly the statement of DeTakats (1936) that amputation is indicated after forty-eight hours still holds true in the main. Reports of two cases in which unsuccessful embolectomy was followed by amputation are listed here.

CASE 7.—A. S., a man, aged 50 years, with arteriosclerosis and arteriosclerotic heart disease, had a sudden onset of pain in the right leg with absent pulses, pallor, and coldness. A diagnosis of right iliac embolism was made and operation performed nine hours after the accident.

Operation (H. N. H.).—A right oblique incision just below the inguinal crease was made, exposing the right femoral artery. While the artery was of normal size, it had no palpable pulsation. A longitudinal 1 cm. arteriotomy incision was made revealing a slow stream of blood coming from both directions, but while there was a very slight pulsation from above, there was none below. Probing downward for a distance of 30 cm. and upward for about the same distance with both a catheter and a probe, revealed no obstruction. Upon sucking the catheter out several times vigorously from the upper segment, the blood flow seemed to be markedly improved but was still far from normal. We could do no more. After closing the arteriotomy wound with a double row of continuous fine arterial silk, 5 c.c. of heparin were injected into the artery. There was no leakage and the superficial wound was closed. The leg was not warmer after the operation.

A midthigh amputation was done eight days after the first operation, and the patient was discharged from the hospital two months later.

CASE 8.—G. McC., aged 62 years, had a history of generalized arteriosclerosis and old coronary occlusion. One week before admission he had another coronary attack and on May 15, 1942 he was admitted thirteen hours after a sudden attack of pain, numbness, and coldness in the left foot. Examination revealed pallor and loss of sensation of the left leg below the calf and absence of all pulsations of the left leg including the femoral. A diagnosis of left iliac embolism was made and operation performed sixteen hours after the accident.

Operation (H. N. H.).—A left paravertebral novocain injection was done with no marked effect. Palpable pulsation remained absent in the left external iliac artery and in the vessels below. The femoral artery was exposed through an oblique incision below the inguinal crease. The artery was pulseless. A 1 cm. longitudinal arteriotomy opening was made revealing no retrograde pulsation, a very slight retrograde ooze, and no ooze or pulsation from the proximal end. A blunt probe was inserted upward for a considerable distance meeting no obstruction, but on removing it a soft thrombus about 1 by 0.5 cm. was removed. This improved the proximal

Anticoagulants.—The use of heparin (discussed in detail elsewhere in this communication) is popular at present. Key (1922) used vaseline coated instruments and irrigation of the wound with 2 per cent sodium citrate. Henschen (1935) and others also advised sodium citrate.

Arteriography.—Leriche, Froment, and Vachon (1934) advised arteriography to locate the embolus.

Concomitant Ligation of Veins.—Ligation was advised by Makins (1922) and other authors, but not by Gage and Ochsner (1940). Larks (1934) suggested ligature of the accompanying vein in cases done too late for an embolectomy. On the whole this procedure has not been widely adopted.

Repeated Embolectomy.—In some cases reoperation may be necessary and good results may follow even after several trials. Harkins (1934) reported two attempts at embolectomy on the same patient, once on the left arm and once on the left leg. Groth (1936) collected 6 cases of re-embolectomy at the same site including one patient of his own with 4 separate embolectomies, 2 at the same site. Deitch (1936) also reported an example of multiple embolectomy. A man, aged 44 years, had an embolus removed from the left common femoral artery in January, 1934, and one from both the right common femoral and left common iliac in December, 1935, with success in all three instances. Lindgren and Wilander (1941) did a bilateral popliteal embolectomy, successful on one side, but requiring amputation on the other. MacFarlane (1940) reported a case of multiple operations.

Miscellaneous Procedures.—Funck-Brentano (1938) discussed the use of thrombotripsy. Neuhof's technique (1932) of intentional partial arterial occlusion as an adjunct to embolectomy was not adopted by other surgeons. Haimovici (1937) pointed out the advantage of noticing after an embolectomy if blood comes from the distal end of the opened vessel. Embolectomy with ligature was suggested by Finch (1934), but Haimovici (1937) points out that arteriectomy is better. Heidrich (1921) reported a 100 per cent mortality after ligation of the common iliac artery. Anastomoses with venous grafts were attempted by Stewart (1907), but the newer methods of arterial anastomosis recently described by Blakemore, Lord, and Stefko (1943) using vitallium tubes offer more promise where such a procedure is indicated.

Nyström (1936) advised the use of rubber tubes for hemostasis rather than rubber-shod clamps. If a reflux of blood occurs when the distal tubes are released, then they are again held taut and the suturing of the incision is begun. At this time, Nyström used interrupted sutures. He did not believe that intima-to-intima approximation was necessary because it may further narrow the lumen. He used bulbous tipped probes for retrograde embolectomy, performing what he called "intra-arterial sweeping." Extreme gentleness is advised at all times.

On the other hand, Koucky, Beck, and Hoffman (1940) used spinal anesthesia. Edwards (1938), in operating on three patients with embolism of the arm, with two good local results used local brachial plexus block anesthesia in all three cases.

Site of Arteriotomy.—A longitudinal arteriotomy incision slightly distal to the location of the embolus is most frequently advised and was used by Carling (1934), Jefferson (1934), Heanley (1939), Groth (1939), and by the present authors. Haimovici (1937) opposed retrograde embolectomy, while Deitch (1936) opened the popliteal artery in one of his patients, only to find a femoral incision necessary. Another advantage of opening below the obstruction, however, is that if any accident occurs, the obstruction will be as low as possible. Concerning the site of arteriotomy, Bernard counseled: "de ne pas artériotomiser un tronc qui donne les branches importantes au niveau de ces branches, mais au-dessous d'elles: si la suture donne lieu à une oblitération secondaire, les branches en question auront néanmoins des chances de rétablir la circulation du membre." Girdlestone (1935) exposed the common femoral artery, but while palpating it the pulsations in it as well as in the posterior tibial suddenly returned, so he assumed he had fortunately pushed the embolus into the profunda femoris. Jefferson (1934) also advised "a deliberate attempt to massage the clot into the subsidiary branch. If this failed the operation would be proceeded with on normal lines and the artery opened."

Removal of Embolus.—Various instruments, including alligator forceps, Babcock's vein probes, uterine sounds, ureteral catheters, small urethral catheters, and Merke's corkscrew probes have been used to remove the emboli. In 1894, Severeanu suggested that in cases of amputation for gangrene due to arterial obstruction, a bougie might be passed up for some distance from the cut surface of the stump into the divided proximal end of the main artery so as to insure its patency, to remove clots, and to minimize the risk of gangrene of the flaps. Andrews and Harkins (1932) used a large urethral catheter for its plunger action to pull out an embolus from the femoral artery. Murphy first used retrograde sounding. Mason and Hurxthal (1928) used a No. 10 catheter to flush out the vessel with sodium citrate solution *after* removal of the embolus. Allen (1929) advised the use of a flexible spiral instrument. Stevenson (1938) and Stevenson and Walker (1938) developed a special needle for arterial embolectomy. This needle is ten inches long and has a ball on the end one-fourth inch in diameter. It is used for probing arteries for emboli.

Closure of Wound.—Mason and Hurxthal (1928) emphasized the need for suturing intima to intima. Jefferson (1934) and Carling (1934) stated that they did not believe it mattered much if the sutures presented a little on the inside of the vessel. Banks (1934) and others advised interrupted sutures, but since the introduction of heparin, a running stitch has been found preferable.

Anticoagulants.—The use of heparin (discussed in detail elsewhere in this communication) is popular at present. Key (1922) used vaseline coated instruments and irrigation of the wound with 2 per cent sodium citrate. Henschen (1935) and others also advised sodium citrate.

Arteriography.—Leriche, Froment, and Vachon (1934) advised arteriography to locate the embolus.

Concomitant Ligation of Veins.—Ligation was advised by Makins (1922) and other authors, but not by Gage and Ochsner (1940). Larks (1934) suggested ligature of the accompanying vein in cases done too late for an embolectomy. On the whole this procedure has not been widely adopted.

Repeated Embolectomy.—In some cases reoperation may be necessary and good results may follow even after several trials. Harkins (1934) reported two attempts at embolectomy on the same patient, once on the left arm and once on the left leg. Groth (1936) collected 6 cases of re-embolectomy at the same site including one patient of his own with 4 separate embolectomies, 2 at the same site. Deitch (1936) also reported an example of multiple embolectomy. A man, aged 44 years, had an embolus removed from the left common femoral artery in January, 1934, and one from both the right common femoral and left common iliac in December, 1935, with success in all three instances. Lindgren and Wilander (1941) did a bilateral popliteal embolectomy, successful on one side, but requiring amputation on the other. MacFarlane (1940) reported a case of multiple operations.

Miscellaneous Procedures.—Funck-Brentano (1938) discussed the use of thrombotripsy. Neuhof's technique (1932) of intentional partial arterial occlusion as an adjunct to embolectomy was not adopted by other surgeons. Haimovici (1937) pointed out the advantage of noticing after an embolectomy if blood comes from the distal end of the opened vessel. Embolectomy with ligature was suggested by Finch (1934), but Haimovici (1937) points out that arteriectomy is better. Heidrich (1921) reported a 100 per cent mortality after ligation of the common iliac artery. Anastomoses with venous grafts were attempted by Stewart (1907), but the newer methods of arterial anastomosis recently described by Blakemore, Lord, and Stefko (1943) using vitallium tubes offer more promise where such a procedure is indicated.

Nyström (1936) advised the use of rubber tubes for hemostasis rather than rubber-shod clamps. If a reflux of blood occurs when the distal tubes are released, then they are again held taut and the suturing of the incision is begun. At this time, Nyström used interrupted sutures. He did not believe that intima-to-intima approximation was necessary because it may further narrow the lumen. He used bulbous tipped probes for retrograde embolectomy, performing what he called "intra-arterial sweeping." Extreme gentleness is advised at all times.

REPORTED CASES OF EMBOLECTOMY

The operation of peripheral arterial embolectomy has been especially practiced in the Scandinavian countries, but has also been done in Great Britain and in the United States quite frequently. Mason and Hurxthal (1928) reported 5 cases of femoral embolectomy. In all instances the embolus lay where the profunda branched off from the common femoral artery. Allen (1929) reported 6 embolectomies in 7 attempts, with one good result. In 1933, Pearse made a statistical study of 286 peripheral embolectomies reported in the literature. He found the time of operation after onset to be of great importance, improvement occurring in 40 per cent of cases following operation performed during the first ten hours, 14 per cent in the second ten hours, and 8 per cent in the third ten hours. Jefferson (1934) reported 6 personal cases, 2 completely successful (1 arm, 1 leg), 2 partly successful (both arm) and 2 unsuccessful (1 arm, 1 leg). Valdoni (1935) collected 333 cases from the literature.

Dissatisfaction with the operation of embolectomy is especially noted in the American literature (Graham [1937], DeTakats [1936], and others). This is largely and justifiably based upon the frequent failures and many postoperative deaths. Strömbeck (1935) reviewed 327 operations following which 63 per cent of the patients died in the hospital and only 12 per cent survived for five years. Danzis (1933) reported that only 41 per cent of reported embolectomies were successful and that one-quarter of these successful ones died in the hospital. Mason and Hurxthal (1928), Allen (1929), and other reporters of small series gave similar pessimistic results. DeTakats (1936) reported 5 embolectomies with 2 good results, both of which were iliac obstructions. Two of the other patients died of other emboli.

In Sweden, Key was able to report, in 1936, that he had personally done 32 embolectomies in 30 cases. At the Maria Hospital, Stockholm, on his service, and in his own private practice, 48 embolectomies were performed on 43 patients, there being an embolus in both legs in 5 cases. Nyström (1936) reported 39 embolectomies done on 35 patients at his clinic in Uppsala (1922-1934). It is of interest that 50 per cent of these went home with restored circulation. The most frequently involved sites of operated embolism of the extremities according to Nyström's collection of 382 Swedish cases are: femoral (54.5 per cent), iliac (17.3 per cent), axillary and brachial (11.8 per cent), and popliteal (11.3 per cent) (see Table VI). Strömbeck's (1935-1936) summary of the late results of 327 peripheral embolectomies performed in Sweden is noteworthy. Of these, 63 per cent died in the hospital, 18 per cent were discharged improved after amputation, and 19 per cent had good circulation on discharge. Of these latter, three-fourths remained alive after one year, one-half after three years, one-third after five years, and one-eighth after ten years. Strömbeck reiterated what

TABLE VI

RESULTS OF EMBOLECTOMY IN 382 SWEDISH CASES (NYSTRÖM)

SITE	DISCHARGED SURVIVING				DIED IN HOSPITAL		TOTAL
	WITH RESTORED CIRCULATION		AFTER AMPUTATION				
	NO.	PER CENT	NO.	PER CENT	NO.	PER CENT	
Axillary artery, Brachial artery	20	44.4	9	20.0	16	35.5	45
Ulnar artery	--	--	--	--	1	--	1
Aortic bifurcation	3	17.7	--	--	14	82.3	17
Iliac artery	10	15.1	13	19.7	43	65.2	66
Femoral artery	43	20.7	32	15.4	133	63.9	208
Popliteal artery	9	20.9	14	32.6	20	46.5	43
Tibial artery	1	--	1	--	--	--	2
Total	86	22.5	69	18.1	227	59.4	382

has been pointed out before that this short survival period is accounted for by three factors: age of the patients, character of the underlying cardiac condition, and tendency to develop new embolisms. Hindmarsh and Sandberg (1936) summarized 45 embolectomies performed in Einar Key's Clinic on 40 patients from 1912 to 1934. The majority (77 per cent) were suffering from heart disease. The local object of the operation was attained 23 times (51 per cent) and of these, 17 (38 per cent) were discharged alive. Of the remaining patients, 10 were discharged alive despite amputation. Olovson (1938) reported 8 peripheral arterial embolectomies. In 3 brachial operations success was attained in 2, while in the third amputation was required with resultant death. Four femoral embolectomies gave 2 good results and 2 deaths from general causes. One popliteal embolectomy was followed by death in ten days from cerebral embolism. Thus, in this series, in 5 patients circulation was restored (62 per cent) and 4 patients were discharged from the hospital free from symptoms (50 per cent). Results in other Swedish cases are shown in Table VII.

In this country, Linton (1937) reported 44 cases of acute arterial occlusion (40 emboli and 4 thrombi) in 36 patients seen at the Massachusetts General Hospital, including 1 case reported by Allen in 1929. Only 67 per cent of 30 of these cases of acute arterial obstruction studied by Linton (1937) gave a history of sudden severe pain in the patient. This agreed with the statistics of McKeehnie and Allen (1935), who found that pain was the initial symptom in only 54 per cent of the cases they studied. In this series, 12 embolectomies in eight years (including one of Allen, reported in 1929) were performed with 4 recoveries. Fifteen patients were treated by pavaex with 9 recoveries.

Griffiths (1940) reported that from 1925 to 1940, he and Jefferson had seen 21 patients with 27 peripheral emboli within forty-eight hours of onset of symptoms. On 16 of these patients, 20 embolectomies were performed. The results included 8 complete failures (postoperative gangrene or death), 1 incomplete failure (limited gangrene), and 11

TABLE VII

RESULTS OF PERIPHERAL EMBOLECTOMY*

AUTHORS	NUMBER OF CASES				MORTALITY PERCENTAGE	PERCENTAGE OF SUCCESS
	DISCHARGED ALIVE		DIED IN HOSPITAL	TOTAL		
	WITH GOOD CIRCULATION	AFTER AMPUTATION				
Swedish cases, except Key (1935)	61	59	207	327	63	19
Key (1935)	17	10	18	45	40	38
Lund (1937)	10	5	12	27	44	37

*Classification as in Papers in Acta Chirurgica Scandinavica, 1935

successes (complete restoration of circulation). The successes included 4 instances of upper limb embolism, the same number of lower limb embolisms, and 3 instances of successful aortic embolectomy.

In their review of 25 patients with peripheral arterial embolism seen at the Cook County Hospital from 1928 to 1938, Koucky, Beck and Hoffman (1940) reported 3 embolectomies with 3 deaths. One of these was a femoral embolectomy while the other two were emboli at the aortic bifurcation, with transperitoneal embolectomies. One of these latter 2 patients lived forty-two hours despite continued gangrene of the legs, while the other lived thirty-six hours with pulse return in one day. Murray (1941) reported 26 embolectomies done in conjunction with the use of heparin. Of Pratt's (1942) series of 12 embolectomies, 5 survived, a mortality of 41.6 per cent. Dickinson (1942) presented 6 cases of embolectomy with 1 recovery, that in an instance of embolism of the common iliac artery.

TABLE VIII

COLLECTED CASES OF PERIPHERAL ARTERIAL EMBOLECTOMY

AUTHOR	NO. OF CASES
Key (1922)	45
Jefferson (1925)	73
Petitpierre (1928)	118
Key (1929)	216
Andrews and Harkins (1932)	268
Pearse (1933)	286
Valdoni (1935)	333
Strombeck (1935)*	327
Nyström (1936)*	382
Groth (1936)	535
McClure and Harkins (1943)†	690

*Swedish cases only.

†Groth's collection plus Murray (1941), 26 cases, Lund (1937), 27 cases, Griffiths (1940), 14 cases (20 less 6 reported by Jefferson in 1941), Pratt (1942), 12 cases, Graham (1937), 10 cases; Olovson (1938) [illegible] Wilander (1941), 8 cases, McClure and Harkins (1943), 6 [illegible] 6 cases DeTakats [illegible] cases each by Collins (1936), 5 cases, Linton (1937), 4 cases, L[illegible] [illegible]ardo (1938), 2 cases and Wilensky (1937), and single cases by [illegible] [illegible]rill (1938), Duncan by Heanley (1939), [illegible] (1938), Stevenson (1938), Burnett (1939), McMaster (1939), Lanier and Cleland (1940), Hughes and Berry (1940), Groth (1940), MacFarlane (1940), Hancroft and Glick (1941), Brunkow (1941), Marshall and Vary (1942), and McGhie (1942)

Additional cases collected from the literature by Loeb and Funck-Brentano (1937) may not be included.

Successful femoral cases were reported by Blackburne (1938) and Wardle (1938). A successful popliteal case was reported by Duncan (1938). Larks (1934), Brunkow (1941), and McGhie (1942) also reported a successful case. Single cases were described by Banks (1934) and Scott (1934) while Zierold (1933) reported 11 cases, and Lesser (1943) described 4 cases. Sheen (1934) reported a case of bilateral embolectomy of the femoral arteries. Tanner and Cleland (1940) reported a successful axillary embolectomy in a woman aged 57 years. These authors used no heparin.

The largest collected series is that of Groth (1936) who gathered 535 cases of peripheral arterial embolectomy from the literature. In 1939, Groth reported that 46 embolectomies were performed at the surgical clinic in Uppsala from 1922 to 1939. Our own collected series numbers 690 and is based on Groth's collection as shown in Table VIII.

Several of our own case reports follow.

CASE 9.—E. B., a man, aged 59 years, had known arteriosclerosis and auricular fibrillation. On the morning of April 20, 1940, he developed sudden pain in the abdomen, followed shortly thereafter by localization in the left leg and hip. He was brought to the hospital. Examination revealed an absent left femoral pulse and sensory loss below the inguinal ligament on the left side. A diagnosis of embolus of the left iliac artery was made and embolectomy was performed under local anesthesia by another surgeon ten hours after lodging of the embolus. No sympathetic block was used, but heparin was given postoperatively.

Operation.—The common femoral artery was exposed just at the point of division into the superficial and deep branches. The embolus lay at the bifurcation and extended down into the superficial femoral, but the deep femoral was free. The common femoral was better exposed by incising Poupart's ligament and a 2 cm. longitudinal incision made in the artery. About 12 cm. of clot was removed and a moderate rush of blood came from the proximal end of the artery. The holding sutures in the artery wall were approximated, a piece of sartorius muscle placed over them, and a second row of Lembert sutures inserted. Heparin was injected in the artery. The return of pulsation in the common femoral artery was only moderate, while in the superficial femoral it was practically absent. The patient died 26 hours after operation with increasing gangrene of the left leg.

It is believed that this patient either developed new emboli, or the previous ones were incompletely removed at operation.

CASE 10.—T. B., a man, aged 41 years, was ill for one week with a temperature of 104° F. and weakness. He awoke at 4 A.M. on May 1, 1935, with pain and numbness in the right hand and fingers. There was marked discoloration of the hand and absent pulse at the wrist with normal pulsation at the elbow. The patient was first taken to another hospital and then transferred to ours. The arm was placed in the pavnex machine with some very slight improvement, but embolectomy was decided upon and was done by one of us (R. D. McC.) at 11 P.M., nineteen hours after the accident.

Operation.—The bifurcation of the brachial artery was exposed under local anesthesia. Pulsation was visible down almost to the bifurcation, but none below. A longitudinal incision was made into the artery and a clot extending into both the

ulnar and radial branches was removed. The clot was not adherent, but it was thought at the time of operation that a piece may have broken off and gone into the radial artery.. The ulnar remained clear. After irrigation of the main wound with salt solution, the arteriotomy wound was closed. Pulsation immediately came through after removal of the clamp and was felt plainly in the ulnar artery, but not in the radial. The color of the hand improved for a time but never became normal so that amputation in the upper third of the right forearm was performed one week later. The patient was improved when last seen three months after operation. A history of pain in the calves of the legs on walking as well as a positive finding of lead in the urine at that time are the only leads as to the causation of the embolus or thrombus.

Earlier operation might have saved this patient but that is uncertain. He was treated in the days before heparin and so did not have the advantage of that type of therapy.

Results of Operation.—The ideal result includes a return of the limb and of its pulse to normal. Tardy recovery of the pulse after successful embolectomy is not uncommon, as pointed out by Ridell (1935) and Griffiths (1938). Deitch (1936) removed an embolus in the left leg, but the pulse did not return. Schein (1935) stated that an ideal embolectomy should result in recovery of the pulse. If Schein's criterion for a successful embolectomy that there must be a return of peripheral pulsations below the site of obstruction is adopted, it would be hard to explain the results of arteriectomy or certain cases collected by Danzis (1933). In Danzis' series, 10 patients with embolic obstruction to the upper extremity, observed six months or more after embolectomy, had perfect functional results, but no peripheral pulsations present in the healed limb. Mosny and Dumont (1911) noted a late return of the pulse in their otherwise successful case.

Other after effects of operation persist in certain cases. Glen (1941) reported the case of a temporary vascular occlusion ending fatally in uremia. Persistence of ischemic neuritis after an otherwise successful arterial operation was described by Schein (1935) after arteriectomy for embolism of the brachial artery. One month postoperatively there was still evidence of hypalgesia and hypesthesia as well as of diminished position and vibration sense in the hand except in the distribution of the ulnar nerve which recovered first. In two of Griffiths' (1940) successful cases of embolectomy and in one case which became a failure—three in all—contractures developed, one of the hand and forearm, two of the calf and foot. In these cases the vein was not involved and Griffiths concluded: "Volkmann's contracture is due to arterial occlusion and to nothing else." DeTakats (1936) reported that he had under observation five patients who had survived leg embolism without gangrene and without embolectomy. Such extremities are pulseless and atrophic, the muscle contracted and fibrosed, and the skin scaly and mottled. Allen and MacLean (1935) reported success in a case of embolism of the right leg.

A few hours later, however, the left leg became occluded and neither papaverine nor pavaex was successful.

Reports of two illustrative cases follow, one an example of complete return of function and of pulse, the other an example of almost complete functional return with practically no restitution of the pulse.

CASE 11.—C. G., a woman, aged 76 years, with hypertension, arteriosclerosis, and auricular fibrillation had a sudden attack of pain, pallor, and coldness of the left leg. Pulsation was absent below the left inguinal ligament. Operation was performed several hours later, on April 26, 1942, with a diagnosis of embolism of the left femoral artery.

Operation (H. N. H.).—The operation was performed under local anesthesia. First the patient was given a paravertebral injection on the left side. The resultant temperature rise was very slight, if perceptible at all. The paravertebral injection consisted of 10 c.c. of 2 per cent novocain into each of the spaces opposite the transverse processes of the first four lumbar vertebrae on the left side by the method advised by Leriche and by Ochsner. The patient was then placed on her back, and with local anesthesia, an oblique incision just below the inguinal crease was made, exposing the left femoral artery. This vessel did not pulsate at all below Poupart's ligament but above Poupart's ligament a definite pulsation was palpable. This indicated that the obstruction was probably just above and that a positive Nordentoft's sign was present. A vertical incision 1 cm. long was made in the artery, revealing it to be in fairly good condition, as far as the wall was concerned, although there was some arteriosclerosis. There was a very slight flow of blood from the distal portion of the artery but no pulsation. No blood came from the proximal end of the artery. Inserting a catheter and later a uterine probe upward, we finally dislodged a hard embolus about 1.5 cm. long and 8 mm. in diameter, which appeared to be an organized clot, probably from the heart. (See Fig. 5.) This was followed by an extensive pulsatile flow of blood, which went several feet across the table.



FIG. 5.—Embolus from femoral artery of C. G., Case 11, April 26, 1942.

At the same time, the distal portion of the artery showed a more prompt flow of blood. The incision in the artery was then closed with continuous fine silk in two layers. Immediately, following the closure, 2 c.c. of heparin were injected into the artery just above the suture line. The wound was then closed superficially, using silk throughout in the usual manner. Immediately after the operation, the popliteal and tibialis anterior pulsations were as marked as on the normal side and the temperature of the leg had markedly improved.

Immediately after operation the foot became warm and all pulses returned. On the eighth postoperative day the patient was able to get out of bed and walked without a limp. She was entirely well as far as the left leg was concerned when last seen on July 31, 1943, fifteen months after operation.

CASE 12.—G. G., a colored man, aged 39 years, had an old mitral stenosis and auricular fibrillation. He was admitted to the hospital on Nov. 16, 1940, with de-

Fig. 6.——Emboli from femoral artery of G. G., Case 12.

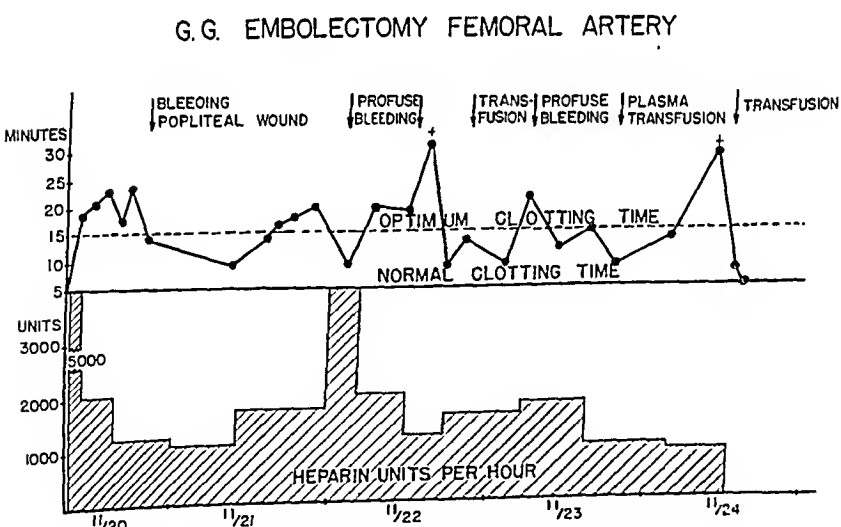

Fig. 7.—Heparin chart of G. G., Case 12. (We are indebted to Dr. C. R. Lam for preparation of this chart.)

compensation and four days later developed a sudden pain in the left leg and foot, with pallor and coldness. A diagnosis of popliteal embolus was made because of the presence of a femoral pulse. It was later found that the pulse was not present except as transmitted down from the iliac (positive Nordentoft's sign). A left paravertebral sympathetic novocain injection was done without much relief so operation was performed four hours after the accident.

Operation (H. N. H.).—A vertical incision over the popliteal fossa exposed the popliteal artery which was opened. No clot was found but no blood flow was present. A catheter introduced upward to its full length encountered no obstruction, so the arteriotomy and superficial wounds were closed and a vertical incision was made over the femoral artery. This was opened longitudinally and no blood flow was encountered. A catheter was passed upward 6 cm. and met an obstruction. The catheter was removed quickly with a piston action and on the second attempt the

Fig. 8.—Patient G. G. several weeks after embolectomy, standing on left, operated leg. There is slight swelling of the left ankle visible in the photograph.

clots (Fig. 6) came out after the catheter with a big rush of blood and landed 18 inches away from the wound. The catheter now passed freely and the arteriotomy wound was closed with two rows of continuous fine silk.

At the end of the operation there was only a slight relative coldness of the left foot instead of 8° F. difference as before. Arterial pulsation could be felt down as far as the adductor tubercle below Hunter's canal but not further. Heparin was started during the operation (Fig. 7). The left foot improved and although the

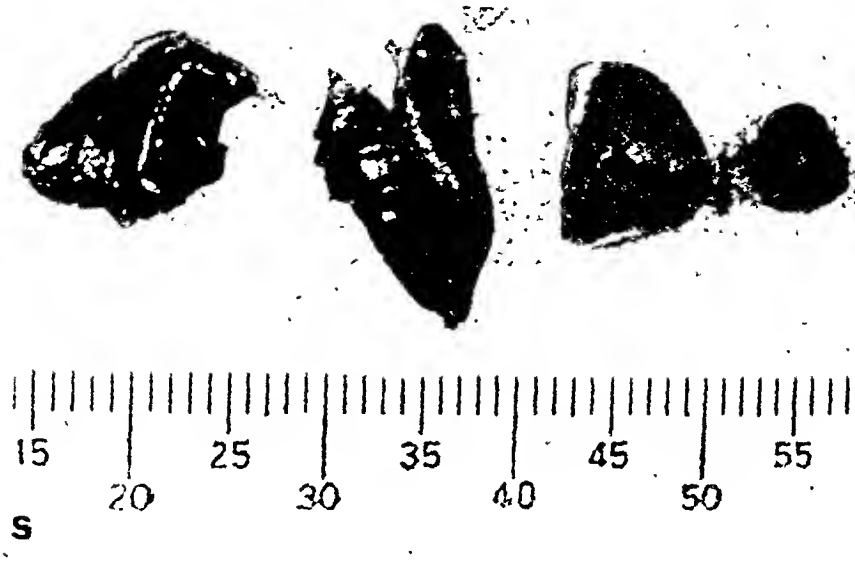

Fig. 6.——Emboli from femoral artery of G. G., Case 12.

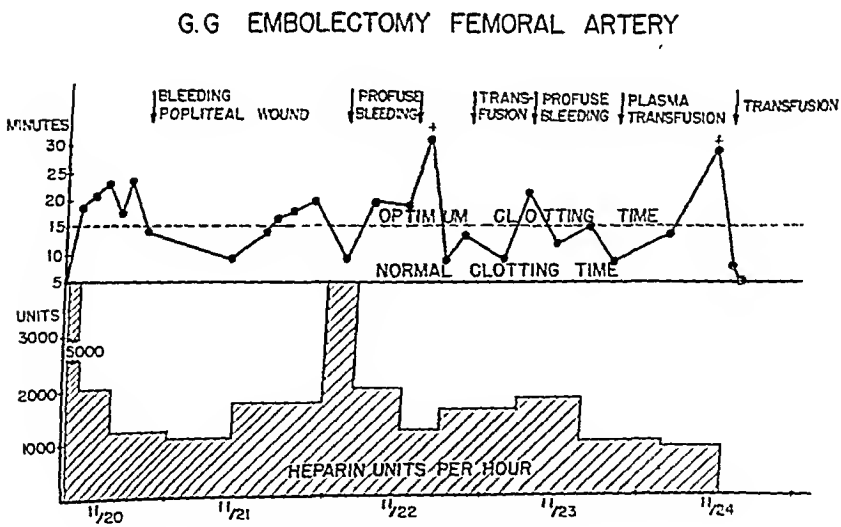

Fig. 7.—Heparin chart of G. G., Case 12. (We are indebted to Dr. C. R. Lam for preparation of this chart.)

compensation and four days later developed a sudden pain in the left leg and foot, with pallor and coldness. A diagnosis of popliteal embolus was made because of the presence of a femoral pulse. It was later found that the pulse was not present except as transmitted down from the iliac (positive Nordentoft's sign). A left paravertebral sympathetic novocain injection was done without much relief so operation was performed four hours after the accident.

and supplemented by lumbar sympathetic novocain block, papaverine, and heparin seems to be the best treatment for lower extremity embolism. Conservative management is advised in most instances of arm embolism. Arteriectomy or amputation should be reserved for difficult or late cases. Heparin acts rather to make more early embolectomies successful, than to prolong greatly the time after which operation can be performed.

3. Ten cases are presented of embolectomy or thrombectomy done at the Henry Ford Hospital as well as one additional instance of attempted embolectomy. Two of these represent undoubted thrombectomies and the patients should not have been operated upon (Cases 1 and 2). Of the remaining 8 cases, 1 was a complete success (Case 11), 1 a complete success but the patient died of cerebral embolism over a year later (Case 5); 1 had a recovery of the limb but not of the pulse and died of pulmonary embolism eight months after operation (Case 12). Two patients with embolectomy as well as the one with attempted embolectomy had to have subsequent amputation and recovered (Cases 7, 8, and 9), while 3 patients died (Cases 4, 6, and 9). The results in this series are not as good as some of those reported in the literature but are representative of the difficulties encountered in this condition.

4. Twenty-one successful aortic embolectomies reported in the literature are reviewed.

REFERENCES

1. Åkesson, N.: Ein Beitrag zur Behandlung der Arterienembolien, Acta chir. Scandinav. 79: 576-580, 1937.
2. Allen, A. W.: The Surgical Treatment of Embolism of the Extremities, New England J. Med. 201: 304-307, 1929.
3. Allen, E. V., and MacLean, A. R.: Treatment of Sudden Arterial Occlusion With Papaverine Hydrochloride: Report of a Case, Proc. Staff Meet., Mayo Clin. 10: 216-220, 1935.
4. Andrews, E., and Harkins, H. N.: Embolectomy: Report of a Case Involving the Femoral Artery, Ann. Surg. 96: 40-43, 1932.
5. Antonioli, F. (1929): Cited by Haimovici.[75]
6. Atlas, L. N.: The Management of Acute Embolic Occlusion of the Arteries to the Extremities, Surg., Gynec. & Obst. 74: 236-239, 1942.
7. Baillat: Cited by Leriche, Froment, and Vachon.[110]
8. Bancroft, F. W.: Use of Anticoagulants in Cases of Postoperative Thrombosis and Embolism, Arch. otolaryng. 32: 934-940, 1940.
9. Bancroft, F. W., and Glick, A. H.: Arterial Embolectomy, Ann. Surg. 114: 1093-1095, 1941.
10. Banks, A. G.: Treatment of Arterial Embolism, Brit. M. J. 2: 219, 1934.
11. Bauer, Fritz: Fall von Embolus aortae abdominalis, Operation, Heilung, Zentralbl. f. Chir. 40: 1945-1946, 1913.
12. Bedrna, Jan: Die Behandlung von Embolien grosser Beinarterien mittels lumbaler Sympathektomie, Zentralbl. f. Chir. 63: 92-100, 1936.
13. Bérard: Traitement chirurgical des arterites aiguës et localisées des membres, Thèse de Lyon, December, 1909: Cited by Hesse.[83]
14. Bernard, R.: Cited by Leriche, Froment, and Vachon.[110]
15. Bernard, R.: Cited by Haimovici.[75]
16. Blackburne, J. R.: A Successful Femoral Artery Embolectomy, Brit. M. J. 1: 730, 1938.
17. Blackemore, A. H., Lord, J. W., Jr., and Stefko, P. L.: Restoration of Blood Flow in Damaged Arteries, Ann. Surg. 117: 481-497, 1943.
18. Brooks, B.: Ligation of the Aorta: An Experimental Study, Tr. South. S. A. 39: 228, 1926.

pulsations below the knee never returned and the patient walked with a slight limp, he had a useful leg as shown in Figs. 8 and 9. Because of some causalgia-like pain in the left foot, two left lumbar novocain blocks were done with an interval of three days one month after operation with improvement. There was a definite (2° F.) but slight relative increase in temperature of the left foot each time. The patient was improved until July 7, 1941, when he died from a pulmonary embolus.

Fig. 9.—Front view of same.

SUMMARY AND CONCLUSIONS

1. A series of 690 peripheral arterial embolectomies reported in the literature is reviewed. This study re-emphasizes the need for prompt diagnosis and early treatment.

2. Early peripheral arterial embolectomy (preferably under twelve hours from the time of the accident) performed under local anesthesia

51. Edwards, E. A.: Nonarterial Disorders Simulating Disease of the Peripheral Arteries, New England J. Med. 225: 91-101, 1941.
52. Edwards, F. R.: Femoral Embolectomy, Brit. M. J. 1: 90-91, 1938.
53. Ferey, D.: Embolie de l'artère axillaire à sa partie moyenne et de l'artère humérale gauche. Sympathectomie axillaire. Artérectomie humérale. Gangrène de la main et de l'avant-bras. Désarticulation du coude, Bull. et mém. Soc. nat. de chir. 61: 546 548, 1935
54. Fiolle, J., and Funck-Brentano, P.: Les Embolies Artérielles des Membres: Physiologie Pathologique et Traitement, Proc. 46th Congrès Français de Chirurgie, Oct. 1937, pp. 109-312.
55. Finch, E.: Treatment of Arterial Embolism, Brit. M. J. 2: 219, 1934.
56. Fischer, A., and Astrup, T.: On the Administration of Heparin *Per Os*. Proc. Soc. Exper. Biol. & Med. 42: 81-82, 1939.
57. Fontaine, R.: Cited by Funck-Brentano.[58]
58. Funck-Brentano, P.: Traitement des embolies artérielles des membres, Rev. de méd., Paris 55: 431-452, 1938.
59. Gage, M., and Ochsner, A.: The Prevention of Ischemic Gangrene Following Surgical Operations Upon the Major Peripheral Arteries by Chemical Section of the Cervicodorsal and Lumbar Sympathetics, Ann. Surg. 112: 938-959, 1940.
60. Gallavardin: Artérectomie pour embolie, Lyon méd. 154: 419, 1934.
61. Garvin, C. F.: Mural Thrombi in the Heart as a Source of Emboli, Am. J. M. Sc. 201: 412-415, 1941.
62. Geisthövel, W.: Venose und arterielle Embolie, Med. Klin. 34: 1592-1595, 1938.
63. Girdlestone, G. R.: Arterial Embolism, Brit. M. J. 2: 1231-1232, 1935.
64. Glen, Allan M.: Temporary Vascular Occlusion Ending Fatally in Uraemia, Brit. M. J. 2: 875 876, 1941.
65. Gohrbandt, E.: Erfolgreiche Embolektomie aus der Bauchaorta, Deutsche med. Wchnschr. 59: 15 16, 1933.
66. Graham, D.: Embolism and Thrombosis of the Larger Arteries: Their Diagnosis and Treatment, Canad. M. A. J. 36. 33-38, 1937.
67. Grégoire: Cited by Leriche, Froment, and Vachon.[110]
68. Grégoire, R.: Conduite a tenir dans l'embolie artérielle des membres: Embolie "manqués"; Embolectomie "manquée"; Guérison totale, Paris méd. 29: 217 219, 1939.
69. Griffiths, D. Ll.: Arterial Embolism: A Study of Eight Cases, Lancet 2: 1339-1344, 1938.
70. Griffiths, D. Ll. Volkmann's Ischaemic Contracture, Brit. J. Surg. 28: 239 260, 1940.
71. Groth, K. E. (1936: Cited by Olovson.[135]
72. Groth, K. E.: Einige Fälle von rezidivierender Arterienembolie in der Extremitaten, Arch. f. klin. Chir. 194: 413-457, 1939.
73. Groth, K. E.: "Melkung" oder intraarterielle Eingriffe bli Embolien des grossen Kreislaufs mit schwer zugänglicher Lokalisation, Chirurg. 11: 73 83, 1939.
74. Groth, K. E.: Tumor Embolism of the Femoral Artery, Treated by Embolectomy and Heparin, Surgery 8: 617 632, 1940
75. Hannovier, H.: Les embolies artérielles des membres, Paris, 1937, Masson & Cie, p. 336.
76. Handley, W. S.: An Operation for Embolus, Brit. M. J. 2: 712, 1907.
77. Harkins, H. N.: Embolectomy. Report of Two Attempts on the Same Patient, Ann. Surg. 99: 555 556, 1934.
78. Harvey, S. C., and Halpert, B.: Studies on Collateral Circulation. II. Thermic Changes After Arterial Ligation, Section of Spinal Cord or Posterior Roots and Ganglionectomy, J. Clin. Investigation 10: 131-434, 1931.
79. Heanley, C. L.: Arterial Embolectomy, Lancet 1: 696 697, 1939.
80. Heidrich, L.: Ueber Ursache und Haufigkeit der Nekrose bei Ligaturen grosser Gefässstamme. Beitr. z. klin. Chir. 124: 607-638, 1921.
81. Henschen, C.: Zur Technik der arteriellen Embolektomie (Durchspülung der Gefässperipherie nach Entfernung des Embolus), Helvet. med. acta 2: 216 220, 1935
82. Herrmann, L. G.: Passive Vascular Exercises and the Conservative Management of Obliterative Arterial Diseases of the Extremities, Philadelphia, 1936, J. B. Lippincott Co.

19. Brooks, B: Ligation of the Aorta: A Clinical and Experimental Study, J. A. M. A. 87: 722 725, 1926.
20. Brooks, B., Blalock, A., and Johnson, G S: Ligation of the Terminal Abdominal Aorta: An Experimental Study, Arch. Surg 17: 794 812, 1928
21. Brunkow, B. H.: Embolic Vascular Accidents of the Extremities, Am J Surg. 53: 440 443, 1941.
22. Bull, P.: What Can More Than 6000 Postmortem Examinations Teach Us About Emboli and Embolic Gangrene of the Extremities? Acta chir. Scandinav. 54: 315 338, 1921-1922.
23. Burnett, W. E: Acute Arterial Occlusion of the Extremities, Am J Surg 44: 25-30, 1939.
24. Carcassonne: Cited by Jeanneney and Dargent.[8]
25. Carling, R.: Treatment of Arterial Embolism, Brit M J. 2: 219 220, 1934
26. Collens, W. S, and Wilensky, N D: Intermittent Venous Occlusion in Treatment of Peripheral Vascular Disease An Experience With One Hundred and Twenty-Four Cases, J. A M A 109: 2125 2130, 1937.
27. Conway, J. H.: Obliterative Vascular Disease: Report of Fifty One Cases Treated With Passive Vascular Exercise, J A M. A 106. 1153 1156, 1936.
28. Crafoord, C.: Preliminary Report on Post Operative Treatment With Heparin as a Preventive of Thrombosis, Acta chir Scandinav 79. 409 426, 1937.
29. Crowe, G. G: Complete Blockage of the Pulmonary Blood Supply Occurring During Common Iliac Embolectomy, Brit J Surg. 29: 441 442, 1942
30. Culmone, G. B.: Successful Aortic Embolectomy: Cited in Quart Cum Ind Med. 29: 361, 1941.
31. Danzis, M.: Arterial Embolectomy, Ann Surg 98: 249 272, 422 437, 1933
32. Danzis, M., and Golden, C H: Right Axillary Embolectomy Recovery With Recurrence One Month Later, J A M A 102: 1926 1929, 1934
33. Danzis, M.: Treatment of Arterial Embolism, Brit M J 2: 219, 1934.
34. DeBakey, M, Burch, G. E, and Ochsner, A: Effect of Chemical Irritation of a Venous Segment on Peripheral Volume, Proc Soc Exper. Biol & Med. 41: 585 590, 1939
35. Deitch, H. I.: Three Arterial Embolectomies in the Same Patient Including One in Each Femoral Artery, Lancet 1: 475 477, 1936
36. Denk, W: Zur Behandlung der arteriellen Embolie, Munchen med. Wchnschr. 81: 437 439, 1934
37. DeTakats, G: Obliterative Vascular Disease Preliminary Report on Treatment by Alternating Negative and Positive Pressures, J. A M A 103: 1920 1924, 1934.
38. DeTakats, G: The Use of Papaverine in Acute Arterial Occlusions, J. A. M. A 106: 1003 1005, 1936
39. DeTakats, G: Acute Arterial Occlusions of Extremities, Am J. Surg 33. 60 67, 1936
40. DeTakats, G, Hick, F. K, and Coulter, J S Intermittent Venous Hyperemia in the Treatment of Peripheral Vascular Disease, J A M. A 108: 1951-1959, 1937.
41. DeTakats, G: Surgical Treatment of Acute Vascular Occlusions, S Clin North America 22: 199 220, 1942
42. DiPalma, J. R, Muss, J, and Foster, F I A Reactive Hyperemia Ring Test in the Study, Evaluation, and Prognosis of Pedal Lesions Caused by Arteriosclerosis Obliterans and Arterial Embolism, Am Heart J 24: 345 364, 1942
43. Dickinson, A M: Embolism of the Peripheral Arteries Report of Six Cases, Am. J. Surg. 57: 508-512, 1942
44. Doberauer (1907): Cited by Hesse[83]
45. Drevermann, P. Beitrag zur operativen Behandlung des Embolus Aortae abdominalis, Deutsche Ztschr. f Chir 230: 147 152, 1931
46. Duncan, G. H. Popliteal Embolectomy, Brit M J 1. 1157, 1938
47. Editorial. Arterial Embolectomy, Lancet 1. 33, 1936
48. Editorial: The Surgery of Embolism, Lancet 2: 1365 1366, 1938
49. Editorial: Traumatic Arterial Spasm, Lancet 2. 806, 1941
50. Edwards, E A: Treatment of Organic Arterial Obstruction by Alternating Suction and Pressure A Device to Relieve Incidental Arteriospasm, J. A. M. A. 108: 626 628, 1937.

119. Linton, R. R.: Peripheral Arterial Embolism, New England J. Med. 224: 189-194, 1941.
120. Linton, R.: Treatment of Acute Arterial Occlusion by Means of Intermittent Venous Occlusion—Report of a Case, Arch. Surg. 46: 395-403, 1943.
121. Lucia, S. P., and Aggeler, P. M.: Heparin and the Blood Coagulation Mechanism, Proc. Soc. Exper. Biol. & Med. 40: 41-45, 1939.
122. Lund, C. C.: The Treatment of Embolism of the Greater Arteries, Ann. Surg. 106: 880-909, 1937.
123. Lund, C. C.: Embolectomy for Peripheral Embolism, Surg., Gynec. & Obst. 69: 117, 1939.
124. Lyons, Champ: The Treatment of Staphylococcal Cavernous Sinus Thrombophlebitis With Heparin and Chemotherapy, Ann. Surg. 113: 113-117, 1941.
125. Mac Farlane, J. A.: Multiple Emboli Treated Surgically, Brit. M. J. 1: 971-972, 1940.
126. Makins (1922): Cited by Haimovici (1937).[75]
127. Marshall, W. H., and Vary, E. P.: Embolectomy of the External Iliac Artery: Case Report, J. Michigan M. Soc. 41: 856-859, 1942.
128. Mason, M. F.: Heparin: A Review of Its History, Chemistry, Physiology and Clinical Applications, SURGERY 5: 451-467, 618-637, 1939.
129. Mason, R. L., and Hurxthal, L. M.: Femoral Embolectomy, New England J. Med. 198: 277-280, 1928.
130. Mason, R. L., and Warren, S.: Embolism of the Abdominal Aorta, New England J. Med. 204: 1129-1133, 1931.
131. Matas, R.: Ligation of the Abdominal Aorta: Report of the Ultimate Result, One Year, Five Months and Nine Days After Ligation of the Abdominal Aorta for Aneurysm at the Bifurcation, Ann. Surg. 81: 457-464, 1925.
132. Mathieu, P., Gérard-Marchant, and Lance, P.: Embolie de l'artère fémorale gauche. Artériectomie fémorale. Échec expliqué par la présence d'un second embolus dans le tronc tibiopéronier et l'artère tibiale postérieure. Amputation de cuisse. Guérison, Bull. et mém. Soc. nat. de chir. 61: 552-553, 1935.
133. McClure, R. D., and Lam, C. R.: Experiences in Heparin Administration, J. A. M. A. 114: 2085-2089, 1940.
134. McGhie, A. G.: Embolism Resulting from Cardiac Disease, McGregor Clinic Bull. 4: 3-6, 1942.
135. McKechnie, R. E., and Allen, E. V.: Sudden Occlusion of the Arteries of the Extremities: A Study of One Hundred Cases of Embolism and Thrombosis, Proc. Staff Meet. Mayo Clin. 10: 678-682, 1935.
136. McMaster, A. M.: Arterial Embolectomy: With Notes of a Case, Brit. M. J. 1: 441-443, 1939.
137. Meyer, Erich: Zur unblutigen Behandlung der arteriellen Embolie, Zentralbl. f. Chir. 67: 342-348, 1940.
138. Montgomery, A. H., and Ireland, J.: Traumatic Segmentary Arterial Segmentary Arterial Spasm, J. A. M. A. 105: 1741-1746, 1935.
139. Mosny, M., and Dumont, M. J.: Embolie fémorale au cours d'un rétrécissement mitral pur. Artériotomie. Guérison, Bull. Acad. de méd., Paris 66: 358-361, 1911.
140. Moynihan, B. G. A.: An Operation for Embolus, Brit. M. J. 2: 826, 1907.
141. Mulvihill, D. A., and Harvey, S. C.: Studies on Collateral Circulation. I. Thermic Changes After Arterial Ligation and Ganglionectomy, J. Clin. Investigation 10: 423-429, 1931.
142. Murphy, J. B.: Removal of an Embolus From the Common Iliac Artery, With Re-Establishment of Circulation in the Femoral, J. A. M. A. 52: 1661-1663, 1909.
143. Murray, G. D. W.: Embolism in Peripheral Arteries, Canad. M. A. J. 35: 61-66, 1936.
144. Murray, G. D. W., Jaques, L. B., Perrett, T. S., and Best, C. H.: Heparin and Vascular Occlusion, Canad. M. A. J. 35: 621-622, 1936.
145. Murray, G. D. W., and Best, C. H.: The Use of Heparin in Thrombosis, Ann. Surg. 108: 163-173, 1938.
146. Murray, G. D. W.: Heparin in Thrombosis and Embolism, Brit. J. Surg. 27: 567-598, 1940.

83. Hesse, E.: Ueber die Embolie und Thrombose der Aorta abdominalis und ihre operative Behandlung, Arch. f. klin. Chir. 115: 812-867, 1921.
84. Hindmarsh, J., and Sandberg, I.: 45 Embolectomies (Retrospective Survey With Special Regard to the After Results), Acta chir. Scandinav. 78: 81-93, 1936.
85. Hughes, J. F., and Berry, P.: A Case of Axillary Embolectomy, Lancet 2: 516-517, 1940.
86. Ipsen, J. (1931): Cited by Haimovici.[75]
87. Jeanneney, G., and Darget, R.: Embolie fémorale. Embolectomie tardive. Artériectomie. Mort, Mém. Acad. de chir. 63: 244-247, 1937.
88. Jefferson, G.: Report of a Successful Case of Embolectomy With a Review of the Literature, Brit. M. J. 2: 985-987, 1925.
89. Jefferson, G.: Treatment of Arterial Embolism, Brit. M. J. 2: 219-220, 1934.
90. Jessop, W. J. E.: The Clinical Bearings of the Parathyroids, Brit. M. J. 1: 989-991, 1938.
91. Jorpes, E.: Pure Heparin for the Prevention and Treatment of Thrombosis, Acta med. Scandinav. 107: 107-115, 1941.
92. Jorpes, E.: Heparin: Its Chemistry, Physiology and Application in Medicine, London, 1939, Oxford University Press.
93. Jouve: Cited by Leriche, Froment, and Vachon.[110]
94. Kaps, L., and Walzel, P.: Aortenembolie nach Trypaflavininjektion bei Endokarditis mit nachfolgender Embolektomie, Mitt. a. d. Grenzgeb. d. Med. u. Chir. 42: 569-577, 1930-31.
95. Key, E.: Über Embolectomi, Acta chir. Scandinav. 54: 339-416, 1921-1922.
96. Key, E.: Die Embolieoperationen auf grund der bishergen Erfahrungen, Ergebn. d. Chir. u. Orthop. 22: 1-94, 1929.
97. Key, E.: Embolectomy on the Vessels of the Extremities, Brit. J. Surg. 24: 350-361, 1936.
98. Koritschoner, R.: Paradoxical Embolism, J. A. M. A. 106: 1269-1270, 1936.
99. Koucky, J. J., Beck, W. C., and Hoffman, J. M.: Peripheral Arterial Embolism, Am. J. Surg. 50: 39-49, 1940.
100. Labey, G.: Case reported by Mosny and Dumont.[139]
101. Lahey, F. H.: The Treatment of Emboli in the Peripheral Vessels, S. Clin. North America 6: 651-666, 1926.
102. Lam, C. R.: Heparin Administration: Methods and Results in Thirty Cases, Ann. Surg. 114: 205-211; (abstr., ibid.) 113: 1085-1086, 1941.
103. Lam, C. R.: The Clinical Use of Heparin, West Virginia M. J. 38: 215-219, 1942.
104. Langeron: Cited by Leriche, Froment and Vachon (1934).[110]
105. Langley, G. J.: Treatment of Arterial Embolism, Brit. M. J. 2: 219, 1934.
106. Larks, G. E.: Treatment of Arterial Embolism, Brit. M. J. 2: 219, 1934.
107. Lejars, F.: De l'attrition sous cutanée directe des grosses artères, Bull. et mém. Soc. de Chir. de Paris 28: 609-619, 1902.
108. Leriche, R.: Conditions Dependont Upon Vasomotor Changes in Blood Vessels, Nelson's System of Surgery, vol. 3, New York, 1927, Thos. Nelson & Sons, 779-832.
109. Leriche (1924): Cited by Leriche, Froment, and Vachon (1934).[110]
110. Leriche, R., Froment, R., and Vachon, A.: Artériectomie pour embolie de l'artère fémorale superficielle. Rétrocession de tous les troubles, Lyon méd. 154: 416-419, 1934.
111. Leriche, R.: Cited by Pampari (1936).[160]
112. Leriche, R.: Cited by Jeanneny and Darget (1937).[87]
113. Leriche, R., Fontaine, R., and Dupertuis, S. M.: Arteriectomy: With Follow-up Studies on 78 Operations, Surg., Gynec. & Obst. 64: 149-155, 1937.
114. Lesser, A.: Embolic Arterial Occlusion of Lower Extremities, J. A. M. A. 122: 285-289, 1943.
115. Lilienthal, H.: End-to-End Arteriovenous Angeiorrhaphy, Ann. Surg. 45: 1-8, 1907.
116. Lindgren: Embolektomie aus der aorta abdominalis unter Ausnutzung des Heparineffektes, glücklich durchgeführt, Arch. f. klin. Chir. 196: 178-182, 1939.
117. Lindgren, S., and Wilander, O.: The Use of Heparin in Vascular Surgery, Acta med. Scandinav. 107: 148-160, 1941.
118. Linton, R. R.: Acute Peripheral Arterial Occlusion and Its Treatment, New England J. Med. 216: 871-875, 1937.

179. Scott, W. J. M.: Some Practical Problems in the Handling of Peripheral Arterial Disease, New York State J. Med. 34: 269-273, 1934.
180. Scupham, G. W.: Therapy of Arterial Thrombosis of the Extremities, J. A. M. A. 104: 1229-1232, 1935.
181. Sencert, L. (1923): Cited by Haimovici (1937).[75]
182. Severeanu: Du cathétérisme des artères, Progrès méd. 20: 89-90, 1894.
183. Sheen, A. W.: Treatment of Arterial Embolism, Brit. M. J. 2: 219, 1934.
184. Siegel, M. L., and Garvin, C. F.: Thrombosis and Embolism of the Abdominal Aorta: Report of a Case With Obstruction of the Renal Arteries, Ohio State M. J. 37: 750-751, 1941.
185. Soupault, R.: Embolectomy, Bull. et mém. Soc. nat. de. chir. 61: 548-552, 1935.
186. Ssabanejeff: On the Question of Blood Vessel Suture, Russk. Khir. Arch. 11: 625-639, 1895.
187. Stegemann (1933): Cited by Fiolle and Funck-Brentano (1937).[54]
188. Stevenson, D. L., and Walker, R. M.: A Modification in the Treatment of Extensive Varicose Veins, Lancet 1: 27-28, 1938.
189. Stevenson, D. L.: A Needle for Varicose Veins and Embolectomy, Lancet 1: 786, 1938.
190. Stevenson, D. L.: A New Technique in Embolectomy, Lancet 1: 723, 1938.
191. Stewart, Francis T.: Arteriotomy for Thrombosis and Embolism, Ann. Surg. 46: 339-349, 1907.
192. Strömbeck, J. P.: The Late Results of Embolectomy Performed on Arteries of the Greater Circulation (Sweden, 1913-1932), Acta chir. Scandinav. 77: 229-255, 1935-1936.
193. Tanner, N. C., and Cleland, W. P.: Arterial Embolectomy, Lancet 1: 30-31, 1940.
194. Tixier, L. (1907): Cited by Haimovici (1937).[75]
195. Usadel, W.: Ein durch Embolektomie geheilter Fall von Embolie der Aorta abdominalis im Bereiche der Bifurkation, Chirurg 3: 1002-1009, 1931, Cited by Fiolle and Funck-Brentano (1937)[54]
196. Usadel, W.: Embolektomie der Aorta abdominalis, Arch. f. klin. Chir. 173: 125-126, 1932.
197. Valdoni, P. (1935): Cited by Haimovici (1937).[75]
198. Villaret, M., and Justin Besançon, L. (1926): Cited by Funck-Brentano (1938).[58]
199. Wardle, E. N.: Femoral Embolectomy, Brit. M. J. 1: 90-91, 1938.
200. Welch, W. H., and Rolleston, H. D.: Embolism and Thrombosis of the Abdominal Aorta, Allbutt's System of Medicine, Vol. VI, London, 1909, The Macmillan Company, pp. 809-816.
201. Westerborn, A.: Zwei mit Erfolg operierte Fälle von wiederholten Arterienembolien, davon einen zweimal wegen Embolie in der Bifurkation der Aorta ohne Laparatomie, Zentralbl. f. Chir. 59: 322-328, 1932.
202. Wikle, H. T., and Cabot, N.: Embolectomy for Riding Embolus of Abdominal Aorta, Surgery 13: 264-269, 1943.
203. Wilson, H., and Roome, N. W.: Passive Vascular Exercise: Observations on Its Value in the Treatment of Peripheral Vascular Diseases, J. A. M. A. 106: 1885-1888, 1936.
204. Wolff: Cited by Haimovici (1937).[75]
205. Wreden (1913): Cited by Hesse (1921).[81]
206. Zierold, A. A.: The Surgical Treatment of Arterial Embolism, J. A. M. A. 101: 7-9, 1933.
207. Ziff, M., and Chargaff, E.: The Mechanism of Action of Heparin, Proc. Soc. Exper. Biol. & Med. 43: 740-742, 1940.

147. Murray, G. D. W.: Heparin in Surgical Treatment of Blood Vessels, Arch. Surg. 40: 307-325, 1940.
148. Murray, G. D. W.: Heparin in Thrombosis and Blood Vessel Surgery, Surg., Gynec. & Obst. 72: 340-344, 1941.
149. Murray, G. D. W.: Personal communication, Oct. 6, 1941.
150. Murray, G. D. W.: Aortic Embolectomy, Surg., Gynec. & Obst. 77: 157-162, 1943.
151. Neuhof, H.: Embolectomy With Partial Arterial Occlusion for Embolism of the Extremities, Ann. Surg. 96: 41-48, 1932.
152. Nordentoft, J.: To Tilfaelde af Embolectomi, Hospitalstid. 72: 55-60, 1929.
153. Nyström, G.: Zur Prognose und Methodik der Embolektomie, Acta chir. Scandinav. 60: 229-254, 1926.
154. Nyström, G.: Lectures on Embolism, Baltimore, 1936, Williams & Wilkins.
Nyström, G.: Die Heparinmedikation bei den Embolektomien, Arch. f. klin. Chir. 196: 182-183, 1939.
155. Olovson, T.: Bericht über 8 Embolektomien, nebst einigen Bemerkungen die Verhütung sekundärer Thrombenbildung, Acta chir. Scandinav. 81: 281-292, 1938.
156. Olovson, T.: Über die Anwendung von Heparin bei Arterienembolie: Eine experimentelle Untersuchung über die Blutungsverhältnisse bei Arteriotomie unter Heparinwirkung, Acta chir. Scandinav. 82: 487-498, 1939.
157. Östling, K. (1939): Cited by Groth (1939).[72]
158. O'Shaughnessy, L.: Treatment of Arterial Embolism, Brit. M. J. 2: 219, 1934.
159. Pal, J.: Das Papaverin als Gefässmittel und Anästheticum, Deutsche med. Wchnschr. 40: 164-168, 1914.
160. Pampari, D.: L'Arteriographie et l'artérectomie dans les lesions traumatiques des artères: Considérations sur un cas clinique de syndrome de Volkmann, Rev. de chir. 55: 481-501, 1936.
161. Pearse, H. E., Jr.: Embolectomy for Arterial Embolism of the Extremities, Ann. Surg. 98: 17-32, 1933.
162. Peiser, A.: Arterielle Embolie und Gefassspasmus, Arch. f. klin. Chir. 170: 30-38, 1932.
163. Pemberton, J. DeJ.: Embolectomy. Report of Three Cases, Ann. Surg. 87: 642-656, 1928.
164. Perlow, S.: Prostigmine in the Treatment of Peripheral Circulatory Disturbances, J. A. M. A. 114: 1991-1993, 1940.
165. Petitpierre, M.: Über Embolektomie der Extremitätenarterien, Deutsche Ztschr. f. Chir. 210: 184-238, 1928.
166. Pickrell, K.: Personal communication, July 18, 1943.
167. Pratt, G. H.: Surgical Treatment of Peripheral Embolism, Am. J. Surg. 56: 566-572, 1942.
168. Pridie, K. H.: Gangrene After Arterial Contusion, Lancet 1: 267-268, 1943.
169. Priestley, J. T., Essex, H. E., and Barker, N. W.: The Use of Heparin in the Prevention and Treatment of Postoperative Thrombosis and Embolism: A Preliminary Report, Proc. Staff Meet., Mayo Clin. 16: 60 64, 1941.
170. Ravdin, I. S., and Wood, F. C.: The Successful Removal of a Saddle Embolus of the Aorta, Eleven Days After Acute Coronary Occlusion, Ann. Surg. 114: 834 839, 1941.
171. Reid, M. R., and Andrus, W. DeW.: Surgery of the Arteries: Thrombectomy and Embolectomy, Nelson's System of Surgery, vol. 1, New York, 1927, Thos. Nelson & Sons, 683 685.
172. Reid, M. R., and Herrmann, L. G.: Treatment of Obliterative Vascular Diseases by Means of an Intermittent Negative Pressure Environment, J. Med. 14: 200-204, 1933.
173. Ridell, V.: Arterial Embolectomy in a Case of Brachial Embolism, Lancet 2: 1230-1231, 1935.
174. Roome, N. W.: Sympathetic Blockade in Peripheral Vascular Accidents, Canad. M. A. J. 44: 594-596, 1941.
175. Rosenqvist, H.: The Usefulness of Heparin in Combatting Arterial Embolism and Thrombotic Complications, Acta med. Scandinav. 107: 161 164, 1941.
176. Schein, A. J.: Embolism of the Brachial Artery, J. Mt. Sinai Hosp. 2: 103 108, 1935.
177. Schmorell, H.: Erfolgreiche Operation bei reitendem Embolus auf der Aortenbifurkation, Arch. f. klin. Chir. 177: 147-148, 1933.
178. Schmorell, H.: Erfolgreiche Operation bei reitendem Embolus auf der Aortenbifurkation, Zentralbl. f. Chir. 60: 1509-1510, 1933.

Frank C. Hamm, Major, Army U. S., Cambridge, Ohio, discussed the organization, construction, and operation of an Army General Hospital in a very instructive manner. The chief urological problem in such hospitals is, of course, gonorrhea It was Hamm's opinion that sulfathiazole is as effective as any other sulfonamide and that, if a dosage of 6 Gm. daily does not yield a cure in three days, it is best abandoned. Eighty per cent of sulfonamide resistant cases have responded to a combination of sulfathiazole and a therapeutic fever of 105° in the cabinet for five hours

After gonorrhea, stones and congenital anomalies are the commonest urogenital disorders in troops not in combat.

Clyde Deming, New Haven, reviewed his experience with lesions of the urinary tract which disqualified men under selective service. Stones were most frequent, but hydronephrosis, pyelonephritis, tuberculosis, and post traumatic disorders were not rare.

E. G. Crabtree of Boston described an instance of a teratoma primary in the epididymis. This tumor is thought to arise in cell rests from the genital ridge, included in the epididymis during development. Crabtree found ninety-two cases in the literature.

The meeting on June 11 included the following:

J. C. McClelland of Toronto, and **J. K. Ormond** of Detroit both discussed fatal cases of anuria from sulfathiazole in which the renal tubules exhibited at necropsy, not crystals, but degenerative changes and vascular thromboses thought to be toxic in origin.

R. C. Graves, Boston, castrated a patient with an undifferentiated carcinoma of the prostate with metastases after subjecting the gland and the involved supraclavicular lymph nodes to biopsy. Stilbestrol was also given. Seven months later the patient felt well and had gained twenty pounds, while the prostate was smaller and softer Biopsy of the involved nodes showed histologic evidence of regression. This is interesting because it has been suggested that, if the serum phosphatase is normal (as in this case) or if the tumor is undifferentiated, therapy with castration or estrogens is likely to fail

In the ensuing discussion, **Herman** also reported success from castration in an anaplastic prostatic cancer **Nesbit** has had 60 per cent of "delayed failures" (recurrences) after castration, and believes that, since the duration of its good effects is limited, it should not be used until the occurrence of pain demands it.

Hugh H. Young of Baltimore, and **G. R. Livermore** of Memphis each reported surgical cures of nonfilarial elephantiasis of the scrotum from excision of enormous amounts of tissue Dr Young's presentation was accompanied by an excellent motion picture, in kodachrome, of the operation

P. B. Hughes (Philadelphia) described a method of studying peristalsis in the intact, undisturbed ureter, an unusual achievement Diodrast is given intravenously with the patient in the Trendelenburg position, and a segment of the ureter is photographed periodically through a slit, on adjoining segments of film by means of the urokymograph. The frequency and amplitude of the peristaltic waves can be measured. The method, if consistently successful, seems to offer great possibilities in the study of the effects of drugs and diseases upon ureteral peristalsis.

E. L. Keyes, New York, reported an unusual case in which cutaneous ureterostomy was performed in a physician with tuberculosis in a solitary kidney. He led

Review of Recent Meetings

MEETING OF THE AMERICAN ASSOCIATION OF GENITO-URINARY SURGEONS AT STOCKBRIDGE, MASS., JUNE 10-12, 1943

C. D. Creevy, M.D., Minneapolis, Minn.

The June 10 session included the following:

W. N. Wishard, Jr., of Indianapolis, discussed the techniques and difficulties of removal of stones from the lower third of the ureter. The latter included the breaking of a wire of a Johnson stone extractor.

Vincent Balkus of Philadelphia (by invitation) described a new stone extractor consisting of an ureteral catheter through the butt end of which a fine stainless steel wire is threaded, emerging from one eye and passing through the other back down the lumen of the catheter. The catheter is passed above the stone, then looped in the ureter by traction on the wire. The catheter, its end kept looped, is then withdrawn (with the stone, if Providence smiles). The instrument was successful at the first trial in ten of thirteen cases.

D. M. Davis of Philadelphia advocated the treatment of stricture of the ureteropelvic juncture and upper ureter by incising the stricture longitudinally, making a nephrostomy, and threading a rubber catheter down the ureter. No sutures are used in the ureter, Nature being left to her own devices in reconstructing the ureter during the three weeks while the catheter is in place. Keyes had done such an operation and had found the kidney in good condition many years later. It seems to the reviewer preferable, where possible, to use the Schwyzer Foley Y plasty which actually widens the narrow area with tissue from the renal pelvis, and thus depends less upon chance for its success. When McIndoe depended upon a catheter to prevent stricture formation in a tubular Thiersch graft used to form an urethra in hypospadias, he found it necessary to leave the catheter in place for six months.

H. G. Bugbee, New York, discussed a patient who had hypertension and uremia due to a stone in the ureter of a solitary kidney. In performing nephrostomy, Bugbee found that compression of or traction upon the renal pedicle caused paroxysmal rises in the blood pressure. The blood pressure returned to normal after drainage of the kidney and subsequent removal of the stone. This observation is evidence of a neurogenic factor in hypertension.

Leon Herman of Philadelphia reported a large adrenal cortical carcinoma in an adult with normal secondary sex characters. Another patient had a huge perineural fibroma. Both displaced the kidney.

N. P. Rathbun* and **H. L. Wehrbein** (by invitation) of Brooklyn discussed six cases of lymphosarcoma of the bladder, five from the literature, and one of their own. They believe that such tumors develop in lymph follicles formed during chronic pyogenic infections.

Received for publication, Aug. 12, 1943.

*President of the American Association of Genitourinary Surgeons

of fine stitches in the bowel. There were two evisceerations on the sixth day when catgut was used, but none have yet occurred since the adoption of stainless steel wire for closure.

W. E. Lower of Cleveland discussed the late results of uretero-enterostomy for nonmalignant disorders. Patients are prepared for operation with daily catharsis, a low residue diet, and sulfasuxidine. The cathartic is replaced by paregoric on the day before operation. Both ureters are transplanted simultaneously in the adult, but a two-stage procedure is preferred in infants. Six of eighty patients are alive twenty years or longer after operation, and five of these are in good health. Excretory urography showed that some degree of hydronephrosis was not uncommon.

In the discussion, **Young** reported that he had done plastic repairs in four cases of exstrophy, but that the failures had outnumbered the successes.

G. G. Smith (Boston) studied the late results in fifty malignant tumors of the testicle (teratomas, embryonal carcinomas, chorioepitheliomas) treated by orchidectomy and irradiation and followed as long as fifteen years. Nineteen were living one to fourteen years after treatment, fourteen of them more than four years. Results were poor when metastases were recognizable at the outset.

H. Q. Woodard (by invitation) and **B. S. Barringer** (New York) have accumulated a considerable series of cases of carcinoma of the prostate in which the acid and alkaline phosphatases in the blood serum have been measured. Twenty-six per cent had normal values in the presence of metastases, a fact which considerably reduces the value of the phosphatase determination as a diagnostic measure.

an active life thereafter for twenty-two years before dying, after a rapid decline, of renal tuberculosis. Necropsy disclosed extensive renal and peritoneal tuberculosis. This is a potent testimony to the usefulness of cutaneous ureterostomy.

Meredith Campbell of New York reviewed a series of 152 cases of stenosis of the external urinary meatus in children. This apparently trivial lesion has produced an appalling array of disturbances in the urinary tract, chiefly in the way of residual urine, hydronephrosis, and infection.

C. D. Creevy, Minneapolis, compared the operative blood loss in a series of fifty-one consecutive cases of transurethral resection of more than 30 Gm. of prostatic tissue with that of a similar series in which a mixture of saline, pitressin, and adrenalin had been injected into the gland just before and during operation. Since the loss of blood was reduced by 35 per cent, the method appears to offer some promise as a means of diminishing the risk and increasing the completeness of the operation.

The June 12 session included the following:

A. I. Dodson, Richmond, Va., discussed his experience with the Deming nephropexy, in which the peritoneum and perirenal fat are sutured beneath the lower pole of the kidney to the lumbar muscles. (Reviewer not present.)

G. F. McKim and **Parke G. Smith**, Cincinnati, reported on a patient who lived for twelve years in comfort with one-fourth of one kidney. (Reviewer not present.)

C. R. O'Crowley with **H. S. Martland** (by invitation) of Newark, N. J., presented evidence in the form of kidneys secured at autopsy, that small islands of normal adrenal tissue are not infrequently found beneath the renal capsule, and speculated on their relationship to the so-called Grawitz tumors of the kidney (hypernephroma, renal carcinoma).

W. F. Braasch of Rochester, Minn., reviewed fifty cases with unmistakable evidence of past trauma to one kidney. The blood pressure was normal in thirty-eight of forty-five cases in which it was recorded. Braasch doubts whether post-traumatic lesions produce hypertension.

J. W. Lord (by invitation) and **A. R. Stevens**, New York, described their experience with the implantation of the dog's ureters into the colon with the aid of tubes of the alloy called vitallium. They were inserted into the ureters so as to protrude into the colon in order to prevent temporary occlusion of the ureters during the postoperative reaction. While the tubes were ordinarily expelled within thirty days, the incidence of plugging by urinary salts was too high to permit use of the method in man.

Charles C. Higgins* of Cleveland has transplanted the ureters into the sigmoid in eighteen infants, between 2 and 11 months of age, for exstrophy of the bladder, with two deaths. He pointed out that 50 per cent of patients with exstrophy will die before the age of 10 years, and 65 to 70 per cent before 20 years if the condition is not corrected. He presented his reasons for early operation as follows: (1) Infants tolerate the operation well; (2) the intestinal organisms are less virulent than they will be later; and (3) there is less danger of subsequent ureteral dilatation and renal infection. He concluded that the results have thus far more than justified early operation. He uses a two-stage "Coffey No. 1" technique, splitting the end of the ureter, using a Mayo fixation suture, and places a single row

*Secretary of the American Association of Genitourinary Surgeons.

now rarely used, Kimpton Brown paraffin tube method and to the various syringe apparatus while there is no mention of the "closed system" which is steadily gaining in popularity. A semiclosed method, however, is recommended in the chapter on preserved blood.

The material on transfusion reactions has been greatly expanded in this edition and the subject is, in the main, adequately covered. The author accords only a few lines to the subject of overloading of the circulation. It probably deserves more recognition. The transfusionist should certainly be impressed with the fact that prompt diagnosis and the application of tourniquets are necessary to save the lives of some recipients.

A new chapter has been introduced in this edition on stored blood, plasma, and serum. The author is lukewarm in his attitude toward stored blood. The advantages are mentioned but not emphasized. Description of the various techniques of preservation is scant. The problems of the administration of a blood bank are not discussed. The preparation and use of plasma and serum have been treated in somewhat more detail.

In spite of these imperfections, the book stands as the best reference work on blood groups in English.

Diseases of the Nose, Throat and Ear: Medical and Surgical. By William Lincoln Ballenger, M.D., F.A.C.S., late professor and head of the Department of Otology, Rhinology and Laryngology, University of Illinois College of Medicine, and Howard Charles Ballenger, M.D., F.A.C.S., associate professor of Otolaryngology, Northwestern University School of Medicine. Ed. 8, thoroughly revised. Pp. 975, with 604 engravings and 27 plates. Philadelphia, 1943, Lea & Febiger. $12.00.

This large but compact volume has five sections. The titles are: The Nose and Accessory Sinuses, the Pharynx and Fauces, Diseases of the Larynx, the Ear, and Bronchoscopy.

This eighth edition seems to be thoroughly up to date in its content. Several specialists have contributed to the text in addition to the Ballengers. J. D. Kelly describes his technique of arytenoidectomy for bilateral paralysis of the recurrent laryngeal nerve. A description of B. T. King's operation for this condition is also included. Revised chapters on Peroral Endoscopy are provided by Gabriel Tucker and C. L. Jackson. Alfred Lewy contributes the chapters on Physiology and Functional Tests of the Labyrinth and Inflammatory Diseases of the Labyrinth.

Included in this eighth edition is a description of Lempert's endaural approach to the mastoid and his fenestration for otosclerosis.

The text is easy to read. Each subject in its section is discussed in orderly fashion with paragraph titles such as etiology, symptoms, pathology, and treatment in large black type, making reference easy. Illustrations are numerous. Important bibliographic references are with few exceptions placed as footnotes.

In addition to the excellence of its content and arrangement, this treatise is noteworthy in that it is the most complete text in otolaryngology written by Americans. Also, it is the oldest treatise in the English language which has gone through eight editions, the last edition of which is up to date.

Otolaryngologists, graduate students in otolaryngology, and resident interns in the specialty should use this book. The physician in general practice will find it a most useful source for reference.

Book Reviews

Gynecology Including Female Urology. By Lawrence L. Wharton. 1943. W. B. Saunders Company.

The author is a member of the department of gynecology (which includes female urology) of the Johns Hopkins Hospital and Medical School. He has put into this text for students the practice of that department in both fields. The text is profusely illustrated with, for the most part, previously published cuts.

This book has distinct possibilities as a teaching text and the author has organized the material with that in mind. He attempts to give the student a variety of interpretations where disagreement is recognized. Little of personal opinion or dogma is included. The references are almost exclusively to the English literature.

Some details will undoubtedly be improved in subsequent editions. Some of the embryology requires reconsideration. There are generalizations, particularly in dealing with uterine bleeding and malignant disease, which will not be generally accepted. The classification of uterine tumors is incomplete.

As a student text, however, this text is better than the average of those recently published.

Blood Groups and Transfusion. By Alexander S. Wiener, M.D., Serologist and Bacteriologist in the office of the chief medical examiner of New York City. Ed. 3. Pp. 438. Springfield, Ill., and Baltimore, Md., 1943, Charles C Thomas, Publisher. Cloth. $7.50.

This book has kept abreast of the rapid advances made in the field since the first edition appeared in 1935. As the title indicates, it is still primarily concerned with the various theoretical aspects of the blood groups while only 160 pages are devoted to the routine problems of blood transfusion.

In the field of blood groups, the author writes with authority. The chapters on the heredity of the blood groups are complete and detailed. Dr. Wiener deserves the credit, along with Dr. Landsteiner, of the discovery of the Rh factor and his chapter on this subject is clear and restrained. There are exhaustive sections devoted to group-specific substances in organs, to anthropologic investigations, and to groups in animal blood. Two valuable chapters cover the medicolegal applications of blood grouping. There is a brief history on blood transfusion.

The problems of blood transfusion are approached from the viewpoint of the laboratory worker. The material on blood grouping and cross-matching is exhaustive. The selection of the donor has been treated at length but he receives scant attention as a patient. There is no reference to the reactions in donors which are occasionally a source of anxiety to the transfusionist. The author has wisely decided against an attempt to describe many techniques for transfusion but his selections are, in some ways, unfortunate. Much space has been devoted to the difficult, and

Books Received

The receipt of books is acknowledged in this section and this treatment must be regarded as sufficient acknowledgement of the courtesy of the sender. Selections will be made for more extensive review dictated by the interests of our readers and as space permits.

BLOOD GROUPS AND TRANSFUSIONS. By Alexander S. Wiener, A.B., M.D., Serologist and Bacteriologist in Office of Chief Medical Examiner of New York City; Head of Transfusion Division, Jewish Hospital of Brooklyn, N. Y. Cloth. Price $7.50. Pp. 438, with 69 illustrations, 106 tables. Springfield, Ill., 1943, Charles C Thomas, Publisher.

MANUAL OF INDUSTRIAL HYGIENE AND MEDICAL SERVICE IN WAR INDUSTRIES. By William M. Gafafer, D.Sc., issued under the Auspices of the Committee on Industrial Medicine of the Division of Medical Sciences of the National Research Council. Cloth. Pp. 508, with 19 illustrations. Philadelphia, 1943, W. B. Saunders Co.

TRANSURETHRAL PROSTATECTOMY. By Reed M. Nesbit, M.D., F.A.C.S., Associate Professor of Surgery, University of Michigan Medical School, Department of Surgery. Cloth. Price $7.50. Pp. 192, with 94 illustrations. Springfield, Ill., 1943, Charles C Thomas, Publisher.

PHYSIOLOGY IN AVIATION. By Chalmers L. Gemmill, B.S., M.D., Commander Medical Corps, U.S.N.R., Associate Professor in Physiology, Johns Hopkins University, School of Medicine, Baltimore, Md.; Instructor in Physiology, School of Medicine, Naval Air Station, Pensacola, Fla. Cloth. Price $2.00. Pp. 124, with 18 illustrations, 18 tables. Springfield, Ill., 1943, Charles C Thomas, Publisher.

THE SURGICAL CLINICS OF NORTH AMERICA—SYMPOSIUM ON TRAUMATIC SURGERY. By many contributors. Cloth. Pp. 638, with 153 illustrations. Philadelphia, 1943, W. B. Saunders Company.

OUTLINE OF ROENTGEN DIAGNOSIS. By Leo C. Rigler, B.S., M.B., M.D., Professor of Radiology, University of Minnesota, Minneapolis, Minn. Cloth. Price $6.50. Pp. 196, with 227 illustrations. Philadelphia, 1943, J. B. Lippincott Company.

CLINICAL SIGNIFICANCE OF THE BLOOD IN TUBERCULOSIS. By Culli Lind H. Muller, M.D., Pathologist and Director of Laboratory, New England Hospital for Women and Children, Boston, Mass. Cloth. Price $3.50. Pp. 516, 52 tables, 19 charts. New York, 1943, Commonwealth Fund.

OPERATIVE SURGERY, VOL. 1. By J. Shelton Horsley, M.D., LL.D., F.A.C.S., Attending Surgeon, St. Elizabeth's Hospital, Richmond, Va., and Isaac A. Bigger, M.D., Professor of Surgery, Medical College of Virginia; Surgeon-in-Chief, Medical College of Virginia Hospitals, Richmond, Va. Cloth. Pp. 674, with 705 illustrations. St. Louis, 1943, The C. V. Mosby Company.

OPERATIVE SURGERY, VOL. 2. By J. Shelton Horsley, M.D., LL.D., F.A.C.S., Attending Surgeon, St. Elizabeth's Hospital, Richmond, Va., and Isaac A. Bigger, M.D., Professor of Surgery, Medical College of Virginia, Surgeon-in-Chief, Medical College of Virginia Hospitals, Richmond, Va. Cloth. Pp. 1387, with 1259 illustrations. St. Louis, 1937, The C. V. Mosby Company.

A TEXTBOOK OF SURGERY. By John Homans, M.D., Clinical Professor of Surgery, Harvard Medical School, Boston, Mass. Cloth. Pp. 1272, with 530 illustrations. Springfield, Ill., 1940, Charles C Thomas, Publisher.

Transurethral Prostatectomy. By Reed M. Nesbit, University of Michigan. Pp. 192, with 94 drawings by Wm. P. Didusch. Springfield, Ill., 1943. Charles C Thomas, Publisher.

This book, written by one of the leading authorities in the field, should be read by everyone who does, or proposes to do, transurethral operations upon the prostate gland. Beginning with a chapter on the blood supply of the prostate by R. H. Flocks, who explains much that happens during and after such operations, it describes Nesbit's method of removing the obstructing portion of the prostate gland with an instrument of his own design. The descriptions are lucid and, coupled with the excellent drawings of Didusch, make the technique of the operation clear to the reader. There are detailed and helpful discussions of such pertinent topics as preoperative management, selection of an anesthetic, postoperative care, complications, and prostatic cancer, including comments on recent developments in this field. The history of the transurethral operation is well presented, and there is an excellent and extensive bibliography.

It might be well to explain that "transurethral prostatectomy" refers to a transurethral resection which seeks to remove as much of the hypertrophied prostate as possible, leaving behind but little more than the surgical capsule of the gland. It is a far cry from the original resection, which aimed at "cutting a channel" through the enlarged gland, and which was and is regularly followed by recurrent obstruction.

The reviewer, having seen the author at work, can testify that the book sticks to the facts in presenting what is, in the reviewer's opinion, the best method thus far devised for attacking the enlarged prostate gland transurethrally. It is not a method to be essayed by the novice.

SURGERY

VOL. 14 DECEMBER, 1943 No. 6

Original Communications

THE SURGICAL TREATMENT OF RECURRENT INGUINAL HERNIA WITH SPECIAL REFERENCE TO A COOPER'S LIGAMENT HERNIOTOMY AND THE USE OF FREE FASCIAL GRAFTS

SAMUEL A. SWENSON, JR., M.D., AND HENRY N. HARKINS, M.D.
DETROIT, MICH.
(From the Division of General Surgery, Henry Ford Hospital, Detroit)

UNTIL late in the nineteenth century, the recurrence of a previously surgically repaired hernia was not an unexpected result. At that time, recurrence rates were quoted as high as 25 to 50 per cent of all cases in which operation was done.

Although present-day recurrence rates are much lower, most often being quoted from 5 to 15 per cent, it is evident that the operation for primary inguinal hernia may be found wanting in many instances. Recently, one of us (H.N.H.) reported a series of 131 consecutive cases in which the McVay modification of the original Lotheissen technique was used, with only one recurrence after a relatively short follow-up period. This technique involves the suture of the transversalis fascia and conjoined tendon to Cooper's ligament rather than to Poupart's ligament. Nothing is fastened to Poupart's ligament. Hence, the operation is properly designated as a Cooper's ligament herniotomy. This communication deals with the results of operation in 37 consecutive cases of recurrent hernia, done during the past two years (1940 to 1942) on the service of one of us (H.N.H.) on 34 patients, with no recurrences to date. Thirty-four of the operations were performed by the senior author, one by the other of us (S.A.S., Jr.), and two by another resident.

In his book, Iason (1941) bases success or failure in operations for hernia upon:

a. The technical method utilized.
b. Failures in technique, hematoma formation, slipping ligatures, etc.
c. Postoperative pulmonary complication, i.e., cough, hiccough.

Received for publication, June 7, 1943.

PAIN MECHANISMS. By W. K. Livingston, Lieutenant Commander, M.C., U.S.N.R., Associate Clinical Professor of Surgery, University of Oregon Medical School, Portland, Ore. Cloth. Price $3.75. Pp. 253, with 26 illustrations. New York, 1943, The Macmillan Company.

DIAGNOSIS OF UTERINE CANCER BY THE VAGINAL SMEAR. By George N. Papanicolaou, M.D., Ph.D., Department of Anatomy, Cornell University Medical College, and Herbert F. Traut, M.D., Department of Obstetrics and Gynecology, Cornell University Medical College and the New York Hospital. Cloth. Price $5.00. Pp. 46, with 11 plates. New York, 1943, Commonwealth Fund.

PICTORIAL HANDBOOK OF FRACTURE TREATMENT. By Edw. L. Compere, M.D., F.A.C.S., and Sam W. Banks, M.D. Cloth. Pp. 210, with 30 illustrations. Chicago, 1943, The Year Book Publishers, Inc.

MANUAL OF FRACTURES, TREATMENT BY EXTERNAL SKELETAL FIXATION. By C. M. Shaar, M.D., F.A.C.S., Captain, M.C., U.S.N., and Frank P. Kreuz, Jr., M.D., F.A.C.S., Lieutenant Commander, Medical Corps, U.S.N. Cloth. Pp. 300, with 148 illustrations. Philadelphia, 1943, W. B. Saunders Company.

SURGICAL CLINICS OF NORTH AMERICA—(BILIARY TRACT AND SURGICAL DIAGNOSIS). By many contributors. Cloth. Pp. 923, with 240 illustrations. Philadelphia, 1943, W. B. Saunders Company.

ROENTGENOGRAPHIC TECHNIQUE. By Darmon Artelle Rhinehart, A.M., M.D., F.A.C.R., Professor of Roentgenology, University of Arkansas, St. Vincent's Infirmary, Missouri Pacific Hospital, Arkansas Children's Hospital. Cloth. Price $5.50. Pp. 471, with 201 illustrations. Philadelphia, 1943, Lea & Febiger.

REHABILITATION OF THE WAR INJURED (A SYMPOSIUM). By William Brown Doherty, M.D., and Dagobert D. Runes, Ph.D. Cloth. Price $10.00. Pp. 684, with 160 illustrations. New York, 1943, Philosophical Library.

SURGICAL CLINICS OF NORTH AMERICA—ORTHOPEDIC SURGERY. By many contributors. Cloth. Pp. 1231, with 340 illustrations. Philadelphia, 1943, W. B. Saunders Company.

LINCOLN—DOUGLAS, THE WEATHER AS DESTINY. By William F. Petersen, M.D. Cloth. Price $3.00. Pp. 211, with 91 illustrations. Springfield, Ill., 1943, Charles C Thomas, Publisher.

been observed over a period of three years. From these observations, one might correctly assume that even though the McVay procedure was originally designed as a repair of large direct hernias, it is equally applicable in indirect hernias, as it so adequately reinforces Hesselbach's triangle and greatly reduces the possibility of a direct recurrence.

Many authors agree that if inguinal hernias do recur, they do so within one month following operation. Iason (1941) states that there is always some evidence of recurrence even before the patient leaves the hospital, and within a few weeks a definite hernia is revealed. In Fallis' series (1937) of 200 recurrent hernias, 82 or 41 per cent were first noted within six months from the original operation.

In the review of this series of cases, it is interesting to note that until the senior surgeon (H.N.H.) became familiar with the McVay procedure, free fascial grafts were used in most of the cases of recurrent inguinal hernias. In general, all of the 37 recurrent hernia operations were done by two methods: (1) fascial graft, and (2) Cooper's ligament procedure (McVay-Lotheissen) using silk. Fascia was used ten times in the first twelve hernial operations, but more recently this suture has been almost entirely abandoned so that fascia was used only two times in the last twenty-five recurrent hernial operations. The technique used was essentially that as proposed by Gallie and LeMesurier (1921). One or two strips of fascia lata 20 to 30 cm. in length were obtained from the thigh by the Wilson fascial stripper, and were used as suture material, usually joining the transversalis fascia and conjoined tendon to Poupart's ligament, and occasionally, a second row of fascial sutures would be placed, including the medial flap of the cut oblique aponeurosis fascia. Alterations in the technique were based upon the use of either the original Halsted or Bassini type of closure.

During the past two years, the McVay technique has been used by us more and more extensively in the repair of recurrent inguinal hernia. With adequate dissection of the structures involved it is usually possible to close off entirely Hesselbach's triangle and suture the conjoined tendon and the transversalis fascia to Cooper's ligament. As has been stated in a previous article, it is absolutely necessary that the sutures be placed without tension and this procedure is greatly facilitated by a relaxing incision in the internal oblique aponeurosis made near the midline at its junction with the anterior rectus sheath. This relaxing incision is extended from about 2 cm. above the pubic symphysis superiorly for a distance of 8 to 10 cm. With sufficient relaxation the transversalis fascia and conjoined tendon are sutured to Cooper's ligament with double heavy silk sutures. The femoral vessels are held out of the way with the index finger placed upon Cooper's ligament, and the most lateral suture is placed first, the vessels being guarded by the finger. The double sutures are first knotted together and then tied separately, effecting a braiding of the suture. Two or three more such

d. Double hernia operations.

e. Constitutional factors.

f. Hereditary tendencies to hernia or congenital atony of the abdominal musculature or changes in the fasciae.

g. Age.

h. Sex.

i. Obesity.

j. The type of work the patient engages in postoperatively.

k. Transplantation of the spermatic cord.

It is difficult to draw the line too sharply as to what may be classed as a recurrent hernia. True recurrences, i.e., the appearance of the hernial sac in the same position as that of the previous operation, are usually the result of failure to ligate the sac at all or failure to ligate it high enough. It is rare, and almost impossible, after an adequate high ligation, for a hernial sac to return at the original site of protrusion. When this does occur, however, there is usually some contributory anatomic muscular or fascial defect surrounding the hernial opening.

False recurrences, or the appearance of a sac in a position different from that observed in the primary operation, are most common. The etiology of this condition may be based upon any one or more of the factors listed by Iason. In our series, as well as the series reported by Fallis in 1937, the number of direct recurrences resulting from operations on indirect hernias done in the Henry Ford Hospital seems to indicate that in this institution the factors which tend to prevent the appearance of a direct hernia were being neglected. At the time of Fallis' report, 88.6 per cent of the hernial repairs were done without transplantation of the cord. Since that time, however, transplantation of the cord has been done on a greater number of patients with the satisfactory result of fewer direct recurrences. At the present time the following rule seems to hold true for hernias operated upon for recurrence at the Henry Ford Hospital. Those patients whose primary operation was performed elsewhere have indirect recurrences; those whose primary operation was performed at our own hospital have direct recurrences. This rule, proposed by Dr. Fallis, seldom fails. Its rationale is that the hernias done elsewhere demonstrate that the sac was either not ligated at all, or ligated too low (in one case operated upon in Europe over 30 years ago, there seemed to be no evidence that the external oblique aponeurosis had ever been opened, a tuck merely having been taken in the external ring); while in our own operations done previous to 1937, there is adequate high ligation of the sac, but often incomplete buttressing of Hesselbach's triangle. In their review of experiences with the McVay herniotomy, Harkins and his co-workers demonstrated that with this type of repair Hesselbach's triangle was adequately reinforced, and in the one recurrence cited the sac was found at the internal ring. No direct recurrences following the McVay procedure, using either the original Halsted or the Bassini closure, have

20 of these cases, it was impossible to determine the duration of the original hernia, the usual reply to the question being: "For quite some time, but I can't say just how long."

TABLE III

DURATION OF ORIGINAL HERNIA IN THIRTY-SEVEN OPERATIONS FOR RECURRENT INGUINAL HERNIA

DURATION	NO. OF CASES	PERCENTAGE
Less than 1 yr.	6	16.2
1 yr.	3	8.1
5 yr.	3	8.1
10 yr.	2	5.4
More than 10 yr.	3	8.1
Not known	20	54.1
Total	37	100.0

Original Hernial Type.—Again, it was difficult to determine the hernial type at the original operation when the operation was done at some place other than Henry Ford Hospital. Occasionally the records of other hospitals could be checked, but in 12, or 32.4 per cent, of our cases the original type was not known. At the time of the second operation, it was sometimes possible to determine the type of the original hernia from the position of the sac or the type of the original repair. It is interesting to note that in the 25 cases we were able to check, no saddlebag or femoral hernias were present at the time of the original operation, but that at second operation, two direct-indirect hernias and one femoral hernia were found.

TABLE IV

ORIGINAL HERNIAL TYPE IN THIRTY-SEVEN OPERATIONS FOR RECURRENT INGUINAL HERNIA

TYPE	NO. OF CASES	PERCENTAGE
Indirect	19	51.4
Direct	6	16.2
Not known	12	32.4
Total	37	100.0

Hospital of First Operation.—Ten of the 37 patients were originally operated upon at Henry Ford Hospital and it is interesting to note that only 3 of these cases presented indirect recurrences, 1 of these being the only case of a recurrence from a McVay herniotomy done in this institution.

Type of First Operation.—One of the most interesting factors in the operation for recurrent inguinal hernia is the opportunity to note the technique used in the first attempt to repair the defect. It is at this time that the student of anatomy may observe firsthand the inadequacies of some types of repair, and may learn the true cause for the failure presented to him. Tissue reactions to suture material have proved extremely interesting. In all cases where absorbable sutures had

sutures are placed on down to the pubic tubercle, the last being taken in Gimbernat's ligament and resulting in complete closure of Hesselbach's triangle.

ANALYSIS OF CASES

Sex.—All of the 34 patients operated upon for recurrent inguinal hernia in this series were men. In a series of 200 operations, Fallis (1937) reported a percentage of 1.5, or 3 women in the entire series.

Age.—Seventy-eight per cent of the cases of recurrent inguinal hernia were in patients in the fourth and fifth decades of life. This figure exactly equals that of Fallis (1937), while Wilmoth (1937) found that in his series of 164 cases of recurrent inguinal hernia, 53 per cent were beyond the age of 40. This suggests that the general laxness of the abdominal wall structures seen at this age may be directly responsible for the frequently weakened internal oblique muscle.

TABLE I

AGE INCIDENCE IN THIRTY-SEVEN OPERATIONS FOR RECURRENT INGUINAL HERNIA

AGES	NO. OF CASES	PERCENTAGE
15-19	1	2.7
20-24	2	5.4
25-29	1	2.7
30-34	1	2.7
35-39	2	5.4
40-44	9	24.3
45-49	8	21.7
50-54	9	24.3
55-59	3	8.1
60-64	1	2.7
Total	37	100.0

Occupation.—Although most of the reports of recurrent inguinal hernia show a major percentage of patients doing hard labor, the figure of 89.2 per cent in our series may be somewhat high, as most of our patients are engaged in heavy industrial work.

TABLE II

OCCUPATION OF PATIENTS IN SERIES OF THIRTY-SEVEN OPERATIONS FOR RECURRENT INGUINAL HERNIA

OCCUPATION	NO. OF CASES	PERCENTAGE
Hard Labor	33	89.2
Sedentary	4	10.8
Total	37	100.0

Duration of Original Hernia.—Six, or 16.2 per cent, of the 37 patients presented themselves for operation within one year after noticing a hernia present, while 3, or 8.1 per cent, did not avail themselves of repair until their hernia had been present for more than ten years. In

20 of these cases, it was impossible to determine the duration of the original hernia, the usual reply to the question being: "For quite some time, but I can't say just how long."

TABLE III

DURATION OF ORIGINAL HERNIA IN THIRTY-SEVEN OPERATIONS FOR RECURRENT INGUINAL HERNIA

DURATION	NO. OF CASES	PERCENTAGE
Less than 1 yr.	6	16.2
1 yr.	3	8.1
5 yr.	3	8.1
10 yr.	2	5.4
More than 10 yr.	3	8.1
Not known	20	54.1
Total	37	100.0

Original Hernial Type.—Again, it was difficult to determine the hernial type at the original operation when the operation was done at some place other than Henry Ford Hospital. Occasionally the records of other hospitals could be checked, but in 12, or 32.4 per cent, of our cases the original type was not known. At the time of the second operation, it was sometimes possible to determine the type of the original hernia from the position of the sac or the type of the original repair. It is interesting to note that in the 25 cases we were able to check, no saddlebag or femoral hernias were present at the time of the original operation, but that at second operation, two direct-indirect hernias and one femoral hernia were found.

TABLE IV

ORIGINAL HERNIAL TYPE IN THIRTY-SEVEN OPERATIONS FOR RECURRENT INGUINAL HERNIA

TYPE	NO. OF CASES	PERCENTAGE
Indirect	19	51.4
Direct	6	16.2
Not known	12	32.4
Total	37	100.0

Hospital of First Operation.—Ten of the 37 patients were originally operated upon at Henry Ford Hospital and it is interesting to note that only 3 of these cases presented indirect recurrences, 1 of these being the only case of a recurrence from a McVay herniotomy done in this institution.

Type of First Operation.—One of the most interesting factors in the operation for recurrent inguinal hernia is the opportunity to note the technique used in the first attempt to repair the defect. It is at this time that the student of anatomy may observe firsthand the inadequacies of some types of repair, and may learn the true cause for the failure presented to him. Tissue reactions to suture material have proved extremely interesting. In all cases where absorbable sutures had

been used, the searring was so extensive that it was diffieult to reeognize and disseet free the essential structures for an adequate repair, while in those eases in whieh silk had been used, searring was minimal and the fascial layers were easily diseernible, greatly faeilitating the repair of the defect. Fifteen, or 40.6 per eent, of the eases had had a Bassini repair at the first operation, retaining the eord beneath the external oblique aponeurosis, while 9 or 24.3 per eent, had had the eord transplanted beneath the skin in the manner of the original Halsted operation. In making the incision for operation of reeurrent inguinal hernia, great eare must be taken until the eord struetures are reeognized. If the incision is made without regard to underlying struetures, a subeutaneous eord may be easily transeeted before it is recognized.

In two eases, the only evidenee of previous operation was the skin incision and a searring around the external ring as though several sutures had been placed in the loose areolar tissue producing a tucking effect and narrowing of the external ring. The aponeurosis of the external oblique and the eord had been left in position undisturbed. One of these patients had had his first operation done in Europe thirty years previously. The other one had been operated upon in the United States.

TABLE V

TYPE OF FIRST OPERATION IN THIRTY-SEVEN CASES OF RECURRENT INGUINAL HERNIA

TYPE OF OPERATION	NO. OF CASES	PERCENTAGE
Bassini	15	40.6
Original Halsted	9	24.3
Modified Bassini	2	5.4
Ligation of sac only	1	2.7
Closure of external ring	2	5.4
Ferguson	2	5.4
Halsted I-McVay	1	2.7
Not known	5	13.5
Total	37	100.0

Suture Material in First Operation.—Silk sutures were found in 9 eases, or 24.4 per eent, of the series. As was previously stated, in those eases in whieh silk had been used as a suture material, identifieation of faseial struetures was much less diffieult than in those eases in whieh absorbable sutures had been used. Most of the eases in whieh absorbable sutures had been used in the first operation showed evidenee of severe tissue reaetion with extensive searring. Silk sutures have been used exclusively in all hernial repairs in the Henry Ford Hospital for more than five years, and in the series of McVay herniotomies reported by Harkins and his associates (1942) silk sutures were extruded in only one ease postoperatively, in the presence of wound infection, and this subsided within eight weeks following operation, without reeurrence of the hernia. Faseial sutures were not reeognized in any of the eases at the time of the second or third operation.

TABLE VI

SUTURE MATERIAL USED IN FIRST OPERATION OBSERVED IN THIRTY-SEVEN OPERATIONS FOR RECURRENT INGUINAL HERNIA

SUTURE MATERIAL	NO. OF CASES	PERCENTAGE
Silk	9	24.4
Absorbable	28	75.6
Total	37	100.0

Duration to Second Operation.—Table VII gives no indication as to the exact time of recurrence. As Iason (1941) stated, if inguinal hernias recur, they will often do so within one month and usually the recurrence can be noted on careful inspection at the time the patient is discharged from the hospital.

TABLE VII

DURATION TO SECOND OPERATION IN THIRTY-SEVEN OPERATIONS FOR RECURRENT INGUINAL HERNIA

DURATION	NO. OF CASES	PERCENTAGE
1 yr. and under	3	8.1
2 yr.	6	16.3
3 yr.	9	24.3
4 yr.	4	10.8
5 yr.	2	5.4
6 yr.	2	5.4
7 yr.	1	2.7
8 yr.	0	0.0
9 yr.	0	0.0
10 yr.	1	2.7
Over 10 yr.	9	24.3
Total	37	100.0

Hernia Type at Second Operation.—Breaking down the statistics shown in Table VIII reveals the previously mentioned rule that in hernias primarily operated upon at Henry Ford Hospital, the recurrence is usually direct, while in operations done elsewhere, the recurrence is usually indirect. Table IX demonstrates all types found at the final operation, including the six cases which had two previous operations.

Previous Operations.—In this series of 37 consecutive operations for recurrent inguinal hernia, 31, or 83.8 per cent, had had only one pre-

TABLE VIII

HERNIAL TYPE AT SECOND OPERATION IN THIRTY-SEVEN OPERATIONS FOR RECURRENT INGUINAL HERNIA

FIRST OPERATION AT HENRY FORD HOSPITAL			FIRST OPERATION ELSEWHERE		
TYPE	NO. OF CASES	PERCENTAGE	TYPE	NO. OF CASES	PERCENTAGE
Indirect	3	30	Indirect	16	59.3
Direct	7	70	Direct	5	18.5
			Direct-indirect	2	7.4
			Direct-femoral	1	3.7
			Not known	3	11.1
Total	10	100		27	100.0

vious repair, and 6 or 16.2 per cent had had two previous attempts at repair of the defect. None of the patient's had had more than two previous operations. None of the cases with two previous operations in this series had been operated upon at the Henry Ford Hospital.

Any attempt at repair of a recurrent hernia which has been subject to two or more previous repairs is recognizably more difficult than a primary repair. Tissue defects, plus scarring and obliteration of landmarks, all combine to increase the problem of adequate repair. The first case in our series presented a combined direct-indirect, femoral hernia. Two incisions were made, one over the femoral bulge, and one over the inguinal hernia. The entire peritoneal sac was transposed to the internal ring by the Hoguet maneuver, but the internal ring was so large, that on consent of the patient, orchectomy was performed and the entire internal ring obliterated. Of the remaining 5 cases, two were of the indirect type, and 3 of the direct type, all presenting large sacs over 10 cm. in length.

Truss.—Conclusions based on this review would seem to indicate that the truss is falling into disuse in the treatment of inguinal hernia. As physical examinations are required for employment in our larger industrial concerns, it is evident that persons with hernias are now more frequently seeking surgical repair rather than go on through life with such artificial support as a truss provides. Only 8, or 21.6 per cent, of our patients gave the history of wearing a truss, leaving 29, or 78.4 per cent, who preferred early surgical treatment. It is generally recognized that the trauma produced by wearing a truss results in extensive adhesions and scarring in the region of the hernial site adding to the difficulty in repair. This observation was borne out in our series of operations upon these patients.

Relative Frequency of the Side Involved.—Contrary to the observations of Fallis, (1937) the greater number of our patients presented recurrences on the right side. We offer no explanation for this happening.

Anesthesia.—Spinal anesthesia is used in almost all operations done in the Henry Ford Hospital for inguinal hernias mainly because of its simplicity and the better relaxation which results. Other types of anesthesia are used only when there is some definite contraindication to the spinal anesthetic. General anesthesia is usually avoided, and was used

TABLE IX

RELATIVE FREQUENCY IN THE SIDE INVOLVED IN THIRTY-SEVEN CONSECUTIVE OPERATIONS FOR RECURRENT INGUINAL HERNIA

SIDE	NO. OF CASES	PERCENTAGE
Right	24	64.9
Left	13	35.1
Total	37	100.0

primarily only in cases in which the patient was so apprehensive that it was necessary to give ethylene anesthesia to control him. In one case, where the operation was extensive and the effect of the spinal anesthetic ceased before the operation was finished, ethylene gas was given as a supplementary anesthetic. Local novocain anesthesia was used in one case in which the blood Kline reaction was positive, and it was deemed advisable not to use a spinal anesthetic. The patient is routinely given a barbiturate on call to the operating room, which generally produces the desired sedative effect.

TABLE X

ANESTHESIA USED IN THIRTY-SEVEN CONSECUTIVE OPERATIONS FOR RECURRENT INGUINAL HERNIA

ANESTHESIA	NO. OF CASES	PERCENTAGE
Spinal	33	89.2
Ethylene	2	5.4
Spinal supplemented with ethylene	1	2.7
Local	1	2.7
Total	37	100.0

Size of Sac.—A definite peritoneal sac was observed in all the cases in this series. A sac of 10 cm. or more in length is classed as a large sac, one 5 cm. or more in length, as a medium sac, and a small sac is less than 5 cm. in length.

TABLE XI

SIZE OF SAC IN THIRTY-SEVEN CONSECUTIVE OPERATIONS FOR RECURRENT INGUINAL HERNIA

SIZE OF SAC	NO. OF CASES	PERCENTAGE
Large	14	37.8
Medium	19	51.4
Small	4	10.8
Total	37	100.0

Type of Hernia.—Table XII merely classifies the type of inguinal hernia found at the final operation reported in this series, including the six patients upon which two operations had previously been done. It represents a distribution similar to that found in most series of hernial operations.

Operation.—As has been discussed previously in this article, emphasis was placed upon the use of free fascial strips in the repair of recurrent inguinal hernia until one of us (H.N.H.) became familiar with the McVay procedure. Since that time, the McVay procedure has been used almost exclusively, but may be supplemented with fascia whenever deemed necessary.

TABLE XII

TYPE OF HERNIA IN THIRTY-SEVEN CONSECUTIVE OPERATIONS FOR RECURRENT INGUINAL HERNIA

TYPE OF HERNIA	NO. OF CASES	PERCENTAGE
Indirect	18	48.6
Direct	15	40.6
Direct-indirect (Saddlebag)	2	5.4
Direct-femoral	1	2.7
Direct-indirect-femoral	1	2.7
Total	37	100.0

TABLE XIII

OPERATIVE TECHNIQUE USED IN THIRTY-SEVEN CONSECUTIVE CASES OF RECURRENT INGUINAL HERNIA

OPERATION	NO. OF CASES	PERCENTAGE
Halsted I		
With fascia	5	13.5
Without fascia	3	8.1
Halsted I-McVay		
With fascia	6	16.2
Without fascia	7	18.9
Bassini-McVay		
With fascia	1	2.7
Without fascia	15	40.6
Total	37	100.0

Associated Operations.—Most of the associated operations listed are those which may be found concurrent with the repair of inguinal hernia. Although many surgeons prefer not to repair both sides at the same time in bilateral hernias, we have noticed no ill effects which might be attributed to the performance of the combined operation. In six of our cases a herniotomy was performed on the opposite side at the same sitting. Three of these were for primary hernia and three for recurrent hernia. In cases with an accompanying large hydrocele, we prefer to lift the testis from the scrotum and invert the tunica vaginalis, holding it in place with one or two sutures, thus doing the "bottle" operation, and then returning the testis into the scrotum.

TABLE XIV

ASSOCIATED OPERATIONS IN THIRTY-SEVEN OPERATIONS FOR RECURRENT INGUINAL HERNIA

ASSOCIATED OPERATIONS	NO. OF CASES	PERCENTAGE
Opposite inguinal herniotomy	6	16.2
"Bottle" operation	2	5.4
Orchectomy	1	2.7
Femoral hernia	1	2.7
Umbilical hernia	1	2.7
None	26	70.3
Total	37	100.0

Follow-up.—If the rule stated by Iason (1941) holds true, the results of this series of 37 operations for recurrent inguinal hernia may be held as being quite promising since no recurrences of hernia have been observed to date. It has been difficult to continue an adequate follow-up at the present time because of the continual shifting of population and the induction of men into the armed forces. Almost one-half of our cases have been followed for two or more years, and we shall continue in our efforts to trace the remaining cases for a longer period of time.

Postoperative complications have been few and relatively inconsequential considering the severity of the condition presented. Slight pain has persisted in the region of the operative wound in 13, or 35.1 per cent, of our cases. Atrophy of the testis on the involved side has been noted in one case.

TABLE XV

FOLLOW-UP IN THIRTY-SEVEN CONSECUTIVE OPERATIONS FOR RECURRENT INGUINAL HERNIA

DURATION	NO. OF CASES	PERCENTAGE
3 yr.	4	10.8
2½ yr.	3	8.1
2 yr.	10	27.0
1½ yr.	4	10.8
1 yr.	7	18.9
½ yr.	9	24.4
Total	37	100.0

In Fallis' series (1937) of 200 recurrent inguinal hernia operations, there were 26 recurrences after reoperation (13 per cent). Since 21 of the 26 (81 per cent of the secondary recurrences) were noted within less than two years, our follow-up of almost one-half of our cases for that length of time is especially significant.

SUMMARY AND CONCLUSIONS

1. The factors involved in the recurrence of inguinal hernia are reviewed.

2. The application of the McVay modification of the Lotheissen operation for femoral hernia to recurrent inguinal hernia is presented. This procedure utilizes Cooper's ligament instead of Poupart's ligament.

3. The use of free fascia grafts in recurrent inguinal hernia is discussed.

4. We present a series of thirty-seven consecutive operations for recurrent inguinal hernia, most of which were performed with the use of free fascial grafts or a Cooper's ligament (McVay) herniotomy, done in the Henry Ford Hospital on a single surgical service during the years 1940 to 1942.

5. No recurrences of hernia in the cases which we have been able to follow have been noted to date.

REFERENCES

1. Fallis, L. S.: Recurrent Inguinal Hernia, an Analysis of 200 Operations, Ann. Surg. 106: 363-372, 1937.
2. Gallie, W. E., and LeMesurier, A. B.: The Use of Living Sutures in Operative Surgery, Canad. M. A. J. 11: 504-513, 1921.
3. Harkins, H. N., Szilagyi, D. E., Brush, B. E., and Williams, R.: Clinical Experiences With the McVay Herniotomy, SURGERY 12: 364-377, 1942.
4. Iason, A. H.: Hernia, Philadelphia, 1941, The Blakiston Company.
5. McVay, C. B., and Anson, B. J.: Aponeurotic and Fascial Continuities in the Abdomen, Pelvis, and Thigh, Anat. Rec. 76: 213-231, 1940.
6. McVay, C. B., and Anson, B. J.: Composition of the Rectus Sheath, Anat. Rec. 77: 213-225, 1940.
7. McVay, C. B.: An Anatomic Error in Current Methods of Inguinal Herniorrhaphy, Ann Surg. 113: 1111-1112, 1941.
8. Wilmoth, C. L.: Recurring Inguiual Hernia, J. Kansas M. Soc. 38: 101-105, 1937.

A STUDY OF RECURRENCES FOLLOWING INGUINAL HERNIOPLASTY

With Report of New Operation

Herbert E. Stein, M.D., F.A.C.S., and Daniel Casten, M.D.
New York, N. Y.
(From the Surgical Services of the Hospital for Joint Diseases)

THERE are few operative procedures of which the results are so little known as inguinal hernioplasty. Halsted[1] once stated that he had not had a recurrence in twenty years. A similar report was made by Torek a few years ago during a symposium at the New York Academy of Medicine. While most surgeons admit a moderate percentage of failures, some put the figure as high as 40 to 50 per cent.

In an attempt to ascertain the true status, two means of approach have been utilized: (1) review and analysis of the current and past literature; (2) a questionnaire.

(1) A review of the important reports in the surgical literature during the past ten years is given in Tables I and II. Analysis of these reports discloses a wide variation in results. For indirect hernias the recurrence rate varies from 0.4 to 33.3 per cent with the average below 10 per cent. For direct hernias the recurrence rate varies from 2.7 to 33.3 per cent with the average between 15 and 20 per cent. Many factors are responsible for this divergence and these will be discussed subsequently.

(2) The following questionnaire was sent to 150 recognized hospitals and universities throughout the country. A few questionnaires were sent abroad. It will be noted that only the essential facts were sought:

1. Date of survey
2. Age of patient
   (a) Younger than twelve years
   (b) Older than twelve years
3. Number of patients operated upon (if bilateral, consider as two)
   (a) Indirect inguinal hernia
   (b) Direct inguinal hernia
   (c) Recurrent inguinal hernia
4. Type or types of operation
5. Number of patients returning for follow-up examination
6. Time between operation and follow-up examination
7. Of the patients with recurrences operated upon, what percentage had had the primary repair at your hospital

Received for publication, July 12, 1943.

A STUDY OF RECURRENCES FOLLOWING OPERATIONS FOR DIRECT AND INDIRECT INGUINAL HERNIAS

AUTHOR	INDIRECT INGUINAL HERNIAS			DIRECT INGUINAL HERNIAS			TOTAL		REMARKS
	CASES FOLLOWED	RECURRENCES		CASES FOLLOWED	RECURRENCES		CASES FOLLOWED	RECURRENCES PER CENT	
		NO.	PER CENT		NO.	PER CENT			
Erdman[4]	665	21	3.1	313	52	16.7			Halsted and Bassini type operations, Willys-Andrews used for direct hernias
Gibson and Felter[5]	1,451	20	1.3	427	28	6.5			Incomplete follow-up (90%), Halsted, Bassini, Willys-Andrews operations
Taylor[6]	356	30	8	47	14	29			Halsted operation; statistics are for personal follow-up, letter follow-up shows fewer recurrences
Coley[7]	332	28	8.7	85	14	16.4			Bassini operation, all patients were adults
Turner and Eckhoff[8]	115	5	4.3						Bassini operation, 40% in children
Ostfeld[9]			4.3			20	239	5.4	Bassini operation, about 70% direct follow-up
Cattell and Anderson[10]	123	6	4.6	51	4	7.8			Bassini type operations, fascial sutures for direct hernias
Page[11]			20.2			25			Bassini operation in adult males
Fallis[12]			7.4			11.6			Halsted operation in most patients and occasionally the Bassini procedure; silk technique in 96%
Glenn and McBride[13]	253	6	2.37	32	2	6.21	285	2.1	Halsted repair, silk technique
Fallis[14]				154	18	11.6			Rectus sheath sutured to Poupart's ligament
Burdick, Gillespie, Higgenbotham[15]	202	35	17.3	310	80	25.8			Fascial sutures used in Gallie type repair
Grace and Johnson[16]			21.2			32			All patients over 50 yr., Bassini repair
Parsons[17]	173 278		9.8 2.16	22 89		13.6 4.49			(a) Chromic catgut used, Halsted type repair (b) Silk sutures used, Halsted type repair

Robins[18]				27					Fascial repair with strips from external obliquo
Novak and Rigler[19]	648	34	5.2	227	20	8.8	875	6	Bassini operation, local anesthesia
Lengacre[20]	474	26	5.6	115	8	6.9			Halsted or Bassini type operation; silk, catgut, and fascial sutures
Quigley[21]							78	11	Ferguson, Bassini, and Halsted operations, all patients over 50 yr.
Shelley[22]	1,668		7.2						Bassini operation or modification; catgut, silk and fascial sutures; recurrences 6.9% with fascia
Shelley[23]				458		14.8			Bassini type operations, catgut and silk and fascia used, recurrences with fascia 10.4%
Shelley[24]	305	4	1.9						Congenital hernias, 63% below 20 yr. of age
Harrison[25]	46			14					LaRocque incision, patch of fascia sutured over defect, follow-up very inadequate
Joyce[26]	495			99			544	2.94	Internal oblique muscle sutured to Poupart's ligament with fascial strips
Wakely[27]							851	5.4	Bassini type repair
Sutton[28]							91	2.2	Intraperitoneal operation of LaRocque
Gray[29]	29	1	3.5	10	1	10	39	5.1	Rectus sheath sutured to Poupart's ligament with fascial strip from external oblique
Williamson[30]	150	6	4	4	0	0	154	3.9	Fascia lata or strips from external oblique used for repair, Bassini type repair
Estes[31]	271	1	0.4	72	2	2.7	343	0.99	Rectus sheath sutured to external oblique aponeurosis and fascia imbricated
MacFee[32]	3	1	33.3	9	3	33.3	12	33.3	Cord transplanted to femoral canal, all patients over 50 yr., difficult cases
Stein[33]	62	0	0	26	3	11	88	3.4	Internal oblique aponeurosis incised and the flap sutured to Poupart's, internal ring narrowed

TABLE II

RESULTS OF OPERATIONS FOR RECURRENT HERNIAS

AUTHOR	CASES FOLLOWED	RECURRENCES		REMARKS
		NO.	PER CENT	
Erdman[4]	51	12	23.1	Halsted and Bassini type operations, Willys-Andrews used for direct hernias
Glenn & McBride[13]	20	6	30.0	Halsted repair, silk technique
Fallis[34]	200	26	13.0	Transversalis fascia sutured to Poupart's ligament, Halsted and Bassini type repairs, silk sutures
Burdick, Gillespie, Higgenbotham[15]	262	92	35.2	Fascial sutures used in Gallie type repair
Grace & Johnson[16]			34.0	All patients over 50 yrs. Bassini repair
Parsons[17]	22		25.0	Chromic catgut used, Halsted type repair
	42		7.6	Silk sutures used, Halsted type repair
Longacre[20]	69	8	11.6	Halsted or Bassini type operation; silk, catgut, and fascial sutures
Wakely[27]	59	23	38.6	Bassini type repair
Gray[29]	4	0	0	Rectus sheath sutured to Poupart's ligament with fascial strip from external oblique
Williamson[30]	9	1	11.1	Fascia lata or strips from external oblique used for repair, Bassini type repair
Estes[31]	17	3	17.6	Rectus sheath sutured to external oblique aponeurosis and fascia imbricated
MacFee[32]	7	1	14.0	Cord transplanted to femoral canal, all patients over 50 yrs. (difficult cases)
Stein[33]	13	1	7.6	Internal oblique aponeurosis incised and the flap sutured to Poupart's; internal ring narrowed

8. Number of recurrences
   (a) Indirect inguinal hernias
   (b) Direct inguinal hernias
   (c) According to type operation
9. Remarks

Only thirty-five responses were obtained, of which eight contained significant data. Three hospitals apologized for their inability to give the desired information owing to inadequate personnel. Very little information was obtained from these questionnaires beyond that already found in the literature. The following are specimen responses.

1. Patients do not return for examination but are contacted by letter, follow-up for six months postoperatively. Recurrences: indirect, 2.73 per cent; direct, 3.09 per cent (Walter Reed Hospital).

2. The time between operation and follow-up varied from six months to two years. The number in each group was not stated (New York Hospital).

3. Rhode Island Hospital reported 103 cases of which 54 were examined in three months with a 10 per cent recurrence rate.

4. No statement as to time of follow-up (Indiana University).

As can be observed from the preceding information there is a great discrepancy in the reported results and frequently an inadequate knowledge of the end results. Some of the causes of this discrepancy may be summarized as follows.

First, a large percentage of patients with recurrence do not consult the original operator. This is definitely shown by the fact that of the patients with recurrent hernias that present themselves at any hospital, almost 75 per cent had been primarily operated upon at another hospital.[2]

Second, the time elapsing between the operation and the follow-up is frequently too short. Examinations should continue for at least two years and probably longer. While most recurrences are observed in the first year after operation they may appear after twenty years.

Third, the patients have not been personally examined but have been permitted to report by mail and it is well known that many patients have a recurrence without knowing it.

Fourth, the percentages are occasionally calculated on the basis of the operations instead of on the number of cases re-examined at the follow-up clinic.

Fifth, many reports group hernias in children with those of adults. As recurrences in the former are very infrequent even after the simplest form of operation, inclusion of these age groups in the reports gives a much lower general percentage recurrent rate. Coley and Hognet,[3] reporting on 5,000 cases, record a very low percentage of recurrence. However, over 50 per cent of the patients in this series were under 12 years of age.

There is a growing realization that operation has failed to cure inguinal hernia in a large percentage of patients. The figures often given for recurrences (2 to 7 per cent for indirect hernias; 10 to 15 per cent for direct hernias; 25 to 35 per cent for recurrent hernias) appear entirely too low.

We would suggest the following method for ascertaining the true figures. A clearing house should be set up, manned by some national

organization such as the College of Surgeons. A report of every recurrent hernia, whether operated on or not, should be sent to this clearing house which would then notify the hospital at which the primary operation had been done. This hospital in turn should send an abstract of the original finding back to the clearing house.

CAUSES OF RECURRENCE

We believe that recurrences are dependent upon one or several of the following factors.

1. Persistence of original structural weakness or defect
   (a) Weak internal oblique muscle
   (b) Weak or torn transversalis fascia
   (c) Long mesentery
   (d) Obesity (?)
2. Inadequate operative procedure and technical errors
   (a) Failure to narrow internal ring
   (b) Internal oblique muscle sutured to Poupart's ligament causing atrophy and paralysis
   (c) Interference with blood supply either by stripping the areolar tissue from the aponeurotic structures, tying ligatures too tightly, or inclusion of too much tissue in the ligature or suture
   (d) Incorrect or insufficient resection of neck of sac
   (e) Inclusion of omentum in sac ligature
   (f) Trauma, incomplete hemostasis, suppuration
   (g) Failure to recognize concomitant indirect and direct hernia
   (h) Use of the same technique for direct hernia as for indirect hernia
   (i) Division of nerves (?)
   (j) Improperly formed knots, early absorption of suture material
   (k) Bilateral operation at one sitting, tending toward more hasty and traumatic dissection, incomplete hemostasis, infection, prolonged anesthesia, pulmonary complications
3. Postoperative increased intra-abdominal pressure.
   (a) Cough
   (b) Early intercourse
   (c) Excess weight lifting
   (d) Abdominal tumor or ascites
   (e) Constipation
   (f) Urinary obstruction (prostatic hypertrophy)

TYPES OF RECURRENCES

(1) The recurrence may appear as an indirect hernia. The statement has often been made that an indirect inguinal hernia, properly operated upon, cannot recur as such, the recurrence being considered either a new hernia or a direct one. We do not believe the facts bear out the correctness of this statement. Recurrent hernias frequently protrude

directly through the internal ring with a typical indirect hernial sac, even though at the primary operation the sac had been recognized and removed. The elasticity of the peritoneum is well known and if the internal ring had not been narrowed and protected at the primary operation the possibility of an outpouching of the peritoneum through the patent ring is always present. Every surgeon has seen these rings frequently stretched to a diameter of 4 to 5 cm. Adequate closure of the ring leaving only sufficient space for the exit of the cord structures is both logical and imperative.

(2) The recurrence may appear as a direct hernia as a result of one or more of the following contingencies: (a) The primary indirect hernia may have been completely cured, the secondary hernia appearing as a direct one; (b) the direct hernia may have been present but not noted at the first operation; (c) selection of the naturally weak route of Hesselbach's triangle for repair of a femoral hernia may result in a subsequent direct inguinal hernia; (d) cure of the direct hernia may have been difficult because of inadequate operative utilization of the natural defenses at this area. The interrelationship between direct inguinal and femoral hernias was brought very forcibly home to one of us when, after a case of bilateral direct hernias was cured, the patient presented himself after one year with bilateral femoral hernias which had not been present at the time of the primary operation.

(3) A spigelian hernia may result. This is a hernia along the semilunar line. At this site there is an area of inherent weakness, covered only by the fascia of the internal oblique muscle, without any underlying muscular structure and situated on a plane cephalad to that of the internal ring. If the internal oblique fascia is cut at this point one comes directly upon the transversalis fascia and peritoneum. In using our technique it is imperative that the incision of this fascia not be extended beyond this weak point. Herniation through this space results in a bulge when the patient attempts to raise his trunk from a horizontal to a sitting posture without the aid of his arms. This was noted in one of the earlier cases.

PREVENTION OF RECURRENCE

Prevention depends upon the adherence to certain principles, the truth of which has been proved. These are (1) elimination of the causes as far as possible; (2) re-establishment of the natural physiologic and mechanical forces; (3) selection of the proper procedure; (4) avoidance of technical errors in the course of the primary operation. As all these factors cannot be completely controlled in every patient, it is evident that we cannot hope to attain perfect results in the treatment of hernia. However, if we are able to reduce materially the number of recurrences, we can claim considerable progress.

We have attempted to adhere to these principles in our technique, the details of which have been previously reported by one of us

(H. E. S.). The essential features in the repair of indirect hernia are elimination of the sac, narrowing of the internal ring, forming a flap of the internal oblique aponeurosis, and suturing it to Poupart's ligament thereby improving the trap-door action of the internal oblique muscle. In direct hernias there are two types to consider: (a) those cases in which a distinct opening in the transversalis fascia and a fusiform sac are noted, and (b) those in which there is simply a bulge in the transversalis fascia and underlying peritoneum. In the former group, elimination of the sac by excision or infolding is necessary, followed by closure of the defect in the transversalis fascia; while in the latter, the transversalis fascia is incised medially to the curving free edge of the internal oblique muscle and the cut edge of fascia thus formed is sutured to Poupart's ligament posterior to the line of suture between the internal oblique aponeurosis and Poupart's ligament. Unless the sac is very large it is not necessary to open and excise it in this, the usual type of direct hernia.

The importance of the internal oblique muscle has only lately been recognized but not sufficiently stressed. Probably in the majority of surgical clinics, the curving free edge of the muscle is sutured to Poupart's ligament. It cannot be denied that this step in the original Bassini operation was a great advance over the types of operation then performed. However, we feel strongly that under no circumstances should the internal oblique muscle be sutured to the inguinal ligament This applies equally to operations for direct or indirect hernia. Such suturing immediately immobilizes and causes subsequent disuse of the muscle and this is one of the factors in the causation of recurrence. The internal oblique muscle has a definite function to perform. Contraction, following increased intra-abdominal pressure, tends to straighten out its line and thus close the space existing between the free edge of the muscle and Poupart's ligament in the upper three-quarters of the canal, at the site of the internal ring.

Proper exposure of the lower portion of the inguinal canal is essential to the cure of a direct hernia and to the prevention of direct hernias following operation for indirect hernia. An adequate incision extending down to the pubic spine followed by separation of the underlying tissues by clean dissection will accomplish the desired result It should not be necessary to retract forcibly at this point, although this is usually done, causing undue trauma.

Avoidance of tension in approximation of the tissues is even more important. However, the usual method of suturing of the conjoined tendon (a fixed structure rarely more than three-quarters of an inch in length) to the lowest or most median portion of Poupart's ligament, another fixed structure, cannot be accomplished without tension. Necrosis of tissue or cutting through of the suture is bound to result in the majority of cases, whether absorbable or nonabsorbable suture

material is used. It is well known that this lower angle is a most vulnerable area. The technique of developing a flap from the internal oblique aponeurosis and suturing it to the lowest portion of Poupart's ligament absolutely fulfills this first principle of all plastic work and at the same time establishes a complete and firm barrier.

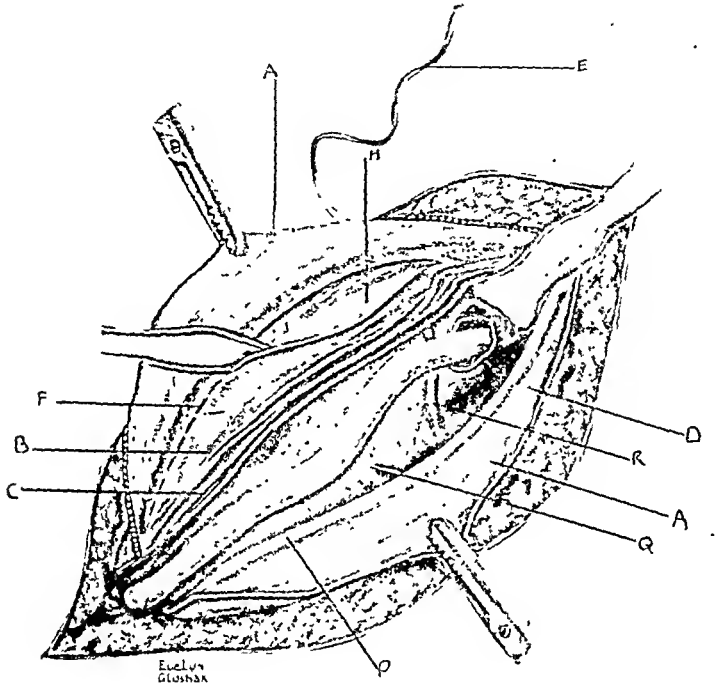

Fig. 1.—*A*, Aponeurosis external oblique muscle; *B*, aponeurosis internal oblique muscle; *C*, internal oblique muscle; *E*, fascial strip from external oblique aponeurosis; *F*, incision of aponeurosis of internal oblique; *H*, flap of aponeurosis of internal oblique; *P*, Poupart's ligament. *Q*, transversalis fascia; and *R*, epigastric vessels.

A great deal of attention has been devoted recently to the type of suture material used. It is questionable whether this is a reasonable and significant factor. These discussions have been repeated in the surgical literature time and again and the relative merits of wire, silk, catgut, and fascial sutures have been thoroughly debated. The important considerations are tensile strength tissue irritation, absorbability, and predisposition to infection. Of late, fascia is being discarded and silk, cotton, wire, and plastic sutures are receiving more attention. The use of very fine chromic catgut for suture material also has its advocates. Parsons believes that linen predisposes to infection, while silk causes practically no tissue reaction. In spite of the care devoted to proper selections of suture material, many recurrences are being

reported with each type. As pointed out frequently, it seems illogical for the suture material to be of greater tensile strength than that of the tissues approximated. The main reason for our better results is probably due to the lesson we have learned of doing cleaner, sharp dissection and avoiding the errors as enumerated above.

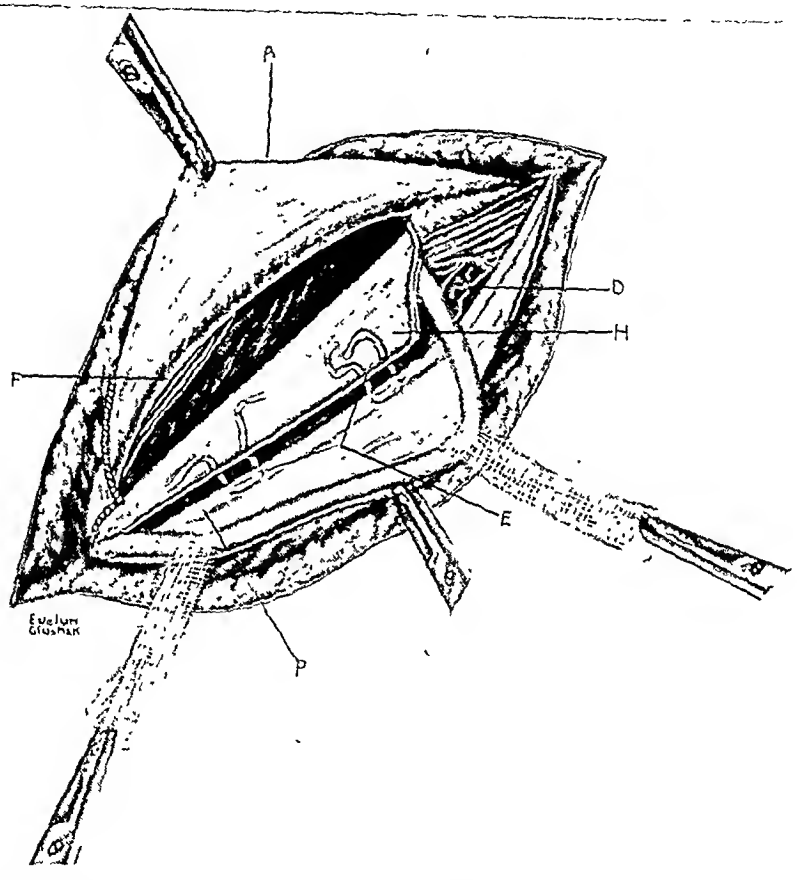

Fig. 2.—*A*, Aponeurosis external oblique muscle; *D*, suture through internal (deep) ring; *E*, mattress sutures uniting internal oblique fascia to Poupart's ligament; *F*, cut edge internal oblique fascia; *H*, fascial flap internal oblique muscle; and *P*, Poupart's ligament.

The technique of our operation for the cure of recurrent hernia differs only in a few details from the procedure for the cure of the primary hernia. It is advisable to start the incision higher than the site of the previous operation so as to expose the external oblique aponeurosis cleanly and follow down from this point. The possibility that the cord had been transplanted subcutaneously at the primary operation must be borne in mind and due care taken to avoid injury. Sharp dissection is preferable. The sac, especially of the indirect variety, being usually adherent to the surrounding tissues, is separated

and dealt with. The internal oblique muscle will usually be found to be partially adherent to Poupart's ligament. This must be severed completely and restored to its former free state. Even if previous suppuration has destroyed a large part of the external aponeurosis, it is always possible and essential to expose the internal oblique aponeurosis and from it fashion the firm flap to be sutured to Poupart's ligament. If the internal ring is large it must be narrowed by taking a few mattress sutures approximating its edges. In the earlier series, fascial

TABLE III

STATISTICS AUTHOR'S OPERATION

TYPES	NUMBER	FOLLOW-UP	NO. OF RECURRENCES	PER CENT
Indirect	135	114	3*	2.6
Direct	60	51	4	7.8
Indirect and Direct	18	15	1	6.6
Recurrent	24	19	2†	10.0
Total	237	199	10	5.0

*All recurred as direct hernias, 1 yr., 15 mo. and 3 yr. postoperatively.

†Pt. 1, G. K., paretic, aged 51 years, sliding recurrent.

Pt. 2, T. K., aged 64 years, Poupart's ligament almost completely destroyed at previous operation. Suture material in pt. I and II, autogenous strips of fascia.

TABLE IV

LENGTH OF FOLLOW-UP PERIOD*

	LESS THAN ONE YEAR	BETWEEN 1 AND 2 YR.	OVER 2 YR.
Indirect	19	17	78
Direct	4	3	44
Indirect and direct	4	5	6
Recurrent	2	1	16

*All patients examined personally by the authors.

strips were taken from the cut edge of the external oblique aponeurosis and fashioned as sutures according to the McArthur technique. In the later cases very fine silk or double zero chromic have been used. Subaponeurotic transplantation of the cord has been done in most but not all cases, particularly in the direct hernias. The results of this operation are illustrated in Tables III and IV.

CONCLUSIONS

1. There is a wide discrepancy in the reported results.

2. This can be corrected by adopting a uniform system of follow-up studies.

3. A sounder understanding of the anatomic, physiologic, and mechanical forces involved in the causation and cure of inguinal hernia is essential.

4. The application of these principles to the proper choice of operation is illustrated in the techniques described.

REFERENCES

1. Halsted, W. S.: Surgical Papers, Bellevue, 1924, Johns Hopkins Press.
2. Wilmoth, C. L.: The Recurrent Inguinal Hernia, Surg., Gynec. and Obst. 71: 802, 1940.
3. Coley, W. B., and Hoguet, J. P.: Operative Treatment of Hernia, Ann. Surg. 68: 255, 1918.
4. Erdman, S.: Inguinal Hernia in the Male, Ann. Surg. 77: 171, 1923.
5. Gibson, C. L., and Felter, R. K.: End Results of Inguinal Hernia Operation, Ann. Surg. 92: 744, 1930.
6. Taylor, A. S.: The Results of Operation for Inguinal Hernia, Arch. Surg. 1: 382, 1920.
7. Coley, B. L.: Three Thousand Consecutive Herniotomies, Ann. Surg. 80: 242, 1924.
8. Turner, P., and Eckhoff, N.: Inguinal Hernia; Results of Treatment by Simple Excision of Sac, Guy's Hosp. Rep. 79: 234, 1929.
9. Ostfeld, D.: Leistenbruchrezidiv und Leistenbruchstatistik, Deutsche Ztschr. f. Chir. 240: 322, 1933.
10. Cattell, R. B., and Anderson, C.: End Results in Operative Treatment of Inguinal Hernia, New England J. Med. 205: 430, 1931.
11. Page, C. M.: Physical Efficiency After Operations for Hernia, Brit. M. J. 2: 896, 1934.
12. Fallis, L. A.: Inguinal Hernia, Ann. Surg. 104: 403, 1936.
13. Glenn, F., and McBride, A. F., Jr.: The Surgical Treatment of 5,000 Hernias, Ann. Surg. 104: 1024, 1936.
14. Fallis, L. A.: Direct Inguinal Hernia, Ann. Surg. 107: 572, 1937.
15. Burdick, C. G., Gillespie, D. H. M., and Higgenbotham, N. F.: Fascial Suture Operations for Hernia, Ann. Surg. 106: 333, 1937.
16. Grace, R. V., and Johnson, V. S.: Results of Herniotomy in Patients of More Than 50 Years of Age, Ann. Surg. 106: 347, 1937.
17. Parsons, W. B.: Silk Sutures in the Repair of Hernia, Ann. Surg. 106: 243, 1937.
18. Robins, C. R.: Direct Inguinal Hernia, Ann. Surg. 108: 389, 1938.
19. Novak, E., and Rigler, A.: Hernias and the Results Obtained by Surgical Therapy, Arch. f. klin. Chir. 195: 342, 1937.
20. Longacre, A. B.: Follow-up of Hernia Repair, Surg., Gynec. & Obst. 68: 238, 1939.
21. Quigley, T. B.: Inguinal Herniorraphy in the Aged, New England J. Med. 222: 666, 1940.
22. Shelley, H. J.: Incomplete Indirect Inguinal Hernia, Arch. Surg. 41: 747, 1940.
23. Shelley, H. J.: Direct Inguinal Hernias, Arch. Surg. 41: 857, 1940.
24. Shelley, H. J.: Complete Indirect Inguinal Hernia, South. Surgeon 9: 257, 1940.
25. Harrison, P. W.: The Cause and Cure of Inguinal Hernia, SURGERY 7: 217, 1940.
26. Joyce, T. M.: Fascial Repair of Inguinal Hernia, J. A. M. A. 113: 971, 1940.
27. Wakely, C. P. G.: The Treatment of Certain Types of External Hernias, Lancet 238: 822, 1940.
28. Sutton, L. L.: The Intraperitoneal Approach for Repair of Inguinal Hernia, Ann. Surg. 104: 1030, 1936.
29. Gray, W.: The Operative Treatment of Inguinal Hernia, Brit. M. J. 1: 568, 1940.
30. Williamson, J. C. L.: The Use of Fascial Grafts in the Cure of Inguinal Hernia, Brit. J. Surg. 28: 384, 1941.
31. Estes, W. L.: End Results in Repair of Inguinal Hernia by a Fascia to Fascia Rectus Sheath Closure, Ann. Surg. 113: 838, 1941.
32. MacFee, W. F.: The Repair of Inguinal Hernia With Transplantation of the Cord to the Femoral Canal, Ann. Surg. 112: 1071, 1940.
33. Stein, H. E.: Inguinal Herniopiasty; A New Modification, SURGERY 5: 398, 1939.
34. Fallis, L. D.: Recurrent Inguinal Hernia, Ann. Surg. 106: 363, 1937.
35. Stein, H. E.: Inguinal Hernia; A New Concept and Operation, Am. J. Surg. 56: 480, 1942.
36. Stein, H. E.: Changing Concepts of Inguinal Hernia, Am. J. Surg. (In press.)

SURGICAL TREATMENT OF CARCINOMA OF THE PAPILLA OF VATER

HOWARD K. GRAY, M.D.,* AND WENDELL S. SHARPE, M.D.†
ROCHESTER, MINN.

LESIONS of the papilla of Vater challenge the ingenuity and ability of the surgeon. This tiny eminence in the duodenal mucosa provides in most persons the principal exit to the gastrointestinal tract for the secretions of the biliary tract and the pancreas. Tumors in this region are not rare and since they are small, grow slowly, metastasize late if at all, and provide early signs of their presence, they should be amenable to surgical treatment. Thirty years ago Upcott[1] wrote, "There is probably no position within the body, outside the central nervous system, where a growth, while yet so small, is heralded by more widespread symptoms." Yet since McNeal[2] first described carcinoma of the papilla of Vater in 1835, as far as we could ascertain less than 125 attempts to remove the lesion have been reported in the literature to 1942, and the disease is rarely diagnosed clinically.

Until recently the major obstruction to the perfection of a method of resection of these lesions was the belief that the permanent interruption of the pathway of pancreatic external secretions was not compatible with life. Other factors more or less responsible for the lack of progress were enumerated by Judd and Hoerner.[3] These are (1) the insidious onset of the disease, (2) the generally poor condition of the patients, (3) the relative inaccessibility of the lesion, (4) the proximity of important structures which cannot be sacrificed, and (5) the extreme technical difficulties of resection. The relatively few attempts at resection for tumors in this region that have been made from the time of Codivilla[4] in 1898, to 1935, when Whipple and his co-workers[5] devised a two-stage operation, and even to 1941, when Trimble and his associates[6] devised a single stage operation, have not been uniformly successful. Palliative operations obviously leave much to be desired. If possible, a successful technique should embody the tenets of surgical treatment of carcinoma, that is block removal of the tumor with its contiguous structures and lymphatic pathways of drainage. Each step in this direction is progress so that Whipple[7] and Trimble and his associates[6] deserve much credit for their suggestions which will be described more fully later in this communication.

The purpose of this study is to present the results of surgical treatment of carcinoma of the papilla of Vater in the Mayo Clinic and to consider the types of treatment available. From 1908 to November, 1941,

*Division of Surgery, Mayo Clinic.
†Fellow in Surgery, Mayo Foundation.
Received for publication, June 26, 1943.

inclusive, resection for carcinoma of the papilla of Vater was carried out in nine cases. In the same period palliative operation only was performed in twenty-three cases, but carcinoma of the papilla of Vater was proved by biopsy or necropsy. In three more cases an exploratory operation was performed but proof of the nature of the tumor was obtained by biopsy or necropsy. In about seventy additional cases the surgeon felt that in all probability the lesion for which a palliative operation was necessary was a carcinoma of the papilla of Vater, although no tissue was removed for examination. In twenty of these, the surgeon felt and described a tumor at the papilla and stated its location in positive terms. These twenty cases are presented as a special group for comparative purposes.

DEFINITION, ETIOLOGIC FACTORS, AND INCIDENCE

Strictly speaking, carcinoma of the papilla of Vater is limited to the tiny eminence forming the exit of the ampulla. The regional anatomy is so minute (the entire region may be circumscribed by a circle 1 cm. in diameter) that the term has come to be applied to any tumor arising from any one of six sources since the symptoms, clinical course, and treatment of all are identical. Outerbridge[8] suggested six plausible points of origin of these tumors: (1) the epithelial lining of the ampulla itself; (2) the epithelium lining the common duct at its lower end; (3) the epithelium of the terminal portion of the pancreatic ducts; (4) the duodenal mucosa directly covering the papilla; (5) the glands of Brünner on rare occasions, and (6) aberrant pancreatic tissue.

Carcinoma of the papilla of Vater and the ampullar region is not a rare disease. About 55 to 65 per cent of carcinoma of the duodenum is periampullar in origin.[8, 9] Probably carcinoma of this region is encountered in about 0.2 per cent of necropsies.[10, 11]

The causative factors of these tumors are unknown. Carcinoma of the gall bladder is associated with lithiasis in about 80 per cent of cases, but choledocholithiasis is associated with carcinoma of the papilla of Vater present in only from 15 to 25 per cent.

PATHOLOGIC ASPECTS

The gross and microscopic pathologic changes in many of the cases included in this article were studied by Baggenstoss.[10] The growths were generally small, firm, nodular masses from 1 to 3 cm. in diameter, protruding into the lumen of the duodenum. Many were polypoid or had ulcerated. All had risen from glandular elements (Fig. 1). Metastasis was found late when it occurred at all. Outerbridge reported that evidence of metastasis was found at necropsy in only 22 per cent of 110 cases.

CLINICAL CONSIDERATIONS

The appalling fact that the presence of these tumors rarely had been recognized before necropsy or exploratory surgical procedures led

Sharpe and Comfort[12] to study forty cases of carcinoma of the papilla of Vater in an attempt to aid timely and accurate diagnosis. In only one of the forty cases had the diagnosis been made prior to operation, but in thirty-eight some obstruction to the common duct was evident. The history and clinical observations were not typical. The disease was not always painless nor was the jaundice always progressive. Since the

Fig. 1.—Adenocarcinoma of ampulla, grade 1; cellular differentiation is apparent with the production of well-formed glandular spaces. The carcinoma cells are tall and fairly uniform in size (×60)

disease simulated both obstruction to the common duct and hepatogenic jaundice, the decision to resort to surgical intervention was often difficult to make. Intrahepatic jaundice is not a surgical problem but any mechanical obstruction to the common bile duct is. The hope of successful surgical treatment of any malignant disease lies in early diagnosis, and any patient who displays evidence of obstruction to the common duct should be given the benefit of exploration if those symptoms persist longer than six to eight weeks and no adequate explanation is found. Careful study will usually eliminate hepatogenic jaundice in that period of time.

Differential diagnosis in the presence of a patent orifice with partial obstruction of the common bile duct is difficult. Benign stricture, stones in the common duct, and carcinoma of the head of the pancreas are a few conditions that must be considered. The treatment of all of these entities is surgical, however, and surgical intervention should be instituted at the earliest possible moment. Chronic interstitial pancreatitis, hepatogenic jaundice, and toxic hepatitis caused by various ingested

inclusive, resection for carcinoma of the papilla of Vater was carried out in nine cases. In the same period palliative operation only was performed in twenty-three cases, but carcinoma of the papilla of Vater was proved by biopsy or necropsy. In three more cases an exploratory operation was performed but proof of the nature of the tumor was obtained by biopsy or necropsy. In about seventy additional cases the surgeon felt that in all probability the lesion for which a palliative operation was necessary was a carcinoma of the papilla of Vater, although no tissue was removed for examination. In twenty of these, the surgeon felt and described a tumor at the papilla and stated its location in positive terms. These twenty cases are presented as a special group for comparative purposes.

DEFINITION, ETIOLOGIC FACTORS, AND INCIDENCE

Strictly speaking, carcinoma of the papilla of Vater is limited to the tiny eminence forming the exit of the ampulla. The regional anatomy is so minute (the entire region may be circumscribed by a circle 1 cm. in diameter) that the term has come to be applied to any tumor arising from any one of six sources since the symptoms, clinical course, and treatment of all are identical. Outerbridge[8] suggested six plausible points of origin of these tumors: (1) the epithelial lining of the ampulla itself; (2) the epithelium lining the common duct at its lower end; (3) the epithelium of the terminal portion of the pancreatic ducts; (4) the duodenal mucosa directly covering the papilla; (5) the glands of Brünner on rare occasions, and (6) aberrant pancreatic tissue.

Carcinoma of the papilla of Vater and the ampullar region is not a rare disease. About 55 to 65 per cent of carcinoma of the duodenum is periampullar in origin.[8, 9] Probably carcinoma of this region is encountered in about 0.2 per cent of necropsies.[10, 11]

The causative factors of these tumors are unknown. Carcinoma of the gall bladder is associated with lithiasis in about 80 per cent of cases, but choledocholithiasis is associated with carcinoma of the papilla of Vater present in only from 15 to 25 per cent.

PATHOLOGIC ASPECTS

The gross and microscopic pathologic changes in many of the cases included in this article were studied by Baggenstoss.[10] The growths were generally small, firm, nodular masses from 1 to 3 cm. in diameter, protruding into the lumen of the duodenum. Many were polypoid or had ulcerated. All had risen from glandular elements (Fig. 1). Metastasis was found late when it occurred at all. Outerbridge reported that evidence of metastasis was found at necropsy in only 22 per cent of 110 cases.

CLINICAL CONSIDERATIONS

The appalling fact that the presence of these tumors rarely had been recognized before necropsy or exploratory surgical procedures led

of a Roux Y gastrojejunostomy. Continuity of the biliary tract was maintained by cholecystojejunostomy performed over a Murphy button. This was probably the first example of the one-stage operation now recommended by Trimble and his associates.[6]

Sauvé[15] not only collected reports of the operations previously performed but, in 1908, suggested the first true two-stage operation aimed at removal of the tumor. In his first stage Sauvé performed only gastroenterostomy, and resected the necessary portion of duodenum with its contiguous structures at the second operation. Usually cholecystojejunostomy was used to maintain biliary continuity.

Outerbridge,[8] in 1913, reviewed 110 cases of carcinoma of the ampulla. Resection had been performed in only twenty-two and in all but five of these, transduodenal excisions only were performed. There were eight primary surgical deaths; five more patients died in a few weeks, and only one patient lived three and three-fourths years. Cohen and Colp[16] collected all the reports of cases in which operation had beeen performed, to 1925, and showed the discouraging results to that time. They reported a gross mortality of more than 40 per cent from all types of procedure in the fifty-nine cases reviewed. Fulde,[17] in the same year, reviewed fifty-two cases and reported a similar mortality. Hunt and Budd[18] collected seventy-six cases of periampullar carcinoma in 1935, in which resection had been done; fifty-nine of these were in Cohen and Colp's series and eighteen were added by Hunt and Budd.

In 1935, Whipple, Parsons, and Mullins[5] gave great impetus to interest in the field by describing their two-stage operation and reporting three cases. This operation embodied the principles of surgical treatment of carcinoma, in that the tumor was removed en bloc with its lymphatic drainage and contiguous structures. In the first stage of this operation (Fig. 3) posterior gastroenterostomy was done, the common bile duct was ligated and cut distal to the patent cystic duct, and cholecystogastrostomy was performed to the anterior wall of the stomach. Three to four weeks later the second stage was performed. The pancreaticoduodenal and gastroduodenal arteries were severed, wide excision of the descending portion of the duodenum and excision of a V-shaped portion of the head of the pancreas were carried out, the pancreatic ducts were ligated, and the denuded pancreatic surface was covered.

Whipple, Parsons, and Mullins[5] did not attempt to re-establish the continuity of the duodenum or provide exit for external pancreatic secretions. The effect on the liver of such patients after partial pancreatectomy has been performed is unknown. It is well known that in the presence of hyperinsulinism and adenomas of the pancreas, large amounts of pancreatic tissue can be removed safely. Berg and Zucker[19] described early degenerative changes and infiltration of the liver with fat in completely depancreatized dogs and in those dogs in which the pancreatic ducts have been completely obstructed for long periods.

agents are other conditions with which periampullar carcinoma may be confused and which are not benefited by surgical treatment. If benefit is to be derived from the characteristic small size of the lesion, its low grade of malignancy, and its reluctance to metastasize, early diagnosis is essential.

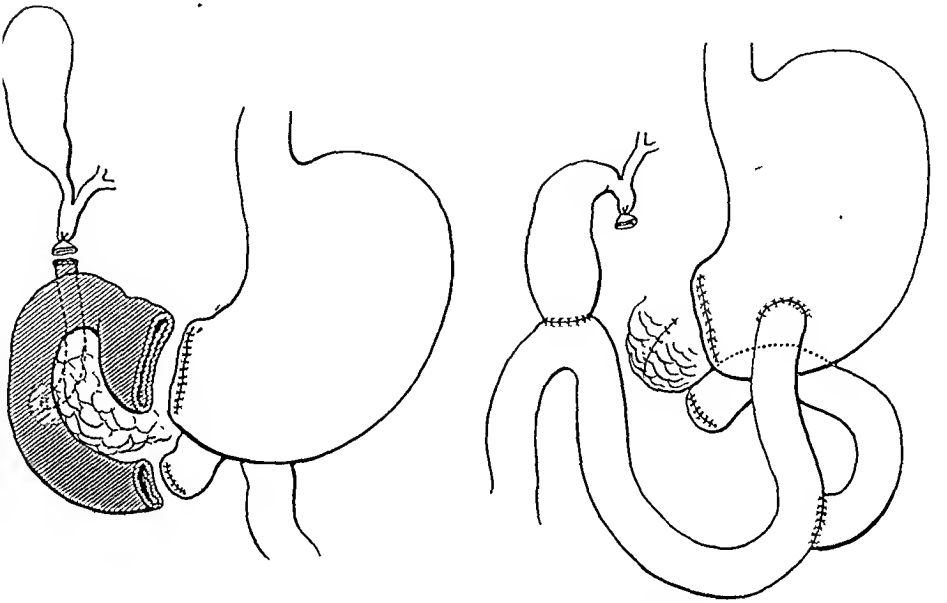

Fig. 2.—Operation performed by Codivilla in 1898.

TREATMENT

The treatment of this disease is surgical. The tumor may be excised by any of several methods to be described, or a palliative short-circuiting of the biliary route may be performed.

Development and Reported Results of Surgical Procedures.—Halsted[13] first excised a growth situated at the papilla of Vater on Feb. 14, 1898. This was performed transduodenally and a large piece of duodenum was excised with the growth. Choledochoduodenostomy was performed and three months later, May 5, 1898, it was necessary to perform cholecystoduodenostomy. The patient lived for about seven months. W. J. Mayo[14] performed cholecystostomy on a patient Nov. 3, 1900, followed by excision of a tumor of the ampulla of Vater, Jan. 31, 1901. The patient lived nine months. Several operations involving the pancreas and not the papilla of Vater preceded these two pioneering attempts. Of these reports, all of which were collected by Sauvé[15] that of Codivilla,[4] in 1898, is particularly worthy to be recorded (Fig. 2). The lesion in his case involved the pancreas also, but he excised en bloc the head of the pancreas, a large portion of the duodenum and pyloric end of the stomach, and re-established gastrointestinal continuity by means

in the literature, to 1941, in which the Whipple operation was performed; five deaths (33.3 per cent) had occurred. One of the patients who survived the operation lived thirty-two months; the others were not adequately followed. Hunt[27] summarized the results of operation in 124 cases from 1898 to 1941 inclusive. He found the surgical mortality rate as follows: 29.0 per cent in ninety-three cases of transduodenal excision; 40.0 per cent in five cases of retroduodenal excision; 45.4 per cent in eleven cases of resection of the duodenum with implantation of the common duct or common duct and pancreatic ducts and end-to-end anastomosis of the duodenum, and 26.6 per cent in the fifteen cases of

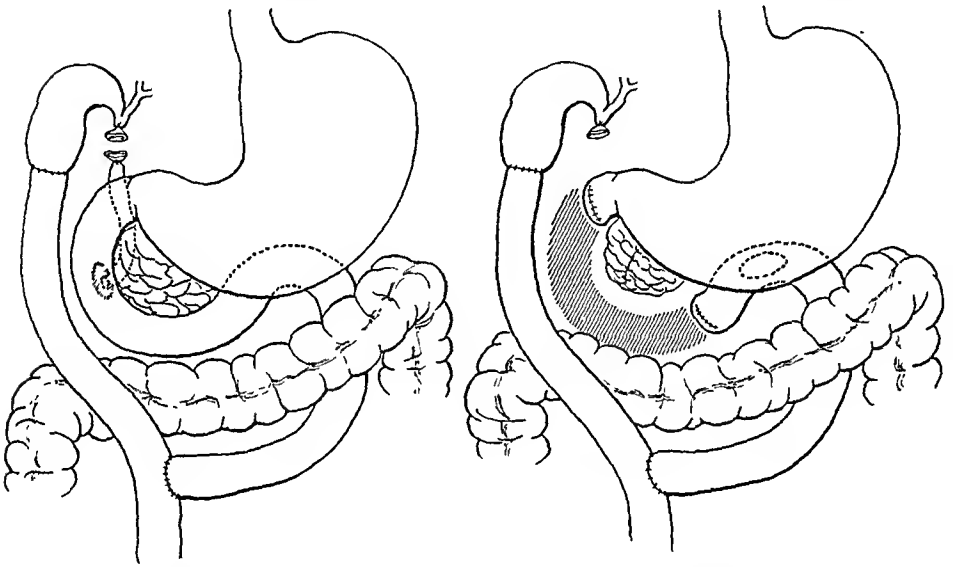

Fig. 4.—Two-stage operation described by Whipple in 1938.

resection of the duodenum and head of the pancreas. There were thirty-eight surgical deaths in the 124 cases considered in his review, a mortality rate of 30.6 per cent. Hunt[27] analyzed further the ninety-three cases in which transduodenal excision was performed. In the twenty-one cases in which transduodenal excision only was performed, eight deaths (38.0 per cent) occurred; in the thirty cases of transduodenal excision with reimplantation of the common duct, or common and pancreatic ducts, five deaths (16.6 per cent) occurred; in the twenty-seven cases in which transduodenal excision with reimplantation of the common or pancreatic duct with establishment of internal or external biliary drainage was performed, seven deaths (25.9 per cent) occurred, and in the fifteen cases in which transduodenal excision without reimplantation of the common or pancreatic duct but with establishment of internal or external biliary drainage was performed, seven deaths (46.6 per cent) occurred.

Dragstedt[20] confirmed at least the effect of pancreatectomy and prevented the hepatic damage by administration of lipocaic. Boyce and McFetridge,[21] however, found that the external secretions can be excluded completely without permanent harm if no pancreatic tissue has been removed. If partial pancreatectomy was performed they found that lecithin, choline, or pancreatic substance would protect the liver from serious damage. Snell and Comfort[22] reported fatty infiltration of the liver in the presence of pancreatic lithiasis and Cole[23] suggested that such changes in the liver accompany fibrosis of the pancreas.

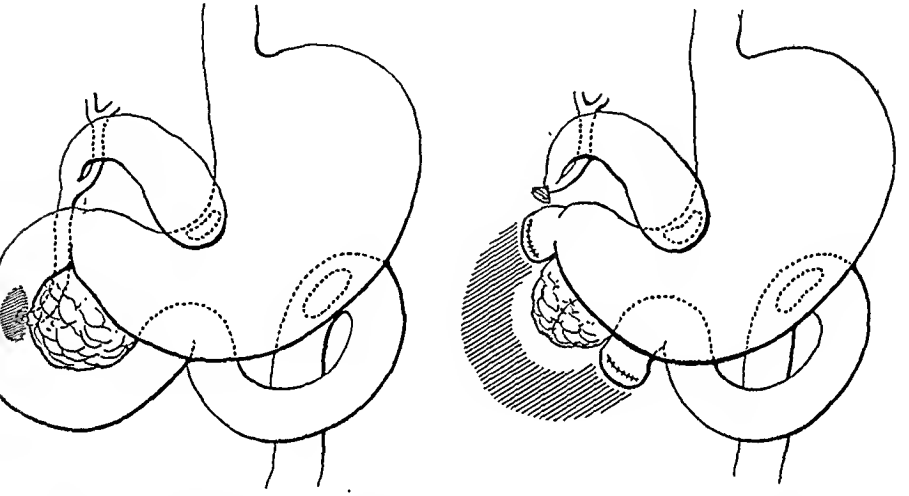

Fig. 3.—Two-stage operation described by Whipple, Parsons, and Mullins in 1935.

The incidence of cholangitis and cholecystitis occasioned by the cholecystogastrostomy was high after the operation devised by Whipple, Parsons, and Mullins.[5] Brunschwig,[24] in 1937, first used a loop of jejunum to establish biliary continuity and performed cholecystojejunostomy and an end-to-side jejunojejunostomy in the first stage of this operation. Whipple,[7] in 1938, described the modified operation now bearing his name (Fig. 4). This, too, was done in two stages. In the first stage, the common duct again was ligated and severed below the patent cystic duct. The jejunum was severed, the distal end was used for an antecolic cholecystojejunostomy, and the proximal end was reimplanted after the Roux Y principle in an end-to-side jejunojejunostomy 10 to 12 cm. below the cholecystojejunostomy. At the second stage, three to four weeks later, posterior gastroenterostomy and radical resection of the second portion of the duodenum, wide of the tumor, and removal of a wedge-shaped piece of the head of the pancreas were done.

Kafka[25] recently reported 115 cases in which some type of operation was done. In twenty-one of these some type of resection resulted in a mortality rate of 47.6 per cent. Orr[26] collected the fifteen cases reported

Hunt's collected series of 124 cases, they are listed in Table III to complete the record.

Excision.—Three of these eight patients (Cases 1, 4, and 7, Tables II and III) underwent transduodenal excision of the tumor without disturbance of the continuity of the common duct and duodenum (Fig. 6*a*). The tumors in these three cases were small and well localized and distant metastatic growths were not demonstrable. One patient (Case 1, Table II) died of hepatic insufficiency eight days after

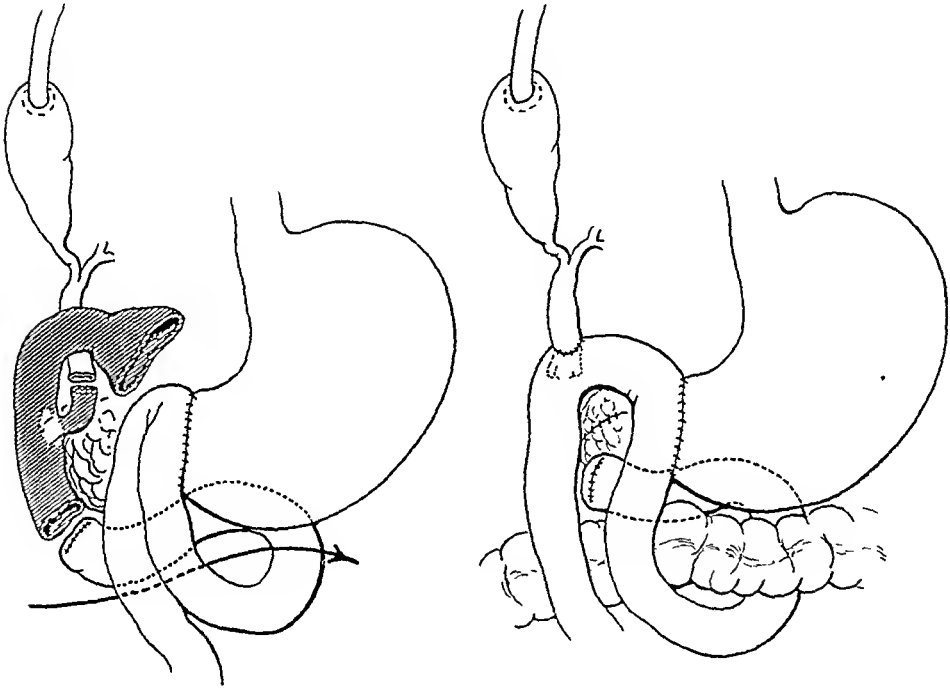

Fig. 5.—One-stage operation suggested by Trimble in 1941.

operation. Internal biliary drainage was established in two of the three cases and no attempt was made to arrange a new permanent route for bile and pancreatic secretions in one case because the common duct seemed to be patent. This patient (Case 4, Table II) lived thirty-five months and died of metastatic carcinoma. Excision of the tumor, however, was preceded by choledochostomy by one month and cholecystogastrostomy became necessary nine months later. He was then comfortable for one and one-half years, at which time symptoms of obstruction at the pylorus necessitated posterior gastrojejunostomy. He lived eight months after this last operation. The third patient (Case 7, Table II) had undergone cholecystogastrostomy, in June, 1939, elsewhere for an indeterminate type of obstruction of the common bile duct. Nine months later transduodenal excision of adenocarcinoma grade 1

There is no more comprehensive review of the operative mortality, cause of death, and subsequent course than this most recent publication of Hunt's. Orr's[28] discussion of this article is pertinent. He stated: "Following palliative operation a patient with proven carcinoma of the ampulla has been known to live thirty-three months; after transduodenal resection patients have lived four to twenty-two years; and after resection of the duodenum and pancreas one patient has lived thirty-four months, although the average length of life in each of these groups is much shorter." Orr[28] summarized the findings of various authors concerning the average time of survival of patients who had carcinoma of the ampullar region as follows: 7.3 months when no treatment was given (Outerbridge); 7.7 months when palliative operation was employed (Judd and Parker); eight months when treatment with radium and roentgen rays was given (Pack and McNeer); more than 1.7 years after radical operation according to Hunt's data on the thirty patients in his series who had died, and more than 2.5 years after radical operation according to Hunt's data on thirty-four patients who were living at the time of his report. In many of the cases in Hunt's last group follow-up data were not recorded so the results may be even better. However, as noted by Orr and shown in Hunt's series of cases collected from the literature, the less radical procedures of transduodenal excision or resection have a lower mortality rate and a small number of patients have survived relatively long periods.

Trimble and his associates[6] have recently described a one-stage operation for tumors in this region which it is suggested has removed all of the objections to the operations previously described (Fig. 5). In this operation the pyloric end of the stomach, the first and second portions of the duodenum, the distal third of the common bile duct, and a wedge-shaped piece from the head of the pancreas are resected en bloc. The duodenal stump is closed and the raw surfaces of the remaining pancreas carefully approximated. Gastrointestinal continuity is reestablished by a complete antecolic isoperistaltic terminolateral gastrojejunostomy. Distal to this anastomosis the stump of the common bile duct is implanted into the jejunum.

Transduodenal Excision or Resection.—If the tumor is small and the patient is in poor condition, transduodenal excision or resection must be considered. Eight such operations were performed at the Mayo Clinic from 1908 to Nov., 1941, inclusive (Tables I and II). All were on men. Symptoms of obstruction to the common duct had been present from three weeks to five and one-half months prior to the first operation. The correct diagnosis was not made in any case before the first operation was performed. The mortality rate was 37.5 per cent. Although many of these cases have been reported previously and are a part of

TABLE I

TYPES OF OPERATION AND MORTALITY

TYPES OF OPERATION	NUMBER	DEATHS	PER CENT
Resection for tumor:			
Transduodenal approach	8	3	37.5
Modified Whipple two-stage operation	1	1	100.0
Palliative operation:			
Origin of tumor proved by biopsy or necropsy	23	9	39.1
Origin of tumor conclusive in opinion of surgeon but not proved by biopsy	20	1	5.1
Exploratory only:			
Origin of tumor proved by biopsy or necropsy	3	3	100.0
Total	55		

tube. The patient died of peritonitis and hemorrhage two days later. Another patient (Case 8, Table II) had had cholecystectomy and choledochostomy in 1940. In six months, symptoms of obstruction of the common duct appeared and in fifteen months choledochostomy revealed the presence of the tumor. Six weeks later transduodenal excision of the tumor with resection of the lower end of the common bile duct and the cuff of the duodenum was performed. Choledochoduodenostomy was performed (Fig. 6*b*). The patient convalesced well and lived for twelve months after the tumor was excised.

Two patients in this group were treated by a one-stage procedure without operative death. One of these (Case 3, Table II) had undergone cholecystectomy two months previous to the onset of jaundice. Secondary exploration revealed the tumor and it was resected transduodenally with a part of the common duct and choledochoduodenostomy was carried out over a Mayo tube. The patient lived twenty-six months, dying of recurrence of the tumor. Twenty-one months after resection of the tumor, exploration revealed the recurrence but no palliative operation could be carried out. The second patient (Case 5, Table II) lived nineteen months after transduodenal resection of the lower end of the common duct and posterior wall of the duodenum. Thirteen months after operation or six months before his death, exploration because of obstructive symptoms revealed the recurrent tumor from which he died.

In the last of the five cases of transduodenal resection (Case 6, Table II) a two-stage operative procedure was employed. It rather resembled a Whipple operation except that it was not so extensive. At the time of cholecystogastrostomy, the tumor was noted; this operation was followed in five months by transduodenal excision of the tumor, lower third of the common duct, a large portion of duodenal wall, and part of the head of the pancreas. The common duct was ligated permanently, internal biliary drainage being anticipated through the cholecystogastrostomy. Jejunostomy was carried out. The patient died in two days of peritonitis.

was done at the clinic and a new cholecystogastrostomy was made because the first one had failed to function. The patient returned to the clinic Nov. 1, 1941, with mild symptoms of pyloric obstruction. Roentgenographic examination showed slight obstruction of the second portion of the duodenum. Nov. 19, 1941, posterior gastroenterostomy was performed and exploration revealed obvious metastatic growth in the retroperitoneal nodes. Convalescence was satisfactory and the patient returned home. Death occurred two months later, two and one-half years after the first palliative procedure was done or nearly two years following excision of the tumor.

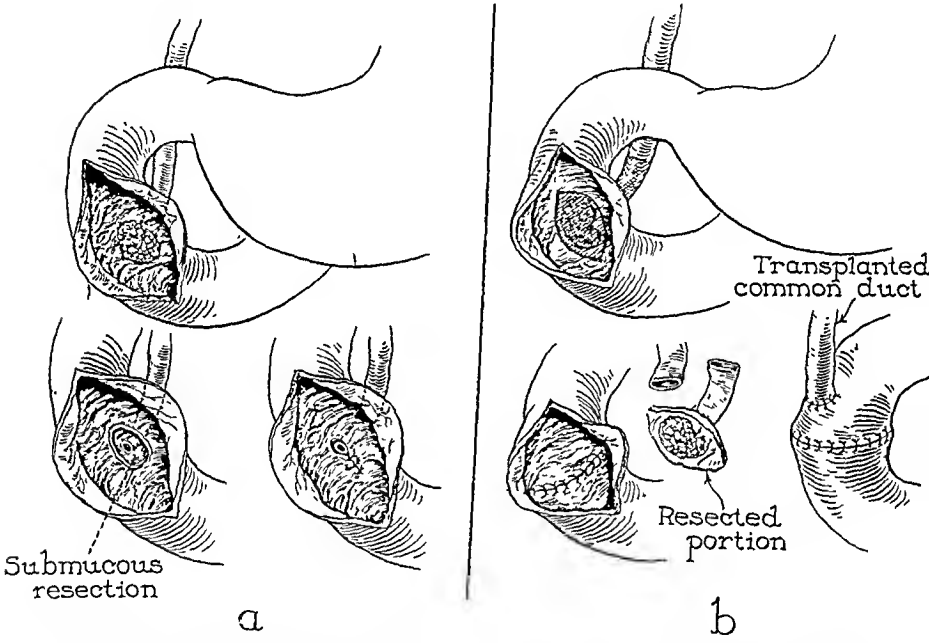

Fig. 6.—Transduodenal excision of the carcinoma of papilla of Vater; *a*, without disturbance of the continuity of the common ducts and duodenum; *b*, with transplantation of the common bile duct.

Resection.—Transduodenal resection for a tumor of some portion of the common duct and duodenum was performed in five cases and a modified Whipple operation was performed in two stages in one case (Table III). The patient who had the Whipple type operation succumbed to peritonitis only eight days after the second operation. Two of the five transduodenal resections were carried out in multiple stages, with one death. In the case in which death occurred (Case 2, Table II), cholecystostomy was done at the time of exploration for obstruction of the common duct of unknown cause. The tumor was noted at that time. Three months later transduodenal excision of the tumor together with resection of 1 inch (2.5 cm.) of common duct was carried out. Internal biliary drainage was instituted by choledochoduodenostomy over a Mayo

TABLE III

TRANSDUODENAL RESECTION OR EXCISION OF CARCINOMA OF AMPULLA

TYPES OF OPERATION	TOTAL	SURVIVED	MORTALITY (PER CENT)	LONGEST SURVIVAL (MO.)*
Excision only, reimplantation common duct not necessary	3	2	33.33	
With establishment of internal biliary drainage	2	1	50	22
Without establishment of internal biliary drainage	1	1	0	35
Excision of tumor and resection of varying amounts of common duct and duodenum	6			
With reimplantation of common duct (multiple stages)	2	1	50	2
With reimplantation of common duct (one stage)	2	2	0	19 and 26
Common duct severed permanently and internal biliary drainage	1	0	100	
Modified Whipple operation, two stages	1	0	100	

*From time of removal of tumor to death.

teen of those patients were men. From one week to thirty months had elapsed between the onset of symptoms of obstruction of the common duct and any attempt at surgical treatment. These patients waited an average of 6.5 months after symptoms appeared before exploration. This is probably significant when compared with the shorter period of five and one-half months in those cases in which some type of removal of the tumor was possible. In most of these cases the patients were in such poor condition that one-stage removal of the lesion could not be attempted. In a few cases the palliative operation was considered as the first stage to subsequent removal of the tumor, but the patients did not return for the completion of the operation. In three cases there was evidence of metastatic growth at the time of the palliative operation. Nine of the twenty-three patients died in the hospital after the operation, a mortality rate of 39.1 per cent.

The types and frequency of palliative operations are listed in Table IV. Cholecystogastrostomy was used most frequently and was followed by a high mortality rate. These facts were emphasized by Judd and Hoerner[3] years ago. However, one patient lived forty-one months after palliative cholecystogastrostomy. Two had further operations, such as gastrojejunostomy, to relieve symptoms of obstruction at the outlet of the stomach. As a group, patients on whom cholecystogastrostomy was performed were in poorer condition than those on whom choledochostomy or choledochoduodenostomy was indicated. Cholecystostomy was performed five times with no deaths, but as would be expected, some further, more permanent operation to relieve obstruction of the common duct was required in all five cases. Choledochostomy or cholecystogastrostomy

TABLE II

TRANSDUODENAL RESECTION OR EXCISION OF THE TUMOR

CASE	DATE	TYPE OF OPERATION	PATHOLOGIC FINDING	DURATION OF LIFE FROM REMOVAL OF TUMOR*
1	5/ 9/19	Transduodenal excision, common duct not severed from duodenum; cholecystoduodenostomy	Adenocarcinoma	8 days
2	12/29/21	Cholecystostomy; tumor noted	Adenocarcinoma	2 days
	3/24/22	Transduodenal resection with 1 inch of common duct; choledochoduodenostomy over Mayo tube; cholecystostomy		
3†	10/ 8/24	Cholecystectomy; tumor not noted	Colloid carcinoma	26 mo.
	1/10/25	Transduodenal resection of lower end of common duct; choledochoduodenostomy over a Mayo tube		
	9/20/26	Exploration for recurrence of carcinoma		
4†	11/ 1/28	Choledochostomy; biopsy	Carcinomatous polyp	35 mo.
	12/21/28	Transduodenal excision; plastic on common duct not necessary		
	9/ 9/29	Cholecystogastrostomy for recurring carcinoma		
	4/27/31	Posterior gastroenterostomy for recurrence of carcinoma		
5†	7/23/31	Transduodenal resection of lower end common duct and posterior wall of duodenum; choledochoduodenostomy over catheter	Adenocarcinoma, grade 2	19 mo.
	8/30/32	Exploration; recurrence of carcinoma		
6	7/13/37	Cholecystogastrostomy; tumor noted	Signet ring adenocarcinoma, grade 2	2 days
	2/10/38	Transduodenal resection of lower end of common duct, wall of duodenum, and part pancreas; common duct tied off permanently; jejunostomy		
7	6/39	Cholecystogastrostomy performed elsewhere	Adenocarcinoma, grade 1	22 mo.
	3/16/40	Transduodenal excision; common duct not severed. New cholecystogastrostomy		
	11/19/41	Exploration and posterior gastroenterostomy for recurrence of carcinoma		
8	6/24/40	Cholecystectomy; choledochostomy	Adenocarcinoma, grade 1	12 mo.
	9/11/41	Choledochostomy; tumor noted		
	10/22/41	Transduodenal resection for tumor, lower end of common duct; choledochoduodenostomy		

*Death had occurred in all cases.
†In Hunt's report.

Palliative Operations.—

Presence of tumor proved by biopsy or necropsy: In twenty-three cases biopsy or necropsy revealed carcinoma of the ampullar region and some type of palliative operation was performed (Table I). Nine-

COMMENT

Carcinoma of the papilla of Vater is not a rare disease, but early and correct clinical diagnosis of the presence of the lesion is unusual. Partly because of this but mostly because of the inaccessibility of the lesion, the usual poor condition of the patients, and the risk of radical surgical procedures, advance in the treatment of the disease has been discouragingly slow. The tumor is usually small, grows slowly, metastasizes late, and even the discerning eye can seldom detect early signs of its presence. Whether or not the prediction of the exact site of the lesion can be made accurately, obstruction to the common bile duct can be suspected early. Most obstructive symptoms attending carcinoma of the papilla will not yield to medical treatment, therefore, since correct preoperative diagnosis of ampullar lesions seems improbable, any patient who exhibits the signs and symptoms of obstruction of the common duct should be given the benefit of exploratory operation if the disturbances do not subside after the use of conservative measures for six to eight weeks. In most instances complete and permanent obstruction of the common bile duct does not occur as it frequently does in cases of carcinoma of the head of the pancreas. In fact, the growth may attain considerable size before complete obstruction of the duct occurs.

The technique of surgical treatment of lesions is rapidly being perfected. It can be applied equally well to carcinoma of the head of the pancreas, the common bile duct, or both. Until recently the best treatment seemed to be palliative procedures aimed at relief of the obstruction. Occasionally, transduodenal excision of the tumor or resection has been attempted, but the rarity of the attempt is attested by the fact that up to 1942 less than 125 cases have been reported in the literature. Recently Whipple revived interest by his two-stage operation and Trimble modified that procedure apparently with good results. Both of these procedures embody the principle of block resection for carcinoma. The gastrojejunostomy advised by both Whipple and Trimble forestalls the pyloric obstruction which is likely to develop if the patient survives for a reasonable length of time.

Although this study would indicate that at present simple palliative procedures anticipating both pyloric and biliary obstruction will offer as many months of comfortable living as any of the more radical operations, efforts to accomplish a cure by the use of the Whipple technique or some modification as suggested by Trimble must be encouraged.

REFERENCES

1. Upcott, Harold: Tumors of the Ampulla of Vater With Report of Two Cases, Ann. Surg. 56: 710-725, 1912.
2. McNeal: Quoted by Marshall, J. M.: Tumors of the Bile Ducts, Surg., Gynec. & Obst. 54: 6-12, 1932.
3. Judd, E. S., and Hoerner, M. T.: Surgical Treatment of Carcinoma of the Head of the Pancreas and of the Ampulla of Vater, Arch. Surg. 31: 937-942, 1935.

TABLE IV

PALLIATIVE OPERATIONS: PRESENCE OF TUMOR PROVED BY BIOPSY OR NECROPSY

TYPE OF OPERATION	NUMBER	OPERATIVE DEATHS	MORTALITY (PER CENT)	FURTHER OPERATION NECESSARY	AVERAGE* LIFE (MO.)	LONGEST LIFE (MO.)
Cholecystogastrostomy	8	5	62.5	2	17	41
Choledochostomy	5	1	20.0	1	16	37†
Cholecystostomy	5	0		5	6	20
Cholecystostomy and choledochostomy	2	1	50.0	1		20
Choledochoduodenostomy	2	1	50.0	0		11
Cholecystogastrostomy and choledochostomy	1	1	100.0			
Total	23	9	39.1	9	13	41

*From time of first palliative operation to date of death (January, 1942).
†Patient living at time of inquiry.

seemed to be the operation of choice if, for some reason, removal of the tumor was impossible. Fourteen patients survived some form of palliative operation; all were traced and all but one had died at the time of the last inquiry (January, 1942); this patient was living thirty-seven months after choledochostomy. The average length of life (Table IV) following palliative operation for this disease was twelve and one-half months in this group of cases.

Presence of tumor not confirmed by biopsy: This group of twenty cases is included only for comparative purposes. No actual proof of the location of the lesion was obtained, but in every instance the surgeon stated definitely that in his opinion the tumor was in the ampulla of Vater. A diagnosis of carcinoma of the papilla was not made preoperatively. Seventeen of the twenty patients were men. Only one died in the hospital immediately after operation (Table I). The other nineteen were traced until Nov. 15, 1941, but only two were living. Cholecystogastrostomy was performed for fourteen of these patients and all survived the operation. Two were still living at the time of the last inquiry (January, 1942). The average postoperative duration of life of the twelve patients who had undergone cholecystogastrostomy and had died was fourteen months. Cholecystostomy only was done in two cases; one patient died in the hospital after operation and one lived fifteen months. Cholecystoduodenostomy was provided in two cases, choledochostomy in one case, and cholecystostomy combined with choledochostomy in one case.

Exploration Only.—In three cases exploration only was carried out because of obstruction of the common duct of unknown origin. Biopsy in one case and necropsy in two cases proved the primary lesion to be in the region of the ampulla. All three patients succumbed within seven days after the operation.

CHRONIC CONSTRICTIVE PERICARDITIS

J. E. Strode, M.D., F.A.C.S., and S. E. Doolittle, M.D., F.A.C.P.
Honolulu, T. H.
(From The Clinic, Honolulu)

CHRONIC constrictive pericarditis, fortunately, is not a common disease. In the past, comparatively few surgeons have had the opportunity of operating upon patients with such a condition. In an analysis of 150 cases in which surgery was done, cited by Heuer and Stewart,[1] there were 49 operators, 27 of whom had operated upon only a single patient, 7 on two patients, 6 on three patients, and only 8 surgeons had operated upon five or more. Blalock and Burwell,[2] and Harrison and White,[3] to date have observed the largest number of cases in the United States, and also the greatest number brought to surgery—the former 28, with 20 patients subjected to surgery, and the latter 37, with 28 operated upon. Perusal of current literature dealing with this subject shows that only in a few of the larger medical centers has this condition received much attention. However, with increased interest in chest surgery in general and with a more widespread familiarity with the clinical picture of constrictive pericarditis, such cases are being recognized and brought to surgery, and in many cases most gratifying results have been obtained.

Every community has its quota of individuals suffering from this condition; individuals who are chronic invalids and who could be returned to a useful occupation and state of happiness if given a correct diagnosis and proper surgical intervention. It is with the idea of stimulating increased interest in this subject, particularly in localities apart from the larger medical centers, that this discussion is presented.

Chronic constrictive pericarditis is a condition brought about by an inflammatory lesion of the pericardium. It results in thickening and shrinking of the cardiac envelope, usually in association with a similar lesion in the epicardium, to the point where cardiac function is seriously interfered with. While there may be some interference with systole, due to myocardial involvement and adhesions, the primary dysfunction results from the inability of the heart to dilate adequately during diastole. This results in the heart being unable to receive enough blood to maintain an adequate arterial circulation.

Heuer and Stewart found in their group of patients that the arterio-venous oxygen difference was increased, the venous pressure was elevated, and the circulation time prolonged, while the cardiac output per

Received for publication, Aug. 13, 1943.

4. Codivilla: Quoted by Sauvé, L.[15]
5. Whipple, A. O., Parsons, W. B., and Mullins, C. R.: Treatment of Carcinoma of the Ampulla of Vater, Ann. Surg. 102: 763-779, 1935.
6. Trimble, I. R., Parsons, J. W., and Sherman, C. P.: One Stage Operation for Cure of Carcinoma of Ampulla of Vater and of Head of Pancreas, Surg., Gynec. & Obst. 73: 711-722, 1941.
7. Whipple, A. O.: Surgical Treatment of Carcinoma of the Ampullary Region and Head of the Pancreas, Am. J. Surg. 40: 260-263, 1938.
8. Outerbridge, G. W.: Carcinoma of the Papilla of Vater, Ann. Surg. 57: 402-426, 1913.
9. Rolleston, Humphry, and McNee, J. W.: Diseases of the Liver, Gall Bladder and Bile Ducts, Ed. 3, London, 1929, Macmillan & Co., Ltd., pp. 738-758.
10. Baggenstoss, A. H.: Major Duodenal Papilla: Variations of Pathologic Interest and Lesions of the Mucosa, Arch. Path. 26: 853-868, 1938.
11. Cooper, W. A.: Carcinoma of the Ampulla of Vater, Ann. Surg. 106: 1009-1034, 1937.
12. Sharpe, W. S., and Comfort, M. W.: Carcinoma of the Papilla of Vater; Clinical Features in 40 Cases, Am. J. M. Sc. 202: 238-245, 1941.
13. Halsted, W. S.: Contributions to the Surgery of the Bile Passages, especially of the Common Bile Duct, Bull. Johns Hopkins Hosp. 11: 1-11, 1900.
14. Mayo, W. J.: Malignant Disease Involving the Gall Bladder. In: A collection of papers published previous to 1909, vol. 1, Philadelphia, 1912, W. B. Saunders Company, pp. 384-391.
15. Sauvé, L.: Physiologic due pancréas, Arch. gén. de méd. pp. 25-44, 1908.
16. Cohen, Ira, and Colp, Ralph: Cancer of the Periampullary Region of the Duodenum, Surg., Gynec. & Obst. 45: 332-346, 1927.
17. Fulde, Ewald: Die bekannt geworden Ergebnisse der Radikaloperationen der Gallengangskrebse, Zentralbl. f. Chir. 54: 1481-1487, 1927.
18. Hunt, V. C., and Budd, J. W.: Transduodenal Resection of the Ampulla of Vater for Carcinoma of the Distal End of the Common Duct, Surg., Gynec. & Obst. 61: 651-661, 1935.
19. Berg, B. N., and Zucker, T. F.: Liver Changes After Deprivation of External Pancreatic Secretion, Proc. Soc. Exper. Biol. & Med. 29: 68-70, 1931.
20. Dragstedt, L. R.: The Present Status of Lipocaic, J. A. M. A. 114: 29-32, 1940.
21. Boyce, F. F., and McFetridge, E. M.: An Experimental Study of Operations Which Involve Exclusion of the Pancreatic Secretion From the Intestinal Tract With Special Reference to the Possible Effects on Protein and Fat Digestion and on the Metabolism of the Liver Cell, SURGERY 4: 51-63, 1938.
22. Snell, A. M., and Comfort, M. W.: Hepatic Lesions Presumably Secondary to Pancreatic Lithiasis and Atrophy; Report of Two Cases, Am. J. Digest. Dis. 4: 215-218, 1937.
23. Cole, W. H.: The Clinical Relationship of Pancreatic Disease to Fatty Infiltration of the Liver, SURGERY 8: 716-718, 1940.
24. Brunschwig, Alexander: Resection of Head of Pancreas and Duodenum for Carcinoma-Pancreatoduodenectomy, Surg., Gynec. & Obst. 65: 681-684, 1937.
25. Kafka, Wenzel: Ein Beitrag zu den Radikaloperationen des Papillenkrebses, Beitr. z. klin. Chir. 170: 547-559, 1939.
26. Orr, T. G.: Resection of Duodenum and Head of Pancreas for Carcinoma of Ampulla, Surg., Gynec. & Obst. 73: 240-243, 1941.
27. Hunt, V. C.: Surgical Management of Carcinoma of the Ampulla of Vater and of the Periampullary Portion of the Duodenum, Ann. Surg. 114: 570-601, 1941.
28. Orr, T. G.: Discussion, Ann. Surg. 114: 601-602, 1941.

Briefly then, the two changes in the dynamics of the circulation that are productive of symptoms and clinical findings are, first, the diminished ability of the heart to pump blood per beat and per minute and its inability to increase the output due to its inability to dilate, and, second, the increase in systemic venous pressure.

The name "Pick's disease" is commonly used to designate the condition of constrictive pericarditis, although White,[4] in a masterly discussion of this subject, points out that this condition was recognized long before Pick's time and that Galen, about A.D. 1600, described pericardial effusion in a monkey and scirrhous thickening in a cock, and surmised such an occurrence in man. White further states that Lower, in 1669, discussed this subject and should receive credit for the first satisfactory account of pericardial disease in man and the initiation of interest in the condition of acute and chronic constrictive pericarditis. Others contributing to the knowledge of the disease were Lancisi in 1728, Morgagni in 1761, and Laennec in 1818. At the end of the nineteenth century, namely in 1896, Pick emphasized the common finding of liver involvement and preponderant ascites, and so the disease has frequently been called by his name.

In the surgical consideration of this condition the names of Brauer, Delorme, Rehn, Sauerbruch, and Schmeiden, and in the United States Churchill, Heuer, Beck, Blalock, Cole, Bigger and others, have been intimately associated with the advancement of this means of therapy. Brauer, in 1898, advocated the resection of the chest wall over the region of the pericardium (the so-called operation of cardiolysis), and this operation was performed for him by Peterson, in 1902. The operation, naturally, has limited value and can be expected to be beneficial only in cases of attachment of the heart to the overlying chest wall. The modern operative procedure of pericardiectomy dates back to 1913 when both Rehn and Sauerbruch reported resection of the pericardium, although Delorme as early as 1895 had recommended this procedure. Churchill, in 1928, performed the first successful operation in America for the cure of this condition and since then a number of successful results have been reported from various clinics.

ETIOLOGY

The etiologic factor in the causation of constrictive pericarditis is variable, and even the commonest cause is not agreed upon. In Blalock and Burwell's series of cases the etiologic agent was established in 21 by aspiration, operation, or autopsy; 18 were found to be due to tuberculosis and 3 to *Staphylococcus aureus*. Such a preponderance of tuberculosis as an etiologic agent is not confirmed by other reports in the literature. Smith and Willius,[5] of the Mayo Clinic, found at autopsy 144 cases of chronic adherent pericarditis among 373 cases of pericardial disease; in 21.5 per cent the etiology was thought to be

minute, the stroke volume, and the cardiac index (cardiac output in liters per square meter of body surface per minute) was diminished.

As the inability of the heart to dilate increases with increasing constriction of the pericardium, or from actual constriction of the large veins at their passage through the pericardium, blood piles up in the vena cava causing increase in venous pressure which is normally negative in this location. Since most systemic veins have valves, the muscular action of the extremities assists in keeping the blood flowing

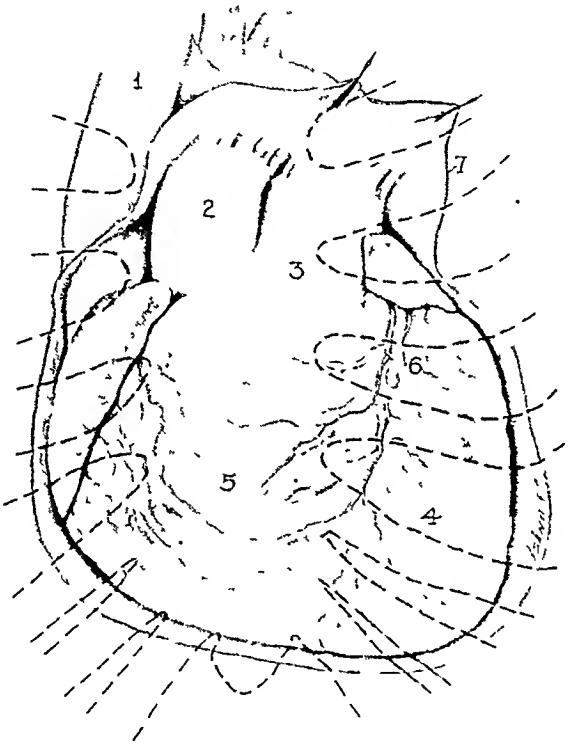

Fig. 1.—The normal anatomy of the heart. *1*, Superior vena cava; *2*, ascending aorta; *3*, conus arteriosus; *4*, left ventricle; *5*, right ventricle, *6*, anterior descending branch of superior coronary artery; and *7*, reflection of pericardium

toward the heart and helps to account for the comparatively late development of edema in the lower extremities. The hepatic veins being without valves, the liver is one of the first organs to be affected by the abnormal venous circulation. The liver becomes congested, enlarged, and tender, and soon portal decompensation results as shown by the development of ascites. From continued insult, fatty degeneration of the liver may occur, and even fibrous replacement. This is one of the reasons why a long period of recovery, even lack of complete recovery, may follow when relief from cardiac constriction is brought about surgically. Later in the course of the disease pleural effusion may take place and edema of the lower extremities usually occurs.

ening of the pericardium. No evidence of valvular heart disease can be made out, although auricular fibrillation may be observed. The arterial pressure is low and the pulse pressure is small. Paradoxical pulse (a pulse that is thready in volume on inspiration) is commonly present. The normal circulation time is 15 to 20 seconds, and in the cases of constrictive pericarditis where this feature has been studied it has been found to vary between 30 and 60 seconds. Fluoroscopy yields additional valuable information. It confirms the physical finding of a small or moderately enlarged heart. Small or absent ventricular pulsation is usually noted. The presence of areas of calcification of the pericardium may be made out. The heart is usually "frozen" to its position and does not change with change in position of the patient. Roentgenographic studies in multiple positions will confirm the fluoroscopic findings and will demonstrate calcium deposits if they are present. Varying degrees of calcification of the pericardium have been noted in from 20 to 40 per cent of the cases studied. In 37 cases reported by Harrison and White the heart was found to be of normal size in 18 instances and moderately enlarged in 19. Roentgen kymography may add important information in the doubtful case of constrictive pericarditis.

Rigler, Wangensteen, and Friedell[7] have this to say about kymography in this disease: "Roentgenologic findings are of paramount importance, since they provide direct evidence of the cardiac impairment caused by pericardial scarring. Of the specific roentgenologic methods, roentgen kymography is probably of greatest merit since it deals directly with important changes in the physiology and dynamics of heart action. It is, therefore, admirably adapted to the study of cardiac impairment in constrictive pericarditis and it is possible that this roentgenologic procedure may become the most important single method in the diagnosis of this disease. In a general way it may be considered as a permanent record of that which may be observed on the fluoroscopic screen which is not only helpful in the diagnosis and progress of the disease but in estimating improvement following surgery."

The electrocardiographic changes associated with pericarditis have been discussed in some detail by Noth and Barnes.[8] The electrocardiographic pattern in constrictive pericarditis is fairly constant. Typically it shows low voltage of the QRS complexes in the three standard leads, and low voltage T waves, isoelectric or inverted in various leads.

Differential Diagnosis.—Cole and his coauthors[9] state that constrictive pericarditis is most often mistaken for congestive heart failure. Dyspnea is common to both conditions, but they point out that it is not relieved by rest and recumbent posture so much in heart failure as in pericarditis. Ascites develops early in constrictive pericarditis, usually preceding edema of the feet. This sequence is usually reversed

due to rheumatic fever, in 17.4 per cent to pulmonary and pleural disease, 6.2 per cent to cardiac infarction, and 2.8 per cent to tuberculosis.

In 1934, Rothstein[6] collected all instances of adhesive pericarditis in children under 15 years of age who had been treated by operation. The number of cases was 34. Sixteen were thought to be due to rheumatic fever, 9 to tuberculosis, and 2 to pyogenic organisms. In Heuer and Stewart's 7 patients in whom surgery was done, only one case was proved to be due to tuberculosis.

White states that if rheumatism can cause Pick's disease it does so in only the rarest cases in contrast to the usually accepted origin. None of the 16 patients under observation at the Massachusetts General Hospital gave a history of rheumatism. He also refers to 1,000 children followed over a period of ten years at the House of the Good Samaritan in Boston. Not one developed constrictive pericarditis although in many, acute episodes of acute rheumatic pericarditis were noted. In a series of 37 cases studied by Harrison and White, the etiologic factor was found to be tuberculosis in 5, pneumonia in 2, sepsis in 1, and the etiology was unknown or questionable in 29.

The cause of the pericarditis in the two cases which we are presenting was not definitely established since no organisms were isolated from the tissue removed at operation and no diagnostic microscopic picture was present. Sepsis was suspected in one case, although tuberculosis could not be ruled out, and the other case may have resulted from a pneumococcus infection, although this is problematic.

CLINICAL FINDINGS

The symptoms and clinical findings in chronic constrictive pericarditis are fairly constant and lend themselves to differentiation from other conditions with which at times they may be confused. Bearing in mind the pathologic physiology of the circulation previously discussed, it is not difficult in most instances to interpret the clinical picture.

These individuals usually present well-marked evidence of circulatory embarrassment. Outstanding symptoms are generalized weakness, lessened work capacity, dyspnea on exertion (usually fairly promptly relieved by rest), congestion, discomfort about the face and neck, and swelling of the abdomen. Signs commonly present are venous congestions, as shown by distended arm, leg, and especially the neck veins. Cyanosis of varying degree is commonly noted, the liver is usually enlarged, at times markedly so, and varying degrees of ascites is usually present. Edema of the lower extremities and pleural effusion are less commonly found and splenomegaly is rarely associated. Venous pressure is constantly elevated. Readings of 20 to 30 cm. of water, which is about three times the normal, are usually found. This occurs without evidence of heart failure.

Physical examination reveals a small, or at most a moderately enlarged, heart. Some of the apparent enlargement may be due to thick-

Prognosis.—What is the outlook for the individual with constrictive pericarditis with and without surgery? The consensus of all observers who have expressed themselves on this subject is that constrictive pericarditis is a progressively crippling disease. There is no medical cure, although by rest, diuretics, and removal of accumulated fluid in the abdomen or pleura, the individual may be temporarily improved. The disease tends to be chronic and is expected to last over a period of several to many years, although it has been known to kill the patient in months rather than years. Spontaneous apparent recoveries or periods of improvement may be explained by an acute phase subsiding by the absorption of pericardial fluid.

What does surgery have to offer? In Churchill's series of cases 6 patients were cured, 3 improved, 1 died on the fifth postoperative day, and 2 in which active tuberculosis was encountered died soon after operation. In a follow-up study of 37 cases by Harrison and White from the Massachusetts General Hospital, including those cited by Churchill, it is reported that 28 of the patients were operated upon. Of these, 14 were clinically cured, 3 were greatly improved, 5 died due to complications from the operation, 2 died primarily of the disease itself, and 4 died at varying times, postoperatively, of other complications. Nine of the patients were not operated upon. In 3 the condition was too mild, 3 were too sick, 1 died of miliary tuberculosis, 1 died before operation came into vogue, and 1 case was lost sight of. Of Schmeiden's 6 patients reported cured, 4 are well after 10, 12, 17, and 18 years. Heuer and Stewart reported 7 cases, with no deaths, 3 patients cured, 3 markedly improved, and 1 too early to determine the outcome. They were able to collect from the literature 143 cases in which the patients had been operated upon and 135 of these had been followed. Fifty or 37 per cent were cured, 31 or 23 per cent had been improved, 54 or 40 per cent died during or soon after operation. They comment, "At first glance this record of surgical results may not appear to be impressive, but in judging the results it should be appreciated that the disease is incapacitating and invariably fatal, and to have improved or cured 60 per cent of cases subjected to surgery is after all a real achievement."

Rigler and his co-workers say, "In this condition we have one of the few cardiac lesions for which there is at hand a specific therapeutic procedure, which in many cases without great risk, results in the transformation of a completely disabled individual into one who is, if not cured, at least competent to perform his daily tasks. In scarcely any phase of the brilliant accomplishments of thoracic surgery during the past decade are the results more dramatic or gratifying."

OPERATION

It is generally agreed that pericardiectomy should not be done during the active stage of the pericarditis. This seems to be particularly

in congestive heart failure. The heart is small, or at most moderately enlarged, in constrictive pericarditis and usually is markedly enlarged in congestive heart failure. In failure of the heart, x-ray studies show congestion of the lung fields, while in constrictive pericarditis this is not found because the blood does not pile up in the auricles due to their inability to dilate. Murmurs or other evidence of underlying primary endocardial or myocardial disease are usually found in heart failure.

The individual with constrictive pericarditis usually has a history of long duration, and a similar amount of peripheral congestion, when due to congestive heart failure, takes place in a period of shorter duration in a much sicker patient. White lists, in the order of their importance, the things that are likely to cause confusion in the diagnosis of constrictive pericarditis.

1. Mitral stenosis
2. Polyserositis
3. Cirrhosis of the liver
4. Nutritional or other edema
5. Mediastinal tumors
6. Tricuspid valvular disease

He further states that mitral stenosis is accompanied by a characteristic diastolic murmur at the cardiac apex in the absence of severe active rheumatic infection, and that the presence of mitral stenosis may be taken at once as ruling out chronic constrictive pericarditis of any serious grade.

The finding of characteristic murmur, liver and venous pulsation, and change in heart contours is also important in the diagnosis of tricuspid heart disease.

In cirrhosis of the liver with ascites this organ is generally small, the individuals are usually in a later age group, and the characteristic findings of paradoxical pulse with low pulse pressure, distended jugular veins, and increase in venous pressure are absent.

Tuberculous peritonitis may have to be ruled out, although the characteristic findings of constrictive pericarditis are not present and the fluid examination shows it to be an exudate rather than a transudate. Evidence of pulmonary tuberculosis may be found in either condition.

Nutritional or other forms of edema are not usually associated with evidence of increased venous pressure. A therapeutic test with newer forms of parenteral vitamin and plasma protein therapy is quickly effective in eliminating these as causes.

Mediastinal tumors are readily differentiated by thorough roentgenographic study.

nal mammary vessels are ligated at the upper and lower ends of the exposure. Approximately one-half of the sternum is usually resected, although Heuer finds this unnecessary. (See Fig. 3.) The edge of the pleura can now be identified and wiped back, frequently resulting in an opening being made through this structure. This is of little consequence and the opening may be sutured or covered over with a moist pad. In fact, some observers advise leaving an opening into the pleura in non-infected cases to allow greater diffusion of any postoperative pericardial fluid. The stage has now been set for an attack on the pericardium. This may be an exceedingly simple procedure if the pericardium is calcified and not attached to the epicardium or it may be a very difficult, tedious, and dangerous task if the pericardium is densely adherent to the epicardium and the lines of cleavage difficult or impossible to identify. Each classification is represented by the two cases we are reporting.

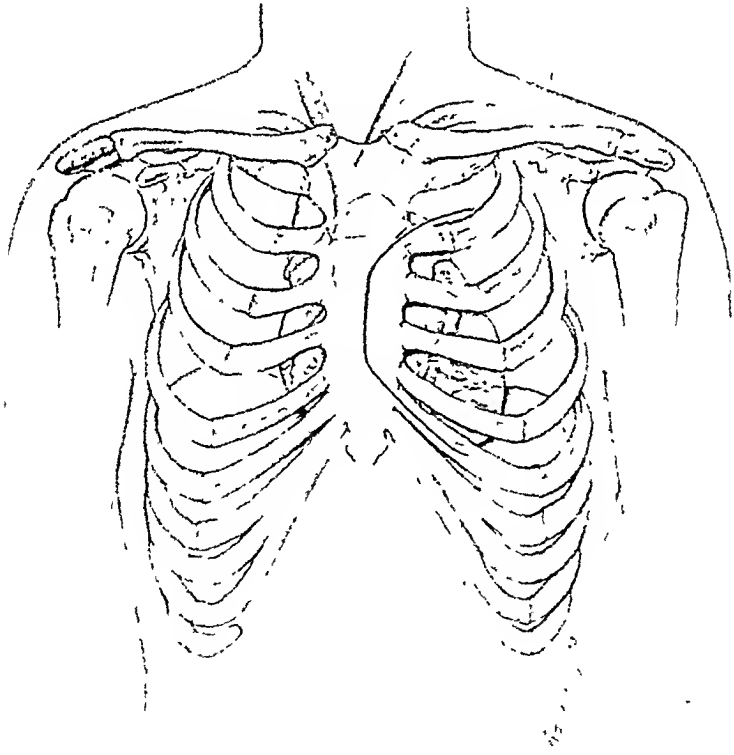

Fig. 2.—The relationship of the incision to the bony cage and underlying structures.

Certain principles governing the removal of the constricting capsule of the heart seem fairly universally agreed upon. First, that extreme care should be used to prevent injury to the anterior descending branch of the left coronary artery lying in the groove between the right and left ventricles. Second, that the left ventricle should be uncovered first.

true when the process is a tuberculous one. Pericarditis of nonrheumatic origin should be watched carefully for the onset of constrictive signs, as numerous cases have been cited where this sequence of events has been observed. Such individuals should not be subjected to surgery until the acute phase has had opportunity to subside; some suggest a period of six months to cool off, although each case should be individualized, and should not be neglected since the disease is usually progressive. With lapse of time the myocardium becomes weakened and the technique of the operation becomes more difficult.

Preoperative Preparation.—These individuals should have the abnormal accumulation of fluid in the tissues and serous cavities reduced to a minimum. Fluid in the pleural and abdominal cavities should be aspirated and that in the tissues reduced by diuretics and by limitation of fluid and salt intake. Mercupurin, 2 c.c. intravenously, every third day, limitation of fluids to 1200 or 1500 c.c. daily, and salt to 2 Gm. daily has been found of value. Intravenous fluids of all kinds such as saline, plasma, and blood are thought to be contraindicated preoperatively because of the edema and postoperatively to prevent undue strain on the decorticated myocardium. If the need postoperatively is great, small amounts of the fluids given slowly may be advisable. The use of digitalis, except in cases with auricular fibrillation, is usually contraindicated.

OPERATIVE TECHNIQUE

Position.—Most observers advise that the head of the operating table be elevated. This seems logical to help prevent venous engorgement. Churchill and others operate with the patient in a dental chair.

Anesthesia.—General anesthesia with differential pressure has distinct advantages because the pleura may be entered and positive pressure will prevent complete collapse of the lung and possible mediastinal shift. Nitrous oxide-oxygen ether mixture, ethylene, and cyclopropane have their advocates. The latter, in our experience with all types of chest surgery, has been most satisfactory. Intratracheal anesthesia is advised by many, although equally satisfactory results are obtained by a well-fitting mask and a closed system.

Incision.—The incision giving the best approach is a curved one, beginning in the region of the left second rib, carried down midsternally, and curved to the left over the sixth costal cartilage. (See Figs. 1 and 2.) The attachments of the pectoralis major muscle are separated from the edge of the sternum and costal cartilages. The third, fourth, fifth, and sixth costal cartilages and portions of the attached ribs are resected. It seems advisable to include the perichondrium if not the periosteum in order to prevent regeneration of the cartilage and thus allow subsequently greater freedom of cardiac movement. The flap consisting of skin, pectoralis major muscle, and intercostal muscle and vessels is turned back to the left as far as necessary to give adequate exposure. The inter-

Postoperatively.—These patients are usually benefited by inhalations of oxygen—by tent, mask, or catheter—by the use of morphine and sedatives, and by methods that were of value preoperatively, such as limitation of fluids and salt, and by aspiration of fluid from serous cavities.

CASE REPORTS

CASE 1 (Queen's Hospital No. 153811).—A Caucasian man, aged 41 years, was admitted March 31, 1942, and discharged April 16, 1942. About one and one-half years before admission to the hospital he began noticing a sense of fullness and flushing of the face, neck, and head, especially after eating, leaning over, or when lifting up objects. He developed shortness of breath when running upstairs and indulging in other exercises, but this had never been marked. He perspired more than he did formerly and had noticed swelling of the ankles, especially the right

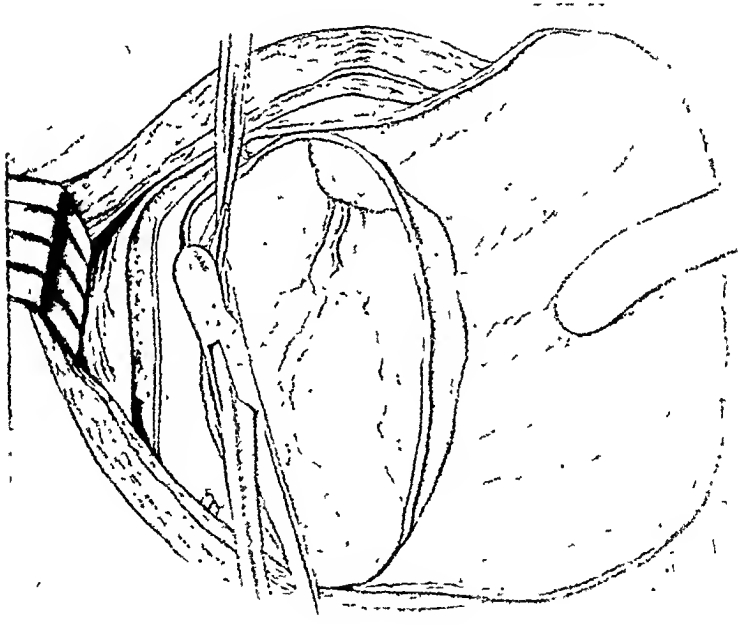

Fig. 3 (Case 1).—Exposure of pericardium showing ease of removal of calcified pericardium when unattached to the epicardium.

one, for the past four months The left one was swollen also, but not as much as the right. There had been increasing leg varicosities for a longer period. Past history was essentially negative except for an illness of serious consequence in 1937. He was told, in 1915, that he should give up swimming because he had some trouble with his heart. He did not, however, cut down on physical activity and suffered no apparent ill effects. In January, 1937, a coral cut on the right foot became infected and lymphangitis and inguinal adenitis quickly developed with associated fever and malaise. Soon after this he developed what appears to have been a metastatic infectious arthritis involving the right wrist and phalangeal joint of the middle finger of the left hand. There has been permanent deformity of these joints since. The patient remembers that he had to sit up for a few nights during the illness because

Its musculature is thick and there is less likelihood of entering the cavity of the heart than elsewhere. Also, if the right ventricle is freed first, more blood will be permitted to enter the lung and this, coupled with lack of support to the heart muscle, may allow the ventricle to dilate, resulting in acute pulmonary edema and cardiac failure. It should be remembered that the greater part of the heart presenting anteriorly is the right ventricle and that the left ventricle lies well to the left and behind. (See Fig. 4.) Third, it is a dangerous procedure and in most instances it is unnecessary to attempt to free the auricles and the great vessels to and from the heart. Their walls are thin and easily penetrated. Fourth, it is necessary to remove not only the pericardium but usually also the epicardium to free the heart. Frequently no line of cleavage exists between these two structures. Fifth, when removing the constricting fibrous tissue it is well, as first pointed out by Bigger,[10] to leave one side attached during the dissection so it can be used as a flap to cover over the area in case the heart cavity is accidentally penetrated.

The extent to which decortication should be carried out is undecided and each case presents its own individual problem. It seems desirable to free as much of both right and left ventricles as can be done with safety, and particularly to free the apex of the heart, which is usually adherent to the diaphragm. It is advisable to give the heart periods of rest during the operation. Frequently the action of the heart becomes irregular and rest of a minute or two will allow it to resume its normal pace. If the patient is in poor physical condition, and frequently such patients are, especially if the nature of their illness has been long unrecognized, and the dissection is time-consuming, it may be advisable to do the operation in stages as was necessary in one of our cases. It may even be advisable, at a subsequent time, to decorticate the right side of the heart through an incision to the right of the sternum similar to the one previously described on the left side.

Little suture material is needed in this operation except for control of hemorrhage in the flap and during the closure. In one of our cases we used silk and in the other cotton. In both instances the operative field was lightly dusted with sulfanilamide powder. Whether or not this is advisable is questionable since the use of this powder in operative wounds elsewhere undoubtedly increases the amount of serum.

Cole advises draining the pericardial area by use of a small rubber drain in the upper or lower end of the incision. Postoperative aspiration, if necessary, would seem advisable rather than drainage as a procedure less likely to result in infection. One of our patients was aspirated, the other was not; neither was drained. It apparently is an infrequent occurrence for cardiac embarrassment to result from tamponade after pericardiectomy because the fluid is no longer encased in a nonelastic sac but can diffuse into the tissues of the chest wall and usually into the mediastinum.

Electrocardiogram showed small QRS complex in three standard leads. T waves were of low amplitude throughout, being flat in the first lead and inverted in Leads II and III. Urine was negative, red cell count 3.95 million, white cell count 8,800, polymorphonuclears 49 per cent, small lymphocytes 40 per cent, monocytes 8 per cent, eosinophiles 3 per cent. Icterus index was 23, van den Bergh delayed direct reaction 16.6 mg. per 1000 c.c. of serum, Weltmann coagulation test, coagulation 1. 6 tubes normal. Sedimentation rate was 3.3 per cent: plasma protein 4.55 Gm. per 100 c.c. of blood; direct venous pressure on March 11, 1942, right arm 26 cm., left arm 22 cm., right leg 18 cm., left leg 23 cm. On April 1, 1942, 1200 c.c. of straw colored fluid was aspirated from the abdomen. Culture was sterile. On April 2, 1942, the patient was given 500 c.c. of plasma with 100 c.c. saline solution.

Fig. 5.—Autopsy specimen showing reaction about heart following pericarditis complicating influenza. It is easy to see how such a reaction might be followed by constrictive pericarditis.

Operation.—Operation was done April 3, 1942, with cyclopropane anesthesia, differential pressure. The head of the table was raised to an angle of 30 degrees. An incision over the front of the chest was made as shown in Fig. 2. The attachments of the pectoralis major muscle were freed and reflected. The third, fourth, fifth, and sixth costal cartilages with the perichondrium were removed, and portions of the fourth and fifth ribs were resected subperiosteally. The left pleura was carefully wiped back to the region of the left phrenic nerve. The mammary vessels were ligated and divided at the upper and lower margins of the exposure. This gave an excellent view of the calcified pericardium. It gave the appearance of a large china egg deposited behind the sternum. No cardiac pulsation was visible and as far as could be determined the entire pericardium had become calcified except the outer layer which was quite thin but tough and fibrous. The underlying calcium was easily broken through and consisted of two very thin layers. In no place was it attached to the epicardium. It shelled off with almost as much ease as one might experience in peeling an onion. The underlying heart looked normal and protruded

of suffocation on lying down. The entire episode lasted about four months. There was a positive family history of tuberculosis. One brother was treated in a sanatorium after he reached adult life. Contact with this brother was infrequent.

For the past six months the patient had noticed some distention of the abdomen. His weight had increased ten pounds but his friends remarked that his face was thin. There was slight distress in the cardiac area but he had never had pain of any severity. The last four or five years when his bed came up close to the wall he noticed that it bumped against the wall with each heart beat, making him think that he must have very strong cardiac pulsations. For the past few months he had been extremely tired and had not been able to do his daily tasks. He found that he rode where he formerly walked. He also complained of loss of sexual desire.

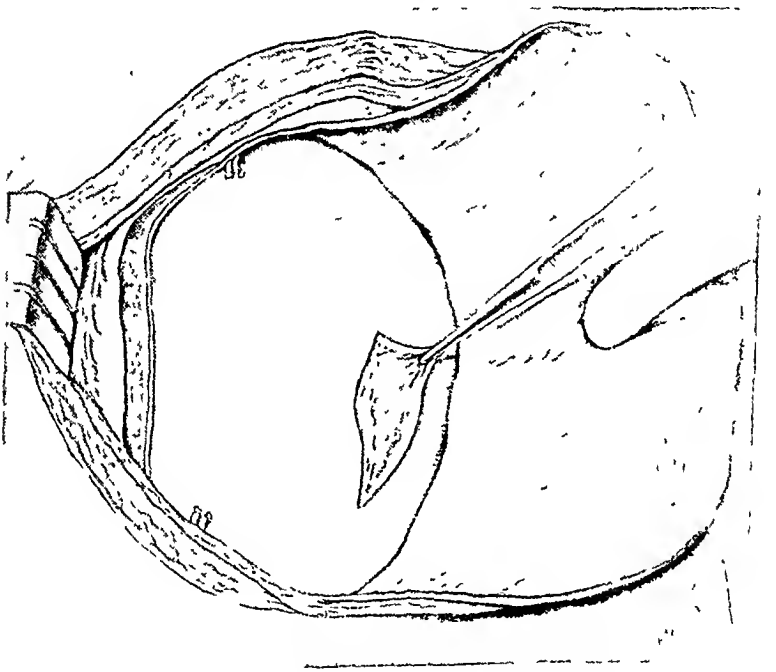

Fig. 4 (Case 2).—Pericardium and epicardium densely united to one another making removal a slow, tedious, and dangerous procedure

Examination showed congestion of the face when lying down and pulsation of the jugular veins. There was slight cyanosis of lips and nail beds. The veins in the arms were prominent and there were rather marked varicosities in both legs. There was edema in both ankles, especially the right. The abdomen was distended and all signs of fluid were present. The liver was palpable four fingerbreadths below the right costal margin, and somewhat nodular. The pulse was regular and no paradoxical tendency was noted. Rectal examination was negative. Blood pressure was 116/70. Heart examination showed the point of maximum impulse just outside of the midclavicular line. Apex beat was somewhat increased in force but sharply circumscribed. A split second sound was heard at the apex (confirmed by stethogram). On fluoroscopy the heart was not enlarged and the amplitude of pulsation was diminished. X-ray of the chest showed large hilar shadows with calcified areas and a small bilateral pleural effusion. The pericardium was calcified practically in its entirety. This was especially well seen in the lateral and oblique positions.

about two fingerbreadths below the right costal margin. Venous pressures were 14 cm. Electrocardiogram showed little change from the previous tracing.

CASE 2.—A Filipino girl, aged 9 years, was admitted to Leahi Hospital, March 22, 1939. She had always been emaciated and sickly. She had pneumonia at the age of 18 months and was hospitalized for three months at the age of 7 years with a diagnosis of malnutrition. In January, 1939, she had been admitted to Aiea Hospital with the diagnosis of pneumonia.



FIG. 7 (Case 1).—Oblique view of chest showing calcification of pericardium.

Examination revealed an emaciated, poorly developed girl. The jugular veins were prominent and pulsated. There was dullness on percussion and absence of breath sounds over the lower part of both chests. The abdomen was prominent and the liver edge was palpable three fingerbreadths below the costal margin. The spleen was not palpable. Blood pressure on admission was 78 systolic and 60 diastolic. The Mantoux test was negative on second strength purified protein derivative and up through 1.0 mg. of old tuberculin. Eagle and Kahn tests were negative. Serum protein was 7.1 mg. per cent, blood sugar 93 mg. per cent, blood cholesterol 138.9 mg. per cent, nonprotein nitrogen 28 mg. per cent. and urine negative.

X-ray of the chest on admission showed more bilateral pleural fluid on right side than on the left. The cardiac outline at the time was obscured but later studies after thoracentesis showed it not to be enlarged. No calcification of the pericardium could be seen. Fluoroscopic studies showed very little cardiac pulsation. Venous pressure averaged around 30 cm. of water. Electrocardiogram showed right axis deviation.

out through the undecked area as though being released from considerable compression. The left ventricle was freed first. The anterior descending branch of the left coronary artery was easily identified and protected. The left auricle and the region of the conus arteriosus were freed without difficulty as were the apex of the heart and the right ventricle and auricle as far as could be reached beneath the sternum. During the operation some irregularity of heart action occurred but not to a significant degree, probably because the heart itself was handled very little. A small opening was made in the left pleura. This was covered with a moist pad and no effort was made to close it. Sufficient positive pressure in the anesthetic system was used to prevent cardiorespiratory embarrassment. The bleeding points were carefully ligated. The operative field was lightly dusted with sulfanilamide powder and the incision was closed tight. Interrupted silk was used throughout.

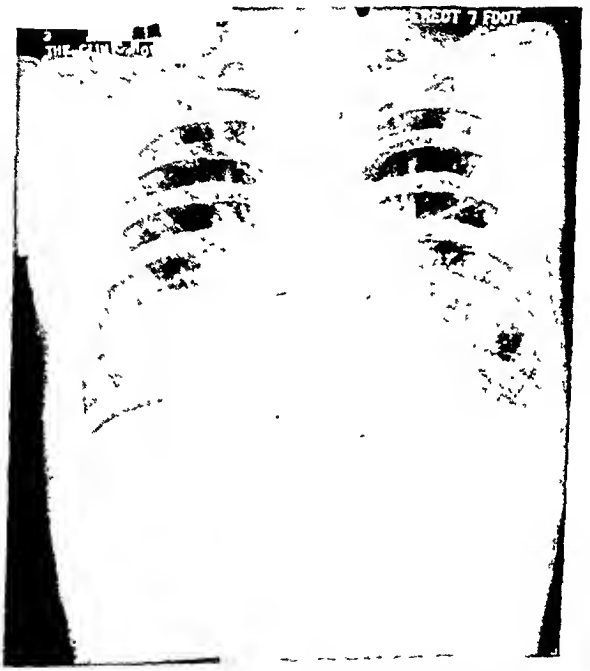

Fig. 6 (Case 1).—Roentgenogram of chest showing calcified left hilum gland, congestion of both hila and bases, and a small puddle of fluid in the costophrenic sulcus bilateral. Heart shadow is normal size.

Postoperative Course.—The patient was given nasal oxygen and morphine, gr. 1/6, as needed. He was given one intravenous injection of 500 c.c. of 5 per cent glucose in lactate Ringer's solution. On the third postoperative day a friction rub was heard in the left axilla, and on the fifth postoperative day 1500 c.c. of serosanguineous fluid was aspirated from the left chest followed by air replacement. On the twelfth postoperative day the venous pressure in the right arm was 12.5 cm. and in the left 11.3 cm. The patient made a good recovery and was discharged from the hospital on the thirteenth postoperative day.

One year after the operation the patient stated that as far as he could tell, he felt practically well. Slight congestion of the neck and face appeared when he lay down. Varicosities of the legs were present although much less marked than formerly. Slight ankle edema appeared at the end of the day. Liver was palpable

about two fingerbreadths below the right costal margin. Venous pressures were 14 cm. Electrocardiogram showed little change from the previous tracing.

CASE 2.—A Filipino girl, aged 9 years, was admitted to Leahi Hospital, March 22, 1939. She had always been emaciated and sickly. She had pneumonia at the age of 18 months and was hospitalized for three months at the age of 7 years with a diagnosis of malnutrition. In January, 1939, she had been admitted to Aiea Hospital with the diagnosis of pneumonia.

Fig 7 (Case 1)—Oblique view of chest showing calcification of pericardium.

Examination revealed an emaciated, poorly developed girl. The jugular veins were prominent and pulsated There was dullness on percussion and absence of breath sounds over the lower part of both chests. The abdomen was prominent and the liver edge was palpable three fingerbreadths below the costal margin. The spleen was not palpable Blood pressure on admission was 78 systolic and 60 diastolic. The Mantoux test was negative on second strength purified protein derivative and up through 1.0 mg. of old tuberculin Eagle and Kahn tests were negative. Serum protein was 7.1 mg. per cent, blood sugar 9[illegible] mg. per cent, blood cholesterol 138.9 mg. per cent, nonprotein nitrogen 28 mg per cent, and urine negative.

X ray of the chest on admission showed more bilateral pleural fluid on right side than on the left. The cardiac outline at the time was obscured but later studies after thoracentesis showed it not to be enlarged No calcification of the pericardium could be seen. Fluoroscopic studies showed very little cardiac pulsation. Venous pressure averaged around 30 cm. of water Electrocardiogram showed right axis deviation.

Between the time of admission, March 22, 1939, and July 29, 1942, at which time the first stage pericardiectomy was done, the right chest was tapped eight times and 3300 c.c. of fluid were removed; the left chest was tapped three times with 475 c.c. of fluid, and the abdomen five times with 30,075 c.c. of fluid removed. In addition to removal of fluid by aspiration the patient was given theophylline and

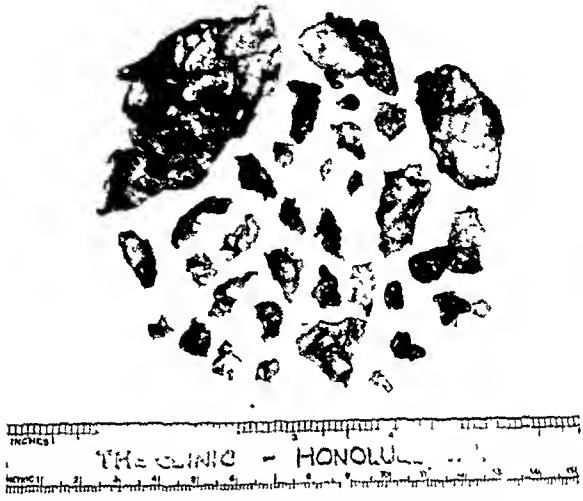

Fig. 8 (Case 1).—Portions of calcium removed at operation.



Fig. 9 (Case 1).—The incision.

salyrgan, 1 c.c. intravenously, about two or three times a week. She was also given enseals of ammonium chloride, 15 gr. daily. Response to these drugs was good as noted by the increase in urinary output but as was to be expected the effects were temporary.

Fig. 10 (Case 2).—Normal sized heart with bilateral pleural fluid. Hydropneumothorax on the right side

Fig. 11 (Case 2).—The patient and incision

Operation—The first stage was done July 29, 1942, under cyclopropane anesthesia The incision and exposure of the pericardium parallel that described in Case 1 The pericardium was greatly thickened and densely adherent to the heart, there being no line of cleavage in most places between the peri and epicardium (See Fig 4) Over the left ventricle a pocket containing 5 or 6 ounces of straw colored fluid was encountered lying between the peri and epicardium This gave a starting point for subsequent dissection The apex of the heart was found densely adherent to the central part of the diaphragm by a broad adhesion This was resected No calcium was encountered during the operation A considerable amount of thickened pericardium overlying the right and left ventricles was removed but not as much as was needed to free the myocardium adequately Operation was discontinued because it was felt that we were dealing with a poor operative risk and it seemed advisable to divide the operation into stages

Following the first operation there was some clinical improvement but this was not marked The patient seemed less cyanotic, the veins in the neck were perhaps less prominent The abdomen was tapped on Aug 26, 1942, and 4500 c c of fluid were removed

The second stage of the operation was done on Sept 9, 1942 The previous incision was opened, the second rib was resected and the third and fourth removed farther back to give better exposure The operation consisted largely of removing the thickened epicardium which had been left at the previous time This was carried out particularly over the right and left ventricles and to some extent in the region of the auricles The undecked muscle expanded significantly, giving much freer heart action in systole and diastole It was felt that a very definite and marked release of the heart from its tightly constricting envelope had been accomplished The pulse pressure during the operation increased from 20 to 40 mm of mercury

Postoperative Course—The patient made a good recovery On the fourth postoperative day the precordial area became prominent and 100 c c of bloody fluid were aspirated Following the second operation the patient made considerable clinical improvement but the results, in August, 1942, did not come up to expectations The right chest was aspirated on Nov 4, 1942, and 200 c c of fluid removed, and 75 c c again on March 20, 1943 The abdomen was aspirated three times on Oct 7, 1942, 3450 c c were removed, on Jan 16, 1943, 4200 c c, and on March 24, 1943, 3300 c c

The venous pressure remained elevated although the blood pressure returned to normal limits Whether the lack of more improvement was due to permanent fibrous changes in the organs outside the heart or whether the heart and great vessels needed further release from constriction is an open question It is probable that a third operative effort should be made by an approach to the right of the sternum unless more improvement takes place within a few months

SUMMARY

A review of the pathologic physiology, the diagnosis and surgical treatment of constrictive pericarditis, and a report of two cases treated surgically is presented.

In concluding this discussion of chronic constrictive pericarditis, we wish to emphasize the cardinal findings in this disease The heart is normal in size, or only moderately enlarged; it is in a fixed position, little or no evidence of pulsation can be elicited by physical or fluoroscopic examination; the peripheral veins are prominent, particularly the external jugulars; the venous pressure is high and the systolic blood pressure and pulse pressure are low. The liver is enlarged and generally

associated with abdominal ascites; there may be fluid in the pleural spaces, and edema of the lower extremities. The signs of passive congestion of the lungs are conspicuous by their absence.

It has not been our purpose in writing this article to attempt to present anything new, for this has not been done. Rather it has been our aim, as stated in the beginning, to help stimulate interest in this subject in faraway places where such conditions do exist and where such individuals cannot avail themselves of the diagnostic and surgical skill of the large medical centers.

REFERENCES

1. Heuer, G. J., and Stewart, H. J.: Surgical Treatment of Chronic Constrictive Pericarditis, Surg., Gynec. & Obst. 68: 979, 1939.
2. Blalock, A., and Burwell, C. S.: Chronic Pericardial Disease; Report of 28 Cases of Constrictive Pericarditis, Surg. Gynec. & Obst. 73: 433, 1941.
3. Harrison, M. B., and White, P. D.: Chronic Constrictive Pericarditis; Follow-up Study of 37 Cases, Ann. Int. Med. 17: 790, 1942.
4. White, P. D.: Chronic Constrictive Pericarditis (Pick's Disease) Treated by Pericardial Resection, Lancet 2: 539, 597, 1935.
5. Smith, H. L., and Willius, F. A.: Pericarditis; Chronic Adherent Pericarditis, Arch. Int. Med. 50: 171, 1932.
6. Rothstein, J. L.: Chronic Adhesive Pericarditis in Children and Its Surgical Treatment, Arch. Pediat. 51: 219, 1934.
7. Rigler, L. G., Wangensteen, O. H., and Friedell, H. L.: Roentgenkymograph in Constrictive Pericarditis, Am. J. Roentgenol. 46: 765, 1941.
8. Noth, P. H., and Barnes, A. R.: Electrocardiographic Changes Associated With Pericarditis, Arch. Int. Med. 65: 291, 1940.
9. Cole, W. H., Weber, R. D., and Keeton, R. W.: Pericardiectomy for Chronic Constrictive Pericarditis, Surg. Gynec. & Obst. 72: 1008, 1941.
10. Bigger, I. A.: Concretio cordis; cardiolysis for concretio cordis, Arch. Surg. 24: 574, 1932.

RECURRENT POSTOPERATIVE ATELECTASIS

Report of a Case

Howard T. Thompson, M.D., Rochester, N. Y.
(From the University of Rochester School of Medicine and Dentistry, Department of Surgery)

CASES of recurrent postoperative atelectasis have been reported by Scott and Joelson,[1] by Farris,[2] and by Apfelbach and Carter.[3] Their cases occurred at operations two and one-half, two and eight months apart, respectively. The first two occurred following abdominal operations and the last following a two stage Torek procedure. We wish to report this case of recurrent postoperative atelectasis occurring in a 57-year-old woman who underwent two breast operations in six days, both of which were followed by atelectasis on the right side.

Case Report.—Mrs. L. G., a 57 year old widow, was admitted to the surgical service of the Rochester Municipal and Strong Memorial Hospitals on Feb. 23, 1943, with the chief complaint of having had a lump in her left breast for one month. She complained of a burning type of pain in her breast and had lost about seventeen pounds in weight in the last few months. She had noted no enlargement of her breast or bleeding from the nipple. Past history was interesting in that she had had four operations in this hospital. In 1933 she had a gastrojejunostomy for duodenal ulcer under avertin and gas oxygen on April 4, on August 26, she had a right lobectomy of her thyroid for toxic nodular goiter under gas oxygen ether; and on November 19, had a dilatation and curettage, amputation of the cervix, and radical cure of cystocele and rectocele under ether. On Feb. 7, 1935, she had a dilatation and curettage for cervical stenosis under gas oxygen. All these procedures were well tolerated without postoperative sequelae.

At the time of these procedures she had had no cardiorespiratory symptoms. With the present admission she had a history of exertional dyspnea, swelling of her ankles, and two pillow orthopnea of one to two years' duration. She had not taken digitalis for five years which she started in 1935 because of symptoms of angina pectoris and evidence of mild decompensation.

General physical examination revealed a well developed and well nourished 57 year old white woman in no acute distress. The heart was enlarged to the right and left. There were no thrusts or thrills. Sounds were regular, of poor quality without murmurs. Pulses were equal without deficit. Lungs were clear to percussion and auscultation. Extremities showed slight pitting edema. Vessels showed moderate arteriosclerosis. In the outer upper quadrant of the left breast there was a rounded firm mass, freely movable, about the size of a cherry (2 by 2 cm.). There was no retraction of the skin. No axillary or supraclavicular glands were palpable. No masses were noted in the right breast. The abdomen was soft and no masses were felt. The liver edge was not palpable. Pelvic examination revealed a healthy amputated stump and a two degree retroversion of the uterus. Numerous telangiectasis were present over the body.

Received for publication Jun. 1, 1943.

X-ray examination of the chest revealed slight left ventricular hypertrophy, a tortuous aorta, clear costophrenic angles, and essentially normal lung fields. There was no evidence of metastasis. Laboratory findings: white blood cell count, 7,400; hemoglobin, 14.8 Gm.; urine, negative; Wassermann, negative.

On Feb. 24, 1943, the patient was taken to the operating room and biopsy of the nodule of the left breast carried out under gas-oxygen-ether anesthesia. Duration of the anesthesia was fifty minutes in all. Operating time was ten minutes. Preoperative medication was .010 morphine sulfate and .0003 atropine sulfate. Frozen sections were not definite and it was decided to close the wound and wait a few days for further study of the sections. The patient was sent to the recovery room where specially trained nurses are in charge of the patients until they respond and are returned to the divisions. The patient responded and was returned to her division. The nurse reported her condition satisfactory at 12:15 P.M. At 1:15 P.M. the patient showed diffuse cyanosis and failed to respond. Respirations were slow and shallow. Examination revealed the trachea to be shifted to the right. Breath sounds were depressed at the right base with some sticky inspiratory râles. Percussion of the chest revealed the mediastinum to be shifted to the right. Breath sounds were normal on the left. A diagnosis of acute atelectasis on the right was made. Preparations were made for immediate bronchoscopy. Oxygen was given because the interval before this was carried out with some decrease in her cyanosis.

Bronchoscopy was carried out using a No. 7 Israel scope and the bedside technique as advocated by Tucker, referred to by Lell.[5] Several large plugs of mucus were removed from the trachea and the right main bronchus. The mucosa appeared edematous. The patient's cyanosis disappeared almost immediately. Breath sounds were evident on the right side by auscultation and the trachea shifted back to the midline. The patient responded well and her only complaint was a slight sore throat. She was started on sulfadiazine by hypodermoclysis prophylactically. Her temperature that afternoon at 4 P.M. was 37.8° C. by mouth and from then on never rose above 37.5° C. Her convalescence from this experience was uneventful. At no time did she develop any cough or sputum.

Pathologic report was returned, papillary cystadenocarcinoma of the breast. Radical mastectomy was indicated and on March 1, 1943, the fifth postoperative day, this was carried out under gas-oxygen-ether. Operating time was two hours. Anesthesia time was two hours and thirty-five minutes. Preparation medication consisted of .016 morphine sulfate and .0003 atropine sulfate. Because of our previous experience with this patient, intratracheal anesthesia was used and suction of the trachea carried out for the final twenty minutes of the operation, the upper respiratory tract and trachea being cleaned of all mucus. Operation was completed at 11:10 A.M. She was sent to the recovery room. At 11:50 A.M. the patient became diffusely cyanotic and had depression of respirations to 8 per minute. Examination revealed essentially the same findings as followed the first operation. The trachea was shifted to the right. Breath sounds were depressed on the right side and there was mediastinal shift to the right. She was given intravenous coramine and bronchoscopy was carried out. This time the right middle and right lower lobe bronchi were found to be occluded by mucus plugs and these were sucked out. The mucosa appeared red and edematous but the trachea was clear. The patient responded immediately and her cyanosis disappeared. Breath sounds were well heard at the right base.

The patient was not started on prophylactic sulfonamide therapy this time. The day following her operation she had a temperature elevation to 38.2° C. There was some depression of breath sounds at the right base and a few sticky

inspiratory râles were present. A diagnosis of residual peripheral atelectasis was made. Sulfadiazine therapy was started. Temperature elevations continued for the next two days to 38.0° C., but she had no cough or expectoration. The remainder of her postoperative course was essentially uneventful. She was discharged home on the sixteenth postoperative day. No x-ray examination of the chest was done after the first acute atelectasis. Two days after her second atelectasis a roentgenogram revealed no evidence of a pneumonic or atelectasis process in the lung fields.

DISCUSSION

The possibilities of the cause of atelectasis in this patient who ten years before had undergone general anesthesia three times, and eight years before once, three of these being major procedures, are manifold. With her present operation this patient now a cardiac, Class III, and with evidence of mild failure might well fit into that class suggested by the vasomotor theory. This theory suggests the possibility of dilatation and stasis in the blood vessels producing obstruction by the outpouring of secretions. The importance of obstructing bronchial secretions was first stressed by Elliott and Dingley[10] and emphasized by Jackson and Lee.[11] The mucous membranes in this case were edematous and the patient at no time had retched or vomited. There were definite plugs which were occluding the bronchi and which were aspirated at the time of bronchoscopy. The patient had received .0003 Gm. of atropine preoperatively both times and the possibility of this drying up the secretions into tenacious mucus plugs must be considered. We believe that .0003 Gm. of atropine is the minimal amount a patient should receive preoperatively who is going to have a general inhalation anesthesia. This vasomotor theory is mentioned by Mousel,[4] who later states that he believes most postoperative atelectasis is caused by an actual plugging of the bronchus, tenacious mucus secretion which has collected in the tracheobronchial tree during anesthesia, by tenacious mucopurulent material present preoperatively, or by mucus, blood, or vomitus which has been aspirated into the bronchus either during or immediately following the anesthesia. We believe that this patient might well fit into the first group.

William Lell[5] mentions as one of his six modus operandi of postoperative atelectasis "the too frequent improper and often unnecessary use of intratracheal anesthesia." He believes that the presence of a large catheter in the glottis of the larynx prevents the vocal cords from approximating and secretions can thus be readily aspirated into the tracheobronchial tree. We did not use it in the first operation. In the second it was used in order that the tracheobronchial tree might be thoroughly aspirated postoperatively. While it might have been a contributing cause to atelectasis in the second operation, this experience does bring out an important point, namely, that even after twenty minutes of assiduous suction by a trained anesthetist, a catheter sue-

tion cannot be effective beyond the bifurcation of the trachea. This was confirmed at bronchoscopy when the trachea was found to be clear but there were two plugs occluding the right lower and middle lobe bronchus.

The suddenness with which these attacks of atelectasis occurred following operation is interesting. Zukschwerdt and Lezius[6] state that postoperative massive collapse of the lung never appears before the second or after the fifth postoperative day. These cases of proved postoperative massive collapse following within three and one-half hours and forty minutes, postoperatively, are contrary to this broad statement as well as cases reported by Gius,[7] and the extremes stated by Adams,[8] who says that it characteristically makes its appearance twenty-four to seventy-two hours following surgery, but may develop as late as seven to ten days postoperatively. These instances are believed to have occurred in the shortest time interval postoperatively yet reported.

Thomas and his co-workers[9] in a discussion on massive collapse of the lung as a complication of surgical procedures mentions as the first important point, postoperatively, the bandaging of the patient. Following the first operation the patient had only a local dry sterile dressing applied to the biopsy wound. There was no restriction to movement of the chest or abdomen by bandaging. After radical mastectomy a large compression bandage was applied to the chest to prevent fluid exudation into the dead space formed by removal of the breast. This did restrict motion of the chest, which in a female predominately a costal breather is an important factor. While a factor in the second instance it was not present in the first attack.

SUMMARY

1. A case of recurrent atelectasis is reported following biopsy of the left breast and five days later radical removal of the left breast.

2. Both instances occurred on the right side; the first involving the right lower lobe and the second the right lower and right middle lobe.

3. Mild cardiac failure seems to be the only condition present in both instances. Its connection with the vasomotor theory is discussed.

4. The time intervals between the operations and the occurrence we believe are the shortest ones yet reported postoperatively.

The operations were performed by Dr Robert Sewell, Resident in Surgery, at the Strong Memorial and Rochester Municipal Hospitals. Bronchoscopies were carried out by Dr. Keith Tarrer, Resident in Otorhinolaryngology, at the Strong Memorial and Rochester Municipal Hospitals

REFERENCES

1. Scott, W. J. M., and Jocelson, J. J.: Postoperative Massive Atelectasis, Arch. Surg. 15: 835, 1927.
2. Farris, H. A.: Atelectasis of the Lung, Canad. M. A. J. 15: 805, 1925.
3. Apfelbach, G. L., and Carter, J. B.: Recurrent Postoperative Atelectasis, Radiology 37: 598, 1941.

4. Mousel, L. H.: Bronchoscopic Treatment of Postoperative Atelectasis, Proc. Staff Meet., Mayo Clin. 15: 261, 1940.
5. Lell, W. A.: Bronchoscopy in the Treatment of Postoperative Pulmonary Atelectasis, Pennsylvania M. J. 44: 1551, 1941.
6. Zukschwerdt, L., and Lezius, A.: The Postoperative Massive Collapse of the Lung, Chirurg 10: 344, 1938.
7. Gius, J. A.: Paravertebral Procaine Block in the Treatment of Postoperative Atelectasis; Preliminary Report, SURGERY 8: 832, 1940.
8. Adams, W. C.: Postoperative Pulmonary Atelectasis, Am. J. Surg. 56: 180, 1942.
9. Thomas, C. P., Maxwell, J., and Rink, E. H.: Discussion on Massive Collapse of the Lung as a Complication of Surgical Operations, Proc. Roy. Soc. Med. 31: 1237, 1938.
10. Elliott, T. R., and Dingley, L. A.: Massive Collapse of the Lungs Following Abdominal Operations, Lancet 1: 1305, 1914.
11. Jackson, C., and Lee, W. E.: Acute Massive Collapse of the Lungs, Ann. Surg. 82: 364, 1925.

THE TREATMENT OF ABSCESS OF THE THYROID GLAND CAUSING TRACHEAL OBSTRUCTION

WILLIAM H. PRIOLEAU, M.D., F.A.C.S., CHARLESTON, S. C.
(From the Department of Surgery, Medical College of the State of South Carolina)

ABSCESS of the tyroid gland probably occurs more often than is indicated by the few cases reported in the literature. Tracheal obstruction is present in nearly all of the reported cases, an incidence higher than likely generally obtains. Abscess formation more commonly takes place in a diseased gland, particularly of the nodular type, the degenerated contents of a nodule being a favorable medium for bacterial growth. On the other hand, abscess may occur incident to an acute thyroiditis in a previously normal gland.[6] Infection commonly takes place by the blood stream, at times, but not necessarily as a result of a systemic infection. It may take place also by lymphatic channels in infections of the tonsils, larynx, or trachea.[4, 8] Except as just stated, the thyroid gland is seldom infected by lymphatics or by continuity from other cervical structures. The inflammatory process in the affected portion of the gland causes such rapid change in shape, increase in size, and tension as frequently to obstruct the trachea by pressure. A commonly associated inflammatory edema of the larynx and trachea may contribute to, or alone may cause obstruction to, respiration.[7] The systemic effect of the infection may be of any degree of severity depending upon the acuteness of the process, the type of the organism, and the physical characteristics of the abscess.

The course of events is generally rapid. The combination of respiratory obstruction and an acute infection makes a very ill patient. In the more fulminating cases a fatal outcome is prevented only by a timely diagnosis and proper treatment. The respiratory distress and the swelling in the neck are the commonly predominant findings. In anteriorly situated abscesses the overlying skin is warm and reddened. There is pain, induration, and fixation anteriorly and to one side of the trachea. In the more deeply situated abscesses there is little more than a sense of firmness on the affected side. Lehey calls attention to a limitation of the elevation of the chin, and a depression of the chin on swallowing.[4]

If the respiratory distress is not so great as to demand immediate operative relief, bed rest and sedation may result in such increase in breathing space as to make it possible to defer the operation for a few hours to a few days, thus leading to general improvement in the patient. During this period the infection tends to localize and to some ex-

Received for publication, June 5, 1943.

tent to subside, thus improving the operative risk. Proper sedation and supportive measures are used. Sulfonamide therapy would appear to be indicated but its use has not been reported. Morphia should be used sparingly and with care due to its depressant effect upon the respiratory center and its benumbing effect upon the consciousness resulting in a lessened respiratory effort. However much this waiting period may be desired, it is to be emphasized that a sustained respiratory effort of more than minimal degree is an absolute indication for a tracheotomy.[9] Failure to provide the patient with this means of relief will inevitably result in complete exhaustion, and only finally a rapidly developing cyanosis which is generally a sign of impending death.

Whether immediate or somewhat deferred, operation is indicated[1, 5, 6] for the relief of the respiratory obstruction, and drainage of the abscess to relieve the systemic infection and to prevent spread particularly into the mediastinum or perforation into the trachea.[2, 7]

The anesthesia of choice is the local infiltration of procaine. Inhalation anesthesia can not be administered safely or effectively through a narrowed and irritable air passage. Rectal or intravenous administration of the anesthetic agent is inadvisable because general anesthesia by any route deprives the patient of the conscious effort which is so important for obtaining adequate oxygenation in the presence of a narrowed airway. The use of an intratracheal catheter is to be avoided except with preliminary exposure of the trachea, since its introduction may be accompanied by such difficulty as to precipitate a complete obstruction to respiration. Also in such cases the trachea is particularly susceptible to damage as indicated by the report of cases in which it has been perforated by the abscess.[2, 3, 7] In these cases, cessation of respiration, whatever its cause, demands an immediate tracheotomy.[10] This must be performed under difficult conditions which add to the danger and decrease its effectiveness.

For operation the patient must be placed in a position which will afford him the greatest ease in breathing. This is generally an awkward position for the surgeon. The usual thyroid approach is made by a low collar incision with the formation of skin platysmal flaps. The prethyroid muscles, if not involved in the abscess wall, are divided in the midline and then transversely as indicated. Gentle manipulation and avoidance of pressure upon the trachea is of the utmost importance to avoid further obstruction to the respiration. The abscess is drained if it is readily accessible, otherwise the trachea is first exposed to permit a safe and quick tracheotomy, should it become necessary. Location and drainage of the abscess is then in order; excision of some of the infected glandular tissue is often advisable. This generally relieves the respiratory obstruction. However, as in one case reported here, tracheotomy may still be necessary on account of edema of the larynx. In all cases a portion of the trachea should be exposed in case a tracheotomy

should become necessary after operation. The wound is loosely closed with adequate provision made for drainage.

When abscess of the thyroid gland is treated in this manner, the result is generally a subsidence of the infection and a return to a normal thyroid balance.

CASE 1 (No. R 29563).—B. B., a single white woman, 73 years of age, was first seen, Nov. 8, 1938, at her residence where the rasping, stertorous breathing could be heard upon opening the front door. Her general health had been good until two weeks previously when she first noticed the sudden appearance of a swelling in her neck. Since then she had been conscious of pressure upon the trachea, and had had a coughing spell every morning. The coughing spells had increased in severity until on the morning of examination she was unable to breathe except with great difficulty. She was conscious and composed, but apprehensive. She was moderately exhausted but not cyanotic. The pulse rate was 120, its volume fair, and its rhythm somewhat irregular. There was a firm fixed swelling above the sternal notch and to the right. A diagnosis was made of nodular goiter which had undergone some internal change causing tracheal obstruction. The urgent need of a tracheotomy was recognized but rather than immediately attempt a difficult procedure under adverse conditions, she was given ¼ gr. of morphia and taken by ambulance directly to the operating room. Novocain was infiltrated locally. A low collar incision was made through the skin and platysma, and flaps were reflected. The prethyroid muscles were divided in the midline. An incision was then made through the overlying thyroid tissue to the trachea, which was displaced posteriorly and to the left, so as to be prepared for a hasty but safe tracheotomy. Mostly by digital manipulation, several large pieces of thyroid tissue were removed from the right side. The tissue was degenerated and suggested carcinoma. Thick pus exuded from several pockets. A limited examination of the partially exposed left lobe revealed some nodular enlargement. At this time breathing was much easier. Gauze was placed loosely in the cavity left by the removal of the thyroid tissue. The wound was partially closed, leaving adequate space for drainage. A culture of the pus was positive for a "pleomorphic gram negative bacillus nonpathogenic." The pathologic examination showed a nodular goiter with follicles of both the distended and hyperplastic types. There were areas of cystic degeneration, necrosis, and scarring. One large area of necrosis showed suppuration at the periphery.

Soon after the patient returned to the ward the obstruction to breathing increased. The patient could not be aroused and a slight facial asymmetry suggested a cerebrovascular accident. Tracheotomy was decided upon and was performed with ease, through the exposed portion of the trachea, two hours after the original operation. Rapid improvement followed. Twenty-four hours later the larynx was seen to be clear and the vocal cords to move well, so the tracheotomy tube was removed and a gauze strip placed against the tracheal opening. Five days later the patient left the hospital with the tracheotomy opening closed and the neck wound discharging seropurulent material. The convalescence was uneventful and recovery was rapid.

On examination, Aug. 17, 1939, the wound was nicely healed. There was no palpable thyroid tissue. She had gained weight and her appearance was that of a normal thyroid balance; the only symptom was a slight unproductive cough. Three years after operation she has had no further trouble, except for an occasional irritative cough.

CASE 2 (No. R 115034).—R. D., a Negro woman, 80 years of age, was first examined Feb. 1, 1941. Two weeks previously she first became conscious of a swelling

in her neck. Since then she had experienced increasing difficulty in breathing, and later in swallowing She was calm but having considerable difficulty in breathing There was a firm, fixed tumor to the left of the trachea engaging the superior strait. Her temperature was 99.6° F., pulse 110, and blood pressure 160/96 The vocal cords could not be seen due to displacement and edema of the larynx X ray examination showed a dense irregular shadow behind the upper portion of the sternum displacing the trachea considerably to the right and also enlarged peri bronchial lymph nodes. The white blood cell count was 9,100 with polymorphonu clears, 73 per cent A diagnosis was made of nodular goiter undergoing some change with resultant pressure upon the trachea Upon bed rest and mild sedation the breathing became much easier so operation was deferred to obtain improvement in the general condition of the patient

Operation was performed Feb 7, 1941 Under novocain infiltration a collar incision was made through the skin and platysma Flaps were reflected The prethyroid muscles were divided in the midline and then transversely on both sides Dissection was next carried down to the trachea, which was exposed with difficulty due to its displacement and the overlying gland The left lobe presented a firm mass which it was decided to remove The superior attachments to the larynx were severed and while attempting to free it from the trachea, to which it was densely adherent, a quantity of pus escaped The opening was enlarged and a thick walled cavity was encountered This was emptied and was found to occupy the lower two thirds of the left lobe which was resected almost completely Limited ex posure of the right lobe revealed only little enlargement Hemostasis and closure were effected with cotton A rubber tissue drain was placed to the left of the trachea The airway was adequate throughout the operation The convalescence was uneventful except for a purulent discharge from the wound. The patient was dis charged from the hospital seventeen days after operation

A culture of the pus from the abscess was positive for a nonhemolytic strep tococcus The pathologic report showed a cystic structure 7½ by 5 by 2 cm The inner lining consisted of suppurative inflammatory tissue, the wall was thick and fibrous An attached piece of thyroid gland was hyperplastic in places In some areas there was cystic distention of the acini

A few months after the operation and during the subsequent year there appeared suppurative tuberculous lymph nodes in the left posterolateral superior cervical region Excision was performed on three occasions Reexamination of the thyroid tissue removed at operation showed no evidence of tuberculosis On April 17, 1942, fourteen months after operation, there was no palpable thyroid gland She had gained weight and appeared to have a normal thyroid balance

COMMENT

The two cases reported are both in elderly women with only two weeks of known duration of tumor in the neck Respiratory obstruction in one necessitated immediate operation, in the other, operation could be deferred In neither case was there but mild systemic infection In both cases suppurative processes were found in glands previously diseased In both cases the result of treatment has been satisfactory

SUMMARY

1. Abscess of the thyroid gland is commonly productive of tracheal obstruction

2 Early recognition with treatment by operative drainage is indicated and generally results in a cure

3. Tracheotomy should be performed in case of sustained respiratory obstruction.

4. Two cases are reported.

REFERENCES

1. Joyce, T. M.: Thyroiditis, Frank Howard Lahey. Birthday Volume, Springfield, Ill., 1940, Charles C Thomas, Publisher, p. 289.
2. Thiesen, C. F.: (1) A Case of Suppurative Thyroiditis With Perforation of the Trachea. (2) An Unusual Infection of the Epiglottis and Larynx in a Child, Tracheotomy Recovery, Ann. Otol., Rhin. & Laryng. 23: 569, 1914.
3. Behrend, M.: Abscess and Gangrene of the Thyroid Gland, Surg., Gynec. & Obst. 39: 293, 1924.
4. Lahey, F. B.: Thyroid Abscess, Boston M & S. J. 176: 94, 1917.
5. Edwards, C. R.: Acute Infection of Thyroid, J. A. M. A. 76: 637, 1921.
6. Young, T. O.: Inflammatory Disease of the Thyroid Gland, Minnesota Med. 23: 105, 1940.
7. Nordland, M.: Thyroiditis, Minnesota Med. 20: 218, 1937.
8. Beilby, G. E.: Acute Thyroiditis, New York State J. Med. 19: 274, 1919.
9. Prioleau, W. H.: The Importance of Early Tracheotomy, Surg., Gynec. & Obst. 47: 726, 1928.
10. Idem: Tracheotomy; Technique and After-care of the Patient, Surg., Gynec. & Obst. 47: 848, 1928.

IMPRESSION TECHNIQUE FOR RECONSTRUCTION OF LARGE SKULL DEFECTS

E. S. Gurdjian, M.D., J. E. Webster, M.D., and
J. Chaignon Brown, D.D.S., Detroit, Mich.
(From the Department of Surgery, Wayne University College of Medicine, and Grace Hospital, Detroit)

THE need occasionally arises for reconstructing defects of the skull which are unusually large and asymmetrical. When an inanimate transplant is used, it may be prepared to fit the defect accurately prior to operative repair. In the following few paragraphs we wish to describe a method for repair of large skull defects with plexiglass (methylmethacrylate).

TECHNIQUE

It is advantageous to secure a model of the patient's entire skull. This is particularly true if the defect extends into the temporofronto-orbital region. The model must include this area completely. The model of the entire skull may be obtained as follows. The patient's head is shaved and the scalp is lubricated with vaseline. A metal rim is applied to the base of the skull to which is attached a cardboard similar to a hat rim and about as wide. Indelible pencil marks are used to outline the defect by marking the scalp along the border of the defect. With a brush, a first layer of snow-white impression plaster No. 1 is applied to the head. When this is partially set, a well-dampened piece of gauze or cheesecloth is placed over the entire area to serve as a binder for the plaster. The purpose of the first application of a thin layer of plaster is to be assured that the unsupported tissue of the defect is not displaced by the second and heavier layer of plaster. A second heavy layer of plaster may then be applied, and when this is set, the impression is removed and a negative of the skull and its defect are thus obtained.

A positive may then be prepared by pouring artificial dental stone into the negative impression. Usually there is sufficient vaseline in the negative to permit the removal of the positive with ease The positive should be placed on a suitable base in order to avoid injuries to its edges or to the defect border. The anatomic markings of the ear and ciliary arches should be present on the final mold. This master model is used instead of the patient for reconstructing the artificial graft with accuracy and convenience.

Particularly in large defects, templates may be used to obtain symmetrical building-up of the defect. A template in the horizontal and

Received for publication, June 28, 1943.

in the vertical position, cut out of cardboard and fitting the normal side, may then be placed on the side with the defect to note the extent of build-up necessary for bilateral symmetry.

The area of defect is then filled with artificial stone and the contour is corrected with the use of templates, adding plaster as needed to produce a symmetry corresponding to that of the normal side. The final build-up represents the contour which is desired when the skin overlies the graft.

The skull in the region of the build-up, in place, is lightly covered with vaseline. A negative impression of the area in defect with the build-up in place is then obtained with dental artificial stone or plaster. In order to compensate for the thickness of the skin, the inner surface of the negative may be reduced with Kerr's No. 28 gauge green soft wax in two thicknesses. In places where the skin is particularly thick, more thicknesses of wax may be used. From this corrected impression a positive model is prepared which represents the skull without overlying skin and which gives the desired contour for the graft. This positive may be made using dental stone. Plexiglass (methylmethacrylate) was used in this study. When plexiglass is used, an adequate amount is cut with a band saw. It is then gently heated with a dry flame from a Bunsen burner until it becomes soft and adaptable. The heated plexiglass is then adapted to the outer surface of the mold. In the process of the adaptation, the edges of the glass are beveled to produce an accurate fitting. Holes are drilled into the edges for the purpose of fixing the graft into position by means of appropriate suture material (steel wire). It is somewhat easier to make a negative of the mold and then adapt the warm plastic to its surface. In fact, the graft may be placed between the positive and the negative and be fixed into position.

CASE REPORT.—G. O., aged 21 years, was operated upon Aug. 3, 1939, at the Grace Hospital, for a large malignant meningioma growing in the left frontal lobe. The marked edema necessitated the sacrificing of the bone flap. Convalescence was satisfactory but the vision, which had been very poor before operation did not improve appreciably. The patient was given deep x-ray therapy in the left frontal lobe neighborhood. On Feb. 5, 1941, she was re operated upon because of recurrent headaches and two generalized epileptic spells. At the second operation only a cherry-sized tumor was seen growing from the dura near the midline. The pathologic report was endothelio-sarcoma of the dura. The brain in the frontal region appeared necrotic, pale white, and contained many small holes (cheeselike). Postoperatively, the patient had almost daily generalized and jacksonian spells, which were eventually controlled with phenobarbital and dilantin. Within a month the spells subsided and she had only one generalized attack until March 19, 1942, when the skull defect was repaired. Because of the disfiguring defect of the skull and dizziness on stooping, it was thought advisable to repair the skull defect with plexiglass. The proposed transplant was prepared prior to the operation in a manner described previously (Figs. 1 and 2). Figs. 3 to 7 show the patient before and after repair. The transplant was sterilized by immersion in 95 per cent alcohol for twenty four hours. It was washed in distilled water before use. The transplant fitted

the defect perfectly and no correction was necessary at the time of the operation. It was held in place by wire sutures. Small holes were made with the hand drill in the skull and in the transplant for suture. The subcutaneous tissue and the skin were sutured over the transplant with interrupted silk with no drainage. Within twenty-four hours there was a collection of serum under the skin. This was thin, brownish in color, and drained easily with a No. 18 needle inserted subcutaneously. A smaller

Fig. 1.—To the left is shown a model of the skull with its defect to be repaired. To the right is shown a positive and negative of the area of defect after build-up. The plexiglass graft is held in the right hand.

Fig. 2.—To the left is shown the plaster model of the skull with the defect eliminated by the use of the plexiglass graft. To the right is shown the positive and negative of the area of defect after build-up.

Fig. 3.—Appearance of patient prior to repair of postoperative skull defect after removal of a large frontal meningioma.

Figs. 4 and 5.—The appearance of patient following repair of the skull defect with plexiglass graft. Figs. 1 and 2 illustrate the same case.

collection was drained the following day. Thereafter there was no collection of fluid and the wound healed by primary intention. During the ensuing ten days, the patient had many minor generalized convulsions in much the same manner as after the second operation. These were controlled with sedatives. In the following thirteen months there was no recurrence of these attacks and during the following fifteen months there were no reactive changes due to the transplant. Further dizziness from bending down ceased to be a complaint.

Figs. 6 and 7.—Anteroposterior and lateral view of patient one year after repair.

DISCUSSION

The subject of repair of skull defects has been studied and the literature reviewed with great care by Grant and Norcross.[1] Several articles have appeared in the literature, since 1938, on the use of inanimate transplants for large defects of the skull. The contributions of Geib,[2] Lipscomb and Grover,[3] Beck,[4] Venable and Stuck,[5] and Pudenz[6] discuss the problem from the standpoint of the use of vitallium and tantalum. It is suggested that the fitting of the transplant to the patient's defect be done at the time of the operation, which we consider to be a disadvantage, particularly if the defect is asymmetrical and possesses many and varied changes in symmetry. In such instances, the preoperative preparation of the transplant, be it tantalum, vitallium, or plastic, is preferable. Only a very small amount of readjusting should be necessary at the time of the operative repair of the defect. In the case of the plastic that has been used in this study, such fitting can be done easily by exposing the transplant to dry heat on the Bunsen burner immediately next door to the operating room or in the operating room, if local anesthesia is used.

Plexiglass (methylmethacrylate) has been used for the construction of femoral head[7] with apparently good results Cameron[8] also has used the material for skull defects and considers it superior to metallic transplants because the plastic transplant is transparent to x-ray and also because it is sturdy and retains its shape.

The purpose of the present communication is not so much to discuss the merits or the disadvantages of plexiglass as a transplant material but more to bring out the described impression technique for the preoperative preparation of the transplant. It seems to us that this is a great advantage in extensive defects in the skull in the frontotemporoorbital region.

The management of smaller defects of the skull by osteoperiosteal transplant from the patient's skull or with rib transplant is generally accepted of proved value. This subject was discussed in a previous article in 1935.[9] We have had the opportunity to use osteoperiosteal transplant from the outer layer of the skull on many subsequent instances with excellent results.

CONCLUSIONS

An impression technique for the building of inanimate transplant for large skull defects is described. In this case methylmethacrylate (plexiglass) was used and at the end of fifteen months was still in excellent repair with no evidence of deleterious reactions to the patient.

REFERENCES

1. Grant, Francis C., and Norcross, Nathan C.: Repair of Cranial Defects by Cranioplasty, Ann. Surg. 110: 488-512, 1939.
2. Geib, F. W.: Vitallium Skull Plates, J. A. M. A. 117: 8-12, 1941.
3. Lipscomb, William R., and Grover, Charles G.: Cast Metal Plate for Closing Defect in Skull From Comminuted Fracture, The Dental Digest, April, 1941.
4. Beck, C. S.: Repair of Defects in Skull by Ready Made Vitallium Plates, J. A. M. A. 118: 798-799, 1942
5. Venable, Charles S., and Stuck, Walter G.: A General Consideration of Metals for Buried Appliances in Surgery, Surg., Gynec. & Obst. 76: 297-304, 1943.
6. Pudenz, R. H.: The Repair of Cranial Defects With Tantalum, J. A. M. A. 121: 478-481, 1943.
7. Harmon, Paul H.: Methacrylate Resins in Surgery, Modern Plastics 20: 56, 1942.
8. Cameron, J. M.: Personal communication.
9. Gurdjian, E. S.: Management of Depressed Fractures of the Skull and Old Skull Defects, Ann. Surg. 102: 89-101, 1935.

CONGENITAL ATRESIA OF THE ESOPHAGUS

The Description of an Operative Procedure

Edgar J. Poth, Ph.D., M.D., Galveston, Texas
(From the Departments of Surgery, Johns Hopkins University School of Medicine, and The University of Texas Medical Branch)

CONGENITAL atresia of the esophagus occurs sufficiently infrequently that few physicians see many of these anomalies. The surgical treatment of this condition has been most unsatisfactory, but it appears now that the solution of this problem is not far distant. It seems desirable, therefore, that any possible attack on this problem be reported so that the technique may be incorporated into whatever procedure may soon prove itself.

Some 330 cases have been reported and are included in recent reviews of this subject.[1-4] A simple, practical, clinical classification of these anomalies was published in 1929 by Vogt.[5] His classification is presented schematically in Fig. 1. Because of its more frequent occurrence, Type III*B* is of greatest surgical importance.

DIAGNOSIS

The diagnosis of esophageal atresia can be made during the first few hours of life by the recurring attacks of coughing, choking, and cyanosis which are aggravated when fluid is given by mouth. Also, there will be an excessive amount of frothy spittle coming from the infant's mouth. The suspicion of the presence of an esophageal anomaly is confirmed by x-ray study. In all types of esophageal atresia, except Type I, a catheter can be introduced into the proximal segment, and the length of the segment demonstrated by x-ray by the distance to which the catheter can be inserted. Radiographically opaque fluid media should not be used. They contribute nothing to the diagnosis with the possible exception of instances of Type III*A*, and may cause damage by their aspiration into the bronchioles and periphery of a lung already involved by a varying degree of inflammation. The absence of gas in the gastrointestinal tract will eliminate the presence of Type III*B* or III*C*. The extent of pneumonitis and pneumonia preoperatively should be evaluated as a guide to prognosis. Satisfactory treatment is largely dependent upon early diagnosis before an aspiration pneumonia has occurred, but sufficient time can be taken for the proper hydration of the patient. Both whole blood and plasma may be given by intramedullary transfusion.

Received for publication, June 30, 1943.

TREATMENT

Various workers have attacked the important problem of eliminating regurgitation from the stomach with its consequent flooding of the pulmonary tree. The procedures to accomplish this result were reviewed by Carter,[6] in 1941.

In 1936, Leven,[7] exteriorized the cardiac ends of the esophagus and stomach, intending that the resulting angulation would prevent regurgitation. In the same year, Gage and Ochsner[4] proposed the ligation of the cardiac end of the esophagus. In the discussion of this report, Mixter reported having ligated and divided the fistulous communication through a right-sided extrapleural approach, the distal esophagus being brought out dorsally and a tube introduced for the purpose of feeding. Likewise, in 1936, Heatly[5] attempted to eliminate regurgitation by closing the cardiac end of the stomach and performing an abdominal esophagostomy to drain the distal segment of the esophagus of two patients. One of the patients lived for 145 days.

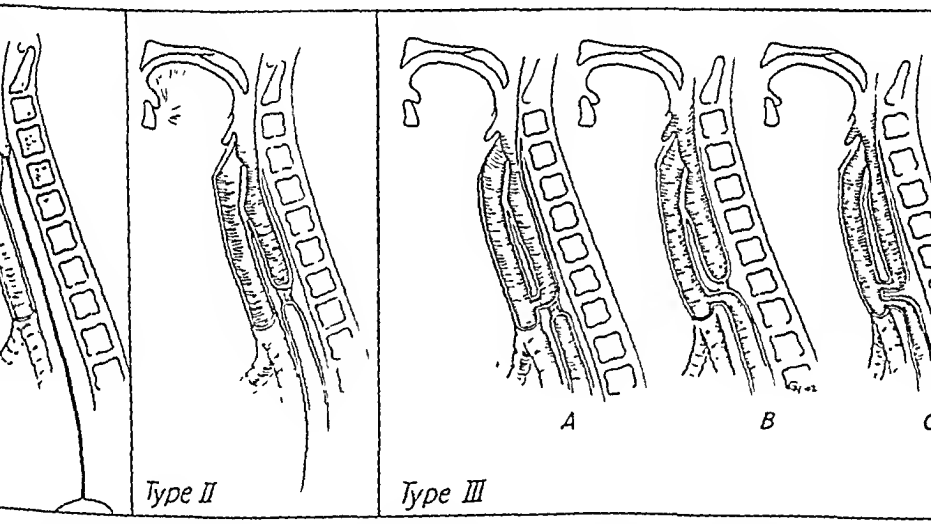

Fig. 1.—A schematic representation of the usual clinically significant types of esophageal anomalies. *Type I*, Congenital absence of esophagus (rare). *Type II*, Blind upper and lower segments of esophagus (rare). *Type III*, Tracheo-esophageal fistulas: *A*, Upper segment of esophagus communicating with the trachea; lower segment blind (rare). *B*, Upper segment of esophagus blind, lower segment communicating with the trachea (occurring most frequently). *C*, Both upper and lower segments of the esophagus communicating with trachea (rare). (Modified from Cole, W. H.: Arch. Surg. 23: 820, 1931.)

I agree with Lanman,[4] Leven,[7] and many others interested in this problem, that the first step of the operation on tracheo-esophageal fistulas of Type III*B* and III*C* is a direct attack on the fistula, and if an immediate anastomosis cannot be effected between the upper and lower segments of the esophagus, the Types III*B* and III*C* are converted into Types II or III*A*. The all-important consideration is that the esophagus be disconnected from the trachea to prevent regurgitation of stomach

contents into the trachea. Within the next three days a Witzel gastrostomy should be performed in order that the infant can be fed. After these manipulations the proximal esophageal segment must be brought out to form a cervical fistula. Should the patient be free of other congenital anomalies and survive the three preceding operations, one is faced with extensive plastic operations to construct an extrathoracic tube connecting the upper esophageal segment with the stomach.[6, 9, 10]

Because of the relative frequency of Type IIIB, its treatment is more important than all of the other forms combined. Obviously, a direct attack on the fistula with an immediate anastomosis of the upper and lower segments of the esophagus is desirable and should give the best results once a technique will ensure success.* Ordinarily, an anastomosis can be done without extensive freeing of either the proximal or distal segments of the esophagus if the segments are not separated by more than 2 cm. It should be noted, however, that the distal segment of the esophagus together with surrounding connective tissue can be liberated even to the freeing of the cardiac portion of stomach and esophagus at the diaphragm. Such a procedure would permit the cardia to be brought up above the diaphragm with a resulting relaxation which would permit a direct end-to-end esophageal anastomosis where the gap between the upper and lower segments exceeds 2 cm. In this instance a transpleural approach is required for sufficient exposure.

The following procedure is outlined because it gives promise of eventual success. After the insertion of a No. 14 French soft rubber catheter into the upper segment of the esophagus, the patient is placed in the prone position with the right arm extended over the head. Because of the danger of inadvertently opening the pleura with collapse of the lung, provision must be made to administer the anesthetic under pressure. During prevoius fluoroscopic examination a paper clip is fixed over the right fifth rib posteriorly under a strip of adhesive. When the skin is prepared, the metal clip is removed, and its impression on the skin marks the level of the fifth rib accurately. The incision begins at the level of the second rib, extends downward just to the right of the midline to the level of the fifth rib to turn laterally along the lower border of the scapula, and is carried outward to the posterior axillary line. Two inches of the fourth rib are excised subperiosteally extending outward from the transverse process. The third and fifth, and occasionally the second and sixth, ribs are transected

*Since the preparation of this manuscript, an excellent article by Haight and Towsley[13] announced the first successful cure of tracheo-esophageal fistula by immediate anastomosis of the esophagus. In this instance, true primary healing did not occur. An esophageal fistula developed to persist for a short period. More recently, A. O. Singleton has successfully performed an immediate anastomosis over a catheter with primary healing. I am advised by Owen H. Wangensteen (June 8, 1943) that N. Logan Leven has successfully treated four cases of congenital tracheo-esophageal fistula.

close to the transverse processes. The pleura is exposed by a T-shaped incision extending outward just superior to the fourth rib and including the section of the third, fourth, and fifth intercostal muscle bundles, nerves, and blood vessels as near the transverse processes as possible.

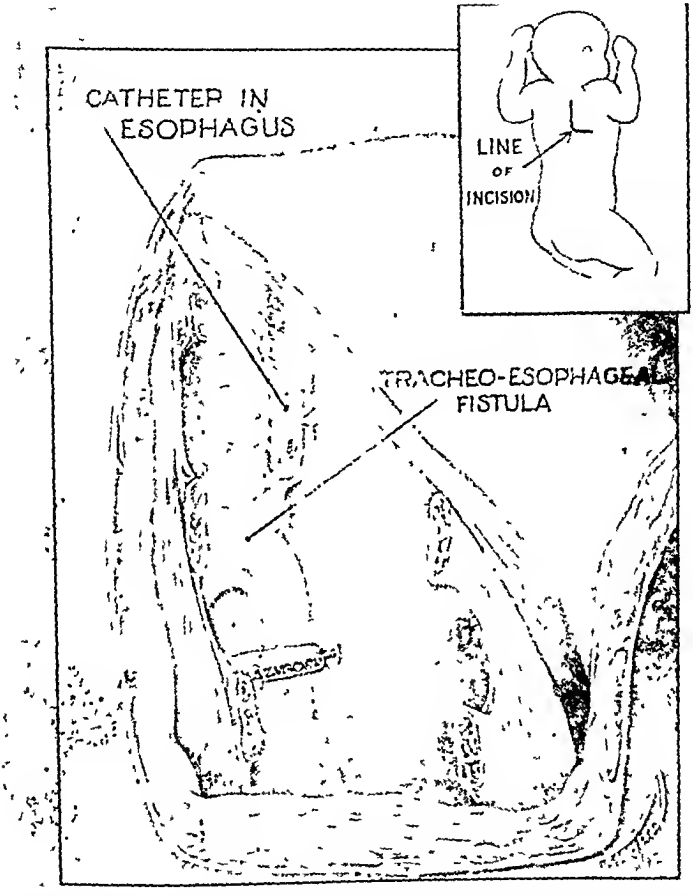

FIG. 2.—Illustrating the catheter showing through the wall of the upper segment of esophagus and the lower segment of the esophagus in a case suitable for immediate anastomosis of the two segments over a catheter. The presence of the catheter aids in the identification of the upper segment. The azygos vein has been divided.

The operator enters the mediastinum by staying close to the vertebral column and carefully pushing aside the pleura. The horizontal portion of the azygos vein where it crosses above the bifurcation of the trachea to join the superior vena cava, is the first prominent structure encountered. This vessel should be divided to give a direct approach to the esophagus at a level just superior to the carina. Careful dissection of the immediate areolar tissue will uncover the esophagus. If at this point the anesthetist will push on the catheter, its tip is readily identified provided the upper segment is sufficiently long to

allow anastomosis between the two segments of esophagus. The presence of the catheter likewise shows the anteroposterior level of the esophagus and gives an excellent guide to its lower segment. A small electric bulb on a flexible carrier, passed into the catheter, is an additional aid in locating the tip of the catheter even though the upper

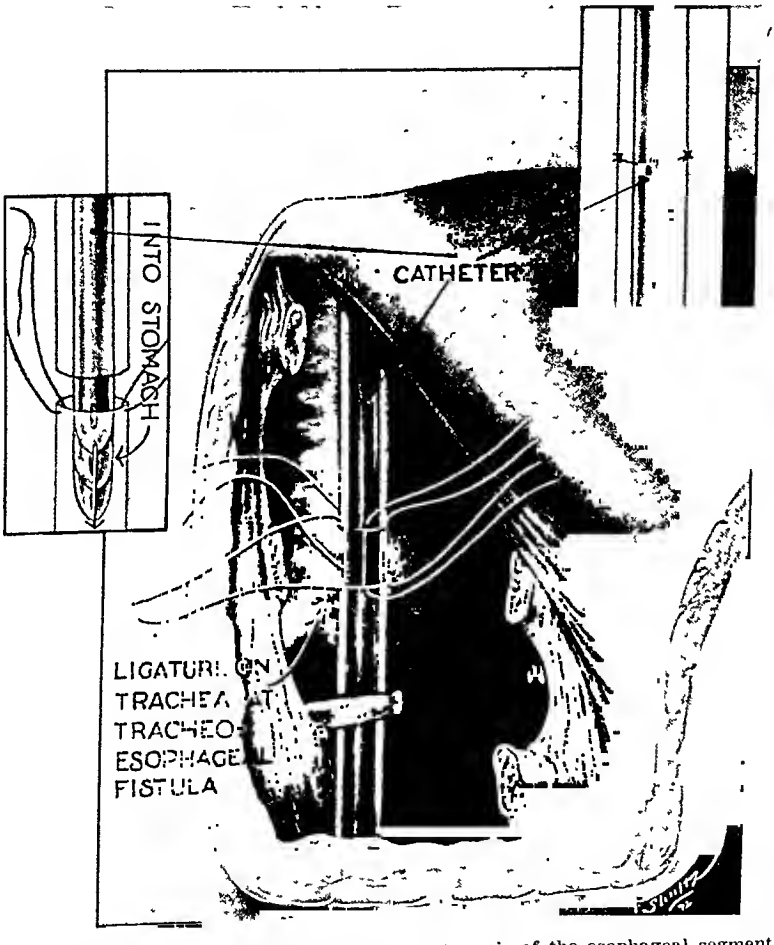

Fig. 3.—A demonstration of the immediate anastomosis of the esophageal segments over an indwelling catheter. The catheter has been introduced into the stomach. The diameter of the catheter should be considerably smaller than that of the esophagus to permit drainage of secretions.

segment is too high to permit direct anastomosis of the segment. The upper and lower segments of the esophagus cannot be anastomosed if the ends are separated by more than 2 cm. without extensive freeing of the distal segment. The tracheo-esophageal fistula is identified, isolated, and ligated adjacent to the trachea. If an immediate anastomosis is possible, the distal segment of the esophagus is divided, as near the tracheo-esophageal fistula as possible. If, however, an anas-

tomosis is impossible, the esophagus is doubly ligated and divided between the ligatures, and the first stage operation is complete.

For immediate anastomosis, minimum lengths of the upper and lower segments of the esophagus are freed. The end of the upper segment is fixed with a traction suture and opened, the catheter is directed into the lower segment and pushed down to enter the stomach, and the esophagus is anastomosed over the catheter, using four simple interrupted sutures.

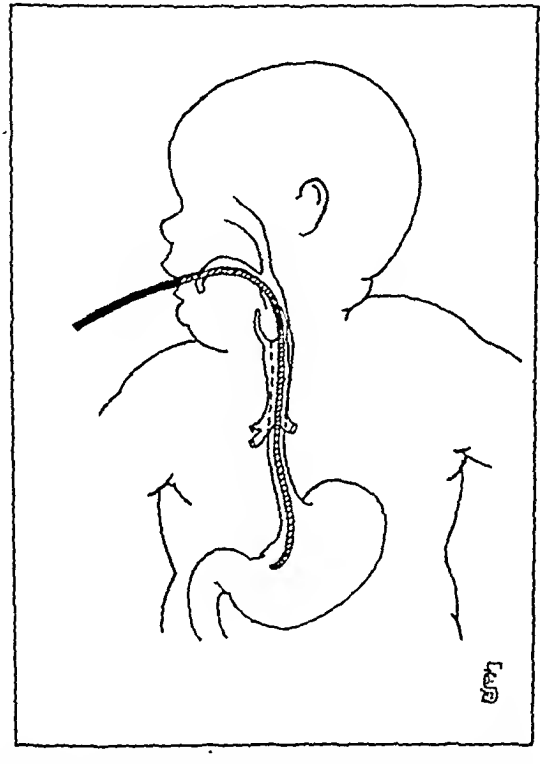

Fig. 1.—A schematic demonstration of the catheter in place permitting feeding during the immediate postoperative period.

After it has been determined that the pleura has not been accidentally damaged and that air has not entered the pleural space, the wound is lightly powdered with sterile sulfanilamide and closed. A simple rubber tissue drain extends into the depths of the wound.

With a tube in the stomach, the infant can be fed immediately and should be given its formula in small amounts each hour. The tube is left open between feedings. The patient is turned frequently and the head is kept lowered and turned to one side. Sulfadiazine should be given before operation and this therapy should be continued postoperatively as a safeguard against pneumonia.

CASE REPORT

M. J., an 11-day-old female infant, was admitted to the Johns Hopkins Hospital on Feb. 26, 1942, with a typical story of esophageal atresia. For eleven days the infant had been fed at regular intervals with disregard of the attacks of coughing and cyanosis with regurgitation of fluids taken by mouth. An x-ray examination with a catheter in the esophagus showed an obstruction opposite the level of the fourth rib and gas in the gastrointestinal tract. The lung fields showed x-ray evidence of extensive pneumonic consolidation. The patient was extremely dehydrated and cyanotic. Because of her poor condition she was given intravenous and subcutaneous fluids and sulfadiazine for 36 hours before operation was undertaken.

Operation was performed through a posterior, extrapleural approach; about two inches of the fourth and fifth ribs were resected, and the third and sixth ribs were cut near the transverse processes. The exposure was adequate. The catheter in the upper segment served as an excellent guide to both upper and lower segments of the esophagus. The tracheo-esophageal fistula, located just above the bifurcation of the trachea, was isolated, ligated, and divided. About 1 cm. of each esophageal segment was freed, the upper segment transfixed with a traction suture and opened, the indwelling catheter passed down the lower esophageal segment into the stomach, and the esophagus anastomosed over the catheter, four simple interrupted silk sutures being used. About ½ Gm. of sterile sulfanilamide powder was sprinkled into the depths of the wound, the mediastinum was drained with a small piece of rubber tissue, and the wound closed with fine silk. The position of the catheter in the stomach was checked by fluoroscopy.

Twelve hours after operation the feeding formula was started by means of the indwelling tube in small amounts each hour. All fluids and medications were administered through the catheter and were well tolerated.

The infant, although kept in an oxygen tent, continued to be cyanotic and died on the fifth post-operative day. The heart continued to beat for some time after respiration ceased. At autopsy it was found that a pleural effusion had partially collapsed the right lung. The left lower lung was involved in a grayish consolidation. The operative field was clean and dry. The esophageal anastomosis was intact, the esophagus appeared normal with a good blood supply, and the anastomosing sutures showed no evidence of tension. The ductus arteriosus was open and about 2 mm. across, and the pericardial cavity contained about 50 c.c. of straw colored fluid.

DISCUSSION

During the past year I have treated four patients with congenital atresia of the esophagus with tracheo-esophageal fistula, all of Type III*B*, Fig. 1. One of these patients had, in addition, an atresia of the rectum. One instance was the case herein reported, in which it was possible to perform a primary anastomosis over a tube.

In this operative procedure a successful anastomosis over a catheter would restore the patient to an essentially normal condition by a single operation. The catheter extending into the stomach would permit immediate feeding, which should contribute much to a successful outcome.

It must be recognized that a tube in the stomach of an infant induces a pylorospasm and tends to induce regurgitation. It is, therefore, best not to perform a Witzel gastrostomy in any case before the tracheo-

esophageal fistula has been closed. In the event a gastrostomy is subsequently necessary, the tube should extend beyond the pylorus. A few days after the closure of the fistula and establishment of continuity of the esophagus, a gastrostomy may be indicated because it will permit the distal end of the indwelling catheter in the esophagus to be brought to the outside. A braided silk thread can be tied into the proximal end of the catheter, the catheter drawn distally so that its proximal opening lies in the esophagus superior to the anastomosis to drain saliva and mucus, and the catheter eventually withdrawn distally to leave a silk thread in the esophagus to facilitate subsequent dilatation of the stricture which will probably occur at the site of the anastomosis.

Leven,[7] Peyton,[11] and Wangensteen[12] found that infants do not tolerate well an indwelling catheter whether it be brought out of the mouth or introduced as a nasal tube. The presence of the tube predisposes to otitis media. Sulfonamide therapy during this period might well prevent the development of an otitis media, and the combined use of an indwelling catheter and sulfonamide therapy is worthy of a trial in a condition demanding heroic procedure.

A review of past attempts to correct esophageal atresia indicates that if the upper and lower segments of the esophagus cannot be joined by direct anastomosis, the first procedure on a patient with a tracheo-esophageal fistula of Types III-*B* and III*C* should be a direct attack to sever the connection between the distal esophagus and the trachea and thereby prevent regurgitation and flooding of the lungs with secretions from the stomach. In the presence of esophageal atresia with a tracheo-esophageal fistula, aspiration may occur from the accumulation of saliva and fluids given by mouth or from the regurgitation of stomach contents. Of these possibilities, that of regurgitation seems the most serious and consequently the patient's head should not be placed dependent before the fistulous opening is closed. After the abnormal communication has been closed, then the head can and should be dependent to permit better drainage of saliva and mucus. The accumulated mucus should be aspirated frequently. Congenital esophageal atresia should be considered a condition demanding immediate surgical treatment.

Final success in the correction of this anomaly will largely depend upon early diagnosis and operation before pneumonic aspiration and infection have occurred. The obstetrician and pediatrician can do much in this solution by early definitive diagnosis without introducing fluid radiopaque media into the upper esophageal segment to be possibly aspirated subsequently.

SUMMARY

A possible operative attack on congenital tracheoesophageal fistula is outlined.

REFERENCES

1. von Brun, P.: Neue deutsche Chirurgie, vol. 34, Chirurgie der Speiseröhre, by Hacker, V. and Lotheissen, G., Stuttgart, 1926, p. 192.
2. Rosenthal, A. R.: Congenital Atresia of the Esophagus With Tracheo-Esophageal Fistula, Arch. Path. 12: 756, 1931.
3. Gage, M., and Ochsner, A.: The Treatment of Congenital Tracheo-Esophageal Fistula in the New Born, Ann. Surg. 103: 725, 1936.
4. Lanman, T. H.: Congenital Atresia of the Esophagus, Arch. Surg. 41: 1060, 1940.
5. Vogt, E. C.: Congenital Esophageal Atresia, Am. J. Roentgenol. 22: 463, 1929.
6. Carter, B. N.: An Operation for the Cure of Congenital Atresia of the Esophagus, Surg., Gynec. & Obst. 73: 485, 1941.
7. Leven, N. L.: Surgical Management of Congenital Atresia of the Esophagus With Tracheo-Esophageal Fistula, SURGERY 6: 30, 1936.
8. Heatly, C. A.: Some Problems in Esophageal Atresia, Ann. Otol., Rhin. & Laryng. 45: 1122, 1936.
9. Leven, N. L.: Congenital Atresia of the Esophagus With Tracheo-Esophageal Fistula, J. Thoracic Surg. 10: 648, 1941.
10. Davis, J. S., and Stafford, E. S.: Successful Construction of an Entrathoracic Esophagus, Bull. Johns Hopkins Hosp. 61: 191, 1942.
11. Peyton, W. T.: Developmental Topography of the Nasal Cavity. Unpublished data in a Ph.D. thesis quoted by O. H. Wangensteen. Intestinal Obstructions, Baltimore, 1942, Charles C Thomas, p. 178.
12. Wangensteen, O. H.: Discussion of Paper by Thomas G. Orr, Tr. West. S. A., 179, 1934.
13. Haight, C., and Towsley, H. A.: Congenital Atresia of the Esophagus With Tracheo-Esophageal Fistula, Surg., Gynec. & Obst. 76: 672, 1943.

EXPERIMENTAL STUDIES ON ALIMENTARY AZOTEMIA

IV. Role of the Liver and Kidneys

Henry N. Harkins, M.D., Ph.D., Donald H. Hooker,* M.D.,
Robert T. Boals,* M.S., M.D., Brock E. Brush, M.S., M.D., and
C. Frank Chunn,* M.S., M.D., Detroit, Mich.
(From the Division of General Surgery, Henry Ford Hospital, Detroit)

IN THE three previous papers[1, 2 and 3] of this series, the following facts were demonstrated: (1) The increase in blood urea nitrogen associated with the presence of blood in the intestinal tract is in large part due to the absorption of the blood. (2) The protein in the blood, and especially that in the red cell fraction, more or less quantitatively accounts for the degree of the azotemia. (3) Azotemia results to a much greater degree when the blood is in the upper than in the lower intestinal tract.

The present study of this syndrome considers the amount of azotemia which occurs in experimental animals with impaired hepatic circulation following the ingestion of blood. For this purpose four sets of experimental preparations were used. In all instances, dogs were utilized. The four preparations included: (1) animals with an Eck fistula (portal vein ligated and the portal circulation shunted into the inferior vena cava), (2) animals with a reverse Eck fistula (inferior vena cava ligated and its blood shunted into the portal vein so that all blood from the lower half of the body goes through the liver), (3) animals with both the portal vein and inferior vena cava ligated (thus representing the condition after the second stage of a three-stage hepatectomy, a reverse Eck fistula being made at the first stage and several weeks later the portal vein being ligated), and (4) animals after total hepatectomy.

ANIMALS WITH ECK FISTULA

The blood urea nitrogen levels were observed following the administration of whole blood or red blood cells by stomach tube in standard doses as described in the previous articles in this series. In five such experiments, there was practically no elevation in blood urea nitrogen, typical results being shown in Figs. 1, 2, and 3.

*Now on active duty with the Armed Forces of the United States.

Received for publication, July 26, 1943

ANIMALS WITH REVERSE ECK FISTULA

Similar doses of whole blood or of red blood cells were given to eight dogs with reverse Eck fistulas. In all instances a definite rise in blood

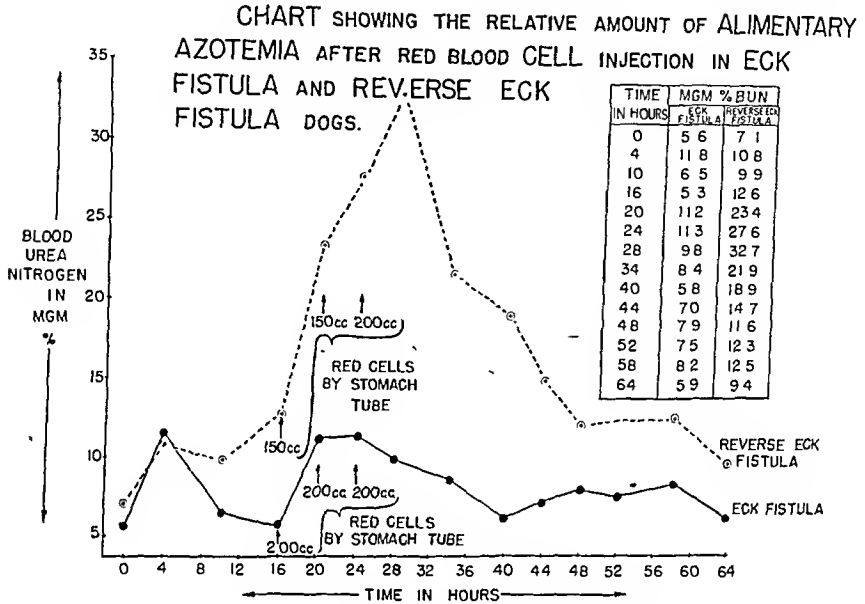

TIME IN HOURS	MGM % BUN ECK FISTULA	MGM % BUN REVERSED FISTULA
0	5 6	7 1
4	11 8	10 8
10	6 5	9 9
16	5 3	12 6
20	11 2	23 4
24	11 3	27 6
28	9 8	32 7
34	8 4	21 9
40	5 8	18 9
44	7 0	14 7
48	7 9	11 6
52	7 5	12 3
58	8 2	12 5
64	5 9	9 4

Fig. 1.—Alimentary azotemia in a dog with Eck fistula (below) and with reverse Eck fistula (above).

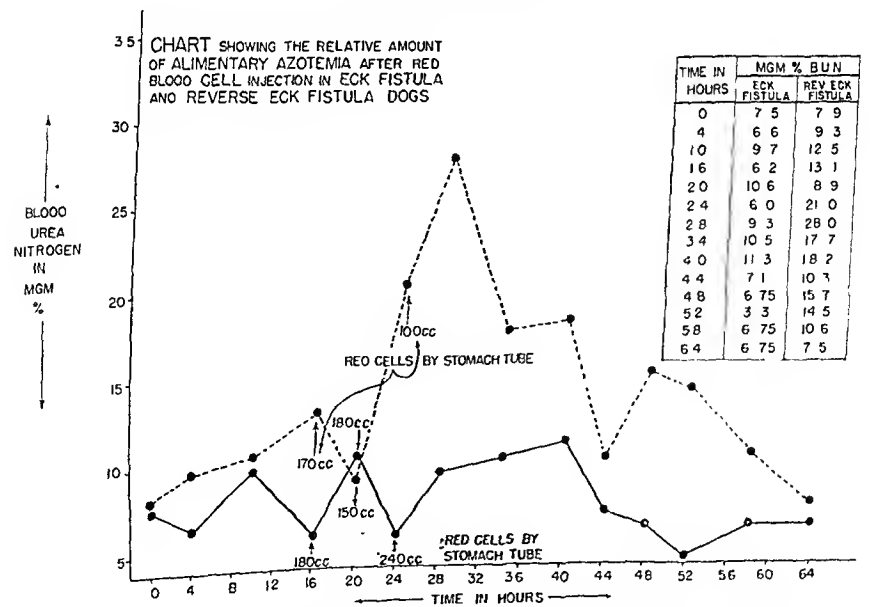

TIME IN HOURS	MGM % BUN ECK FISTULA	MGM % BUN REV ECK FISTULA
0	7 5	7 9
4	6 6	9 3
10	9 7	12 5
16	6 2	13 1
20	10 6	8 9
24	6 0	21 0
28	9 3	28 0
34	10 5	17 7
40	11 3	18 2
44	7 1	10 3
48	6 75	15 7
52	3 3	14 5
58	6 75	10 6
64	6 75	7 5

Fig. 2.—Same as Fig. 1. The solid line below represents the dog with the Eck fistula and the broken line above represents the dog with the reverse Eck fistula.

urea nitrogen resulted as shown in three typical experiments in Figs. 1, 2, and 3. In one other experiment not shown in the figures, the blood urea nitrogen rose from 11 to 46 mg. per cent. In four of the dogs with reverse Eck fistulas, the rise was classified as moderate (see Figs. 2 and 3), and in the four others it was classified as marked (see Fig. 1). In all cases the increase was much greater than that occurring in the animals with Eck fistulas. Also, in every instance it was as marked as that occurring in normal dogs and, in several cases, was definitely more than would be expected in normal dogs.

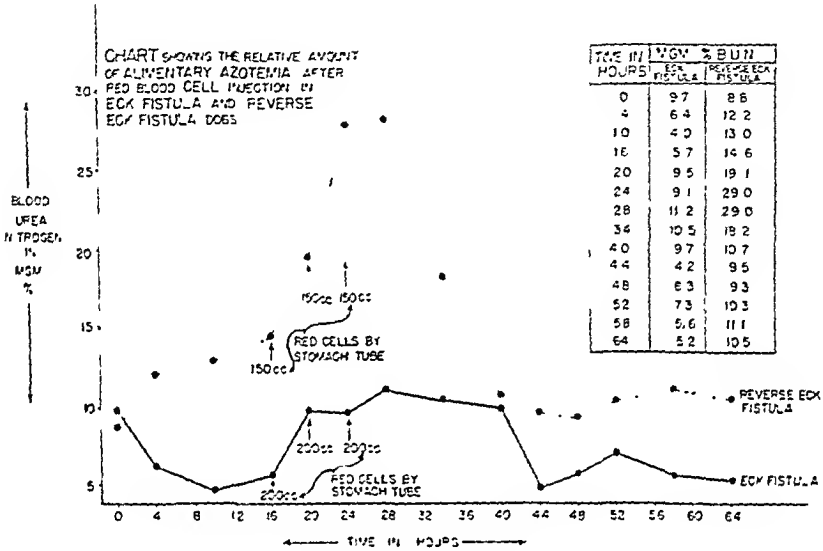

TIME IN HOURS	MGM % BUN	
	ECK FISTULA	REVERSE ECK FISTULA
0	9.7	8.6
4	6.4	12.2
10	4.0	13.0
16	5.7	14.6
20	9.5	19.1
24	9.1	29.0
28	11.2	29.0
34	10.5	18.2
40	9.7	10.7
44	4.2	9.5
48	6.3	9.3
52	7.3	10.3
58	5.6	11.1
64	5.2	10.5

Fig. 3.—The same as Fig. 2.

ANIMALS WITH BOTH PORTAL VEIN AND VENA CAVA LIGATED

In two such animals, after the administration of red blood cells by stomach tube, a moderate rise in blood urea nitrogen occurred as shown in Fig. 4. This rise was roughly proportionate to that occurring in normal animals, and while less than that resulting in most of the dogs with reverse Eck fistulas, it was far more than that noted in any of the dogs with Eck fistulas.

HEPATECTOMIZED ANIMALS

Red blood cells were given by duodenostomy tube to five dogs following total hepatectomy. In no instance was there a marked rise in the blood urea nitrogen. In one experiment shown in Fig. 5, the level fell slightly at first and rose terminally. In another experiment not illustrated, the level fell slightly until just before death and then dropped to 2 mg. per cent just at the time of death. The results in the other three experiments are demonstrated in Fig. 6: in one no change; in two a definite decrease.

The method of performing the urea analyses was described in the first article of this series.[1] It is essentially that of Van Slyke and Cullen. While check readings on the same sample of blood were usually accurate

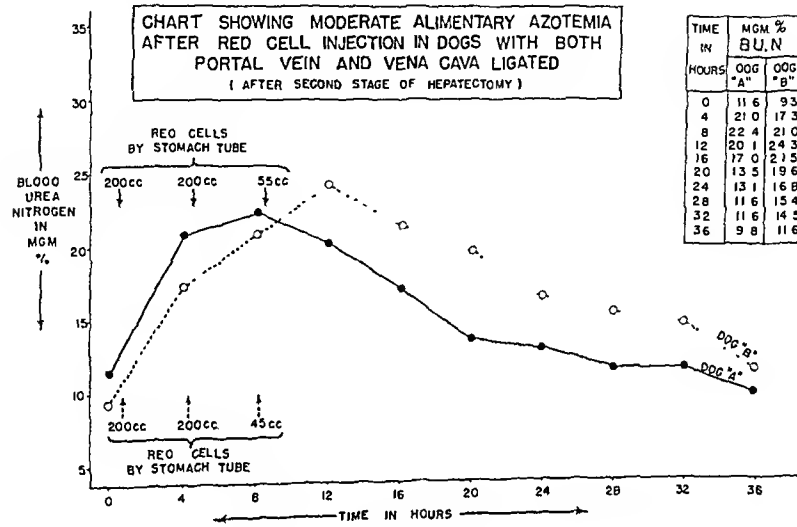

TIME IN HOURS	MGM % B.U.N DOG "A"	DOG "B"
0	11 6	9 3
4	21 0	17 3
8	22 4	21 0
12	20 1	24 3
16	17 0	21 5
20	13 5	19 6
24	13 1	16 8
28	11 6	15 4
32	11 6	14 5
36	9 8	11 6

Fig. 4.—Alimentary azotemia in two dogs with both portal vein and vena cava ligated.

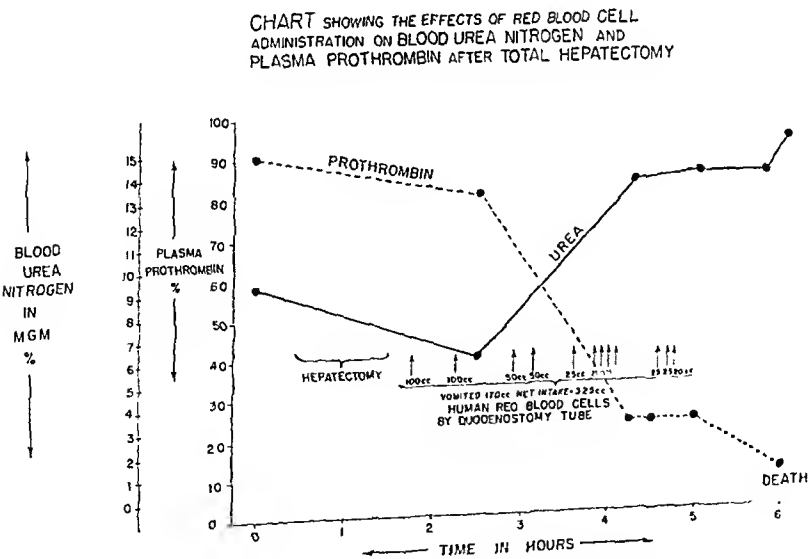

Fig. 5.—Changes in blood urea nitrogen and plasma prothrombin after total hepatectomy.

to within 2 to 3 mg. per cent, we believe the rise in blood urea nitrogen in the single experiment shown in Fig. 5 must in some way represent

an experimental error rather than evidence of blood urea formation in the absence of the liver.

Associated Prothrombin Levels.—While the decrease in plasma prothrombin following hepatectomy has been observed before, this observa-

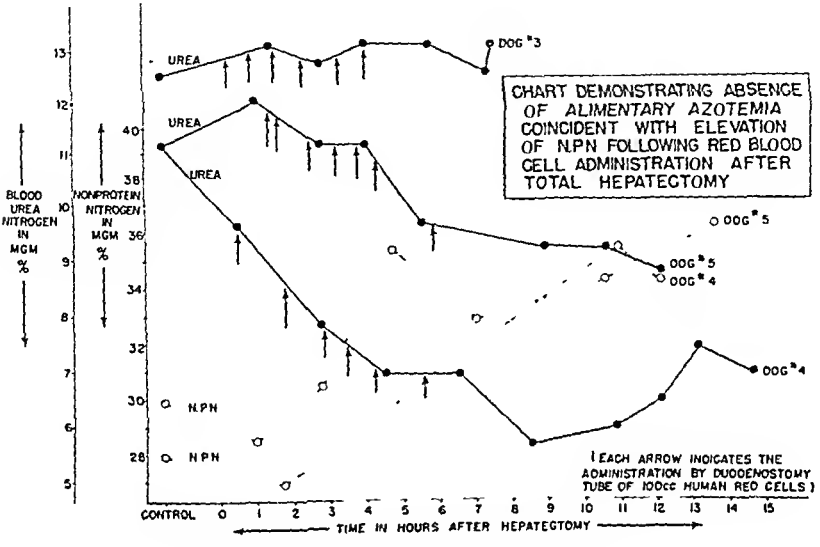

Fig. 6.—Contrasting changes in blood urea nitrogen and nonprotein nitrogen following hepatectomy

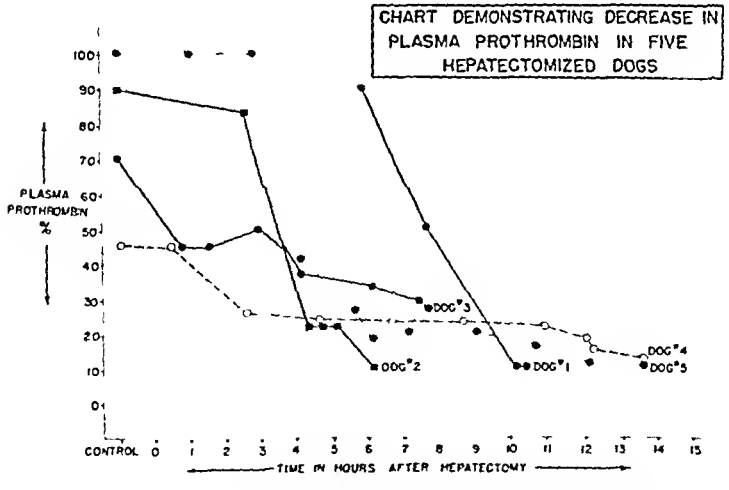

Fig. 7.—Decrease in prothrombin in five hepatectomized dogs

tion has been reported in the literature so little as to deserve re-emphasis here. In Fig. 7, a fall in prothrombin level in all five dogs is demonstrated.

Associated Rise in Blood Nonprotein Nitrogen Levels.—In two animals [illegible] levels exhibited a definite rise as shown

in Fig. 6. It is of especial interest that these two dogs showed the most steady decrease in blood urea nitrogen, demonstrating the lack of parallelism between the changes in these two nitrogenous compounds in these experiments.

BRIEF NOTE ON ROLE OF KIDNEYS IN ALIMENTARY AZOTEMIA

Our observations in this regard are too scant to warrant other than a brief note at this time, especially since only one aspect of the subject is touched upon. Two dogs with kidney damage produced from roentgen rays by the method of Hartman were used.* Red blood cells were administered by stomach tube, and in both animals a rise in blood urea nitrogen occurred. This rise was relatively of about the same extent as that occurring in normal dogs, but was characterized by two differences: (1) It tended to be more prolonged, and (2) it started from a higher base line (about 40 to 50 mg. per cent).

COMMENT

The study of increased blood urea nitrogen following the introduction of blood into the intestinal tract is not only of academic but of practical interest. In the treatment of bleeding peptic ulcer the condition is also of importance. In a case where one is in doubt as to whether or not to operate, an increased blood urea due to renal or hepatic involvement might influence the decision far more than an elevation due to absorption of digested blood.. It was because of this manifest difference in the importance of the syndrome depending on its cause that we started the present studies.

The name azotemia has been applied to this syndrome since Sanguinetti's description[4] in 1934. This word denotes the presence of urea or of other nitrogenous bodies in the blood in abnormal amounts. Arguing from analogy to the commonly used term "alimentary hyperglycemia," it seems logical that the urea syndrome be termed "alimentary azotemia." The mechanism in both is the same, and the adjective differentiates both conditions from similar ones of different causation. Use of the designation "extrarenal azotemia" is not definitive enough. "Alimentary azotemia" means the azotemia due to ingestion of excessive proteins. In bleeding peptic ulcer it is probable that a large share of the resultant azotemia is alimentary azotemia due to ingestion of blood proteins; part of it may be due to other types of extrarenal azotemia, while in some instances actual renal azotemia may be a contributory factor.

SUMMARY AND CONCLUSIONS

1. The degree of alimentary azotemia (as evidenced by a rise in blood urea nitrogen) resulting from the administration of blood elements by stomach tube is altered by certain experimental manipulations on the circulation of the liver.

*These dogs were supplied to us through the courtesy of Dr. F. W. Hartman.

2. More specifically, the amount of elevation in the blood urea nitrogen level following the ingestion of whole blood or blood cells is greatest in animals with reverse Eck fistulas, is moderate in animals with both portal vein and vena cava ligated or in normal animals, and is inappreciable in animals with Eck fistulas or in those in which total hepatectomy has been done.

REFERENCES

1. Chunn, C. F., and Harkins, H. N.: Experimental Studies on Alimentary Azotemia: I. Role of Blood Absorption from the Gastrointestinal Tract, SURGERY 9: 695-705, 1941.
2. Harkins, H. N., and Chunn, C. F.: Experimental Studies on Alimentary Azotemia: II. The Relative Importance of the Plasma and Erythrocyte Fractions of Absorbed Blood, SURGERY 10: 991-998, 1941.
3. Chunn, C. F., Harkins, H. N., and Boals, R. T.: Experimental Studies On Alimentary Azotemia: III. Site of Blood Absorption, SURGERY 11: 56-62, 1942.
4. Sanguinetti, L. V.: Azoemias en el curso de las hemorragias retenidas a nivel del tubo digestivo (estudio clínico y experimental), Arch. argent. de enferm. d. ap. digest. y de la nutrición 9: 264-287, 1934.

CLINICAL STUDY OF RELATIVE EFFICIENCY FOR NITROGEN METABOLISM OF CASEIN DIGEST ADMINISTERED INTRAVENOUSLY AND PROTEIN INGESTED BY MOUTH*

ALEXANDER BRUNSCHWIG, M.D., AND NANCY CORBIN, M.S., CHICAGO, ILL.
(From the Department of Surgery, The University of Chicago)

IT HAS been repeatedly demonstrated that casein digests may be administered intravenously with safety to man, and that by such means a negative nitrogen balance may be reduced, a nitrogen equilibrium maintained, and even a positive nitrogen balance obtained. The question of the efficiency in metabolism of nitrogen administered intravenously as a casein digest, as compared to its ingestion as protein by mouth, presents itself. For such study a group of postoperative patients who had undergone a variety of major intra-abdominal procedures were placed on nitrogen balance studies beginning the day after operation. Urine and feces were collected and total nitrogen loss determined, to be compared with nitrogen intake during each twenty-four hour period. During the initial period casein digest (Amigen) was administered daily together with dextrose. After four to six days, nitrogen balance studies continuing, a light diet was permitted by mouth, the daily protein content of which represented a quantity of nitrogen equivalent to the amount previously administered daily by vein as casein digest. The total caloric value of the diet by mouth (which included a small quantity of fat) was equivalent to the caloric value of the casein digest with glucose administered by vein. The calculated total calorie intakes usually varied from 780 to 1,200 calories.

In the interest of brevity the details of the total calorie intakes of each of the patients are not presented, suffice it to state again that for each individual patient these conditions were approximately uniform during the periods of parenteral nutrition and during the subsequent periods of nourishment by mouth. In a few instances the patients did not consume all of the diet on the first or second day when feeding by mouth was permitted. The nitrogen balances on such days, therefore, were not considered in the study; only those days where the full diet was consumed are taken into account.

The results of the nitrogen metabolism studies under these conditions are summarized in Table I. The patients presented are a selected group and are those in whom the postoperative course was essentially uneventful except for slightly elevated temperatures on the first two or three

*This study was conducted under a grant from Mead Johnson & Company, Evansville, Indiana.
Received for publication, Aug. 10, 1943.

TABLE I

COMPARISON OF NITROGEN BALANCE IN POSTOPERATIVE PATIENTS DURING PERIOD OF NITROGEN NUTRITION BY VEIN (CASEIN DIGEST-AMIGEN) WITH PERIOD OF PROTEIN NUTRITION BY MOUTH

PATIENT	PERIOD OF INTRAVENOUS INJECTIONS OF CASEIN DIGEST				PERIOD OF NITROGEN INGESTION BY MOUTH AS FOOD PROTEIN			
	NO. OF DAYS	TOTAL N INTAKE (GM.)	TOTAL N EXCRETION (GM.)	AVERAGE DAILY N BALANCE (GM.)	NO. OF DAYS	TOTAL N INTAKE (GM.)	TOTAL N EXCRETION (GM.)	AVERAGE DAILY N BALANCE (GM.)
I (L.)	5	75.00	76.00	−0.20	4	60.00	56.56	+0.86
II (L.)	5	75.00	64.00	+2.20	5	76.00	43.40	+6.72
III (F.)*	4	60.00	61.94	−0.49	4	28.80	27.00	+0.45
IV (K.)	6	72.00	94 67	−3.72	6	72.00	62.14	+1.64
V (W.)	4	60.00	68.37	−2.09	4	60.80	61.85	−0.26
VI (C.)	5	45.75	48.70	−0.59	5	41.00	44.50	−0.70
VII (D.)	4	24.00	28.40	−1.10	4	23.20	31.00	−2.2
VIII (L.)	5	75.00	74.22	−0.16	5	75.00	49.21	+5.16
IX (H.)	5	36.00	32.34	+0.73	5	23.60	21.2	+0.48
X (C.)	5	15.00	66.16	−10.23	5	13.00	50.34	−7.47
XI (H.)	5	30.00	58.7	−5.74	5	26.28	40.74	−2.89
XII (M.)	4	48.00	46.88	+0.48	5	55.60	60.00	−0.88

*Total gastrectomy for carcinoma.

days postoperatively. This selection was necessary since where severe nausea and vomiting occur the nitrogen excretion might be inordinantly high; also, patients with moderate to high febrile reactions excrete relatively large quantities of nitrogen.

DISCUSSION

Among the twelve patients studied, three (II, IX, and XII) exhibited positive nitrogen balances during the injection period and in one (II) the positive balance was substantially greater when nitrogen was ingested by mouth as protein. In Patient IX the positive balance was less during the period of oral feeding but the total nitrogen intake was less than it was by vein. In Patient XII there was a slightly negative nitrogen balance on oral feeding as compared to a slightly positive nitrogen balance during the injection period.

In two patients (I and VIII) nitrogen equilibrium obtained during the injection period with slight positive balance in Patient I on oral feedings, and markedly positive nitrogen balance in Patient VIII during this period.

In two patients (III and VI) there was slight negative balance during the injection period, with slight positive nitrogen balance and nitrogen equilibrium, respectively, during the periods of oral feeding.

Two patients (V and VII) were in moderate negative nitrogen balance during the injection periods, and during the periods of oral feeding one (V) came into moderate positive nitrogen balance, while the other (VII) exhibited a greater negative balance.

Three patients exhibited rather pronounced negative nitrogen balances during the injection period (IV, X, XI), and during the oral feeding

period one (IV) was in moderate positive nitrogen balance, the second (X) remained in pronounced negative balance although less than during the injection period, and the third (XI) exhibited moderate negative balance, the total nitrogen intake, however, being appreciably less than that obtained during the injections.

It is noted that there was considerable variation in the results observed when comparing nitrogen balance during periods of nitrogen administration by vein as casein digest with periods when nitrogen was ingested orally as food protein. In most instances, however, the differences in the two periods were not pronounced. In the preceding patients the conditions of the experimental observations themselves favored a more pronounced negative nitrogen balance during the period which immediately followed operation and was the period during which injections of casein digest were carried out. Previously reported studies[1] on postoperative nitrogen loss have shown that this loss is much more pronounced during the first five days after operation. Thus, it could hardly be anticipated that nitrogen balance would be as favorable, under the aforementioned conditions of observations during the injection periods as during the periods of oral feedings. That the differences were, in general, not greater in favor of the efficiency of nitrogen metabolism when nitrogen was administered as food protein by mouth, attests to the efficacy of intravenous nitrogenous nutrition with casein digest.

It might appear superfluous in view of the classical biochemical and physiological teachings to demonstrate that intravenous nitrogenous nutrition by injection of amino acids (casein digest) approaches the efficiency of nitrogen utilization when taken by mouth as protein. However, until such studies were actually made in man and animals (the latter having been previously reported by others), the question of the existence of some unknown and important factor concerned with nitrogen assimilation and utilization in the wall of the alimentary tract could not be settled. *It thus appears that such a factor does not exist.*

SUMMARY

Data are presented to indicate that the efficiency in utilization of nitrogen administered intravenously as casein digest in man closely approaches the efficiency of utilization of nitrogen when ingested orally as food protein. The conditions of the clinical experiments recorded here favored, in themselves, a greater loss of nitrogen during the periods in which the digest was administered, as compared with the periods in the same patient when nitrogen was ingested as food protein.

REFERENCE

1. Brunschwig, A., Clark, D. E., and Corbin, N.: *Postoperative Nitrogen Loss and Studies on Parenteral Nitrogen Nutrition by Means of Casein Digest*, Ann. Surg. 115: 1091, 1942.

VARICOSE VEINS

A New Technique Resulting in the Rapid Obliteration of the Venous Channels Without the Formation of the Usual Large Thrombi

Maunsel B. Pearce, M.D.,* Camp Claiborne, La.

(From the Department of Surgery, Station Hospital, Camp Claiborne)

PAST experiences in the management of the varicose veins in patients have created a desire to find some procedure that would give rapid complete obliteration of all venous channels without the usual large thrombi formation. Ligation and injection at the fossa ovalis in the usual manner resulted in incomplete thrombosis and large thrombi. Recurrences appeared in many cases. The following discourse is based upon a new compression bandage technique with the ligation of all the branches of the saphenous vein and the saphenous vein itself at the fossa ovalis together with low ligation and injection of the saphenous vein only at the low level.

Between October, 1942, and May 15, 1943, 299 patients have been observed. Disposition was recommended according to Table I.

One hundred forty-one patients have been operated upon, and of these, 105 cases have been carefully followed.

The incidence of varicose veins according to age and sex is shown in Table II.

Anatomically there are three systems of veins in the thigh and leg, namely, the internal or long saphenous, the external or short saphenous, and the femoral or deep venous system. In reference to varicosities there is a fourth group which cannot be ignored. This group of veins we call the subcutaneous veins, made up of segmental veins which may

Table I

	PATIENTS	PER CENT
Reclassification without treatment because of other defects	5	1.7
No treatment needed	31	10.4
Certificate of disability for discharge because of other diseases	5	1.7
Injection treatment only	59	19.7
*Advised to seek separation from service W.D. Cir. No. 397	37	12.3
Operation advised	162	54.2
Total	299	100.0

*War Department authorizing discharge of inductees above 38 years of age who were engaged in essential war industries prior to induction.

*Major, U. S. Army.

Received for publication, Aug. 9, 1943.

TABLE II

AGES	PATIENTS	PER CENT	M	F
Between 19 and 20	2	1.9	2	0
Between 21 and 25	24	22.86	24	0
Between 26 and 30	35	33.33	34	1
Between 31 and 35	24	22.86	24	0
Between 36 and 40	10	9.52	10	0
Between 41 and 45	9	8.59	9	0
Between 46 and 50	1	0.95	1	0
Total	105	100.0	104	1

*One on the basis of psychoneurosis and the other because of severe bronchial asthma.

communicate with the long saphenous system at different points or may communicate in segmental fashion between the superficial branches of the long and short saphenous systems. The important point is that upon complete obliteration of the circulation in the long and short saphenous systems of the patient with varicose veins, these segmental subcutaneous channels with their varicosities may persist and vice versa.

These segmental subcutaneous varicose veins, however, are most amenable to injection treatment alone, because they communicate only indirectly with the main saphenous systems and are not a direct part of these systems per se.

Injections of sclerosing fluid into the varicosities of either the long saphenous or short saphenous system without ligation are almost sure to result in poor response or complete failure.

Mild varicosities of the internal or external saphenous system per se need no treatment and cause no symptoms. Appearance is the only indication of their presence. However, even mild varicosities of the subcutaneous group may produce sensations of prickling, discoloration, and even pain by forming small thrombi. Injection alone will secure excellent results in this small group, but will not eradicate the varicosities of the internal and external saphenous system.

Varicosities that are large, tortuous, ectatic, and producing symptoms of fullness in the veins and legs, leg fatigue, cramps in muscles, thrombi in segments, pains and cramps during or following long marches or upon standing at attention for long intervals, discoloration of the skin with suspected or impending ulceration, should be treated by active surgical and injection procedures.

Table III illustrates the incidence of varicosities according to legs involved.

TABLE III

	PATIENTS	PER CENT
Right leg	75	72.4
Left leg	66	62.8
Bilateral	36	34.3
Unilateral	69	65.7

Table IV illustrates the incidence of varicosities according to systems.

TABLE IV

	PATIENTS	PER CENT
Internal saphenous unilaterally	69	65.7
Internal saphenous bilaterally	36	34.4
Internal plus external saphenous	16	15.2
External saphenous only	4	3.8
Subcutaneous veins needing injection	26	24.7

The treatment of choice is one that will give complete thrombosis with elimination of the circulation throughout all varicosities, and is of such a nature that it is without untoward effects.

Another important point in treatment, especially in this group, is to accomplish the complete obliteration of the varicosities in the shortest time to be consistent with saving man power for the fullest expression of the war effort. Every soldier with varicosities producing symptoms that warrant operative intervention is potentially a candidate for reclassification to limited service or for a certificate of disability for discharge. Table V shows the ultimate disposition of cases in which operation was done.

TABLE V

	PATIENTS	PER CENT
Reclassified to limited service	17	12.05
Returned to full duty	122	86.53
*Certificate of disability for discharge	2	1.42
Total	141	100.00

*One on the basis of psychoneurosis and the other because of severe bronchial asthma.

The following procedure has been used uniformly in 141 patients with sustained excellent primary results, and without untoward effects.

A careful history is taken as to symptoms, duration, previous serious illnesses or operations, attacks of pain or swelling of the legs, with or without edema, and previous treatment, if any. One patient had as many as eighteen injections into the main saphenous systems without improvement.

To establish evidence of whether the varicosities are in the internal or external saphenous system per se or are of the subcutaneous type, or to establish evidence of adequate deep circulation without segmental or extensive thrombophlebitis these steps are taken with the patient standing, bearing equal weight on both feet: observation, palpation, percussion of venous channels, percussion of venous channels along with palpation, the application of continuous point pressure over venous channels with leg elevated and then with patient standing; the Ochsner-Mahorner[1] various level, comparative tourniquet test; and the Trendelenburg-Brodie test.

If the long saphenous system is at fault unilaterally or bilaterally, the saphenous vein is marked with 1 per cent gentian violet immediately over the fossa ovalis and again over the lower long saphenous vein in the thigh, just above the knee as shown (Fig. 1). If the short saphenous vein is to be ligated or if a segmental vein is to be ligated and injected, it is marked in like manner. If the patient is scheduled for operation, the leg is shaved widely around the operative sites the night before. He eats breakfast as usual the following morning, and no preliminary sedation is used because these patients must get up and walk postoperatively from the operating table to the stretcher, a distance of at least fifteen feet, because early and continuous walking obviates saphenous vein stump thrombosis.

Fig. 1.—The leg is shown marked with gentian violet over the internal saphenous vein at the fossa ovalis and at the lower thigh; wrapped with the rubber bandage and in position on the operating table.

Upon being placed on the operating table, the leg is held up in nearly perpendicular position, and all varicosities emptied of blood as completely as possible. Massage from the foot toward the body is used if necessary to collapse them. While the leg remains in an elevated position, a compression bandage 2 inches wide and 12 feet long of the ACE type, or better a pure, all rubber bandage (Davol) 2½ inches wide and 12 feet long is snugly wrapped from foot to knee, the end being tucked under the last turn so that it can be easily released. Another bandage is begun just above the operative site on the lower thigh and is carried to the groin.

The leg is now placed on the operating table with the knee elevated slightly on a sandbag as shown (Fig. 1). The groin and unwrapped thigh area are painted with tincture of iodine. The iodine is thoroughly

dried by fanning with a towel before the leg is draped. The gentian violet marks are still plainly visible as the iodine does not remove them.

The line of incision through the skin and parallel to the fold in the groin as previously marked is inflated with 5 c.c. of 1 per cent novocain using a small hypodermic needle. Ten cubic centimeters of 1 per cent novocain are infiltrated through a No. 22 gauge three-inch needle into the subcutaneous tissue and injected toward the incoming nerves above. Five cubic centimeters of 1 per cent novocain are deposited directly over the femoral artery and vein. Withdrawal of the plunger before injection of novocain precludes possible introduction into blood vessels. This area is then massaged with a dry sponge to cause better diffusion of the anesthetic solution.

An incision of 1½ to 2 inches in length, parallel to the skin fold, is made just through the skin. By careful dissection the superficial tissues are separated and the saphenous vein with all of its branches is dissected and identified. The branches are doubly ligated with cotton and severed between the ligatures. Four ligatures of cotton are placed on the saphenous vein, the uppermost one being above the pudendal branch and the two lower ones as far distal as possible. The smallest size cotton thread adequate for ligation of the vessels concerned should be used. No. 40, 30, 20, and 8 cotton have been employed. The section of vein in between is removed; the superficial fascia closed with interrupted sutures of No. 50 cotton and the skin with interrupted sutures of No. 20 or No. 8 cotton.

In no patient is sclerosing fluid injected at the upper thigh level at the time of operation. Thrombosis occurs in these segments in almost every instance. If thrombosis has not occurred within two weeks following operation, 5 c.c. of sodium morrhuate are injected. This was necessary in less than 5 per cent of the patients in this series.

The foot and leg drape is now moved down to the lower level. The skin is infiltrated with 2 c.c. of 1 per cent novocain, and 2 c.c. are injected deeply on each side of the vein. A transverse incision is made, and by careful dissection the saphenous vein is elevated. Two ligatures of cotton are placed around the proximal portion and a loose ligature of cotton is placed around the distal portion. The vein is cut in half transversely, lying on a small clamp while a gentle pull is made by the assistant on the loose ligature. A cannula made of a No. 19 gauge needle filed smooth at its point is inserted, attached to a 10 c.c. syringe carrying 5 c.c. of 5 per cent sodium morrhuate with 2 per cent benzyl alcohol. The loose ligature is tightened so that the cannula is fixed in the lumen and no leakage of sclerosing fluid will occur. While the cannula is held steady, an operating room attendant begins to unwrap the bandage from the knee toward the foot. As the leg is unwrapped, the sodium morrhuate is injected so that when the last turn is off, the last of the sclerosing

fluid is injected into an empty or nearly empty venous system. Rapid removal of the bandage is desired. The cannula is withdrawn, the ligature tightened, and a second ligature placed on the distal end before the vein is severed. If there is duplication of the saphenous vein, both are injected and ligated. The drapes are removed and the remaining bandage removed from the thigh.

If there are any long subcutaneous tributary veins present at this lower level they are also ligated but not necessarily injected. Ligation at the lower thigh level is done in every instance regardless of single or double positive Trendelenburg test, and even though the Oehsner-Mahorner test shows no communicators with incompetent valves. This low level ligation is necessary to accomplish the desired effect of the sclerosing fluid on the intima of the empty veins, and it also seems desirous to interrupt permanently the continuity of this long venous channel.

Small sterile dressings are placed over the wounds and fixed with adhesive tape. It is very desirous that small dressings be used as they do not interfere with the patient in walking.

The patient immediately sits on the side of the operating table, gets off and walks to the stretcher, a distance of fifteen feet. When he arrives at the ward he must walk every thirty minutes during the rest of the day. If he awakes at night, he is asked to get up and walk. The second day he walks about the ward at least every hour and the third day he is encouraged to walk at frequent intervals and to walk to the mess hall.

Within twenty-four to forty-eight hours following operation the sclerosing fluid, which has penetrated the furthermost ramification of the varicosities in the internal saphenous system of the lower leg, has caused red or slightly brownish streaks to appear along the varicose channels. The varicosities do not refill with blood, and the large thrombi seen before the use of the compression bandage technique are not present. It would appear that this phenomenon is due to the constricting action of the sclerosing fluid as it comes in contact with the intima of the empty vein into which it is injected. It also seems plausible that the smaller the thrombi, the less the discomfort and the quicker the patient's leg returns to normal condition. This has certainly been our experience.

This same method of procedure is applicable to treatment of the short saphenous vein in which case it is only necessary to wrap the rubber bandage over the lower leg. Segmental subcutaneous veins for ligation and injection can also be emptied by use of the bandage.

Thrombosis readily takes place in the thigh varicosities due to the ligation alone. In some cases thrombosis occurs as rapidly as in the veins which have received the sclerosing fluid and again it may be two weeks before the thrombus forms.

In the dissections of the saphenous vein at the fossa ovalis we have seen the anatomic variations of all type, as have been so adequately described by Glasser.[2]

The average period of hospitalization is fourteen days, at the end of which time these patients return to regular duty.

Evidence to substantiate the clinical experience was sought by roentgenographic studies of the varicose veins when injected with x-ray opaque diodrast.

Five cubic centimeters of diodrast were injected into the internal saphenous system at the lower thigh while the internal saphenous vein was full of blood as the leg lay in the horizontal position on the operating table. A roentgenogram was made thirty seconds later and it shows stagnation of the diodrast in the upper segment of the vein (Fig. 2a, *A*).

The leg was then elevated and wrapped with the compression rubber bandage from the foot to the operative site at the lower thigh. Another roentgenogram was taken to show that all the diodrast was extruded from the system (Fig. 2a, *B*). Now as the rubber bandage was removed from the thigh toward the foot, 5 c.c. of diodrast were injected and thirty seconds later another roentgenogram was taken showing the dissimination of this, an equal volume of diodrast into the distal most ramifications of the varicosities (Fig. 2b, *A*). The other view (*B*) in Fig. 2b shows the diodrast still present three minutes later.

Another patient was studied and again 5 c.c. of diodrast were injected into the internal saphenous system at the lower thigh while the internal saphenous vein was full of blood as the leg lay in the horizontal position on the operating table. A roentgenogram was made thirty seconds later and it shows stagnation of the diodrast in the upper vein segment (Fig. 3a, *A*). Another roentgenogram was made three minutes later to determine if after a time interval there was better dissimination, but none occurred (Fig. 3a, *B*).

The leg was then elevated and wrapped with the compression rubber bandage from the foot to the operative site at the lower thigh. Now again as the rubber bandage was removed, 5 c.c. of diodrast were injected and thirty seconds later another roentgenogram was taken showing the dissimination of the diodrast into the ramifications of the varicosities (Fig. 3b, *A*). Three minutes later another roentgenogram was taken and the diodrast was still prominently visible (Fig. 3b, *B*).

One must conclude that an equal volume 5 c.c. of sodium morrhuate would and does likewise disseminate into the most distal varicosities of the system injected and therefore causes more complete obliteration of that system.

The maximum amount of sodium morrhuate injected into any one vein is 5 c.c. and the maximum amount given to any one patient at any one time, even in bilateral long saphenous ligation together with single

fluid is injected into an empty or nearly empty venous system. Rapid removal of the bandage is desired. The cannula is withdrawn, the ligature tightened, and a second ligature placed on the distal end before the vein is severed. If there is duplication of the saphenous vein, both are injected and ligated. The drapes are removed and the remaining bandage removed from the thigh.

If there are any long subcutaneous tributary veins present at this lower level they are also ligated but not necessarily injected. Ligation at the lower thigh level is done in every instance regardless of single or double positive Trendelenburg test, and even though the Oehsner-Mahorner test shows no communicators with incompetent valves. This low level ligation is necessary to accomplish the desired effect of the sclerosing fluid on the intima of the empty veins, and it also seems desirous to interrupt permanently the continuity of this long venous channel.

Small sterile dressings are placed over the wounds and fixed with adhesive tape. It is very desirous that small dressings be used as they do not interfere with the patient in walking.

The patient immediately sits on the side of the operating table, gets off and walks to the stretcher, a distance of fifteen feet. When he arrives at the ward he must walk every thirty minutes during the rest of the day. If he awakes at night, he is asked to get up and walk. The second day he walks about the ward at least every hour and the third day he is encouraged to walk at frequent intervals and to walk to the mess hall.

Within twenty-four to forty-eight hours following operation the sclerosing fluid, which has penetrated the furthermost ramification of the varicosities in the internal saphenous system of the lower leg, has caused red or slightly brownish streaks to appear along the varicose channels. The varicosities do not refill with blood, and the large thrombi seen before the use of the compression bandage technique are not present. It would appear that this phenomenon is due to the constricting action of the sclerosing fluid as it comes in contact with the intima of the empty vein into which it is injected. It also seems plausible that the smaller the thrombi, the less the discomfort and the quicker the patient's leg returns to normal condition. This has certainly been our experience.

This same method of procedure is applicable to treatment of the short saphenous vein in which case it is only necessary to wrap the rubber bandage over the lower leg. Segmental subcutaneous veins for ligation and injection can also be emptied by use of the bandage.

Thrombosis readily takes place in the thigh varicosities due to the ligation alone. In some cases thrombosis occurs as rapidly as in the veins which have received the sclerosing fluid and again it may be two weeks before the thrombus forms.

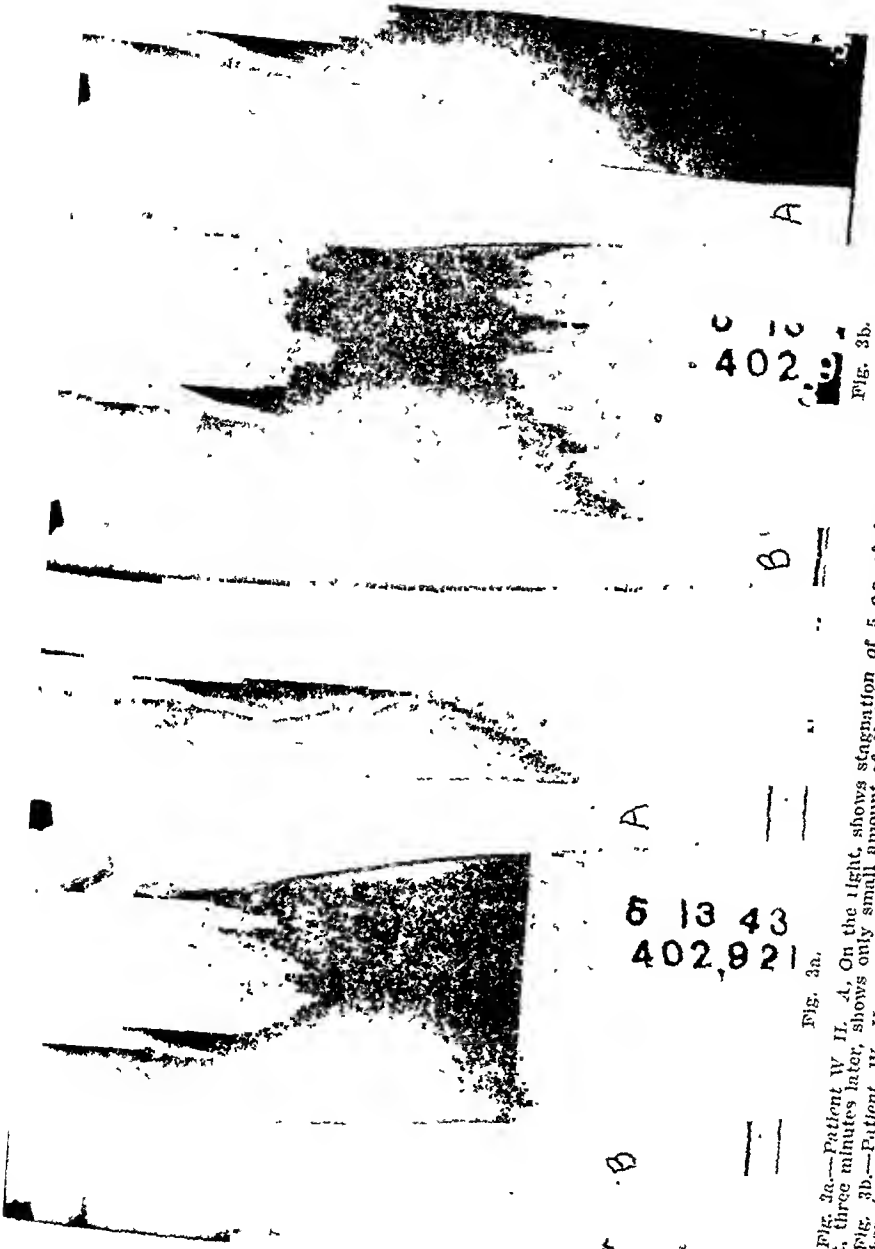

Fig. 3a.

Fig. 3b.

Fig. 3a.—Patient W. H. *A*, On the right, shows stagnation of 5 c.c. of diodrast in the upper vein segment. *B*, On the left, three minutes later, shows only small amount of diodrast present.

Fig. 3b.—Patient W. H. *A*, On the right, shows the dissemination of 5 c.c. of diodrast when injected using the rubber bandage technique. *B*, On the left, three minutes later, shows the diodrast still prominently visible.



Fig. 2a.

Fig. 2b.

Fig. 2a.—Patient C. J. S. *A*, On the right, shows stagnation of the diodrast in the upper vein segment. *B*, On the left, shows all diodrast expelled before the second injection of 5 c.c. is done.

Fig. 2b.—Patient C. J. S *A*, On the right, shows the dissemination of 5 c.c. of diodrast when injected using the rubber bandage technique. *B*, On the left, shows the diodrast three minutes later still visible.



Fig. 5.—Patient S. De G., aged 36 years. *A*, Shows bilateral varicosities of the internal saphenous system plus subcutaneous segmental varicosities of the left leg behind the knee. *B*, Shows the patient three days following bilateral ligations at fossa ovalis and at lower thighs with bilateral injections of 5 c.c. sodium morrhuate, and also ligation and injection of 3 c.c. sodium morrhuate in subcutaneous vein. Note absence of large thrombi. *C*.—Showing the patient four weeks postoperatively.

short saphenous ligation, is 12 c.c. These amounts produce adequate thrombosis.

There have been no systemic reactions, such as anaphylaxis, coughing, nausea or vomiting, pallor or fainting. Local reactions, severe in some cases, manifested by red streaks along veins, erythema, and edema, all have subsided and disappeared within seven to ten days. Small hard thrombi remain as evidence of the original varicosities, and these are absorbed only after months have passed.

Fig. 4, *A* and *B*.—Patient R. P., aged 25 years. This patient had varicose veins bilateral, involving the internal saphenous veins bilaterally and the right external saphenous system.

C and *D*.—Showing end result four months later following bilateral ligations at the fossa ovalis and at the lower thighs with injections of 5 c.c. sodium morrhuate into each long saphenous vein and ligation of the right external saphenous vein with injection of 4 c.c. sodium morrhuate. This patient has continued to remain on full military duty status and marches 12 miles without discomfort.

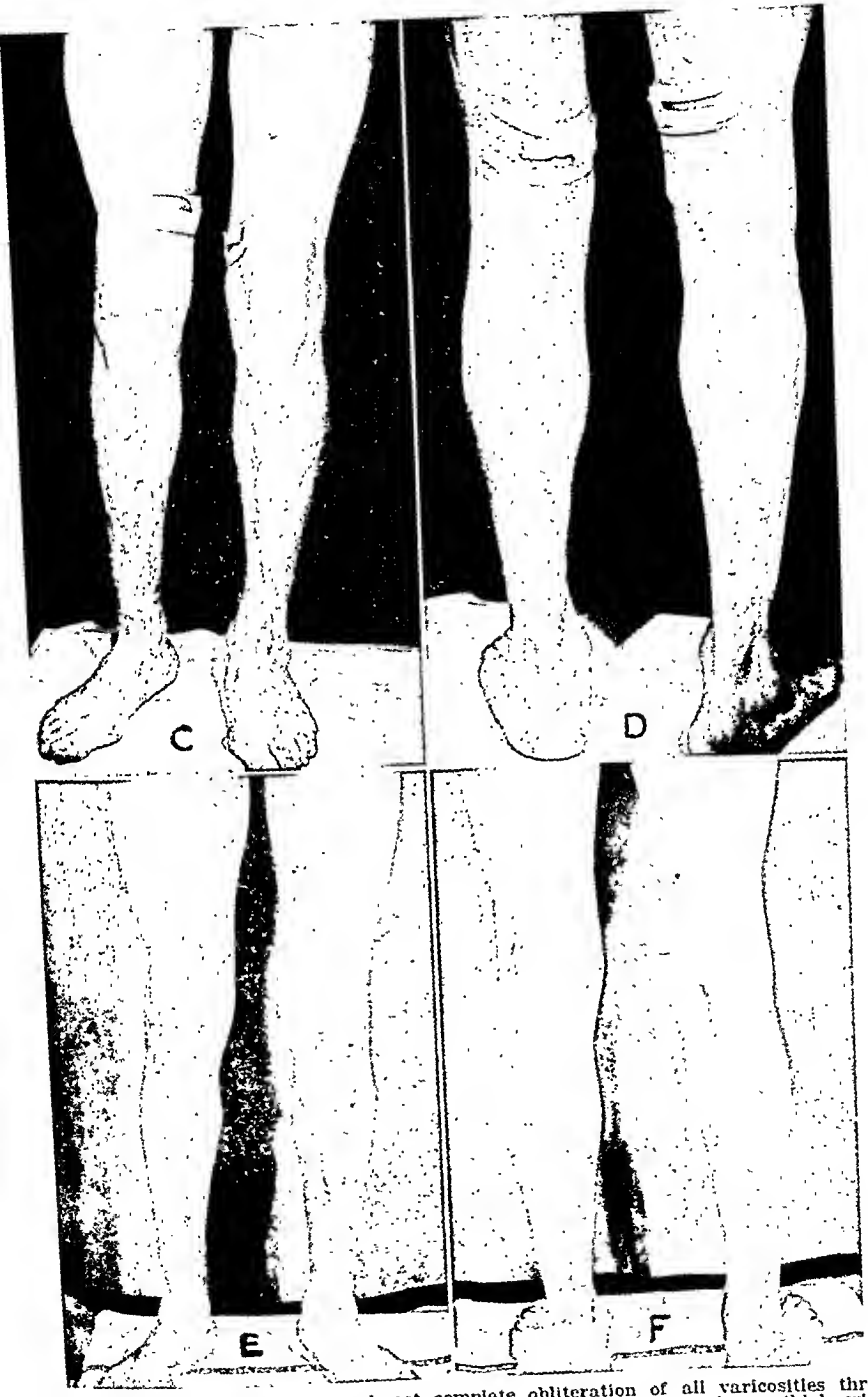

Fig. 6. *C* and *D*.—Showing almost complete obliteration of all varicosities three days following bilateral ligations at the fossa ovalis and at the lower thigh with bilateral injection of 5 c.c. sodium morrhuate; note absence of large thrombi.

E and *F*.—Showing patient fourteen days postoperatively with complete obliteration of the varicosities.

Only two wounds have broken down in the region of the groin, both because of hematoma formation, and both promptly healed following evacuation of clots and warm saline dressings.

Only two patients have shown mild persistent edema of the leg, and this only over the tibia.

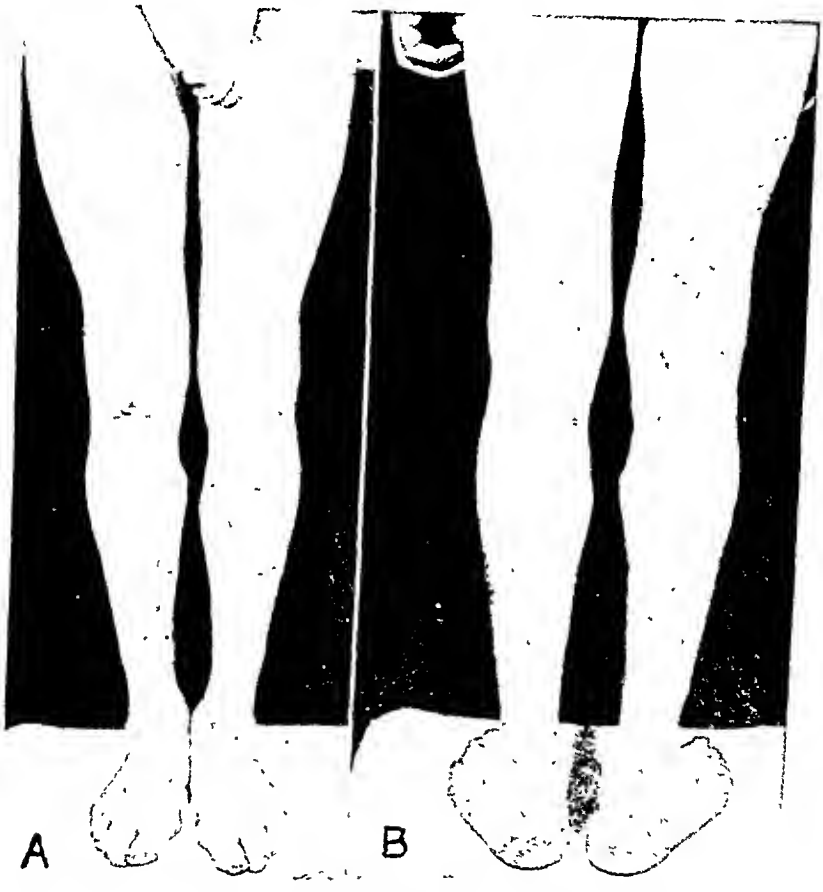

Fig. 6, *A* and *B*.—Patient W. G., aged 35 years. Showing varicose veins of internal saphenous systems bilaterally.

SUMMARY

1. One hundred forty-one cases of varicose veins are reported. All those involving the long saphenous were treated by uniform ligation of all its branches and the saphenous itself at the fossa ovalis without injection of sclerosing fluid into the thigh, together with ligation and injection of the internal saphenous at the lower thigh.

2. It is believed that complete emptying of the veins by compression bandages of the ACE or rubber type is a distinct advantage in reducing the size of the thrombi and insures better diffusion of the sclerosing fluid into the most distal ramifications of the varicosities.

SYNTHETIC VITAMIN K AND THE THROMBOSIS OF VEINS FOLLOWING INJURY

CHARLES BRUCE MORTON, M.D.,* EDWIN W. SHEARBURN, M.D.,† AND RAY E. BURGER, M.D.‡

(From the Department of Surgery and Gynecology, University of Virginia School of Medicine, Charlottesville, Va.)

VITAMIN K is used widely in certain surgical patients to combat a bleeding tendency and in parturient women to prevent hemorrhagic disease of the newborn. Both surgical patients and parturient women are particularly susceptible to thrombosis and thrombophlebitis, although the use of vitamin K does not appear clinically to increase their susceptibility. The following study was made of a group of patients and of a series of experiments with animals to determine what influence, if any, the use of vitamin K might have on thrombus formation.

The suggestion of the relationship of hemorrhagic diathesis to a deficiency of the fat-soluble vitamin K, in 1929,[1] and later in 1934,[2] by Dam, stimulated great interest in this new vitamin. Vitamin K is concerned with the production of plasma prothrombin which is involved in the mechanism of the clotting of the blood. In animals, prolongation of the prothrombin time with accompanying bleeding has been observed in chicks after the withdrawal of the vitamin from the diet, and in cattle with sweet clover disease. In man, a lowered blood prothrombin with its bleeding accompaniment has been observed in hemorrhagic disease of the newborn, obstructive jaundice, severe liver damage, and in chronic gastrointestinal diseases and conditions such as sprue, chronic ulcerative colitis, intestinal polyposis, and gastrocolic fistula. The attendant hemorrhages have been treated prophylactically and therapeutically in the last few years with vitamin K, with the addition of bile salts in the jaundiced patient. Doisy and his associates[3] have been mainly responsible for the synthesis of vitamin K, the compound being 2-methyl-1,4-naphthoquinone.

Waddell, Guerry, and Birdsong[8, 9, 10] have made a study of prothrombin deficiency in infants in this hospital and have obviated hemorrhages in the newborn infants by administering vitamin K concentrate and synthetic vitamin K to infants in the first few days of life, and to mothers in the last two weeks of pregnancy.

No observer so far has reported an increased incidence of thrombosis or thrombophlebitis in patients treated with vitamin K. In the University of Virginia Hospital, at the time this investigation was commenced,

*Professor of Clinical Surgery and Gynecology.
†Captain, Medical Corps, U. S. Army.
‡Instructor in Surgery.
Received for publication, Aug. 31, 1943.

3. Five cubic centimeters of sodium morrhuate produce excellent thrombosis in varicosities of the lower leg and this is the maximum amount used in any single vein.

4. It would appear that this technique yields a complete obliteration of all varicosities without untoward manifestations.

5. No recurrences have been noted but it is unquestionably too soon to estimate this phase of the subject. It is hoped that a supplementary report may be made in the future.

The author would like to acknowledge the cooperation of Colonel Lucius F. Wright, Station Hospital; Lt. Colonel A. Scott Hamilton, Surgery Division; Lt. Colonel P. V. McCarthy, x-ray department; Sergeant Leonard Ingber, who made the photographs, and the entire surgical staff in the preparation of this paper.

REFERENCES

1. Ochsner, A., and Mahorner, H.: Varicose Veins, St. Louis, 1939, The C. V. Mosby Company.
2. Glasser, S. T.: An Anatomic Study of Venous Variations at the Fossa Ovalis; the Significance of Recurrence Following Ligations, Arch. Surg. 46: 289, 1943.

both needles withdrawn together by a rotary motion so as to tear slightly the intima throughout, approximately 6 to 8 cm. of the length of the vessel. The amount of trauma was in all instances made as uniform as possible. The site of insertion of the needle and the level to which it was introduced in the vein was then marked by tatooing the leg.

Under general anesthesia with Abbott veterinary nembutal given intraperitoneally and intravenously (1 c.c. per 5 pounds), at approximately forty-eight hours after the traumatizing procedure described, the veins were removed by surgical excision from ten control dogs and from ten dogs treated with synthetic vitamin K. Care was taken to avoid trauma at the time of removal. At ninety-six hours veins were removed from the legs of fifteen dogs of the control group, and from seventeen dogs of the vitamin K group. Prothrombin times, hematocrit determination, and, in some, clotting times were repeated on all dogs immediately before operation.

Each of the excised veins were fixed in 10 per cent formalin before sectioning. Four sections were taken from each vein at various levels. They were processed in the usual manner, mounted in paraffin, and stained with hematoxylin and eosin.

RESULTS

In some instances the initial venipuncture was unsatisfactory and consequently these vessels were not included in the study. The stained sections of all veins were studied alone and by a pathologist who in no instance knew whether he was dealing with experimental or control material. Only those vessels showing subtotal or total occlusion of the lumen were adjudged thrombosed. Some veins had a minimal amount of fibrin deposited at the puncture site and were excluded from the group of thrombosed veins. There was no significant difference between the incidence of thrombosis in the animals at forty-eight and ninety-six hours after trauma.

The incidence of thrombosis in the animals which were used as controls was twenty-nine out of eighty-nine veins, or 33.0 per cent. In the vitamin K group there were thirty-seven out of ninety-seven veins or 38.0 per cent (Table II). There was no significant difference in the incidence of thrombosis in those receiving Squibb's synthetic preparation of vitamin K in corn oil, and those receiving Abbott's synthetic preparation of vitamin K in sesame oil.

The prothrombin time of all the animals, both before and after ad-

TABLE II

COMPARISON OF RESULTS IN THE GROUP OF DOGS GIVEN VITAMIN K AND THE GROUP USED AS CONTROLS

GROUP	NO. OF VEINS	POSITIVE FOR THROMBOSIS	PER CENT OF POSITIVES
Vitamin K	97	37	38.0
Control	89	29	33.0

both the natural and synthetic vitamin K complex had been administered orally and intravenously to 700 pregnant women during the antepartum period with only one case attended by thrombophlebitis, and that following a Porro section, performed because of fibroids of the uterus complicating the delivery. The incidence of thrombophlebitis in this group of 700 was, therefore, only 0.14 per cent. In the preceding ten years without vitamin K there had been 5,728 deliveries with twenty-eight cases complicated by thrombophlebitis during the puerperium. Almost one-half of these cases had had some accompanying operative procedure, such as a Cesarean section, Porro section, or sterilization. The incidence of thrombophlebitis in this group was 0.48 per cent. Consequently, the incidence of thrombophlebitis was greater in the larger group receiving no vitamin K, other than that obtained in the average diet (Table I).

EXPERIMENTAL METHODS

The plan devised was to traumatize mechanically the leg veins of two groups of dogs. The first group was to be fed an excess of vitamin K in addition to a normal diet. The second, the control group, was to receive the diet alone.

Mongrel dogs weighing nine to forty-two pounds were used and were fed a normal diet throughout. Twenty-five dogs were used as controls and twenty-seven dogs were given vitamin K, 3 mg. of 2-methyl-1,4-naphthoquinone* per dog per day during the entire experiment. Prothrombin determinations by the Quick method[5, 6] and hematocrit determinations were made on all the dogs before the start of the investigation and at the end of one week. In some of the animals clotting times were made by placing about 1 c.c. of venous blood gently in a glass-stoppered

TABLE I

INCIDENCE OF THROMBOPHLEBITIS IN PARTURIENT WOMEN IN THE UNIVERSITY OF VIRGINIA HOSPITAL

GROUP	NO. OF DELIVERIES	CASES OF THROMBOPHLEBITIS	PER CENT OF THROMBOPHLEBITIS
Vitamin K	700	1	0.14
Control	5,728	28	0.48

weighing dish, and recording the time of clot formation. On the eighth day of the experiment, the radial and saphenous veins of the four legs of both the experimental and control groups of dogs were treated in the following manner. Pressure was applied to the limb proximally to engorge the vessel. A No. 15 intravenous needle was then introduced well into the lumen of the vein after which a No. 22 spinal needle with a slight "hook" on the tip was inserted, through the larger needle, farther into the vein. The vein was then collapsed by releasing the pressure and

*Part were given Abbott's synthetic preparation in sesame oil, part Squibb's synthetic preparation in corn oil.

in the control group and vitamin K group before and after feeding vitamin K.

Clinically, vitamin K has proved efficacious in the prophylactic and therapeutic treatment of hemorrhagic diathesis of the newborn infant, with no increase in the number of thromboses. The incidence of thrombophlebitis in only one of 700 pregnant women given vitamin K in its various forms, orally and intravenously, as prophylaxis against hemorrhagic disease in the infant was 0.14 per cent over a period of two years. In 5,728 women delivered but not given vitamin K in a preceding ten-year period, there were twenty-eight cases of thrombophlebitis or an incidence of 0.48 per cent.

As shown by Norris and Bennett,[4] the average plasma prothrombin values of mothers at delivery are greater than normal controls, being 111 per cent. This may contribute to the slightly increased incidence of thrombophlebitis in parturient women.

SUMMARY

A group of experiments performed to study the possible influence of vitamin K on thrombus formation in dogs has been described. The radial and saphenous veins of the legs of fifty-two dogs were traumatized mechanically by scarifying the intima with a hooked needle. The veins were removed at forty-eight and ninety-six hour intervals afterwards. Twenty-seven of the animals received a surplus of synthetic vitamin K along with the regular diet for a week prior to the injury, and the remaining twenty-five were utilized as controls. Prothrombin times, hematocrit determinations, and clotting times were made in each animal at intervals, without any demonstrable effect of synthetic vitamin K administration.

The incidence of thrombosis after injury to the intima of the veins was not significantly increased coincident with the administration of synthetic vitamin K, being 33.0 per cent in the control group and 38.0 per cent in the vitamin K group. The small difference does not seem important. The prothrombin values, which are important in the coagulation process, did not significantly change after the administration of synthetic vitamin K. There was no significant difference in the results obtained by the Squibb and Abbott synthetic preparations. Those dogs with a hematocrit reading below 40 per cent, however, revealed a slightly higher incidence of thrombosis in both the control and vitamin K fed group.

Clinically, the incidence of thrombophlebitis has been less in the University of Virginia Hospital in the smaller group of women given vitamin K just before or at the time of delivery than in the larger group receiving no exogenous vitamin K except in the normal diet.

CONCLUSIONS

The clinical and experimental data reported demonstrate that an excess of vitamin K does not result in an increased rate of thrombosis.

ministration of vitamin K, was well within normal limits. In the group fed vitamin K the average prothrombin time before the start of the experiment was 6.6 seconds, and the average on the eighth, tenth, and twelfth days was 6.3 seconds.

Hematocrit determinations revealed no significant change in the relative erythrocyte volume during the period of experimentation. In the six dogs in the vitamin K group having one or more hematocrit readings below 40 per cent, the incidence of thrombosis was 62.0 per cent. In the five dogs of the control group with a reading below 40 per cent, the thrombosis rate was 44.0 per cent (Table III). This is in agreement

TABLE III

RESULTS: INCIDENCE OF THROMBUS FORMATION IN THE DOGS HAVING ONE OR MORE HEMATOCRIT READINGS BELOW 40 PER CENT

GROUP	NO. OF VEINS	POSITIVE FOR THROMBOSIS	PER CENT OF POSITIVES
Vitamin K	21	13	62.0
Control	18	8	44.0

with the findings of other workers from the time of Weleh,[11] who found an increased thrombosis rate in patients with anemia, deficiency states, and cachexia.

A few clotting times were well above normal, but most of these were in those dogs which were under anesthesia, which will increase the clotting time of the blood. The average clotting times of the unanesthetized dogs were within the normal range without marked variation, varying from 6.1 to 8.9 minutes on the various days. In the anesthetized groups the average varied from 8 to 11.4 minutes.

DISCUSSION

The foregoing experiments were undertaken in the belief that synthetic vitamin K would probably not influence the incidence of thrombosis in a group of normal dogs which had been and were on an adequate diet, and whose prothrombin times indicated a normal plasma prothrombin. Since the normal animal has a large excess of prothrombin which far exceeds the physiologic requirements, and at least 80 per cent may be lost before the coagulation time is greatly prolonged,[7] feeding vitamin K to a normal animal should not appreciably alter the prothrombin time and concentration. Actually, feeding synthetic vitamin K for at least a week or more was found to lower the average prothrombin time only 0.3 second, which is within the limits of experimental error.

The slight difference in the incidence of thrombosis between the control and experimental groups of dogs is probably of no significance. The thromboplastin, calcium, and fibrinogen factors which are essential to the clotting process were presumably equal in the two groups, and the prothrombin factor was found to have essentially the same normal value

ACUTE DIVERTICULITIS OF THE JEJUNUM—CASE REPORT

FRED F. RUDDER, M.D.,* PANAMA, R. P.

(From the Surgical Service, Gorgas Hospital)

IN THE course of surgical operations requiring an inspection of the stomach and upper gastrointestinal tract I have encountered both single and multiple diverticula of the jejunum on fairly numerous occasions.

Previously, in no instance, either pre- or postoperatively, had this condition given rise to any symptoms. Recently, a Costa Rican farmer was admitted to the surgical service of Gorgas Hospital with a diagnosis of acute surgical abdomen. A definite preoperative diagnosis could not be arrived at, and an exploratory laparotomy revealed that he was suffering from an acute diverticulitis of the jejunum. Due to the rarity of this condition, the following case is reported.

E. C., aged 56 years, was admitted to the hospital Dec. 19, 1942. The chief complaint was agonizing colicky pain in the upper abdomen, and vomiting of three days' duration. The onset of this illness had been three days previously with acute colicky pains in the epigastrium. The pain was intermittent in character, and so severe that he was doubled up with each seizure. The pain increased in severity and remained in the epigastric region. There was no radiation of the pain. It was increased by deep breathing. No position accorded any relief. Nausea and vomiting were present for three days. The vomitus was yellow in color. There were no chills nor fever, no jaundice, no clay-colored stools, no tarry stools. When asked why he came to the hospital he replied that he was brought by his family against his will; pain was so severe he thought he would surely die.

Past History.—For two months prior to this attack he had been having slight, dull aching pains in the epigastric region about thirty minutes after meals. All types of food caused pain.

Physical examination revealed an acutely ill, thin, dehydrated mestizo man, lying in bed with both lower extremities flexed on the abdomen. He held his upper abdomen with both hands crying out with each paroxysm of pain. Temperature was 99.6° F., pulse 90, respiration 20. Skin was dry; there was no jaundice. Head and neck were normal, as were heart and lungs. Blood pressure was 130/54. Abdomen was flat, with no distention; it was held rigid. The respirations were thoracic. Palpation revealed generalized spasticity and rigidity, most marked in the upper abdomen. The point of maximum tenderness was in the midepigastrium just to the right of the midline. The liver could not be palpated and no abdominal masses were palpated. There was no tenderness to deep percussion over the kidney regions. Peristalsis was slightly increased. The genitourinary system was normal; neurologic system was normal.

Laboratory Findings.—Hemoglobin was 70 per cent; red blood cells 4,000,000; white blood cells 24,600; polymorphonuclear neutrophil leucocytes 93 per cent; eosinophiles 2 per cent; lymphocytes 5 per cent. Thick and thin smears for malaria were negative, Kahn test was negative, and urinalysis normal. X-rays of the chest were

*Lt. Col., Medical Corps, Army United States; Assistant Chief, Surgical Service.

Received for publication Sept. 18, 1943.

We wish to express appreciation to Dr. J. K. Scott, Department of Pathology, for valuable aid rendered in microscopic study of the tissues, and to Dr. K. B. Grim, Department of Clinical Pathology, for making the prothrombin and hematocrit determinations.

REFERENCES

1. Dam, H.: Cholesterinstoffwechsel in Hühnereiem und Hühnchen, Biochem. Ztschr. 215: 475, 1929.
2. Dam, H., and Schouheyder, F.: A Deficiency Disease in Chicks Resembling Scurvy, Biochem. J. 28: 1355, 1934.
3. Doisy, E. A., MacCorquodale, D. W., Thayer, S. A., Binkley, S. B., and McKee, R. W.: The Isolation, Constitution and Synthesis of Vitamin K, Science 90: 407, 1939.
4. Norris, R. F., and Bennett, N. C.: Plasma Prothrombin Values of Mothers and Infants at Delivery, Surg., Gynec. & Obst. 72: 758, 1941.
5. Quick, A. J.: The Prothrombin in Hemophilia and in Obstructive Jaundice, J. Biol. Chem. 109: LXXIII, 1935.
6. Quick, A. J., and Lee, M.: Quantitative Determination of Prothrombin, J. Biol. Chem. 119: LXXXI, 1937.
7. Quick, A. J., Stanley-Brown, M., and Bancroft, F. W.: A Study of the Coagulation Defect in Hemophilia and Jaundice, Am. J. M. Sc. 190: 501, 1935.
8. Waddell, W. W., Jr., and Guerry, D. III: Effect of Vitamin K on the Clotting Time of the Prothrombin and the Blood, J. A. M. A. 112: 2259, 1939.
9. Idem: The Role of Vitamin K in the Etiology, Prevention and Treatment of Hemorrhage in the Newly Born, J. Pediat. 15: 802, 1939.
10. Waddell, W. W., Jr., Guerry, D. III, and Birdsong, McL.: The Role of Vitamin K in the Etiology, Prevention and Treatment of Hypoprothrombinemia and the Hemorrhagic Diathesis of the Newly Born, South. M. J. 33: 974, 1940.
11. Welch, W. H.: Thrombosis, Papers and Addresses, Vol. I, Baltimore, 1920, Johns Hopkins Press, p. 110.

The gross specimen showed rather marked reddening and congestion of the serosa. The wall was slightly thickened, the rugae of the mucosa were prominent. There was no ulceration or perforation. Microscopic examination showed hyperplasia of the jejunal mucosa. The lamina propria of the mucosa was markedly congested. A few of the vessels had ruptured, spilling blood into the interstitial tissue. The lamina propria in some areas was heavily infiltrated with plasma cells, eosinophilic leucocytes, a few small round cells, and a rare polymorphonuclear leucocyte. A slight subacute inflammatory reaction was noted within the submucosa. The serosal vessels were slightly congested. No evidence of malignancy or acute perforation was found.

The postoperative course was uneventful. The patient was discharged on the twentieth postoperative day. Re-examination eight months later, Aug. 13, 1943, showed the patient to be in excellent health. He had regained his original weight of 104 pounds. He has had no abdominal pain, he can eat any type food without discomfort. X-ray of the gastrointestinal tract was normal.

SUMMARY

1. A case of acute diverticulitis of the jejunum is reported.

2. Due to the rarity of this condition, it was thought advisable to include it in the literature.

negative. There was no air underneath the diaphragm. A flat plate of the abdomen was negative and no renal or biliary calculi were seen.

A tentative diagnosis of acute cholecystitis was made and the patient was given ¼ gr. of morphine and 1000 c.c. of 5 per cent glucose in normal saline solution. Three hours later his condition was much worse. The pain in the epigastrium returned with greater intensity, it was now constant, he was unable to lie still, and rolled from one side of the bed to the other, crying out with the pain. The temperature rose to 101.2° F., pulse 110, respiration 24. The abdominal rigidity was now boardlike. The white blood cell count was repeated and was 49,100, polymorphonuclear neutrophil leucocytes 91 per cent, eosinophiles 2, and lymphocytes 7.

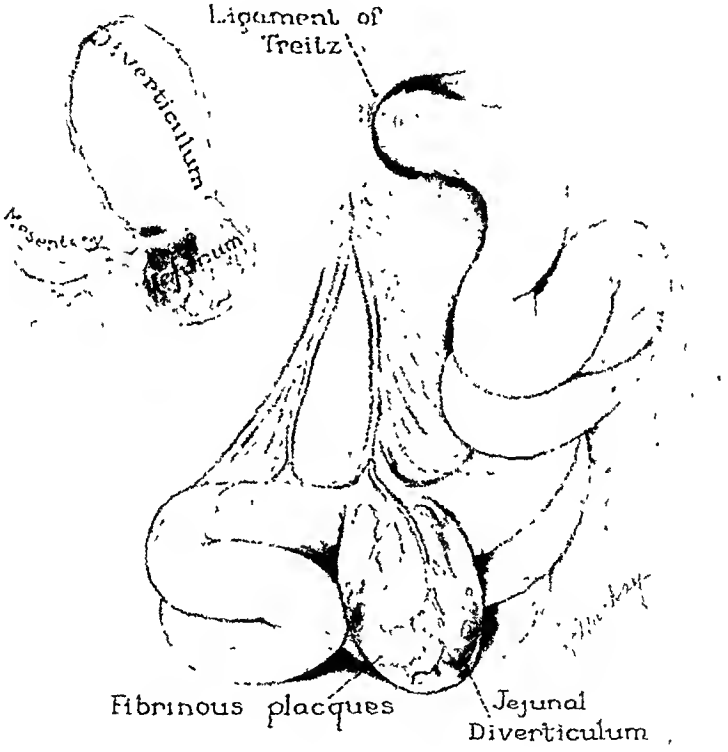

Fig. 1.

An exploratory laparotomy was done for perforation of the gall bladder. Under ether anesthesia an upper right rectus incision was made. On opening the peritoneal cavity there was a moderate amount of cloudy fluid. The peritoneum and serosa of the intestines were slightly injected. The gall bladder and bile ducts were normal. No gastric or duodenal ulcers were found. The pancreas was normal and appendix was normal. A search of the small gut revealed a large solitary diverticulum of the jejunum about eighteen inches from the ligament of Treitz (Fig. 1). It arose from the superior aspect of the jejunum about 1 cm. from the mesenteric border. It measured 2½ cm. at its base, 4 cm. in width, and 6 cm. in length. Its serosa was markedly injected, and scattered over its surface were numerous fibrinous placques, similar to the reaction seen in acute suppurative appendicitis. The walls of the diverticulum were slightly thickened, and its contents, mostly gas, were easily evacuated into the jejunum. Its base was clamped, and the diverticulum was removed.

The gross specimen showed rather marked reddening and congestion of the serosa. The wall was slightly thickened, the rugae of the mucosa were prominent. There was no ulceration or perforation. Microscopic examination showed hyperplasia of the jejunal mucosa. The lamina propria of the mucosa was markedly congested. A few of the vessels had ruptured, spilling blood into the interstitial tissue. The lamina propria in some areas was heavily infiltrated with plasma cells, eosinophilic leucocytes, a few small round cells, and a rare polymorphonuclear leucocyte. A slight subacute inflammatory reaction was noted within the submucosa. The serosal vessels were slightly congested. No evidence of malignancy or acute perforation was found.

The postoperative course was uneventful. The patient was discharged on the twentieth postoperative day. Re-examination eight months later, Aug. 13, 1943, showed the patient to be in excellent health. He had regained his original weight of 104 pounds. He has had no abdominal pain, he can eat any type food without discomfort. X-ray of the gastrointestinal tract was normal.

SUMMARY

1. A case of acute diverticulitis of the jejunum is reported.

2. Due to the rarity of this condition, it was thought advisable to include it in the literature.

TUMORS OF SALIVARY GLAND ORIGIN

So-Called Mixed Tumors

Guy F. Robbins, M.D.* New York, N. Y.

(From the Department of Surgery, New York Post-Graduate Medical School and Hospital)

Introduction.—Although "mixed" tumors of salivary gland origin are not uncommon, debate still rages about etiology, and to a lesser degree, about diagnosis, and treatment. This report by various members of the staff of the New York Post-Graduate Hospital, of fifty-six cases seen at this institution during eleven years from February, 1930, to February, 1941, may serve to clarify the problems of diagnosis and therapy.

Pathogenesis.—The pathogenesis of this group of tumors has been a controversial subject for many years. Maximow and Bloom, Arey, Zymbal, Li and Yang, and Sheldon have contributed to its study. Sheldon agreed with most authors that the cartilage-like cells, often so prominent a feature of the tumors, were in reality epithelial cells, but contended that true cartilage may be present, the latter arising, not from epithelium, but from the stroma itself. He regarded the neoplasms as composed of one or two different types of cells, both normally present in salivary glands; one is represented by secreting epithelium, and the other by the basket cells which are peculiar muscle cells belonging to the myoepithelium. Allen opposed his conclusions to those represented by Zymbal and by Sheldon. Working with four so-called mixed tumors from mammary glands of dogs and one from a human breast, Allen considered the "cartilage" in three canine cases to be true cartilage "derived directly from adult epithelium," and indicated that these conclusions were applicable to "mixed" tumors of the salivary glands.

Gross Anatomy.—Relatively few neoplasms of the salivary glands are clinically and microscopically carcinomas, and almost all are referred to as "mixed" tumors. The word "mixed" is placed in quotation marks because practically none are really mixed, in the sense of teratomas (ovary, testis, etc.) and refers to the fact that, in addition to the predominating epithelium, there is stroma with diverse features suggesting dysontogenesis.

"Encapsulation" is a term with various interpretations. The capsule of a salivary gland neoplasm bears no resemblance to the true capsule of the spleen or kidney. It consists of the more or less thickened pre-existent interlobular septa of the peripheral part of the gland. This means that, on the one hand, the "capsule" is intimately connected with

*Captain, Medical Corps, U. S. Army.

Received for publication, July 22, 1943.

the septa in the area of the tumor, and that, on the other hand, the "capsule" is also connected with the septa of the surrounding nonneoplastic portion of the salivary gland. As a result, when the neoplasm is "enucleated," nonneoplastic tissues are also removed as they lie outside the capsule of the tumor.

There are dilated neoplastic acini just inside and closely adherent to the capsule. If an attempt were made to remove the tumor without the capsule, the outermost walls of such tumor acini would be left behind to serve as the nidus for a so-called recurrence of the new growth.

Malignancy may manifest itself as extension of the neoplasm beyond the capsule, or, less commonly, by metastasis.

"Aberrant" cannot be applied to the neoplasms found in the mouth. Aberration of the normal process of development may be responsible for the presence of salivary gland tissues in structures adjacent to the oral cavity, including the base of the skull. The lobe of the ear is too close to the parotid gland to be considered a significant aberrant site. A few tumors similar to the so-called aberrant tumors have been found elsewhere in the body, as, for example, on the leg. The close resemblance between cutaneous basal tumors and salivary gland tumors suggests that such neoplasms of the extremities are probably extreme variants of basal cell carcinoma.

The surface of the salivary gland tumor is frequently nodular because the neoplastic process involves many lobules. The cut surface is usually lobulated, light gray to yellowish gray, and often has mucoid or glassy areas. The latter are foci of cartilage-like stroma, which however, rarely cut with the resistance of true cartilage.

Microscopic Anatomy.—Microscopically, the predominant element is the epithelium which appears in the form of interlacing strands, convoluted columns, solid nests, cribriform nests, acini, etc. Impressive evidence, including that provided by tissue culture, has been marshalled by Zymbal to indicate that the neoplasms are not mixed. His work tends to show that the mucoid portions of the stroma are due to degeneration and subsequent disintegration of the epithelium. The so-called cartilage is, therefore, not cartilage but altered stroma that suggests but does not have the features of true cartilage.

Other changes in the stroma include hyalinization (frequently a prominent feature), calcification, and even ossification. Fat is sometimes found. Many salivary gland tumors do not have the cartilage-like areas in conspicuous fashion, so that unless several sections are examined the microscopic picture may look like that of an adenoma, a relatively rare salivary gland tumor.

Site.—There were 56 mixed tumors of the salivary gland region in 55 patients. One patient had two distinct tumors, one of the soft palate and another of the parotid gland. The tumor of the soft palate was completely removed and seven years later a tumor of the parotid gland

was noted and removed; neither has recurred. Of the 56 tumors, 32 were in the parotid, 3 in the submaxillary, and 1 in the sublingual gland. Twenty others, not connected with the large glands, were found in various parts of the head. Eight were in the hard palate, 2 in the upper lips, 2 in the lower lips, and 2 in the cheek. There was 1 each in the scalp, lobe of the ear, soft palate, nasolabial fold, infraorbital and postauricular areas. One tumor was found on the leg which microscopically closely resembled the neoplasms of this group, but it is not included in the statistical study.

Age and Sex.—Twenty-eight men and 27 women comprised the group reported here. The average age when the tumor was noted was 35 years. The youngest patient was 14 years of age and the oldest, 75 years; 79 per cent were under 50 years of age, and 50 per cent were between 21 and 40. In Wood's series of 42 cases, one-half of the number of patients were between 21 and 50 years of age. Chen and Loucks reported 45 cases of which 80 per cent of the patients were less than 40 years of age. McFarland collected 90 cases, more than one-half of which were in the third and fourth decades. His youngest patient was 1 year old, and his oldest, 75 years.

The youngest patient coming to operation was 16 years of age and the oldest, 76 years; the average age was 43.4 years. Two-thirds of the patients were operated upon during the third, fourth, and fifth decades.

Duration.—A characteristic feature of this group of tumors is the long lapse of time before operation. One patient had noticed a mass for 34 years before coming to the hospital. Benedict and Meigs described a tumor that had been present for at least 38 years. The average duration in this series was 8.4 years, as compared with 7 years as reported by McFarland, and 8.75 years by Wood. One-third of our patients presented themselves within a year after first noting the mass; 79 per cent were seen within 5 years.

Rate of Growth.—No fixed growth rate was noted. Twenty-seven of the patients said their tumors grew slowly. Eleven had noticed a lump for many years which suddenly began to grow rapidly. The tumors of the hard and soft palates came to observation an average of 12 months after first being recognized by the patients. This was probably because growth interfered with mastication and deglutition.

Size, Consistency, and Mobility.—Most of the tumors were smaller than 3 cm. in diameter, but some were as large as 12 cm. Larger neoplasms have been reported; McFarland quotes Conterill as having seen a parotid tumor weighing 26 pounds.

On clinical examination, the majority (37) of the neoplasms was firm. However, 8 were described as cystic, 7 as soft, 3 as nodular, and 1 as fluctuant. The primary parotid tumors were freely movable, but the recurrent tumors were adherent to the skin and deeper structures. Twelve of the twenty tumors found in the head outside the large sali-

vary glands were fixed to underlying tissues; the others were freely movable, as were the neoplasms of the submaxillary glands. The single sublingual gland tumor was fixed to the adjacent structures.

Metastasis.—Distant metastasis is recognized as a rare occurrence. In none of the cases in this series was there metastasis to lymph nodes or to distant regions, but a few submaxillary and sublingual mixed tumors with metastasis to the pleura, lungs, and regional nodes have been reported. Erosion of adjacent bone is frequent in cases of tumor of the hard palate, and two patients of this series have had three recurrences, each involving bone.

Diagnosis.—Only 29 of the 56 tumors (43 per cent) were correctly diagnosed before operation. The record was even poorer with the 20 tumors located outside the large salivary glands; only 1 was properly identified clinically. The fact that salivary gland neoplasm is usually not considered in the differential diagnosis of oral tumors probably is responsible. Tuberculous adenitis, branchiogenic cysts, cysts of the parotid, lipoma, sebaceous or mucous cysts, fibroma, and carcinoma were among the clinical diagnoses.

Most diagnostic problems in neoplasia are simplified by biopsy, but the use of this method has not been helpful in this series. Most of these tumors are so small that primary complete surgical removal is not difficult and is to be preferred.

Blady and Hocker, and others, reported radiographic studies on salivary tumors after injection of the ducts with a radiopaque oil. The filling defect in the duct system was said to be of an "orderly nature" in mixed tumors, whereas carcinoma produced an irregular defect which has been described as "puddling."

Treatment.—All of the 56 tumors here reported were excised widely, with the goal of the entire removal of the tumor and its apparently encapsulating tissues. Erich has suggested electrodesiccation of the wound edges in cases of hard palate tumors—a procedure employed in our clinic.

One patient was given x-ray irradiation preoperatively and another postoperatively. Two others were advised to have postoperative x-ray therapy, but failed to reappear for treatment. (Both treated patients have had no recurrences to date.)

Branches of the facial nerve were sacrificed when necessary. A good cosmetic result was considered secondary to complete removal of tumor tissue. Transient facial paralysis was noted in 3 cases. One patient has permanent postoperative paralysis of the mandibular branch of the seventh nerve.

There is no unanimity of choice of therapy in the literature. There is, however, a trend away from the use of x-ray and radium irradiation and toward radical surgical removal of the tumor, including the apparently encapsulating tissues. Ewing advised radical surgery and had little faith in the use of x-rays. Levine has suggested partial excision of

the tumor mass with implantation of radon seeds and radium blocks. Benedict and Meigs, Widmann, Martin and Elkin, and Cohn considered x-ray and radium palliative at best. Fox reported poor results with x-ray. Brunschwig's use of radium and surgery in a case involving the tongue with lymph node metastasis apparently served to check the growth. Thibaudeau and Burke, Malcom, Merritt, and Martin and Elkin wrote of instances in which patients have done well with combined surgical and x-ray treatment.

McFarland reported 300 cases of mixed salivary tumors, and later 413 instances. He thought x-ray of no value and advised complete surgical excision of the tumor and its apparently encapsulating tissues, indicating that this can best be accomplished by allowing the tumor to reach the size of a lemon before operating. This suggestion is obviously useless in dealing with intraoral tumors. Chen and Loucks practiced radical surgical excision of the tumor and all of its capsule, condemning enucleation alone. Kini and Rao, Cohn, and Swinton and Warren all advised primary radical surgery. The latter two authors mentioned persistent salivary fistulas and facial nerve paralysis as troublesome complications. Repair of the facial nerve was suggested by anastomosis of the spinal accessory or hypoglossal nerve to the facial nerve, together with resection of the superior sympathetic chain.

Recurrences.—Nine of the 55 patients in this series did not return to the follow-up clinics. The remaining 46 patients were alive and still under observation in February, 1941; the average postoperative period is 3.8 years. One patient has been observed for less than 3 months, one has been observed over a period of 10 years, and 3 more for over 8 years. Inasmuch as recurrence may take place many years after primary surgical excision (McFarland reports a recurrence 47 years postoperatively), the postoperative period is too short to be certain of cure. Of the 7 patients with tumors which were recurrent upon admission, 5 have been followed with only 1 recurrence since coming under our observation. In this case there is a nodule, 2 by 3 mm., overlying the parotid area. It has not enlarged since it was first noted 1.5 years ago (8 months postoperatively). There have been 4 recurrences (8.4 per cent) in primary cases, making a total of 5 (10.5 per cent) with recurrence since operation at the New York Post-Graduate Hospital. At present there are 3 patients (6.3 per cent) with recurrences, and of these, 2 (4.2 per cent), both with tumors of the hard palate, have active progressive disease. One was unable to foretell which tumors would recur by studying the microscopic anatomy of the primary tumors, a conclusion also reached by McFarland in a recent article. The 2 patients with active recurrent disease were tumors of the hard palate. One was biopsied and the other desiccated before being submitted to surgical excision. These 2 primary tumors showed microscopic features quite similar to others which have not recurred.

At present it is difficult to form any definite conclusions from one's

own observations or from the literature as to why tumors of the salivary gland region recur. However, results lead to the belief that wide regional excision is the only apparent assurance against recurrences.

There is great variation in the percentage of recurrences reported by others. McFarland reports 69 recurrences (23 per cent) among 297 cases, with 13 fatalities. Martin found 34 mixed tumors of the parotid among 65,351 admissions at the Barnard Free Skin and Cancer Hospital, St. Louis, Mo. Of these, 18 submitted to treatment; 10 showed no evidence of recurrence. Thibaudeau and Burke reported 29 cases. Eighteen were symptom-free, 2 improved, 3 recurrent, and 6 dead in a 10-year series. Patey recorded 50 mixed tumors: 38, parotid; 6, submaxillary; 5, hard palate; 1, sublingual. There were 7 recurrences (19 per cent); these included 5 parotid tumors, 1 submaxillary, 1 of hard palate, and the single sublingual neoplasm. One submaxillary case failed to return to the follow-up clinic. Patey believed that the fear of damaging the facial nerve and the failure to remove the encapsulating tissue of the tumor increased the probability of recurrence.

Swinton and Warren had 2 recurrences (4.3 per cent) among 81 cases, of which 9 were classified as malignant. Wide surgical excision was the procedure followed by them. Eggers collected 87 mixed tumors of the hard palate from the literature and added 5 cases of his own; there were only 2 recurrences (2.1 per cent). Sonnenschein called attention to the frequent recurrence of mixed tumors of the soft palate. Chen and Loucks have followed 18 of 38 mixed tumors; they had no recurrences. Nine of the 18 cases had been followed for less than a year.

Prognosis.—It is well known that mixed tumors of salivary gland origin rarely metastasize to distant regions, but they frequently recur locally. Wood reported a tumor that recurred 17 times during 34 years. Statistics compiled over an 11-year period obviously cannot serve as a basis for satisfactory prognosis. Some tumors are quiescent for years. Paller recorded a tumor which was inactive for 37 years, only to increase in size at the end of that time. McFarland reported quiescence for 49 years and Wood for 53 years. It is not unlikely, however, that the probability of recurrence is smaller following radical surgical excision than after any other form of therapy. Those who have followed this course have had, to date, as good or better results than those who utilize combined surgical and x-ray therapy, or x-ray alone.

CONCLUSIONS

1. A series of 56 mixed tumors of salivary structure is reported.
2. Salivary gland tumors outside the large glands are rarely diagnosed correctly.
3. Wide primary surgical excision of the tumor and its apparent capsule is the treatment of choice and the only protection against recurrence.
4. The primary histologic picture does not reveal information which aids in foretelling recurrence.
5. In the series there are 2 patients (4.2 per cent) with active recur-

rent disease; 5 (10.5 per cent) with recurrences since operation, and 4 (8.4 per cent) with recurrences in tumors which were primary upon admission. Of the original 55 patients, 46 (84 per cent) were included in follow-up studies.

REFERENCES

Allen, A. C.: So-Called Mixed Tumors of Mammary Gland of Dog and Man, Arch. Path. 29: 589, 1940.

Arey, L. B.: Developmental Anatomy, Ed. 2, Philadelphia and London, 1931, W. B. Saunders Company, pp. 159-160.

Benedict, E. B., and Meigs, J. W.: Tumors of Parotid Gland. A Study of 225 Cases With Complete End Results in 80 Cases, Surg. Gynec. & Obst. 51: 626, 1930.

Blady, J. V., and Hocker, A. F.: Application of Sialography in X-ray Studies in Non-Neoplastic Diseases of Parotid Gland, Radiology 32: 131, 1939.

Brunschwig, A.: Mixed Tumors of Tongue and Sublingual Gland, Surg., Gynec. & Obst. 50: 407, 1930.

Chen, H. I., and Loucks, H. H.: Composite Tumors of Salivary Glands. A Clinico-Pathologic Study of 45 Cases, Chinese M. J. 47: 138, 1933.

Cohn, I.: Surgical Clinic: Retroperitoneal Tumors, Sarcoma of Chest Wall; Mixed Tumors of Parotid, Internat. Clin. 2: 257, 1938.

Eggers, H. E.: Mixed Tumors of Palate, Arch. Path. 6: 378, 1928.

Erich, J. B.: Cancer of Jaw, Proc. Staff Meet., Mayo Clin. 16: 75, 1941.

Ewing, J.: Neoplastic Diseases, Ed. 4, Philadelphia and London, 1940, W. B. Saunders Company, p. 794.

Fitzwilliams, D. C. L.: Salivary Gland Tumor, Lancet 229: (2): 769, 1935.

Fox, C. C.: Mixed Tumors of Salivary Gland Type Seen in Pharynx, Arch. Otolaryng. 30: 73, 1939.

Kini, M. G., and Rao, P. R.: Adenoid Epithelial Tumors of Submaxillary Gland With Discussion on Nature of So-called Mixed Tumor of Salivary Gland, Lancet 235 (2): 369, 1938.

Lang, F. H.: Pathologische Anatomie der grossen Kopfspeicheldruesen, in Henke, F. and Lubarsch, O.: Handbuch der Speziellen Pathologischen Anatomie und Histologie, vol. 5, pt. 2, Berlin, 1929, Julius Springer.

Levine, I.: Pathogenesis and Radium Therapy in Mixed Tumors of Salivary Glands, Radiology 34: 69, 1940.

Li, P. I., and Yang, C. S.: Inquiry Into Origin of Mixed Tumors of Salivary Glands With Reference to Their Embryonic Inter-Relationships, Am. J. Cancer 25: 259, 1935.

Malcolm, R. B.: Tumors of Parotid Gland, S. Clin. North America 14: 837, 1934.

Martin, J. D., and Elkin, D. C.: Tumors of Salivary Glands, Arch. Surg. 28: 727, 1934.

Maximow, A. A., and Bloom, W.: Textbook of Histology, 1938, Philadelphia and London, W. B. Saunders Company, pp. 353-361.

McFarland, J.: Ninety Tumors of the Parotid Region, in All of Which Postoperative History Was Traced, Am. J. M. Sc. 172: 804, 1926.

McFarland, J.: Three Hundred Mixed Tumors of Salivary Glands, of Which 69 Recurred, Surg., Gynec. & Obst. 63: 457, 1936.

McFarland, J.: Mysterious Mixed Tumors of Salivary Glands, Surg., Gynec. & Obst. 76: 23, 1943.

Merritt, A.: Mixed Tumors of Parotid Gland, Am. J. Roentgenol. 25: 507, 1931.

Paller, T.: Quoted by Ewing, p. 794.

Patey, D. H.: Mixed Tumors of Salivary Glands, Brit. J. Surg. 18: 241, 1930.

Sheldon, W. H.: So-called Mixed Tumors of Salivary Glands, Arch. Path. 35: 1, 1943.

Sonnenschein, R.: Mixed Tumors in Soft Palate, Arch. Otolaryng. 11: 137, 1930.

Swinton, N. W., and Warren, S.: Salivary Gland Tumors, Surg., Gynec. & Obst. 67: 424, 1938.

Thibaudeau, A. A., and Burke, E. M.: Histological Study of Salivary Gland Tumors, Cancer Research 14: 440, 1930.

Widmann, B. P.: Treatment of Parotid Tumors With Roentgen Rays and Radium, J. M. Soc. New Jersey 31: 95, 1934.

Wilson, L. B., and Willis, B. C.: So-called "Mixed Tumors" of Salivary Glands, Am. J. M. Sc. 143: 656, 1912.

Wood, F. C.: Mixed Tumors of Salivary Glands, Ann. Surg. 39: 57, 207, 1904.

Zymbal, W. E.: Histologische und experimentelle Untersuchungen ueber die Geschwuelste der Speicheldruesen, Beitr. z. path. Anat. u. z. allg. Path. 91: 113, 1933.

SOME STUDIES WITH ZEPHIRAN

With Particular Reference to Its Use in Time of War

Harris B. Shumacker, Jr., M.D.,* and William R. Bethea, Jr., M.D.†

(From the Surgical and Laboratory Services of the 118th General Hospital)

Zephiran is a mixture of high molecular alkyl-dimethyl-benzyl ammonium chlorides in which the alkyl group represents a series of homologous radicals derived from the fatty acids of cocoanut oil. It is the purpose of this communication to describe its properties, its applicability in surgery, to report studies which extend its sphere of usefulness and to point out its special utility in surgery in war time.

Zephiran is an amber colored solid of soaplike consistency. It is marketed as a 1:10 concentrate. It is readily soluble in water, alcohol, and acetone. The solution is colorless and almost odorless. It has a definite detergent, keratolytic and emollient action, and is not irritating to skin. It has a low surface tension, 1:1000 aqueous solution having a surface tension of 37.4 dynes per cubic centimeter at 25.3° C.[5] It is procurable and inexpensive. Soap exerts some inactivating influence upon zephiran,[11] but zephiran is compatible with local anesthetic agents, the sulfonamides and other substances with which it may come in contact in operative surgery. It is stable and active over a wide range of temperatures. Freezing, storage at temperatures in excess of 50° C. for eighteen days, and storage at room temperature for more than eight months cause no apparent loss in germicidal efficacy.[4]

Since Domagk[2] described the remarkable bactericidal property of this agent a number of studies have confirmed its value as a germicide.‡[1, 3, 4, 6, 7, 8, 12, 13]

Testing its efficacy against *Staphylococcus aureus, Eberthella typhosa, E. coli, Streptococcus hemolyticus, Str. viridans, Cryptococcus hominis,* and *Monilia albicans* at 37° C., Dunn[4] found its phenol coefficient varied from 274 against *M. albicans* to 579 against *Str. hemolyticus.* The highest dilution which would kill these organisms in ten but not in five minutes varied from 1:25000 against *Staph. aureus* and *M. albicans* to 1:95000 against *Str. hemolyticus.* Comparing the bactericidal activity of phenol, hexylresorcinol, tincture of merthiolate 1:1000, tincture of metaphen 1:200, pepsodent, and aqueous zephiran 1:1000, Dunn[5] found zephiran superior to all the others against *Staph. aureus* both at 20 and 37° C., superior to all of them against *E. coli* at 20° C., and to

Received for publication, July 5, 1943.

*Captain, Medical Corps, U. S. Army.

†First Lieutenant, Medical Corps, U. S. Army.

‡We shall not attempt to review the literature completely. A number of articles are not available to us in our present situation.

all except metaphen at 37° C. Comparative studies of the bactericidal action of these agents against *Staph. aureus* in 50 per cent horse serum showed zephiran to be superior to the others. Penetration and inhibition tests carried out by Heineman[6] with the agar cup-plate method demonstrated that zephiran has excellent capacity for penetration and inhibition. *Staph. aureus* was inhibited in a concentration of 1:100,000; *E. typhosa* in a concentration of 1:5000 but not in a concentration of 1:10,000. Miller, Baker, and Harrison[5] found zephiran more active in inhibiting the metabolism of dental bacteria and yeast than fluoride and iodo-acetate. Action of zephiran against the spores of *B. subtilis* is enhanced if the solution is brought to a pH of 8.6.[5]

Zephiran for Preparation of the Hands of Members of the Operating Team.—Since dilute aqueous zephiran has, in our experience, proved so eminently satisfactory for the preparation of the skin of the patient before operation it was felt advisable to investigate its possible use for attempting to sterilize the hands of the operating team. One might suppose that any agent satisfactory for the preoperative preparation of skin might be equally useful in preparing the hands of the members of the operating room staff. This is not necessarily true for two reasons. First, there is a remarkably rapid increase of organisms within the gloved hand increasing with the length of time the gloves are worn.[10] Second, the patient may have greater resistance to the flora of his own skin than to that of others. In addition, however, to remarkable germicidal activity, any solution which might be found useful in this regard would necessarily have to possess two additional attributes, namely, lack of irritation of skin when used repeatedly over long periods of time, and extreme lowness of cost. We know of no other agent which apparently possesses all of these qualities.

Experimental Method.—Two problems had to be solved before the study could be undertaken, first, to devise a method which would give reliable comparative estimates of the worth of various methods of preparing the hands, and second, to make sure that any good results which might be obtained would be due to bactericidal and not to bacteriostatic action. Price[10] has described a method of study giving almost quantitative results and constituting a real advance in the investigation of skin sterilization. This depends upon calculation of the number of organisms present on the skin by scrubbing into a large number of basins for one minute each, doing bacterial counts upon the contents of each basin, and plotting the results, which follow a regular logarithmic curve. Such a method of study could not be employed, however, because in a busy army hospital neither the time nor supplies were available. The method decided upon is the following: The hands were prepared and sterile gloves were put on. After the desired interval of time the cuff of the glove was pulled away from the wrist so that the palmar surface of the hand was visible. Ten cubic centimeters of

sterile normal saline solution were then poured into the glove in such a way as to avoid contact with the cuff of the glove which was contaminated. The fingers of the gloved hand were then extended and flexed so as to mix thoroughly the salt solution with any sweat or epithelial debris which might be present on the palmar surface of the hand, following which several cubic centimeters of the solution were withdrawn by sterile pipette. Exactly 1 c.c. was then plated out in 10 c.c. of dextrose agar. Cultures were read after incubation for forty-eight hours at 37° C. This gave us a roughly semiquantitative method with all factors the same in each instance except the bacterial flora of the hands being tested.

After doing a number of experiments dealing with the inactivation of zephiran by soap, the second problem was finally met by experiments such as are recorded in Tables I and II. In the first experiment

TABLE I

SHOWING THAT ABSENCE OF BACTERIAL GROWTH IN CULTURES OF THE PALMAR SURFACE OF HANDS PREVIOUSLY SOAKED FOR 3 MINUTES IN 1:2500 AQUEOUS ZEPHIRAN AND PLACED IN STERILE RUBBER GLOVES WET WITH THE ZEPHIRAN SOLUTION IS DUE TO DEATH OF ORGANISMS AND NOT TO INHIBITION OF GROWTH BY ANY TRACES OF ZEPHIRAN PRESENT

SOURCE	METHOD OF CULTURE	PLATE NUMBER	NUMBER OF COLONIES
Solution from glove	1 c.c. in 10 c.c. dextrose agar	1	0
	1 c.c. plus 1 drop soap in 10 c.c. dextrose agar	2	0
	1 c.c. plus 2 drops soap in 10 c.c. dextrose agar	3	0
5 c.c. of solution from glove contaminated with 0.1 c.c. of 24 hour old *Staph. aureus* broth culture	1 c.c. in 10 c.c. dextrose agar	4	S. T.*
	1 c.c. plus 1 drop soap in 10 c.c. dextrose agar	5	S. T.*
	1 c.c. plus 2 drops soap in 10 c.c. dextrose agar	6	S. T.*
5 c.c. sterile normal salt solution contaminated with 0.1 c.c. of 24 hour old *Staph. aureus* broth culture	1 c.c. in 10 c.c. dextrose agar	7	S. T.*
	1 c.c. plus 1 drop soap in 10 c.c. dextrose agar	8	S. T.*
	1 c.c. plus 2 drops soap in 10 c.c. dextrose agar	9	S. T.*

*S. T., Several thousand; no significant difference in the number of colonies in plates 4 to 9.

a subject, without other preparation of his hands, soaked them for three minutes in 1:2500 aqueous zephiran and put on sterile gloves wet with zephiran. After thirty minutes 10 c.c. of sterile salt solution were poured onto the palmar surface of his gloved hand according to the method described and as much as possible was removed by sterile pipette. One cubic centimeter of this solution was plated out in dextrose agar, and to two similar plates, one and two drops of liquid green soap were added. Five cubic centimeters of the solution removed from the gloved hand were then inoculated with 0.1 c.c. of a twenty-four hour broth culture of *Staph. aureus* and 1 c.c. portions of this contaminated solution were similarly plated. Five cubic centimeters of sterile normal

TABLE II

SHOWING THAT ABSENCE OF BACTERIAL GROWTH IN CULTURES OF THE PALMAR SURFACE OF HANDS PREVIOUSLY SOAKED FOR 3 MINUTES IN 1:1000 AQUEOUS ZEPHIRAN AND PLACED IN STERILE RUBBER GLOVES WET WITH THE ZEPHIRAN SOLUTION IS DUE TO DEATH OF ORGANISMS AND NOT TO INHIBITION OF GROWTH BY ANY TRACES OF ZEPHIRAN PRESENT

SOURCE	METHOD OF CULTURE	PLATE NUMBER	NUMBER OF COLONIES
Solution from glove	1 c.c. in 10 c.c. dextrose agar	1	0
5 c.c. of solution from glove contaminated with 0.1 c.c. of 24 hour old broth culture of *Staph. albus*	1 c.c. in 10 c.c. dextrose agar	2	4000-6000*
5 c.c. of sterile normal salt solution contaminated with 0.1 c.c. of 24 hour old broth culture of *Staph. albus*	1 c.c. in 10 c.c. dextrose agar	3	4000-6000*

*Counting under magnification of a small measured area revealed no significant difference in the number of colonies in plates 2 and 3.

salt solution were then contaminated with 0.1 c.c. of the same broth culture, and 1 c.c. portions of this were plated in similar fashion. After forty-eight hours there was no growth in the first three plates. Several thousand colonies were present in the remaining six plates. Although the colonies were too numerous for accurate count, counting of a small measured portion of each plate under magnification revealed no significant difference in the number of colonies in these six plates. This experiment demonstrated that the maximal amount of zephiran which might be present on the palmar surface of the hands on which 1:2500 zephiran had been used was insufficient to cause any inhibition of growth once it had been diluted with the standard amount of salt solution and agar. A second experiment carried out in the same manner gave identical results. In the experiment recorded in Table II similar studies were made after soaking the hands in 1:1000 aqueous zephiran and putting on gloves wet with the zephiran solution. This experiment also showed that not enough zephiran was present to cause any inhibition of growth in the culture plates.

The studies were all carried out in the operating room, usually in the midafternoon. The room temperature could not be kept constant but varied little from day to day, averaging 85° F. Subjects were officers, nurses, and enlisted men of the operating room staff. Before the experiments were begun the subjects had been performing their regular duties, such as oiling instruments, sorting dirty linen, scrubbing the floor. The hands were not washed and the nails were not cleaned before the experiments were begun. After preparation of the hands the subjects put on sterile rubber gloves and then resumed their regular duties, no effort being made to keep the outside of the gloves sterile. Gowns were not worn. In two instances a glove was inadvertently torn so that culture from this hand could not be obtained. Ordinarily six subjects were used, a culture being obtained from the left hand after having the gloves

on for one-half hour and from the right hand after one hour.

The results obtained are recorded in Table III. Two subjects whose hands were grossly clean but had not been prepared in any manner put on sterile gloves, and cultures were obtained after thirty and sixty minutes. There was considerable variation in the number of colonies present in cultures of the hands of the two individuals. There was an average of more than 120 colonies after thirty minutes and more than 300 after one hour. Six subjects scrubbed their hands and forearms vigorously with liquid green soap and running tap water for three minutes using sterile brushes, then carefully cleaned their nails, scrubbed with soap and water for an additional five minutes and then soaked their hands and forearms for three minutes in 70 per cent by weight ethyl alcohol. After thirty minutes none of the twelve hands cultured showed any growth of organisms, but after one hour 42 per cent of the hands cultured showed some growth, the average number of colonies in those plates showing growth being 1.4 per plate.

Without any cleansing of the hands or nails twelve subjects soaked their hands for three minutes in 1:2500 aqueous zephiran, washing the hands with a wash cloth as they soaked. Following this, sterile gloves were put on wet with zephiran, the hands being held up to allow all of the solution possible to drain out of the gloves. After the gloves were on for one-half hour 42 per cent of the cultures showed some growth, the average number of colonies being 3.2; after one hour 42 per cent also showed some growth, the average number of colonies being 1.6. Twelve subjects similarly prepared their hands by soaking for three minutes in 1:2500 aqueous zephiran after which they dried their hands and put on dry sterile gloves. After one-half hour 25 per cent showed some growth, the average number of colonies being 2, and after one hour 25 per cent showed some growth of organisms, the average number of colonies being 1.3. The slightly higher incidence of positive cultures with the wet technique may have possibly been due to the fact that certain subjects may have inadvertently lowered their gloved hands while their unsterile forearms were still wet with the solution which had drained down from within the glove, thus carrying back into the glove some organisms. Twelve subjects scrubbed their hands with 1:2500 aqueous zephiran and tap water for three minutes, following which the hands were soaked in 1:2500 zephiran for three minutes. There was only one colony which grew out in the plates from twenty-three hands cultured.

Similar experiments were carried out with 1:1000 aqueous zephiran. After a three minute soak, gloves were put on by the wet technique. Only one hand cultured showed any growth of organisms and in this instance only a single colony. After hands were soaked for three minutes and dry gloves put on, two hands showed a growth of a single colony in thirty minutes and one after one hour. Twelve subjects

TABLE III

THE RESULTS OBTAINED FROM CULTURE OF HANDS PREPARED IN VARIOUS WAYS

TECHNIQUE	GLOVES KEPT ON FOR 30 MIN.			GLOVES KEPT ON FOR 60 MIN.			TOTAL		
	NO. HANDS CULTURED	PER CENT SHOWING GROWTH IN CULTURE	AVERAGE NO. COLONIES IN THOSE SHOWING GROWTH	NO. HANDS CULTURED	PER CENT SHOWING GROWTH IN CULTURE	AVERAGE NO. COLONIES IN THOSE SHOWING GROWTH	NO. HANDS CULTURED	PER CENT SHOWING GROWTH IN CULTURE	AVERAGE NO. COLONIES IN THOSE SHOWING GROWTH
No preparation	2	100	120	2	100	300	4	100	210
Soap & water scrub for 8 min., alcohol soak 3 min., gloves dry	12	0	0	12	42	1.4	24	21	1.4
Zephiran 1:2500, soak 3 min., gloves wet	12	42	3.2	12	42	1.6			
Zephiran 1:2500, scrub 3 min., gloves dry	12	25	2.0	12	25	1.3	71	24	2.0
Zephiran 1:2500, scrub 3 min., soak 3 min., gloves dry	12	8	1.0	11	0	0			
Zephiran 1:1000, soak 3 min., gloves wet	12	0	0	12	8	1.0			
Zephiran 1:1000, soak 3 min., gloves dry	12	17	1.0	12	8	1.0	71	7	1.0
Zephiran 1:1000, scrub 3 min., soak 3 min., gloves dry	12	0	0	11	9	1.0			

scrubbed their hands for three minutes in a basin containing 1:1000 zephiran, all scrubbing into the same small basin and using no running water at all, after which the hands were soaked for three minutes in 1:1000 zephiran. Only one hand showed any growth of organisms, this being a single colony.

It is not felt that the absence of growth of organisms in cultures from the gloved hands of our subjects indicates that the hands were sterile. It appears that absolute sterility of the skin of hands and forearms is impossible to attain.[10] It is felt, however, that the method employed is a valid comparison of the effectiveness of the various methods used in these experiments in rendering the hands as free of organisms as is possible. The method of culture was the same in all instances and that portion of the gloved hands cultured is the one in which sweating is most abundant.

It is apparent that there were fewer hands from which positive cultures were obtained after brief scrubbing with 1:2500 zephiran and a short soak in this solution, and after simply soaking the uncleansed hands in 1:1000 zephiran for three minutes than there were after the most rigorous scrubbing with liquid green soap for eight minutes followed by soaking in 70 per cent alcohol for three minutes. Twenty-one per cent of the hands prepared by the usual soap and water and alcohol technique showed some growth of organisms. Of seventy-one hands prepared with 1:2500 aqueous zephiran, 24 per cent showed growth of some organisms. Of seventy-one hands prepared with 1:1000 zephiran, only 7 per cent showed growth of organisms, only one colony growing out in each instance. It would appear that one could at least conclude from this that a brief soak in 1:1000 zephiran brings about as good a preparation of the hands as the most rigorous soap and water scrubbing followed by soaking in alcohol. Certainly this would appear to be particularly true if the soak in zephiran is preceded by a brief scrubbing in this solution.

After soaking in zephiran the hand has a very comfortable satiny feel which persists for several hours. Zephiran cleans the hands very well. It is more effective in removing oil and greasy debris than is soap and water. Used day after day over a long period of time it never causes any skin irritation and does not make the nails brittle or discolored.

It is our feeling that preparation of the skin of the hands and forearms of members of the operating team can be reliably carried out as follows: Clean the nails, scrub the hands and forearms vigorously in aqueous zephiran 1:1000 for three minutes, and soak them for three minutes in a basin containing this solution. Between clean cases soak the hands in zephiran for three minutes. Scrubbing with 1:1000 aqueous zephiran causes no real lather but a lather is obtained when one scrubs with 1:500 zephiran and this dilution may be employed for

scrubbing if it is desired. If the hands are moistened with zephiran they can be easily slipped into powdered, dry sterilized gloves. Most of those who have put on gloves in this manner feel that their hands are more comfortable than when they are put on dry with talcum powder. Although we have no objective proof it would seem likely that the film of zephiran on the hands would tend to inhibit growth of those organisms which may remain on the skin.

Zephiran in the Preparation of the Operative Field.—Zephiran has been used by a number of individuals in the preparation of the patient's skin before operation, but ordinarily in combination with some other antiseptic agent. Walter[12] reports that 2000 patients have undergone operation at the Peter Bent Brigham Hospital, with the operator using three changes of 1:1000 aqueous zephiran alternating with three changes of 70 per cent alcohol. He did not cite the incidence of wound infections. In 75 cases a biopsy was taken of the skin prepared in this manner from which cultures were made after maceration of the tissue. Seventy-three per cent showed no growth of organisms. White, Collins, and Newman[13] used a skin preparation of soap and water, benzine, alcohol, and tincture of zephiran, 1:1000. In fifty-one operative cases there was a single wound infection while there were seven wound infections (28 per cent) in twenty-five cases in which 3.5 per cent tincture of iodine was used in preparation of the skin. Biopsies of the skin taken before and after this clean up in fifty-one cases were cultured. In every instance there were organisms from the biopsy taken before skin preparation, in only two instances from biopsies taken after skin preparation.

Wright and Wilkinson[14] found zephiran very useful in traumatic surgery. One of us (H. B. S., Jr.) began to use zephiran for skin preparation in 1937, at which time he was a member of the surgical staff of the New Haven Hospital. The routine skin preparation in this hospital consisted of soap and water, alcohol, and 1:2000 aqueous zephiran. With this technique, in the year 1937-1938 the incidence of wound infection was as low as during any preceding year in which other germicidal agents had been used, the incidence in clean cases being 2.4 per cent including all stitch abscesses and other trivial infections as well as the more obvious wound infections.

In the 118th General Hospital the routine skin preparation before operation on the surgical service has consisted in sponging off the operative field with three or four changes of 1:2500 aqueous zephiran. Preceding this, the area has been shaved either dry or after simply wetting the area with aqueous zephiran. All members of the staff have been pleased with this routine. The incidence of stitch abscesses is not known but we have the impression that it is very low. There were three obvious wound infections in the first 350 clean cases thus prepared. One of these was a subcutaneous abscess under the donor area from

which pinch grafts were removed to be placed upon an infected granulating area. It appears that the donor site must have been contaminated by some faulty technique from the infected recipient area, or that the needle or procaine solution was contaminated. The second case was that of a superficial wound infection following repair of a ventral postoperative hernia which was carried out eleven weeks after exploration for multiple perforations of the bowel and only five weeks after a partially disrupted wound had healed. The third instance was that of an unexplained mild wound infection after inguinal herniorrhaphy. In none of these instances was sulfanilamide powder used. In a rather large number of the cases included in this group sulfanilamide powder in small amounts was implanted in the wound.

These data are not given as proof of the superiority of zephiran for preparation of the skin. In those reports mentioned other germicidal agents were used in conjunction with zephiran. In our own cases sulfanilamide powder was used locally in many wounds. Even if a series of cases was presented eliminating such factors, it would not necessarily furnish any conclusive evidence that the zephiran was responsible for the low incidence of wound infections. Many things must be considered in such an evaluation. Wound infections will be fewer when the surgical technique is gentle, when absolute hemostasis is achieved, when mass ligatures and strangulation of tissue are avoided, when small suture material is used, and when a rigid aseptic technique is maintained. In addition, there are two sources of organisms which may contaminate wounds other than the patient's skin, namely, the air of the operating room and the hands of the operator and his assistants. Indeed, there is much to suggest that the hands of the operating team may be more frequently the source of organisms causing wound infection than either the patient's skin or the air of the operating room. Gloves are punctured in a surprisingly large number of cases and a punctured glove may be responsible for thousands of organisms entering the wound. It is felt, however, that the data given do indicate that zephiran is a perfectly adequate agent for skin preparation. Furthermore, in vitro studies demonstrate it to have greater germicidal efficacy than most of the antiseptics commonly employed for this purpose. In addition, its cheapness commends it. It has other very distinct advantages for the preparation of skin.

It is easily applied and cleanses the skin well since it has a certain detergent and keratolytic action. It has not been necessary to use with it any other cleansing agent. In numerous instances when patients have been brought in after traumatic lacerations received on the streets, areas covered with grease and dirt have been cleaned without difficulty. Should the situation arise where it is felt that grease is being inadequately removed one might supplement the zephiran clean-up by sponging the area with ether. The solution is nonirritating to skin. From

a rather large personal experience and the reports of the literature examined, we know of no instance in which there has occurred dermatitis, burn, or any skin irritation due to the use of aqueous zephiran. In the dilute solutions which are employed it causes no reaction if it is allowed to run into the various body orifices and cavities. It has a great advantage in the preparation of the face where it can be allowed to run into the external auditory canal, eyes, nose, and the mouth without fear of tissue damage. One has no concern about the various body creases and folds as one does with so many of the antiseptics employed for skin preparation. One particular advantage of dilute aqueous zephiran is that it can be used freely in open wounds with apparently no deleterious tissue reaction. Walter[12] and Deskowitz[1] injected 1:1000 aqueous zephiran into the peritoneal cavities of guinea pigs daily for a long period of time and found that the solution caused no reaction, although more concentrated solutions did cause some fibrinous reaction. We have poured the solution freely into open wounds both in traumatic cases and in elective operations and have never noticed any tissue reaction or any retardation of healing. This is a marked contrast to the severe tissue damage which is caused by alcohol, iodine, and many other agents which are used in skin preparation. In traumatic lacerations the task of preparing the area about the wound is immensely simplified when one can permit the solution to run into the laceration.

If there is difficulty in preparing a hand or foot it may be useful to scrub the part with a brush wet with zephiran and soak it in a basin of this solution. For those who prefer to prepare the operative field some hours beforehand as well as immediately before operation, the area may be prepared with zephiran and covered with a wet zephiran dressing some hours before the patient is brought to the operating room and prepared again in the usual manner immediately before draping the patient. For most general surgical procedures there is no disadvantage and possibly some advantage in using a colorless solution, but where a large area must be prepared as, for example, in certain orthopedic operations it may be preferable to add to the zephiran solution some dye to impart color to the skin with which it comes in contact.

Although we have found 1:2500 aqueous zephiran to be satisfactory for the preparation of skin we are now using a 1:1000 solution since in vitro studies demonstrate that the 1:1000 solution kills organisms much more quickly than does the 1:2500. This is illustrated by the experiment described in Table IV. Twenty-one hemostats were immersed in a broth culture containing a luxuriant growth of *Staph. aureus, Str. hemolyticus, B. proteus, E. coli,* and *Clostridium tetani.* They were then placed upon a sterile field in order to dry and to allow the organisms to become fixed. Six of the clamps were then immersed for varying lengths of time in 1:2500 zephiran, another six in 1:1000 zephiran, and another six in an instrument-sterilization solution containing formalin

TABLE IV

EFFECTIVENESS OF 1:2500 AND 1:1000 AQUEOUS ZEPHIRAN IN THE STERILIZATION OF INSTRUMENTS

SOLUTION USED	ORGANISMS PRESENT AFTER SOAKING CONTAMINATED INSTRUMENT IN GERMICIDAL SOLUTION FOR VARYING LENGTHS OF TIME					
	1 MIN.	5 MIN.	10 MIN.	15 MIN.	20 MIN.	30 MIN.
Zephiran 1:2500	Gram–rods Gram+rods Gram+cocci Heavy	Gram–rods Gram+cocci Moderate	Gram–rods Gram+cocci Moderate	Rare Gram+rod Gram+cocci	Sterile	Sterile
Zephiran 1:1000	Moderate Gram–rods Rare Gram+cocci	Sterile	Sterile	Sterile	Sterile	Sterile
Instrument—sterilizing fluid	Sterile	Sterile	Sterile	Sterile	Sterile	Sterile
Control A:	Gram+cocci Gram–rods Gram+rods (rare) Heavy	Control B:	Gram+cocci Gram–rods Gram+rods Heavy	Control C:	Gram+cocci Gram–rods Gram+rods Heavy	

Control A: Instrument contaminated, allowed to dry and placed in culture medium. Control for viability of organisms.

Control B: Instrument contaminated, dried, placed in 1:1000 zephiran, washed, recontaminated, and cultured. Control for possible inhibition by traces of zephiran on instrument.

Control C: Instrument contaminated, dried, placed in instrument-sterilizing fluid, washed, recontaminated, and cultured. Control for possible inhibition by traces of instrument-sterilizing fluid on instrument.

which had been prepared in this hospital by Major W. B. Vandegrift for the cold sterilization of instruments. Following immersion in the various solutions each clamp was momentarily rinsed with sterile saline solution in order to remove traces of the germicidal agent and was then placed in a test tube containing Brewer's thioglycollate medium and incubated at 37° C. for twenty-four hours. The clamps were left in the medium for fourteen hours. One clamp was not immersed in any antiseptic solution but was placed in Brewer's thioglycollate medium as a control for the viability of the organisms. All of the organisms multiplied in large numbers (Control A). A second clamp was used as a control for the instrument-sterilizing solution, the clamp being recontaminated with organisms after it had been placed in the solution and had been rinsed with salt solution in the usual manner. All of the organisms grew readily, demonstrating that with the technique employed any traces of the germicidal agent present were insufficient to inhibit growth (Control C). A similar test with 1:1000 zephiran also showed that there was not enough zephiran present to inhibit growth of organisms (Control B). There was no growth from any of the contaminated clamps which had been placed in the instrument-sterilizing solution even after only one minute in the solution. There was a moderate growth of gram-negative rods and a rare gram-positive coccus from the contaminated clamp which had been in contact with 1:1000

zephiran for one minute, but there was no growth whatsoever from the clamps which had been in the solution for five minutes or more. There was some slight growth of organisms from the clamp which had been in contact with 1:2500 zephiran for fifteen minutes. It is not felt that this experiment forms a sufficient basis to permit any positive conclusion in regard to the utility of aqueous zephiran for the cold sterilization of instruments but it suggests that solutions as dilute as 1:1000 may be fairly satisfactory for this purpose. Of course if aqueous zephiran or any other aqueous solution is used for the cold sterilization of instruments it is necessary to add some substance to prevent rusting. It is our feeling that formalin solutions of the type marketed by Bard-Parker Company, Inc., are so eminently satisfactory for cold sterilization of instruments that solutions of this sort should preferably be used for this purpose.

Other Uses of Zephiran.—Dilute aqueous zephiran (1:1000 or 1:2500) has a number of other uses. It is ideal for washing instruments and the hands of the operating team during the course of an operation. Whereas 76 per cent of basins of sterile water so used were found to be contaminated at the close of the operation, Poppe[9] found that basins of 1:5000 aqueous zephiran were always sterile. Similarly, aqueous zephiran is useful for wash basins necessary in maintenance of isolation technique for cases of infectious disease. It is perfectly satisfactory for cleansing skin before venipunctures and various parenteral injections. Where instruments on dressing carriages are kept in some irritating sterilizing fluid, it is useful to keep alongside a jar of aqueous zephiran in which the instruments can be rinsed before being used. It is useful in compresses and soaks for various pyogenic skin lesions, and for epidermophytosis, particularly when it is associated with secondary infection. It is occasionally useful as a compress in clearing up infections of granulating areas. It works well as an irrigating solution for empyema and other abscess cavities. As a 1:20,000 solution it is satisfactory for urethral instillations. More concentrated solutions cause irritation. The possibilities of its use as instillations in the conjunctival sac for conjunctivitis and in preparation for ophthalmologic operations are under investigation in association with Capt. F. M. Reese. Instillations and tampons of 1:2500 zephiran have proved useful in treating various pyogenic and fungus infections of the external auditory canal. Zephiran in concentration of 1:50,000 has been found ideal for the preservation of biologic fluids such as bacteriophage and vaccines.[7]

The Use of Zephiran in Time of War.—In time of war certain considerations assume a significance which is not existant in time of peace, such as the conservation of materials which are vital in the making of munitions and military supplies. Such a substance is alcohol, of which enormous quantities are ordinarily employed in the practice of

medicine. It is used alone or in combination with other germicidal agents by the vast majority of physicians for the preparation of the patient's skin before operation, as a soak for hands after scrubbing, in preparing skin before venipuncture and various parenteral injections, for cleaning the skin when dressings are changed, and for many other purposes. For none of the purposes mentioned is it really necessary, and it is felt that by more extensive use of substances such as zephiran great quantities of alcohol can be conserved for purposes which are immediately more vital than these medical uses. Aqueous zephiran is a better germicidal agent and is more stable. It must be remembered that, although 70 per cent ethyl alcohol by weight is a good germicide, it is difficult to maintain this exact concentration, and that even slight changes in concentration render the solution totally ineffective against organisms.[10]

In regard to the medical services of the armed forces, certain other considerations arise. Scattered as the various medical installations are over the surface of the globe, transportation of medical supplies assumes gigantic proportions. If a substance can be transported in small volume which will do equally well the work that far greater volumes of some other agent will accomplish, there are obvious advantages in utilizing the former. If 1:2500 zephiran is employed, 250 gallons are available for use from each gallon of the concentrate transported to the medical unit. If 1:1000 zephiran is used 100 gallons are available for use from each gallon transported. Furthermore, it is entirely possible that should the armed forces desire to employ this agent in any considerable quantity, the manufacturers could supply the solid zephiran rather than the 1:10 concentrate, which would multiply again by ten the amount of solution available for use from each unit of material transported. Another feature which is desirable in the various medical installations is a simplification of the pharmaceutical armamentarium. Zephiran can be utilized so effectively in place of alcohol and the numbers of other germicidal agents which are ordinarily supplied, that it would seem worth while to substitute it for others. These considerations are particularly applicable in the forward medical installations such as the portable hospitals and the clearing companies of the medical battalions. It is our feeling that such units could perform a good service without any real handicap if they were supplied with adequate amounts of zephiran alone and no other bactericidal agents except for what alcohol is needed for the preparation of certain tinctures which may be advisable and except for a small amount of some formalin instrument-sterilization solution. A further consideration is that of expense, which remains important even at a time when Federal expenditures are necessarily gigantic. In the base from which this paper is written, zephiran, which is made in the United States and transported thousands of miles as a 1:10 concentrate, can be purchased at such a price that

1:1000 aqueous zephiran costs only approximately 13 cents per gallon, 1:2500 zephiran only about 5 cents per gallon. In contrast, the ingredients which are used in the preparation of liquid green soap bring the cost of this substance to about 25 cents a gallon, and the cost of alcohol is approximately 32 cents a gallon. Needless to say, many of the germicidal agents employed are a great deal more expensive. Another consideration which is of special importance is that of the preparation of the hands of the members of operating teams which can be carried out adequately with aqueous zephiran in any forward medical installation.

SUMMARY AND CONCLUSIONS

Zephiran is a cheap and reliable germicidal agent. In dilute solution it has been found to serve very satisfactorily for multiple purposes in hospital and medical practice and its sphere of usefulness appears to be steadily increasing. It serves ideally as an agent for preparing the skin of patients before operation. It has many advantages over some of the more commonly employed germicidal agents: cheapness and procurability, well proved high and nonspecific germicidal activity, failure to cause burns, dermatitis, or other irritation of skin and mucus membranes, ease of application. Studies indicate that a brief scrubbing of the hands and forearms in 1:1000 aqueous zephiran followed by a three-minute soak in this solution achieves, with ease, as thorough cleansing as prolonged scrubbing, in situations where facilities for proper scrubbing according to the generally used soap-and-water technique are not available. Since zephiran is used in dilute solution, large amounts are available for use from a relatively small amount of the concentrate or solid transported to any given point. Its use results in a conservation of alcohol which is essential for vital war products. Because of these considerations it is felt that a widespread use of this reliable agent is particularly desirable in time of war.

The authors wish to express their appreciation to Major Paul Kunkel who suggested that zephiran might prove of value in the preparation of hands, to Dr. Samuel C. Harvey for permission to cite statistics from the New Haven Hospital, and to 2nd Lt. Anne H. Seeney and the members of the operating room staff for their cooperation in carrying out the experiments.

REFERENCES

1. Deskowitz, M. G.: Some Germicidal and Physiological Properties of a Mixture of High Molecular Alkyl-Dimethyl-Benzyl-Ammonium Chlorides (Unpublished report); cited by Walter.[12]
2. Domagk, G.: Eine neue Klasse von Disenfektionsmitteln, Deutsche. med. Wchnschr. 61: 829-832, 1935.
3. Dunn, C. G.: Antiseptic and Germicidal Properties of a Mixture of High Molecular Alkyl-Dimethyl-Benzyl-Ammonium Chlorides, Am. J. Hyg. 26: 46-52, 1937.
4. Dunn, C. G.: A Comparative Study of Some Antiseptics and Germicides With Special Reference to Alkyl-Dimethyl-Benzyl-Ammonium Chlorides, Am. J. Surg. 41: 268-271, 1938.
5. Dunn, C. G.: Cited by Walter.[12]
6. Heineman, P. G.: Antiseptic Properties of Alkyl-Dimethyl-Benzyl-Ammonium Chloride, J. Am. Pharm. A. 26: 711-717, 1937.

7. Maier, E.: Preservation of Biological Fluids (Bacteriophage, Vaccines and Venom Solutions) With Alkyl-Dimethyl-Benzyl-Ammonium-Chloride, J. Bact. 38: 33-39, 1939.
8. Miller, B. F., Baker, Z., and Harrison, R. W.: Action of a Quarternary Ammonium Type of Wetting Agent on Metabolism of Microörganisms Associated With Dental Caries, Proc. Soc. Exper. Biol. & Med. 42: 705-706, 1939.
9. Poppe, J. K.: Wash Basin Contamination in Operating Rooms, Arch. Surg. 44: 103-107, 1942.
10. Price, P. B.: New Studies in Surgical Bacteriology and Surgical Technic, With Special Reference to Disinfection of Skin, J. A. M. A. 111: 1993-1996, 1938.
11. Price, P. B.: Personal communication.
12. Walter, C. W.: Use of a Mixture of Coconut Oil Derivatives as a Bactericide in the Operating Room, Surg., Gynec. & Obst. 67: 683-688, 1938.
13. White, C. S., Collins, J. L., and Newman, H. E.: The Clinical Use of Alkyl-Dimethyl-Benzyl-Ammonium Chloride (Zephiran), Preliminary Report, Am. J. Surg. 39: 607-609, 1938.
14. Wright, L. T., and Wilkinson, R. S.: The Use of Alkyl-Dimethyl-Benzyl-Ammonium Chloride in Injury, Am. J. Surg. 44: 626-630, 1939.

Book Reviews

Renal Lithiasis. By Charles C. Higgins. Pp. 140, with 18 illustrations. Springfield, Ill., 1943. Charles C Thomas.

This is a collection of Beaumont lectures. Considering its small size, it is a remarkably thorough discussion of renal lithiasis, and particularly of those factors which lead to the production of stones composed of phosphates and carbonates, although there is some discussion of other types. It seems to the reviewer that there is a little too much emphasis upon the role of deficiency of vitamin A in the diet, upon the reaction of the urine, and upon infection, since there are many cases in which these factors cannot be shown to have operated. The mechanism of formation of oxalate stones is not explained (I am not sure that anyone *can* explain it yet), and it is unfortunate that a book on lithiasis for the medical profession in general makes no mention of the importance of bone injury with prolonged recumbency as a factor in lithiasis, since this is one situation in which the formation of stones can probably be prevented by the alert physician.

It is questionable whether anyone besides the author has succeeded, or will succeed, in dissolving any considerable number of renal calculi by dietary regulation alone.

However, the book is of great value to all who are interested in urinary lithiasis, and should be read with care. It contains a map delineating stone areas, discussions of operative technique, and detailed tables of various diets intended for the dissolution or prevention of calculi of different types. There is a valuable bibliography.

The author also describes chemical methods for the recognition of the various constituents in stones. These are said to be far more accurate than those in general use.

INDEX TO VOLUME 14

AUTHORS INDEX*

In this index following the author's name, the title of the subject is given as it appeared in the JOURNAL. Editorials are also included in the list and are indicated by (*E*).

A

ALLEN, ARTHUR W. Carcinoma of colon, 350

ASHWORTH, C. T. (*See* Muirhead, Ashworth, Kregel, and Hill), 171

AYERS, WILLIAM B. (*See* Lyons, Owen, and Ayers), 99

B

BABCOCK, W. WAYNE, SANO, MACHTELD E., AND GIBSON, STUART B. Destructive angiocystic disease of pancreas, 588

BELLIS, CARROLL J. Study of physical factors concerned in inflammation; III. Fixation of bacteria in inflamed tissue, 111

BESSER, E. L., AND EHRENHAFT, J. L. Relationship of acute anemia to wound healing, 239

BETHEA, WILLIAM R., JR. (*See* Shumacker, Jr., and Bethea, Jr.), 931

BISGARD, J. DEWEY. Report of annual meeting of American Surgical Association, 473

BLALOCK, ALFRED. Consideration of present status of shock problem, 487

—, AND RAVITCH, MARK M. Consideration of nonoperative treatment of cardiac tamponade resulting from wounds of heart, 157

BOALS, ROBERT T. (*See* Harkins, Hooker, Boals, Brush, and Chunn), 891

BROWN, J. CHAIGNON. (*See* Gurdjian, Webster, and Brown), 876

BROWN, R. C., AND GHORMLEY, RALPH K. Solitary eccentric (cortical) abscess in bone, 541

BRUNSCHWIG, ALEXANDER, AND CORBIN, NANCY. Relative efficiency for nitrogen metabolism of casein digest administered intravenously and protein ingested by mouth, 898

BRUSH, BROCK E. (*See* Harkins, Hooker, Boals, Brush, and Chunn), 891

BURGER, RAY E. (*See* Morton, Shearburn, and Burger), 915

C

CASTEN, DANIEL. (*See* Stein and Casten), 819

CATTELL, RICHARD B. Carcinoma of colon and rectum, 378

CHENOWETH, ARTHUR I. Appendical abscess, 702

CHUNN, C. FRANK. (*See* Harkins, Hooker, Boals, Brush, and Chunn), 891

CLARK, BLISS B. (*See* Miscall and Clark), 83

COLEMAN, REESE C., JR. (*See* Wattenberg and Coleman, Jr.), 570

COLLER, FREDERICK A., AND EASTMAN, PETER F. Urinary retention following combined abdominoperineal resection, 223

CORBIN, NANCY. (*See* Brunschwig and Corbin), 898

CORRIGAN, FRANK P., AND PINES, IGNACY. Renal circulation after compression of renal artery according to method of Goldblatt, 88

CREEVY, C. D. Meeting of American Association of Genitourinary Surgeons, 798

CULLEN, STUART C. Use of curare for improvement of abdominal muscle relaxation during inhalation anesthesia, 261

—, AND QUINN, C. S. Use of curare in treatment of tetanus, 256

CUMMINGS, HARWOOD W. (*See* Flo and Cummings), 216

D

DAVID, VERNON C. Management of polyps occurring in rectum and colon, 387

DEBAKEY, MICHAEL. (*See* Ochsner and DeBakey), 679

DENNIS, CLARENCE. Simplified suture-testing apparatus, 640

DE TAKATS, GEZA. Effect of sulfur compounds on blood clotting, 661

DOOLITTLE, S. E. (*See* Strode and Doolittle), 847

*July, pp. 1-156; August, pp. 157-320; September, pp. 321-486; October, pp. 487-644; November, pp. 645-806; December, pp. 807-958.

DUNPHY, J. E., AND GIBSON, JOHN G., II. Effect of infusions of bovine serum albumin in experimental shock, 509

E

EASTMAN, PETER F. (*See* Coller and Eastman), 223

EHRENHAFT, J. L. (*See* Besser and Ehrenhaft), 239

F

FALLIS, LAURENCE SIDNEY. Anterior resection of rectosigmoid and upper rectum with re-establishment of continuity, 397

FINDLEY, THOMAS. (*See* Schwartz and Findley), 267

FLO, SPENCER C., AND CUMMINGS, HARWOOD W. Unilateral decapsulation of kidney for transfusion oliguria, 216

FLYNN, J. EDWARD. Surgical significance of middle palmar septum of hand, 134

FOSHEE, J. C. Fascia lata regeneration, 554

G

GAARDE, FRED W. (*See* Hausmann and Gaarde), 246

GHORMLEY, RALPH K. (*See* Brown and Ghormley), 541

GIBBS, EDWARD W., AND SUTTON, PAUL W. Intussusception—ninety-two cases in infancy and childhood, 708

GIBSON, JOHN G., II. (*See* Dunphy and Gibson, II), 509

GIBSON, STUART B. (*See* Babcock, Sano, and Gibson), 588

GILES, E. J. (*See* Mayerson, Long, and Giles), 519

GLASSER, R. D. (*See* Payne, Strauss, and Glasser), 719

GLASSER, S. THOMAS. Leg ulcers as complication of caisson disease, 302

GRACE, KENNETH D., AND IRWIN, THOMAS M. Perforation of cervical esophagus with mediastinitis, 631

GRAY, HOWARD K., AND SHARPE, WENDELL S. Surgical treatment of carcinoma of papilla of Vater, 831

GURDJIAN, E. S., WEBSTER, J. E., AND BROWN, J. CHAIGNON. Impression technique for reconstruction of large skull defects, 876

H

HARKINS, HENRY N. (*See* McClure and Harkins), 747

—. (*See* Swenson, Jr., and Harkins), 807

—, HOOKER, DONALD H., BOALS, ROBERT T., BRUSH, BROCK E., AND CHUNN, C. FRANK. Experimental studies on alimentary azotemia; IV. Role of liver and kidneys, 891

HAUSMANN, PAUL F., AND GAARDE, FRED W. Malignant neoplasm of spleen, 246

HENRY, CHARLES M., AND VALE, C. FREMONT. Abdominal puncture as diagnostic aid, 574

HILL, J. M. (*See* Muirhead, Ashworth, Kregel, and Hill), 171

HILL, WILLIAM R. (*See* Paletta and Hill), 32

HIRSHFELD, JOHN WINSLOW. (*See* Maun, Schneider, Pilling, and Hirshfeld), 229

HOOKER, DONALD H. (*See* Harkins, Hooker, Boals, Brush, and Chunn), 891

HOXWORTH, PAUL I. (*See* Zinninger and Hoxworth), 366

I

IRWIN, THOMAS M. (*See* Grace and Irwin), 631

J

JONES, THOMAS E. Consideration of elective surgical procedures in various segments of colon, 342

K

KELLY, EMERSON CROSBY. Nonpenetrating abdominal trauma, 163

KENNEY, WILLIAM E. Association of carcinoma in body and tail of pancreas with multiple venous thrombi, 600

KERNWEIN, GRAHAM A., AND QUEEN, FRANK B. Solitary eosinophilic granuloma, 105

KESAVALU, AUTHI, AND MANN, FRANK C. Influence of duodenal contents on intragastric acidity, 578

KEY, J. ALBERT. Kenny versus orthodox treatment of anterior poliomyelitis, 20

KREGEL, L. A. (*See* Muirhead, Ashworth, Kregel, and Hill), 171

L

LICH, ROBERT, JR., AND SAMSON, RALPH B. New simple and rapid method for hernial sac ligation, 306

LONG, CARROLL H. (*See* Mayerson, Long, and Giles), 519

LYONS, CHAMP, OWEN, CORA R., AND AYERS, WILLIAM B. Sulfonamide therapy in actinomycotic infections, 99

M

MANN, FRANK C. (*See* Kesavalu and Mann), 578

MATAS, RUDOLPH. Crile, Kelly, Lane, 1

MATHES, MARY E. (*See* Poth and Mathes), 617

MAUN, MARK E., SCHNEIDER, RICHARD C., PILLING, MATTHEW A., AND HIRSHFELD, JOHN WINSLOW. Tissue reactions to medicaments used in local treatment of burns, 229

MAYERSON, H. S., LONG, CARROLL H., AND GILES, E. J. Venous pressures in patients with varicose veins, 519

MCCLURE, ROY D., AND HARKINS, HENRY N. Recent advances in treatment of peripheral arterial embolism, 747

MEADE, RICHARD H., JR. Study of healing of abdominal operative wounds following closure of perforated ulcers of stomach and duodenum, 526

MEYER, KARL A., AND RAGINS, ALEX B. Carcinoma of parathyroid gland, 282

MILLER, R. B. (*See* Watson and Miller), 296

MISCALL, LAURENCE, AND CLARK, BLISS B. Murphy button in esophagogastrostomy, 83

MORTON, CHARLES BRUCE, SHEARBURN, EDWIN W., AND BURGER, RAY E. Synthetic vitamin K and thrombosis of veins following injury, 915

MUIRHEAD, E. E., ASHWORTH, C. T., KREGEL, L. A., AND HILL, J. M. Therapy of shock in experimental animals with serum protein solutions; II. Fate in body of concentrated and dilute serum and saline solutions, 171

N

NEWBURGER, BERNHARD. Early postoperative walking; II. Collective review, 142

O

OCHSNER, ALTON. Cancer of colon, 433 (*E*)

—, AND DEBAKEY, MICHAEL. Intravenous clotting and its sequelae, 679

ORD, A. G., SHACKMAN, RALPH, AND ROUALLE, H. L. M. Traumatic surgery, 651

OREMLAND, BENJAMIN H. (*See* Sarnoff and Oremland), 272

OWEN, CORA R. (*See* Lyons, Owen, and Ayers), 99

P

PACK, GEORGE T. (*See* Rekers, Pack, and Rhoads), 197

PALETTA, FRANCIS X., AND HILL, WILLIAM R. Acute perforated gastric and duodenal ulcers, 32

PAYNE, ROBERT L., STRAUSS, ARNOLD F., AND GLASSER, R. D. Mastitis obliterans, 719

PEARCE, MAUNSEL B. Varicose veins, 901

PILLING, MATTHEW A. (*See* Maun, Schneider, Pilling, and Hirshfeld), 229

PINES, BERNARD. (*See* Rabinovitch and Pines), 669

PINES, IGNACY. (*See* Corrigan and Pines), 88

POTH, EDGAR J. Congenital atresia of esophagus, 882

—, AND MATHES, MARY E. Treatment of acute empyema by continuous tidal irrigation, 617

PRIOLEAU, WILLIAM H. Treatment of abscess of thyroid gland causing tracheal obstruction, 871

PRIOR, JOHN A. (*See* Waugh and Prior), 125

Q

QUEEN, FRANK B. (*See* Kernwein and Queen), 105

QUINN, C. S. (*See* Cullen and Quinn), 256

R

RABINOVITCH, JACOB, AND PINES, BERNARD. Effect of heparin on experimentally produced venous thrombosis, 669

RAGINS, ALEX B. (*See* Meyer and Ragins), 282

RANSOHOFF, JOSEPH. (*See* Schnug and Ransohoff), 278

RAVDIN, I. S. (*See* Zintel, Rhoads, and Ravdin), 728

RAVITCH, MARK M. (*See* Blalock and Ravitch), 157

REKERS, P. E., PACK, GEORGE T., AND RHOADS, C. P. Metabolic studies in patients with cancer of gastrointestinal tract; VI. Disorders in alimentary digestion and absorption in patients who have undergone total gastrectomy for carcinoma of stomach, 197

RHOADS, C. P. (*See* Rekers, Pack, and Rhoads), 197

RHOADS, J. E. (*See* Zintel, Rhoads, and Ravdin), 728

RICHARDS, VICTOR. Sulfonamides in surgery, 308

ROBBINS, GUY F. Tumors of salivary gland origin, 924

ROUALLE, H. L. M. (*See* Ord, Shackman, and Roualle), 651
RUDDER, FRED F. Acute diverticulitis of jejunum, 921

S

SAMSON, RALPH B. (*See* Lich, Jr., and Samson), 306
SANO, MACHTELD E. (*See* Babcock, Sano, and Gibson), 588
SARNOFF, JACOB, AND OREMLAND, BENJAMIN H. Traumatic rupture of duodenum, 272
SCHNEIDER, RICHARD C. (*See* Maun, Schneider, Pilling, and Hirshfeld), 229
SCHNUG, EDWARD. Ligation of superior mesenteric vein, 610
—, AND RANSOHOFF, JOSEPH. Traumatic chylothorax—case treated with intravenous chyle, 278
SCHOTTENFELD, LEWIS E. Lipomas of gastrointestinal tract, 47
SCHWARTZ, HENRY G., AND FINDLEY, THOMAS. Preliminary observations concerning paravertebral injection of sympathetic system in hypertension, 267
SEEGERS, W. H. (*See* Tidrick, Seegers, and Warner), 191
SEIDENSTEIN, HOWARD ROBERT. Rectal stricture due to lymphogranuloma venereum, 73
SHACKMAN, RALPH. (*See* Ord, Shackman, and Roualle), 651
SHARPE, WENDELL S. (*See* Gray and Sharpe), 831
SHEARBURN, EDWIN W. Actinomycosis of stomach and duodenum, 38
—. (*See* Morton, Shearburn, and Burger), 915
SHUMACKER, HARRIS B., JR., AND BETHEA, WILLIAM R., JR. Some studies with zephrian, 931
SINGLETON, ALBERT O. Blood supply of large bowel with reference to resection, 328
—. One-stage perineo-abdominal operation for cancer of rectum, 691
SLAUGHTER, DANELY P. Role of surgery in treatment of malignant skin tumors, 732
STEIN, HERBERT P., AND CASTEN, DANIEL. Recurrences following inguinal herniopiasty, 819
STRAUSS, ARNOLD F. (*See* Payne, Strauss, and Glasser), 719
STRODE, J. E., AND DOOLITTLE, S. E. Chronic constrictive pericarditis, 847
SUTTON, PAUL W. (*See* Gibbs and Sutton), 708
SWENSON, SAMUEL A., JR., AND HARKINS, HENRY N. Surgical treatment of recurrent inguinal hernia with special reference to Cooper's ligament herniotomy and use of free fascial grafts, 807

T

TAKATS, GEZA DE. Effect of sulfur compounds on blood clotting, 661
THOMPSON, HOWARD T. Recurrent postoperative atelectasis, 866
TIDRICK, R. T., SEEGERS, W. H., AND WARNER, E. D. Clinical experience with thrombin as hemostatic agent, 191
TOUMEY, JAMES W. Sulfathiazole in chronic osteomyelitis, 531

V

VALE, C. FREMONT. (*See* Henry and Vale), 574

W

WAKELEY, CECIL P. G. New practical sigmoidoscope, 395
WALTON, FRANKLIN E. Surgical service of station hospital in Middle East, 645
WANGENSTEEN, OWEN H. Primary resection (closed anastomosis) of colon and rectosigmoid, 403
WARNER, E. D. (*See* Tidrick, Seegers, and Warner), 191
WATSON, JAMES R., AND MILLER R. B. Arteriovenous fistula of common femoral vessels with extreme dilatation of external iliac vein, 296
WATTENBERG, CARL A., AND COLEMAN, REESE C., JR. Sulfathiazole toxic nephrosis and kidney decapsulation, 570
WAUGH, RICHEY L., AND PRIOR, JOHN A. Traumatic rupture of spleen with delayed hemorrhage, 125
WEBSTER, J. E. (*See* Gurdjian, Webster, and Brown), 876
WELLS, L. J. Descent of testis: anatomical and hormonal considerations, 436
WHIPPLE, ALLEN O. Surgery of terminal ileum, cecum, and right colon, 321
WIKLE, HERBERT T. Unusual intra-abdominal foreign body, 122

Z

ZINNINGER, M. M. Mont Rogers Reid; In memoriam, 642
—, AND HOXWORTH, PAUL I. Cancer of colon, 366
ZINTEL, H. A., RHOADS, J. E., AND RAVDIN, I. S. Use of intravenous ammonium chloride in treatment of alkalosis, 728

SUBJECT INDEX*

Book reviews are indicated by (*B. Rev.*); editorials by (*E*).

A

Abdominal muscle relaxation during inhalation anesthesia, use of curare for improvement of (Cullen), 261
operative wounds, study of healing of, following closure of perforated ulcers of stomach and duodenum (Meade, Jr.), 526
puncture as diagnostic aid (Henry and Vale), 574
trauma, nonpenetrating (Kelly), 163
Abdominoperineal resection, combined, urinary retention following (Coller and Eastman), 223
Abscess, appendical (Chenoweth), 702
in bone, solitary eccentric (cortical) (Brown and Ghormley), 541
of thyroid gland causing tracheal obstruction, treatment of (Prioleau), 871
Absorption, disorders in alimentary digestion and (VI); Metabolic studies in patients with cancer of gastrointestinal tract (Rekers), 197
Acidity, intragastric, influence of duodenal contents on (Kesavalu and Mann), 578
Actinomycosis of stomach and duodenum (Shearburn), 38
Actinomycotic infections, sulfonamide therapy in (Lyons et al.), 99
Acute anemia, relationship of, to wound healing (Besser and Ehrenhaft), 239
diverticulitis of jejunum (Rudder), 921
empyema by continuous tidal irrigation, treatment (Poth and Mathes), 617
perforated gastric and duodenal ulcers (Paletta and Hill), 32
Albumin, bovine serum, in experimental shock, effect of infusions of (Dunphy and Gibson, II), 509
Alimentary azotemia, experimental studies on; IV. Role of liver and kidneys (Harkins et al.), 891
digestion and absorption, disorders in (VI); Metabolic studies in patients with cancer of gastrointestinal tract (Rekers et al.), 197
Alkalosis, treatment of, use of intravenous ammonium chloride in (Zintel et al.), 728
American Association of Genitourinary Surgeons, meeting of (Creevy), 798
Surgical Association, report of annual meeting of (Bisgard), 473
Ammonium chloride, intravenous, use of, in treatment of alkalosis (Zintel et al.), 728
Anastomosis, closed, primary resection of colon and rectosigmoid (Wangensteen), 403
Anema, acute, relationship of, to wound healing (Besser and Ehrenhaft), 239
Anesthesia, inhalation, use of curare for improvement of abdominal muscle relaxation during (Cullen), 261
Angiocystic disease of pancreas, destructive (Babcock et al.), 588
Appendical abscess (Chenoweth), 702
Arterial embolism, peripheral, recent advances in treatment of (McClure and Harkins), 747
Arteriovenous fistula of common femoral vessels with extreme dilatation of external iliac vein (Watson and Miller), 296
Artery, renal, compression of, renal circulation after, according to method of Goldblatt (Corrigan and Pines), 88
Atelectasis, recurrent postoperative (Thompson), 866
Atresia of esophagus, congenital (Poth), 882
Aviation, physiology in, 320 (*B. Rev.*)
Azotemia, alimentary, experimental studies on; IV. Role of liver and kidneys (Harkins et al.), 891

B

Bacteria, fixation of, in inflamed tissues (III): Physical factors concerned in inflammation (Bellis), 111
Blood clotting, effect of sulfur compounds on (de Takats), 661
groups and transfusion, 802 (*B. Rev.*)
supply of large bowel with reference to resection (Singleton), 328

*July, pp. 1-156; August, pp. 157-320; September, pp. 321-486; October, pp. 487-644, November, pp. 645-806; December, pp. 807-958.

Bone, abscess in, solitary eccentric (cortical) (Brown and Ghormley), 541
and joint injuries in wartime, review of some; traumatic surgery (Ord et al.), 651
Book reviews, 155-156, 320, 485-486, 644, 802-806, 946
Books received, 805-806
Bovine serum albumin in experimental shock, effect of infusions of (Dunphy and Gibson, II), 509
Bowel, large, blood supply of, with reference to resection (Singleton), 328
Burns, local treatment of, tissue reactions to medicaments used in (Maun et al.), 229
Button, Murphy, in esophagogastrostomy (Miscall and Clark), 83

C

Caisson disease, leg ulcers as complication of (Glasser), 302
Cancer of colon (Ochsner), 433 (*E*) (Zinninger and Hoxworth), 366
of gastrointestinal tract, metabolic studies in patients with (VI), (Rekers et al.), 197
of rectum, one-stage perineo-abdominal operation for (Singleton), 691
Carcinoma in body and tail of pancreas with multiple venous thrombi, association of (Kenney), 600
of colon (Allen), 350
and rectum (Cattell), 378
of papilla of Vater, surgical treatment of (Gray and Sharpe), 831
of parathyroid gland (Meyer and Ragins), 282
of rectal ampulla, abdomino-anal methods for restoration of continuity accompanying excision of; Primary resection (closed anastomosis) of colon and rectosigmoid (Wangensteen), 403
Cardiac tamponade, nonoperative treatment of, resulting from wounds of heart (Blalock and Raviteh), 157
Cardiology, short history of, 156 (*B. Rev.*)
Casein digest administered intravenously and protein ingested by mouth, clinical study of relative efficiency for nitrogen metabolism of (Brunschwig and Corbin), 898
Cecum, terminal ileum, and right colon, surgery of (Whipple), 321
Cervical esophagus, perforation of, with mediastinitis (Grace and Irwin), 631
Chloride, ammonium, intravenous, use of, in treatment of alkalosis (Zintel et al.), 728
Chronic constrictive pericarditis (Strode and Doolittle), 847
osteomyelitis, sulfathiazole in (Toumey), 531
Chyle, intravenous, traumatic chylothorax treated with (Schnug and Ransohoff), 278
Chylothorax, traumatic, treated with intravenous chyle (Schnug and Ransohoff), 278
Circulation, renal, after compression of renal artery according to method of Goldblatt (Corrigan and Pines), 88
Clinical experience with thrombin as hemostatic agent (Tidrick et al.), 191
Closure of perforated ulcers of stomach and duodenum, study of healing of abdominal operative wounds following (Meade, Jr.), 526
Clotting, blood, effect of sulfur compounds on (de Takats), 661
intravenous, and its sequelae (Ochsner and DeBakey), 679
Colon and rectosigmoid, primary resection (closed anastomosis) of (Wangensteen), 403
and rectum carcinoma of (Cattell), 378
management of polyps occurring in (David), 387
cancer of (Ochsner), 433 (*E*); (Zinninger and Hoxworth), 366
carcinoma of (Allen), 350
malignancy of, symposium on surgical management of, 321-435
right, terminal ileum, and cecum, surgery of (Whipple), 321
various segments of, consideration of elective surgical procedures in (Jones), 342
Congenital atresia of esophagus (Poth), 882
Constrictive pericarditis, chronic (Strode and Doolittle), 847
Continuity, re-establishment of, anterior resection of rectosigmoid and upper rectum with (Fallis), 397
Cooper's ligament herniotomy and use of free fascial grafts, surgical treatment of recurrent inguinal hernia with special reference to (Swenson and Harkins), 807
Cortical, solitary eccentric abscess in bone (Brown and Ghormley), 541
Crile, Kelly, Lane (Matas), 1
Curare, use of, for improvement of abdominal muscle relaxation during inhalation anesthesia (Cullen), 261
in treatment of tetanus (Cullen and Quinn), 256

D

Decapsulation, kidney, and sulfathiazole toxic nephrosis (Wattenberg and Coleman, Jr.), 570

Decapsulation—Cont'd
unilateral, of kidney for transfusion oliguria (Flo and Cummings), 216
Defects, large skull, impression technique for reconstruction of (Gurdjian et al.), 876
Descent of testis: Anatomical and hormonal considerations (Wells), 436
Diagnostic aid, abdominal puncture as (Henry and Vale), 574
Digest, casein, administered intravenously and protein ingested by mouth, clinical study of relative efficiency for nitrogen metabolism of (Brunschwig and Corbin), 898
Disability evaluation principles of treatment of compensable injuries, 155 (*B. Rev.*)
Disease, caisson, leg ulcers as complication of (Glasser), 302
destructive angiocystic, of pancreas (Babcock et al.), 588
Diseases of nose, throat and ear; medical and surgical, 803 (*B. Rev.*)
Dislocation, fractures, and sprains, management of, 320 (*B. Rev.*)
Diverticulitis, acute, of jejunum (Rudder), 921
Duodenal and perforated gastric ulcers, acute (Paletta and Hill), 32
contents, influence of, on intragastric acidity (Kesavalu and Mann), 578
Duodenum and stomach, actinomycosis of (Shearburn), 38
closure of perforated ulcers of, study of healing of abdominal operative wounds following (Meade, Jr.), 526
traumatic rupture of (Sarnoff and Oremland), 272

E

Ear, nose and throat, diseases of; medical and surgical, 803 (*B. Rev.*)
Early postoperative walking (II), (Newburger), 142
Eccentric, solitary (cortical) abscess in bone (Brown and Ghormley), 541
Embolism, peripheral arterial, recent advances in treatment of (McClure and Harkins), 747
Empyema by continuous tidal irrigation, treatment of acute (Poth and Mathes), 617
Eosinophilic granuloma, solitary (Kernwein and Queen), 105
Esophagogastrostomy, Murphy button in (Miscall and Clark), 83
Esophagus, cervical, perforation of, with mediastinitis (Grace and Irwin), 631
congenital atresia of (Poth), 882

F

Fascia lata regeneration (Foshee), 554
Fascial grafts, free, use of, and Cooper's ligament herniotomy, surgical treatment of recurrent inguinal hernia with special reference to (Swenson and Harkins), 807
Femoral vessels, common, arteriovenous fistula of, with extreme dilatation of external iliac vein (Watson and Miller), 296
Fistula, arteriovenous, of common femoral vessels with extreme dilatation of external iliac vein (Watson and Miller), 296
Foreign body, unusual intra-abdominal (Wikle), 122
Fracture, dislocation, and sprains, management of, 320 (*B. Rev.*)
Free fascial grafts, use of, and Cooper's ligament herniotomy, surgical treatment of recurrent inguinal hernia with special reference to (Swenson and Harkins), 807
Frei antigen and sulfonamide, in rectal stricture due to lymphogranuloma (Seidenstein), 73

G

Gastric and duodenal ulcers, acute perforated (Paletta and Hill), 32
Gastrointestinal tract, cancer of, metabolic studies in patients with (VI), (Rekers), 197
lipomas of (Schottenfeld), 47
Genitourinary surgeons, meeting of American Association of (Creevy), 798
Gland, parathyroid, carcinoma of (Meyer and Ragins), 282
salivary, origin of, tumors of (Robbins), 924
thyroid, abscess of, causing tracheal obstruction, treatment of (Prioleau), 871
Goldblatt, method of, renal circulation after compression of renal artery according to (Corrigan and Pines), 88
Gonadotropins; descent of testis (Wells), 436
Grafts, free fascial, use of, and Cooper's ligament herniotomy, surgical treatment of recurrent inguinal hernia with special reference to (Swenson and Harkins), 807
Granuloma, solitary eosinophilic (Kernwein and Queen), 105
Gynecology including female urology, 802 (*B. Rev.*)

H

Hand, middle palmar septum of, surgical significance of (Flynn), 134

Healing, wound relationship of acute anemia to (Besser and Ehrenhaft), 239
Heart, wounds of, nonoperative treatment of cardiac tamponade resulting from (Blalock and Ravitch), 157
Hemorrhage, delayed, traumatic rupture of spleen with (Waugh and Prior), 125
Hemostatic agent, thrombin as, clinical experience with (Tidrick et al.), 191
Heparin, effect of, on experimentally produced venous thrombosis (Rabinovitch and Pines), 669
Hernia, recurrent inguinal, surgical treatment of, with special reference to Cooper's ligament herniotomy and use of free fascial grafts (Swenson and Harkins), 807
Hernial sac ligation, new simple and rapid methods for (Lich, Jr., and Samson), 306
Herniopiasty, inguinal, recurrences following (Stein and Casten), 819
Herniotomy, Cooper's ligament, and use of free fascial grafts, surgical treatment of recurrent inguinal hernia with special reference to (Swenson and Harkins), 807
Hormonal and anatomical considerations: descent of testis (Wells), 436
Hospital, station, surgical service of, in Middle East (Walton), 645
Hypertension, sympathetic system in, preliminary observations concerning paravertebral injection of (Schwartz and Findley), 267

I

Ileum and small intestine, lipomas of (Schottenfeld), 47
terminal, cecum, and right colon, surgery of (Whipple), 321
Iliac vein, external, arteriovenous fistula of common femoral vessels with extreme dilatation of (Watson and Miller), 296
Impression technique for reconstruction of large skull defects (Gurdjian et al.), 876
Infections, actinomycotic, sulfonamide therapy in (Lyons et al.), 99
Inflammation, physical factors concerned in (III), (Bellis), 111
Inguinal hernia, recurrent, surgical treatment of, with special reference to Cooper's ligament herniotomy and use of free fascial grafts (Swenson and Harkins), 807
herniopiasty, recurrences following (Stein and Casten), 819
Inhalation anesthesia, use of curare for improvement of abdominal muscle relaxation during (Cullen), 261
Injection, paravertebral, of sympathetic system in hypertension, preliminary observations concerning (Schwartz and Findley), 267
Intestine, small, and ileum, lipomas of (Schottenfeld), 47
Intra-abdominal foreign body, unusual (Wikle), 122
Intragastric acidity, influence of duodenal contents on (Kesavalu and Mann), 578
Intravenous ammonium chloride, use of, in treatment of alkalosis (Zintel et al.), 728
chyle, traumatic chylothorax treated with (Schnug and Ransohoff), 278
clotting and its sequelae (Ochsner and DeBakey), 679
Intussusception in infancy and childhood (Gibbs and Sutton), 708
Irritation, continuous tidal, treatment of acute empyema by (Poth and Mathes), 617

J

Jejunum, acute diverticulitis of (Rudder), 921
Joint and bone injuries in wartime, review of some; traumatic surgery (Ord et al.), 651

K

K, vitamin, synthetic, and thrombosis of veins following injury (Morton et al.), 915
Kelly, Lane, Crile (Matas), 1
Kenny versus orthodox treatment of anterior poliomyelitis (Key), 20
Kidney decapsulation and sulfathiazole toxic nephrosis (Wattenberg and Coleman, Jr.), 570
unilateral decapsulation of, for transfusion oliguria (Flo and Cummings), 216
Kidneys and liver, role of (IV); Experimental studies on alimentary azotemia (Harkins et al.), 891

L

Lane, Crile, Kelly (Matas), 1
Leg ulcers as complication of caisson disease (Glasser), 302
Ligation, hernial sac, new simple and rapid method for (Lich, Jr., and Samson), 306
of superior mesenteric vein (Schnug), 610
Lipomas of gastrointestinal tract (Schottenfeld), 47
Liver and kidneys, role of (IV); Experimental studies on alimentary azotemia (Harkins et al.), 891
Local treatment of burns, tissue reactions to medicaments used in (Maun et al.), 229

Lymph node metastases, 644 (*B. Rev.*)
Lymphogranuloma venereum, rectal stricture due to (Seidenstein), 73
Lymphosarcoma, primary (reticulum-cell type); Malignant neoplasms of spleen (Hausmann and Gaarde), 246

M

Malignant neoplasms of spleen (Hausmann and Gaarde), 246
Mastitis obliterans (Payne et al.), 719
Metastases, lymph node, 644 (*B. Rev.*)
Mediastinitis, perforation of cervical esophagus with (Grace and Irwin), 631
Medicaments used in local treatment of burns, tissue reactions to (Mann et al.), 229
Meetings, recent, review of, 473, 798
Mesenteric vein, ligation of superior (Schnug), 610
Metabolic studies in patients with cancer of gastrointestinal tract (VI), (Rekers et al.), 197
Metabolism, nitrogen, of casein digest administered intravenously and protein ingested by mouth, clinical study of relative efficiency for (Brunschwig and Corbin), 898
Middle palmar septum of hand, surgical significance of (Flynn), 134
Murphy button in esophagogastrostomy (Miscall and Clark), 83
Muscle relaxation, abdominal, during inhalation anesthesia, use of curare for improvement of (Cullen), 261

N

Neoplasms, malignant, of spleen (Hausmann and Gaarde), 246
Nephrosis, sulfathiazole toxic, and kidney decapsulation (Wattenberg and Coleman, Jr.), 570
Nervous system, diseases of, roentgen treatment of, 155 (*B. Rev.*)
Nitrogen metabolism of casein digest administered intravenously and protein ingested by mouth, clinical study of relative efficiency for (Brunschwig and Corbin), 898
Nonoperative treatment of cardiac tamponade resulting from wounds of heart (Blalock and Ravitch), 157
Nonpenetrating abdominal trauma (Kelly), 163
Nose, throat and ear, diseases of; medical and surgical, 803 (*B. Rev.*)

O

Obliterans, mastitis (Payne et al.), 719
Obstruction, tracheal, treatment of abscess of thyroid gland causing (Prioleau), 871
Oliguria, transfusion, unilateral decapsulation of kidney for (Flo and Cummings), 216
One-stage perineo-abdominal operation for cancer of rectum (Singleton), 691
Operation, one-stage perineo-abdominal, for cancer of rectum (Singleton), 691
Orthodox versus Kenny treatment of anterior poliomyelitis (Key), 20
Orthopedic subjects, 485 (*B. Rev.*)
Osteomyelitis, chronic sulfathiazole in (Toumey), 531

P

Palmar septum, middle, of hand, surgical significance of (Flynn), 134
Pancreas, body and tail of, association of carcinoma in, with multiple venous thrombi (Kenney), 600
destructive angiocystic disease of (Babcock et al.), 588
Papilla of Vater, carcinoma of, surgical treatment of (Gray and Sharpe), 831
Parathyroid gland, carcinoma of (Meyer and Ragins), 282
Paravertebral injection of sympathetic system in hypertension, preliminary observations concerning (Schwartz and Findley), 267
Perforated gastric and duodenal ulcers, acute (Paletta and Hill), 32
Perforation of cervical esophagus with mediastinitis (Grace and Irwin), 631
Pericarditis, chronic constrictive (Strode and Doolittle), 847
Perineo-abdominal operation, one-stage, for cancer of rectum (Singleton), 691
Peripheral arterial embolism, recent advances in treatment of (McClure and Harkins), 747
Physical factors concerned in inflammation (III), (Bellis), 111
Physiology in aviation, 320 (*B. Rev.*)
Poliomyelitis, anterior, Kenny versus orthodox treatment of (Key), 20
Polyps occurring in rectum and colon, management of (David), 387
Postoperative atelectasis, recurrent (Thompson), 866
walking, early (II), (Newburger), 142
Pressures, venous, in patients with varicose veins (Mayerson et al.), 519
Prostatectomy, transurethral, 801 (*B. Rev.*)
Protein ingested by mouth and casein digest administered intravenously, clinical study of relative effi-

Protein—Cont'd
ciency for nitrogen metabolism of (Brunschwig and Corbin), 898
solutions, serum, therapy of shock in experimental animals with (II), (Muirhead et al.), 171
Puncture, abdominal, as diagnostic aid (Henry and Vale), 574

R

Reactions, tissue, to medicaments used in local treatment of burns (Maun et al.), 229
Reconstruction of large skull defects, impression technique for (Gurdjian et al.), 876
Rectal stricture due to lymphogranuloma venereum (Seidenstein), 73
Rectosigmoid and colon, primary resection (closed anastomosis) of (Wangensteen), 403
and upper rectum, anterior resection of, with re-establishment of continuity (Fallis), 397
Rectum and colon, carcinoma of (Cattell), 378
management of polyps occurring in (David), 387
cancer of, one-stage perineo-abdominal operation for (Singleton), 691
upper, and rectosigmoid, anterior resection of, with re-establishment of continuity (Fallis), 397
Recurrences following inguinal herniaplasty (Stein and Casten), 819
Recurrent postoperative atelectasis (Thompson), 866
Regeneration, fascia lata (Foshee), 554
Reid, Mont Rogers; In memoriam (Zinninger), 642
Renal artery, renal circulation after compression of, according to method of Goldblatt (Corrigan and Pines), 88
circulation after compression of renal artery according to method of Goldblatt (Corrigan and Pines), 88
lithiasis, 946 (*B. Rev.*)
Resection, anterior, of rectosigmoid and upper rectum with re-establishment of continuity (Fallis), 397
blood supply of large bowel with reference to (Singleton), 328
combined abdominoperineal, urinary retention following (Coller and Eastman), 223
primary (closed anastomosis) of colon and rectosigmoid (Wangensteen), 403
Retention, urinary, following combined abdominoperineal resection (Coller and Eastman), 223
Rib fractures, traumatic rupture of spleen with delayed hemorrhage as complication of (Waugh and Prior), 125
Roentgen treatment of diseases of nervous system, 155 (*B. Rev.*)
Rupture, traumatic, of duodenum (Sarnoff and Oremland), 272
of spleen, with delayed hemorrhage (Waugh and Prior), 125

S

Saline concentrated and dilute serum solutions and, fate in body of (II): Therapy of shock in experimental animals with serum protein solutions (Muirhead et al.), 171
Salivary gland, origin of, tumors of (Robbins), 924
Septum, middle palmar, of hand, surgical significance of (Flynn), 134
Sequelae, intravenous clotting and its (Ochsner and DeBakey), 679
Serum albumin, bovine, in experimental shock, effect of infusions of (Dunphy and Gibson, II), 509
concentrated and dilute and saline solutions, fate in body of (II): Therapy of shock in experimental animals with serum protein solutions (Muirhead et al.), 171
protein solutions, therapy of shock in experimental animals with (II), (Muirhead et al.), 171
Shock, experimental, bovine serum albumin in, effect of infusions of (Dunphy and Gibson, II), 509
problem, consideration of present status of (Blalock), 487
therapy of, in experimental animals with serum protein solutions (II), (Muirhead et al.), 171
Sigmoidoscope, new practical (Wakeley), 395
Skin tumors, malignant, role of surgery in treatment of (Slaughter), 732
Skull defects, large, impression technique for reconstruction of (Gurdjian et al.), 876
Solitary eccentric (cortical) abscess in bone (Brown and Ghormley), 541
eosinophilic granuloma (Kernwein and Queen), 105
Solutions, serum protein, therapy of shock in experimental animals with (II), (Muirhead), 171
Spleen, malignant neoplasms of (Hansmann and Gaarde), 246
traumatic rupture of, with delayed hemorrhage (Waugh and Prior), 125
Sprains, fractures, and dislocations, management of, 320 (*B. Rev.*)
Station hospital, surgical service of, in Middle East (Walton), 645
Stomach and duodenum, actinomycosis of (Shearburn), 38

Stomach and duodenum—Cont'd
closure of perforated ulcers of, study of healing of abdominal operative wounds following (Meade, Jr.), 526
Stricture, rectal, due to lymphogranuloma venereum (Seidenstein), 73
Sulfathiazole in chronic osteomyelitis (Toumey), 531
toxic nephrosis and kidney decapsulation (Wattenberg and Coleman, Jr.), 570
Sulfonamide and Frei antigen, in rectal stricture due to lymphogranuloma venereum (Seidenstein), 73
therapy in actinomycotic infections (Lyons et al.), 99
Sulfonamides in surgery (Richards), 308
Sulfur compounds, effect of, on blood clotting (de Takats), 661
Surgery, role of, in treatment of malignant skin tumors (Slaughter), 732
sulfonamides in (Richards), 308
terminal ileum, cecum, and right colon (Whipple), 321
traumatic (Ord et al.), 651
war, principles and practice of, 485 (*B. Rev.*)
Surgical association, American, report of annual meeting of (Bisgard), 473
procedures, elective, consideration of, in various segments of colon (Jones), 342
service of station hospital in Middle East (Walton), 645
significance of middle palmar septum of hand (Flynn), 134
treatment of carcinoma of papilla of Vater (Gray and Sharpe), 831
of recurrent inguinal hernia with special reference to Cooper's ligament herniotomy and use of free fascial grafts (Swenson and Harkins), 807
Suture testing apparatus, simplified (Dennis), 640
Sympathetic system in hypertension, preliminary observations concerning paravertebral injection of (Schwartz and Findley), 267
Symposium on surgical management of malignancy of colon, 321 435
System, sympathetic, in hypertension, preliminary observations concerning paravertebral injection of (Schwartz and Findley), 267

T

Tamponade, cardiac, nonoperative treatment of, resulting from wounds of heart (Blalock and Ravitch), 157
Technique, impression, for reconstruction of large skull defects (Gurdjian et al.), 876
Testis, descent of: Anatomical and hormonal considerations (Wells), 436
Tetanus, use of curare in treatment of (Cullen and Quinn), 256
Therapy, sulfonamide, in actinomycotic infections (Lyons et al.), 99
Throat, nose and ear, diseases of; medical and surgical, 803 (*B. Rev.*)
Thrombi, multiple venous, association of carcinoma in body and tail of pancreas with (Kenney), 600
Thrombin as hemostatic agent, clinical experience with (Tidrick et al.), 191
Thrombosis of veins and synthetic vitamin K following injury (Morton et al.), 915
venous, experimentally produced, effect of heparin on (Rabinovitch and Pines), 669
Thyroid gland, abscess of, causing tracheal obstruction, treatment of (Prioleau), 871
Tidal irrigation, continuous, treatment of acute empyema by (Poth and Mathes), 617
Tissue reactions to medicaments used in local treatment of burns (Maun et al.), 229
Tissues, inflamed, fixation of bacteria in (III): Physical factors concerned in inflammation (Bellis), 111
Tracheal obstruction, treatment of abscess of thyroid gland causing (Prioleau), 871
Tract, gastrointestinal, cancer of, metabolic studies in patients with (VI), (Rekers), 197
lipomas of (Schottenfeld), 47
Transfusion and blood groups, 802 (*B. Rev.*)
oliguria, unilateral decapsulation of kidney for (Flo and Cummings), 216
Transurethral prostatectomy, 804 (*B. Rev.*)
Trauma, nonpenetrating abdominal (Kelly), 163
Traumatic chylothorax, treated with intravenous chyle (Schnug and Ransohoff), 278
rupture of duodenum (Sarnoff and Oremland), 272
of spleen with delayed hemorrhage (Waugh and Prior), 125
surgery (Ord et al.), 651
Treatment, local, of burns, tissue reactions to medicaments used in (Maun et al.), 229
nonoperative, of cardiac tamponade resulting from wounds of heart (Blalock and Ravitch), 157
orthodox, of anterior poliomyelitis, Kenny versus (Key), 20

Treatment—Cont'd
surgical, of carcinoma of papilla of Vater (Gray and Sharpe), 831
of recurrent inguinal hernia with special reference to Cooper's ligament herniotomy and use of free fascial grafts (Swenson and Harkins), 807
Tumors of salivary gland origin (Robbins), 924
skin, malignant, role of surgery in treatment of (Slaughter), 732

U

Ulcers, acute perforated gastric and duodenal (Paletta and Hill), 32
leg, as complication of caisson disease (Glasser), 302
perforated, of stomach and duodenum, study of healing of abdominal operative wounds following closure of (Meade, Jr.), 526
Unilateral decapsulation of kidney for transfusion oliguria (Flo and Cummings), 216
Urinary retention following combined abdominoperineal resection (Coller and Eastman), 223
Urology, female, gynecology including, 802 (*B. Rev.*)

V

Varicose veins (Pearce), 901
venous pressures in patients with (Mayerson et al.), 519
Vater, papilla of, surgical treatment of carcinoma of (Gray and Sharpe), 831
Vein, external iliac, arteriovenous fistula of common femoral vessels with extreme dilatation of (Watson and Miller), 296
superior mesenteric, ligation of (Schnug), 610
Veins, thrombosis of, and synthetic vitamin K following injury (Morton et al.), 915
varicose (Pearce), 901
venous pressures in patients with (Mayerson et al.), 519
Venereum, lymphogranuloma, rectal stricture due to (Seidenstein), 73
Venous pressures in patients with varicose veins (Mayerson et al.), 519
thrombi, multiple, association of carcinoma in body and tail of pancreas with (Kenney), 600
thrombosis, experimentally produced, effect of heparin on (Rabinovitch and Pines), 669
Vitamin K, synthetic, and thrombosis of veins following injury (Morton et al.), 915

W

Walking, early postoperative (II), (Newburger), 142
War, studies on use of zephiran in time of (Shumacker, Jr., and Bethea, Jr.), 931
surgery, principles and practice of, 485 (*B. Rev.*)
Wartime, review of some bone and joint injuries in; traumatic surgery (Ord et al.), 651
Wound healing, relationship of acute anemia to (Besser and Ehrenhaft), 239
Wounds, abdominal operative, study of healing of, following closure of perforated ulcers of stomach and duodenum (Meade, Jr.), 526

Z

Zephiran, some studies with; its use in time of war (Shumacker, Jr. and Bethea, Jr.), 931